

# We are IntechOpen, the world's leading publisher of Open Access books Built by scientists, for scientists

**4,800**

Open access books available

**122,000**

International authors and editors

**135M**

Downloads

Our authors are among the

**154**

Countries delivered to

**TOP 1%**

most cited scientists

**12.2%**

Contributors from top 500 universities



**WEB OF SCIENCE™**

Selection of our books indexed in the Book Citation Index  
in Web of Science™ Core Collection (BKCI)

Interested in publishing with us?  
Contact [book.department@intechopen.com](mailto:book.department@intechopen.com)

Numbers displayed above are based on latest data collected.

For more information visit [www.intechopen.com](http://www.intechopen.com)



# Liver Biopsy in Transplantation: Nonalcoholic Fatty Liver Disease and the Eosinophils

Kishi, Sugawara and Kokudo  
*University of Tokyo,  
Japan*

## 1. Introduction

Liver biopsy is important in the perioperative management of liver transplantation with regard to the preoperative evaluation of donor liver graft, especially to rule out steatotic liver, and the postoperative diagnosis of acute cellular rejection (ACR), especially to differentiate ACR from other causes of liver dysfunction. In both situations, liver biopsy is mandatory to confirm the diagnosis.

The recent increases in metabolic syndrome and diabetes mellitus in the general population have led to an increased incidence of liver steatosis, even in donors without a history of excessive alcohol intake. Nonalcoholic fatty liver disease (NAFLD) includes a broad spectrum of liver injuries that resemble alcoholic hepatitis, ranging from simple steatosis to nonalcoholic steatohepatitis (NASH). NASH is the progressed stage of NAFLD and further progression results in fibrosis and cirrhosis, which might also be an indication for liver transplantation. ACR is one of the most serious adverse events after transplantation. It is often difficult to distinguish it from recurrent hepatitis C virus (HCV), and prompt treatment with an appropriate diagnosis is important.

In this chapter, the indications for liver biopsy and the histologic findings for the diagnosis of NAFLD and ACR are described.

## 2. NAFLD

The pathophysiology of NAFLD is yet to be fully elucidated, although the two-hit story proposed by James et al.<sup>1</sup> is widely accepted. In their hypothesis, insulin resistance is the first hit, resulting in the production and accumulation of triglycerides in the liver due to dysregulated lipogenesis and lipolysis. Further, oxidative stress and lipid peroxidation as the second hit leads to hepatic injury, inflammation, and fibrosis by multiple cytokines and adipokines. The prevalence of NAFLD is therefore associated with metabolic syndrome and will thus continue to increase in developed countries. Previous autopsy studies<sup>2-6</sup> in Western countries reported the incidence of NAFLD as 16% to 64% of the population. The incidence in the Asian-Pacific region is also increasing and is currently 10% to 30%<sup>7</sup>.

Therefore, hepatectomy or transplantation for NAFLD related cirrhosis or hepatocellular carcinomas will likely increase. In addition, because NAFLD is usually asymptomatic and the diagnosis can be confirmed only by biopsy, the possibility to encounter the liver donor with NAFLD will also increase. Whether hepatic steatosis is associated with impaired liver regeneration or an increased risk of morbidity or mortality after liver surgery is

controversial. Selzner and Clavien<sup>8</sup> showed impaired liver regeneration in steatotic livers using rat models. Similarly, impaired regeneration of steatotic liver after large hepatectomy or portal vein ligation was reported in subsequent rat model experiments.<sup>9,10</sup> In the clinical setting, Kooby et al.<sup>11</sup> evaluated the outcomes of hepatic resection in 160, 223, and 102 patients with no, mild (<30%), and marked ( $\geq 30\%$ ) steatosis, respectively, and showed that preoperative comorbidity, steatosis, blood loss, and resection of one lobe or more were independent predictors of postoperative morbidity.

Vauthey et al.<sup>12</sup> reported that steatohepatitis induced by irinotecan-based chemotherapy is associated with an increased risk of 90-day mortality after hepatic resection for colorectal metastases. On the other hand, Hussein et al. reported a comparable Ki-67 labeling index which is a marker of liver regeneration among three groups of patients with simple fatty liver (9 patients), NASH (13 patients), and chronic hepatitis C (25 patients), with a similar degree of inflammation. They concluded that liver regeneration in patients with NASH is not altered.<sup>13</sup> The number of patients included in this study was small, however, and no patients underwent hepatic resection. Further, the Ki-67 labeling index in patients with NASH was smaller than that in patients with fatty liver or HCV, although the difference was not statistically significant. Considering that NAFLD is a progressive disease ultimately resulting in liver cirrhosis, liver-related surgery must be performed with special attention to the patient's safety. Safety is the first priority in any patient, and especially in living organ donors. In general, most transplantation centers do not accept live donors with histologic liver steatosis of greater than 30%.<sup>14,15</sup> Actually one donor death with NASH has been reported<sup>15</sup>. The controversy surrounds whether all liver donor candidates should undergo liver biopsy because diagnosis of NAFLD can be made only by histopathologic examination. Body mass index (BMI) is widely regarded as a predictor of liver steatosis. Rinella et al.<sup>16</sup> reported that no hepatic steatosis was observed among biopsy specimens of live-liver donor candidates with a BMI of less than 25 kg/m<sup>2</sup>, while hepatic steatosis was found in 76% of candidates with BMI greater than 28 kg/m<sup>2</sup>. On the other hand, other studies<sup>17,18</sup> demonstrated that 7% to 26% of donor candidates with a BMI of less than 25 kg/m<sup>2</sup> had hepatic steatosis. Yamashiki et al. recently proposed the following criteria for donor biopsy: an aspartate aminotransferase/alanine aminotransferase ratio of less than 1, BMI of at least 25, and ultrasonography findings suggestive of steatosis. Based on these criteria, liver biopsy was indicated for 25% of their referred Japanese donor candidates, and hepatic steatosis of at least 10% was revealed in 12% of the donor candidates. Further, they evaluated the visceral fat area measured from a single CT slice image at the level of the umbilicus. Receiver operating characteristic curve analysis showed that a visceral fat area of at least 96 cm<sup>2</sup> predicted steatosis of 10% or more with a sensitivity and specificity of 78% and 87%, respectively<sup>19</sup>.

NASH can be an indication for liver transplantation, but it also can recur or even occur de novo in the transplanted liver graft. In general, immunosuppression with corticosteroids, calcineurin inhibitors, or sirolimus is associated with body weight gain, insulin resistance, and hyperlipidemia. Therefore, post-transplant patients are susceptible to developing NAFLD. Poodad et al.<sup>20</sup> reported de novo NAFLD that occurred within 3 months of liver transplantation in 4 of 88 patients. Later, Seo et al.<sup>21</sup> evaluated the incidence and predictors of de novo NAFLD among 68 recipients. De novo NAFLD was diagnosed in 12 patients (18%) based on follow-up biopsy specimens 11 to 51 months after transplantation. NASH was diagnosed in 6 patients (9%). Multivariate analyses showed that a BMI increase of more than 10% was a risk factor and the use of angiotensin-converting enzyme inhibitors was associated with reduced risk of de novo NAFLD. Although NAFLD in one of the patients in Poodad's report showed improvement following treatment with ursodeoxycholic acid (UDCA)<sup>20</sup>, a subsequent randomized control trial<sup>22</sup> showed no therapeutic effect of UDCA

for the treatment of NASH compared to placebo. To date, there is no established treatment to improve NASH, and prevention should be the first priority.

### 3. Histology

The important factor in the diagnosis of NAFLD is the differentiation of NASH from simple steatosis or steatosis with inflammation. For this purpose, several scoring systems have been proposed to date.

Histologic characteristics of NASH include (1) macrovesicular steatosis, (2) hepatocellular ballooning and disarray, (3) intra-lobular inflammation, (4) portal tract inflammation, (5) Mallory's hyaline bodies, (6) acidophil bodies, (7) PAS-D Kupffer cells, (8) glycogenated nuclei, (9) lipogranulomas, and (10) hepatocellular iron. Brunt et al. evaluated these variables semiquantitatively and proposed three grades (mild, moderate, and severe) for necroinflammatory changes. Fibrosis was evaluated separately and scored as stage 1, zone 3 perisinusoidal/pericellular fibrosis; stage 2, zone 3 perisinusoidal/pericellular fibrosis with focal or extensive periportal fibrosis; stage 3, zone 3 perisinusoidal/pericellular fibrosis and portal fibrosis with focal or extensive fibrosis; and stage 4, cirrhosis<sup>23</sup>. Promrat et al.<sup>24</sup> demonstrated the histologic improvement of NASH by pioglitazone, which is an insulin-sensitizing agent, and introduced another scoring system. In this system, six factors; steatosis, hepatocellular injury (ballooning degeneration /apoptosis/dropout cells), parenchymal inflammation, portal inflammation, fibrosis, and Mallory bodies, were evaluated and each was scored semiquantitatively from 0 to 4.

Feature	Category	Score
Steatosis grade	<5%	0
	5%-33%	1
	>33%-66%	2
	>66%	3
Lobular inflammation	No foci	0
	<2 foci	1
	2-4 foci	2
	>4 foci	3
Ballooning degeneration	None	0
	Few	1
	Many	2

Table 1. Kleiner's scoring system for the diagnosis of NAFLD. The sum of the scores (ranging 0-8): 0-2, not NASH;  $\geq 5$ , NASH

These scoring systems, however, emphasize NASH and did not encompass the entire spectrum of NAFLD. Later, the Pathology Committee of the NASH Clinical Research Network proposed a NAFLD activity scoring system that addressed the full spectrum of NAFLD and this was reported by Kleiner et al.<sup>25</sup> in 2005. In this study, 14 variables in 5 broad categories; steatosis, inflammation, hepatocellular injury, fibrosis, and miscellaneous features, were evaluated in 32 adult and 18 pediatric liver biopsy specimens by 9 pathologists. Based on the intra-rater and inter-rater agreement analysis and multivariate analysis for the association of the variables with a diagnosis of steatohepatitis, the NAFLD activity index was defined as the sum of the scores of three variables; steatosis, lobular inflammation, and ballooning (Table 1). Although fibrosis is considered an independent

predictor, it was not included because it is less a reversible change and more a result of disease activity than a feature of injury activity.

#### 4. Acute cellular rejection

Acute cellular rejection (ACR) is suspected when liver function tests worsen. At the University of Tokyo, liver transplant recipients undergo postoperative blood chemistry daily or every other day during hospitalization, and once every 2 weeks or once a month in the outpatient clinics. If all liver function data (aspartate aminotransferase, alanine aminotransferase, gamma-glutamyltranspeptidase, alkaline phosphatase, and total bilirubin) are elevated compared with previous levels and bile duct complications have been ruled out by ultrasound, biopsy is indicated. There are no serum markers specific for ACR and biopsy is mandatory to confirm the diagnosis. In contrast to biopsy for the donor candidates, biopsy for the diagnosis of ACR should not be delayed because ACR may result in chronic rejection, which is characterized by ductopenia or atrophy and pyknosis of the bile duct epithelium with parenchymal severe cholestasis,<sup>26</sup> and graft loss. Because ACR can be treated by immunosuppression, prompt and accurate diagnosis is important.

Category	Criteria	Score
Portal Inflammation	Mostly lymphocytic inflammation involving a minority of the triads.	1
	Lymphocyte infiltration to most or all of the triads.	2
	Mixed infiltration to most or all of the triads with inflammatory spillover into the periportal parenchyma.	3
Bile duct inflammation	A minority of the ducts are cuffed and infiltrated by inflammatory cells and show only mild reactive changes.	1
	Most or all of the ducts infiltrated by inflammatory cells. More than an occasional duct shows degenerative changes.	2
	As above for 2, with most or all of the ducts showing degenerative changes or focal luminal disruption.	3
Venous endothelial inflammation	Subendothelial lymphocytic infiltration involving some portal and/or hepatic venules.	1
	Subendothelial infiltration involving most or all of the portal and/or hepatic venules.	2
	As above for 2, with moderate or severe perivenular inflammation that extends into the perivenular parenchyma and is associated with perivenular hepatocyte necrosis.	3

Table 2. Banff scheme for rejection activity index

In general, the diagnosis of ACR is confirmed and graded into four classes according to the Banff scheme<sup>27,28</sup> (Grade 0 [G0]: no evidence of rejection; Grade 1 [G1]: mild rejection; Grade 2 [G2]: moderate rejection; and Grade 3 [G3]: severe rejection). This grading system is based on the degree of portal infiltration of lymphocytes (P0-3), bile duct inflammation or damage (B0-3), and venous endothelial inflammation (V0-3) (Table 2).

### 5. Eosinophilia as an aid to diagnose ACR

To facilitate the diagnosis of ACR, the efficacy of blood and/or histologic eosinophilia has been reported in several studies<sup>29-38</sup> (Table 3). In these studies, sensitivity and specificity of blood eosinophilia to predict ACR before biopsy were reported to be 32% to 96% and 63% to 97%, respectively, while those of histologic eosinophilia were 54% to 92% and 65% to 98%, respectively. Further, the correlation of eosinophilia with the severity of ACR, or a decrease of blood eosinophil count in response to treatment was reported in most of these studies<sup>39,40</sup>, although the effect of steroids alone to downregulate eosinophils cannot be ignored.

Author	Year	N (Biopsy specimens)	Blood			Histology		
			Cut off	Sensitivity/ Specificity	Correlation with ACR grade	Cut off	Sensitivity/ Specificity	Correlation with ACR grade
Foster PF	1989	283	AEC>500/mm <sup>3</sup>	96%/87%	N.A.	>7% of infiltrating cells are eosinophil	92%/98%	N.A.
Foster PF	1991	331	N.A.		N.A.	Average >2.5 cells/portal tract	82%/91%	N.A.
Ben-Ari Z	1995	92	N.A.		N.A.	N.A.		+
Manzarbeitia C	1995	43	AEC>430/mm <sup>3</sup>	35%/83%	N.A.	N.A.		N.A.
Dollinger MM	1997	55	AEC>330/mm <sup>3</sup> on 7POD	70%/63%	N.A.	N.A.		N.A.
Hughes VF	1998	71	AEC increase >20% within 28 days prior to biopsy	81%/74%	N.A.	N.A.		N.A.
Nagraal A	2001	129	AEC≥400/mm <sup>3</sup>	34%/92%	-	N.A.		N.A.
Barnes EJ	2003	275	REC≥4% AEC>400/mm <sup>3</sup> & REC>4%	43%/84%	-	N.A.		N.A.
Kishi Y	2005	314	AEC>400/mm <sup>3</sup> REC>4%	32%/89%	+	N.A.		N.A.
			AEC>400/mm <sup>3</sup> REC>4%	28%/97%	+	N.A.		N.A.
			REC>4%	33%/93%	N.A.	Maximal ≥2 per portal tract	54%/84%	+
Kishi Y	2007	263	AEC≥82/mm <sup>3</sup>	64%/79%	N.A.	Proportion of portal tract with eosinophil infiltration ≥8%	72%/65%	+

Table 3. Summary of the studies evaluating blood of histologic eosinophilia with the diagnosis of acute cellular rejection (ACR). AEC, absolute eosinophil count; REC, percentage of eosinophil count in the whole leukocyte count.

Notably, blood eosinophilia a few days before biopsy is associated with ACR. Although rather low sensitivity is a problem, careful monitoring of the differential leukocyte count may contribute to the early detection of ACR. On the other hand, histologic eosinophilia predicts ACR with rather high sensitivity and specificity. Gupta et al. validated the inclusion of eosinophilia in addition to portal inflammation, endothelialitis, and bile duct damage for the grading of ACR and proposed the Royal free hospital (RFH) scoring system. In this system, the highest eosinophil count in a portal tract is graded as the follows: none (score 0), 0; mild (score 1), 1-4 cells; moderate (score 2), 5-9 cells; severe (score 3), 10 or more cells.<sup>41</sup> Kishi et al.<sup>38</sup> evaluated histologic eosinophilia as the maximum eosinophil count per portal tract (E<sub>max</sub>) and the rate of portal tracts that included at least one eosinophil (E(+) rate), and demonstrated that both were associated with ACR as well as with ACR severity. This finding was later validated in another study by Demirhan et al.<sup>42</sup>, in which marked eosinophilia assessed as E<sub>max</sub> and E(+) rate correlated with ACR severity and response to treatment.

## 6. Differentiation from HCV recurrence

Differential diagnoses of ACR include recurrent or new-onset viral hepatitis by HBV, HCV, cytomegalovirus, or Epstein-Barr virus, autoimmune hepatitis, primary biliary cirrhosis, or primary sclerosing cholangitis. Among them the differentiation from recurrent HCV is difficult especially in the early postoperative period because histologic features overlap<sup>43</sup>, but is critical because the treatment strategy is completely opposite.

To date, several studies have evaluated the interobserver agreement for the differential diagnosis of ACR and recurrent hepatitis C. Regev et al.<sup>43</sup> evaluated the interobserver and intraobserver agreement among five experienced pathologists for the diagnosis of 102 biopsy specimens. The results indicated that both the interobserver and the intraobserver agreement were relatively low, with Kappa scores ranging from 0.20 to 0.24 for interobserver agreement and from 0.19 to 0.42 for intraobserver agreement, indicating only slight to moderate agreement<sup>43</sup>. Netto et al.<sup>44</sup> reported the results of a multiinstitutional study to evaluate the agreement on the diagnosis of 11 biopsy specimens based on the Banff schema ACR scoring system and Batts and Ludwig schema for HCV staging by 17 pathologists. The results showed a Kappa score of 0.62 to 0.76 for interobserver agreement on the diagnosis of ACR or HCV, indicating substantial or almost perfect agreement<sup>45</sup>.

In general, pathologists tend to over diagnose ACR rather than HCV recurrence. Leung et al.<sup>46</sup> reported a case of histologically diagnosed ACR that improved only by interferon and ribavirin therapy, and suggested that histologic characteristics traditionally associated with ACR might represent early recurrent HCV. Barnes et al. reported that HCV-positive patients with ACR are less likely to have blood eosinophilia than HCV-negative patients with ACR. They thus proposed that the eosinophil response might be suppressed in HCV-positive patients with ACR, and that ACR might be overdiagnosed if based on histopathology in patients with normal eosinophil levels<sup>36</sup>. Similarly, Kishi et al.<sup>47</sup> reported that HCV-positive patients diagnosed with ACR had significantly higher blood eosinophil counts on the day of biopsy than HCV-positive patients without ACR. These findings indicate that measures of blood eosinophil levels might contribute to the differential diagnosis of ACR in HCV-positive recipients.

Several blood or histologic markers have been proposed to facilitate the differentiation between ACR and recurrent HCV. Unitt et al.<sup>48</sup> reported that minichromosome maintenance

protein-2 (Mcm-2) visualized by immunohistochemical staining in lymphocytes infiltrating into the portal tracts is more frequently expressed in ACR than in HCV recurrence. The number of Mcm-2-positive lymphocytes in the portal tract was not correlated with the ACR grade, but a cut-off of 107 positive cells per portal tract distinguished ACR from HCV with a sensitivity of 82% and a specificity of 92%. MacQuillan et al.<sup>49</sup> performed immunohistochemical analysis to evaluate the expression of MxA protein, which belongs to the class of guanosine triphosphatases and is a marker of activation of the type 1 interferon pathway. The findings demonstrated strong hepatocellular MxA staining in 78% of HCV recurrence and in 30% of ACR biopsy specimens.

Typical histologic features of recurrent hepatitis C include lobular disarray, Kupffer cell hypertrophy, hepatocyte apoptosis, mild sinusoidal lymphocytosis, mononuclear portal inflammation, macrovesicular steatosis involving periportal and midzonal hepatocytes. In chronic hepatitis, lobular changes wane and portal inflammation increases. Occasionally, nodular portal-based lymphoid aggregates are formed with emerging necroinflammatory and ductular-type interface activity. Further, fibrosing cholestatic hepatitis (FCH), which is clinically featured by rapidly progressive jaundice and extremely high HCV viral loads, may occur and is fatal in most cases. The incidence of FCH among the recipients who underwent liver transplantation for HCV-related cirrhosis is reported to be 6 to 14%<sup>50-52</sup>. Histologically, FCH is characterized by extensive fibrosis with immature fibrous bands extending from the portal tracts to the sinusoidal spaces, prominent canalicular and hepatocellular cholestasis, ground-glass transformation, ballooning of hepatocytes with cell loss, and a mild mixed inflammatory reaction may occur<sup>53</sup>. A small case series<sup>52,54,55</sup> reported that a certain proportion of patients with FCH might respond to interferon plus ribavirin with or without conversion of tacrolimus to cyclosporine A. Increased immunosuppression as a treatment for ACR is an important cause of FCH<sup>56</sup>.

## 7. References

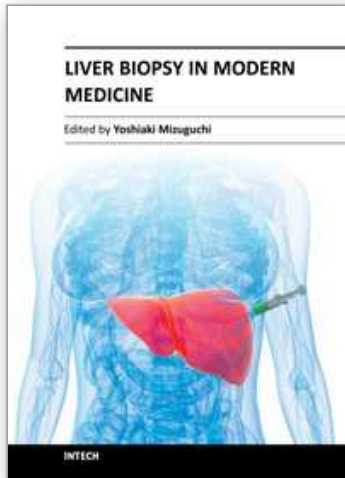
- [1] Day CP, James OF: Steatohepatitis: a tale of two "hits"? *Gastroenterology* 114:842-5, 1998
- [2] Hilden M, Christoffersen P, Juhl E, et al: Liver histology in a 'normal' population--examinations of 503 consecutive fatal traffic casualties. *Scandinavian journal of gastroenterology* 12:593-7, 1977
- [3] Underwood Ground KE: Prevalence of fatty liver in healthy male adults accidentally killed. *Aviation, space, and environmental medicine* 55:59-61, 1984
- [4] Hultcrantz R, Glaumann H, Lindberg G, et al: Liver investigation in 149 asymptomatic patients with moderately elevated activities of serum aminotransferases. *Scandinavian journal of gastroenterology* 21:109-13, 1986
- [5] Wanless IR, Lentz JS: Fatty liver hepatitis (steatohepatitis) and obesity: an autopsy study with analysis of risk factors. *Hepatology* 12:1106-10, 1990
- [6] Daniel S, Ben-Menachem T, Vasudevan G, et al: Prospective evaluation of unexplained chronic liver transaminase abnormalities in asymptomatic and symptomatic patients. *The American journal of gastroenterology* 94:3010-4, 1999
- [7] Chitturi S, Farrell GC, Hashimoto E, et al: Non-alcoholic fatty liver disease in the Asia-Pacific region: definitions and overview of proposed guidelines. *Journal of gastroenterology and hepatology* 22:778-87, 2007
- [8] Selzner M, Clavien PA: Failure of regeneration of the steatotic rat liver: disruption at two different levels in the regeneration pathway. *Hepatology* 31:35-42, 2000



- [9] Vetelainen R, van Vliet AK, van Gulik TM: Severe steatosis increases hepatocellular injury and impairs liver regeneration in a rat model of partial hepatectomy. *Annals of surgery* 245:44-50, 2007
- [10] Hsiao IT, Lin KJ, Chang SI, et al: Impaired liver regeneration of steatotic rats after portal vein ligation: a particular emphasis on (99m)Tc-DISIDA scintigraphy and adiponectin signaling. *Journal of hepatology* 52:540-9, 2010
- [11] 11. Kooby DA, Fong Y, Suriawinata A, et al: Impact of steatosis on perioperative outcome following hepatic resection. *J Gastrointest Surg* 7:1034-44, 2003
- [12] Vauthey JN, Pawlik TM, Ribero D, et al: Chemotherapy regimen predicts steatohepatitis and an increase in 90-day mortality after surgery for hepatic colorectal metastases. *J Clin Oncol* 24:2065-72, 2006
- [13] Hussein O, Szvalb S, Van den Akker-Berman LM, et al: Liver regeneration is not altered in patients with nonalcoholic steatohepatitis (NASH) when compared to chronic hepatitis C infection with similar grade of inflammation. *Digestive diseases and sciences* 47:1926-31, 2002
- [14] Cho JY, Suh KS, Kwon CH, et al: Mild hepatic steatosis is not a major risk factor for hepatectomy and regenerative power is not impaired. *Surgery* 139:508-15, 2006
- [15] Yamamoto K, Takada Y, Fujimoto Y, et al: Nonalcoholic steatohepatitis in donors for living donor liver transplantation. *Transplantation* 83:257-62, 2007
- [16] Rinella ME, Alonso E, Rao S, et al: Body mass index as a predictor of hepatic steatosis in living liver donors. *Liver transplantation : official publication of the American Association for the Study of Liver Diseases and the International Liver Transplantation Society* 7:409-14, 2001
- [17] Ryan CK, Johnson LA, Germin BI, et al: One hundred consecutive hepatic biopsies in the workup of living donors for right lobe liver transplantation. *Liver transplantation : official publication of the American Association for the Study of Liver Diseases and the International Liver Transplantation Society* 8:1114-22, 2002
- [18] Tran TT, Changsri C, Shackleton CR, et al: Living donor liver transplantation: histological abnormalities found on liver biopsies of apparently healthy potential donors. *Journal of gastroenterology and hepatology* 21:381-3, 2006
- [19] Yamashiki N, Sugawara Y, Tamura S, et al: Noninvasive estimation of hepatic steatosis in living liver donors: usefulness of visceral fat area measurement. *Transplantation* 88:575-81, 2009
- [20] Poordad F, Gish R, Wakil A, et al: De novo non-alcoholic fatty liver disease following orthotopic liver transplantation. *American journal of transplantation : official journal of the American Society of Transplantation and the American Society of Transplant Surgeons* 3:1413-7, 2003
- [21] Seo S, Maganti K, Khehra M, et al: De novo nonalcoholic fatty liver disease after liver transplantation. *Liver transplantation : official publication of the American Association for the Study of Liver Diseases and the International Liver Transplantation Society* 13:844-7, 2007
- [22] Lindor KD, Kowdley KV, Heathcote EJ, et al: Ursodeoxycholic acid for treatment of nonalcoholic steatohepatitis: results of a randomized trial. *Hepatology* 39:770-8, 2004
- [23] Brunt EM, Janney CG, Di Bisceglie AM, et al: Nonalcoholic steatohepatitis: a proposal for grading and staging the histological lesions. *The American journal of gastroenterology* 94:2467-74, 1999
- [24] Promrat K, Lutchman G, Uwaifo GI, et al: A pilot study of pioglitazone treatment for nonalcoholic steatohepatitis. *Hepatology* 39:188-96, 2004

- [25] Kleiner DE, Brunt EM, Van Natta M, et al: Design and validation of a histological scoring system for nonalcoholic fatty liver disease. *Hepatology* 41:1313-21, 2005
- [26] Demetris AJ, Seaberg EC, Batts KP, et al: Chronic liver allograft rejection: a National Institute of Diabetes and Digestive and Kidney Diseases interinstitutional study analyzing the reliability of current criteria and proposal of an expanded definition. National Institute of Diabetes and Digestive and Kidney Diseases Liver Transplantation Database. *The American journal of surgical pathology* 22:28-39, 1998
- [27] Banff schema for grading liver allograft rejection: an international consensus document. *Hepatology* 25:658-63, 1997
- [28] Demetris A, Adams D, Bellamy C, et al: Update of the International Banff Schema for Liver Allograft Rejection: working recommendations for the histopathologic staging and reporting of chronic rejection. An International Panel. *Hepatology* 31:792-9, 2000
- [29] Foster PF, Sankary HN, Hart M, et al: Blood and graft eosinophilia as predictors of rejection in human liver transplantation. *Transplantation* 47:72-4, 1989
- [30] Foster PF, Sankary HN, Williams JW, et al: Morphometric inflammatory cell analysis of human liver allograft biopsies. *Transplantation* 51:873-6, 1991
- [31] Ben-Ari Z, Booth JD, Gupta SD, et al: Morphometric image analysis and eosinophil counts in human liver allografts. *Transpl Int* 8:346-52, 1995
- [32] Manzarbeitia C, Rustgi VK, Jonsson J, et al: Absolute peripheral blood eosinophilia. An early marker for rejection in clinical liver transplantation. *Transplantation* 59:1358-60, 1995
- [33] Dollinger MM, Plevris JN, Bouchier IA, et al: Peripheral eosinophil count both before and after liver transplantation predicts acute cellular rejection. *Liver Transpl Surg* 3:112-7, 1997
- [34] Hughes VF, Trull AK, Joshi O, et al: Monitoring eosinophil activation and liver function after liver transplantation. *Transplantation* 65:1334-9, 1998
- [35] Nagral A, Quaglia A, Sabin CA, et al: Blood and graft eosinophils in acute cellular rejection of liver allografts. *Transplant Proc* 33:2588-93, 2001
- [36] Barnes EJ, Abdel-Rehim MM, Goulis Y, et al: Applications and limitations of blood eosinophilia for the diagnosis of acute cellular rejection in liver transplantation. *Am J Transplant* 3:432-8, 2003
- [37] Kishi Y, Sugawara Y, Tamura S, et al: Is blood eosinophilia an effective predictor of acute rejection in living donor liver transplantation? *Transpl Int* 18:1147-51, 2005
- [38] Kishi Y, Sugawara Y, Tamura S, et al: Histologic eosinophilia as an aid to diagnose acute cellular rejection after living donor liver transplantation. *Clinical transplantation* 21:214-8, 2007
- [39] Lautenschlager I, von Willebrand E, Hayry P: Blood eosinophilia, steroids, and rejection. *Transplantation* 40:354-7, 1985
- [40] Meagher LC, Cousin JM, Seckl JR, et al: Opposing effects of glucocorticoids on the rate of apoptosis in neutrophilic and eosinophilic granulocytes. *J Immunol* 156:4422-8, 1996
- [41] Datta Gupta S, Hudson M, Burroughs AK, et al: Grading of cellular rejection after orthotopic liver transplantation. *Hepatology* 21:46-57, 1995
- [42] Demirhan B, Bilezikci B, Haberal AN, et al: Hepatic parenchymal changes and histologic eosinophilia as predictors of subsequent acute liver allograft rejection. *Liver Transpl* 14:214-9, 2008

- [43] Regev A, Molina E, Moura R, et al: Reliability of histopathologic assessment for the differentiation of recurrent hepatitis C from acute rejection after liver transplantation. *Liver transplantation : official publication of the American Association for the Study of Liver Diseases and the International Liver Transplantation Society* 10:1233-9, 2004
- [44] Batts KP, Ludwig J: Chronic hepatitis. An update on terminology and reporting. *The American journal of surgical pathology* 19:1409-17, 1995
- [45] Netto GJ, Watkins DL, Williams JW, et al: Interobserver agreement in hepatitis C grading and staging and in the Banff grading schema for acute cellular rejection: the "hepatitis C 3" multi-institutional trial experience. *Archives of pathology & laboratory medicine* 130:1157-62, 2006
- [46] Leung JY, Abraczinskas DR, Bhan AK, et al: Recurrent allograft HCV presenting as acute cellular rejection: successful management with interferon and ribavirin alone. *Clinical transplantation* 17:275-83, 2003
- [47] Kishi Y, Sugawara Y, Kaneko J, et al: Blood eosinophilia after living donor liver transplantation for hepatitis C virus-related cirrhosis. *Transplantation proceedings* 39:1540-3, 2007
- [48] Unitt E, Gelson W, Davies SE, et al: Minichromosome maintenance protein-2-positive portal tract lymphocytes distinguish acute cellular rejection from hepatitis C virus recurrence after liver transplantation. *Liver Transpl* 15:306-12, 2009
- [49] MacQuillan GC, de Boer WB, Allan JE, et al: Hepatocellular MxA protein expression supports the differentiation of recurrent hepatitis C disease from acute cellular rejection after liver transplantation. *Clinical transplantation* 24:252-8, 2010
- [50] Schluger LK, Sheiner PA, Thung SN, et al: Severe recurrent cholestatic hepatitis C following orthotopic liver transplantation. *Hepatology* 23:971-6, 1996
- [51] Satapathy SK, Sclair S, Fiel MI, et al: Clinical characterization of patients developing histologically-proven fibrosing cholestatic hepatitis C post-liver transplantation. *Hepatology research : the official journal of the Japan Society of Hepatology* 41:328-39, 2011
- [52] Cimsit B, Assis D, Caldwell C, et al: Successful treatment of fibrosing cholestatic hepatitis after liver transplantation. *Transplantation proceedings* 43:905-8, 2011
- [53] Davies SE, Portmann BC, O'Grady JG, et al: Hepatic histological findings after transplantation for chronic hepatitis B virus infection, including a unique pattern of fibrosing cholestatic hepatitis. *Hepatology* 13:150-7, 1991
- [54] Ong JP, Younossi ZM, Gramlich T, et al: Interferon alpha 2B and ribavirin in severe recurrent cholestatic hepatitis C. *Transplantation* 71:1486-7, 2001
- [55] Gopal DV, Rosen HR: Duration of antiviral therapy for cholestatic HCV recurrence may need to be indefinite. *Liver transplantation : official publication of the American Association for the Study of Liver Diseases and the International Liver Transplantation Society* 9:348-53, 2003
- [56] Testa G, Crippin JS, Netto GJ, et al: Liver transplantation for hepatitis C: recurrence and disease progression in 300 patients. *Liver transplantation : official publication of the American Association for the Study of Liver Diseases and the International Liver Transplantation Society* 6:553-61, 2000



## **Liver Biopsy in Modern Medicine**

Edited by Dr. Yoshiaki Mizuguchi

ISBN 978-953-307-883-0

Hard cover, 378 pages

**Publisher** InTech

**Published online** 10, October, 2011

**Published in print edition** October, 2011

Liver biopsy, first performed by Paul Ehrlich in 1883, remains an important diagnostic procedure for the management of hepatobiliary disorders and the candidate/donated organ for transplantation. The book "Liver biopsy in Modern Medicine" comprises 21 chapters covering the various aspects of the biopsy procedure in detail and provides an up-to-date insightful coverage to the recent advances in the management of the various disorders with liver biopsy. This book will keep up with cutting edge understanding of liver biopsy to many clinicians, physicians, scientists, pharmaceuticals, engineers and other experts in a wide variety of different disciplines.

### **How to reference**

In order to correctly reference this scholarly work, feel free to copy and paste the following:

Yasuhiko Sugawara, Norihiro Kokudo and Yoji Kishi (2011). Liver Biopsy in Transplantation: Nonalcoholic Fatty Liver Disease and the Eosinophils, Liver Biopsy in Modern Medicine, Dr. Yoshiaki Mizuguchi (Ed.), ISBN: 978-953-307-883-0, InTech, Available from: <http://www.intechopen.com/books/liver-biopsy-in-modern-medicine/liver-biopsy-in-transplantation-nonalcoholic-fatty-liver-disease-and-the-eosinophils>

**INTECH**  
open science | open minds

### **InTech Europe**

University Campus STeP Ri  
Slavka Krautzeka 83/A  
51000 Rijeka, Croatia  
Phone: +385 (51) 770 447  
Fax: +385 (51) 686 166  
[www.intechopen.com](http://www.intechopen.com)

### **InTech China**

Unit 405, Office Block, Hotel Equatorial Shanghai  
No.65, Yan An Road (West), Shanghai, 200040, China  
中国上海市延安西路65号上海国际贵都大饭店办公楼405单元  
Phone: +86-21-62489820  
Fax: +86-21-62489821

© 2011 The Author(s). Licensee IntechOpen. This is an open access article distributed under the terms of the [Creative Commons Attribution 3.0 License](#), which permits unrestricted use, distribution, and reproduction in any medium, provided the original work is properly cited.

IntechOpen

IntechOpen