

# We are IntechOpen, the world's leading publisher of Open Access books Built by scientists, for scientists

## 4,800

Open access books available

## 122,000

International authors and editors

## 135M

Downloads

Our authors are among the

## 154

Countries delivered to

## TOP 1%

most cited scientists

## 12.2%

Contributors from top 500 universities

**WEB OF SCIENCE™**Selection of our books indexed in the Book Citation Index  
in Web of Science™ Core Collection (BKCI)

Interested in publishing with us?  
Contact [book.department@intechopen.com](mailto:book.department@intechopen.com)

Numbers displayed above are based on latest data collected.

For more information visit [www.intechopen.com](http://www.intechopen.com)

## Choroidal Melanoma

Raquel Correa, Mario Lobato and José Antonio Medina  
*Virgen de la Victoria Hospital, Málaga,  
Spain*

### 1. Introduction

Uveal melanoma is the most common primary ocular malignancy in adults. There are about 0.6-0.8 new patients per 100,000 inhabitants (in Europe). Several studies have demonstrated that complete removal of the tumour by enucleation is not advantageous compared with conservative therapies in terms of metastatic spread and survival.

The primary treatment for uveal melanoma depends on many factors: size, location, extraocular extension, visual function, age and performance status.

### 2. Enucleation

Enucleation has been the standard treatment since the nineteenth century and is still the treatment of choice in large uveal melanomas.

Enucleation is still required in a significant proportion of patients, either because the tumour is too extensive at presentation or because of the complications of conservative therapy. The procedure is performed in the surgeon's preferred fashion. It is essential to perform binocular indirect ophthalmoscopy after draping the patient to confirm that the correct eye is being removed. The main complication specific to uveal melanoma is orbital tumour recurrence, which is rare. If this occurs, it is treated with local resection and external beam radiotherapy. It was previously believed that surgical manipulations during enucleation disseminated tumour cells into the vascular system, thereby causing metastatic disease; however, as we will see later, COMS-10 study has shown no improvement of survival after pre-enucleation radiotherapy, thereby casting doubt on this hypothesis.

Globe preserving techniques include: laser photocoagulation, transpupillary thermotherapy, local resection, radiotherapy and gammaknife.

Observation without treatment is a modality used for melanomas that are small and have dormant characteristics. Patients managed by this strategy are often asymptomatic and have the lesion picked up on routine ocular examination. Another subgroup of patients who may be managed by observation includes elderly patients with severe systemic health problems or short life expectancy.

Radiotherapy (RT) offers a conservative treatment for those patients who are suitable for visual and motion conservation.

### 3. Radiobiology

Radiations kills a tumour either by producing free radicals that destroy cellular DNA immediately or by induction of mutations that go on to kill tumour cells over a protracted

period of time. Radiation also induces vascular fibrosis and secondary hypoxia, which again may take time to cause cell death. Thus, RT provides both short- and long-term effects<sup>1</sup>.

There are two main modalities: brachytherapy and external beam radiotherapy (that includes charged particles and special techniques like intensity modulated radiotherapy).

#### 4. Brachytherapy

In the United States, controversies about the appropriate management of choroidal melanoma led to the development of the COMS (Collaborative Ocular Melanoma Study) group, which conducted a series of randomised studies on the use of enucleation, brachytherapy and radiotherapy. To date, their principal results have been that preoperative radiotherapy for large size melanomas does not improve survival compared with enucleation alone, and that there is no difference as regards survival between those patients treated with I-125 seed brachytherapy and those who underwent enucleation. The results of these studies show brachytherapy as an alternative to enucleation.

Various materials for delivering radiation have been investigated in brachytherapy. Iodine-125 is currently the most commonly used isotope for plaque radiotherapy of choroidal melanoma. Although cobalt-60, ruthenium-106, Iridium -196, strontium-90 and palladium-103 have also been used.

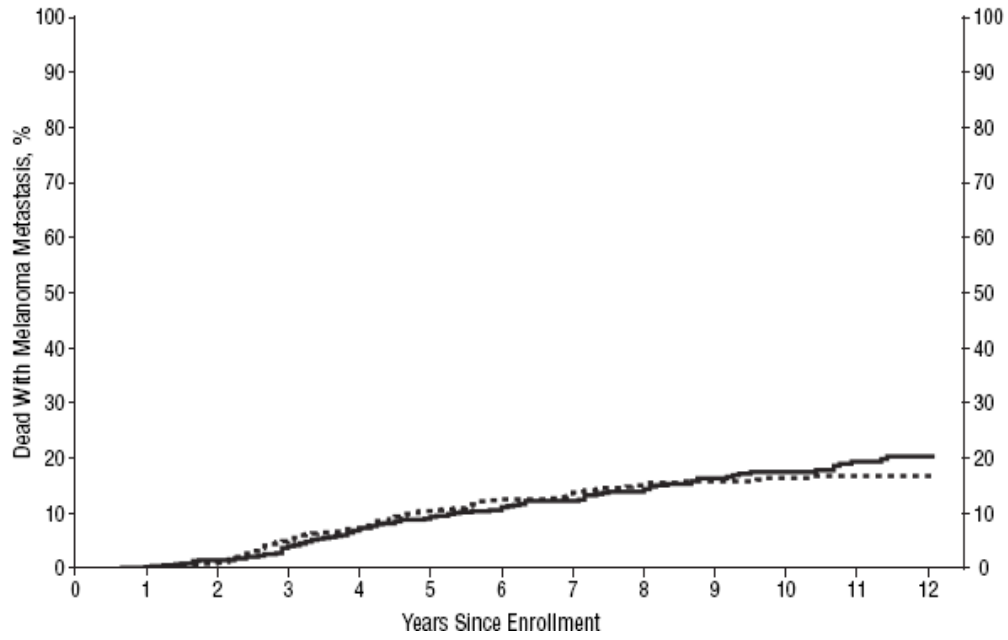
Radionuclide	Symbol	Type	Energy	Half-life	Introduced	depth
Cobalt	Co-60	Gamma/beta	1.3MeV/320Kev	5.2 years	1948	
Ruthenium	Ru-106	Beta	293 KeV	373 days	1964	5 mm
Iodine	I-125	Gamma	27-35 KeV	60 days	1975	
Strontium	Sr-90	Beta	546 KeV	29 years	1983	5 mm
Iridium	Ir-192	Gamma/Beta	600KeV/370 KeV	74 days	1983	
Palladium	Pd-102	Gamma	21 KeV	17 days	1986	

Table 1.

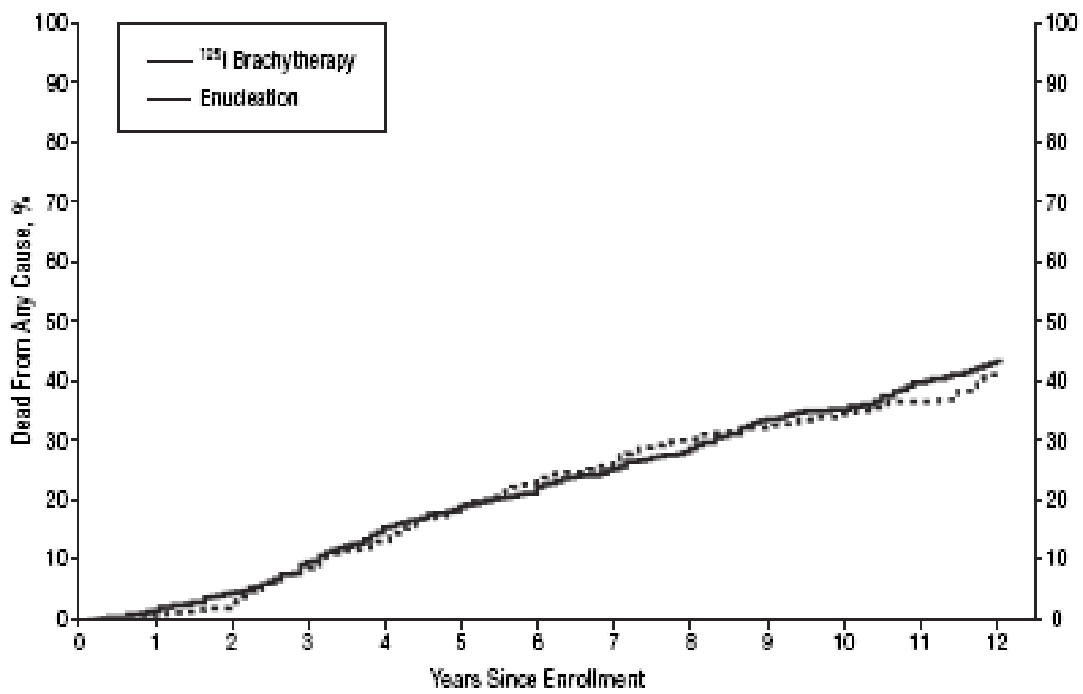
Before the COMS trials were initiated in 1986, interest in radiation therapy had increased because of the potential for saving the eye and perhaps some vision.

The COMS-18 trial enrolled 1317 patients with medium size melanomas to enucleation or brachytherapy with iodine-125 (I-125) plaques. Six hundred and sixty were randomly assigned to enucleation and 657 to I-125 brachytherapy (85 Gy ). Only 2 patients in the enucleation arm were found to have been misdiagnosed when histopathology was centrally reviewed. All but 17 patients (1.3%) received the assigned treatment. Adherence to the brachytherapy protocol was excellent, with 91% of patients treated per protocol. Based on time since enrolment, 1072 patients (81%) had been followed for mortality at 5 years and 416 (32%) at 10 years. A total of 364 patients had died: 188 (28%) of 660 patients in the enucleation arm and 176 (27%) of 657 patients in the brachytherapy arm. The unadjusted estimated 5-year survival rates were 81% and 82%, respectively; there was no clinically or statistically significant difference in survival rates overall ( $P = 0.48$ , log-rank test). The

adjusted estimated risk ratio for I-125 brachytherapy vs enucleation was 0.99 (95% confidence interval [CI], 0.80-1.22). Five-year rates of death with histopathologically confirmed melanoma metastases were 11% and 9% following enucleation and brachytherapy respectively; after adjustment, the estimated risk ratio was 0.91 (95% CI, 0.66-1.24). Graphs 1 and 2. They concluded that mortality rates following I-125 brachytherapy did not differ from mortality rates following enucleation for up to 12 years after treatment <sup>2</sup>.



Graph 1. Dead with melanoma metastasis at COMS-18 trial



Graph 2. Dead from any cause at COMS-18 trial

Visual acuity declined in a substantial proportion of eyes in the brachytherapy group. There was a quadrupling of the minimum angle of resolution, or loss of 6 or more lines of visual acuity from baseline in 18% of patients at 1 year, 34% at 2 years and 49% at 3 years. The risk of vision loss was associated with a history of diabetes, thick tumours, tumours close to or beneath the macula, tumours with secondary retinal detachments and tumours that were not dome-shaped<sup>3</sup>. Secondary strabismus has also occurred in 5% of patients as a result of moving extraocular muscles in order to properly place the plaque to hold the radioactive seeds (see figure 2).

Tumours with larger basal diameters are more likely to recur. Karlsson et al. found that patients with local tumour recurrence, which is likely to occur at the tumour margin, were at greater risk of life-threatening distant metastasis, having a 5-year survival rate of 58% compared with 82% for those without local recurrence. However, while local control of choroidal melanomas treated with brachytherapy has been reported at more than 90%, many treated eyes develop complications secondary to radiation delivered to adjacent structures. Radiation retinopathy has been identified in up to 43%. Other complications include optic atrophy, cystoid macular edema, cataracts, glaucoma, central retina vein occlusion and scleral necrosis.

In the COMS-10 trial of preoperative radiation, patients with large tumours were randomized to enucleation alone or to enucleation preceded by 20 Gy of external beam radiation. This trial was designed to see if radiation before enucleation (removal of the eye) would prevent metastasis. The idea was to see if pre-operative irradiation would sterilize any cells that might break free during surgery.

The two randomly assigned groups of patients were followed for at least five years or until death and were compared on the basis of length of remaining life and other outcomes. A total of 1,003 patients were enrolled; 506 were assigned to enucleation alone and 497 to pre-enucleation radiation. With 5-year outcome known for 801 patients enrolled (80%), the estimated 5-year survival rates and 95% confidence intervals (CIs) were 57% (95% CI, 52% to 62%) for enucleation alone and 62% (95% CI, 57% to 66%) for pre-enucleation radiation. Among the baseline covariates evaluated, only age and longest basal diameter of the melanoma affected the prognosis for survival to a statistically significant degree. The risk of death among patients treated with pre-enucleation radiation relative to those treated with enucleation alone after adjustment for baseline characteristics of patients, eyes, and tumours was 1.03 (95% CI, 0.85 to 1.25). Of 435 deaths classified by the Mortality Coding Committee, 269 patients had histologically confirmed melanoma metastases at the time of death. Estimated 5-year survival rates for this secondary outcome were 72% (95% CI, 68% to 76%) for enucleation alone and 74% (95% CI, 69% to 78%) for pre-enucleation radiation. The Large-sized Choroidal Melanoma Study concluded that patients who received external irradiation to their eye before it was removed, had an equal chance of developing metastatic disease as compared to those who were treated by enucleation (removal of the eye) alone.

This study did not find any survival difference attributable to pre-enucleation radiation of large choroidal melanoma, using the COMS fractionation Schedule<sup>4</sup>.

Accrual to a nonrandomized pilot study to assess the feasibility of a randomized trial for small tumors was halted in 1989. Additional follow-up of these patients was carried out from 1994 to 1996. From December 1986 to August 1989, 204 patients with small choroidal melanoma, not large enough to be eligible for the COMS clinical trials, were offered

participation in a nonrandomized prospective follow-up study. Small choroidal melanomas were defined as 1.0 to 3.0 mm in apical height and at least 5.0 mm in basal diameter. A total of 204 patients were enrolled in the study. Patients were followed up annually through August 1989. Two additional assessments of treatment status and mortality were conducted in 1993-1994 and 1995-1996. The median length of follow-up was 92 months. Eight percent of patients were treated at the time of study enrolment and an additional 33% were treated during follow-up. Twenty-seven patients have died; 6 deaths were reported by the clinical center as due to metastatic melanoma. The Kaplan-Meier estimate of 5-year all-cause mortality was 6.0% (95% confidence interval, 2.7%-9.3%) and 8-year all-cause mortality was 14.9% (95% confidence interval, 9.6%-20.2%). The study concluded that healthy patients, average age of 60 years, without a previous diagnosis of malignant disease who had small choroidal lesions judged to be melanoma had a low risk of dying within 5 years<sup>5</sup>.

## 5. Implant sequence

The procedure is performed thanks to the joint efforts of a multidisciplinary team composed of ophthalmologists, radiation oncologists, anaesthetists, physicists, and specialised radiotherapy technicians.

Patient preparation:

1. Placing of the radioactive plaque. This is carried out with both local and general anaesthetic, depending on each case, but mostly using retrobulbar anaesthesia with akinesis.
2. Gestures: In general, a limbic peritomy is performed, dissecting Tenon's capsule to leave the scleral surface which coincides with the tumour base exposed. If the lesion affects the muscle insertion area, the muscle must be disinserted.
3. CTV (Clinical target volume) Determination: Pupilar transillumination is used for the localization and marking of the base of the melanoma. Various non-absorbable sutures are placed at the scleral level, at positions marked by an inactive phantom, in order to check the correct size of the proposed plaque; the definitive radioactive plaque is then positioned and the sutures are tied. The diameter of the radioactive applicator should be 2 mm greater than the tumour base, to ensure that the microscopic disease is covered by a safety zone for complete irradiation of its margins. Additional margins are not taken to cover eye movements.
4. Post-operative: Anti-inflammatory drugs and antibiotics are administered subconjunctivally, topically and systemically in theatre. The patient is subsequently transferred to a darkened room.
5. Treatment course: The treatment is given as scheduled and all patients remain admitted to the Brachytherapy Unit. During admission, analgesic and prophylactic antibiotic treatment is prescribed.
6. Implant removal: On extraction of the ophthalmic plaque, the patient is again transferred to the implant room where it is disinserted under anaesthesia and complete removal of the radioactive load is checked. Once the plaque had been extracted, the patient returns to his room where he remains until recovery and discharge. See figure 1, 2, 3 and 4.

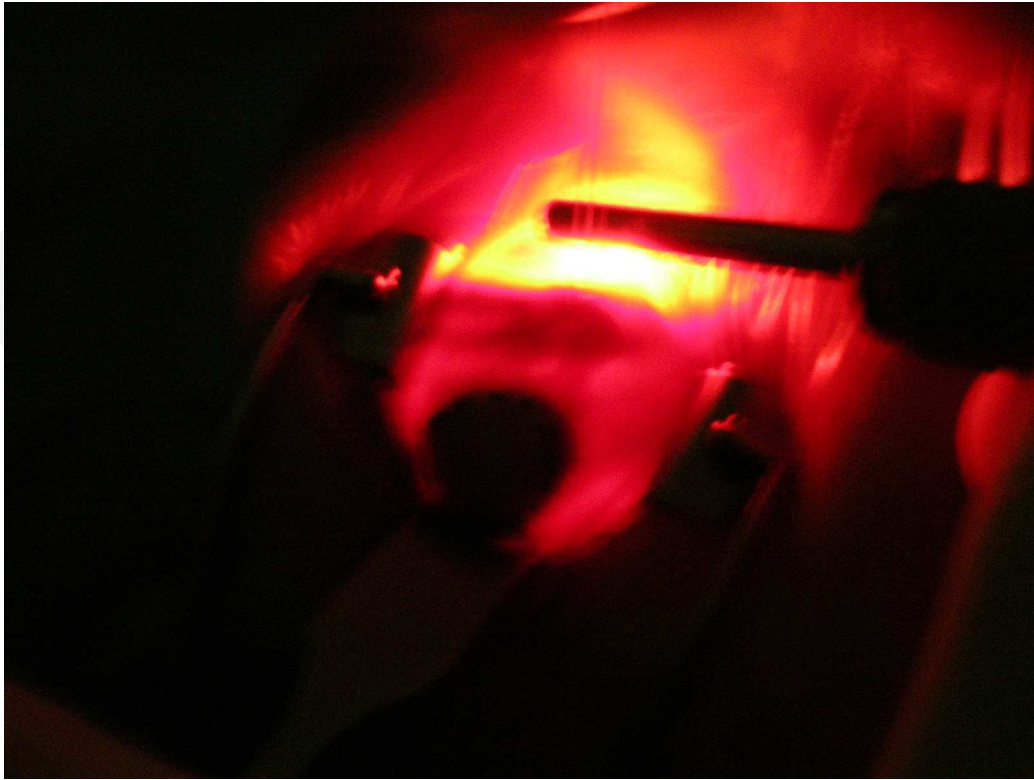


Fig. 1. Pupilar transillumination

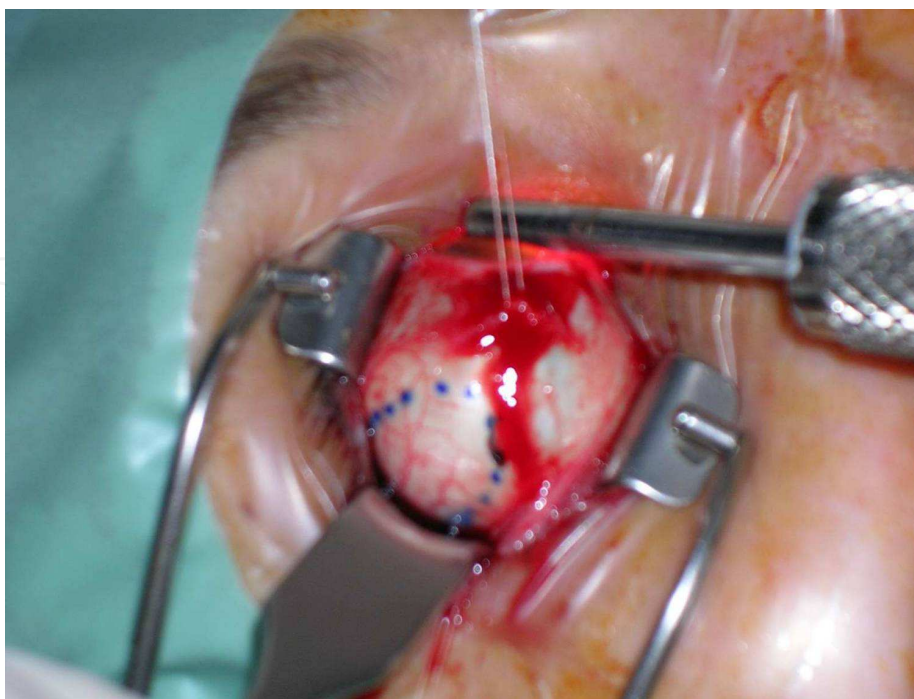


Fig. 2. Target volume delineation




Fig. 3. Plaque with I-125 seeds.

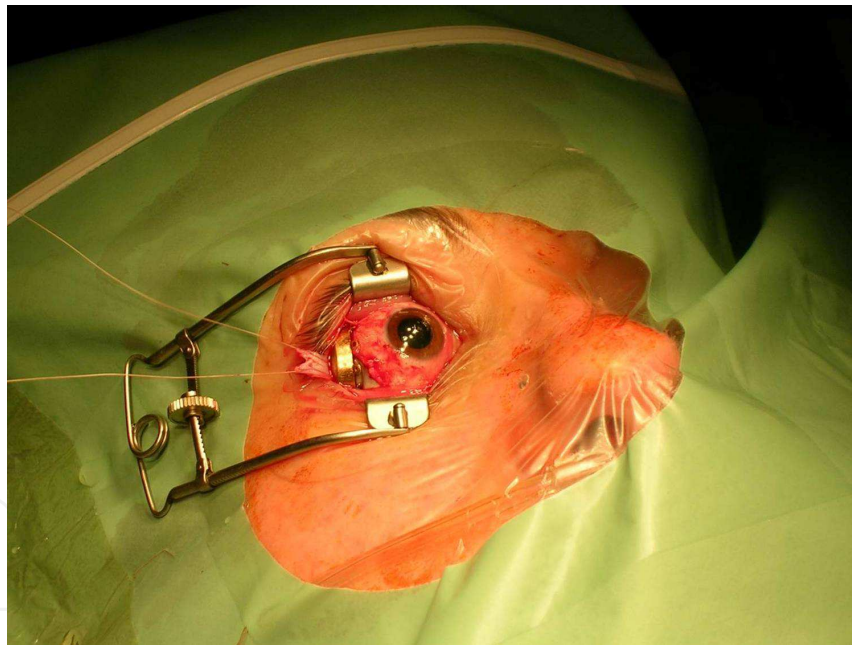


Fig. 4. Eye with the plaque in place.

## 6. Prescription dose

The prescription point is defined as the tumour apex for tumours measuring 5.0 mm or more in apical height; but for smaller tumours, the prescription point is 5 mm from the interior surface of the sclera. In 1996, the COMS adopted the recommendations of the American Association of Physicists in Medicine Task Group (TG-43) regarding dosimetry of interstitial sources in anticipation of a revised calibration standard for I-125 seeds by the



National Institute for Standards and Technology (NIST). Under the TG-43 formalism, the absorbed dose at the prescription point was 85 Gy delivered at a rate of at least 0.42 Gy/hour, but no more than 1.05 Gy/hour. Before adopting the TG-43 formalism, the prescribed total dose was calculated to be 100 Gy; however, the actual amount of radiation delivered was not affected by the change. All dose data included in the majority of reports were recalculated based on the TG-43 formalism. The actual radiation dose delivered to the prescription point, tumour apex, sclera at the center of the plaque and critical structures within the eye was reported to and confirmed by the COMS Radiologic Physics Center (Houston, TX). Doses were calculated based on presumed plaque location, I-125 seed activity and location in the plaque, and times of plaque insertion and removal.

## 7. Combined treatment

Combined plaque irradiation and laser photocoagulation or thermotherapy have been used recently to increase the likelihood of complete local tumour destruction, particularly in patients with tumours adjacent to the optic disc. In 1998, Shields et al. published the results of 100 patients treated with plaque and transpupillary thermotherapy and found a recurrence rate of 3% in 8 years.

## 8. Proton beam radiotherapy

Proton-beam radiotherapy (PBRT) was first utilized in the management of uveal melanoma in 1975<sup>6</sup>. It is now predominantly used for choroidal and ciliary body melanomas. PBRT is an alternative method of delivering radiation to an ocular tumour that uses charged particles, either protons or helium ions (PBRT). Tantalum clips are fixed to the episcleral surface around the base of the tumour, and charged particles are then directed toward the tumour from an anterior approach. With this technique the dose is delivered in four or five equivalent fractions over a 7-days period. Typically a total dose of 70 Cobalt gray equivalent (CGE) is administered over 5 fractions.

The density of ionization of protons increases markedly near the end of their path (Bragg peak). This characteristic enables accurate treatment, especially important for large lesions close to vital ocular structures. The advantages of charged particles include a uniform dose distribution throughout the treatment zone and a predictable area of treatment, since protons travel in a straight line and stop after a certain distance based on the initial energy imparted. Figure 5

No handling of radioactive material is required by the ophthalmologist or the radiation oncologist dealing with PBRT, in contrast to brachytherapy where handling is required. The highly collimated beam of irradiation includes a 1 mm tumour margin, a 0.5 mm margin for patient movement and a 1 mm margin for the penumbral effect. Seventy percent of the maximum radiation dose is delivered by the entrance beam as it travels through the eye before reaching the tumour. Therefore anterior complications including epiphora, lash loss and neovascular glaucoma occur more frequently with charged particles than with radiation delivered posteriorly<sup>7</sup>.

As of December 2002 more than 3000 patients with uveal melanoma have been treated with protons at the Massachusetts General Hospital. The 5-year actuarial local control rate is 96% for all sites within the globe, with an 80% survival rate. The probability of eye retention at 5 years was estimated to be 90% for the entire group and 97%, 93% and 78% for patients

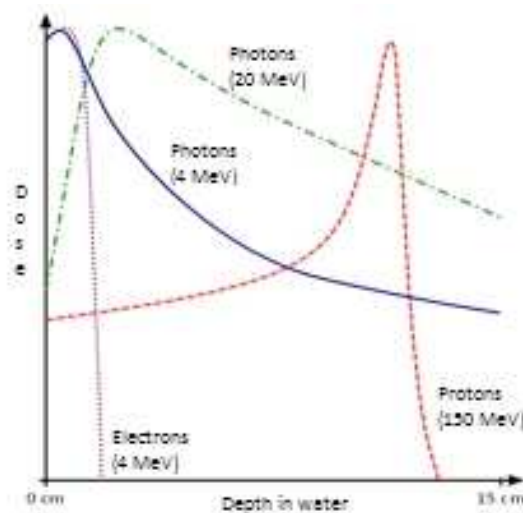


Fig. 5.

with small, intermediate and large tumours respectively. Independent risk factors for enucleation were the involvement of the ciliary body, a tumour height greater than 8 mm and the distance between the posterior tumour edge and the fovea<sup>8</sup>. These results compare favourably with local control rates of 89% reported with protons in Nice, France<sup>9</sup>, and similar results from the Paul Scherrer Institute in Villigen, Switzerland.<sup>10</sup>

Because some patients have experienced deteriorating vision after doses of 70 CGE, a randomized trial of 50 versus 70 CGE for small and intermediate-sized lesions located within 6 mm of the optic disc of the macula was conducted. Interim analysis of 188 patients, with a median follow-up of 60 months suggested no reduction in local control or survival. No significant improvement in visual outcomes or complications was observed. However visual field analysis showed a smaller mean defect in the patients randomized to 50 CGE<sup>11</sup>.

Egger et al. reported long-term results of eye retention after treatment of uveal melanoma with proton beam radiotherapy<sup>12</sup>. A total of 2645 patients (2648 eyes) were treated at the Paul Scherrer Institute in Switzerland between 1984 and 1999. The overall eye retention rates at 5, 10 and 15 years after treatment were 89, 86 and 83% respectively. Enucleation was related to large tumour size, mainly tumour height, male gender, high intraocular pressure and a large degree of retinal detachment at treatment time.

Gragoudas et al. reported that radiation maculopathy occurred in approximately 75% of tumours within 1 disc diameter of the fovea and in 40% of tumours greater than 1 disc diameter from the fovea treated with PBRT<sup>11</sup>.

Wilson and Hungerford found local recurrence of 5.2% with PBRT. Metastatic death rates of 12.8% at 5 years and 20.7% at 10 years were reported following PBRT<sup>13</sup>.

## 9. Stereotactic radiosurgery

Newer techniques like stereotactic radiosurgery and gammaknife radiotherapy are being used at some centres; however, no long-term data is available on the efficacy or complication rates.

Gammaknife radiosurgery (GKR) was initially introduced to successfully treat intracranial lesions such as brain tumours, vascular abnormalities, skull base tumours and neurological

functional diseases. Gammaknife radiosurgery has been shown to be an alternative to enucleation for the treatment of large uveal melanomas.

## 10. Methods

### 10.1 Extraocular muscle sutures

After the patient receives retrobulbar anesthesia with long-acting agents (5 cm<sup>3</sup> of 1% Ropivacaine) to obtain complete akinesia, two extraocular muscles are sutured through the conjunctiva using 3.0 black silk suture. The two muscles are chosen according to tumour location to optimise globe position during treatment.

### 10.2 Stereotactic lightweight aluminium frame fixation

The stereotactic frame is attached to the patient's head with four pins lodged in the outer plate of the skull. The frame provides the coordinate system for target determination by magnetic resonance imaging.

### 10.3 Globe immobilisation and orientation

The threads of the two sutured muscles are fixed to the stereotactic frame to immobilise and orientate the globe. The globe is oriented in order to localise the tumour as closely as possible to the centre of the stereotactic frame. This condition may reduce magnetic resonance image distortion. Correct globe immobilisation is crucial to performing precise GKR.

### 10.4 Neuroimaging

High-resolution magnetic resonance (2 mm slices) with gadolinium of the brain is performed, and the images are transferred to the gamma knife three-dimensional treatment planning system (Gamma Plan). The use of gadolinium increases the definition of tumour margins in the presence of subretinal fluid and retinal detachment.

Besides the advantages of being non-invasive and easier for the patient to tolerate, radiosurgery provides a single day treatment that can be completed within a few hours<sup>14, 15</sup>. No other technique offers the same convenience for the patient. Although previous studies have shown GKS to be a minimally invasive, eye-saving treatment modality for uveal melanomas, secondary enucleation is still common with this procedure. Tumour volume and tumour location are thought to be major determinants of intraocular complications after GKS. Eagan et al. proposed that tumours of the ciliary body and tumors larger than 8 mm in height are more likely to require secondary enucleation after treatment. Complications of the treatment itself may also lead to enucleation.

For a series of 81 patients who underwent GKS for the treatment of uveal melanoma, Simanová et al. achieved an 84% local tumour control rate at 10 months by applying a minimum dose of 31.4 Gy<sup>16</sup>. Similarly, Modorati and colleagues achieved 91% tumour control in a group of 78 patients treated with 30–50 Gy of radiation at the tumour periphery. However, they observed high complication rates, including enucleation (10.3%), retinal detachment (33.3%) and glaucoma (18.7%). Zehetmayer et al. used one to three fractions of GKS for 62 selected uveal melanoma patients, with a mean follow-up of 28.3 months, achieving a tumour control rate of 98%. In a previous series involving GKS, doses as high as 70 Gy were applied to the immobilized the eye during the procedure; however, it appears

that the high intraocular complication rate associated with higher doses may jeopardize the conservative advantages of GKS.

## 11. Other treatment modalities

### 11.1 Trans-scleral resection

Local trans-scleral resection has largely been abandoned in favour of more successful treatment methods. In 1986, Foulds and Damato recommended local resection for tumours of 10 to 15 mm in diameter after finding that most of the failures in their series involved tumours larger than 15 mm in diameter. They reported a 19% incidence of retinal detachment as a result of the surgery, only 41% of which responded well to repair<sup>17, 18</sup>. However, 81.1% of the eyes in the COMS showed local invasion of the sclera which the authors stated argued against the advisability of scleral resection as a treatment for choroidal melanoma due to the fact that potentially viable melanoma cells are likely to remain following surgery<sup>19</sup>. Proponents of transcleral resection now recommend adjuvant brachytherapy to irradiate any remaining tumor cells<sup>20</sup>.

### 11.2 Transpupillary Thermotherapy (TTT)


TTT uses a diode laser to deliver a beam of infrared radiation through a dilated pupil into an intraocular tumour in order to induce tumour cell necrosis<sup>21</sup>.

The entire surface of the tumour is covered with overlapping treatment areas extending 1.5 mm past the edge of the tumour into normal tissue. The advantages of TTT include immediate necrosis with quickly evident clinical regression, precision of treatment, and ease of treatment on an outpatient basis with local anesthesia. TTT causes less choroidal damage than plaque radiotherapy. However, TTT cannot be performed if the pupil cannot be dilated to allow passage of the beam, if the tumour is so peripheral that the edges are not visible, if opacities prevent a clear view, or if there is more than 3 mm of subretinal fluid. TTT has been used successfully in select cases where plaque brachytherapy has failed. TTT has also been combined with plaque radiotherapy in a technique called sandwich therapy, as TTT is maximally effective at the apex of the tumour and brachytherapy is maximally effective at the base<sup>22, 23, 24</sup>. Moreover, TTT may show benefit in the treatment of hemangiomas and small retinoblastomas in addition to uveal melanomas.

## 12. References

- [1] Finger PT. Radiation therapy for choroidal melanoma. *Surv Ophthalmol.* 1997; 42: 215-232.
- [2] Diener-West M, Earle JD, Fine S et al. The COMS randomized trial of iodine 125 brachytherapy for choroidal melanoma, III: initial mortality findings. COMS Report No. 18. *Arch Ophthalmol.* 2001 Jul; 119(7): 969-82
- [3] Melia BM, Abramson DH, Albert DM et al. Collaborative ocular melanoma study (COMS) randomized trial of I-125 brachytherapy for medium choroidal melanoma. I. Visual acuity after 3 years COMS report no.16. *Ophthalmology.* 2001 Feb;108(2):348-66.
- [4] The Collaborative Ocular Melanoma Study (COMS) randomized trial of pre-enucleation radiation of large choroidal melanoma II: initial mortality findings. COMS report no. 10. *Am J Ophthalmol.* 1998 Jun;125(6):779-96.

- [5] Mortality in patients with small choroidal melanoma. COMS report N<sup>o</sup>.4. The Collaborative Ocular Melanoma Study Group. *Arch Ophthalmol.*1997; 115:886-893.
- [6] Gragoudas ES, Goitein M, Koehler AM, et al. Proton irradiation of small choroidal malignant melanomas. *Am J Ophthalmol.* 1977;83:665-73.
- [7] *Clinical Radiation Oncology.* Gunderson and Tepper. Second edition. Churchill-Livingstone. Elsevier. 2007.
- [8] Munzenrider JE: Proton therapy for uveal melanomas and other eye lesions. *Strahlenther Onkol* 175 (suppl 2): 68, 1999.
- [9] Courdi A, CaujolleJP, Grange JD et al: Results of proton therapy of uveal melanomas treated in Nice. *Int J Radiat Oncol Biol Phys* 45: 5-11, 1999.
- [10] Egger E, Schalenbourg A, Zografos L, et al: Maximizing local tumor control and survival after proton beam radiotherapy of uveal melanoma. *Int J Radiat Oncol Biol Phys* 51: 138-147, 2001.
- [11] Gragoudas ES, Lane AM, Regan S. A randomized controlled trial of varying radiation doses in the treatment of choroidal melanoma. *Arch Ophthalmol.* 2000; 118:773-778.
- [12] Egger E, Zografos L, Schalenbourg A et al: Eye retention after proton beam radiotherapy for uveal melanomas. *Int J Radiat Oncol Biol Phys* 55: 867-880, 2003.
- [13] Wilson NW, Hungerford JL. Comparison of episcleral plaque and proton beam radiotherapy for the treatment of choroidal melanoma. *Ophthalmology.*1999; 106: 1579-1587.
- [14] Fakiris AJ, Lo SS, Henderson MA, et al. Gamma-knife-based stereotactic radiosurgery for uveal melanoma. *Stereotact Funct Neurosurg* 2007;85:106-12.
- [15] Modorati G, Miserocchi E, Galli L, et al. Gamma knife radiosurgery for uveal melanoma: 12 years of experience. *Br J Ophthalmol* 2009;93:40-4.
- [16] Simonová G, Novotný J, Liscák R, et al. Leksell gamma knife treatment of uveal melanoma. *J Neurosurg* 2002;97(5 Suppl.):635-9.
- [17] Foulds WS, Damato BE. Alternatives to enucleation in the management of choroidal melanoma. *Aust N Z J Ophthalmol.* 1986;14: 19-27.
- [18] Darren J. Bell, MD, and Matthew W. Wilson, MD. Choroidal Melanoma: Natural History and Management Options. *Cancer Control.* 2004, Vol. 11, No.5
- [19] Histopathologic characteristics of uveal melanomas in eyes enucleated from the Collaborative Ocular Melanoma Study. COMS report No. 6. *Am J Ophthalmol.* 1998;125:745-766
- [20] Damato B, Lecuona K. Conservation of eyes with choroidal melanoma by a multimodality approach to treatment: an audit of 1632 patients. *Ophthalmology.* 2004;111:977-983
- [21] Shields CL, Shields JA, Perez N, et al. Primary transpupillary thermotherapy for small choroidal melanoma in 256 consecutive cases: outcomes and limitations. *Ophthalmology.* 2002;109:225-234
- [22] Robertson DM, Buettner H, Bennett SR. Transpupillary thermotherapy as primary treatment for small choroidal melanomas. *Arch Ophthalmol.* 1999;117:1512-1519
- [23] Stoffelns BM. Primary transpupillary thermotherapy (TTT) for malignant choroidal melanoma. *Acta Ophthalmol Scand.* 2002; 80:25-31.
- [24] Journée-de Korver JG, Oosterhuis JA, de Wolff-Rouendaal D, et al. Histopathological findings in human choroidal melanomas after transpupillary thermotherapy. *Br J Ophthalmol.* 1997;81:234-239.



## **Treatment of Metastatic Melanoma**

Edited by Ms Rachael Morton

ISBN 978-953-307-574-7

Hard cover, 348 pages

**Publisher** InTech

**Published online** 03, October, 2011

**Published in print edition** October, 2011

Surgery continues to be the mainstay treatment for melanoma localized to the primary tumor and/or lymph nodes. Results from randomized controlled trials indicate that sentinel node biopsy for the treatment of cutaneous melanoma of intermediate thickness has a beneficial effect on recurrence rates, and adjuvant radiotherapy to regional lymph node fields following surgical resection reduces loco-regional recurrence in patients at high risk of relapse. Isolated limb perfusion, electrochemotherapy, and photodynamic therapy continue to be evaluated for treatment of stage IV disease. However, the greatest excitement in new treatment has been with targeted therapies for genetic mutations. In particular, the promising results of partial and complete tumor response in stage IV disease from early phase trials of the B-RAF kinase inhibitors. This book provides a contemporary insight into the therapeutic treatment options for patients with metastatic melanoma and is relevant to clinicians and researchers worldwide. In addition, an update on current clinical trials for melanoma treatment has been included, and two chapters have been reserved to discuss the treatment of oral and uveal melanoma.

### **How to reference**

In order to correctly reference this scholarly work, feel free to copy and paste the following:

Raquel Correa, Mario Lobato and José Antonio Medina (2011). Choroidal Melanoma, Treatment of Metastatic Melanoma, Ms Rachael Morton (Ed.), ISBN: 978-953-307-574-7, InTech, Available from:  
<http://www.intechopen.com/books/treatment-of-metastatic-melanoma/choroidal-melanoma>

**INTECH**  
open science | open minds

### **InTech Europe**

University Campus STeP Ri  
Slavka Krautzeka 83/A  
51000 Rijeka, Croatia  
Phone: +385 (51) 770 447  
Fax: +385 (51) 686 166  
[www.intechopen.com](http://www.intechopen.com)

### **InTech China**

Unit 405, Office Block, Hotel Equatorial Shanghai  
No.65, Yan An Road (West), Shanghai, 200040, China  
中国上海市延安西路65号上海国际贵都大饭店办公楼405单元  
Phone: +86-21-62489820  
Fax: +86-21-62489821

© 2011 The Author(s). Licensee IntechOpen. This is an open access article distributed under the terms of the [Creative Commons Attribution 3.0 License](#), which permits unrestricted use, distribution, and reproduction in any medium, provided the original work is properly cited.

IntechOpen

IntechOpen