

We are IntechOpen, the world's leading publisher of Open Access books Built by scientists, for scientists

4,800

Open access books available

122,000

International authors and editors

135M

Downloads

Our authors are among the

154

Countries delivered to

TOP 1%

most cited scientists

12.2%

Contributors from top 500 universities



WEB OF SCIENCE™

Selection of our books indexed in the Book Citation Index
in Web of Science™ Core Collection (BKCI)

Interested in publishing with us?
Contact book.department@intechopen.com

Numbers displayed above are based on latest data collected.

For more information visit www.intechopen.com



CT Scanning and Dental Implant

Yeon-Jo Choi¹, Sang-Ho Jun², Young-Dae Song³,
Myoung-Woo Chang⁴ and Jong-Jin Kwon⁵

^{1,2,3,5}Department of Dentistry Korea University Medical Center

⁴Restorative Dentistry and Biomaterials Sciences
Harvard School of Dental Medicine

^{1,2,3,5}Korea

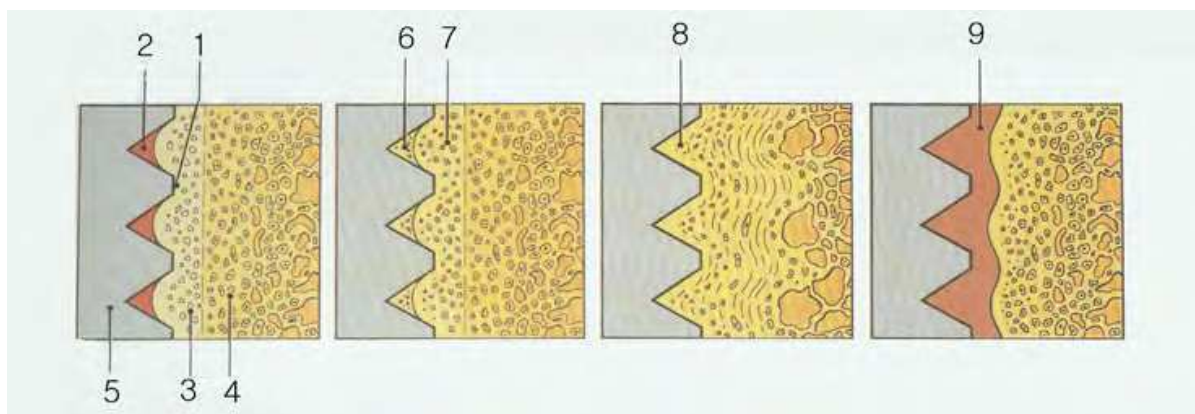
⁴U.S.A.

1. Introduction

1.1 Osseointegration and bone density

Osseointegrated screw-shaped titanium implants that support dental prosthesis have been used to restore function and esthetics of missing teeth with favorable clinical results. Restoration using dental implants is now the most popular treatment in the field of dentistry. Since Brånemark P-I reported the treatment using titanium-made dental implants for the edentulous patient in 1977, there has been enormous advancement in the field of implant dentistry.

Successful osseointegration, which is an utmost determining factor for the success of implant treatments, has been viewed as the direct, structural, and functional connection existing between ordered, living bone and the surface of a functionally loaded implant (Fig. 1 a to d). Many clinical studies and investigations were performed to propose success criteria for dental implants. Albrektsson et al. report in 1986 was specific for implants with rigid fixation and is widely used today (Table 1).



From Brånemark P, Zarb G, Albrektsson T. Introduction to osseointegration. In: Brånemark PI, ZarbGA, Albrektsson T (eds). *Tissue-integrated Prostheses: Osseointegration in clinical Dentistry*. Chicago: Quintessence, 1985:12.

Fig. 1. Diagrammatic representation of biology of osseointegration

Fig. 1a The threaded bone site cannot be made perfectly congruent to the implant. Object of making a threaded socket in bone is to provide immobilization immediately after installation and during the initial healing period. The diagram is based on relative dimensions of fixture and fixture site. 1 = contact between fixture and bone (immobilization); 2= hematoma in closed cavity. Bordered by fixture and bone; 3= bone that was damaged by unavoidable thermal and mechanical trauma; 4= original undamaged bone; and 5 = fixture.

Fig. 1b During the unloaded healing period, the hematoma becomes transformed into new bone through callus formation (6). Damaged bone, which also heals, undergoes revascularization, and demineralization and remineralization (7).

Fig. 1c After the initial healing period, vital bone tissue is in close contact with fixture surface, without any other intermediate tissue. Border zone bone (8) remodels in response to the masticatory load applied.

Fig. 1d In unsuccessful cases nonmineralized connective tissue (9), constituting a kind of pseudoarthrosis, forms in the border zone at the implant. This development can be initiated by excessive preparation trauma, infection, loading too early in the healing period before adequate mineralization and organization of hard tissue has taken place, or supraliminal loading at any time, even many years after integration has been established. Once lost, osseointegration cannot be reconstituted. Connective tissue can become organized to a certain degree, but is not a proper anchoring tissue because of its inadequate mechanical and biologic capacities, resulting in creation of a locus minorisresistentiae.

Immobility	An individual, unattached implant is immobile when tested clinically
No periimplantradioducency	A radiograph does not demonstrate any evidence of periimplant radiolucency
Vertical bone loss	Vertical bone loss is less than 0.2mm annually following the implant's first year of service
No symptoms	Individual implant performance is characterized by an absence of persistent and/or irreversible signs and symptoms such as pain, infections, neuropathies, paresthesia, of violation of the mandibular canal
Long term survival rate	In the context of the above, a success rate of 85% at the end of a 5-year observation period and 80% at the end of a 10-year period are minimum criteria for success

From Albrektsson T, ZarbGA, Worthington P et al: The long-term efficacy of currently used dental implants: a review and proposed criteria of success, *Int J Oral MaxillofacImplants* 1986;1:1.

Table 1. Criteria for Implant Success

Implant stability, an indirect indication of osseointegration, is a measure of the clinical mobility of an implant and plays an essential role in the long-term success of dental implants. It is classified into two; 1) primary and 2) secondary. Primary stability mostly comes from mechanical engagement of cortical bone, and it is a function of local bone

quality and quantity, the geometry of an implant (i.e. length, diameter, and type), and the placement technique used. Primary stability occurs at the time of implant placement and is related to the level of primary bone contact and to the biomechanical properties of the surrounding bone. Secondary stability offers biological stability through remodeling and regeneration of surrounding bone, and results after the formation of secondary bone contact of woven and lamellar bone. During the early phase of healing process after implant placement osseointegration of the implant relies on primary or mechanical stability, and secondary or biological stability plays a major role for osseointegration with the decrease of primary stability over time (Fig. 2).

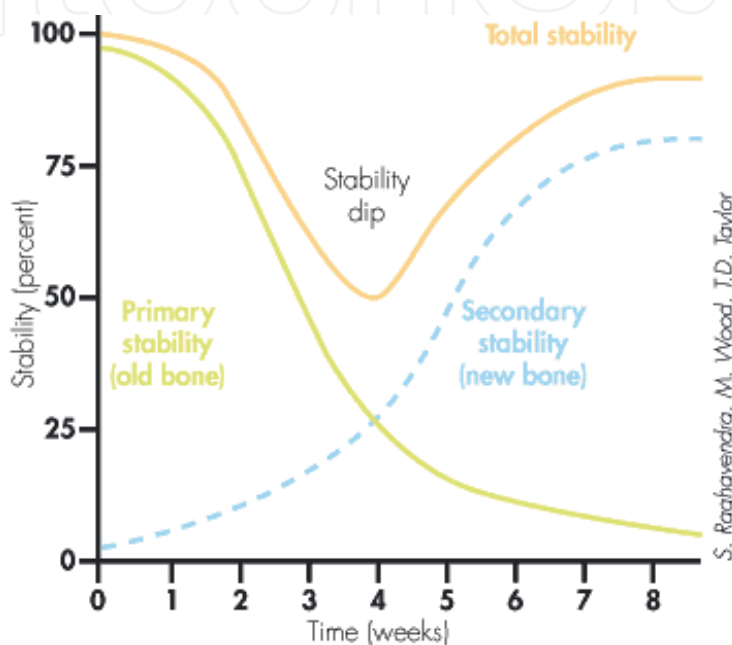


Fig. 2. Implant Stability Dip

Primary stability is a requirement of successful secondary stability. The latter, however, dictates the time of functional loading. Secondary stability has been shown to begin to increase at 4 weeks after implant placement.

Osseointegration and implant stability is affected by various factors during healing process (Table 2).

Factors affecting primary stability
Bone quality and quantity
Surgical technique, including the skill of the surgeon
Implant; geometry, length, diameter, surface characteristics
Factors affecting secondary stability
Primary stability
Bone regeneration and remodeling
Implant surface conditions

Table 2. Factors affecting implant stability

Available bone is particularly important in implant dentistry and describes the external architecture or volume of the edentulous area considered for implants. In addition, bone has an internal structure described in terms of density or quality, which reflects the strength of the bone. The density of available bone in an edentulous site is a determining factor in treatment planning, implant design, surgical approach, healing time, and initial progressive bone loading during prosthetic reconstruction.

The classification of bone density and its relation to dental implant treatments have been evaluated in the last three decades. Linkow in 1970, classified bone density into three categories:

Class I bone structure: This ideal bone type consists of evenly spaced trabeculae with small cancellated spaces.

Class II bone structure: The bone has slightly larger cancellated spaces with less uniformity of the osseous pattern.

Class III bone structure: large marrow-filled spaces exist between bone trabeculae.

Linkow stated that Class III bone results in a loose-fitting implant; Class II bone was satisfactory for implants; and Class I bone was a very satisfactory for implant restoration.

In 1985, Lekholm and Zarb listed four bone qualities based on both the radiographic assessment, and the sensation of resistance experienced by the surgeon when preparing the implant placement (Table 3; Fig. 3).

Quality 1: Entirely homogeneous compact bone

Quality 2: A thick layer of compact bone surrounding a core of dense trabecular bone

Quality 3: A thin layer of cortical bone surrounding dense trabecular bone of favorable strength

Quality 4: A thin layer of cortical bone surrounding a core of low-density trabecular bone

Bone type	Grade 1	Grade 2	Grade 3, 4
Cortical bone	Thick	Moderate	(very)Thin
Trabecular bone	Dense	Moderate	(very)Poor

Table 3. Tactile evaluation of the cortical and trabecular bone during surgery

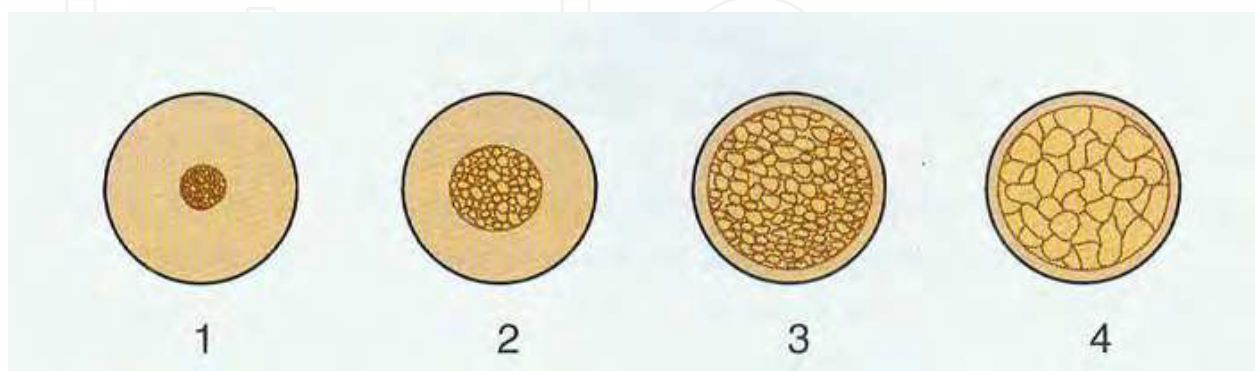


Fig. 3. Grading system for bone quality assessment (Lekholm & Zarb 1985).

In 1988, Misch defined four bone density groups based on macroscopic cortical and trabecular bone characteristics (Table 4). Based on Misch classification of bone density, human jaw bone is divided into the four regions and listed in Table 5.

Bone	Density
D1	Dense cortical bone
D2	Thick dense to porous cortical bone on crest and coarse trabecular bone within
D3	Thin porous cortical bone on crest and fine trabecular bone within
D4	Fine trabecular bone

Table 4. Misch Bone Density Classification

Bone	Anterior maxilla	Posterior maxilla	Anterior mandible	Posterior mandible
D1	0	0	6	3
D2	25	10	66	50
D3	65	50	25	46
D4	10	40	3	1

Table 5. Usual Anatomic Location of Bone Density Types (% Occurrence)

Osseointegrated implants have created a revolution in functional and esthetic rehabilitation in clinical dental practice. The surgical protocol proposed by Brånemark in 1969 included a 2-stage surgical technique: The implant was placed in bone and completely covered by oral mucosa, so that functional loading was avoided during the initial healing period of the bone tissue. The recommended healing period before functional loading was 6-month for maxilla and 4-month for mandible (Fig. 4).




Fig. 4. Three Different Surgical approaches: (A) 2-stage (healing submerged, then uncover surgery), (B) 1-stage (implant with permucosal healing, no uncover surgery), and (C) immediate restoration (restoration placed at the time of the surgical placement).

However, the requirement of a healing period under submerged and stress-free conditions has been questioned. Research into immediate loading protocols has shown encouraging results since the 1980s. Several studies involving immediate loading of implants placed using a 1-step surgical protocol have been published in an attempt to improve the esthetic results, reduce the treatment period, and simplify the treatment process. In immediate

loading protocols, an implant is placed in bone and loaded at once or within 48 hours of surgery. Immediate loading of dental implants has recently gained popularity due to such advantages from both clinicians and patients.

A fundamental prerequisite for the success of immediate loading of dental implants is bone density and primary stability at the time of insertion and following functional loading of the implant. If strong mechanical retention resulting from primary stability is not gained at the time of implant placement, there is a high risk of implant failure due to immediate functional or occlusal loading applied onto the implant. A poor bone density has been indicated as the main risk factors of implant failure as it may be associated with excessive bone resorption and impairment in the healing process compared with higher density bone. Therefore, the bone density of recipient sites of implants has to be precisely analyzed before, during, and after implant placement for the long-term success.

The three fore-mentioned classifications of bone density heavily rely on the clinician's tactile sensation of drilling into jaw bone during implant placement and the subjective radiographic evaluation of the clinician. Presently, more objective diagnostic analyses have been suggested to evaluate bone density at various time points and to estimate a long term prognosis based upon measured implant stability: 1) Housefield units (Hu) scale of computed tomography (CT), 2) Insertion torque value, 3) Removal torque.

2. Computed tomography

CT was invented by Housefield and was announced to the imaging world in 1972, but it had its origins in mathematics(1917) and astrophysics(1956). The first CT scanners appeared in medical imaging departments during the mid-1970s and were so successful that they largely replaced complex tomography by the early 1980s.

The power and usefulness of CT for maxillofacial imaging and diagnosis were apparent as soon as high resolution CT was introduced in early 1980s. CT was used for imaging the temporomandibular joint, evaluating dental-bone lesion, assessing maxillofacial deformities, and preoperative and postoperative evaluation of the maxillofacial region. CT provides a unique means of postimaging analysis of proposed surgery or implant sites by reformatting the image data to create tangential and cross-sectional tomographic images of the implant site. The density of structures within the image is absolute and quantitative and can be used to differentiate tissues in the region and characterize bone quality (Table 6).

Density	Hounsfield Units
D1	1250
D2	850-1250
D3	350-850
D4	150-350
D5	<150

Table 6. Bone quality

CT enables the evaluation of proposed implant sites and provides diagnostic information that other imaging or combinations of imaging techniques cannot provide. The utility of CT for dental implant treatment planning was evident, but the access to these imaging techniques was limited. And even though advances enhanced diagnostic skills, there were

inherent shortcomings to medical scanners used for dental purposes. Because medical scanners were not developed for dental reformatting, there existed inherent errors such as distortion, magnification, and positioning problems that led to inaccuracies when reformatted (Table 7).

advantages	Negligible magnification
	Relatively high-contrast image
	Various views
	Three-dimensional bone models
	Interactive treatment planning
	Cross-referencing
limitations	Cost
	Technique sensitive
indications	Interactive treatment planning
	Determination of bone density
	Vital structure location
	Subperiosteal implant fabrication
	Determination of pathology
	Preplanning for bone augmentation

Table 7. Computed Tomography

This was overcome with the advent of sophisticated scanning appliances, stereolithographic resin bone models, interactive software, computer-generated surgical guides, and CT-based image-guided navigation system, which allowed for ideal placement and prosthetic outcome to be established.

Although the clinical problems of medical scanners have been remedied, there still existed numerous disadvantages—radiation exposure and availability. The amount of radiation exposure of medical scans has been shown to be excessive and unnecessary. It has been postulated that radiation exposure for a scan involving the maxilla and mandible is equivalent to approximately 20 panoramic radiographs.

3. Cone beam CT

3.1 A new type of CT

To overcome some of the disadvantages of conventional medical CT scanners, a new type of CT specific for dental applications has recently been developed. The x-ray dose absorbed by the patient during CT scanning may limit the use of this modality for routine diagnosis or repeated surveys. However, a new type of CT—CBCT (Cone Beam Computed Tomography) machine for the purpose of dental and maxillofacial imaging has been introduced (NewTom, Model QR-DVT 9000; QR, Verona, Italy) (Fig. 5) that lessens the patient's radiation exposure. The average absorbed radiation dose from a CBCT scanner (NewTom 3G) is approximately 12.0 mSv. This dose is equivalent to five D-speed dental x-rays or 25% of the radiation from a typical panoramic radiograph. Medical scanners acquire images that use radiation doses of 40 to 60 times that of CBCT doses.

The CBCT technique was employed previously in radiotherapy using fluoroscopic systems or modified simulators to obtain cross-sections of the patient in the same geometric

conditions as the treatment. It was also used in vascular imaging and in microtomography of small specimens for biomedical and industrial applications. Nowadays, radiotherapy has become another relevant field for this machine.

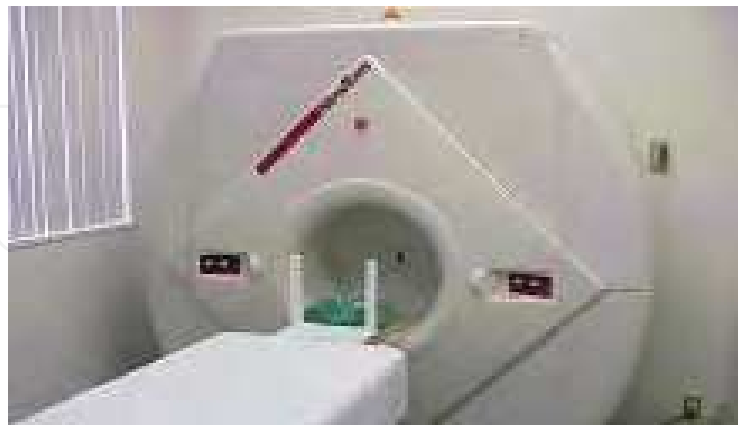

Fig. 5. Cone-beam computerized tomography (CBCT) device (NewTom)

In May 2001, CBCT imaging for dentistry was introduced to the United States by QR srl of Verona, Italy, the manufacturer of the New-Tom. This same company has recently developed a new model named NewTom 3G. Besides the latter, we can presently find four other models: I-CAT (Imaging Sciences International, Hatfield, USA), 3D Panoramic X-ray CT scanner PSR 9000N (Asahi Roentgen, Kyoto, Japan), CB MercuRay (Hitachi Medico Technology Corporation, Kashiwa, Chiba, Japan), and 3D Accuitomo (J. Morita, Kyoto, Japan). Specifications of these cone beam devices devoted to dentistry are shown in Table. 8.

Cone beam CT devices	Company	Size of Reconstructed Image(diameter x height)	X-ray source voltage (kV)	X-ray source current (xtime) mA(s)	Scanning time (s)	Voxel size (xy)	Min reconstruct. Inc. or cubic
3D Accuitomo	J.Morita, Kyoto, Japan	4x3,4x4,6x6	60-80 (step 1kV)	1-10 mA (step 0.1mA)	18	0.125	0.125
NewTom 9000	Quantitative Radiology, Verona, Italy	13x13	110	15 mA	72	0.29	0.2
NewTom 3G		8x8,10x10,13x13,15x15,18x18,22,22	110	15 mA	36	0.16-0.42	0.16
I-CAT	Imaging Sciences, Hatfield, Pennsylvania, USA	16x21,16x13,16x8,16x8	120	12.48 mAs, 23.87 mAs, 46.72 mAs	10,20,40	0.2-0.4	0.2
CB MercuRay	Hitachi, Medical, Kyoto, Japan	5.12x5.12,10.2x10.2, 15x15, 19x19	60-120 (step 20kV)	10 or 15 mA	10	0.1-0.4	0.1
3D Panoramic X-ray CT scanner PSR 9000N	Asahi Roentgen, Kyoto, Japan	3.6x4, 4.1x4	60-100 (step 1kV)	2-12 mA (step 2mA)	20,30	0.1-0.15	0.1-0.15

Table 8. Company, X-ray source voltage, X-ray source current (x time), scanning time, in plane voxel size and reconstruction increment for each cone beam CT device

This technique uses a cone-shaped x-ray beam centered on an x-ray area detector and is termed cone-beam CT (CBCT). As in conventional CT imaging, quantitative bone density measurements expressed in HU can be retrieved (quantitative CBCT [QCBCT]). Volume data can be acquired in a single rotation of the beam and detector (Fig. 6)

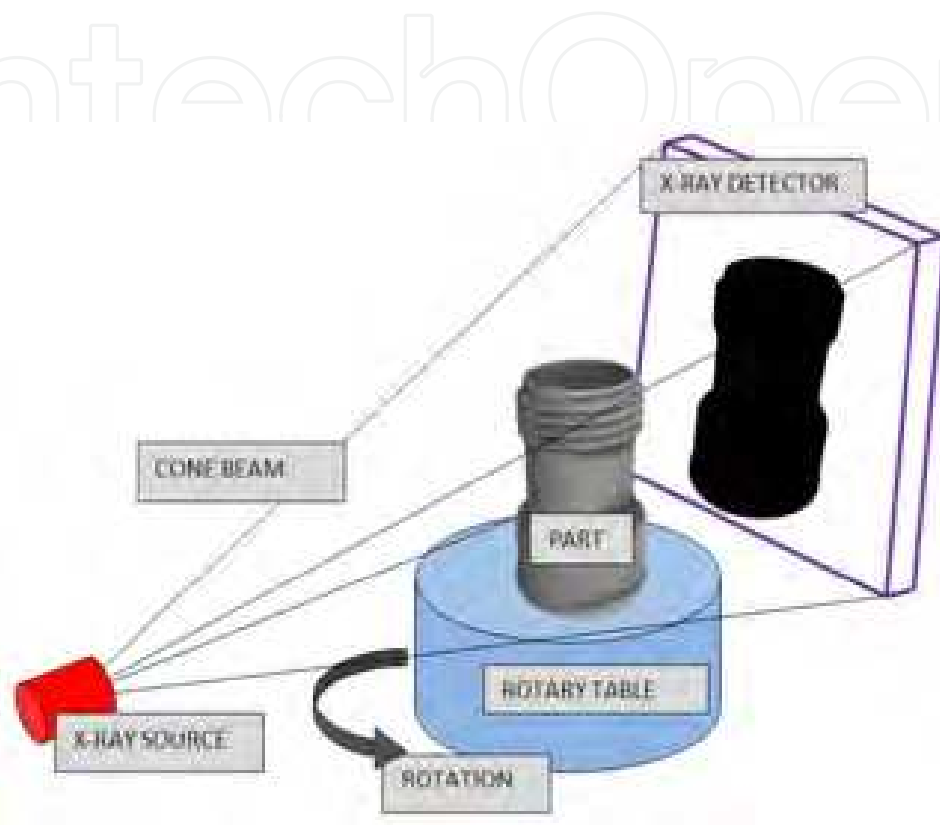


Fig. 6. Cone-shaped x-ray beam centered on an x-ray area detector

The amount of radiation absorbed by the patient for each scan is reportedly 0.62 mGy. Utilization of CBCT clearly illustrates the true 3-D shape and size of all anatomical structures. By combining CBCT and 3-D treatment planning, implants are being placed with ideal prosthetic results.

3.2 Image quality

Image quality on cone beam computed tomography was established that the generation of the CT hardware, data acquisition, and parameters such as slice thickness and interval of the reconstruction can determine the imaging resolution. Schulze et al. demonstrated high-contrast structures with the CBCT device. In addition, several authors revealed excellent image acquisition for different structures such as morphology of the mandible, location of the inferior alveolar canal, and even for the relationship of radioopaque templates to the bone. The error factor in CBCT is determined by the size of the voxel (Fig. 7).

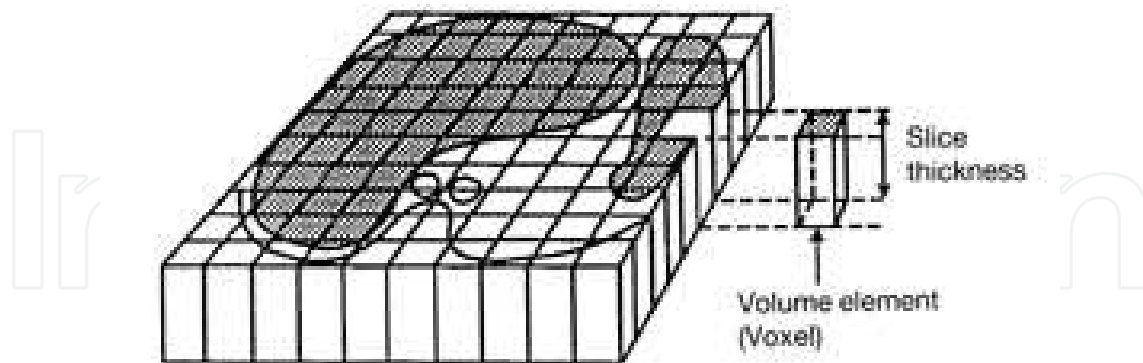


Fig. 7. Voxel Voxel, short for volume pixel, is the smallest distinguishable box-shaped part of a three-dimensional image. Voxelization is the process of adding depth to an image using a set of cross-sectional images known as a volumetric dataset. The dataset is processed when slices are stacked in computer memory based on inter-pixel and inter-slice distances to accurately reflect the real world sampled volume. Now that the data set exists as a solid block of data, the pixels in each slice have taken on volume and are now voxels. For a true 3-D image, voxels must undergo opacity transformation. Opacity transformation gives voxels different opacity values. This is important when it is crucial to expose interior details of an image that otherwise would be hidden by darker more opaque outside-layer voxels.

3.3 CBCT Imaging for implant installation

Implant Installation through the use of CBCT has dramatically helped to improve the placement of implants. Several imaging modalities have been used for the pre-surgical evaluation of implant sites. The panoramic, periapical and cephalometric images contain superimpositions, have large information voids related to depth and are affected by projection geometry so that measurements are not reliable. Only tomography, conventional CT scans and cone beam CT scans provide the information desired about each implant site. When the imaging goals are extended to occlusion, maxillomandibular spatial relationships and the temporomandibular joint then cone beam CT scans stands alone as the best value. Cone beam CT creates the opportunity to extend the information yield beyond the conventional imaging methods and is an ideal modality for implant planning. CBCT produces accurate 3 dimensional image data (Fig. 8). The field of view is scalable and one scan can include the entire maxillofacial region including the maxilla, mandible, base of skull and TMJs. The small voxel size would allow feature detection size and dimensional accuracy in the range of 0.2-0.8 mm. A single cone beam CT scan contains enough information to satisfy the imaging objectives stated above including maxillomandibular spatial relationships. The software used to create the images utilizes tools that accurately mark the delineation of the nerve and provide 1:1 images, allowing for accurate measurements. Software is used to display and visualize the anatomy in a way that is clinically meaningful. The software allows for multiplanar reformation and display.

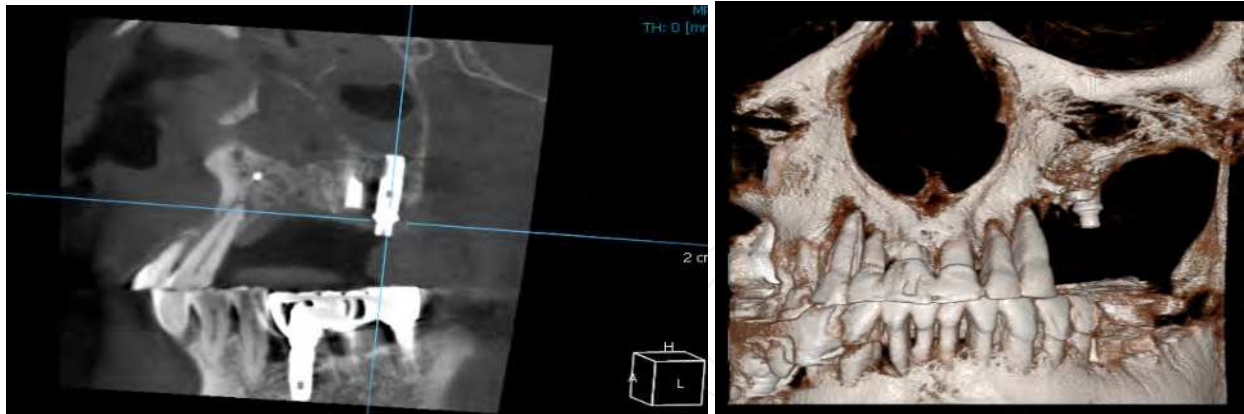


Fig. 8. Accurate 3 dimensional image data of Cone Beam CT (AZ-3000 CT, ASAHI)

But, many surgeons require additional information. They desire the ability to integrate the CBCT data into implant surgery. Using CBCT without any type of radiographic markers or a 3-D program that places implants into the study can be as analogous to arriving at a fork in the road with no directional signs leaving the surgeon unable to understand the true treatment plan (Fig. 9).

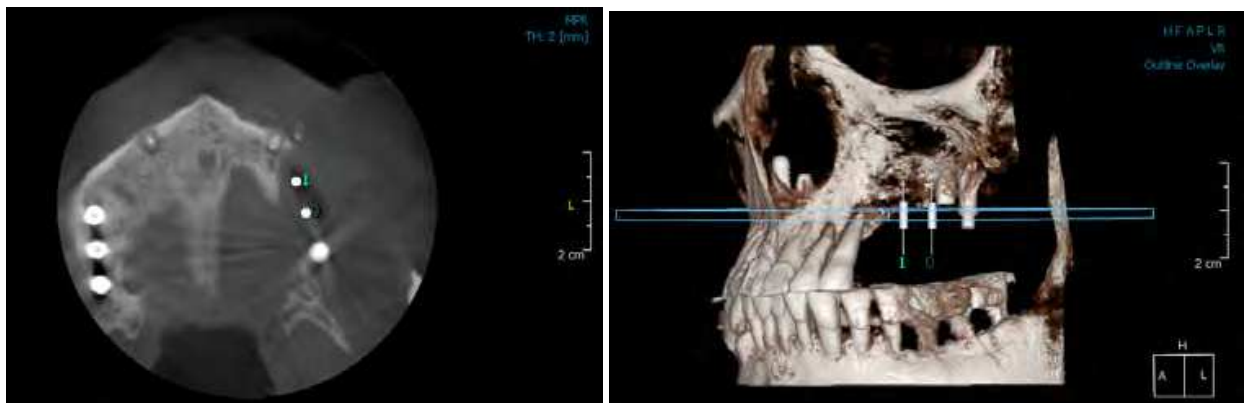


Fig. 9. Virtual Imaging of Implant Installation (AZ-3000 CT, ASAHI)

4. Insertion torque value

The cutting resistance refers to the energy required in cutting of a unit volume of bone (Friberg *et al.*, 1995) while the insertional torque occurs during the fixture tightening procedure (Ueda *et al.*, 1991). Both of these measurements consider the lateral compression force and friction at the interface during implant insertion and are mainly influenced by the tolerance of the fixture thread design (O'Sullivan *et al.*, 2000). Many researchers also used the peak insertional torque value, which is generated during the last fixture tightening step, as an indicator of primary implant stability.

A non-destructive quantitative method is necessary to measure the implant stability (Rasmusson *et al.* 1998). A precise and scientifically established method for the evaluation of the bone quality/primary stability is the measure of the insertion torque (Al-Nawas *et al.* 2006; Rabel *et al.* 2007). The cutting resistance, during implant insertion, has been recommended in the evaluation of bone quality (Johansson *et al.* 2004). A high IT value probably indicates that the implant is stable from a mechanical point of view (Ito *et al.* 2008).

In cutting resistance analysis (CRA), originally developed by Johansson and Strid and later improved by Friberg et al in in vitro and in vivo human models, the energy (J/mm³) required for a currentfed electric motor in cutting off a unit volume of bone during implant surgery is measured. This energy was shown to be significantly correlated with bone density, which has been suggested as one of factors that significantly influences implant stability. To minimize the interoperator variation, hand pressure during drilling was controlled. CRA can be used to identify any area of low-density bone (or poor-quality bone) and to quantify bone hardness during the low-speed threading of implant osteotomy sites. A torque gauge incorporated within the drilling unit (eg, Osseocare; Nobel Biocare, Göteborg, Sweden) can be used to measure implant insertion torque in Ncm to indirectly represent J/mm³. Insertion torque values have been used to measure bone quality in various parts of the jaw during implant placement.

CRA gives a far more objective assessment of bone density than clinician-dependent evaluation of bone quality based on Lekholm and Zarb classification. Clinical relevance was demonstrated by studies that showed the highest frequency of implant failures in jaws with advanced resorption and poor bone quality, often seen in maxilla. Therefore, cutting resistance value may provide useful information in determining an optimal healing period in a given arch location with a certain bone quality.

The major limitation of CRA is that it does not give any information on bone quality until the osteotomy site is prepared. CRA also cannot identify the lower “critical” limit of cutting torque value (ie, the value at which and implant would be at risk). Furthermore, longitudinal data cannot be collected to assess bone quality changes after implant placement. Its primary use, therefore, lies in estimating the primary stability of an implant. For instance, in Misch’s 6 time-dependent stages of implant failure-(1)surgical, (2)osseous healing, (3) early loading, (4) intermediate, (5)late, and (6) long-term- CRA can only provide information on the first 2 stages. Estimation of implant primary stability alone from CRA is still of value, as high implant failure rates are observed in the first 3 phases. Nonetheless, long-term evaluation of implant stability after implant placement, phases 3 to 7, is desired and should not be overlooked. This Limitation has led to development of other diagnostic tests. Table 9 summarizes CRA.

advantages	Detect bone density
	High correlation between cutting resistance and bone quality
	Reliable method to assess bone quality
	Identify bone density during surgery
	Can be used in daily practice
disadvantages	Can only be used during surgery

Table 9. Advantages and disadvantages of CRA

5. Removal torque value

The removal torque refers to the torsional force necessary for unscrewing the fixture and was first investigated by Johansson and coworkers (Johansson *et al.*, 1998). The removal torque value was recorded using a torque manometer calibrated in Newton-centimeters (Ncm).

Unlike CRA, which measures the bone density and the resistance to cutting torque, the reverse torque test (RTT), proposed by Roberts et al. and developed by Johansson and Albrektsson, measures the “critical” torque threshold where bone-implant contact (BIC) was destroyed. This indirectly provides information on the degree of BIC in a given implant. In the study conducted by Johansson and Albrektsson, a reverse torque was applied to remove implants placed in the tibiae of rabbits 1, 3, 6, and 12 months postsurgery. Reverse torque value and histologic evaluation showed that greater BIC could be achieved with a longer healing time. Similar observations at the histologic level have been made in other animal studies. Removal torque value (RTV) as an indirect measurement of BIC or clinical osseointegration was later reported to range from 45 to 48 Ncm in 404 clinically osseointegrated implants in humans. Sullivan et al further speculated that any RTV greater than 20Ncm may be acceptable as a criterion for a successful osseointegration, since none of the implants in their study could be removed during abutment connection at 20Ncm. It was further suggested that RTT is, therefore, a reliable diagnostic method for verification of osseointegration.

However, this method has been criticized as being destructive. Brånemark et al cautioned about the risk of irreversible plastic deformation within peri-implant bone and of implant failure if unnecessary load was applied to an implant that was still undergoing osseointegration. Furthermore, a 20Ncm threshold RTV for successful osseointegration has not yet been supported by scientific data. The threshold limit varies among patients depending on the implant material and the bone quality and quantity. A threshold RTV may be lower in type 4bone than in denser bone, for instance. Hence, subjecting implants placed in this bone type to RTV may result in a shearing of BIC interface and cause implant failure. Furthermore, RTV can only provide information as to “all or none” outcome (osseointegrated or failed); it cannot quantify degree of osseointegration. Hence, RTT is only used in experiments and has no clinical meaning.

6. Periotest

Periotest (Siemens AG, Bensheim, Germany) uses an electromagnetically driven and electronically controlled tapping metallic rod in a handpiece (Fig. 10).

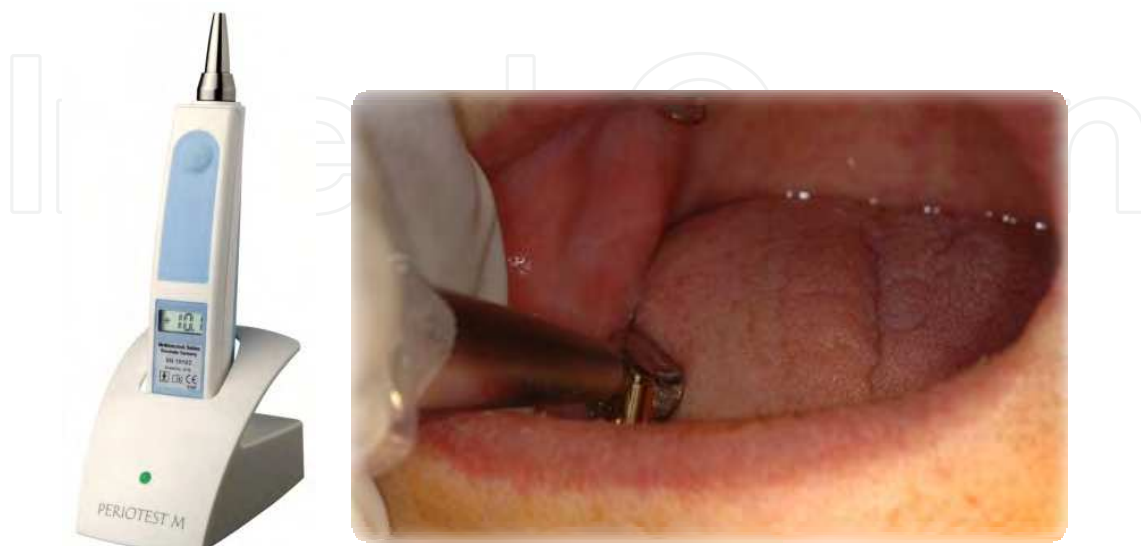


Fig. 10. Periotest (Siemens AG, Bensheim, Germany)

Response to a striking or “barking” is measured by a small accelerometer incorporated into the head. Contact time between the test object and tapping rod is measured on the time axis as a signal for analysis. The signals are then converted to a unique value called the Periotest value (PTV), which depends on the damping characteristics of tissues surrounding teeth or implants. In the case of a natural tooth, the buffering capacity of the PDL poses a problem in analyzing the distribution of impact force exerted on a tooth. When dynamic characteristics are analyzed based upon an assumption that the whole periodontal structure functions as a mechanical unit, it is difficult to model the attenuation from the PDL. The soft tissue, including the periosteum, is considered a viscoelastic medium; thus, Hooke’s law does not apply to the behavior of the PDL under and applied load. Thus, viscoelasticity of the PDL has always posed a difficulty in analysis of the physical characteristics of periodontal tissue. By contrast, bone-implant interface with no PDL is believed to be similar to the serial spring model which follows Hooke’s law, and mobility measurement is considered easier.

Most reports of the use of a natural tooth mobility detector such as Periotest to measure implant mobility have pointed out a lack of sensitivity in these devices. Such devices permit a very wide dynamic range (in case of Periotest, PTV is -8 to +50) to permit the measurement of a wide variety of natural tooth mobility. However, the dynamic range used for measuring implant mobility is very limited. Thus, the sensitivity of these devices is insufficient to measure implant mobility.

In the use of mobility measurement to assess implant stability, the presence or absence of a PDL makes a crucial difference. Similar to impact/vibration testing, values measured with Periotest are significantly influenced by excitation conditions, such as position and direction. The Periotest user’s manual contains clear instructions about striking point position and angle: “The Periotest measurement must be made in a midbuccal direction” and “During measurement the Periotest handpiece must always be held perpendicular to the tooth axes.”

Even if it could be assumed that PTV precisely reflects the condition of BIC (bone implant contact) as reported by previous studies, an average PTV has no importance. Despite a wide variation in host factors such as bone density, normal PTV of an osseointegrated implant falls in a relatively narrow zone (-5 to +5) within a wide scale (-8 to +50). Therefore, the measured PTV may falsely be interpreted as having a small standard deviation and therefore viewed as having a good accuracy. PTV cannot be used to identify a “borderline implant” or “implant in the process of osseointegration” which may or may not continue to a successful osseointegration.

It has been suggested that these limitations of Periotest measurement have been suggested to be strongly related to the orientation of excitation source or striking point. In vitro and in vivo experiments demonstrated that the influence of striking point on PTV is much greater than the effects from increased implant length due to marginal bone resorption or other excitation conditions such as the angle of the handpiece or repercussion of a rod. Unfortunately, controlling these influential factors is extremely difficult. Despite some positive claims for Periotest, the prognostic accuracy of PTV for implant stability has been criticized for a lack of resolution, poor sensitivity, and susceptibility to operator variables.

7. RFA (resonance frequency analysis)

The resonance frequency analysis (RFA) method was presented by Meredith et al in 1996. RFA is a noninvasive diagnostic method that measures implant stability and bone density at various time points using vibration and a principle of structural analysis (Fig. 11).

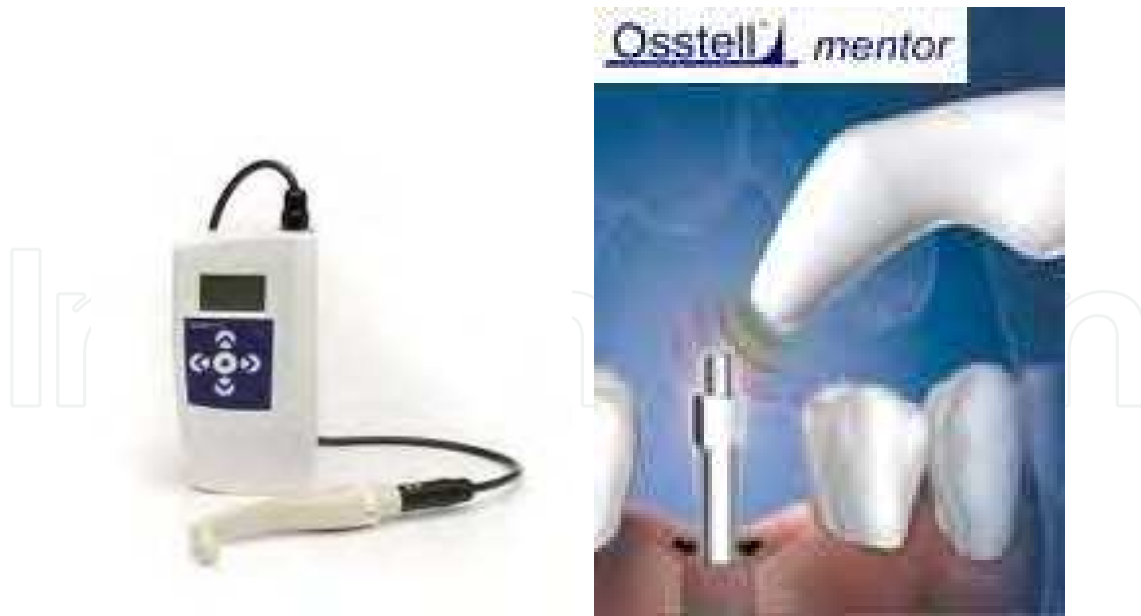

Fig. 11. RFA (Osstell AB, Göteborg, Sweden)

This method uses a small L-shaped transducer that is fastened by a screw to the implant or to the mucosa-penetrating abutment. Two piezoceramic elements are attached to the vertical beam. Using a personal computer, a frequency response analyzer, and dedicated software, the vertical beam of the transducer is vibrated over a range of frequencies, typically 5 kHz to 15 kHz, through one of the piezoceramic elements. The other serves as a receptor for the signal. Resonance peaks from the received signal indicate the first flexural resonance frequency of the measured object. In vitro and in vivo studies have suggested that this resonance peak may be used to assess implant stability in a quantitative manner.

It is assumed that an implant and the surrounding bone function as a single unit; thus, a change in stiffness is considered to represent the change of osseointegration of an implant. A steady-state sinusoidal force in a form of sine wave is applied to the implant-bone unit to measure the implant stability via resonance. Frequency and amplitude are then picked up as a response. Higher frequency and sharp peak indicate more stable implant, whereas a wider and lower peak and lower frequency indicate implant failure. In brief, RFA may be a useful method in predicting the prognosis of the implant after surgery.

8. Dominant frequency sound analyzer

This device (Fig.12) is still under the state of prototype, and its mechanism of striking a target object is quite similar to that of periotest. Periotest measures the contact time of striking rod onto implant surface, and implant stability can be predicted by utilizing the contact time. Sound analyzer evaluates stability of the implant in a different way of analyzing specific striking sound of the implant compared with periotest. The sound of multiple strikes of an object is collected, graphically analyzed (Fig.13), and numerically displayed in average. Depending on the degree of osseointegration and implant stability different sound is produced from the same implant. Further investigations are still necessary to demonstrate versatile application of this device into the field of dentistry based on clinical evidences.

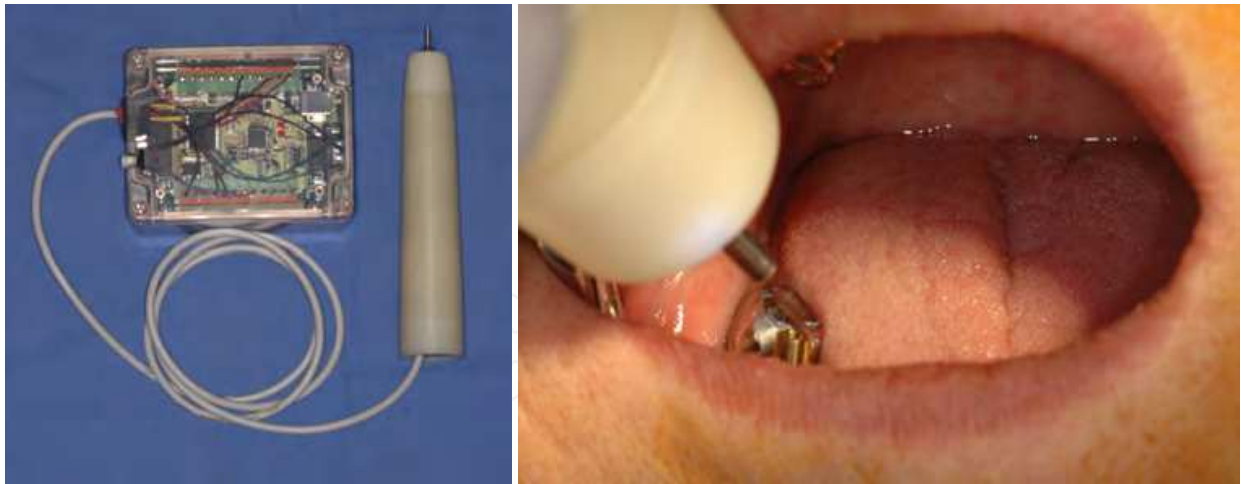


Fig. 12. Dominant Frequency Sound Analyzer

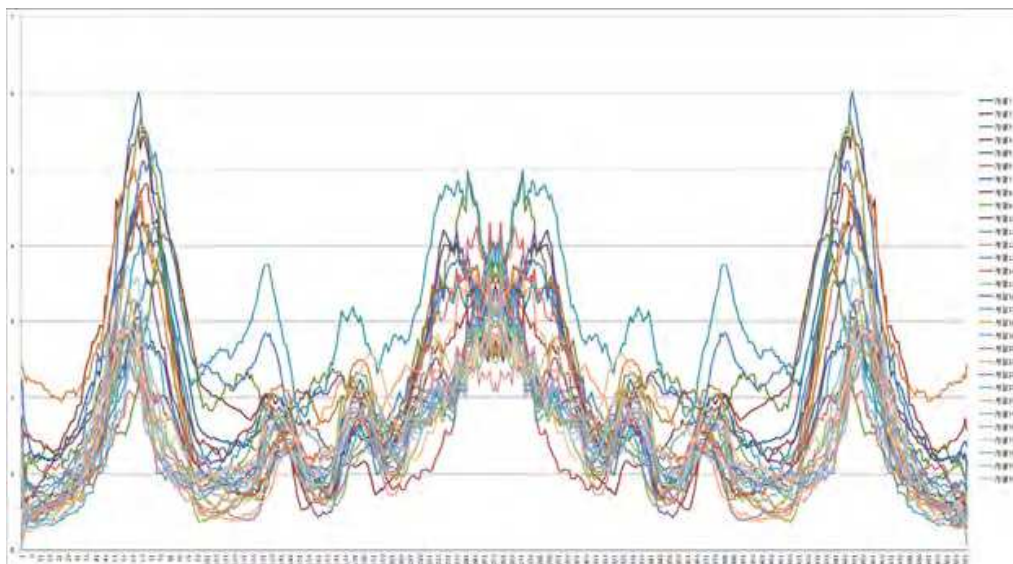


Fig. 13. Graphical analysis of sound analyzer

9. Clinical implications

Currently the use of osseointegrated implants to treat partially or completely the edentulous arch is considered reliable and predictable, with a success rate of 98% or higher. Among the factors affecting implant success, Bone density and implant stability are key factors to take into account and important for implant osseointegration, which has been widely demonstrated by several authors. Clinical studies show greater implant survival in the mandible than in the maxilla, due to the area's characteristics of bone density; more type I, II, or III bones are observed in the mandible than in the maxilla. New 3-D cone beam CT (CBCT) analyzes and classifies implant placement sites based on the bone density in Housefield units (Hu) with high reliability. With the aid of this high technology equipment it is possible to make an accurate treatment plan for the number, size, and location of implants along with the bone density at the implant placement sites and predict prognosis of the treatment before surgery. Periapical or panoramic radiographs are not very beneficial

to determine bone density because the lateral cortical plates often obscure the trabecular bone density. In addition, classification of bone density on periapical or panoramic radiographs depends on clinician's subjective evaluation. The values of Housefield units are numerically displayed on CBCT, and bone density of the installation site is objectively classified by the numbers. Also, 3-D image of the operation sites allows to view precise vital structure locations and reduce the risk of damage to the structures during surgery. Now, measurements of periotest, insertion torque, or resonance frequency are widely used for the evaluation of implant stability before and after surgery. Many studies evaluated correlations between bone density measured by CBCT and implant stability by periotest, insertion torque, and resonance frequency analysis. It was reported that implant stability measured by RFA is most likely to have a positive relation with bone density measured by CBCT. However, there is no definite correlation between these three methods reported up to now. Along with the advancement of technology, it will be possible in near future to match the data obtained from CBCT to that of periotest, insertion torque, or RFA and predict long-term implant stability by utilizing CBCT.

10. References

- Adell R, Ericksson B, Lekholm U, Branemark PI, Jemt T. A long-term follow-up study of osseointegrated implants in the treatment of totally edentulous jaws. *Int J Oral Maxillofac Implants* 1990;5:347-59.
- Aparicio C. The use of the Periotest value as the initial success criteria of an implant:8-year report. *Int J Periodontics Restorative Dent* 1997;17:150-161.
- Albrektsson T, Hansson T, Lekholm T. Osseointegrated dental implants. *Dent Clin North Am* 1986;30:151-174.
- Albrektsson T, Zarb GA, Worthington P et al: The long-term efficacy of currently used dental implants: a review and proposed criteria of success, *Int J Oral Maxillofac Impl* 1:1-25, 1986.
- Albrektsson T. A multicenter report on osseointegrated oral implants. *J Prosthet Dent* 1988;60:75-84.
- Andersson J-E, Svartz K: CT scanning in the preoperative planning of osseointegrated implants in the maxilla, *Int J Oral Maxillofac Surg* 17:33-35, 1988.
- Aral Y, Tammiäsalö E, Iwai K: Development of a compact computed tomographic apparatus for dental use, *Dentomaxillofac Radiol* 28A:245-248, 1999.
- Arvidson K, Bystedt H, Frykholm A, von Konow L, Lothigius E, A 3-year clinical study of Astra dental implants in the treatment of edentulous mandibles. *Int J Oral Maxillofac Implants* 1992;7:321-9.
- Branemark P-I, Hansson BO, Adell T, et al. Osseointegrated implants in the treatment of the edentulous jaw. Experience from a 10-year period. *Scand J Plast Reconstr Surg* 1977; 11 (Suppl.16): 39-94.
- Branemark P-I, Zarb GA, Albrektsson T. Introduction to Osseointegration. In: Branemark P-I, Zarb GA, Albrektsson T (eds). *Tissue-Integrated Prostheses Osseointegration in Clinical Dentistry*. Chicago: Quintessence, 1985:11-76.
- Brooks RA: comparative evaluation of CT scanner technology. In Fullerton GD, Zagzebski JA, editor: *Medical physics monograph no. 6. Medical physics of CT and*

- ultrasound: tissue imaging and characterization, New York, 1980, American Institute of physics.
- Brunski JB. Biomechanical factors affecting the bone-dental implant interface. *Clin Mater* 1992;10:153-201.
- Buser D, Mericske-Stern R, Bernard JP, et al. Long-term evaluation of non-submerged ITI implants. Part1: 8-year life table analysis of a prospective multi-center study with 2359 implants. *Clin Oral Implants Res* 1997;8:161-172
- Buser D, Nydegger T, Hirt Hp, Cochran DL, Nolte LP. Removal torque values of titanium implants in the maxilla of miniature pigs. *Int J Oral Maxillofac Implants* 1988;13:611-619
- Cann CE: Quantitative CT for for determination of bone mineral density: a review, *Radiology* 141:718-724, 1982.
- Clark DE, Danforth RA, Barnes RW et al: Radiation absorbed from dental implant radiography: a comparison of linear tomography, CT scan, and panoramic and intraoral techniques, *J Oral Implants* 3:156-164, 1990.
- Cochran KL, Schenk RK, Lussi A, Higginbottom FL, Buser D. Bone response to unloaded and loaded titanium implants with a sandblasted and acid-etched surface: A histometric study in the canine mandible. *J Biomed Mater Res* 1998;40:1-11.
- Cranin AN, Silverbrand H, Sher J et al: The requirements and clinical performance of dental implants. In Smith DC, Williams DF, editors: *Biocompatibility of dental materials*, vol4, p198, Boca Raton, Fla, 1982, CRC Press.
- Dae-Hyun Lee, Young Ku, In-Chul Rhyu, Jeong-Ug Hong, Cheol-Woo Lee, Min-Suk Heo, Kyung-Hoe Huh. A clinical study of alveolar bone quality using the fractal dimension and the implant stability quotient. *J Periodontal Implant Sci.* 2010 February; 40(1): 19-24.
- Dental implants: benefit and risk, A National Institutes of Health-Harvard consensus development conference, Publication 81:1531, Washington DC, 1980, U.S. Dept of Health and Human Services.
- Derhami K, Wolfaardt JF, Faulkner G, Grace M. Assessment of the Periotest device in baseline mobility measurements of craniofacial implants. *Int J Oral Maxillofac Implants* 2000;15:221-229.
- Engquist B, Bergendal T, Kallus T, Linden U. A retrospective multicenter evaluation of osseointegrated implants supporting overdentures. *Int J Oral Maxillofac Implants* 1988;3:129-134
- Engstrom H, Svendsen P: Computed tomography of the maxilla in edentulous patients, *Oral Surg Oral Med Oral Pathol* 52:557-560, 1981.
- Fjellstrom C-A, Strom C: CT of the edentulous maxilla intended for osseo-integrated implants, *J Craniomaxillofac Surg* 15:45-46, 1987.
- Friberg B, Jemt T, Lekholm U. Early failures in 4,641 consecutively placed Branemark dental implants: A study from stage 1 surgery to the connection of completed prostheses. *Int J Oral Maxillofac Implants* 1991;6:142-146
- Friberg B, Sennerby L, Grondahl K, Bergstrom C, Back T, Lekholm U. On cutting torque measurements during implant placement: A 3-year clinical prospective study. *Clin Implant Dent Relat Res* 1999;1:75-83


- Friberg B, Sennerby L, Merredith N, Lekholm U. A comparison between cutting torque and resonance frequency measurements of maxillary implants. A 20-month clinical study. *Int J Oral Maxillofac Surg* 1999;28:297-303.
- Friberg B, Sennerby L, Roos J, Johansson P, Strid CG, Lekholm U. Evaluation of bone density using cutting resistance measurements and microradiography: An in vitro study in pig ribs. *Clin Oral Implants Res* 1995;6:164-171.
- Friberg B, Sennerby L, Roos J, Lekholm U. Identification of bone quality in conjunction with insertion of titanium implants. A pilot study in jaw autopsy specimens. *Clin Oral Implants Res* 1995;6:213-219
- Gapski R, Wang HL, Mascarenhas P, Lang NP. Critical review of immediate implant loading. *Clin Oral Implants Res* 2003;14:515-517.
- Genant HK: Quantitative computed tomography: update, *Calcif Tissue Int* 41:179-186,1987.
- Helms C, Morrish R, Kirocos LT: Computed tomography of the TMJ: preliminary considerations, *Radiology* 141:718-724, 1982.
- Hendee WR: the physical principles of computed tomography, Boston, 1983, Little, brown.
- Herrmann I, Lekholm U, Holm S, Kultje C. Evaluation of patient and implant characteristics as potential prognostic factors for oral implant failures. *Int J Oral Maxillofac Implants* 2005;20:220-30.
- Hounsfield GN: Computerized transverse axial scanning (tomography), *Br J Radiol* 46:1016-1022, 1973.
- Ito K, Gomi Y, Sato S, Arai Y, Shinoda K (2001) Clinical application of a new compact CT system to assess 3-D images for the preoperative treatment planning of implants in the posterior mandible. A case report. *Clin Oral Implants Res* 12:539-542
- Ito K, Yoshinuma N, Goke E, Arai Y, Shinoda K. Clinical application of a new compact computed tomography system for evaluating the outcome of regenerative therapy: A case report. *J Periodontol* 2001;72: 696-702.
- Jemt T, Lekholm U, Adell R. Osseointegrated implants in the treatment of partially edentulous patients: A preliminary study on 876 consecutively placed fixtures. *Int J Oral Maxillofac Implants* 1989;4:211-217
- Jensen O, The Carter hypothesis. In: Buser K, Kahlin C, Schenk RK (eds). *Guided Bone Regeneration in Implant Dentistry*. Hong Kong: Quintessence, 1994:238-239.
- Joe Merheb, Nele Van Assche, Wim Coucke, Reinhilde Jacobs, Ignace Naert, Marc Quirynen. Relationship between cortical bone thickness or computerized tomography-derived bone density values and implant stability. *Clinical oral implants research*. 21, 2010;612-617.
- Johansson C, Albrektsson T. Integration of screw implants in the rabbit: A 1-year follow-up of removal torque of titanium implants. *Int J Oral Maxillofac Implants* 1987;2:69-75
- Johansson CB, Albrektsson T. A removal torque and histomorphometric study of commercially pure niobium and titanium implants in rabbit bone. *Clin Oral Implants Res* 1991;2:24-29
- Johansson CB, Sennerby L, Albrektsson T. A removal torque and histomorphometric study of bone tissue reactions to commercially pure titanium and vitallium implants. *Int J Oral Maxillofac Implants* 1991;6:437-441
- Johansson P, Strid K. Assessment of bone quality from cutting resistance during implant surgery. *Int J Oral Maxillofac Implants* 1994;9:279-288

- Jun SH, Chang BM, Weber HP, Kwon JJ. Comparison of initial stability parameters and histomorphometric analysis of implants inserted into extraction sockets: human fresh cadaver study. *Int J Oral Maxillofac Implants*. 2010 Sep-Oct;25(5):985-90.
- Jurzeler MB, Quinones CR, Schupbach P, Vlassis JM, Strub JR, Caffesse RG. Influence of the suprastructure on the perio-implant tissues in eagle dongs. *Clin Oral Implants Res* 1995;6:139-148
- Kim KD, Jeong HG, Choi SH et al: Effect of mandibular positioning on pre-implant site measurement of the mandible in reformatted CT, *Int J Periodont Rest Dent* 23:177-183, 2003.
- Kircos LT: Quantitative implant imaging with a focus on interactive computed tomography: successful implant cases. Are they possible? For how long? Lecture, March 13-14, 1994, Loma Linda University.
- Lekholm U, Zarb Ga, Albrektsson T (eds). *Tissue-integrated Prosthesis: Osseointegration in Clinical Dentistry*. Chicago: Quintessence, 1985;199-209
- Lindh T, Gunne J, Tillberg A, Molin M. A meta-analysis of implants in partial edentulism. *Clin Oral Implants Res* 1998;9:80-90
- Linkow LI, Chercheve R: *Theories and techniques of oral implantology*, vol. I, St Louis, 1970, Mosby.
- MaGivney GP, Haughton V, Strandt IE et al: A comparison of computer-assisted tomography and data-gathering modalities in prosthodontics, *Int J Oral Maxillofac Implants* 1:55-58, 1986.
- McKinney RV, Koth DC, Steflik DE: Clinical standards for dental implants. In Clark JW, editor: *Clinical dentistry*, p198, Harperstown, PA, 1984, Harper & Row.
- Meredith N. Assessment of implant stability as a prognostic determinant. *Int J Prosthodont* 1998;11:491-501
- Meredith N, Shagaldi F, Alleyne D, Sennerby L, Cawley P. The application of resonance frequency measurements to study the stability of titanium implants during healing in the rabbit tibia. *Clin Oral Implants Res* 1997;8:234-243.
- Mihoko Atsumi, Sang-hoon Park, Hom-Lay Wang. Methods used to Assess Implant Stability: Current Status, *Quintessence* 2007 Vol 22, number 5, 743-754
- Misch C, Meffert RM. Implant quality of health scale: A clinical assessment of the health disease continuum In: Misch C(ed). *Dental Implant Prosthetics*. St Louis: Elsevier Mosby, 2005;596-603
- Misch CE: Bone character: second vital implant criterion. *Dent Today* 39-40, June/July 1988.
- Misch CE: Density of bone: Effect on treatment plans, surgical approach, healing, and progressive loading, *Int J Oral Implant* 6:23-31, 1990.
- Morris HE, Ochi S, Crum P, Orenstein I, Plezia R. Bone density: Its influence on implant stability after uncovering. *J Oral Implantol* 2003;29:263-269
- Mozzo P, Procacci C, Tacconi A, Martini PT, Andreis IA (1998) A new volumetric CT machine for dental imaging based on the cone-beam technique: preliminary results. *Eur Radiol* 8:1558-1564
- Mozzo P, Procacci C, Tacconi A: A new volumetric CT machine for dental imaging based on the cone-beam technique, *Eur Radial* 8:1558-1564, 1988.

- Mozzo P, Procacci C, Tacconi A, Martini PT, Andreis IA. A new volumetric CT machine for dental imaging based on the cone-beam technique: Preliminary results. *Eur Radiol* 1998;8: 1558-1564.
- Naert IE, Rosenberg D, van Steenberghe D, Tricio JA, Nys M. The influence of splinting procedures on the periodontal and peri-implant tissue damping characteristics. A longitudinal study with the Periotest device. *J Clin Periodontol* 1995;22:703-708
- Nakagawa Y, Kobayashi K, Mishima, Ishii H, Asada K, Ishibashi K (2002) Preoperative application of limited cone beam computerized tomography as an assessment tool before minor oral surgery. *Int J Oral Maxillofac Surg* 31:322-327
- Norton MR, Gamble C: Bone classification: an objective scale of bone density using the computerized tomography scan, *Clin Oral Implants Res* 12:79-84, 2001.
- O'Sullivan D, Sennerby L, Jagger D, Meredith N. A comparison of two methods of enhancing implant primary stability. *Clin Implant Dent Relat Res* 2004;6:48-57
- Olive J, Aparicio C. Periotest method as a measure of osseointegrated oral implant stability. *Int J Oral Maxillofac Implants* 2000;5:390-400
- Rasmusson L, Meredith N, Kahnberg KE, Sennerby L. Stability assessments and histology of titanium implants placed simultaneously with autogenous onlay bone in the rabbit tibia. *Int J Oral Maxillofac Surg* 1998;27:229-235.
- Roberts WE, Helm FR, Marshall KJ, Gongloff RK, Rigid endosseous implants for orthodontic and orthopedic anchorage. *Angle Ortho* 1989;59:247-256
- Roberts WE, Smith RK, Zilberman Y, Mozsary PG, Smith RS. Osseous adaptation to continuous loading of rigid endosseous implants. *Am J Orthod* 1984;86:95-111
- Romanos GE, Toh CG, Siar CH, Wicht H, Yacoob H, Nentwig GH. Bone-implant interface around titanium implants under different loading conditions: a histomorphometrical analysis in the Macaca fascicularis monkey. *Journal of Periodontology* 2003;74:1483-90.
- Sarment D, Sukovic P, Clinthorne N: Accuracy of implant placement with a stereolithographic surgical guide, *Int J Oral maxillofac Impl* 18:571-577, 2003.
- Schnitman PA, Shulman LB: Recommendations of the consensus development conference on dental implants, *J Am Dent Assoc* 98:373-377, 1979.
- Schulze D, Heiland M, Schmelzle R, Rother UJ (2004) Diagnostic possibilities of cone-beam computed tomography in the facial skeleton. *Int Congr Ser* 1268:1179-1183
- Sennerby L, Roos J. Surgical determinants of clinical success of osseointegrated oral implants: A review of the literature. *Int J Prosthodont* 1998;11:408-420.
- Song YD, Jun SH, Kwon JJ. Correlation between bone quality evaluated by cone-beam computerized tomography and implant primary stability. *Int J Oral Maxillofac Implants*. 2009 Jan-Feb;24(1):59-64.
- Shahlaie M, Gantes B, Schulz E et al: Bone density assessments of dental implant sites: quantitative computed tomography, *Int J Oral Maxillofac Implants* 18:224-231, 2003.
- Sullivan DY, Sherwood RL, Collins TA, Krogh PH. The reverse torque test: A clinical report. *Int J Oral Maxillofac Implants* 1996;11:179-185
- Swartz MS, Rothman SLG, Rhodes ML et al: Computed tomography. 1. Preoperative assessments of the mandible for edentulous implants surgery, *Int J Oral Maxillofac Implants* 2: 137-141, 1987

- Teerlinck J, Quirynen M, Darius P, van Steenberghe D. Periotest: An objective clinical diagnosis of bone apposition toward implants. *Int J Oral Maxillofac Implants* 1991;6:55-61.
- Tjellstrom A, Jacobsson M, Albrektsson T. Removal torque of osseointegrated craniofacial implants: A clinical study. *Int J Oral Maxillofac Implants* 1988;3:287-289
- Van Steenberghe D, Lekholm U, Bolender Ch, et al. The applicability of osseointegrated oral implants in the rehabilitation of partial edentulism: a prospective multicenter study on 558 fixtures. *Int J Oral Maxillofac Implants* 1990;5:275-81.
- Vannier MW: Craniofacial computed tomography scanning: technology, application, and future trends, *Orthod Craniofac Res* 6(suppl 1):23-30, 2003.

IntechOpen



CT Scanning - Techniques and Applications

Edited by Dr. Karupppasamy Subburaj

ISBN 978-953-307-943-1

Hard cover, 348 pages

Publisher InTech

Published online 30, September, 2011

Published in print edition September, 2011

Since its introduction in 1972, X-ray computed tomography (CT) has evolved into an essential diagnostic imaging tool for a continually increasing variety of clinical applications. The goal of this book was not simply to summarize currently available CT imaging techniques but also to provide clinical perspectives, advances in hybrid technologies, new applications other than medicine and an outlook on future developments. Major experts in this growing field contributed to this book, which is geared to radiologists, orthopedic surgeons, engineers, and clinical and basic researchers. We believe that CT scanning is an effective and essential tools in treatment planning, basic understanding of physiology, and and tackling the ever-increasing challenge of diagnosis in our society.

How to reference

In order to correctly reference this scholarly work, feel free to copy and paste the following:

Yeon-Jo Choi, Sang-Ho Jun, Young-Dae Song, Myoung-Woo Chang and Jong-Jin Kwon (2011). CT Scanning and Dental Implant, CT Scanning - Techniques and Applications, Dr. Karupppasamy Subburaj (Ed.), ISBN: 978-953-307-943-1, InTech, Available from: <http://www.intechopen.com/books/ct-scanning-techniques-and-applications/ct-scanning-and-dental-implant>

INTECH
open science | open minds

InTech Europe

University Campus STeP Ri
Slavka Krautzeka 83/A
51000 Rijeka, Croatia
Phone: +385 (51) 770 447
Fax: +385 (51) 686 166
www.intechopen.com

InTech China

Unit 405, Office Block, Hotel Equatorial Shanghai
No.65, Yan An Road (West), Shanghai, 200040, China
中国上海市延安西路65号上海国际贵都大饭店办公楼405单元
Phone: +86-21-62489820
Fax: +86-21-62489821

© 2011 The Author(s). Licensee IntechOpen. This chapter is distributed under the terms of the [Creative Commons Attribution-NonCommercial-ShareAlike-3.0 License](#), which permits use, distribution and reproduction for non-commercial purposes, provided the original is properly cited and derivative works building on this content are distributed under the same license.

IntechOpen

IntechOpen