

We are IntechOpen, the world's leading publisher of Open Access books Built by scientists, for scientists

4,800

Open access books available

122,000

International authors and editors

135M

Downloads

Our authors are among the

154

Countries delivered to

TOP 1%

most cited scientists

12.2%

Contributors from top 500 universities



WEB OF SCIENCE™

Selection of our books indexed in the Book Citation Index
in Web of Science™ Core Collection (BKCI)

Interested in publishing with us?
Contact book.department@intechopen.com

Numbers displayed above are based on latest data collected.
For more information visit www.intechopen.com



Transgastrostomal Observation and Management Using an Ultrathin Endoscope After Percutaneous Endoscopic Gastrostomy

Shinji Nishiwaki¹, Hiroo Hatakeyama¹,
Masahide Iwashita¹ and Hiroshi Araki²

¹*Department of Internal Medicine, Nishimino Kosei Hospital,*

²*Department of Gastroenterology, Graduate School of Medicine, Gifu University,
Japan*

1. Introduction

Recent developments have made ultrathin endoscopes available for routine esophagogastroduodenoscopy and also for unsedated transnasal observation (Shaker, 1994). Transnasal endoscopy is known to be less of a burden for patients (more tolerable) than transoral endoscopy and has benefits including fewer effects on respiratory and cardiovascular status and reduced recovery time after the procedure (Campo et al., 1998; Dumortier et al., 1999; Mori et al., 2008). Transnasal ultrathin endoscopy has also been applied for biliary drainage, insertion of a nasoenteral feeding tube or a long intestinal tube, and percutaneous endoscopic gastrostomy (PEG) (Fang et al., 2005; Itoi et al., 2008; Sato et al., 2008; Vitale et al., 2005). PEG has become the primary access for long term enteral feeding since its introduction in 1980 (Gauderer et al., 1980; Ponsky & Gauderer, 1981), being a very easy and rapid method compared with the previous surgical technique to place a gastrostomy tube.

The endoscopic approach from the gastrocutaneous tract was first described by Chaurasia, et al. for the insertion of a jejunal feeding tube through the PEG (PEG-J) tract (Chaurasia & Chang, 1995). Although they used a pediatric bronchoscope at that time, an ultrathin endoscope later took its place for this purpose (Adler et al., 2002). We have been employing an ultrathin endoscope through the gastrostomy tract for observation, diagnosis, and treatment of various digestive diseases from April 2003. We also investigated the usefulness of such transgastrostomal endoscopy (TGE) for management of patients who had undergone percutaneous endoscopic gastrostomy (PEG).

2. Procedure of transgastrostomal endoscopy (TGE)

Patients with a mature gastrocutaneous tract are candidates for this procedure. Patients before the maturation of the fistula (2 to 4 weeks after the PEG) have higher risk of fistula disruption. If it is necessary to perform TGE in an earlier phase or at the PEG, tight affixation of the stomach to the abdominal wall using a gastropexy device (Rogers, 1989) allows TGE to be performed.

2.1 Equipment

The endoscopes we used were GIF-XP240, GIF-XP260 and GIF-XP260N (Olympus Optical Co., Ltd., Tokyo, Japan) (Fig. 1). The diameters of these endoscopes were 7.7, 6.5, and 5.2 mm, respectively. The diameter of the working channel of these endoscopes was 2.0 mm. GIF-XP240, GIF-XP260, and GIF-XP260N allow insertion through more than 24, 20 and 18 F fistula tracts, respectively.

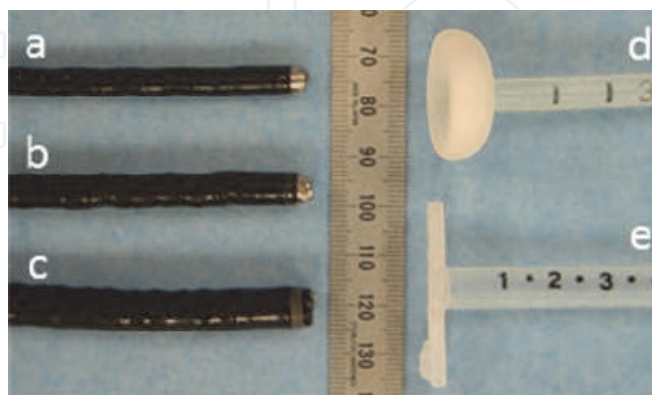

Fig. 1. Photograph of ultrathin endoscopes and gastrostomy tubes. a: GIF-XP260N, b: GIF-XP260, c: GIF-XP240 (Olympus Optical Co., Ltd., Tokyo, Japan), d: Ponsky NBR, 20F (Bard Access Systems, Inc., Salt Lake City, UT, USA), e: Securi-T, 24F (Boston Scientific, Natick, MA, USA)

2.2 Routine observation by TGE

The patient is usually infused with 500 ml of water instead of liquid feeds for several hours before the endoscopic examination to remove the gastric mucus. The patient is laid in the supine position and then the gastrostomy tube is removed. After applying lidocaine jelly around the stoma, an ultrathin endoscope is inserted through the fistular tract and proceeded into the gastric lumen (Fig. 2A). The endoscope is directed to the oral side and advanced to the esophagogastric junction (Fig. 2B). The junction can be observed in detail without disturbance, free from the shade of the endoscope. The endoscope is retrogradely inserted through the esophagus, and we can observe oral cavity as well as pharyngeal cavity if necessary. The endoscope is then withdrawn to the stomach and directed to the anal side. The endoscope is easily inserted up to the upper jejunum from the stoma (Fig. 2C). The endoscope is pulled back to the stomach and turned back to see around the stoma (Fig. 2D).

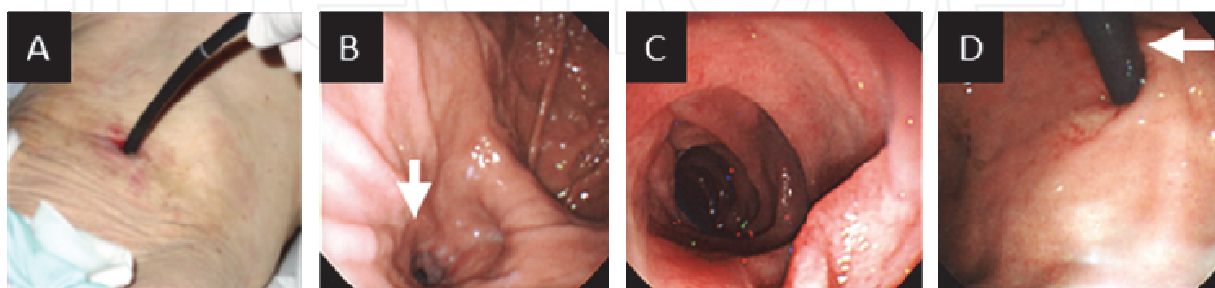


Fig. 2. A: Insertion of an ultrathin endoscope through the gastrostomy tract. B: Endoscopic view of esophagogastric junction (arrow) which is retrogradely observed from the stomach. C: Endoscopic view of upper jejunum. D: Endoscopic view of the stoma from the stomach. Arrow indicates the endoscope inserted through the stoma.

After the observation of the upper gastrointestinal tract, the endoscope is withdrawn from the stoma and a new gastrostomy tube is replaced via the skin incision.

3. Diagnostic application of TGE

Since most of patients who undergo PEG are of advanced age and also have comorbid diseases, they usually do not undergo esophagogastroduodenoscopy after PEG. As TGE is a less invasive procedure to perform even for critically ill patients, we have routinely conducted TGE at the periodical replacement of gastrostomy tubes. We have found variety of newly developed lesions in the upper gastrointestinal tracts and were able to treat them at an early stage without symptoms.

3.1 Cardiopulmonary tolerance during the procedure of TGE

TGE is a less invasive examination compared to transoral and transnasal endoscopy, because TGE does not pass through the pharynx. It requires neither local anesthesia of the pharynx or nasal tract nor conscious sedation before the procedure of TGE. We monitored blood pressure, heart rate, and percutaneous oxygen saturation concentration measurement of the arterial blood (SPO₂) during TGE procedures in 20 consecutive patients. The values were compared to those for patients with the same clinical background during the examination of transoral endoscopy in routine esophagogastroduodenoscopy. Table 1 shows the comparison of cardiopulmonary effects during the procedures of TGE and transoral endoscopy. None of the TGE examinations required sedation, while the transoral examinations required 1 to 4 mg of intravenous administration of midazolam. There were no significant differences in the fluctuation of blood pressure and heart rate between TGE and transoral endoscopy. TGE displayed no effects on SPO₂ during the procedure, while transoral endoscopy caused a decrease of SPO₂ in 46% of the patients.

	Transgastrostomal endoscopy (n=20)	Transoral endoscopy (n=13)	P value
Fluctuation of blood pressure (more than 20%)	5% (1/20)	23% (3/13)	P = 0.157
Fluctuation of heart rate (more than 20%)	15% (3/20)	15% (2/13)	P > 0.5
Decrease of SPO ₂ (more than 3%)	0% (0/20)	46% (6/13)	P < 0.01

Table 1. The effects of TGE and transoral endoscopy on blood pressure, heart rate, and SPO₂.

3.2 Newly developed lesions in upper gastrointestinal tract after PEG

We have been conducting TGE for screening the upper gastrointestinal tract since April 2003. TGE was carried out 805 times in 245 PEG patients (Table 2) during routine replacement of gastrostomy tubes until November 2010. The demographic data are shown in Table 2. The mean age of the subjects was 80.8 years old, and the most frequent underlying disease was cerebrovascular disease. The endoscopic findings of TGE were compared to those at PEG placement. There were a variety of newly developed lesions after PEG.

Age (mean \pm SD)	80.8 \pm 8.9
Gender (male : female)	71 : 174
Underlying disease	
Cerebrovascular disease	143
Dementia	42
Neuromuscular disease	23
Pneumonia	20
Malignant tumor	6
Others	11

Table 2. Demographic data of patients who underwent TGE after PEG.

Reflux esophagitis was found in 35 patients (14.2%), which was the most frequent lesion after PEG. Among the 35 patients, reflux esophagitis was absent at the PEG tube placement in the 30 patients. There were 5 severe cases with symptoms of hematemesis and this had subsequently led to stricture of the lower esophagus in 3 patients (Fig. 3A). Although in these 3 patients, we were unable to insert a transoral endoscope into the stomach, we were able to conduct endoscopic observation of the stomach by TGE (Fig. 3B).

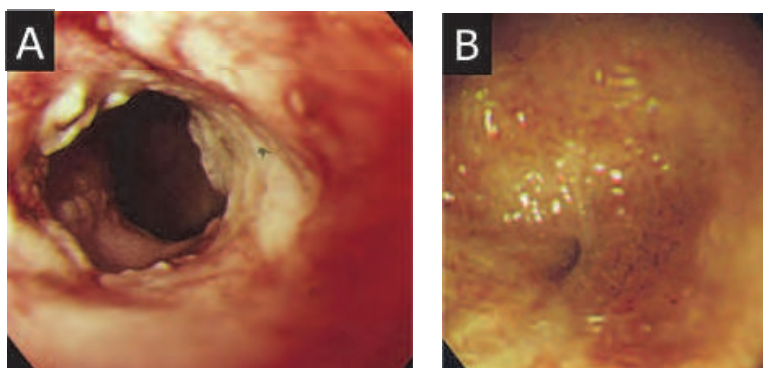


Fig. 3. Endoscopic view of severe reflux esophagitis after PEG. A: Circumferential ulcer was observed by emergency transoral esophagoscopy after the symptom of hematemesis. B: The stricture of the lower esophagus after administration of proton pump inhibitor was observed from the stomach by TGE.

The next most frequent lesion after PEG was polypoid lesion around the stoma. We classified polypoid lesions into 3 types according to their location e.g.; basal bumper type, peri-bumper type and opposite-bumper type. The basal-bumper type polyp was communicated with the fistular tract and the pathology was inflammatory granulation (Fig. 4A). The peri-bumper type polyp was located around the stoma and often observed in cases with decompression by a mushroom type gastrostomy tube (Fig. 4B). Pathological examination revealed hyperplasia of the gastric mucosa. The opposite-bumper type polyp was located on the contra lateral wall of the stoma, probably caused by the contact of the top of the bumper or tube (Fig. 4C). The pathology was hyperplasia. Most of the polypoid lesion was not significantly changed in the subsequent observation by TGE. One case with haemorrhage from the basal-bumper type granuloma was resected by polypectomy using TGE.

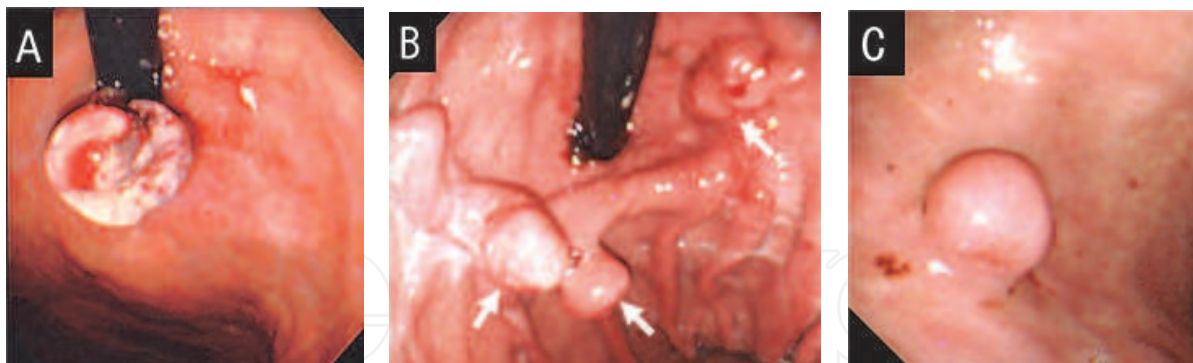

Fig. 4. Endoscopic views of polypoid lesions around the stoma. A: basal-bumper type, B: peri-bumper type, C: opposite-bumper type.

Gastric ulcer was observed in 6 patients. All of their lesions were accidentally found at TGE, because they did not complain of symptoms due to their comorbid diseases. Among the 6 patients, the lesions of 3 patients were supposed to have been caused by direct contact with the bumper. These ulcers were characterized by their location on the contralateral side of the bumper (Fig. 5A). The remaining 3 patients were sporadic cases (Fig. 5B). We have also experienced additional 2 cases of symptomatic gastric ulcer which were detected by transoral endoscopy. For their initial symptoms of hematemesis and tarry stool, emergent esophagogastroduodenoscopy was performed (Nishiwaki et al., 2010b). Hemostasis was obtained by endoscopic hemoclips and coagulation, respectively. TGE was not available for such therapy, because the working channel of the ultrathin endoscope was too narrow to insert the devices to achieve hemostasis.

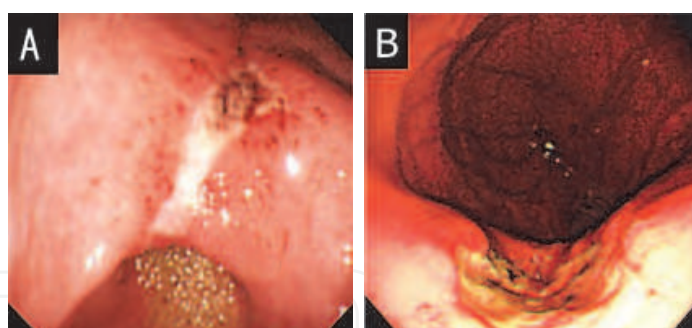


Fig. 5. A: Gastric ulcer was observed on the posterior wall of the lower body of the stomach, contralateral to the stoma. B: Peptic ulcer was observed on the lesser curvature of the upper body in the stomach.

Neoplastic lesions were also detected by TGE. We have experienced 3 cases of early gastric cancer and one case of carcinoid tumor that developed after PEG. One case was recurrence of early gastric cancer after endoscopic mucosal resection before the PEG. One case of early gastric cancer underwent coagulation therapy with argon plasma (Fig. 6A). The remaining two cancer (Fig. 6B) and one carcinoid tumor lesions were resected by endoscopic submucosal dissection assisted by TGE, the technique of which is described in section 4.2.1. The primary duodenal cancer was accidentally found by TGE at the first endoscopic examination 5 years after PEG.

Candida esophagitis was observed in 4 patients. All of the patients were administered proton pump inhibitor, which might have been involved in the development of the esophagitis.

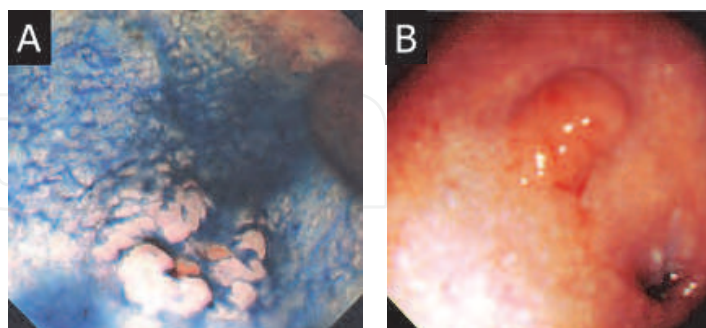


Fig. 6. A: Indigocarmine sprayed endoscopic view of early gastric cancer. Superficial depressed lesion (IIc) was observed on the greater curvature of the antrum. The biopsy specimen of the lesion was well-differentiated tubular adenocarcinoma. B: Superficial elevated lesion (IIa) was observed on the lesser curvature of the upper body of the stomach. Pathological finding of the biopsy specimen was well-differentiated tubular adenocarcinoma.

Table 3 summarizes newly developed lesions after PEG. TGE was useful for the early detection and follow up of these lesions.

Pathological conditions	Number of patients
Reflux esophagitis	30
Polypoid lesion around the stoma	28
Gastric ulcer	6
Neoplastic lesions	
Early gastric cancer	3
Gastric carcinoid tumor	1
Primary duodenal cancer	1
Candida esophagitis	4
Total	73

Table 3. Newly developed upper gastrointestinal lesions which were detected by TGE after PEG.

4. Therapeutic application of TGE

TGE also offers several advantages for endoscopic treatments compared with a transoral endoscope. TGE can easily access up to the upper jejunum with less patient discomfort. TGE covers treatments for lesions from the upper esophagus to upper jejunum. Table 4 shows the list of TGE we have conducted for therapeutic purposes. .

	No. of trial	No. of success
Establishment of direct jejunal feeding access		
Placement of jejunal feeding thorough the PEG (PEG-J)	27	27
Direct percutaneous endoscopic jejunostomy (DPEJ)	36	33
Resection of upper gastrointestinal tumors		
TGE assisted endoscopic submucosal dissection (ESD)	5	5
Endoscopic mucosal resection	1	1
Polypectomy	1	1
Palliative therapy for gastrointestinal obstruction		
Transgastrostomal gastroduodenal stenting	5	4
Placement of long intestinal decompression tube	2	2
Other usage for endoscopic treatments		
Recovery of disrupted gastrocutaneous tract	5	5
Transgastrostomic biliary drainage	1	1

Table 4. Reference chart of TGE for therapeutic purposes and their outcomes.

4.1 Establishment of direct jejunal feeding access

Since the introduction of endoscopic placement of a gastrostomy tube, PEG has been the primary choice for long-term enteral access. However, there are some situations which postpyloric or jejunal feeding is preferable to gastric feeding. The indications for jejunal feeding include a high risk of aspiration, previous gastric resection, gastric pull-up, gastric outlet obstruction, an obstructed or nonfunctioning gastrojejunostomy, and gastric dysmotility (Shike & Latkany, 1998). The access for jejunal feeding was initially established as two methods, i.e.; transnasal insertion of a feeding tube and surgical placement of a jejunostomy tube. Alternative accesses methods for jejunal feeding have been developed; placement of a jejunal feeding tube through the PEG (PEG-J) and direct percutaneous endoscopic jejunostomy (DPEJ). We utilized TGE for the establishment of the two access methods.

4.1.1 Placement of a jejunal feeding tube through the PEG (PEG-J)

PEG-J was first described in 1984 (Ponsky & Aszodi, 1984). This technique was usually conducted for patients with high risk of aspiration due to gastroesophageal reflux of food after PEG (Nishiwaki et al., 2006). The tube is usually placed under fluoroscopic guidance. However, it is sometimes difficult to pass the feeding tube through the pyloric ring and duodenum using only fluoroscopy. A technique to assist the tube passage into the duodenum by transoral endoscopy has been reported (Duckworth et al., 1994; Leichus L et al., 1997). A transgastric technique using a pediatric bronchoscope or an ultrathin endoscope was described first in 1995 (Adler et al., 2002; Chaurasia & Chang, 1995).

We treated 27 patients using this technique with the following procedures: 1. Remove the gastrostomy tube. 2. Insert an endoscope through the gastrostomy and proceed up to the jejunum (Fig. 7A). 3. Insert a guidewire through the working channel of the endoscope. 4. Remove the endoscope retaining the guidewire (Fig. 7B). 5. Place a jejunal feeding tube over the guidewire through the PEG under fluoroscopic guidance (Figs. 7 C & D).

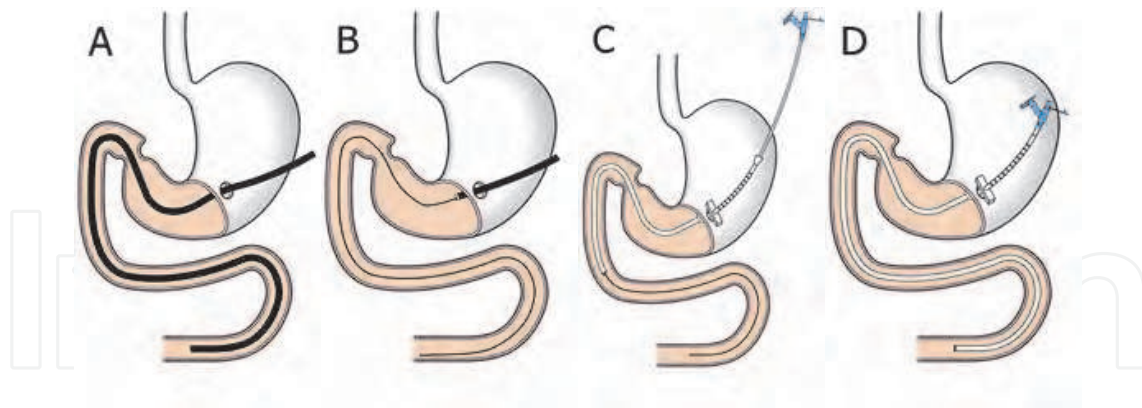


Fig. 7. Schematic procedure of PEG-J using TGE.

The jejunal feeding tubes (J-tube, Boston Scientific, Natick, MA, USA, or Jejunal Feeding Tube, Bard Access Systems, Inc., Salt Lake City, UT, USA) were successfully placed in all 27 patients. The duration of the procedure ranged from 4 to 20 minutes, which was remarkably quick compared with the procedure using only fluoroscopic guidance.

4.1.2 Direct percutaneous endoscopic jejunostomy (DPEJ)

Direct percutaneous placement of the jejunostomy tube was first described in 1987 (Shike et al., 1987). The first case series were for patients with previous gastric resection, and the technique was subsequently applied for patients with intact stomach. Because the length of the endoscope for the performance of DPEJ in the transoral route is 160 cm or longer, it requires the use of a long colonoscope or a small intestinal scope (Shike et al., 1991). However, the transgastrostomal approach facilitates access to the upper jejunum without difficulty. DPEJ using TGE was first described in 2002 (Baron, 2002). Although they successfully placed a jejunostomy tube through the mature gastrostomy tract, the gastrocutaneous tract was disrupted by passing through the bumper of the jejunostomy tube. We modified the procedure (Fig. 8) so that the jejunostomy tube does not pass the gastrostomy tract (Nishiwaki et al., 2009b).

After conscious sedation with intravenous administration of midazolam (1 to 2 mg) in most patients, an ultrathin endoscope was inserted through the gastrocutaneous tract immediately after the removal of the gastrostomy tube. The endoscope was inserted up to the jejunum and the site for placement was determined by transillumination to the abdominal wall and finger pressure against the jejunum (Fig. 8A). The abdominal skin surface of the placement area was cleansed with povidone-iodine, and local anesthesia was done administering 1% lidocaine. After test-puncturing with a 21-gauge needle, one or two point sutures were made using gastropexy devices (Create Medic Co., Ltd., Yokohama, Japan, or Easy Tie, Boston Scientific Japan K.K., Tokyo, Japan) to fix the jejunum against the abdominal wall. A 16- or 18-gauge Seldinger needle was inserted through the abdomen toward an open snare inserted through the TGE and a loop wire was passed through the outer sheath of the needle. The loop wire was grasped by the snare and pulled out through the gastrocutaneous tract with the endoscope (Fig. 8B). In most cases, the loop wire was then grasped in the stomach by biopsy forceps of an orally inserted endoscope (Fig. 8C) and pulled out via the mouth (Fig. 8D). In a few cases, the loop wire was directly brought out from the mouth by transgastrostomic endoscopy. Next, an jejunostomy tube was connected

to the loop wire and the tube was placed in the jejunum by the pull-through technique (Fig. 8E). The systems to place the jejunostomy tube were One Step Button (Boston Scientific Co., Natick, MA, USA) or Bard Ponsky Pull PEG (Bard Access Systems, Inc., Salt Lake City, UT, USA)

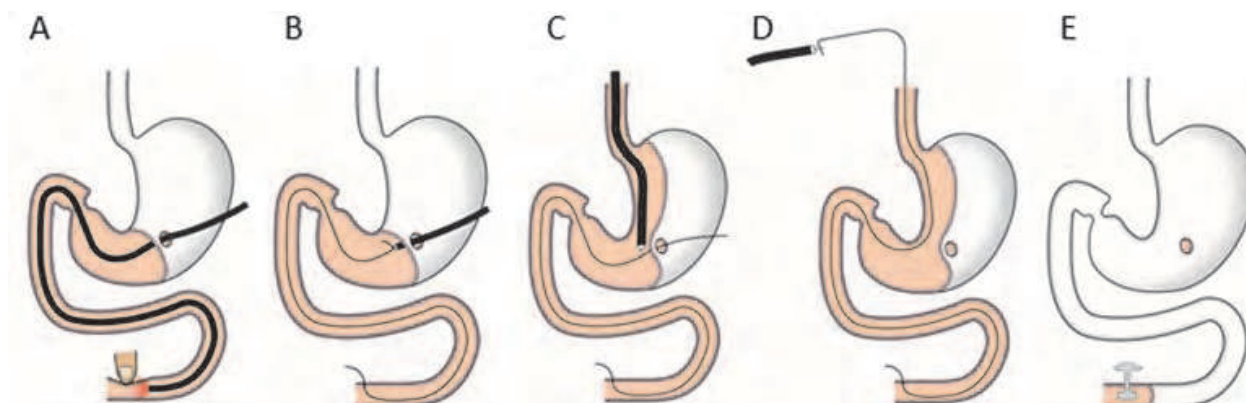


Fig. 8. Schematic procedure of DPEJ using TGE.

Thirty six DPEJ procedures were attempted in 35 patients, with 33 (92%) successful placements. One unsuccessful placement was due to jejunum migration away from the abdominal wall during the puncture; this patient was maintained by feeding via the PEG-J. The other two failures were due to the lack of transillumination. The average \pm SD of duration of procedure, from insertion of the endoscope to the placement of the jejunostomy tube, was 29.6 ± 13.1 (15 to 70) min.

Procedure-related complications consisted of 1 case each of pneumonia, colocutaneous fistula, and pneumoperitoneum. Of these, pneumonia and colocutaneous fistula were considered major complications. In the former case, placement of the jejunostomy tube took 50 min, and pneumonia occurred before administration of nutrients. The patient died 4 days after DPEJ due to respiratory failure. In the latter case, the fact that the jejunostomy tube had been placed penetrating through the colon was revealed at the second replacement of the jejunostomy tube. The colocutaneous fistula was naturally closed after removal of the replaced tube and DPEJ was successfully completed 28 days after the removal. Pneumoperitoneum, a minor complication, was observed in a severely obese patient.

4.2 Resection of upper gastrointestinal tumors

Endoscopic techniques to remove gastrointestinal tumors have been established as snare polypectomy and endoscopic mucosal resection (EMR). EMR allows the removal of flat lesions by injection with saline into the submucosal layer, but it is difficult to remove larger tumors. Recent development of the technique of endoscopic submucosal dissection (ESD) facilitates the removal of widely-spread neoplastic lesions compared to the EMR. We utilized TGE for these resection techniques of the upper gastrointestinal tumors.

4.2.1 TGE assisted endoscopic submucosal dissection (ESD)

ESD is a new technique for the resection of early gastric cancer (Ono et al., 2001). This technique allows en bloc resection even for larger lesions and allows for precise histological analyses. However, this method has a high incidence of complications such as bleeding and perforation, and the technique requires skill and a longer time for resection compared to

conventional EMR (Gotoda 2006). One of the technical problems of ESD is the difficulty of maintaining a clear view of the submucosal layer of the gastric wall during submucosal dissection. We developed the technique of ESD assisted by TGE to dissolve the problem (Nishiwaki et al., 2009a).

Five patients previously established with PEG underwent TGE-assisted ESD (Table 5). ESD was carried out by a single-channel videoendoscope, GIF H260 (Olympus Optical Co., Ltd, Tokyo), attached with a short hood. The high-frequency electrosurgical unit was the Erbotom ICC 200 in Cases 1-3, and the VIO 300D in Cases 4 and 5 (ERBE Elektromedizin GmbH, Tübingen, Germany). After circumferential markings around the lesion, submucosal injection was carried out using a mixture of hyaluronic acid and glycerol containing indigocarmine, according to the method described by Fujishiro, et al (Fujishiro et al., 2006). Circumferential mucosal cutting and submucosal dissection were carried out using a needle knife, a Flex knife, an insulation-tipped (IT) knife, or a combination of the three. TGE was inserted through the mature gastrotomous tract and grasped the edge of the resecting specimen to achieve appropriate counter-traction during submucosal dissection (Figs. 9A-C). Hemostatic forceps were used when active bleeding took place during the procedure or to prevent bleeding from large vessels before cutting in soft coagulation mode. TGE also worked for additional submucosal injection, washing with water, aspiration of gastric fluid.

Case I.D.	1	2	3	4	5
Age/Gender	83/M	82/F	72/M	79/F	82/F
Pathology	tub 1	tub 1	adenoma	tub 1	carcinoid tumor
Location	a.w. antrum	l.c. body	p.w. antrum	g.c. body	a.w. body
Dissection size (mm)	24 X 22	20 X 20	60 X 30	30 X 22	15 X 10
Operative duration (min)	21	18	105	55	80

tub 1: well differentiated tubular adenocarcinoma, a.w.: anterior wall, l.c.: lesser curvature, p.w.: posterior wall, g.c.: greater curvature

Table 5. Summary of the patients who underwent TGE-assisted ESD.

A laparoscopic port with a trocar is inserted into the gastric lumen percutaneously and assists in the ESD using an IT knife (Kondo et al., 2004). However these methods are thought to be limited for some tumor locations, as the assisting devices are not flexible. EMR assisted by a magnetic anchor has also been reported to create strong counter traction (Kobayashi et al., 2004). In our methods, an ultrathin endoscope is inserted through the gastrotomous tract after PEG, and assisted ESD is performed with an orally inserted videoendoscope. TGE can cover the whole stomach and esophagus and create appropriate counter traction for dissection of the lesion. Furthermore, TGE not only can provide traction control but can also support diverse procedures of ESD, such as marking, submucosal injection, washing out or aspiration of the intragastric contents. TGE facilitates ESD by this type of assistance, and the operation duration of TGE-assisted ESD has been found to be relatively short compared to the single-scope ESD in our hospital.

One of the problems of this method is light interference between the two endoscopes (Fig. 9D). When the two endoscopes faced each other, the position of the TGE had to be changed to eliminate the light interference. The other problem of this method is that it might be

difficult to perform TGE before maturation of the gastrocutaneous tract. In the present case series, gastric tumors were found after PEG in three cases, but two tumors were found at the placement of PEG catheter. In general, it takes 3-4 weeks to complete the stoma. ESD was conducted in the two cases 3-4 weeks after PEG, after waiting for maturation of the gastrocutaneous tract. Pneumoperitoneum occurred after ESD in Case 3, although it recovered spontaneously. The use of gastropexy devices enabled us to fix the abdominal and gastric walls more tightly, such that pneumoperitoneum might be prevented even with prolonged endoscopic treatment. Narrowing of the ultrathin endoscope would be helpful for this method. Therefore, simultaneous PEG and TGE-assisted ESD using a gastropexy device and an ultrathin endoscope might be possible for large, difficult lesions.

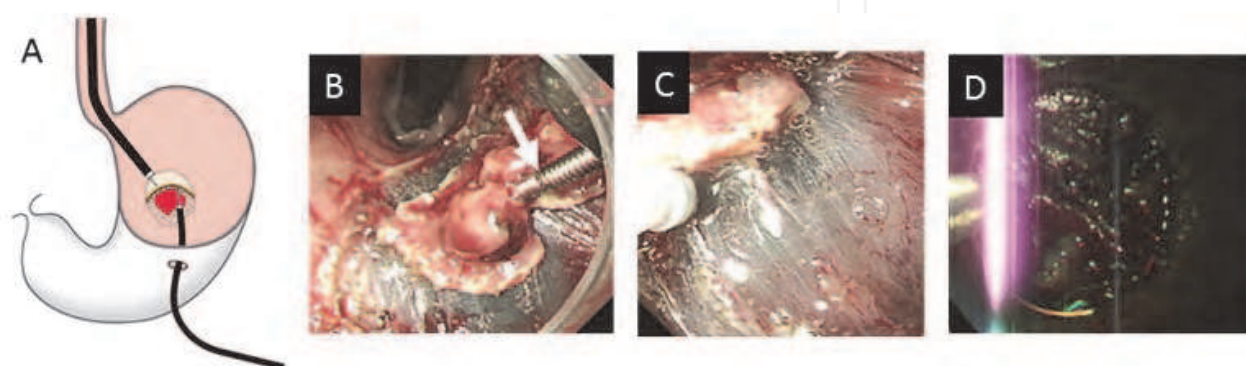


Fig. 9. TGE-assisted ESD. A. Schematic illustration of ESD assisted by TGE. B. Endoscopic view from transoral endoscope in Case 4. A grasping forceps was inserted through the TGE and grasped the edge of the gastric tumor (arrow). C. Endoscopic view from transoral endoscope in Case 4. Counter traction of the exfoliating lesion by TGE facilitated the submucosal dissection by a Flex knife. D. Endoscopic view from transoral endoscope in Case 1. Light from the TGE impeded the procedure of ESD when the endoscope faces each other. The position of TGE should be changed so as not to disturb the procedure.

4.2.2 Endoscopic mucosal resection (EMR) and polypectomy

The performance of ESD by TGE alone is quite difficult because the working channel of the ultrathin endoscope is too narrow to insert the devices for ESD. However, TGE itself can be used for polypectomy and EMR by using an appropriate injection needle and snare for the ultrathin endoscope. We carried out resection of two benign polyps by TGE. One case was a hyperplastic polyp on the prepylorus, and the other was inflammatory granuloma on the gastric stoma (Fig. 4A). Both polyps showed a tendency to develop during the periodical observation by TGE. Transgastric resections were successfully conducted without conscious sedation.

4.3 Palliative therapy for gastrointestinal obstruction using TGE

One of the indications of PEG is decompression of gastrointestinal content in cases of obstruction of gastrointestinal tract. On the other hand, some cases develop gastrointestinal obstruction after PEG. TGE also facilitates the palliative therapy in such cases.

4.3.1 Transgastrostomal stenting on gastroduodenal outlet obstruction

Endoscopic deployment of stents for malignant gastroduodenal outlet obstruction has been reported as a less invasive palliative therapy compared to a surgical bypass operation (Yim

et al., 2001). It is more difficult to place the stent across the postpyloric lesion compared to the esophagus, because the delivery system often forms a loop in the stomach before passing through the obstruction. When the gastrostomy site is adjacent to the obstructed lesion, a transgastric approach for stenting is easier than a transoral approach. Transgastrostomic stenting for malignant duodenal obstruction was first described in 1993 (Keymling et al., 1993).

The schematic procedure of transgastrostomal stenting is shown in Fig. 10. An ultrathin endoscope is inserted through the mature gastrocutaneous tract followed by removal of the gastrostomy tube. A guidewire is advanced through the stenosis (Fig. 10A). The endoscope is once removed from the gastrostomy keeping the position of the guidewire. A balloon catheter is inserted over the guidewire and the stenosis is dilated with the balloon catheter (Fig. 10B). The ultrathin endoscope is inserted after the removal of the balloon catheter and advanced to the upper jejunum (Fig. 10C). A guidewire is inserted deeply in the jejunum through the endoscope and the endoscope is removed again, retaining the guidewire. A stent is finally deployed over the guidewire across the obstructed lesion using a delivery device (Figs. 10D & E).

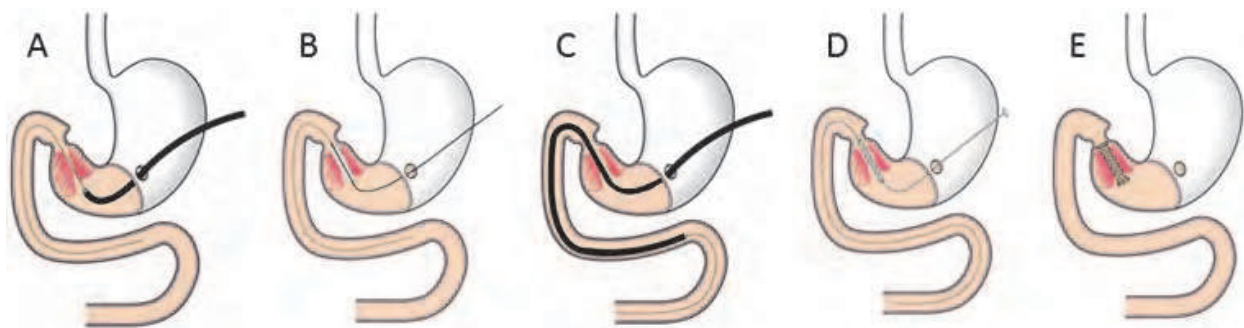


Fig. 10. Schematic procedure of the placement of an expandable metallic stent on the pyloric stenosis.

We tried this procedure for 5 patients in whom we had failed to place a stent by the transoral approach (Table 6). In 4 out of 5 patients, a non-covered expandable metallic stent was successfully deployed (Ultraflex, Boston Scientific Co., Natick, MA, USA). The one case (#5) of failure was changed to the placement of a jejunal feeding tube through the obstruction. The duodenal obstruction of this case was too severe to pass the delivery device but a 12F jejunal feeding tube was successfully inserted through the obstruction. All of the patients could successfully feed again after the procedure.

Case I.D.	1	2	3	4	5
Age/Gender	88/F	82/F	84/M	75/M	72/F
Tumors	Stomach	CBD	Stomach	CBD	Gall bladder
Obstruction	Pylorus	Duodenum	Pylorus	Duodenum	Duodenum
Operative duration (min)	20	27	15	45	
Outcome	Success	Success	Success	Success	Failure

CBD: common bile duct

Table 6. Summary of the cases with transgastrostomal stenting.

4.3.2 Placement of long intestinal decompression tube

Placement of a long intestinal decompression tube was carried out for malignant lower intestinal obstructions. A series of radiographs of the procedure in the case with ascending colon cancer is shown in Fig. 11. The procedure was the same as for the placement of a PEG-J tube as described in 4.1.1. The benefit of this procedure is that it is more comfortable for the patient, especially in the prolonged period of decompression, compared to transnasal placement.

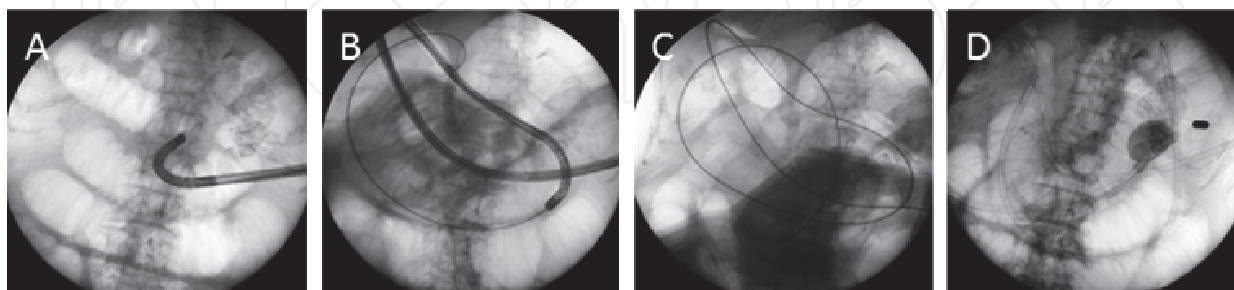


Fig. 11. Radiographs of the placement of a long intestinal decompression tube. A. An ultrathin endoscope was inserted into the stomach after removal of the gastrostomy tube. B. The endoscope was advanced to the upper jejunum. C. A guidewire was passed through the endoscope. D. A long intestinal decompression tube (CLINY Ileus Tube, Create Medic Co. Ltd., Yokohama, Japan) was placed over the guidewire.

4.4 Other usage for endoscopic treatments

We utilized TGE to treat other pathological conditions. The applications for pancreaticobiliary and esophageal diseases have been reported. Alternative possibilities for the usage of TGE are discussed in this section.

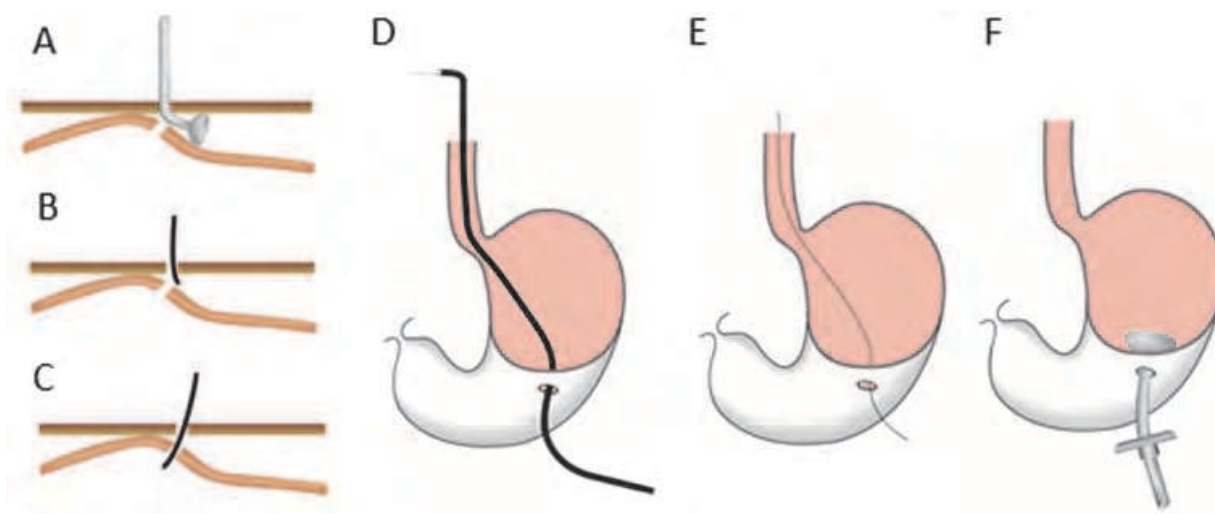


Fig. 12. Schematic illustrations of the recanalization of a disrupted fistula using TGE. A. Misplacement of a gastrostomy tube into the peritoneal cavity. B. Insertion of ultrathin endoscopy from the skin incision and looking for the gastric lumen. C. Successful insertion into the stomach. D. Passing the endoscope through the esophagus to the oral cavity. E. Insertion of a loop wire from the stoma out of mouth. F. A new gastrostomy tube is replaced by the pull-through technique.

4.4.1 Recovery of disrupted gastrocutaneous tract

Fistula disruption usually occurs upon early dislodgement of the gastrostomy tube or upon replacement of the tube. It might cause the serious complication of peritonitis due to leaking of gastric contents or feeding materials into the peritoneal cavity (Fang, 2007; McQuaid & Little, 1992; Romero et al., 1996). In order to place a new gastrostomy tube, a PEG procedure is often performed adjacent to the disrupted fistula (Galat et al., 1990). We employed TGE for recanalization of the disrupted fistula at the tube replacement (Nishiwaki et al., 2009 c). Schematic illustrations of the procedure are shown in Fig. 12.

We tried this technique for 5 patients with fistula disruption and in all of the patients, the disrupted fistula tract was successfully recovered. Before the introduction of this procedure, we inserted a guidewire to search for the gastric lumen from the skin incision under fluoroscopic guidance. However, in 2 out of 5 trials, we failed to reestablish a gastrocutaneous tract. The endoscopic view of TGE is helpful to locate the intragastric route from the skin incision.

4.4.2 Transgastrostomic biliary drainage

Endoscopic retrograde cholangiopancreatography from the gastrostomy have been reported (Baron & Vickers, 1998; Mori et al., 2007). Since all ultrathin endoscopes are forward-viewing, it is more difficult to insert a canula into a pancreatic or bile duct. Moreover, endoscopic treatment has limitations because of the limited availability of therapeutic devices. However, there is a benefit of direct access into the bile duct after sphincterotomy and the ability to conduct direct endoscopic observation of the bile tract (Larghi & Waxman, 2006).

We only experienced one case with transgastrostomal biliary drainage for obstructive jaundice in a patient with primary sclerosing cholangitis (Fig. 13). Placement of a transgastrostomal drain tube is more comfortable than that of a transnasal drain tube.




Fig. 13. Establishment of transgastrostomal biliary drainage. A. Endoscopically placed retrograde biliary drainage tube (FLEXIMA Single-Use Biliary Stent System, 6F, Boston Scientific, Maple Grove, MN, USA) was retrieved from the gastric stoma by TGE. B. The tube was passed through a 12F Jejunal Feeding Tube (Bard Access Systems, Inc., Salt Lake City, UT, USA). This procedure allowed the patient to continue to feed through the gastric decompression port of the tube.

4.4.3 Transstomal endoscopy other than gastrostomy

Transstomal endoscopy is also available via other routes than the gastrostomy tract. We experienced two cases of endoscopic placement of a jejunal extension tube through direct endoscopic jejunostomy. The first case had undergone DPEJ and showed repeated aspiration due to jejunoesophageal reflux of the feeding materials. We inserted the top of a feeding tube to 40 cm anal direction from the jejunostomy site using a transjejunostomal endoscope (Fig. 14). Another case was jejunal obstruction caused by inflammatory granuloma of the jejunostomy site (Nishiwaki et al., 2007). We could successfully place a feeding tube on the anal side of the obstruction by transjejunostomal endoscope. Although a similar procedure has previously reported under fluoroscopic guidance (Luttman et al., 2005), it might be easier to place a feeding tube using the transjejunostomal endoscope.

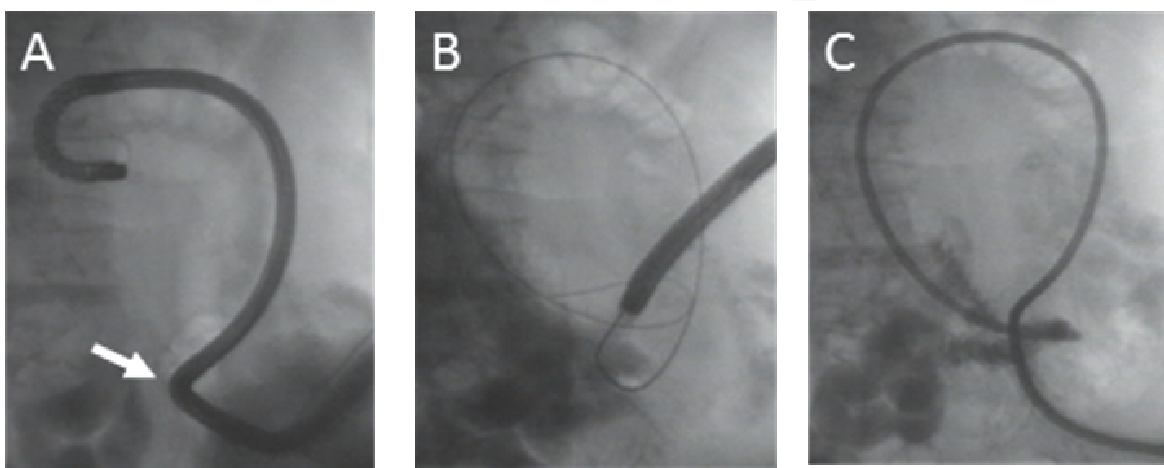


Fig. 14. Placement of an extension feeding tube through the DPEJ. A. An ultrathin endoscope was inserted through the jejunostomy site (arrow) and advanced to the anal side. B. A guidewire was placed through the endoscope. C. J-tube (Boston Scientific, Natick, MA, USA) was placed over the guidewire.

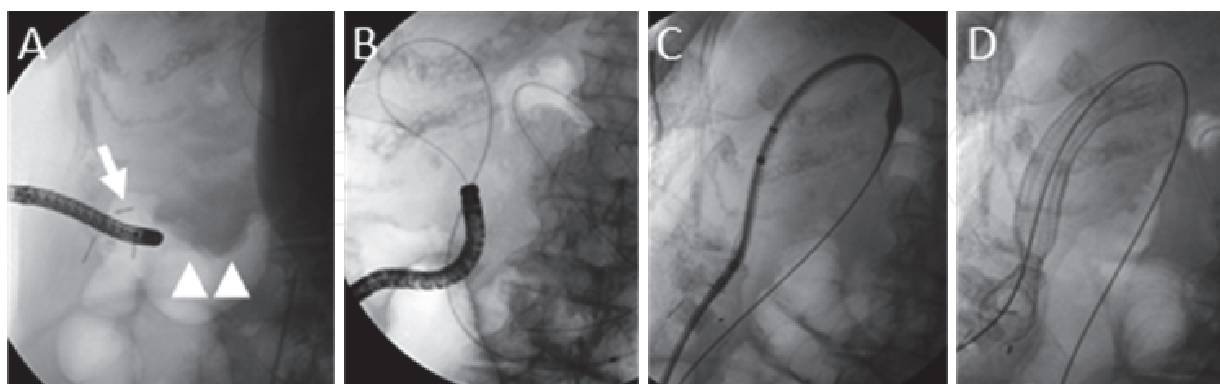


Fig. 15. Placement of an expandable metallic stent (Ultraflex, Boston Scientific, Natick MA, USA) across the obstructed ascending cancer. A. Insertion of an ultrathin endoscope through the cecostomy (arrow). Arrow heads indicate the location of the tumor. B. A guidewire was passed through the obstruction and inserted deeply along the anal side of the bowel under the guidance of fluoroscopy. C. Delivery system of the Ultraflex was

inserted through the obstruction over the guidewire. D. Ultraflex was deployed across the tumor.

We additionally experienced one case of transcecostomal endoscopy for stent placement across the ascending colon cancer (Nishiwaki et al., 2010b). The patient was too critically ill to undergo surgical treatment, and we were also unable to place a colonic stent by colonoscopy. After establishment of ultrasonography-guided percutaneous cecostomy, transcecostomal endoscopy facilitated the passing of a guidewire through the obstruction. The procedure of the stent deployment is shown in Fig. 15.

4.4.4 Other applications

TGE was reported to be useful for the dilatation of radiation-induced complete esophageal obstruction (Maple et al., 2006). The rendezvous technique for the dilatation of esophageal stricture was conducted by cooperative use of transoral endoscope and TGE. The use of TGE made the procedure more safe and effective.

Recent developments in super ultrathin endoscopes allow for insertion through the gastrostomy tube. The endoscope is then utilized for verification of a replaced gastrostomy tube into the stomach.

5. Conclusions

TGE offers a less invasive way to observe the upper gastrointestinal tract and allows for the detection of early stage gastrointestinal lesions. TGE also facilitates endoscopic treatments which might be more difficult by transoral endoscope. However, the narrow working channel of the ultrathin endoscope is a limitation of therapeutic TGE. Further improvements to the endoscope and applicable devices will be expected in the future.

6. Acknowledgements

We express our appreciation to Dr. Saito, Nishimino Kosei Hospital, for generous advice on these procedures. We also appreciate the members of the endoscopy unit of Nishimino Kosei Hospital (Dr. Maeda, Dr. Hayashi, Dr. Tagami, and Dr. Takada) for their assistance with the endoscopic procedures.

7. References

- Adler D. G.; Gostout C. J. & Baron T. H. (2002) Percutaneous transgastric placement of jejunal feeding tubes with an ultrathin endoscope. *Gastrointest. Endosc.*, Vol.55, No.1, (Jan 2002), pp. 106-110, ISSN 0016-5107
- Baron T. H. & Vickers S. M. (1998) Surgical gastrostomy placement as access for diagnostic and therapeutic ERCP. *Gastrointest. Endosc.*, Vol.48, No.6, (Dec 1998), pp. 640-641, ISSN 0016-5107
- Baron T. H. (2002) Direct percutaneous endoscopic jejunostomy through a mature gastrostomy tract. *Gastrointest. Endosc.*, Vol.56, No.6, (Dec 2002), pp. 946-947, ISSN 0016-5107

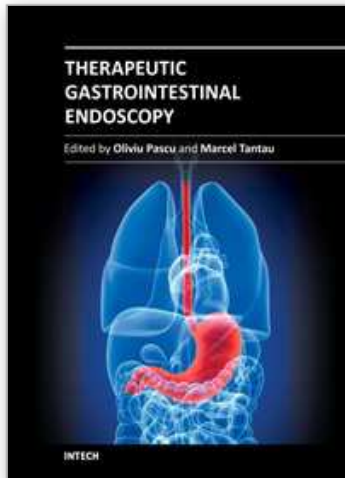
- Campo R.; Montserrat A. & Brullet E. (1998). Transnasal gastroscopy compared to conventional gastroscopy: a randomized study of feasibility, safety, and tolerance. *Endoscopy*. Vol.30, No.5, (Jun 1998), pp. 448-452, ISSN 0013-726X
- Chaurasia O. P. & Chang K. J. (1995) A novel technique for percutaneous endoscopic gastrojejunostomy tube placement. *Gastrointest. Endosc.*, Vol.42, No.2, (Aug 1995), pp. 165-168, ISSN 0016-5107
- Duckworth P. F. Jr.; Kirby D. F.; McHenry L.; DeLegge M. H. & Foxx-Orenstein A. (1994) Percutaneous endoscopic gastrojejunostomy made easy: a new over-the-wire technique. *Gastrointest. Endosc.*, Vol.40, No.3, (May-Jun 1994), pp. 350-353, ISSN 0016-5107
- Dumortier J.; Ponchon T.; Scoazec J. Y.; Moulinier B.; Zarka F.; Paliard P. & Lambert R. (1999) Prospective evaluation of transnasal esophagogastroduodenoscopy: feasibility and study on performance and tolerance. *Gastrointest. Endosc.*, Vol.49, No.3, (Mar 1999), pp. 285-291, ISSN 0016-5107
- Fang J. C.; Hilden K.; Holubkov R. & DiSario J. A. (2005) Transnasal endoscopy vs. fluoroscopy for the placement of nasoenteric feeding tubes in critically ill patients. *Gastrointest. Endosc.*, Vol.62, No.5, (Nov 2005), pp. 661-666, ISSN 0016-5107
- Fang J. C. (2007) Minimizing endoscopic complications in enteral access. *Gastrointest. Endosc. Clin. N. Am.*, Vol.17, No.1, (Jan 2007), pp. 179-196, ISSN 1052-5157
- Fujishiro M.; Yahagi N.; Nakamura M.; Kakushima N.; Kodashima S.; Ono S.; Kobayashi K.; Hashimoto T.; Yamamichi N.; Tateishi A.; Shimizu Y.; Oka M.; Ogura K.; Kawabe T.; Ichinose M. & Omata M. (2006) Successful outcomes of a novel endoscopic treatment for GI tumors: endoscopic submucosal dissection with a mixture of high-molecular-weight hyaluronic acid, glycerin, and sugar. *Gastrointest. Endosc.*, Vol.63, No.2, (Feb 2006), pp. 243-249, ISSN 0016-5107
- Galat S. A.; Gerig K. D.; Porter J. A. & Slezak F. A. (1990) Management of premature removal of the percutaneous gastrostomy. *Am Surg.*, Vo.56, No.11 (Nov 1990) pp. 733-736, ISSN 0003-1348
- Gauderer M. W.; Ponsky J. L. & Izant R.J. Jr. (1980) Gastrostomy without laparotomy: a percutaneous endoscopic technique. *J Pediatr Surg.*, Vol.15, No.6, (Dec 1980) pp. 872-875, ISSN 0022-3468
- Gotoda T. (2006) Endoscopic resection of early gastric cancer: the Japanese perspective. *Curr Opin Gastroenterol.*, Vol.22, No.5, (Sep 2006) pp. 561-569, ISSN 0267-1379.
- Itoi T.; Kawai T.; Itokawa F.; Sofuni A.; Kurihara T.; Tsuchiya T.; Ishii K.; Tsuji S.; Ikeuchi N.; Takeuchi M.; Sakai Y. & Moriyasu F. (2008) Initial experience of transnasal endoscopic biliary drainage without conscious sedation for the treatment of acute cholangitis (with video). *Gastrointest. Endosc.*, Vol.67, No.2, (Feb 2008), pp. 328-332, ISSN 0016-5107
- Keymling M.; Wagner H. J.; Vakil N. & Knyrim K. (1993) Relief of malignant duodenal obstruction by percutaneous insertion of a metal stent. *Gastrointest. Endosc.*, Vol.39, No.3, (May-Jun 1993), pp. 439-441, ISSN 0016-5107
- Kobayashi T.; Gotohda T.; Tamakawa K.; Ueda H. & Kakizoe T. (2004) Magnetic anchor for more effective endoscopic mucosal resection. *Jpn J Clin Oncol.*, Vol.34, No.3, (Mar 2004) pp. 118-123, ISSN 0368-2811

- Kondo H.; Gotoda T.; Ono H.; Oda I.; Kozu T.; Fujishiro M.; Saito D. & Yoshida S. (2004) Percutaneous traction-assisted EMR by using an insulation-tipped electrosurgical knife for early stage gastric cancer. *Gastrointest. Endosc.*, Vol.59, No.2, (Feb 2004), pp. 284-288, ISSN 0016-5107
- Larghi A. & Waxman I. (2006) Endoscopic direct cholangioscopy by using an ultra-slim upper endoscope: a feasibility study. *Gastrointest. Endosc.*, Vol.63, No.6, (May 2006), pp. 853-857, ISSN 0016-5107
- Leichus L.; Patel R. & Johlin F. (1997) Percutaneous endoscopic gastrostomy/jejunostomy (PEG/PEJ) tube placement: a novel approach. *Gastrointest. Endosc.*, Vol.45, No.1, (Jan 1997), pp. 79-81, ISSN 0016-5107
- Luttmann A.; Deppe H.; Wejda B. U.; Huchzermeyer H. & Dormann A. J. (2005) Placement of a jejunal enteral tube through a percutaneous endoscopic jejunostomy to prevent recurrent aspiration during intestinal feeding. *Gastrointest. Endosc.*, Vol.61, No.3, (Mar 2005), pp. 492-493, ISSN 0016-5107
- Maple J. T.; Petersen B. T.; Baron T. H.; Kasperbauer J. L.; Wong Kee Song L. M. & Larson M. V. (2006) Endoscopic management of radiation-induced complete upper esophageal obstruction with an antegrade-retrograde rendezvous technique. *Gastrointest. Endosc.*, Vol.64, No5, (Nov 2006), pp. 822-828, ISSN 0016-5107
- McQuaid K. R. & Little T. E. (1992) Two fatal complications related to gastrostomy "button" placement. *Gastrointest. Endosc.*, Vol.38, No.5, (Sep-Oct 1992), pp. 601-603, ISSN 0016-5107
- Mori A.; Ohashi N.; Maruyama T.; Tatebe H.; Sakai K.; Inoue H.; Takegoshi S. & Okuno M. (2007) Endoscopic retrograde cholangiopancreatography through a gastric stoma using an ultrathin endoscope: a novel approach. *Endoscopy* Vol.39, Suppl.1, (Feb 2007), E. 323, ISSN 0013-726X
- Mori A.; Ohashi N.; Maruyama T.; Tatebe H.; Sakai K.; Shibuya T.; Inoue H.; Takegoshi S. & Okuno M. (2008) Transnasal endoscopic retrograde cholangiopancreatography using an ultrathin endoscope: a prospective comparison with a routine oral procedure. *World J Gastroenterol.*, Vol.14, No.10, (Mar 2008), pp. 1514-1520, ISSN 1007-9327
- Nishiwaki S.; Araki H.; Goto N.; Niwa Y.; Kubota M.; Iwashita M.; Onogi N.; Hatakeyama H.; Hayashi T.; Maeda T. & Saitoh K. (2006) Clinical analysis of gastroesophageal reflux after PEG. *Gastrointest. Endosc.*, Vol.64, No.6, (Dec 2006), pp. 890-896, ISSN 0016-5107
- Nishiwaki S.; Shirakami Y.; Hayashi T. & Saitoh K. (2007) Jejunal inflammatory granuloma: a complication of direct percutaneous endoscopic jejunostomy. *Endoscopy* Vol.39, Suppl.1, (Feb 2007), E. 116, ISSN 0013-726X
- Nishiwaki S.; Araki H.; Shirakami Y.; Niwa Y.; Iwashita M.; Hatakeyama H. & Saitoh K. (2009a) Transgastrostomic endoscopy-assisted endoscopic submucosal dissection. *Endoscopy* Vol.41, Suppl.2, (Feb 2009), E. 13, ISSN 0013-726X
- Nishiwaki S.; Araki H.; Shirakami Y.; Kawaguchi J.; Asano T.; Iwashita M.; Tagami A.; Hatakeyama H.; Hayashi T.; Maeda T.; Naganawa S. & Saitoh K. (2009b) Direct percutaneous endoscopic jejunostomy using a transgastrostomic endoscope in

- patients with previous endoscopic gastrostomy. *Endoscopy* Vol.41, Suppl.2, (Mar 2009), E. 36-37, ISSN 0013-726X
- Nishiwaki S.; Araki H.; Takada J.; Watanabe N.; Asano T.; Iwashita M.; Tagami A.; Hatakeyama H.; Hayashi T.; Maeda T. & Saitoh K. (2009c) Usefulness of an ultrathin endoscope in recanalization of a disrupted fistulous tract following percutaneous endoscopic gastrostomy or jejunostomy. *Endoscopy* Vol.41, Suppl.2, (Oct 2009), E. 273-274, ISSN 0013-726X
- Nishiwaki S.; Hatakeyama H.; Takada J.; Watanabe N.; Iwashita M.; Araki H. & Saito K. (2010a) Transcecostomal colonic stent placement after US-guided percutaneous cecostomy. *Gastrointest. Endosc.*, Vol.71, No.6, (May 2010), pp. 1097-1099, ISSN 0016-5107
- Nishiwaki S.; Araki H.; Takada J.; Watanabe N.; Asano T.; Iwashita M.; Tagami A.; Hatakeyama H.; Hayashi T.; Maeda T. & Saito K. (2010b) Clinical investigation of upper gastrointestinal hemorrhage after percutaneous endoscopic gastrostomy. *Dig Endosc.*, Vol.22, No.3, (Jul 2010), pp. 180-185, ISSN 0915-5635
- Ono H.; Kondo H.; Gotoda T.; Shirao K.; Yamaguchi H.; Saito D.; Hosokawa K.; Shimoda T. & Yoshida S. (2001) Endoscopic mucosal resection for treatment of early gastric cancer. *Gut*, Vol.48, No.2, (Feb 2001), pp. 225-229, ISSN 0017-5749
- Ponsky J. L. & Gauderer M. W. (1981) Percutaneous endoscopic gastrostomy: a nonoperative technique for feeding gastrostomy. *Gastrointest. Endosc.*, Vol.27, No.1, (Feb 1981), pp. 9-11, ISSN 0016-5107
- Ponsky J. L. & Aszodi A. (1984) Percutaneous endoscopic jejunostomy. *Am J Gastroenterol.*, Vol.79, No.2, (Feb 1984), pp.113-116, ISSN 0002-9270
- Rogers B. H.; Kaminski M. V. Jr & All J. (1989) Stabilizing sutures for percutaneous endoscopic gastrostomy. *Gastrointest. Endosc.*, Vol.35, No.3, (May-Jun 1989), pp. 241-243, ISSN 0016-5107
- Romero R.; Martinez F. L, Robinson S. Y.; Sullivan K. M. & Hart M. H. (1996) Complicated PEG-to-skin level gastrostomy conversions: analysis of risk factors for tract disruption. *Gastrointest. Endosc.* Vol.44, No.3, (Sep 1996), pp. 230-234, ISSN 0016-5107
- Sato R.; Watari J.; Tanabe H.; Fujiya M.; Ueno N.; Konno Y.; Ishikawa C.; Ito T.; Moriichi K.; Okamoto K.; Maemoto A.; Chisaka K.; Kitano Y.; Matsumoto K.; Ashida T.; Kono T. & Kohgo Y. (2008) Transnasal ultrathin endoscopy for placement of a long intestinal tube in patients with intestinal obstruction. *Gastrointest. Endosc.*, Vol.67, No.6, (May 2008), pp. 953-957, ISSN 0016-5107
- Shaker R. (1994). Unsedated trans-nasal pharyngoesophagogastrroduodenoscopy (T-EGD): technique. *Gastrointest. Endosc.*, Vol.40, No.3, (May-Jun 1994), pp. 346-348, ISSN 0016-5107
- Shike M.; Schroy P.; Ritchie M. A., Lightdale C. J. & Morse R. (1987) Percutaneous endoscopic jejunostomy in cancer patients with previous gastric resection. *Gastrointest. Endosc.*, Vol.33, No.5, (Oct 1987), pp. 372-374, ISSN 0016-5107
- Shike M.; Wallach C.; Likier H. Direct percutaneous endoscopic jejunostomies. *Gastrointest. Endosc.*, Vol.37, No.1, (Jan-Feb 1991), pp. 62-65, ISSN 0016-5107

- Shike M.; Latkany L. Direct percutaneous endoscopic jejunostomy. (1998) *Gastrointest. Endosc Clin N Am.*, Vol.8, No.3, (July 1998), pp. 569-580, ISSN 1052-5157
- Vitale M. A.; Villotti G.; D'Alba L.; De Cesare M. A.; Frontespezi S. & Iacopini G. (2005) Unsedated transnasal percutaneous endoscopic gastrostomy placement in selected patients. *Endoscopy*, Vol.37, No.1, (Jan 2005), pp. 48-51, ISSN 0013-726X
- Yim H. B.; Jacobson B. C.; Saltzman J. R.; Johannes R. S.; Bounds B. C.; Lee J. H.; Shields S. J.; Ruymann F. W.; Van Dam J. & Carr-Locke D. L. (2001) Clinical outcome of the use of enteral stents for palliation of patients with malignant upper GI obstruction. *Gastrointest. Endosc.*, Vol.53, No.3, (Mar 2001), pp. 329-332, ISSN 0016-5107

IntechOpen



Therapeutic Gastrointestinal Endoscopy

Edited by Prof. Oliviu Pascu

ISBN 978-953-307-743-7

Hard cover, 216 pages

Publisher InTech

Published online 22, September, 2011

Published in print edition September, 2011

Endoscopy has had a big role in the development of modern gastroenterology. Modern endoscopy will certainly be more therapeutic. It started with endoscopic hemostasis and polypectomy, than beginning of the 1970's with the advent of endoscopic sphincterotomy extended to biliopancreatic pathology and has a huge impact in this difficult pathology. Plastic stents made the first steps in endoscopic palliation of neoplastic jaundice, metallic stents, covered or uncovered are better for biliary palliation and can be used also for palliation neoplastic obstruction at different levels of the digestive tube. Resection of digestive tumors has evolved now to sub-mucosal resection, looking to have one-piece complete resection. Interventional endoscopy is now very complex and takes a lot of time for endoscopists to learn properly these techniques. This book is a very good up-to-date overview of new techniques of interventional endoscopy for those who want to learn or develop their knowledges in this field.

How to reference

In order to correctly reference this scholarly work, feel free to copy and paste the following:

Shinji Nishiwaki, Hiroo Hatakeyama, Masahide Iwashita and Hiroshi Araki (2011). Transgastrostomal Observation and Management Using an Ultrathin Endoscope After Percutaneous Endoscopic Gastrostomy, Therapeutic Gastrointestinal Endoscopy, Prof. Oliviu Pascu (Ed.), ISBN: 978-953-307-743-7, InTech, Available from: <http://www.intechopen.com/books/therapeutic-gastrointestinal-endoscopy/transgastrostomal-observation-and-management-using-an-ultrathin-endoscope-after-percutaneous-endosco>

INTECH
open science | open minds

InTech Europe

University Campus STeP Ri
Slavka Krautzeka 83/A
51000 Rijeka, Croatia
Phone: +385 (51) 770 447
Fax: +385 (51) 686 166
www.intechopen.com

InTech China

Unit 405, Office Block, Hotel Equatorial Shanghai
No.65, Yan An Road (West), Shanghai, 200040, China
中国上海市延安西路65号上海国际贵都大饭店办公楼405单元
Phone: +86-21-62489820
Fax: +86-21-62489821

© 2011 The Author(s). Licensee IntechOpen. This chapter is distributed under the terms of the [Creative Commons Attribution-NonCommercial-ShareAlike-3.0 License](#), which permits use, distribution and reproduction for non-commercial purposes, provided the original is properly cited and derivative works building on this content are distributed under the same license.

IntechOpen

IntechOpen