

# We are IntechOpen, the world's leading publisher of Open Access books Built by scientists, for scientists

4,800

Open access books available

122,000

International authors and editors

135M

Downloads

Our authors are among the

154

Countries delivered to

TOP 1%

most cited scientists

12.2%

Contributors from top 500 universities



WEB OF SCIENCE™

Selection of our books indexed in the Book Citation Index  
in Web of Science™ Core Collection (BKCI)

Interested in publishing with us?  
Contact [book.department@intechopen.com](mailto:book.department@intechopen.com)

Numbers displayed above are based on latest data collected.  
For more information visit [www.intechopen.com](http://www.intechopen.com)



# Magnifying Endoscopy and Chromoendoscopy in Upper Gastrointestinal Tract: Clinical Applications

Alina Boeriu, Daniela Dobru, Ofelia Pascarenco,  
Mircea Stoian and Simona Mocan  
*University of Medicine and Pharmacy Targu Mures,  
Romania*

## 1. Introduction

In recent years endoscopic diagnosis has evolved to include new endoscopic techniques that enhance visualization of gastrointestinal mucosa. This has improved diagnostic accuracy, as well as patient surveillance and management. Magnifying endoscopy is an endoscopic imaging technique that enhances visualisation of fine mucosal structures and capillary patterns. Studies utilizing magnification in conjunction with chromoendoscopy in the identification of intestinal metaplasia, dysplasia, early carcinoma in the upper gastrointestinal tract, as well as different patterns in colonic polyps, have elucidated its usefulness. The interpretation of the images and patterns seen with these new endoscopic methods, or inter-observer agreement, remains a challenge in clinical practice. Magnifying endoscopy is useful in predicting the histological diagnosis during the endoscopic examination itself, but requires a careful, time consuming, inspection of the mucosa. In this chapter we discuss different patterns observed by magnifying chromoendoscopy as well as the current challenges in performing the endoscopic procedures and in interpretation of images.

## 2. Technique of magnifying endoscopy and chromoendoscopy

### 2.1 Equipment

Standard endoscopic findings have a poor correlation with histopathologic diagnosis. Because of the patchy distribution of lesions within the mucosa, the sensitivity of random biopsies technique is low. New endoscopic methods have been developed to improve diagnostic sensitivity by enhancing the detection of suspicious lesions, followed by targeted biopsies. High resolution endoscopes provide better quality visualization. Magnifying endoscopes enlarge the image by using a movable lens, allowing for improved imaging of fine mucosal structures and microvascular architecture. Magnifying gastroscopes have an adjustable focus system that provides the capacity to obtain conventional images as well as close-up views. A transparent cap is affixed to the tip of the endoscope in order to maintain a distance of 2-3 mm between mucosa under examination and the endoscope. This helps to retain a focused image and permits a proper analysis of mucosal details by the endoscopist.

## 2.2 Chromoendoscopy

We use magnifying endoscopy in conjunction with chromoscopy in order to improve visualization of mucosal details. Acetic acid is weak acid with a pH of 2.5 that produces reversible intracellular cytoplasmic protein denaturation. The chemical response of the mucosa to acetic acid creates an observed whitening over time. The application of acetic acid highlights the surface of the mucosa and highlights subtle mucosal patterns. Methylene blue is a vital stain that is taken up by absorbent tissues such as the small intestinal epithelium. We used it for improved detection of intestinal metaplasia in the esophagogastric junction or in the gastric mucosa. The amount of dye that we use is 5 to 10 ml for the examination of esophageal mucosa and 10 to 20 ml in the gastric mucosa. An application of a limited amount of dye and repeated suctioning are necessary in order to avoid aspiration during the procedure.

## 2.3 Method

We perform conventional endoscopy, followed by magnification chromoendoscopy to identify different patterns corresponding to normal or modified mucosa and to establish the practical usefulness of these methods. Informed consent is obtained from all patients before performing all endoscopic examinations. All magnification endoscopy procedures are performed using an Olympus Gif-Q 160Z high-magnification endoscope which provides up to 115 times magnification. A transparent cap is attached to the endoscopic tip in order to maintain good focus. Initially, we examine the esophagus, stomach and duodenum by conventional endoscopy to identify visible changes of the mucosa. After that, the dye is spread onto the surface of the mucosa and we switch to the magnification function of the endoscope to examine modified areas and surrounding normal mucosa. We use a spray catheter inserted through the biopsy channel of the scope to spread the dye on the mucosa. We rotate the scope during the dye application for uniform coverage of the mucosa. Excess dye and water is removed by suction before starting the magnification. Previous white light endoscopic examination allows proper identification of some lesions and may help to narrow the area necessary to be surveyed in a focused, magnified endoscopic examination. Later, targeted biopsies from areas with modified patterns are obtained for correlation with histopathological findings. It is important to examine the entire mucosa before taking biopsies, as the presence of post-biopsy bleeding can interfere with obtaining subsequent magnified image. We take endoscopic photographs with relevant conventional and magnified views. Registered images are evaluated by three endoscopists. Previous published reports on normal magnified mucosa and modified mucosa with associated patterns are used for proper evaluation. The diagnosis of lesions is established by magnifying chromoendoscopy from the viewpoint of the fine mucosal pattern (so called, pit pattern) and the minute vessels. We study the correlation between mucosal patterns and the histological conditions. We classify the magnifying endoscopic pattern as follows: normal patterns and abnormal (modified) patterns. Corresponding biopsies are analyzed in Department of Pathology.

## 2.4 Patient selection

We perform magnifying endoscopy in patients with suspected esophageal or gastric lesions. As a first step, we perform conventional upper endoscopies. We identify patients with modified esophagogastric junction mucosa, atrophic gastritis, gastric polyps or other gastric lesions: erosions, nodular appearance of the mucosa, ulcer scars, superficial elevated lesions or flat lesions. Patients with advanced cancer, malignant lymphoma are excluded.

## 2.5 Challenges

An analysis of fine mucosal details and vasculature requires patient cooperation. This can be achieved by adequately sedation during the procedure. Occasionally, patient agitation creates esophageal and gastric motion and it is difficult to maintain a focused image. This can result in both prolongation of the procedure and an inadequate endoscopic survey. Additionally, dye application and careful examination of mucosal and vascular details increase the time necessary for the entire procedure. We have found that an experienced anesthesiologist can reliably ensure adequate sedation utilizing Propofol during the endoscopic examination. Mucus or secretions, as well as gastric and esophageal peristalsis, may interfere with obtaining good, relevant images.

## 3. Clinical applications

### 3.1 The esophagus

We select patients with presumed Barrett's esophagus on conventional endoscopy and modified esophagogastric junction for dye application and magnification. We examine the distal esophagus and esophagogastric junction with magnification. We first identify intra-epithelial papillary capillary loop (IPCL) in the squamous epithelium (Fig.1).

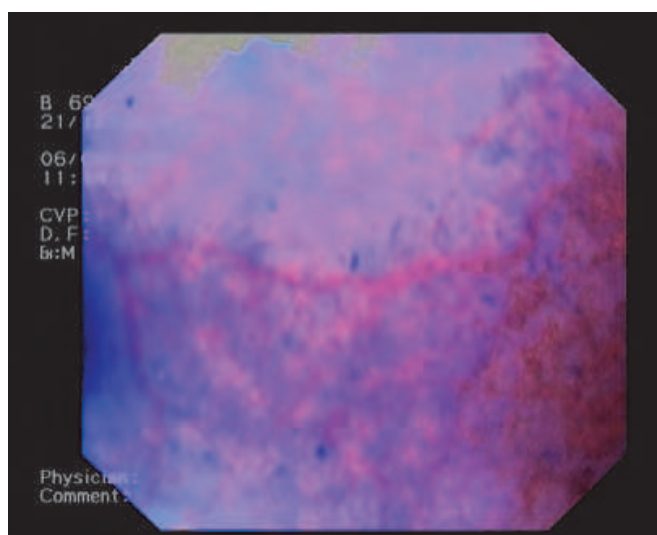


Fig. 1. Magnified view of intra-epithelial papillary capillary loop (IPCL)

#### 3.1.1 Barrett's esophagus (BE)

Barrett's esophagus is characterized by the replacement of the squamous epithelium of the esophagus by columnar epithelium. According to international guidelines, only patients with specialized columnar epithelium, that means intestinal metaplasia, are advised to undergo periodic endoscopic surveillance for the detection of dysplasia or early carcinoma (American Society for Gastrointestinal Endoscopy [ASGE], 2006). In clinical practice, 4-quadrant random biopsies are taken every 1 and 2 cm from the columnar-lined esophagus for the detection of early premalignant and malignant lesions. Previous reports emphasized the risk for the patients with cardiac-type mucosa in the columnar-line esophagus for development of esophageal adenocarcinoma (Sampliner, 2002). Riddell & Odze showed that patients with esophageal columnar metaplasia, without goblet cells, are also at risk for the development of carcinoma. These patients should be also included in surveillance programs

and guidelines for the diagnosis of BE should be revisited (Riddell & Odze, 2009). Kerkhof et al. demonstrated that the length of columnar-lined esophagus is one of the most important predictors for the presence of intestinal metaplasia, in addition to male gender and hiatal hernia size (Kerkhof et al., 2007). Thus, increasing the length of columnar metaplasia raises the chance of detecting goblet cells in biopsies. The detection of goblet cells in BE decreases in the case of short-segment BE (Jones et al., 2002). We perform magnified examinations in patients with long-segment BE (Fig.2), which is easily suspected based on conventional endoscopic appearance. The real challenge, however, is to diagnose columnar metaplasia that measures less than 1 cm in length. The endoscopic appearance of ultrashort BE is impossible to differentiate from an irregular Z-line with conventional endoscopy. Areas with intestinal metaplasia and dysplasia are difficult to detect with conventional endoscopy and a random biopsy technique is used in clinical practice. Mucosal changes, especially in the situation of short BE or ultrashort BE, are sometimes not easily identified. Sampling errors create the major limitations in the diagnosis accuracy.

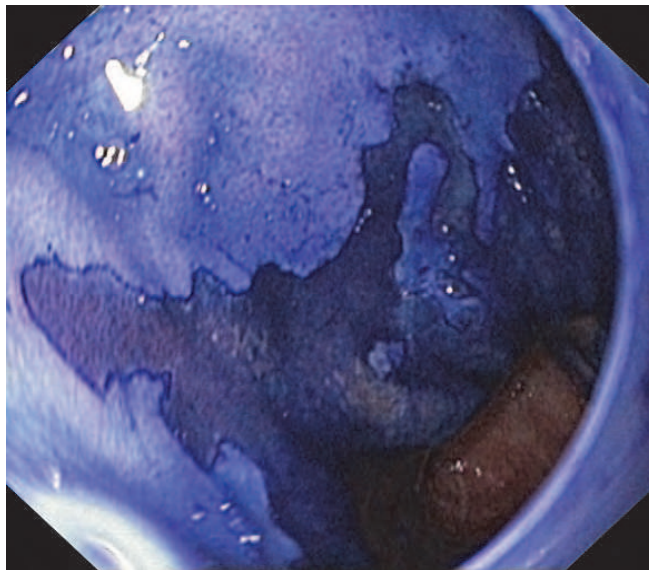


Fig. 2. Long-segment Barrett's esophagus: methylene blue selectively stains specialized columnar epithelium

Magnification chromoendoscopy has been shown to improve the detection of Barrett's esophagus. Several classification systems for the mucosal patterns have been proposed. Endo et al. identified 5 different patterns by using methylene blue magnification chromoendoscopy for the detection of BE: small/round pattern, straight, long oval, tubular and villous pattern. Round and straight pattern corresponded to gastric epithelium, whereas area showing tubular and villous pattern contained intestinal-type epithelium (Endo et al., 2002). Guelrud et al. used magnifying endoscopy in conjunction with chromoendoscopy with acetic acid to detect characteristic patterns in the esophagogastric junction, including intestinal metaplasia. They named this technique enhanced-magnification endoscopy. The result was the detection of four different patterns in the distal esophagus: round, reticular, villous and ridged. Areas showing villous or ridged pattern corresponded with the detection of intestinal metaplasia (Guelrud et al., 2001). Hoffman et al. demonstrated the usefulness of magnifying endoscopy with acetic acid in the detection of BE, with fewer biopsies needed for diagnosis compared with a random biopsy technique (Hoffman et al., 2006). We perform magnifying endoscopy with methylene



blue application to identify different patterns in the esophagogastric junction. For the detection of BE, we first identify the proximal margin of gastric folds on conventional endoscopy. On magnified examination, we search for the identification of the transition from circular pattern corresponding with cardiac mucosa, to a modified pattern: villous or tubular pattern corresponding to intestinal metaplasia. The application of methylene blue allows a good demarcation of modified areas, including the small islands of columnar metaplasia, almost invisible on white light examination. The goal of the examination is the detection of modified patterns, that correspond with metaplastic and dysplastic mucosa. We identify different types of mucosal patterns: round pattern, circular pattern and oval pattern, tubular pattern and villous pattern. The presence of circular and oval patterns is associated with cardiac-type mucosa (Fig.3). Round pattern corresponds to fundic epithelium (Fig.4). Tubular and villous patterns exhibit intestinal metaplasia by histologic evaluation (Fig.5, Fig.6, Fig.7).

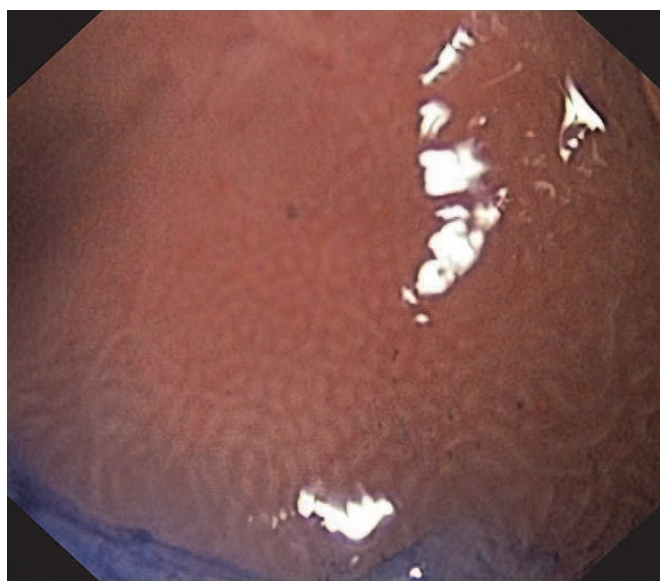


Fig. 3. Circular or oval pits corresponding to cardiac-type mucosa

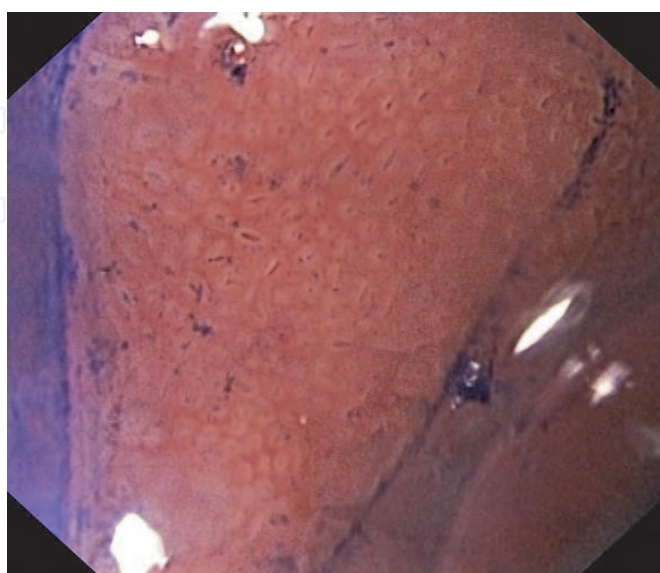


Fig. 4. Round pits regular in shape and arrangement corresponding to fundic mucosa

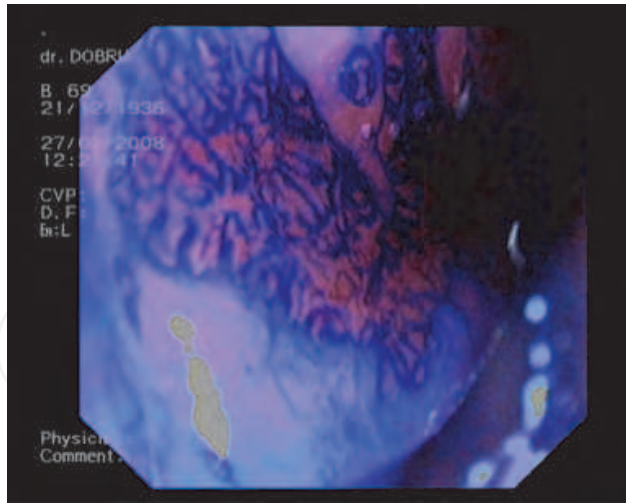


Fig. 5. Tubular pattern corresponding to intestinal metaplasia in a long- segment BE

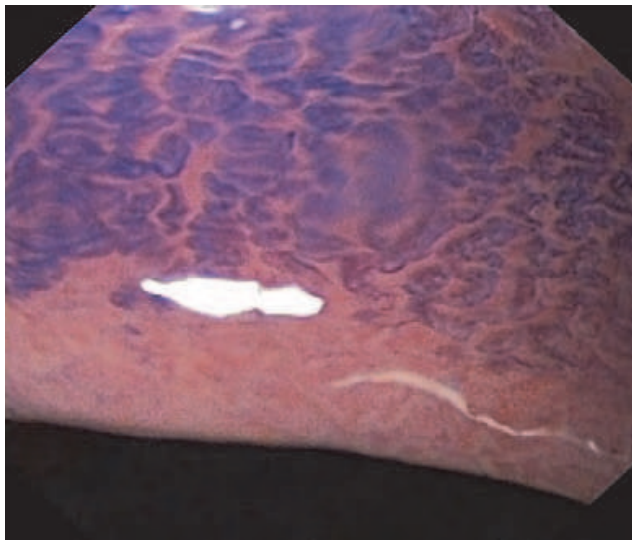


Fig. 6. Tubular pattern corresponding to intestinal metaplasia in a short-segment BE

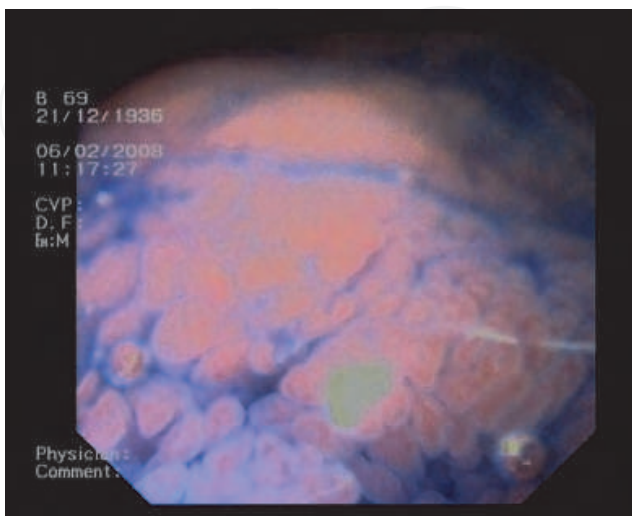


Fig. 7. Villous pattern corresponding to intestinal metaplasia in a short-segment BE

We use enhanced magnifying endoscopy for the diagnosis of short-segment BE. We observe a whitish discoloration of epithelium, followed by a clear differentiation between columnar and squamous epithelium two minutes after acetic acid application: the squamous epithelium remains white, while columnar epithelium becomes reddish (Fig.8). We identify small islands of columnar mucosa at the esophagogastric junction after dye application. A focused magnification on these areas allows the identification of different patterns and targeted biopsies (Fig.9).

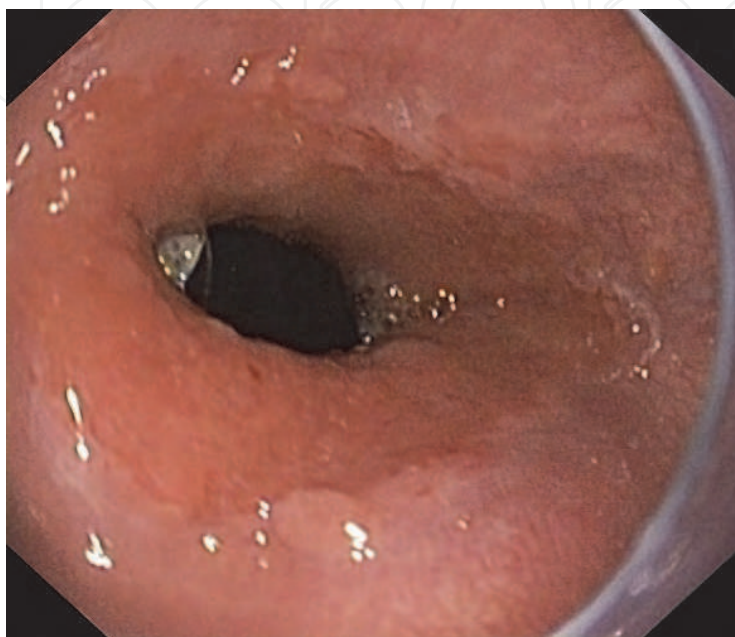


Fig. 8. The acetowhitening reaction in a case of short-segment BE: columnar epithelium becomes reddish and swollen

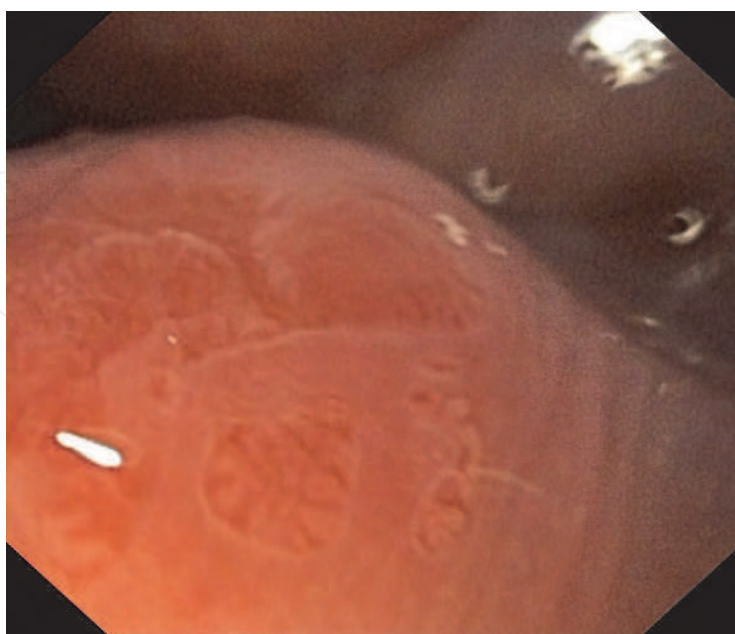


Fig. 9. Small islands of columnar epithelium are clearly detected; the villous pattern corresponds to intestinal metaplasia



This method has limitations because it requires additional time, experience in performance, as well as experience in the interpretation of different mucosal patterns. Dye may not uniformly spread on the mucosa (Fig.10). We identify areas with irregular patterns, corresponding to dysplastic BE. These areas are appropriate for targeted biopsies and subsequent surveillance (Fig.11).




Fig. 10. Heterogenous stained areas in patient with dysplasia

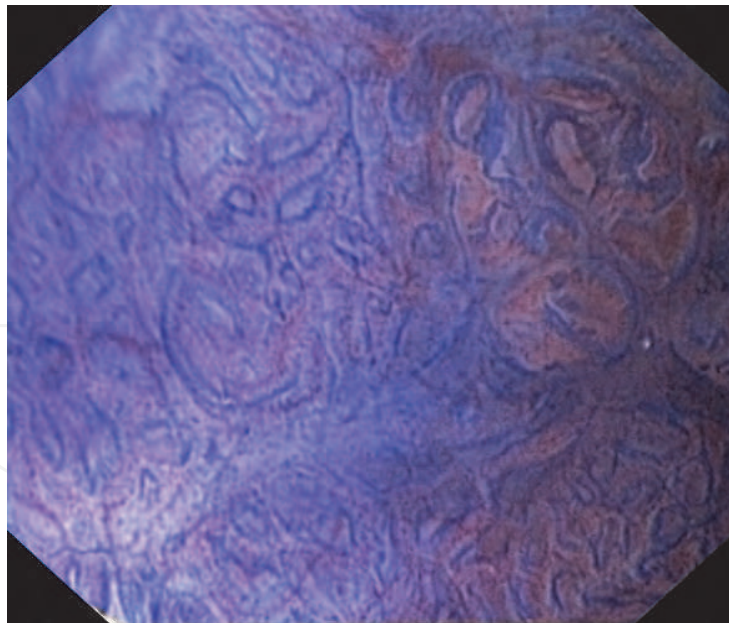


Fig. 11. Distorsion of the cerebriform pattern in a patient with long-segment BE; the detection of an irregular/distorted pattern is followed by focused biopsies for the diagnosis of dysplasia

Some studies show that magnifying endoscopy improves the detection of neoplasia in BE. An irregular mucosal pattern, an irregular vascular pattern and the presence of abnormal blood vessels are findings reported to be predictors for high-grade dysplasia (HGD) or early neoplasia in BE. Sharma et al. reported the detection of an irregular/distorted pattern in

patients with BE which corresponded to HGD on biopsy specimens. They did not identify a specific pattern corresponding to low-grade dysplasia (LGD) in these patients (Sharma et al., 2003). Vascular patterns are better identified with narrow band imaging (NBI) than with chromoendoscopy, because the blood vessels may be masked by the use of stains. The observation of capillary patterns by NBI improves the diagnostic value for detecting specialized intestinal epithelium and superficial Barrett's adenocarcinoma (Goda et al., 2007).

### 3.2 The stomach

In the stomach, we analyze two different anatomical findings by magnification: the mucosal structure and the microvascular architecture. Small round pits of uniform shape are identified in normal gastric body mucosa. The capillary loops surround the necks of gastric pits and have a honeycomb-like appearance under magnification. The collecting venules, which drain from the mucosal surface towards the submucosa, have a starfish-like appearance. The normal magnified view of gastric mucosa was previously described and the evaluation of normal patterns is useful for the detection of any inflammatory or malignant changes of the mucosa (Kato et al., 2005). When we identify a mucosal lesion by conventional endoscopy we magnify suspicious areas, as well as normal appearing surrounding mucosa. In selected cases, we use dyes such as methylene blue or acetic acid for better visualization of fine mucosal structure and a clearer demarcation between normal and pathologic mucosa.

#### 3.2.1 Normal gastric mucosa

Magnified endoscopic findings of normal gastric mucosa are different in the gastric body and antral areas. A honeycomb-like appearance of subepithelial capillary network (SECN) and collecting venules (CV) are specific findings of the microvascular architecture in the gastric body (Fig.12). The microvascular architecture of the gastric body mucosa was first described *in vivo* by Yagi. (Yagi, 2001). Gastric antrum demonstrates a different pattern, without the detection of CVs, due to their location in a deeper part of the lamina propria than in the gastric body. The microvascular architecture of the antral mucosa shows a coil-shaped SECN (Fig.13).

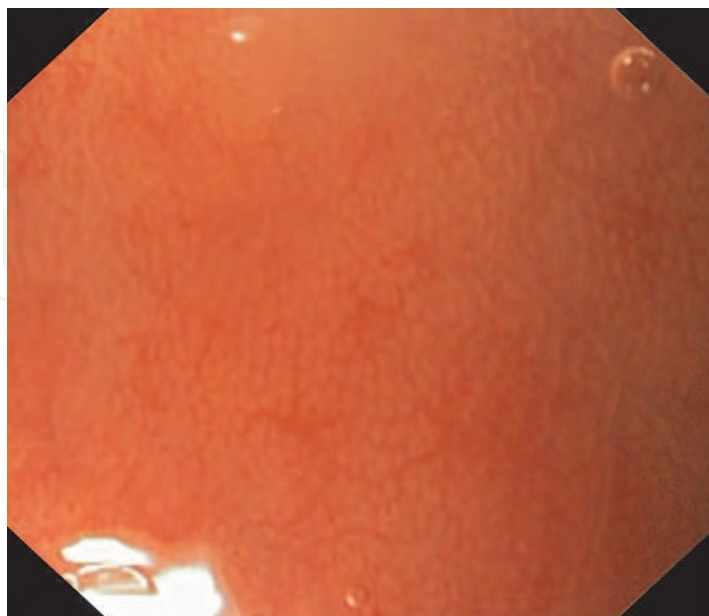


Fig. 12. Normal gastric body: regular round pits, honeycomb-like SECN and regular arrangement of CVs

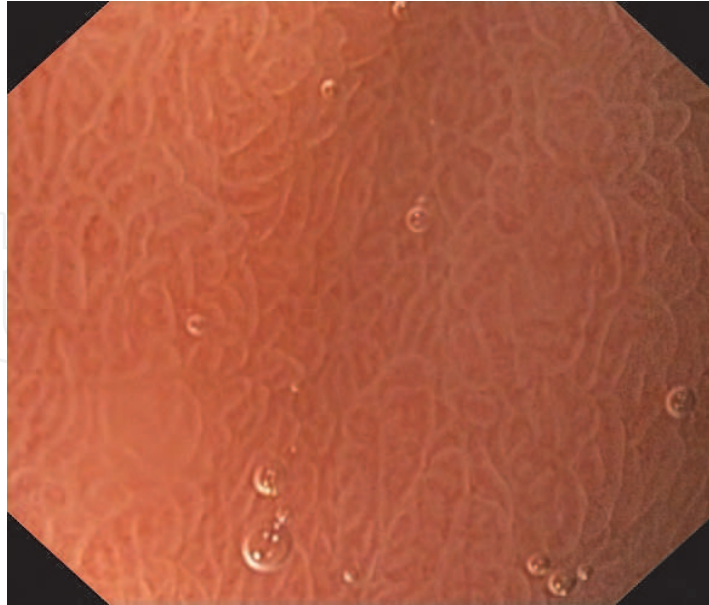


Fig. 13. Normal antral mucosa: the SECN is coil-shaped

The first description in vivo of the characteristic pattern of the gastric antrum was by Yao. (Yao & Oishi, 2001). We observe these specific patterns of gastric mucosa free from pathological changes in order to be able to distinguish them from abnormal situations associated with modified mucosa due to inflammation, atrophy or neoplasia.

### 3.2.2 Chronic gastritis

Different findings on magnifying endoscopy are reported to be associated with modified gastric mucosa as a result of inflammation or atrophy. The proper evaluation of mucosal changes is an important step in detection of premalignant lesions and subsequent surveillance for some of these patients. Four different patterns are described in association with normal mucosa, *Helicobacter pylori* (HP)-infected stomach and gastric atrophy: type 1 shows regular round pits, honeycomb-like SECN with regular arrangement of CVs; type 2 shows regular round pits and honeycomb-like SECN, with the loss of CVs; type 3 shows enlarged white pits surrounded by erythema, with the loss of normal SECN and CVs; type 4 shows the loss of round pits and SECN, with an irregular arrangement of CVs (Anagnostopoulos et al., 2007). The authors reported the correspondence between type 1 and normal gastric mucosa, type 2 or 3 and HP-infected gastric mucosa. Type 4 pattern corresponds to mucosal atrophy. The visibility of collecting venules is affected by HP-induced inflammation and atrophy. We identify a magnified appearance of large white pits with surrounding erythema in cases of HP-induced gastritis. Collecting venules are not visible (Fig.14). Several studies report the use of magnification endoscopy for the evaluation of mucosal patterns of the gastric body after successful eradication of HP. Yagi K et al. described the characteristic features of the gastric mucosa in this situation: (i) disappearance of swelling and/or erythema between gastric pits; (ii) white pits change to pinhole-like pits; and (iii) collecting venules became visible (Yagi et al., 2002). Using magnifying technique, we are able to identify HP-infected mucosa during the endoscopic procedure and are also able to evaluate the efficiency of the eradication therapy.

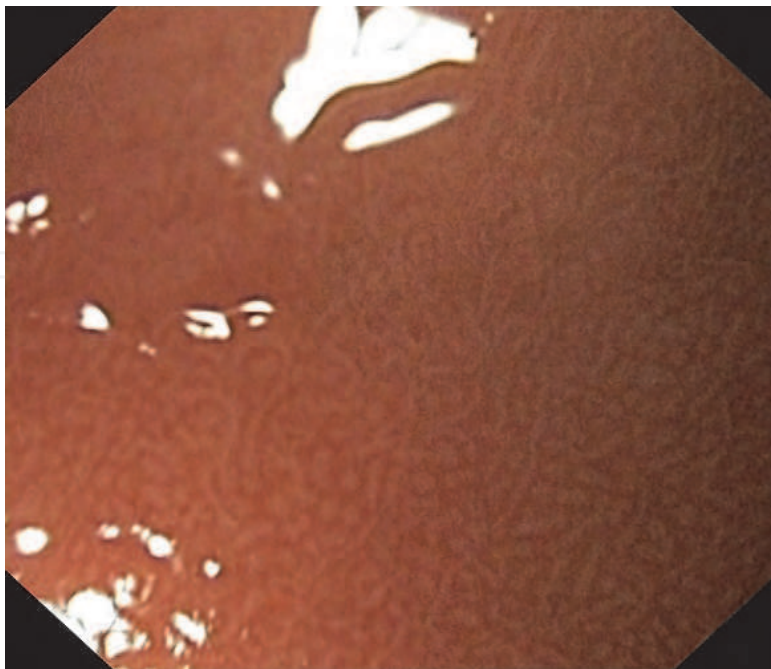


Fig. 14. Helicobacter pylori- induced gastritis: enlarged white pits surrounded by erythema

In case of atrophic gastritis, we notice an irregular arrangement of collecting venules with the disappearance of normal SECN pattern (Fig.15). Magnifying endoscopic observation is helpful for the identification of patients with extensive atrophy. These patients are selected for dye application and targeted inspection, followed by biopsying suspicious areas for the detection of intestinal metaplasia or gastric dysplasia (Fig.16, Fig.17).

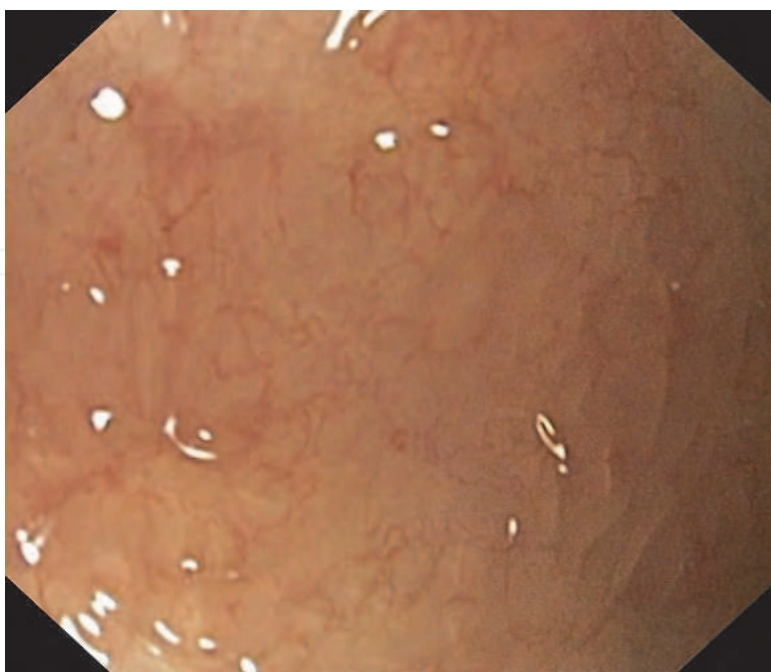


Fig. 15. Atrophic gastritis: the disappearance of normal SECN and round pits, irregular arrangement of CVs



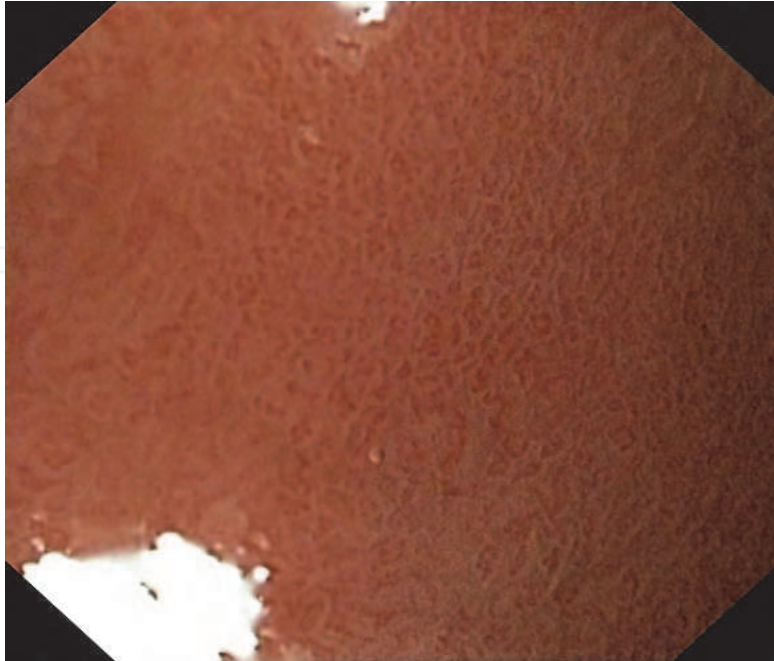


Fig. 16. Area with modified pattern corresponding to intestinal metaplasia

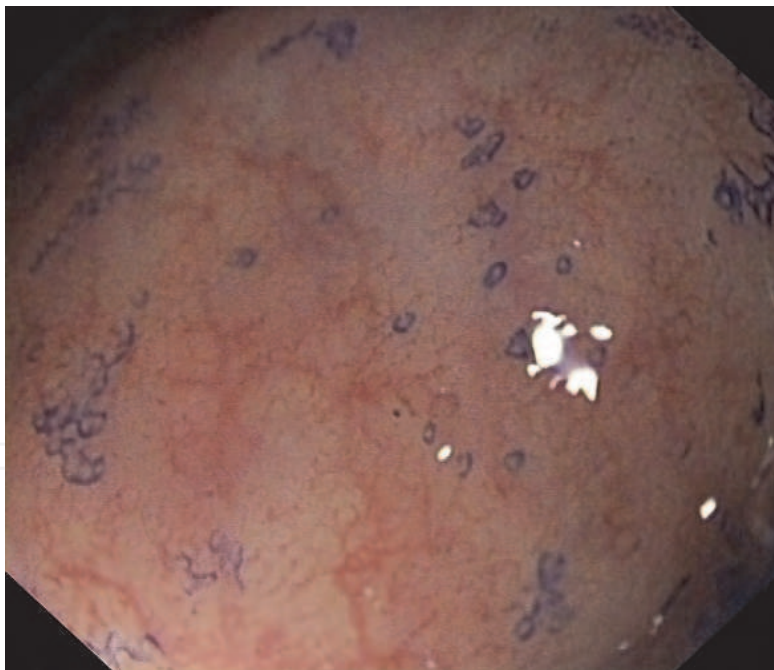


Fig. 17. Islands of intestinal metaplasia in the area of atrophic gastritis identified after methylene blue application

### 3.2.3 Premalignant lesions: Intestinal metaplasia, low-grade dysplasia (LGD)

It is well known that the prognosis of patients with gastric cancer depends on the stage at diagnosis. As a multistep process in gastric carcinogenesis has been defined, early detection and vigilant surveillance of these histopathologic lesions are mandatory:

atrophic gastritis, intestinal metaplasia and dysplasia. The methods for detection and surveillance are different in different parts of the world and an ideal technique, biopsy protocol, and optimum time interval between endoscopic procedures, have not yet been defined. Some authors emphasize the benefits of annual surveillance of patients with atrophic gastritis or intestinal metaplasia in detecting cancer at an early stage, with improvement in survival (Whiting et al., 2002). The diagnosis of premalignant lesions and the performance of surveillance depend upon random biopsy technique. The updated Sydney System recommended taking two antral biopsies, two corporal biopsies and one biopsy from the incisura angularis (Dixon et al., 1996). This prescribes a considerable effort in order to evaluate the risk of the patient for the development of gastric cancer. Magnification chromoendoscopy may optimize the evaluation of premalignant gastric lesions (Areia et al., 2008). Topographic mapping for the detection of extensive intestinal metaplasia or more advanced lesions such as dysplasia or carcinoma should be considered when evaluating the patient's risk (Correa et al., 2010). As previously discussed, not all patients are suitable for the magnifying examination of the entire gastric mucosa. A full magnified survey of the normal appearing mucosa can be a technical challenge and lengthens the procedure. A focus on areas of modified mucosa, followed by targeted magnifying examination of suspicious areas, could improve the detection of early pre-neoplastic and neoplastic lesions. We have tried to identify the specific endoscopic patterns associated with intestinal metaplasia and dysplasia on histopathological evaluation. We apply a mucolytic agent (10% N-acetylcysteine) onto the mucosa. After that, a solution of methylene blue 1% is sprayed over the mucosa. Three minutes later, we wash the mucosa with water and remove the excess methylene blue and water. Using this technique, we obtain areas of mucosa with blue homogeneous staining and magnify these particularly areas as well as the surrounding mucosa (Fig.18). Blue stained areas are islands of intestinal metaplasia in contrast to surrounding nonabsorptive gastric epithelium.

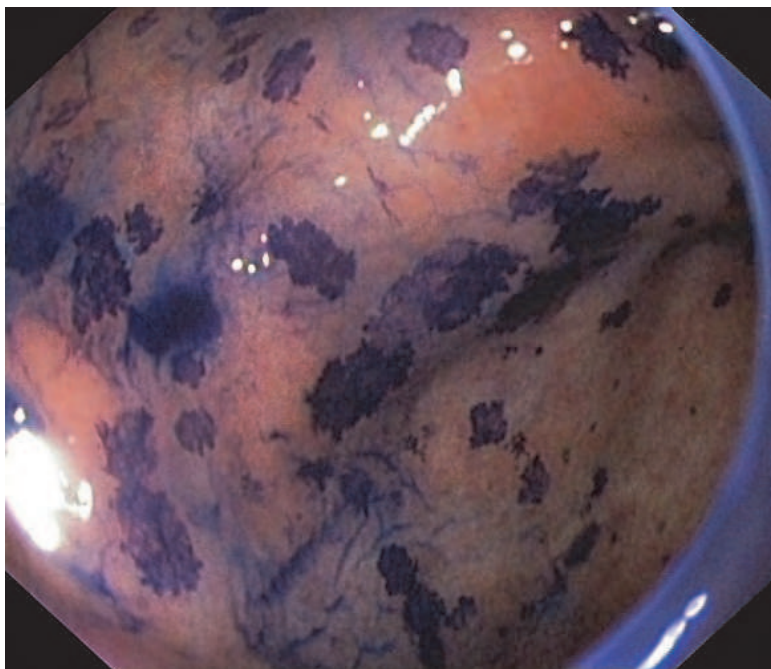


Fig. 18. Blue stained areas detected after methylene blue application

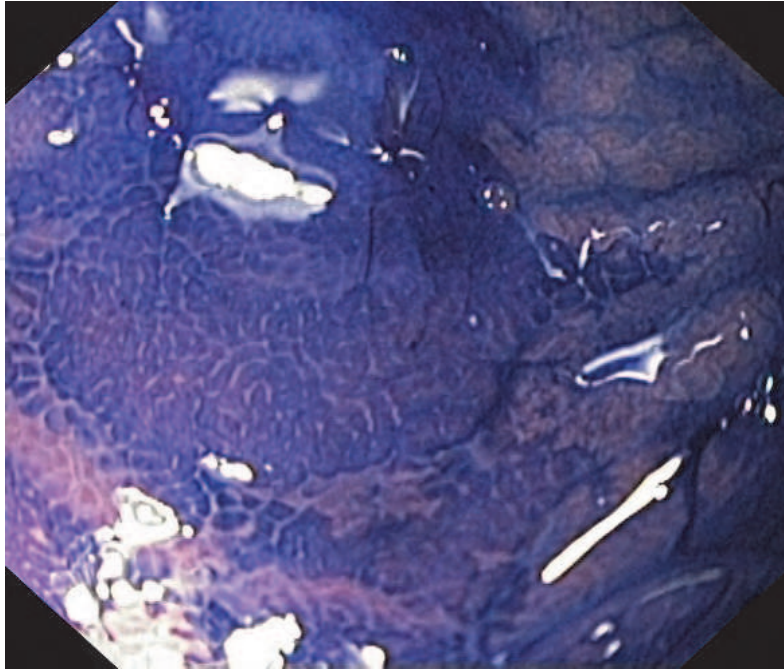


Fig. 19. Focused magnification on homogenous stained areas

Keeping in mind that dysplasia and carcinoma may develop in areas of intestinal metaplasia, we perform focused magnification in these areas (Fig.19). We identify specific pit patterns in stained areas: round and tubular pits, blue small pits (Fig.20, Fig.21). Targeted biopsies are taken from these areas and histopathological evaluation confirm the presence of intestinal metaplasia.

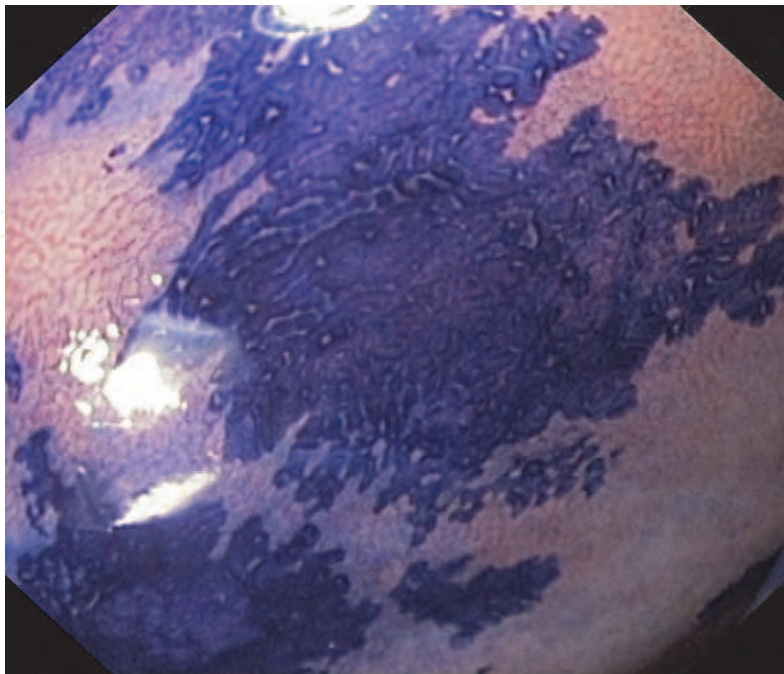


Fig. 20. Blue small pits in areas with intestinal metaplasia



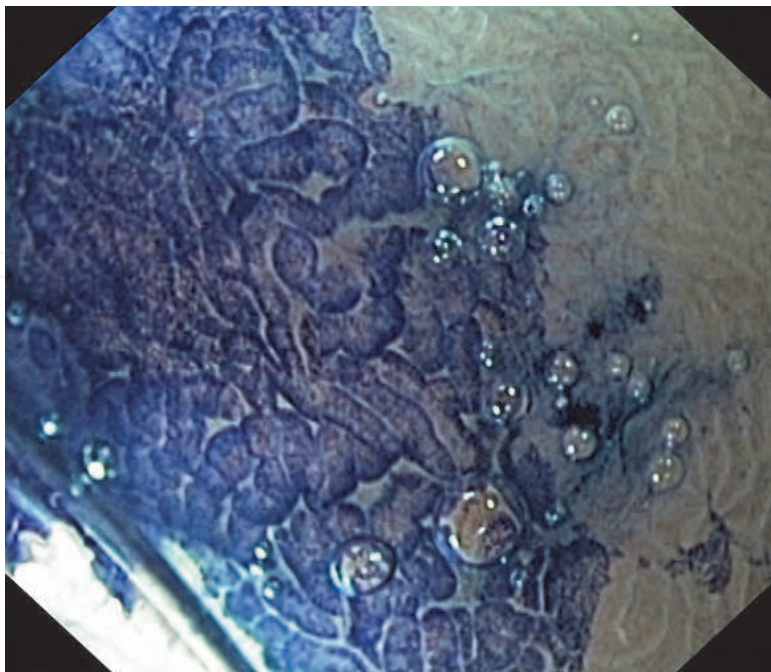


Fig. 21. Tubular pits in areas with intestinal metaplasia

In some cases we obtain a heterogeneous staining mucosa with an unclear pattern (Fig. 22, Fig.23). It is difficult to achieve reliable inter-observer agreement in these cases where different patterns are not clearly identified. Uneven spreading of the dye across the mucosa often causes these unclassified findings and affects the diagnosis accuracy. Targeted biopsies are mandatory to clarify the diagnosis because the detection of irregular patterns is highly suspicious for the diagnosis of dysplasia.

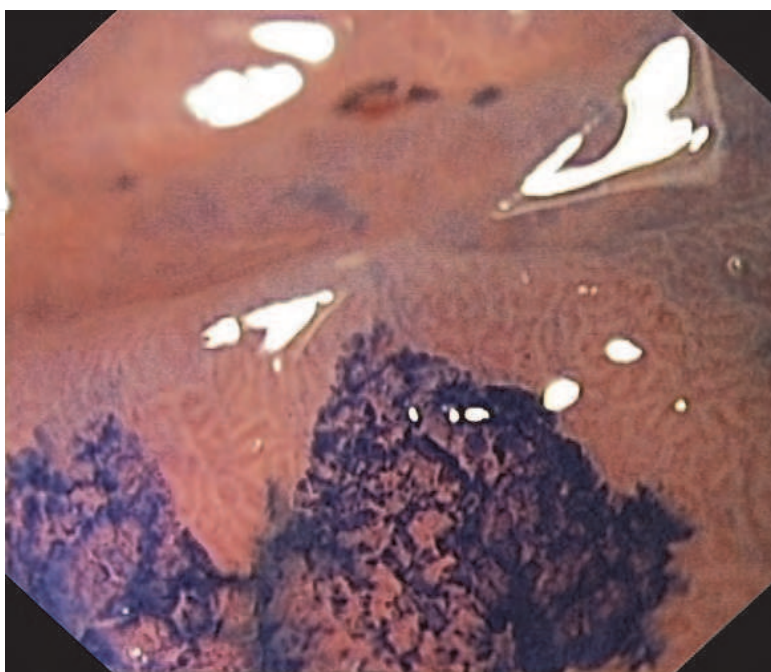


Fig. 22. Heterogenous stained area obtained after methylene blue application



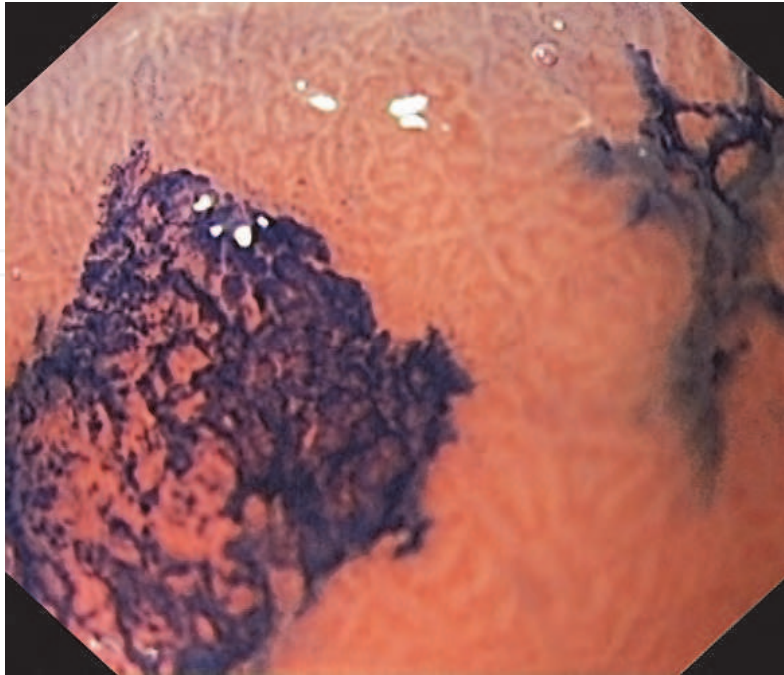


Fig. 23. Heterogenous stained area showing the loss of the clear pattern

Mucosal patterns corresponding to intestinal metaplasia and dysplasia were previously defined by Dinis-Ribeiro et al. The authors identified three groups of endoscopic patterns after methylene blue staining, as follows: Group I (nonmetaplastic, nondysplastic mucosa), Group II (metaplastic mucosa) and Group III (dysplastic mucosa) (Dinis-Ribeiro et al., 2003).

We are sometimes faced with the clinical situation of a patient with previously detected LGD on random biopsies where subsequent follow-up endoscopies with biopsies failed to detect any dysplasia. A surveillance strategy based on magnifying endoscopy with targeted biopsies should offer a better assurance for these patients, compared to a conventional examination with random biopsies (Fig.24). This is particularly true since the main concern in cases of the random diagnosis of LGD is the failure of the detection of a synchronous lesion such as HGD or even carcinoma.

International guidelines recommend the surveillance of patients with LGD and the treatment (surgical or endoscopic) for patients with HGD (ASGE, 2006). Surveillance of patients with LGD is challenging given the large surface area that must to be evaluated, the difficulty of reliably re-locating suspicious mucosal sites seen on prior endoscopies, as well as inter-observer variability. We recommended surveillance based on magnifying examination of gastric mucosa and focused biopsies in our patients with LGD. The management and surveillance of patients with premalignant lesions remain controversial in different part of the world. In the United States the surveillance of patients with gastric intestinal metaplasia is not recommended (ASGE, 2006). On the other hand, studies from the United Kingdom show the benefit of performing surveillance in patients with premalignant lesions for the early detection of gastric cancer (Whiting et al., 2002). Magnifying chromoendoscopy provides the ability to evaluate the extension of gastric atrophy and intestinal metaplasia. This may yet prove to be a reliable way to follow the evolving risk to the patient. Specific recommendations should be considered for each individual patient,

based upon the detection of dysplasia and the extent and severity of premalignant lesions (atrophic gastritis and intestinal metaplasia).

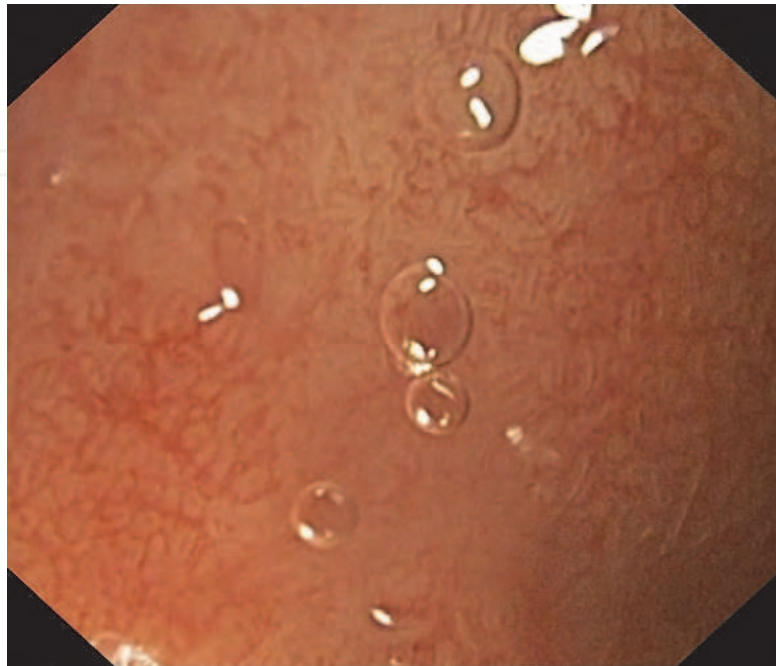


Fig. 24. Area with lack of visible structure in a patient with LGD

### 3.2.4 High-grade dysplasia (HGD) and early gastric cancer (EGC)

Several reports describe the magnification findings of early gastric cancer (Fig.25). Since endoscopic treatment for gastric cancer was developed, the proper evaluation of the lesion,

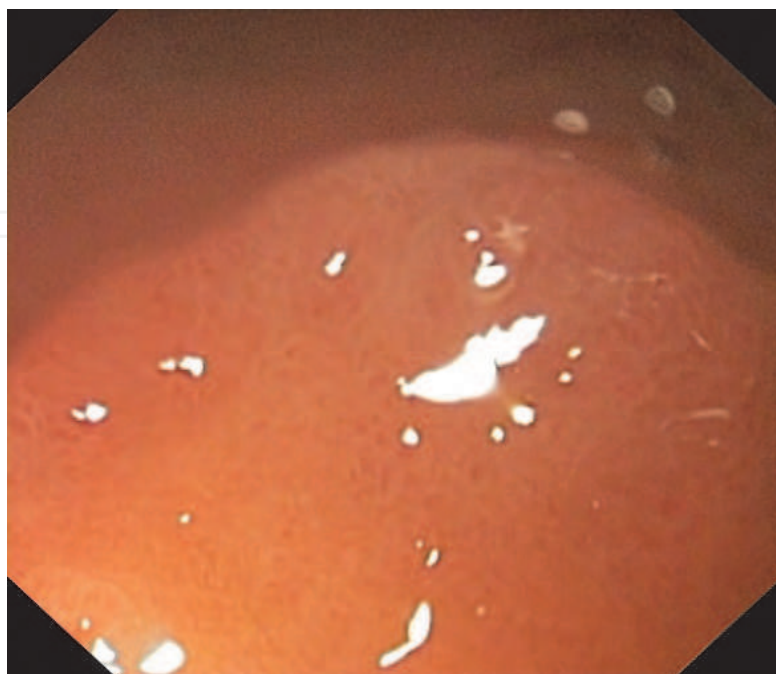

Fig. 25. Area showing the loss of regular SECN pattern (EGC)

with regards to invasion, lateral spreading, and histopathological features, has become even more essential. Otsuka et al. classified the characteristic patterns of EGC as follows: (i) a small regular pattern of sulci and ridges; (ii) an irregular pattern of sulci and ridges; and (iii) a lack of visible structure. The presence of irregular minute vessels and the variation in the caliber of vessels are specific vascular patterns in EGC. The fine observation provides information about histological characteristics of the detected lesions. Small regular patterns were observed more frequently in differentiated adenocarcinoma; lack of visible structure and irregular patterns were characteristic to undifferentiated adenocarcinoma (Otsuka et al., 2004).

In differentiated carcinoma, the regular SECN pattern disappeared and irregular microvessels proliferated within the cancerous mucosa. It was a clear demarcation line between the cancerous and non-cancerous mucosa. The detection of an irregular shape and distribution of microvessels makes the difference between early cancer and focal gastritis (Fig.26). Irregular microvessels are tumorous vessels. The demarcation line between cancer and normal mucosa allowed the evaluation of the margin of the carcinoma before endoscopic resection. In case of undifferentiated carcinoma, magnification endoscopic findings show the loss of the regular SECN pattern. According to Yao et al., the analysis of vascular architecture by magnifying endoscopy could be a new diagnostic system for the early detection of gastric cancer. Characteristic microvascular patterns were identified for different histopathological type of carcinoma (Yao et al., 2004).

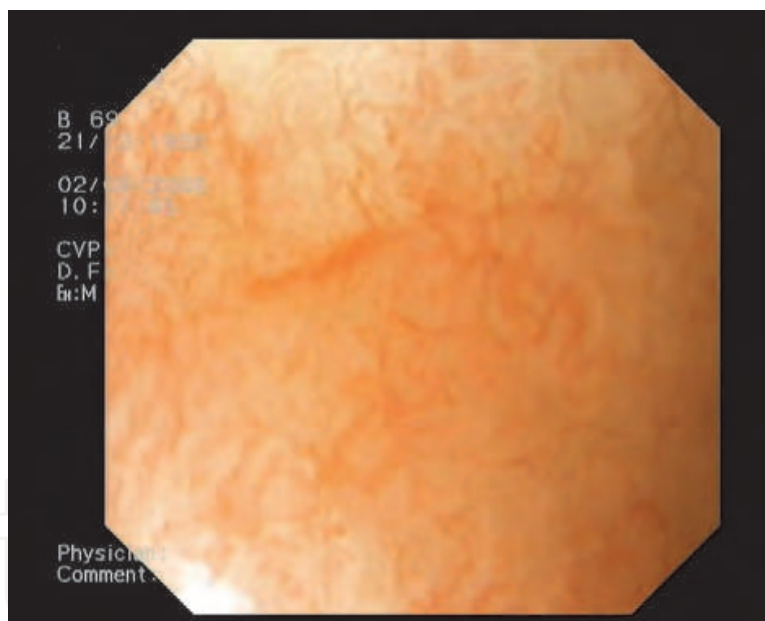


Fig. 26. Irregular shape and arrangement of microvessels (EGC)

The distinction between a flat reddened lesion due to inflammation (chronic gastritis) or EGC of superficial flat type is sometimes impossible by conventional endoscopy. The examination of fine mucosal structure and microvascular architecture by magnification allows the detection of irregular microvessels and the loss of the regular SECN pattern in case of HGD (Fig.27). We have encountered situations where the differentiation between modified mucosa due to inflammation or malignant transformation has been difficult. In one such case, under magnification, we detected the loss of regular SECN pattern, but no irregular microvessels. The histopathological evaluation subsequently demonstrated chronic gastritis with intestinal metaplasia (Fig.28).

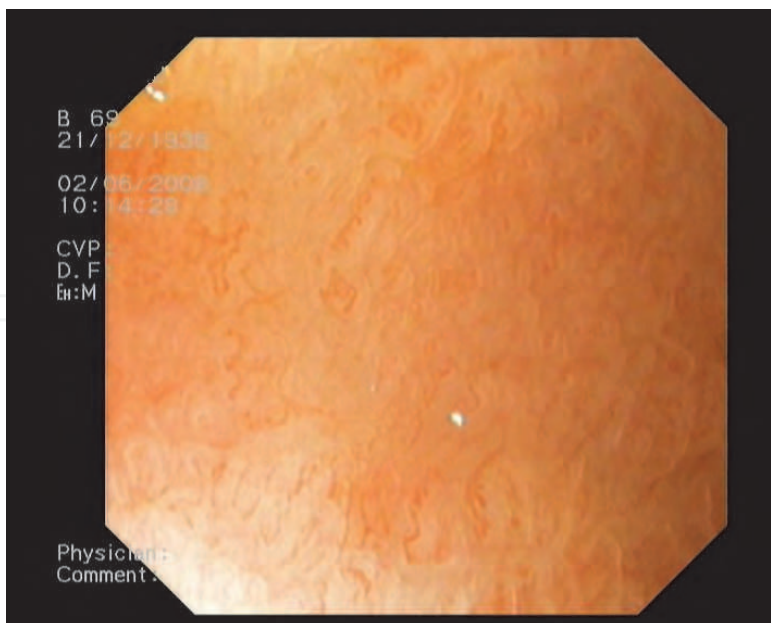

Fig. 27. Area with abnormal microvessels and variation of vessel caliber (HGD)

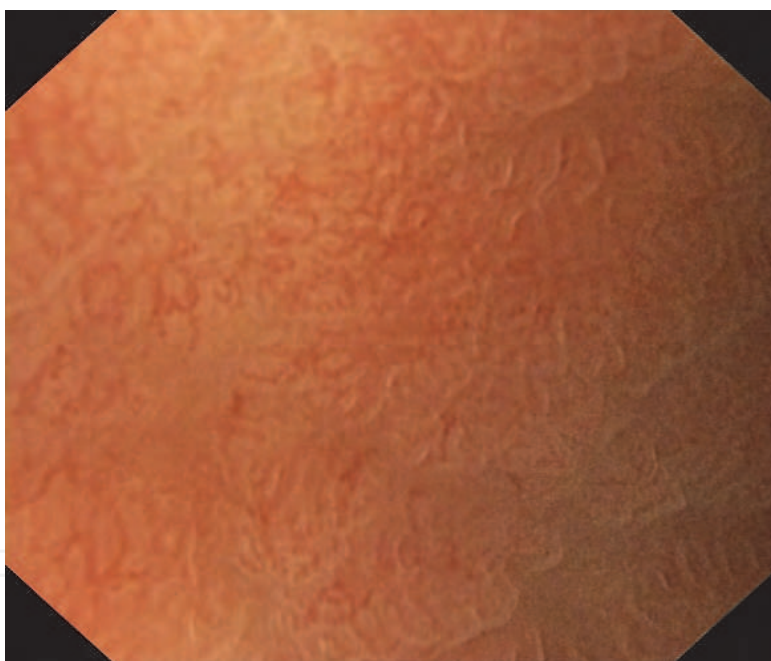


Fig. 28. Disappearance of the regular SECN pattern, without the detection of abnormal microvessels (chronic gastritis with intestinal metaplasia)

To summarize, some lesions are difficult to recognize as cancerous or non-cancerous based upon conventional or magnified examination. The detection of a modified pattern requires targeted biopsies in order to clarify the diagnosis. Gastric mucosa can be modified in various situations such as inflammation, atrophy, dysplasia or cancer. We must keep in mind that all of these alter the endoscopic appearance of the mucosa on magnification. That is why the interpretation of different patterns can be so difficult. We found that an examination of the mucosal and vascular architecture improves our accuracy in the endoscopic detection of gastric neoplasia.



### 3.2.5 Gastric polyps

Proper diagnosis and management of patients with gastric polyps involves a histopathologic evaluation of the polyp and also of the surrounding mucosa (Carmack et al., 2009). That entails many biopsy samples, both from the lesion and from unaffected mucosa. Magnified endoscopic findings corresponding to gastric polyps are described by Tajiri et al. Hyperplastic polyps show a reddish, coarse pattern on magnifying endoscopy. Gastric adenomas show a white, minute, regular mucosal pattern (Tajiri et al., 2002). We identify specific patterns corresponding to gastric polyps (Fig.29, Fig.30). The true extension of premalignant lesions such as atrophic gastritis and intestinal metaplasia are identified after methylene blue or acetic acid application.



Fig. 29. Minute, regular pattern in gastric adenoma

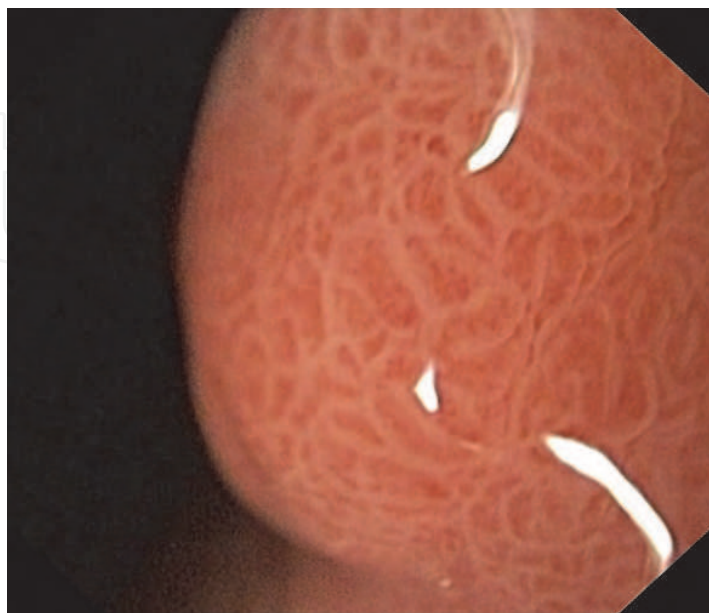


Fig. 30. Reddish, coarse pattern in hyperplastic polyps

In the case of a patient with multiple polypoid lesions in the body of the stomach, magnified examination allowed the identification of a specific, modified pattern (Fig. 31). The histopathological evaluation established the diagnosis: gastric carcinoids. We detected characteristic pattern corresponding to gastric atrophy by magnifying the surrounding mucosa (Fig.32).

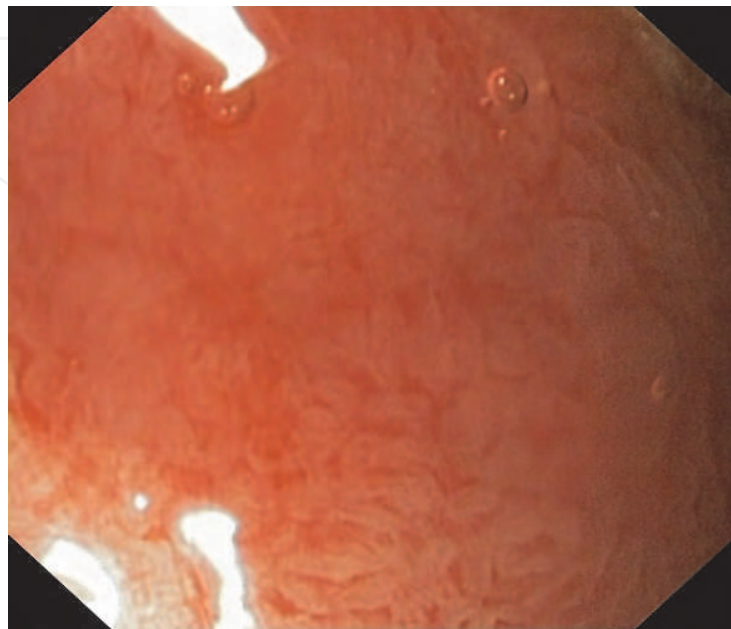


Fig. 31. Irregular pattern in gastric carcinoid

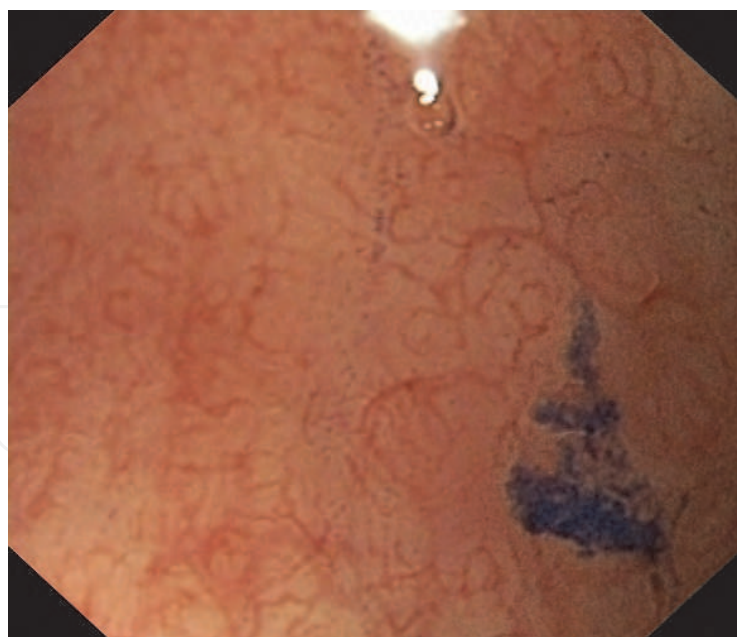


Fig. 32. Irregular arrangement of the CVs in the surrounding mucosa (atrophic gastritis)

In conclusion, the evaluation of the mucosa that surrounds gastric polyps is recommended when consider management recommendations. We identify characteristic endoscopic features that serve as useful tools for improving the diagnostic accuracy and ease of surveillance in these patients.

### 3.3 Normal duodenal mucosa and celiac disease

Magnification endoscopy allows the identification of details of the villous structure of the normal duodenal mucosa (Fig.33, Fig.34).

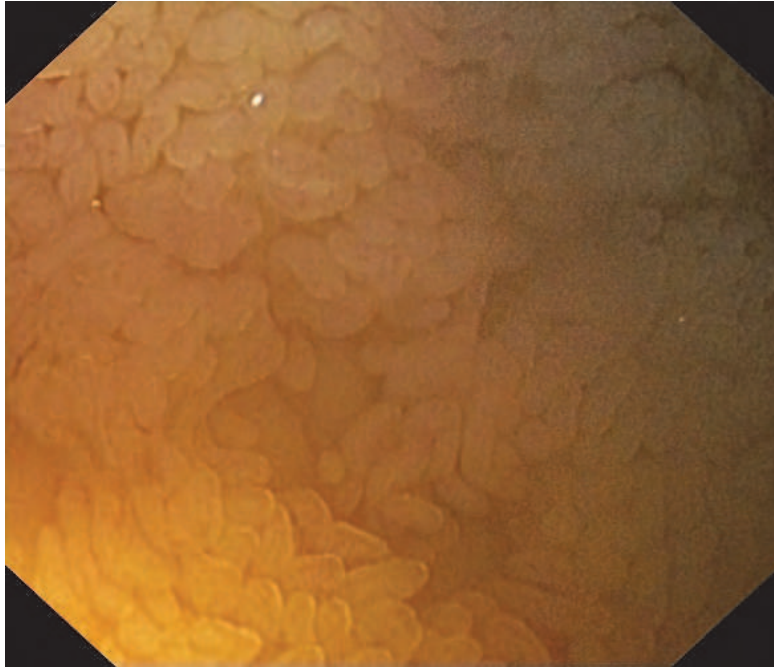


Fig. 33. Normal duodenal mucosa on magnifying endoscopy

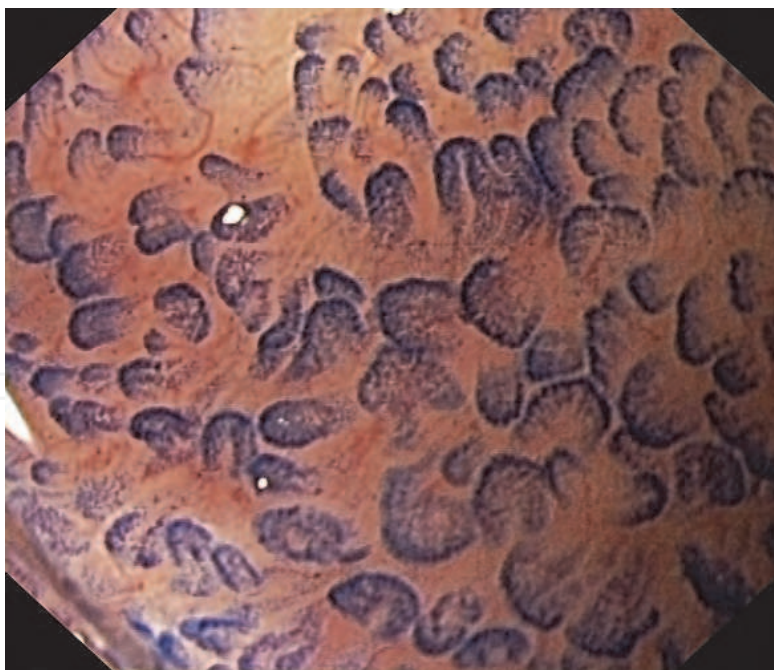


Fig. 34. Magnified view of villi after methylene blue application

Scalloping and reduced number of duodenal folds, mosaic appearance and mucosal grooves are all characteristic conventional endoscopic features of the duodenal mucosa in patients with celiac disease (Fig.35). Because of the patchy distribution of the disease, in some situations targeted biopsies increase diagnostic accuracy. The detection of villous atrophy



was improved by the use of magnification endoscopy (Cammara et al., 2004). Enhanced magnification endoscopy revealed 4 mucosal patterns: I, normal; II, stubbed; III, ridged and IV, foveolar. Patterns II, III and IV corresponded to villous atrophy. This method was superior to standard endoscopy in detecting patchy areas of partial mucosal atrophy (Lo et al., 2007). By using magnifying endoscopy, we identify areas with short duodenal villi and we take biopsies samples from these areas (Fig.36, Fig.37). Histopathological evaluation confirms the presence of villous atrophy in these areas. This can be a method to avoid random biopsies and delays in diagnosis in patients with malabsorption syndrome.

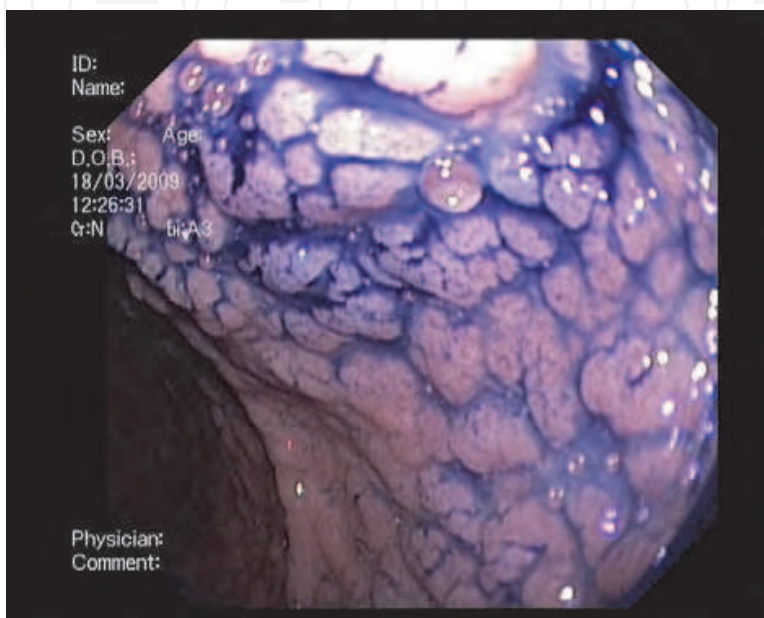


Fig. 35. Cobblestoning appearance becomes more visible after methylene blue application (celiac disease)

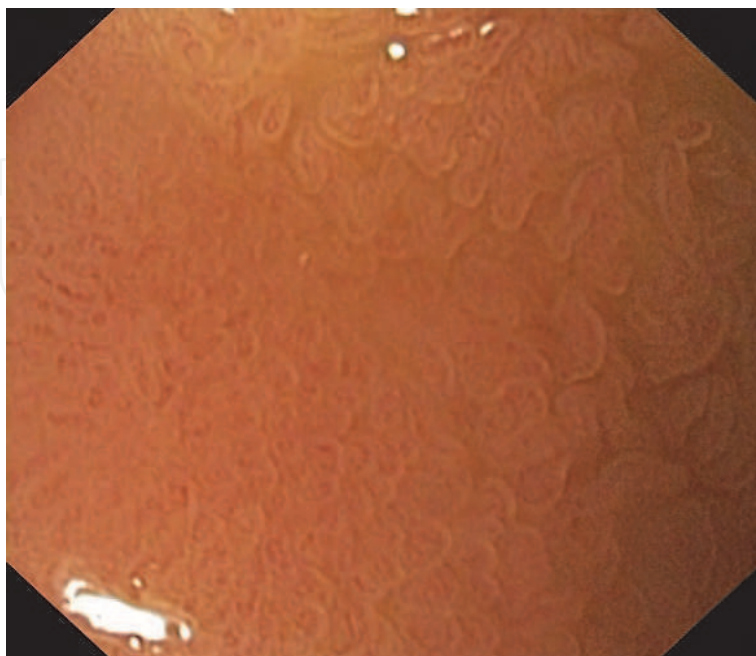


Fig. 36. Patchy atrophy with stunted villi (celiac disease)



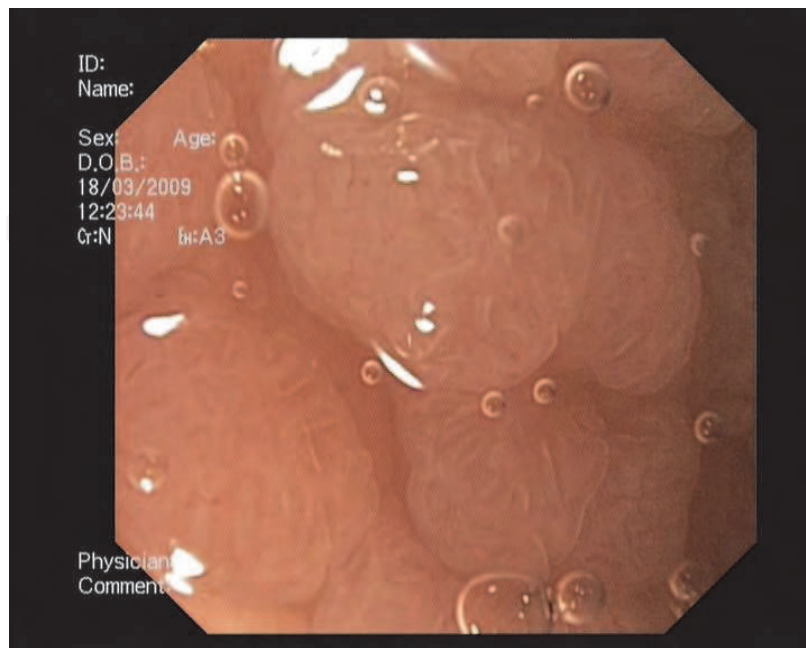


Fig. 37. Detection of foveolar pattern in a patient with celiac disease

#### 4. Challenges and future directions

Magnification chromoendoscopy is a valuable useful tool for the detection and surveillance of inflammatory and neoplastic lesions of the upper gastrointestinal tract. Authors have described major challenges in the use of magnification chromoendoscopy. There are few endoscopists specifically trained in these techniques. There is a lack of standardization in methods and terminologies, as well as an absence of a unified classification of mucosal patterns (Canto, 2005; Sharma, 2005). The procedure requires additional time and the interpretation of different endoscopic images is quite challenging in some situations. Novel endoscopic techniques, with better visualization of mucosal changes, in the future may offer further answers to important questions regarding the risk of the patient and appropriate surveillance strategies. Magnifying endoscopy combined with NBI improve the diagnosis sensitivity of the early cancer by enhancing the visualization of microvascular network. The detection of irregular microvascular pattern and the evaluation of the extent of cancer might relate to optical biopsy (Kaise et al., 2007).

#### 5. Conclusion

Different endoscopic techniques require time and attention from the endoscopist because of the variation in the interpretation of images. Not all patients are appropriate for a magnifying examination. The prior detection of suspicious endoscopic areas by conventional endoscopy, followed by focused magnification and targeted biopsies from areas exhibiting modified patterns, could improve diagnostic accuracy. Later examination of different patterns and images recorded on videotapes, as well as correlation with subsequent histopathological findings, are key steps in learning and interpreting mucosal

changes. The goals of endoscopic magnifying examination in conjunction with chromoscopy for esophageal evaluation are an improvement in detection, particularly the detection of short-segment BE and small islands of metaplastic mucosa, as well as the early detection of malignant transformation with the diagnosis of dysplasia and better surveillance of these patients by targeted biopsies. Risk stratification, based upon the detection of premalignant gastric lesions, could be of value in developing surveillance strategies. Although the method of magnifying endoscopy cannot replace histology-based decision for surveillance, it may help to decide whether follow-up endoscopies should be performed in patients with previously detected dysplasia or in patients with gastric atrophy and intestinal metaplasia, without dysplasia. We consider that intensive surveillance should be focused on patients with extensive gastric atrophy, intestinal metaplasia and in patients with dysplasia. Magnifying endoscopy allows the detection and the evaluation of extension of all of these lesions. Our work is mainly focused on the clinical application of the method in order to achieve standardized terminologies and criteria.

## 6. Acknowledgement

This paper is partly supported by the Sectorial Operational Programme Human Resources Development (SOP HRD), financed from the European Social Fund and by the Romanian Government under the contract number POSDRU 60782

## 7. References

- Anagnostopoulos, G.K.; Yao, K.; Kaye, P.; Fogden, E.; Fortun, P.; Shonde, A.; Foley, S.; Sunil, S.; Atherton, J.J.; Hawkey, C. & Ragnath, K. (2007). High-resolution magnification endoscopy can reliably identify normal gastric mucosa, Helicobacter pylori-associated gastritis, and gastric atrophy. *Endoscopy*, Vol. 39, No.3, (March 2007), pp. 202-207, ISSN 0013-726X
- Areia, M.; Amaro, P.; Dinis-Ribeiro, M.; Cipriano, M.A.; Marinho, C.; Costa-Pereira, A.; Lopes, C.; Moreira-Dias, L.; Romaozinho, J.M.; Gouveia, H.; Freitas, D. & Leitao, M.C. (2008). External validation of a classification for methylene blue magnification chromoendoscopy in premalignant gastric lesions. *Gastrointestinal Endoscopy*, Vol. 67, No.7, (June 2008), pp. 1011-1018, ISSN 0016-5107
- ASGE guideline: the role of endoscopy in the surveillance of premalignant conditions of the upper GI tract. (2006). *Gastrointestinal Endoscopy*, Vol.63, No.4, (April 2006), pp. 570-580, ISSN 0016-5107
- Cammarota, G.; Martino, A.; Pirozzi, G.A.; Cianci, R.; Cremonini, F.; Zuccala, G.; Cuoco, L.; Ojjetti, V.; Montalto, M.; Vecchio, F.M.; Gasbarrini, A. & Gasbarrini, G. (2004). Direct visualization of intestinal villi by high-resolution magnifying upper endoscopy: a validation study. *Gastrointestinal Endoscopy*, Vol.60, No.5, (November 2004), pp. 732-738, ISSN 0016-5107
- Canto, M.I. (2005). Chromoendoscopy and magnifying endoscopy for Barrett's esophagus. *Clinical Gastroenterology and Hepatology*, Vol.3, Suppl.1, (July 2005), S12-S15, ISSN 1542-3565

- Carmack, S.W.; Genta, R.M.; Graham, D.Y. & Lauwers, G.Y. (2009). Management of gastric polyps: a pathology-based guide for gastroenterologists. *Nature reviews Gastroenterology and Hepatology*, Vol.6, No.6, (June 2009), pp. 331-341, ISSN 1759-5045
- Correa, P.; Piazzuelo, M.B. & Wilson, K.T. (2010). Pathology of gastric intestinal metaplasia: clinical implications. *The American Journal of Gastroenterology*, Vol.105, No.3, (March 2010), pp. 493-498, ISSN 0002-9270
- Dinis-Ribeiro, M.; da Costa-Pereira, A.; Lopes, C.; Lara-Santos, L.; Guilherme, M.; Moreira-Dias, L.; Lomba-Viana, H.; Ribeiro, A.; Santos, C.; Soares, J.; Mesquita, N.; Silva, R. & Lomba-Viana, R. (2003). Magnification chromoendoscopy for the diagnosis of gastric intestinal metaplasia and dysplasia. *Gastrointestinal Endoscopy*, Vol.57, No.4, (April 2003), pp. 498-504, ISSN 0016-5107
- Dixon, M.F.; Path, F.R.C.; Genta, R.M.; Yardley, J.H.; Correa, P. & the Participants in the International Workshop on the Histopathology of Gastritis Houston, 1994. (1996). Classification and grading of gastritis: The updated Sidney System. *American Journal of Surgical Pathology*, Vol.20, No. 10, (October 1996), pp.1161-1181, ISSN 0147-5185
- Endo, T.; Awakawa, T.; Takahashi, H.; Arimura, Y.; Itoh, F.; Yamashita, K.; Sasaki, S.; Yamamoto, H.; Tang, X. & Imai, K. (2002). Classification of Barrett's epithelium by magnifying endoscopy. *Gastrointestinal Endoscopy*, Vol. 55, No.6, (May 2002), pp. 641-7, ISSN 0016-5107
- Goda, K.; Tajiri, H.; Ikegami, M.; Urashima, M.; Nakayoshi, T. & Kaise, M. (2007). Usefulness of magnifying endoscopy with narrow band imaging for the detection of specialized intestinal metaplasia in columnar-lined esophagus and Barrett's adenocarcinoma. *Gastrointestinal Endoscopy*, Vol.65, No.1, (January 2007), pp. 36-46, ISSN 0016-5107
- Guelrud, M.; Herrera, I.; Essenfled, H. & Castro, J. (2001). Enhanced magnification endoscopy: a new technique to identify specialized intestinal metaplasia in Barrett's esophagus. *Gastrointestinal Endoscopy*, Vol. 53, No.6, (May 2001), pp. 559-65, ISSN 0016-5107
- Hoffman, A.; Kiesslich, R.; Bender, A.; Neurath, M.F.; Nafe, B.; Herrmann, G. & Jung, M. (2006). Acetic acid-guided biopsies after magnifying endoscopy compared with random biopsies in the detection of Barrett's esophagus: a prospective randomized trial with crossover design. *Gastrointestinal Endoscopy*, Vol. 64, No.1, (July 2006), pp. 1-8, ISSN 0016-5107
- Jones, T.F.; Sharma, P.; Daaboul, B.; Cherian, R.; Mayo, M.; Topalovski, M. & Weston, A.P. (2002). Yield of intestinal metaplasia in patients with suspected short-segment Barrett's esophagus (SSBE) on repeat endoscopy. *Digestive Diseases and Sciences*, Vol.47, No.9, (September 2002), pp. 2108-11, ISSN 0163-2116
- Kaise, M.; Najayoshi, T. & Tajiri H. (2007). Magnifying endoscopy with NBI in the diagnosis of superficial gastric neoplasia and its application for ESD, In: *Comprehensive atlas of high resolution endoscopy and narrowband imaging*, Jonathan Cohen, (Ed.), pp. 83-87, Blackwell Publishing, ISBN 978-1-4051-5886-2, Massachusetts, USA

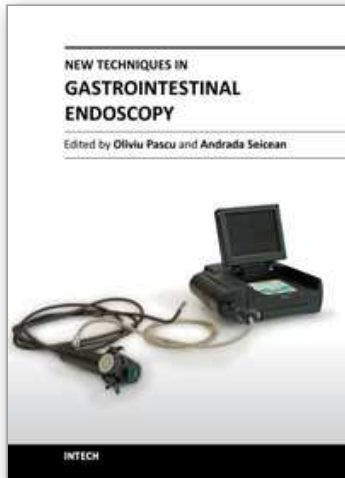
- Kato, M.; Shimizu, Y.; Nakagawa, S.; Yamamoto, J. & Asaka, M. (2005). Usefulness of magnifying endoscopy in upper gastrointestinal tract: history and recent studies. *Digestive Endoscopy*, Vol.17, Suppl., (July 2005), pp. S5-S10, ISSN 1443-1661
- Kerkhof, M.; Steyerberg, E.W.; Kusters, J.G.; Kuipers E.J. & Siersema, P.D. (2007). Predicting presence of intestinal metaplasia and dysplasia in columnar-lined esophagus: a multivariate analysis. *Endoscopy*, Vol.39, No.9, (September 2007), pp. 772-778, ISSN 0013-726X
- Lo, A.; Guelrud, M.; Essenfled, H. & Bonis, P. (2007). Classification of villous atrophy with enhanced magnification endoscopy in patients with celiac disease and tropical sprue. *Gastrointestinal Endoscopy*, Vol.66, No.2, (August 2007), pp. 377-382, ISSN 0016-5107
- Otsuka, Y.; Niwa, Y.; Ohmiya, N.; Ando, N.; Ohashi, A.; Hirooka, Y. & Goto, H. (2004). Usefulness of magnifying endoscopy in the diagnosis of early gastric cancer. *Endoscopy*, Vol.36, No.2, (February 2004), pp. 165-169, ISSN 0013-726X
- Riddell, R.H. & Odze, R.D. (2009). Definition of Barrett's esophagus: Time for a rethink-Is intestinal metaplasia dead? *The American Journal of Gastroenterology*, Vol.104, No. 10, (October 2009), pp. 2588-2594, ISSN 0002-9270
- Sampliner, R.E. (2002). Updated guidelines for the diagnosis, surveillance and therapy of Barrett's esophagus. *The American Journal of Gastroenterology*, Vol.97, No.8, (August 2002), pp. 1888-1895, ISSN 0002-9270
- Sharma, P.; Weston, A.; Topalowski, M.; Cherian, R.; Bhattacharyya, A. & Sampliner, R.E. (2003). Magnification chromoendoscopy for the detection of intestinal metaplasia and dysplasia in Barrett's esophagus. *Gut*, Vol.52, No.1, (January 2003), pp. 24-7, ISSN 0017-5749
- Sharma, P. (2005). Magnification endoscopy. *Gastrointestinal Endoscopy*, Vol.61, No.3, (March 2005), pp. 435-443, ISSN 0016-5107
- Tajiri, H.; Doi, T.; Endo, H.; Nishina, T.; Terao, T.; Hyodo, I.; Matsuda, K. & Yagi, K. (2002). Routine endoscopic using a magnifying endoscope for gastric cancer diagnosis. *Endoscopy*, Vol.34, No.10, (October 2002), pp. 772-777, ISSN 0013-726X
- Whiting, J.L.; Sigurdsson, A.; Rowlands, D.C.; Hallissey M.T. & Fielding J.W.L. (2002). The long term results of endoscopic surveillance of premalignant gastric lesions. *Gut*, Vol. 50, No.3, (March 2002), pp. 378-81, ISSN 0017-5749
- Yagi, K. (2001). Endoscopic features and magnified endoscopic views of corpus in the Helicobacter pylori- negative stomach. *Digestive Endoscopy*, Vol. 13, Suppl., (July 2001), pp. S34-S35, ISSN 1443-1661
- Yagi, K.; Nakamura, A. & Sekine, A. (2002). Magnifying endoscopy of the gastric body: a comparison of the findings before and after eradication of Helicobacter Pylori. *Digestive Endoscopy*, Vol.14, Suppl., (July 2002), pp. S76-S82, ISSN 1443-1661
- Yao, K. & Oishi, T. (2001). Microgastroscopic findings of mucosal microvascular architecture as visualized by magnifying endoscopy. *Digestive Endoscopy*, Vol.13, Suppl., (July 2001), pp. S27-S33, ISSN 1443-1661



Yao, K.; Iwashita, A. & Yao, T. (2004). Early gastric cancer: proposal for a new diagnostic system based on microvascular architecture as visualized by magnified endoscopy. *Digestive Endoscopy*, Vol.16, Suppl., (July 2004), pp. S110-S117, ISSN 1443-1661

IntechOpen

IntechOpen



## **New Techniques in Gastrointestinal Endoscopy**

Edited by Prof. Oliviu Pascu

ISBN 978-953-307-777-2

Hard cover, 310 pages

**Publisher** InTech

**Published online** 30, September, 2011

**Published in print edition** September, 2011

As result of progress, endoscopy has become more complex, using more sophisticated devices and has claimed a special form. In this moment, the gastroenterologist performing endoscopy has to be an expert in macroscopic view of the lesions in the gut, with good skills for using standard endoscopes, with good experience in ultrasound (for performing endoscopic ultrasound), with pathology experience for confocal examination. It is compulsory to get experience and to have patience and attention for the follow-up of thousands of images transmitted during capsule endoscopy or to have knowledge in physics necessary for autofluorescence imaging endoscopy. Therefore, the idea of an endoscopist has changed. Examinations mentioned need a special formation, a superior level of instruction, accessible to those who have already gained enough experience in basic diagnostic endoscopy. This is the reason for what these new issues of endoscopy are presented in this book of New techniques in Gastrointestinal Endoscopy.

### **How to reference**

In order to correctly reference this scholarly work, feel free to copy and paste the following:

Alina Boeriu, Daniela Dobru, Ofelia Pascarenco, Mircea Stoian and Simona Mocan (2011). Magnifying Endoscopy and Chromoendoscopy in Upper Gastrointestinal Tract - Clinical Applications, New Techniques in Gastrointestinal Endoscopy, Prof. Oliviu Pascu (Ed.), ISBN: 978-953-307-777-2, InTech, Available from: <http://www.intechopen.com/books/new-techniques-in-gastrointestinal-endoscopy/magnifying-endoscopy-and-chromoendoscopy-in-upper-gastrointestinal-tract-clinical-applications>

**INTECH**  
open science | open minds

### **InTech Europe**

University Campus STeP Ri  
Slavka Krautzeka 83/A  
51000 Rijeka, Croatia  
Phone: +385 (51) 770 447  
Fax: +385 (51) 686 166  
[www.intechopen.com](http://www.intechopen.com)

### **InTech China**

Unit 405, Office Block, Hotel Equatorial Shanghai  
No.65, Yan An Road (West), Shanghai, 200040, China  
中国上海市延安西路65号上海国际贵都大饭店办公楼405单元  
Phone: +86-21-62489820  
Fax: +86-21-62489821

© 2011 The Author(s). Licensee IntechOpen. This chapter is distributed under the terms of the [Creative Commons Attribution-NonCommercial-ShareAlike-3.0 License](#), which permits use, distribution and reproduction for non-commercial purposes, provided the original is properly cited and derivative works building on this content are distributed under the same license.

IntechOpen

IntechOpen