

We are IntechOpen, the world's leading publisher of Open Access books Built by scientists, for scientists

4,800

Open access books available

122,000

International authors and editors

135M

Downloads

Our authors are among the

154

Countries delivered to

TOP 1%

most cited scientists

12.2%

Contributors from top 500 universities



WEB OF SCIENCE™

Selection of our books indexed in the Book Citation Index
in Web of Science™ Core Collection (BKCI)

Interested in publishing with us?
Contact book.department@intechopen.com

Numbers displayed above are based on latest data collected.

For more information visit www.intechopen.com



Endorectal Ultrasound Scan

Rani Kanthan and Selliah Kanthan
*Dept. of Surgery, Royal University Hospital, Saskatoon,
Canada*

1. Introduction

1.1 Endoscopic ultrasound anatomy of rectum

Assessment of the rectum with endoscopic ultrasound [EUS] has evolved as an excellent tool in the management of malignant as well as benign diseases of the rectum and anus. The endoluminal ultrasound provides accurate evaluation of rectal, perirectal and perianal pathology. Initially, the standard radial endoscopic ultrasound scan was used in the assessment of the rectum as people were familiar with its usage in the management of upper gastrointestinal tract problems. The rigid endoscopic ultrasound scan has been used since the early 80's. Improvements in the instrument as well as high resolution of the ultrasonic waves have resulted in very significantly improved image quality and accurate interpretation of this particular examination. Color Doppler as well as 3D imaging has also added some benefits to this modality. The EUS has now become an excellent tool in the preoperative staging of low rectal cancer compared to CT scan and/or MRI. The rigid probe is 20cm in length, has the rotating transducer at the tip covered by a balloon filled with water. There are different types of linear as well as radial scanning devices available in the market and the frequencies vary from 3.5 MHz to 15MHz. EUS is portable, cost effective and can be completed in a short time with minimal discomfort to the patient. Most of the patients can have it done without any sedation and the recovery time is very short.

1.2 Examination technique

Patients are often given full bowel prep or Fleet enemas to clean the rectum. This is quite important as fecal material can interfere with the interpretation of the test. Sedation is optional. The examination is often preceded by a digital rectal exam to evaluate the size, fixation, location and morphology of the rectal lesion. In most instances a large bore proctoscope is used as it allows visual examination of the rectum and facilitates suctioning any residual stools or enema fluid that can interfere with the ultrasound acoustic waves leading to distorted images. Patients are usually placed on left lateral position and then the rigid scope is passed up to 20cm.

The probe with lower frequency gives better details of the depth of the tumour whereas the probe with the higher frequency gives better details of the bowel wall. One may choose the appropriate probe depending on the clinical situation. The balloon is then inflated with water and the normal anatomy is identified. The probe is then withdrawn slowly looking for perirectal lymph nodes as well as the lesion. Detailed examination of the lesion is carried out by placing the probe on top of the lesion. If the probe cannot be passed beyond the lesion in the rectum, the examination can be quite difficult.

1.3 EUS anatomy of the rectum

The rectal wall appears as concentric layers of rings on the endoscopic ultrasound images. Some adjustment has to be made to the ultrasound scan unit to provide optimal imaging. Vary rarely one can perfectly show all the 5 layers of the rectum circumferentially. Usually, only a portion of the bowel wall is displayed clearly. However, in the newer machines changing the zoom facilities enables one to have a global view of the entire rectal wall. This is usually accompanied by images with much less clarity; yet when one zooms it to one portion of the rectal wall, the clarity becomes much more apparent. This is however then limited to partial visualization of the rectal wall.

The rectal wall appears as concentric rings of echo-dense followed by echo-poor layers. The first three layers correspond to the mucosa and submucosa, the fourth layer corresponds to the muscularis propria and the fifth layer corresponds to the perirectal fat.

The inner white line represents the interface between the balloon and the mucosa. The inner dark or high poor echo ring signifies the mucosa and muscularis mucosa. The submucosa is represented by the middle white layer. The outer black ring is muscularis propria and the outer white line represents the interface between the perirectal fat. [Figure1a,1b]. Interpretation of changes in these layers is clinically significant. For example in the evaluation of rectal neoplasms, the relationship of the tumour to each layer is an important determinant in the staging of rectal cancer.

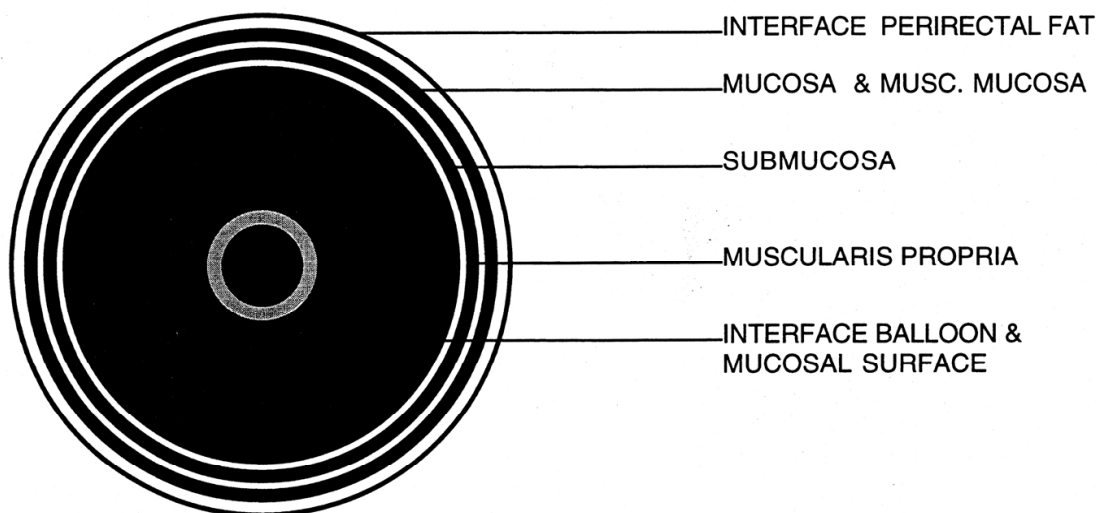


Fig. 1. (A) The normal rectal anatomy is visualized as dark hyperechoic and light hypoechoic regions

The perirectal tissue shows different echogenicity. The blood vessels show up as circular echo-poor areas which may be difficult to differentiate from the lymph nodes. However, the blood vessels have a tendency to run either longitudinally or circumferentially which is a helpful hint to differentiate between the lymph nodes and the blood vessels. The hypoechoic areas also branch and elongate in longitudinal fashion confirming the presence of a blood vessel rather than a node. Normal size lymph nodes are generally not visualized on routine ultrasound scan examination. There are established guidelines to identify lymph nodes in

the perirectal tissue. In a male patient, the prostate and the seminal vesicles are easily detectable on ultrasound scan examination.

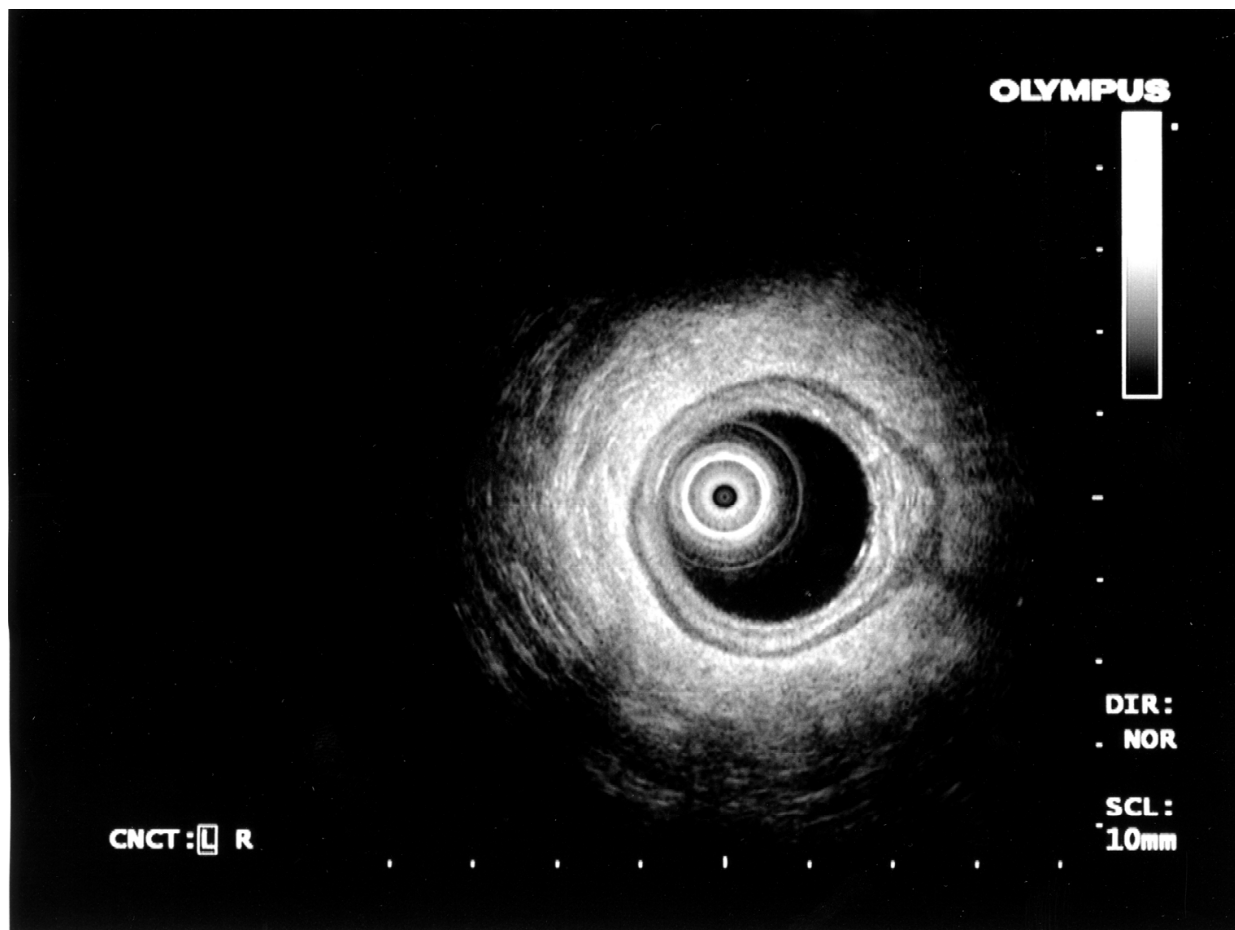


Fig. 1. (B) Endorectal ultrasonographic images of the normal rectal anatomy

The normal anal canal is nicely demonstrated by endo anal ultrasonography. The internal anal sphincter and external anal sphincters are better defined in the mid-low anal canal. In the distal anal canal, the internal sphincter is not visualized and the external sphincter is seen as a mixed echogenic structure on ultrasound scanning.

2. Indications for using EUS in the rectum

The most common use of EUS is for staging of rectal cancer. This will help in deciding whether a patient should undergo preoperative chemoradiation or whether surgery alone would be sufficient to treat an early cancer. The use of EUS to determine very early invasion in a villous polyp has limited usage. In this context, EUS can assess suitability for transanal excision. Retrorectal masses though rare can also be visualized and assessed. EUS can also be used in the diagnosis and management of submucosal lesions such as submucosal lipoma, carcinoid tumour and occasionally in gastro intestinal tumours [GIST] as well. For this purpose a 12 MHz probe is more useful than the 7.5 MHz probe. The higher frequency allows a more detailed examination of the bowel wall where as the lower frequency allows us to examine more in depth than the high frequency. However, for the detection of lymph node metastases, a 7.5MHz might serve better than a 12.5 MHz probe. It is also a necessity to

have a fluid interspace between the transducer and the bowel wall to get accurate pictures. For cancer staging the relationship of the tumor to the 4th echo-poor layer has particular significance as this would determine whether a lesion is UT2] or UT3 [Ultrasound T stage which in turn will determine the sequence of therapy for the patient.

3. Preoperative staging for rectal carcinoma

The depth of invasion, T [Tumour] stage of the rectal cancer can be assessed by EUS with 90-95% accuracy. However, the N [Node] staging is more difficult and the specificity and sensitivity of EUS staging of lymph nodes is only up to 65-70%.

UT1 tumour specifies a tumour mass invading the first 3 innermost layers shown previously.

UT2 carcinoma extends into the muscularis propria which is the 4th layer which is echo-poor. However, this does not breach this layer and extend beyond this.

UT3 carcinoma corresponds to the infiltration into the pericolic fat or the perirectal tissue with an irregular outer margin.

UT4 lesion involves the adjacent structures such as uterus, vagina, seminal vesicles, prostate and/or bladder.

In practice, a tumour tends to get overstaged on endoscopic ultrasound scan rather than under staged. This is partially because of peri-tumor inflammation which may mimic invasion on ultrasonographic examination.

EUS has limitations in rectal carcinoma staging. Limitations that preclude optimal imaging include faeces in the rectum, stenotic lesion and an extremely mobile lesion that moves with the ultrasound probe and deters adequate examination.

Lymph node metastasis is an independent prognostic variable in colorectal cancer. Metastatic lymph nodes can also be visualized on EUS. Detection of lymph nodes is much more difficult. Lymph nodes have to be separated from blood vessels. During the active scanning it is relatively easy to separate a blood vessel from a lymph node usually. Detailed examination of the lymph node is also a necessity to determine the likely hood of its involvement with cancer. A lymph node that is more than 2cm with irregular margins and no hilar fat is much more likely to be involved with a tumour deposit than smaller lymph nodes. A size criterion is most commonly accepted determinant in the evaluation of lymph nodes. The shape of the lymph node, demarcation and echogenicity are soft criteria and somewhat less well defined. The difference between a metastatic and an inflammatory lymph node can be extremely difficult especially when the lymph nodes are small. In summary, there is no agreed consensus to the EUS guidelines that should be used in determining whether a lymph node is involved with carcinoma or not. In this context, though targeted Ultrasound guided transrectal biopsy of these lymph nodes have been described; it has not gained popularity for widespread clinical use.

Preoperative EUS therefore helps to direct choice of therapy for rectal cancer such as planning for neo adjuvant therapies in combination with less extensive surgeries. It thereby improves the quality control of the various treatment modalities available.

EUS for restaging following neo adjuvant chemotherapy has not gained popularity due to its relative inaccuracy reflected by the poor concordance with pathological staging. This is largely attributed to the post radiation induced oedema and fibrosis that distort ultrasonic images.

4. Post-operative follow-up of rectal cancer

One of the major problems of rectal cancer surgery is the local recurrence. Even though endoscopic evaluation is used as the main method for early detection of asymptomatic recurrences at the anastomotic site it is important to recall that the majority of recurrences commonly occur in an extra luminal area which is closely correlated to suboptimal total mesorectal excision [TME] techniques at the time of primary surgery. In summary, though EUS is a useful tool in the evaluation of early anastomotic recurrences it is of limited use in the evaluation of extra luminal recurrences.

5. The use of EUS in anal canal

The use of endoluminal ultrasonographic probes in the anal canal is limited in comparison to its widespread usage in rectal lesions. The procedure is similar to that employed for imaging the rectum. However, a plastic cap is used instead of the balloon to cover the probe.

The anal ultrasonic image differs from the rectal image in having only four layers.

1. Hyper echoic inner ring
2. Hypo echoic -internal anal sphincter
3. Hyper echoic-/ hypoechoic outer ring longitudinal muscle/external anal sphincter and
4. Mixed pattern- ischiorectal fat.

The T staging for anal cancers refers to the size of the tumour as opposed to the depth of infiltration in rectal cancers. Therefore endoanal imaging has limited value in the preoperative staging as the anus is easily accessible for determining the size of the lesion.

EUS can be used for sphincter assessment. EUS complements manometric testing in this regard. EUS can define the precise locations, thickness of the internal and external sphincters and to detect muscular defects especially in the investigations of patients with fecal incontinence or in women with anal problems following childbirth. .

EUS is helpful in the evaluation and treatment of select perianal inflammatory conditions. The use of EUS is however not widespread in the management of uncomplicated perianal sepsis or perianal fistula. However, in the case of complex fistulas, EUS has been used to evaluate the extent of the fistulous tract, the location of the internal opening, as well as any residual undrained fluid collections and assess the state of the sphincters. Many of these patients have often had multiple previous surgeries, resulting in quite distorted anatomy; therefore accurate assessment of the sphincter mechanism can be quite difficult. In comparison, detection of undrained fluid collections or abscess locations is identified on EUS relatively easily as hypoechoic areas. Additionally image enhancing techniques to improve the detection of fistulous tract as well as visualization of the internal opening include injecting the tract with hydrogen peroxide. In summary endoanal ultrasound has limited clinical value in anal tumours yet is easy to use and remains a safe, inexpensive means to assess the anus in inflammatory disease.

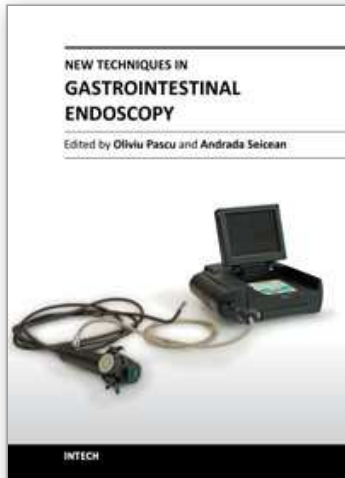
6. Conclusion

In conclusion endoluminal ultrasonography is easily performed and is an extremely useful modality of investigation for evaluation and staging of anorectal lesions. It is a simple inexpensive outpatient procedure that can be accomplished with minimal sedation. EUS offers good staging accuracy in rectal tumours with T [tumour depth] and N [nodal] staging. This directs management pathways by facilitating the selection of stage-dependent

treatment options including preoperative chemo radiation therapy. Such preoperative staging of malignancies can help to decrease extensive colorectal surgery thereby improving the quality of life without any sacrifice to the oncological principles of disease management and control. In current practice EUS is an established valuable staging method for rectal cancers that is superior to digital examination and CT scan with impact on treatment selection for radical extirpation or trans anal local excision. In contrast, the role of EUS in restaging anorectal malignancies post chemo radiation therapy is less clear as accuracy is impaired due to therapy related oedema, inflammation and fibrosis. Similar problems are encountered in restaging extramural recurrences or recurrent lymphadenopathy. However, if a definite mass or recurrent lymphadenopathy is identified complementary testing with a Fine Needle Aspiration Biopsy may improve accuracy of the assessment of disease recurrence.

7. References

- [1] Wong WD. Selecting Appropriate Therapy for Rectal Cancer in Problems in General Surgery. J.B. Lippincott Company, Philadelphia, publishers. 1992;9(4):641-654.
- [2] Wong WD, Orrom WJ, Jensen LL. Preoperative staging of rectal cancer with endorectal ultrasonography in Schrock TR (ed). Perspectives in Colon and Rectal Surgery. Quality Medical Publishing, St. Louise, publishers. 1990;315.
- [3] Orrom WJ, Wong WD, Rotheberger DA, Jensen LL, Goldberg SM. Endorectal ultrasound in the preoperative staging of rectal tumors. Disease of Colon Rectum 1990;33:654.
- [4] Nicholls RJ, Mason AY, Morson BC, et al. The clinical staging of rectal cancer. Br J Surg 69:404-409;1982.
- [5] Grabbe E, Lierse W, Winkler R. The perirectal fascia: Morphology and use in staging of rectal carcinoma. Radiology 149:241-246;1983.
- [6] Beynon J, Roe AM, Foy DMA, et al. Preoperative staging of local invasion in rectal cancer using endoluminal ultrasound. J R Soc Med 80:23-24;1987.
- [7] Hinder JM, Chu J, Bokey EL, et al. Use of transrectal ultrasound to evaluation direct tumor spread and lymph node status in patients with rectal cancer. Aust N Z J Surg 60:19-23;1990.
- [8] Neoadjuvant therapy in rectal cancer. Fleming FJ, Pahlman L, Monson JR. Dis Colon Rectum. 2011 Jul;54(7):901-12.
- [9] Determining the need for radical surgery in patient with T1 rectal cancer. Salinas HM, Dursun A, Klos CL, Shellito P, Sylla P, Berger D, Bordeianou L. Arch Surg. 2011 May;146(5):540-3.
- [10] Linear array ultrasonography to stage rectal neoplasias suitable for local treatment. Ravizza D, Tamayo D, Fiori G, Trovato C, De Roberto G, de Leone A, Crosta C. Dig Liver Dis. 2011 Aug;43(8):636-41. Epub 2011 May 7.
- [11] Surgical approach to the locoregional recurrence of cancer of the rectum. Lizarazu A, Enriquez-Navascues JM, Placer C, Carrillo A, Sainz-Lete A, Elosegui JL. Cir Esp. 2011 May;89(5):269-74. Epub 2011 Mar 22. Spanish.
- [12] Endorectal ultrasound and magnetic resonance imaging (MRI) scan in rectal cancer: a comparative study. Balena V, Martino D, Lorusso F, Martino T, Valerio P. Arch Ital Urol Anrol. 2010 Dec;82(4):259-61.
- [13] Endorectal ultrasound in rectal carcinoma – do the literature results really correspond to the realities of routine clinical care? Marusch F, Ptok H, Sahm M, Schmidt U, Ridwelski K, Gastinger I, Lippert H. Endoscopy. 2011 May;43(5):425-31. Epub 2011 Jan 13.



New Techniques in Gastrointestinal Endoscopy

Edited by Prof. Oliviu Pascu

ISBN 978-953-307-777-2

Hard cover, 310 pages

Publisher InTech

Published online 30, September, 2011

Published in print edition September, 2011

As result of progress, endoscopy has become more complex, using more sophisticated devices and has claimed a special form. In this moment, the gastroenterologist performing endoscopy has to be an expert in macroscopic view of the lesions in the gut, with good skills for using standard endoscopes, with good experience in ultrasound (for performing endoscopic ultrasound), with pathology experience for confocal examination. It is compulsory to get experience and to have patience and attention for the follow-up of thousands of images transmitted during capsule endoscopy or to have knowledge in physics necessary for autofluorescence imaging endoscopy. Therefore, the idea of an endoscopist has changed. Examinations mentioned need a special formation, a superior level of instruction, accessible to those who have already gained enough experience in basic diagnostic endoscopy. This is the reason for what these new issues of endoscopy are presented in this book of New techniques in Gastrointestinal Endoscopy.

How to reference

In order to correctly reference this scholarly work, feel free to copy and paste the following:

Rani Kanthan and Selliah Kanthan (2011). Endorectal Ultrasound Scan, New Techniques in Gastrointestinal Endoscopy, Prof. Oliviu Pascu (Ed.), ISBN: 978-953-307-777-2, InTech, Available from:
<http://www.intechopen.com/books/new-techniques-in-gastrointestinal-endoscopy/endorectal-ultrasound-scan>

INTECH
open science | open minds

InTech Europe

University Campus STeP Ri
Slavka Krautzeka 83/A
51000 Rijeka, Croatia
Phone: +385 (51) 770 447
Fax: +385 (51) 686 166
www.intechopen.com

InTech China

Unit 405, Office Block, Hotel Equatorial Shanghai
No.65, Yan An Road (West), Shanghai, 200040, China
中国上海市延安西路65号上海国际贵都大饭店办公楼405单元
Phone: +86-21-62489820
Fax: +86-21-62489821

© 2011 The Author(s). Licensee IntechOpen. This chapter is distributed under the terms of the [Creative Commons Attribution-NonCommercial-ShareAlike-3.0 License](#), which permits use, distribution and reproduction for non-commercial purposes, provided the original is properly cited and derivative works building on this content are distributed under the same license.

IntechOpen

IntechOpen