

We are IntechOpen, the world's leading publisher of Open Access books Built by scientists, for scientists

4,800

Open access books available

122,000

International authors and editors

135M

Downloads

Our authors are among the

154

Countries delivered to

TOP 1%

most cited scientists

12.2%

Contributors from top 500 universities



WEB OF SCIENCE™

Selection of our books indexed in the Book Citation Index
in Web of Science™ Core Collection (BKCI)

Interested in publishing with us?
Contact book.department@intechopen.com

Numbers displayed above are based on latest data collected.

For more information visit www.intechopen.com



Laparoscopy for the Undescended Testes

Nerli R. B., Reddy M. N. and Hiremath M.B.

*Dept of Urology, KLES Kidney Foundation, KLE University's JN Medical College
Belgaum, Karnataka
India*

1. Introduction

Cryptorchidism is a term that has been used interchangeably with the term undescended testis. Both terms refer to an abnormally positioned testis, but cryptorchidism literally means "hidden testis". Isolated cryptorchidism is one of the most common congenital anomalies found at birth and affects upward of 3% of full-term male newborns¹⁻³. Unilateral cryptorchidism is more common than bilateral cryptorchidism, which occurs in 1.6% to 1.9% of boys. Testicular descent into scrotum is usually complete by the second trimester; however a significantly higher rate of cryptorchidism in premature boys suggests that the process of descent may not be complete until close to term. The cause of cryptorchidism is multifactorial. An undescended testis can be located anywhere between the abdominal cavity and just outside the anatomic scrotum. Approximately 70% to 77% of cryptorchid testes will spontaneously descend, usually by 3 months of age³. Factors that predict complete spontaneous descent by 3 months of age include low birth weight, bilateral cryptorchidism, normal scrotal anatomy and testis that are positioned lower along the normal path of descent; boys with a small or poorly rugated scrotum and those with hypospadias are more likely to be cryptorchid at 3 months². By 1 year of age, the incidence of cryptorchidism declines to about 1% and remains constant throughout adulthood.

Normal germ cell development during childhood is a continuous process that is completed at puberty⁴. Undescended testes demonstrate more pronounced impairment in germ cell development the higher the testes are located, although newborns with intrabdominal testes have a normal number of germ cells⁴. The histopathologic hallmarks associated with cryptorchidism are evident between 1 and 2 years of age and include decreased numbers of leydig cells, degeneration of sertoli cells, delayed disappearance of gonocytes, delayed appearance of adult dark (Ad) spermatogonia, failure of primary spermatocytes to develop, and reduced total germ cell counts⁵⁻⁷. A decrease in cryptorchid testes volume by 6 months of age has been reported⁸. Similar pathology has been observed in the contralateral descended testis, though to a lesser extent, which supports the theory of hypogonadotropic hypogonadism as the possible cause of the decreased fertility seen in males with unilateral cryptorchidism^{6, 9}. Histopathologic studies in younger cohorts of patients have provided evidence of abnormal germ cell maturation correlating with spermiograms in adulthood. Biopsy findings from children with unilateral cryptorchidism typically demonstrate reduced total germ cell counts as a result of failure of the two prepubertal steps involved in maturation and proliferation of germ cells: 1) transformation of the fetal stem cell pool (gonocytes) into adult stem cell pool (Ad spermatogonia) at 2 to 3 months of age and 2) transformation of Ad spermatogonia into primary spermatocytes (meiosis) at 4 to 5 years¹⁰.

When specific stage of germ cell maturation was examined, transformation of gonocytes into Ad spermatogonia between 2 and 3 months of age appeared to be critical for male fertility, not the total number of germ cells. Lee ¹¹ postulated that paternity would be a better index for verification than the sperm count because it is known that men with subnormal sperm counts can have normal paternity rates. When compared with a control group, paternity was significantly compromised in men with previous bilateral, but not unilateral cryptorchidism (53% versus 75%, respectively) ¹².

It is a well established fact that children born with undescended testes are at increased risk for testicular malignancy. Approximately 10% of testicular tumors arise from an undescended testis ¹³. The incidence of a testicular tumor in the general population is 1 in 100,000 , and the incidence of a germ cell tumor in men formally cryptorchid is 1 in 2550 ; therefore , the relative risk is approximately 40 times greater ¹³. It is controversial whether orchiopexy affects the natural history of development of a testicular tumor, although emerging evidence supports the claim that prepubescent orchiopexy may lessen the risk. Moller and associates ¹⁴ reported on a large cohort of men in Denmark and found the relative risk for testicular cancer in men with treated or persisting cryptorchidism to be 3.6 (95% confidence interval (CI), 1.8 to 6.9) , but no increase in risk was observed in men who reported a history of undescended testes that underwent spontaneous descent . Studies provide evidence to support the contention that early orchidopexy may protect against the development of malignancy.

2. Management of cryptorchidism

Definitive treatment of an undescended testis should take place between 6 and 12 months of age. Spontaneous descent occurs by 3 months of age in most boys. Early intervention should be considered in order to theoretically prevent the complications of cryptorchidism that may be manifested before 1 year of age. Every effort should be made to preserve any testicular tissue at an early age, especially in children with unilateral or bilateral intra-abdominal testes. This recommendation is based on the poor paternity rates in men with a history of bilateral cryptorchidism. Orchiectomy is typically reserved for postpubescent males with a contralateral normally descended testis when the cryptorchid testis is either anatomically or morphologically abnormal or too far from scrotum to allow for tension free placement without compromising the vascular integrity of the testis.

Laparoscopy has achieved its greatest degree of general acceptance, both diagnostically and therapeutically, in the realm of pediatric urology for the management of a nonpalpable testis. Several thousand cases in the literature have documented the impact of laparoscopy in the management of a nonpalpable testis, over a quarter of century. Clear advantages of laparoscopy with regard to specificity and sensitivity have been shown compared to ultrasonography and magnetic resonance imaging in detecting intra-abdominal testes. The principles of surgery for a nonpalpable testis are equal to, if not enhanced by a laparoscopic approach; exposure, lighting and magnification remain critical to this pediatric procedure. The advantages of laparoscopy over conventional open surgical approach to a nonpalpable testis include accurate anatomic assessment of testicular position and viability and, when necessary, optimal accessibility to the crux of the surgical problem ¹⁵.

3. Indications for laparoscopy

- All cases of nonpalpable testes: integrated concept of diagnostic laparoscopy combined with open surgery (revision of inguinal canal, with or without orchiopexy) or combined

with therapeutic laparoscopy (staged orchiopexy or orchiectomy for intra-abdominal testes).

- Suspected intersex (laparoscopy for diagnosis, eventually biopsy and/or orchiectomy).
- Several limitations can be associated with laparoscopy especially in children as smaller body size implies smaller space tolerances of the abdominal wall, which makes standard trocar placement more dangerous. Looser attachments of the peritoneum to the extraperitoneal structures in children makes trocar placement more difficult. Use of a dull trocar is a potentially dangerous instrument in children. Acute infectious disease, coagulopathy and prior abdominal surgery with suspected adhesions form contraindications for a laparoscopic procedure.

Instruments for laparoscopic procedures should include a video cart with insufflators, light source, video camera, video monitor, video recorder and electrocautery unit. In smaller children it is preferable to use mini-laparoscope (1.9 mm) with 2.7 mm trocar shaft, and for older children 3.5 or 5 mm laparoscopes. 3.5 mm trocars and laparoscopic forceps/graspers/scissors are used in smaller children, whereas 5 mm trocars and instruments are used in older children. 5 mm or 10 mm clipping instruments may also be necessary.

4. Diagnostic laparoscopy for a nonpalpable testis

A nonpalpable testis accounts for approximately one fifth of children with an undescended testis. Diagnostic laparoscopy has been commonly used for the assessment of a nonpalpable testis, with the accuracy of testicular localization reported to be greater than 95%^{16, 17}. Radiologic imaging studies carried out to identify a nonpalpable testis, carry unacceptable false-negative and false-positive rates^{18, 19}. Elder²⁰ reported that inguinal ultrasound, rarely localises a true nonpalpable testis and in only 18% of cases correctly identified testes located in the inguinal canal. Magnetic resonance imaging has been shown to be an effective method of detection in 37% of cases²¹. Radiographic imaging is also not adequately sensitive enough to determine the quality of the testis when compared with direct visualization. This includes assessing whether the testis is dysmorphic or hypoplastic or whether epididymal or vassal non-union anomalies coexist that would ultimately have an impact on the type of surgical procedure performed. Whatever be the technique used, radiographic or surgical, it must be highly accurate because the fate of a missed intra-abdominal testis is potentially serious with respect to preserving testicular function and can be catastrophic because of the risk of malignancy. Diagnostic laparoscopy has also been shown to be useful in the management of a previous inconclusive open exploration for a nonpalpable testis^{22, 23}.

5. Technique

The technique of diagnostic laparoscopy begins with patient in supine and 10° head down position. A bladder catheter is placed and if need arises a nasogastric tube is also inserted. Access is gained either with a modified veress needle technique where the rectus fascia is identified and incised prior to needle introduction, or via the open technique. The open technique involves a semilunar supraumbilical or an infraumbilical incision carried down to the rectus fascia. The rectus fascia is opened and the preperitoneal fat is spread enough to expose the peritoneum. The peritoneum is grasped and brought up to the incision. The peritoneal layer is opened sharply and the trocar placed usually between the obliterated

umbilical arteries. This open (Hasson technique) method lessens the risk of inadvertent trauma to the intra-abdominal structures, as well as extraperitoneal insufflation. Pneumoperitoneum is created with CO₂ at a flow rate between 8 and 10 L/min with a pressure limit of 8 to 10 mm Hg. A 2-0 absorbable U stitch is placed in the rectus fascia to help maintain the pneumoperitoneum and facilitate quick closure, especially if the fasciotomy has been generous. The anaesthesiologist is requested not to use NO₂ during induction or any portion of the procedure to avoid bowel distension.

The pediatric laparoscope is introduced to view the intraperitoneal pelvic anatomy. The various anatomical landmarks are identified which include the bladder and the urachal ligament, lateral umbilical ligaments, inferior epigastric vessels, internal ring, vas deferens and spermatic vessels. Examining the side opposite the pathology is useful for comparing normal anatomy, especially in the case of a vanishing testis, so that the degree of atresia can be directly measured.

There are three distinct possibilities and courses of action that can arise when diagnostic laparoscopy is used to assess a nonpalpable testis.

1. All spermatic cord structures are present and enter into the inguinal canal (viable intracanalicular testis or an intracanalicular or scrotal atrophic testis)
2. Spermatic vessels and vas deferens can be identified. They end blindly on the psoas muscle without any detectable testis (vanishing testis, anorchia)
3. Intra-abdominal testis present with or without open inguinal canal

Examination of the contralateral testis has been helpful in predicting the fate of the nonpalpable testis; however, it is not a reliable method of definitely determining testicular presence or absence. Hypertrophy of a normally descended testis may connote monorchia. A dysgenetic or hypoplastic testis will not usually result in contralateral testicular hypertrophy, defined as a testis greater than 2 ml or testicular length greater than 2 cm. A contralateral testis length of 2.0 cm or greater predicted monorchia in over 90% of cases²⁴⁻²⁶. Approximately 34% to 64% of children with a nonpalpable testis will be monorchid²⁷. An intra-abdominal vanishing testis will demonstrate the classic anatomy of a blind ending vas and spermatic vessels, usually within a few centimetres of the internal ring. No testicular tissue will be present. When blind ending spermatic vessels are found, no further surgical intervention is necessary, although considerations should be given to performing a trans-scrotal testicular fixation procedure on the normally descended contralateral testis because of the reported risk for abnormal testicular fixation²⁸.

When the spermatic vessels and the vas are seen exiting the internal ring, including those that are comparatively hypoplastic, one must consider viable testicular tissue within the caudal extent of the descent. An inguino-scrotal exploration must be performed and the cord remnant excised. Even though most testicular remnants or nubbins demonstrate histologic evidence of ischemia and necrosis, in up to 13% of cases viable residual testicular elements will be present^{29,30}.

An intra-abdominal testis usually is seen within a few centimetres of the internal ring. In most of these cases, the processus vaginalis is patent and the vas deferens is seen exiting into the inguinal canal (long looping vas deferens). Occasionally an intra-abdominal testis can be much further from the internal ring and has been reported though rarely, in the perinephric, perihepatic or crossed ectopic sites. The vas deferens can demonstrate non-union with any cryptorchid testis and therefore, when blindly ending, is not confirmative of a vanishing testis³⁰. The entire abdomen should be inspected at the time of diagnostic laparoscopy. Inspection of the ipsilateral internal ring during diagnostic laparoscopy is important because

in 91% of boys with a patent processus vaginalis the testis will be viable whereas if the processus vaginalis is closed 97% of the testes will be vanished or absent³¹.

6. Open inguinal versus laparoscopic exploration for a nonpalpable testis

The choice of traditional open surgical exploration versus primary laparoscopy for assessment of a nonpalpable testis is a matter of debate. Open surgical exploration via an inguinal incision was the procedure most commonly used before the introduction of laparoscopy in the management of a nonpalpable testis. The arguments exist that inguinal-scrotal exploration is nonetheless necessary to evaluate the cord and gonadal structures exiting the internal ring, and thus laparoscopy may have been avoided altogether³². Kanemoto et al³³ combined inguinal exploration and transinguinal laparoscopy to test this strategy as an alternative. They found that an extended incision was unnecessary in the case of a blind ending vas and vessels in the peritoneum because this could be easily assessed with transinguinal laparoscopy. Laparoscopy was avoided in 73.3% of cases altogether because the testis, its remnant or testicular vessels, and the vas deferens were detected by inspecting the inguinal region. Ravasse et al³⁴ felt that laparoscopy was critical to a change in management in only 23% of patients. Several other reports have appeared, wherein utility was found in at-least 50% of patients when diagnostic laparoscopy was performed as the primary approach to a nonpalpable testis. Cisek et al²⁷ reported that in 66% of their patients benefitted from a primary laparoscopic diagnosis and treatment strategy that would have otherwise resulted in compromised exposure via an inguinal exploration. Laparoscopy, whether primary or adjunctive to an open exploration, offers a logical extension of surgical principles, especially if conversion to a therapeutic laparoscopic procedure is anticipated.

7. Laparoscopic orchidopexy

One of the first indications for laparoscopy in pediatric urology was a nonpalpable testis, reported more than 30 years ago³⁵. Originally this procedure was only for diagnostic purposes. As laparoscopy became more and more feasible in pediatric patients, the procedure has progressed to complete laparoscopic orchidopexy in the intervening time. Laparoscopic orchidopexy is now standard in the management of an intra-abdominal undescended testis. A laparoscopic approach has advantages over standard open orchidopexy, in that it accurately assesses the presence, absence, viability and entire anatomy of an intra-abdominal testis. Laparoscopic orchidopexy allows accessibility to the entire course of the spermatic vessels to their origin, usually the limiting factor in tension-free mobilization of an intra-abdominal testis. Dissection close to the origin of the spermatic vessels is possible because the surgeon's range of motion with laparoscopic instrumentation extends across the entire abdominal cavity. Magnification of these delicate vessels aids in dissection and preservation of the main and collateral blood supply.

Technique : The age at which laparoscopic orchidopexy should be performed is the same as for standard open orchidopexy, usually between 6 and 8 months and certainly before 1 year of age. The surgical procedure for a boy with a nonpalpable testis begins with examination under anaesthesia. In approximately 18% of boys a previously nonpalpable testis will be palpable²⁷. An 8 Fr catheter or infant feeding tube is placed per urethra to drain the bladder before and during the entire procedure. Diagnostic laparoscopy is performed initially. We prefer a modified open technique for placement of the first trocar in a child so as to reduce

the inherent complications associated with blind placement of a Veress needle, such as extraperitoneal emphysema or bowel injury. A semilunar incision is made within the umbilical groove and carried down to the rectus fascia. The fascia is grasped with 2-0 absorbable sutures and then incised in the midline until the peritoneum is visualized. The Veress needle is then introduced and radially dilated to allow a 5 mm port. This modified open technique allows a tight seal and minimizes loss of insufflation during the procedure. An intra-abdominal testes is usually found within 1 to 2 cm of the internal ring, which is usually patent (Figure 1). Once it has been decided to proceed with laparoscopic orchidopexy, two more 3 or 5 mm ports are placed under direct vision. As to where these ports should be placed, it is the surgeon's preference so as to achieve the greatest degree of instrument freedom and avoid crossing instruments during dissection (Figure 2). Attention to the distal paratesticular elements is necessary to determine whether the vas deferens exits beyond the internal ring into the inguinal canal as in a looping vas. The first element of testicular mobilization is drawing the gubernaculum attachment from the internal ring/inguinal canal, transecting it, and using it as a grasping point for safe testicular manipulation (Figure 3). The retroperitoneum is incised with a minimal 1 cm margin laterally to the testicle and medially alongside the vas deferens. The peritoneum is mobilized carefully across the spermatic vessels. All vessels around the vas deferens and the peritoneal plane between vas and vessels is left intact. Electrocautery is avoided as far as possible. The testis is carefully mobilized from the psoas fascia towards the inguinal ring.

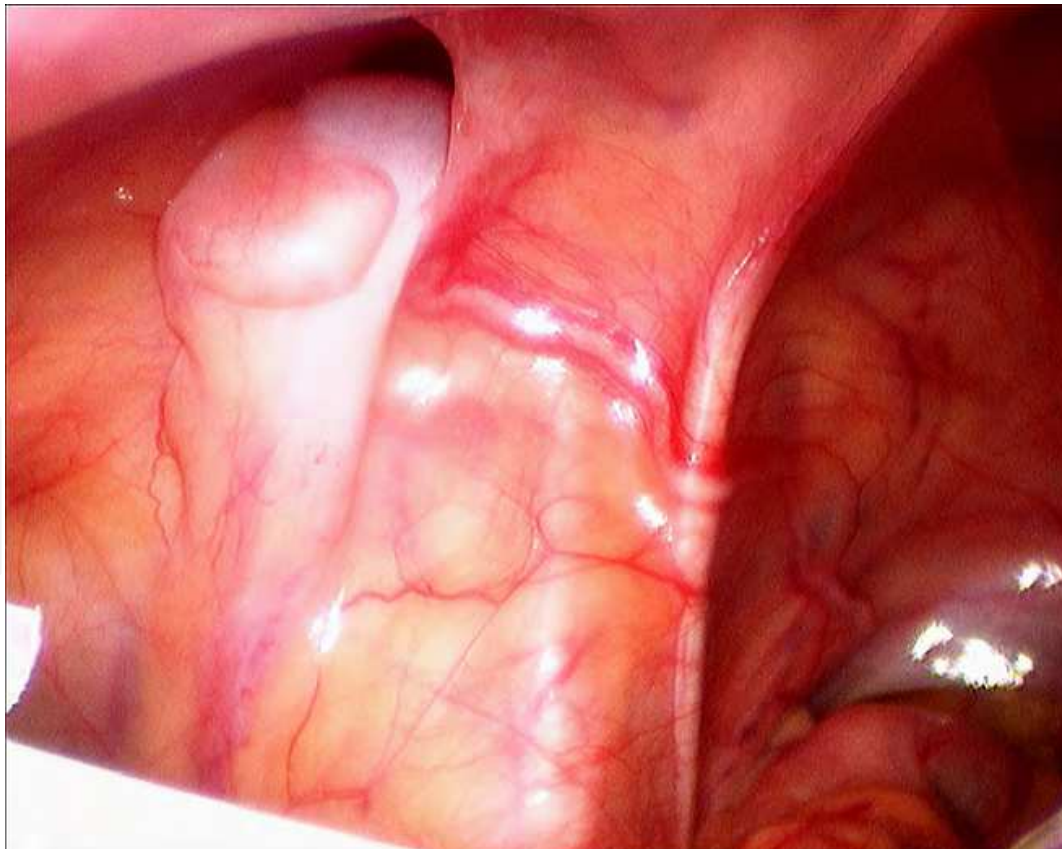


Fig. 1. A non-palpable left testis is seen at the left internal ring. The vas deferens is noted passing laterally towards the testis over the medial umbilical ligament. The spermatic vessels are seen proximal to the testis.

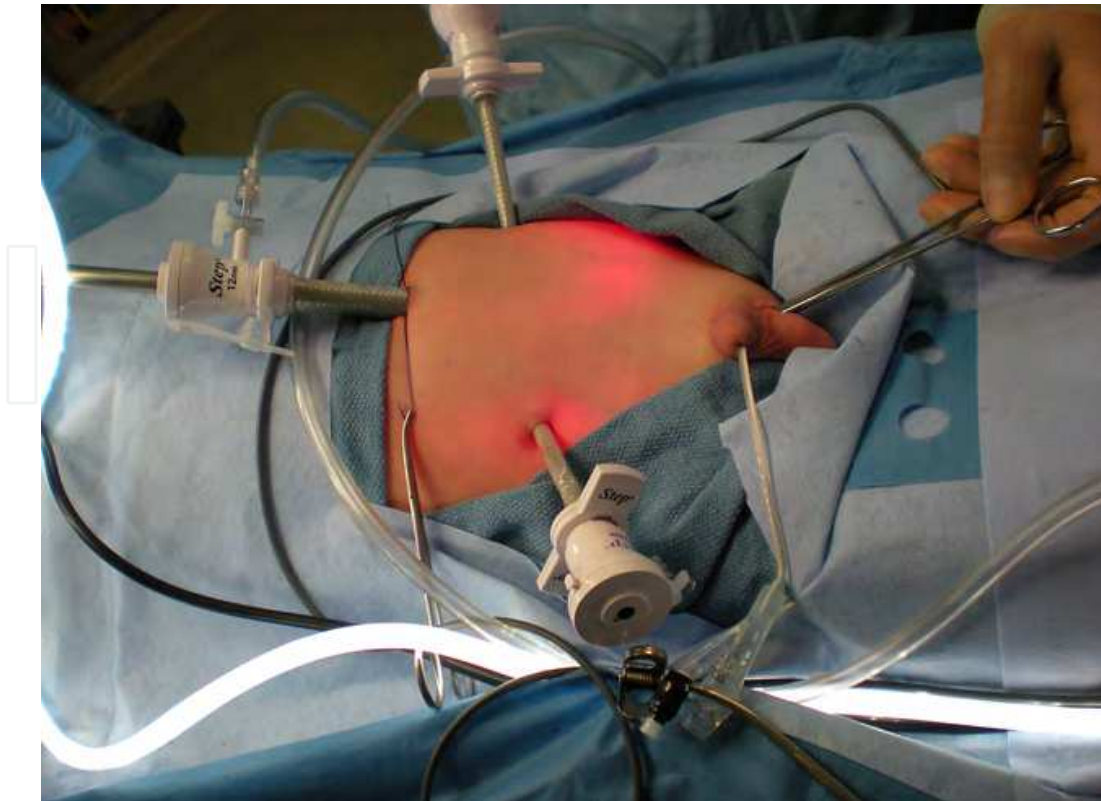

Fig. 2. A three port technique for laparoscopic orchidopexy demonstrates a single 5 mm umbilical port and 2 additional working 3 or 5 mm ports placed in the mid-clavicular line at the level of the anterior superior iliac spine. The working ports may be placed further cephalad depending on the size of the patient and length of instruments.

Care is taken to preserve the triangle of tissue medial to the spermatic vessels and lateral to the vas deferens during mobilization (Figure 4). Adequate mobilization is complete when the testis easily reaches the contralateral internal ring without undue tension. As in the Prentis manoeuvre, a new internal ring is created medially to the epigastric vessels which shortens the overall distance to the scrotal position. An incision is made at the lower pole of the scrotum to provide a dartos pouch. A laparoscopic grasper is inserted and guided through a tunnel to the new inguinal ring and pull the mobilized testis in to the scrotum without forced tension. With an assistant maintaining the position of the testis near the scrotum, the surgeon may now incise redundant peritoneal folds laparoscopically to gain some additional length (Figure 5). It is critical for the surgeon to personally monitor tension on the spermatic cord as the testis is passed into the scrotum to avoid inadvertent avulsion of the spermatic vessels.

Before the ports are removed, bleeding should be assessed laparoscopically under low intra-abdominal pressure by releasing the pneumoperitoneum. On removing the ports, hemostasis should also be assessed at the port sites, as well as being sure that the umbilical closure does not include bowel or omentum.

Esposito et al ³⁶ reported their experience with diagnostic laparoscopic in 85 children with nonpalpable testes, of whom 25 children had intra-abdominal testes. In 24 children laparoscopic orchidopexy was successful. Surgery lasted between 40 and 80 minutes. There was only 1 (4%) intraoperative complication namely iatrogenic rupture of the spermatic vessels. Similarly Radmayr et al ³⁷ analyzed the success rate and long term outcome of

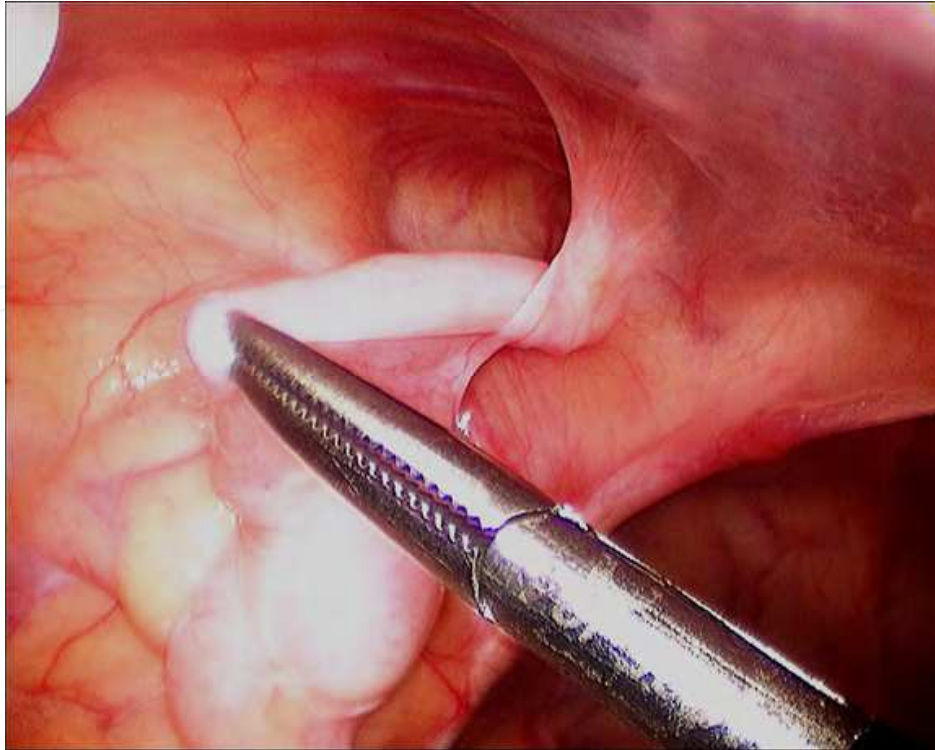


Fig. 3. The gubernaculum of the testis is mobilized. Once confirmed that a looping vas deferens is not present, the gubernaculum is divided using cautery.

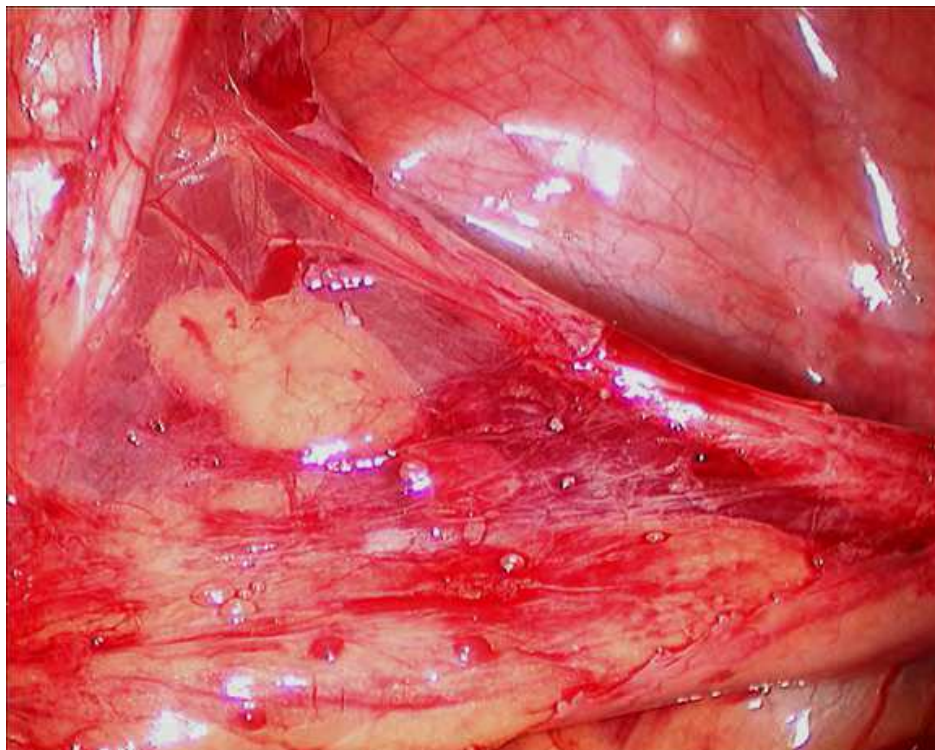


Fig. 4. The left testis is mobilized towards the contralateral right internal ring demonstrating the triangle of preserved mesentery between the vas deferens and spermatic vessels of the left testis.

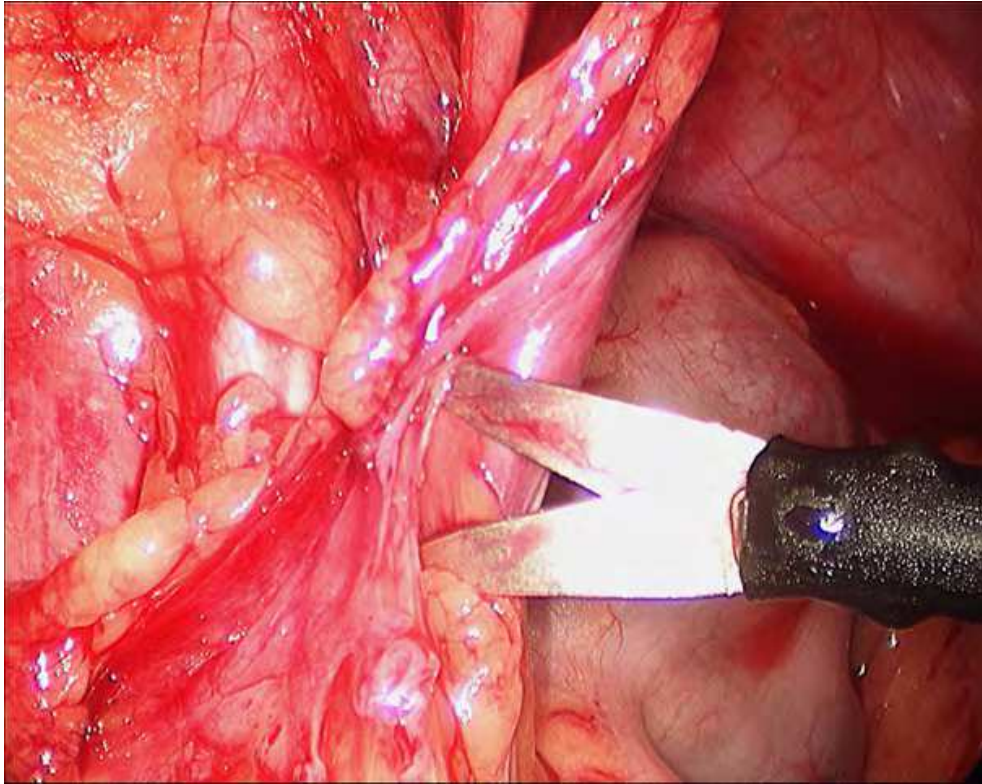


Fig. 5. With the left testis now mobilized into the left hemiscrotum via an incision medial to the medial umbilical ligament, residual peritoneal attachments may be incised laparoscopically to gain additional length to the testicle.

laparoscopic orchiopey in 84 patients .28 were managed by direct laparoscopic orchiopey . After a mean follow-up of 6.2 years all laparoscopically managed testicles were in a normal scrotal position with normal perfusion as revealed by colour Doppler sonography.

Riqueimo et al ³⁸ reported on results of laparoscopic orchiopey in children with palpable undescended testes. 28 children with 30 undescended palpable testes were treated by laparoscopic orchiopey. The operative time was 50 minutes. On follow-up ranging 5 months to 5 years, 29 of these testes maintained good size and a correct position.

8. Laparoscopic fowler-stephens orchidopexy

If the testes is immobile and beyond 2.5 cm from the internal ring , it may be prudent to perform a staged orchidopexy consisting of clipping the internal spermatic vessels and returning 6 months later to mobilize the testis on collateral vessels and the deferential artery. Fowler-Stephens step I involves incising retroperitoneum bilaterally parallel to the spermatic vessels at-least 2 cm cranially to the upper pole of the testis. The spermatic vessels are mobilized, held with grasper and two absorbable clips applied without dividing them. Vessel ablation can also be done using the harmonic scalpel via a 5mm port.

The second stage of the orchidopexy is usually completed 6 months later. It can be performed in either open or laparoscopic fashion. The same principles apply as with an open second stage procedure if performed laparoscopically. Dissection begins in the area where the spermatic vessels were earlier clipped. The vessels are now divided. The retroperitoneum is incised with a 1 cm margin laterally to the testis and medially alongside the vas deferens. The peritoneal flap remains pedicled to the vas deferens. All the vessels

around the vas deferens and the peritoneal plane between the vas and vessels are left intact. The gubernaculum is dissected as far distally as possible. The testis is mobilized carefully from the psoas fascia towards the inguinal ring. A new internal ring is created medially to the epigastric vessels. An incision is made at the lower pole of the scrotum and a dartos pouch is created. A laparoscopic grasper is guided through a tunnel to the new internal ring and the mobilized testis is pulled into the scrotum.

Lindgren et al ³⁹ performed 18 laparoscopic Fowler-Stephens procedure in 14 patients. Five testes were treated with a 2 stage procedure, while 11 were managed by laparoscopic mobilization followed by laparoscopic vessel clipping and orchiopexy in 1 stage. In 2 additional patients, nearly all dissection was performed laparoscopically but due to extenuating circumstances, inguinal incisions were required as well. At mean follow-up of 6 months all cases without previous surgery that were managed by laparoscopic orchiopexy were without atrophy and the testes were in scrotal position. They concluded that laparoscopic transection of the testicular vessels was safe in boys with high abdominal testes.


9. References

- [1] Scorer CG, Farrington GH: *Congenital Deformities of the Testis and Epididymis*, New York, Appleton-Century-Crofts, 1971
- [2] Cryptorchidism: A prospective study of 7500 consecutive male births, 1984-8. John Radcliffe Hospital Cryptorchidism Study Group. *Arch Dis Child* 1992; 67:892-899
- [3] Berkowitz GS, Lapinski RH, Dolgin SE, et al: Prevalence and natural history of cryptorchidism. *Pediatrics* 1993; 92:44-49
- [4] Hadziselimovic F, Herzog B, Buser M: Development of cryptorchid testes. *Eur J Pediatr* 1987; 146(Suppl 2):S8-S12.
- [5] Huff DS, Hadziselimovic F, Duckett JW, et al: Germ cell counts in semithin sections of biopsies of 115 unilaterally cryptorchid testes. The experience from the Children's Hospital of Philadelphia. *Eur J Pediatr* 1987; 146(Suppl 2):S25-S27.
- [6] Huff DS, Hadziselimovic F, Snyder 3rd HM, et al: Histologic maldevelopment of unilaterally cryptorchid testes and their descended partners. *Eur J Pediatr* 1993; 152(Suppl 2):S11-S14.
- [7] Rune GM, Mayr J, Neugebauer H, et al: Pattern of Sertoli cell degeneration in cryptorchid prepubertal testes. *Int J Androl* 1992; 15:19-31
- [8] Cendron M, Huff DS, Keating MA, et al: Anatomical, morphological and volumetric analysis: A review of 759 cases of testicular maldescent. *J Urol* 1993; 149:570-573.
- [9] Huff DS, Hadziselimovic F, Snyder 3rd HM, et al: Postnatal testicular maldevelopment in unilateral cryptorchidism. *J Urol* 1989; 142:546-548. discussion 572.
- [10] Huff DS, Fenig DM, Canning DA, et al: Abnormal germ cell development in cryptorchidism. *Horm Res* 2001; 55:11-17
- [11] Lee PA: Fertility in cryptorchidism. Does treatment make a difference?. *Endocrinol Metab Clin North Am* 1993; 22:479-490
- [12] Lee PA, O'Leary LA, Songer NJ, et al: Paternity after cryptorchidism: Lack of correlation with age at orchidopexy. *Br J Urol* 1995; 75:704-707.
- [13] Farrer JH, Walker AH, Rajfer J: Management of the postpubertal cryptorchid testis: A statistical review. *J Urol* 1985; 134:1071-1076

- [14] Moller H, Prener A, Skakkebaek NE: Testicular cancer, cryptorchidism, inguinal hernia, testicular atrophy, and genital malformations: Case-control studies in Denmark. *Cancer Causes Control* 1996; 7:264-274.
- [15] Schnech FX and Bellinger MF ; Abnormalities of the testes and scrotum and their surgical management , in Wein AJ, Kavoussi LR, Novick AC, Partin AW and Peters CA , Ed Campbell Walsh Urology, 9th ed , Saunders Elsevier , Philadelphia, 2008 :p 3745-3798
- [16] Moore RG, Peters CA, Bauer SB, et al: Laparoscopic evaluation of the nonpalpable testis: A prospective assessment of accuracy. *J Urol* 1994; 151:728-731.
- [17] Tennenbaum SY, Lerner SE, McAleer IM, et al: Preoperative laparoscopic localization of the nonpalpable testis: A critical analysis of a 10-year experience. *J Urol* 1994; 151:732-734
- [18] Hrebinko RL, Bellinger MF: The limited role of imaging techniques in managing children with undescended testes. *J Urol* 1993; 150:458-460.
- [19] Siemer S, Humke U, Uder M, et al: Diagnosis of nonpalpable testes in childhood: Comparison of magnetic resonance imaging and laparoscopy in a prospective study. *Eur J Pediatr Surg* 2000; 10:114-118.
- [20] Elder JS: Ultrasonography is unnecessary in evaluating boys with a nonpalpable testis. *Pediatrics* 2002; 110:748-751
- [21] Bakr AA, Kotb M: Laparoscopic orchidopexy: The treatment of choice for the impalpable undescended testis. *J Soc Laparoendosc Surg* 1998; 2:259-262.
- [22] Lakhoo K, Thomas DF, Najmaldin AS: Is inguinal exploration for the impalpable testis an outdated operation?. *Br J Urol* 1996; 77:452-454
- [23] Barqawi AZ, Blyth B, Jordan GH, et al: Role of laparoscopy in patients with previous negative exploration for impalpable testis. *Urology* 2003; 61:1234-1237.discussion 1237
- [24] Koff SA: Does compensatory testicular enlargement predict monorchism?. *J Urol* 1991; 146:632- 633
- [25] Hurwitz RS, Kaptein JS: How well does contralateral testis hypertrophy predict the absence of the nonpalpable testis?. *J Urol* 2001; 165:588-592.
- [26] Belman AB, Rushton HG: Is an empty left hemiscrotum and hypertrophied right descended testis predictive of perinatal torsion?. *J Urol* 2003; 170:1674-1675.discussion 1675-6.
- [27] Cisek LJ, Peters CA, Atala A, et al: Current findings in diagnostic laparoscopic evaluation of the nonpalpable testis. *J Urol* 1998; 160:1145-1149.discussion 1150.
- [28] Van Savage JG: Avoidance of inguinal incision in laparoscopically confirmed vanishing testis syndrome. *J Urol* 2001; 166:1421-1424
- [29] Grady RW, Mitchell ME, Carr MC: Laparoscopic and histologic evaluation of the inguinal vanishing testis. *Urology* 1998; 52:866-869.
- [30] De Luna AM, Ortenberg J, Craver RD: Exploration for testicular remnants: Implications of residual seminiferous tubules and crossed testicular ectopia. *J Urol* 2003; 169:1486-1489.
- [31] Elder JS: Laparoscopy for impalpable testes: Significance of the patent processus vaginalis. *J Urol* 1994; 152:776-778.
- [32] Belman AB, Rushton HG: Is the vanished testis always a scrotal event?. *BJU Int* 2001; 87:480-483.

- [33] Kanemoto K, Hayashi Y, Kojima Y, et al: The management of nonpalpable testis with combined groin exploration and subsequent transinguinal laparoscopy. *J Urol* 2002; 167:674-676.
- [34] Ravasse P, Petit T, Delmas P: [Impalpable testis: Complete inguinal exploration by laparoscopy.]. *Prog Urol* 2003; 13:103-105.discussion, 105-106.
- [35] Cortesi N, Ferrari P, Zambarda E, Manenti A, Baldini A, Morano FP. Diagnosis of bilateral abdominal cryptorchidism by laparoscopy . *Endoscopy* 1976; 9: 33
- [36] Esposito C, Damiano R, Gonzalez-Sabin MA, Savanelli A, Centonza A, Settimi A, Sacco R . Laparoscopic assisted orchidopexy: an ideal treatment for children with intra-abdominal testes . *J Endourol* 2002, 16: 659-662
- [37] Radmayr C, Oswald J, Schwenter C, Neururer R , Peschel R, Bartsch G. Long term outcome of laparoscopically managed nonpalpable testes . *J Urol* 2003; 170: 2409-2411
- [38] Riqueime M, Aranda A, Rodriguez C, Villalvazo H , Alvarez G. Laparoscopic orchiopexy for palpable undescended testes: a 5 year experience . *J Lap Ad Surg Tech* 2006; 16:321-324
- [39] Lindgren BW, Franco I, Blick S, Levitt SB, Brock WA , Palmer LS, Friedman SC, Reda EF. Laparoscopic Fowler-Stephens orchiopexy for the high abdominal testis. *J Urol* 1999; 162: 990- 993

IntechOpen



Advanced Laparoscopy

Edited by Prof. Ali Shamsa

ISBN 978-953-307-674-4

Hard cover, 190 pages

Publisher InTech

Published online 30, September, 2011

Published in print edition September, 2011

The present book, published by InTech, has been written by a number of highly outstanding authors from all over the world. Every author provides information concerning treatment of different diseases based on his or her knowledge, experience and skills. The chapters are very useful and innovative. This book is not merely devoted to urology sciences. There are also clear results and conclusions on the treatment of many diseases, for example well-differentiated papillary mesothelioma. We should not forget nor neglect that laparoscopy is in use more extensively than before, and in the future new subjects such as use of laparoscopy in treatment of kidney cysts, simple nephrectomy, pyeloplasty, donor nephrectomy and even robotic laparoscopy will be researched further.

How to reference

In order to correctly reference this scholarly work, feel free to copy and paste the following:

Nerli R. B., Reddy M. N. and Hiremath M.B. (2011). Laparoscopy for the Undescended Testes, Advanced Laparoscopy, Prof. Ali Shamsa (Ed.), ISBN: 978-953-307-674-4, InTech, Available from:
<http://www.intechopen.com/books/advanced-laparoscopy/laparoscopy-for-the-undescended-testes>

INTECH
open science | open minds

InTech Europe

University Campus STeP Ri
Slavka Krautzeka 83/A
51000 Rijeka, Croatia
Phone: +385 (51) 770 447
Fax: +385 (51) 686 166
www.intechopen.com

InTech China

Unit 405, Office Block, Hotel Equatorial Shanghai
No.65, Yan An Road (West), Shanghai, 200040, China
中国上海市延安西路65号上海国际贵都大饭店办公楼405单元
Phone: +86-21-62489820
Fax: +86-21-62489821

© 2011 The Author(s). Licensee IntechOpen. This chapter is distributed under the terms of the [Creative Commons Attribution-NonCommercial-ShareAlike-3.0 License](#), which permits use, distribution and reproduction for non-commercial purposes, provided the original is properly cited and derivative works building on this content are distributed under the same license.

IntechOpen

IntechOpen