

# We are IntechOpen, the world's leading publisher of Open Access books Built by scientists, for scientists

**4,800**

Open access books available

**122,000**

International authors and editors

**135M**

Downloads

Our authors are among the

**154**

Countries delivered to

**TOP 1%**

most cited scientists

**12.2%**

Contributors from top 500 universities



**WEB OF SCIENCE™**

Selection of our books indexed in the Book Citation Index  
in Web of Science™ Core Collection (BKCI)

Interested in publishing with us?  
Contact [book.department@intechopen.com](mailto:book.department@intechopen.com)

Numbers displayed above are based on latest data collected.

For more information visit [www.intechopen.com](http://www.intechopen.com)



# Expanding Applications of Defibrillators and Cardiac Resynchronization Therapy to Include Adult Congenital Heart Disease

K Michael<sup>1</sup>, B Mayosi<sup>2</sup>, J Morgan<sup>3</sup> and G Veldtman<sup>4</sup>

<sup>1</sup>Queen's University Heart Rhythm Service, Kingston, Ontario

<sup>2</sup>University of Cape Town, Department of Medicine

<sup>3</sup>Wessex Cardiothoracic Unit and

<sup>4</sup>Grown Up Congenital Heart Disease Unit, Southampton University's Hospital,

<sup>1</sup>Canada

<sup>2</sup>South Africa

<sup>3,4</sup>UK

## 1. Introduction

Atrial redirection surgery, brought into common use by Mustard's modification of the Senning procedure, transformed the natural history of dextro-transposition of the great arteries (d-TGA) from a 90% one year mortality to a 90% 1 year survival(1). Although rendering the infant acyanotic with excellent functional capacity, the morphological right ventricle(sRV) is required to support the systemic circulation. The sRV faces substantial pressure overload resulting in a high incidence of late ventricular failure(2). This prompted an evolution to a more physiologically acceptable correction in the form of the arterial switch or Jatene operation(3). The arrhythmias and heart failure that usually manifest by the second decade of life in patients after atrial redirection surgery pose a challenge to management.

Apart from the progressive sRV dysfunction and heart failure, sinus bradycardia commonly arises because of surgical disruption to the sino-atrial node blood supply warranting early pacemaker implantation (4). The incidence of tachyarrhythmias, most notably atrial flutter and fibrillation, may be related to ventricular dysfunction or as a consequence of atrial scarring following surgery. Ventricular tachycardia (VT) and fibrillation (VF) have been documented on holter monitoring in various long term studies and the incidence of sudden cardiac death (SCD) ranges between 2-11%(5). Cardiac resynchronization with a biventricular implantable cardioverter-defibrillator (ICD) therefore poses an attractive option particularly as a bridge to transplantation in this group of patients. We examine the challenges in terms of the anatomical constraints in a group of consecutive patients with surgically corrected TGA(6;7).

### 1.1 Relevant anatomical issues

Placement of intracardiac leads may compromise the haemodynamic status of the patient. Mechanical obstruction from an intra-baffle stenosis or thrombotic obstruction may be encountered or concomitant known associations such as severe tricuspid regurgitation, valvar and sub-valvar pulmonary stenosis must be borne in mind.

Intra-baffle leaks raise the possibility of systemic embolization and inadvertent lead positioning within the sRV.

The coronary sinus (CS) in d-TGA, as in the normal human heart, lies in the atrio-ventricular groove between the left atrium and sub-pulmonic left ventricle (pLV). In the case of surgically altered d-TGA, the resultant sRV, is therefore not encircled by the CS. This limits transvenous access to the lateral wall of the sRV, for lead placement. A large aberrant coronary vein arising from the sRV may drain into the CS or directly into the right atrium (RA) **figure 1**. This may present an option for lead placement. An anterolateral cardiac vein may be regarded as a poor pacing site for a failing systemic LV but may be entirely suitable for pacing the sRV. In an anatomical study by Uemura et al, in hearts with congenitally corrected transposition (atrio-ventricular and ventriculo-arterial discordance), the CS drained the sRV in the majority (87%) of specimens with 5 having partial or complete drainage directly into the atrium (8).

Electrical stimulation of the failing systemic ventricle is usually achieved transvenously via CS cannulation, utilising specially designed left ventricular pacing leads. If this is unsuccessful (eg. lack of a suitable ventricular vein) a trans-sternal, surgical approach may be used. The latter, however, may be preferable if conducted at the time of cardiac surgery or with surgically or congenitally altered anatomy that makes transvenous CS access difficult or unachievable.

Access to the coronary venous vasculature post Mustard surgery in d-TGA is also dependent on whether the surgeon leaves the CS open to the systemic-atrial side of the baffle or to the pulmonary-venous portion. The next challenge is percutaneous cannulation of the CS given the altered atrial structure. Pre-procedural imaging using cardiac magnetic resonance, computerized tomography, intracardiac or transoesophageal echocardiography improves identification of coronary venous anatomy (9-11).

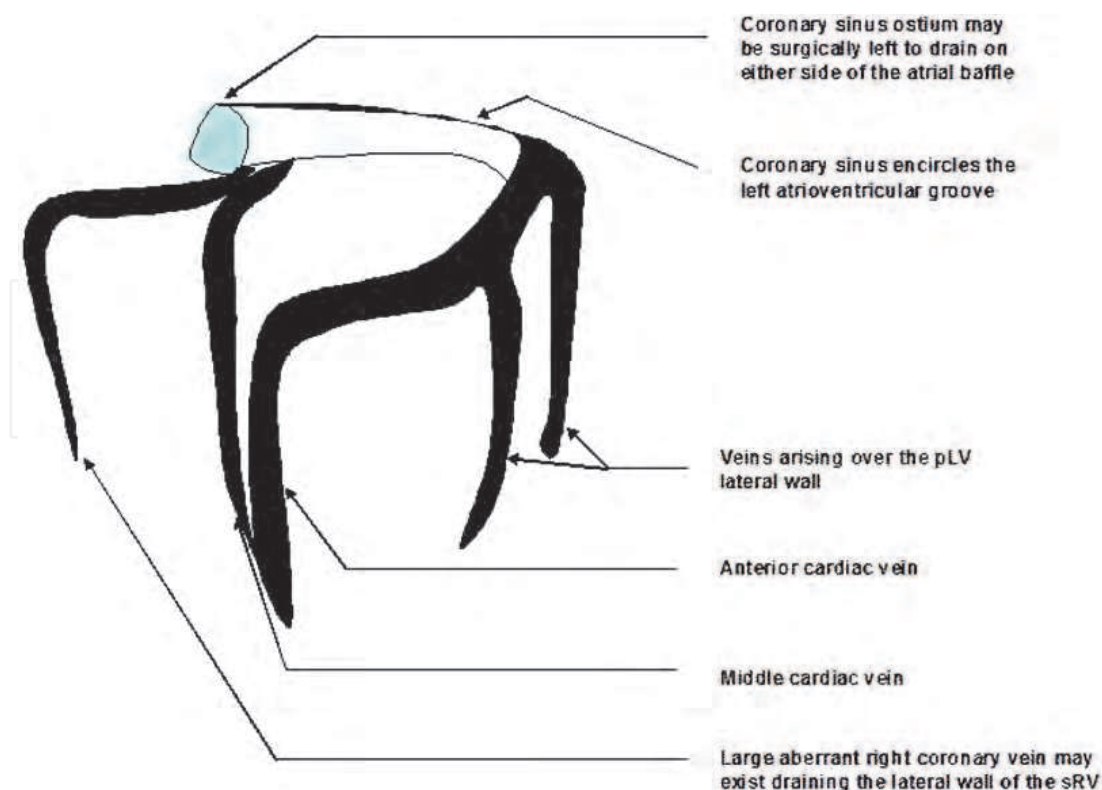


Fig. 1. The anticipated coronary venous structure in dTGA.

### **1.2 Evolving concepts of cardiac resynchronization therapy**

Cardiac resynchronization therapy (CRT) has become an integral part of the management of patients with ischaemic and non-ischaemic cardiomyopathies presenting with advanced heart failure. This device based strategy has also been successfully applied in patients with adult congenital heart disease and ventricular dysfunction (12).

Cardiac asynchrony has been traditionally defined in patients in terms of electrical (QRS width >120ms) and doppler echocardiography (conventional/ tissue doppler). The CRT non-responder population however remains between 20-30% warranting evaluation of additional or alternative measurements. Experience is however limited in patients with morphological sRVs and these selection criteria may not be relevant in this peculiar population (13;14;15).

### **1.3 Patients**

All patients were derived from a jointly managed group of patients at a tertiary referral centre for clinical electrophysiology and adult congenital heart disease. All patients had NYHA grade II-III heart failure symptoms with a perceived risk of SCD. Conventional management would have entailed inevitable cardiac transplantation, with its associated complications. The decision to resort to device therapy was therefore taken out of clinical and life-saving necessity and was conducted in terms of our current understanding of best clinical practice. Where innovative strategies were employed, this was used primarily to increase patient benefit from a more refined and patient specific technique.

### **1.4 Statistical analysis**

Demographic data and simple statistical analysis was performed using SPSS and represented at mean $\pm$ std dev. Where relevant a test of significance was performed using a t-test.

## **2. Application of cardiac defibrillator therapy for at risk patients with failing systemic right ventricles**

Technical considerations implant details, and follow-up on 5 patients with d-TGA and a Mustard procedure receiving an ICD  $\pm$  concomitant CRT are addressed below. Right ventricular function was assessed by a combining echocardiographic visual appraisal and planimetry as well as RV angiography. An individualized approach to implantation was undertaken, taking into consideration existing transvenous electrodes and post surgical cardiac anatomy. After implantation, patients were followed-up at 4-6 weeks and then 6-monthly intervals. Data at follow-up including functional assessment, device interrogation, ECG and transthoracic echocardiograms (TTEs) were reviewed.

The baseline characteristics of the 5 patients (4 male, age 18-35 years) studied are shown in **table 1**. All had significantly impaired sRV function (mean sRV EF=30%) and impaired functional class (NYHA class II-III). Two patients had sustained VT, 3 non-sustained VT, and 4 had atrial arrhythmias. Four patients had previously implanted pacemakers. Pre-implant electrophysiological studies were not performed.

### **2.1 Implant considerations**

Implanting a transvenous electrode into the pLV requires that the lead navigates through the surgical baffle. Baffle stenosis impeding flow from the superior vena cava (SVC) to the

pLV is common post Mustard modification(1). Defibrillator electrode placement will potentially further impede venous drainage and pLV filling. A strategic decision was therefore made not to implant multiple leads via anatomically narrow baffles and to treat any baffle stenosis prior to the implant. An entirely transthoracic defibrillation strategy was therefore employed in the first patient using a high energy defibrillator (maximum output of 41J) with subcutaneous, single finger arrays (Model 6996. 25cm coil, 500cm<sup>2</sup> surface. Medtronic, USA). Despite this defibrillation was ineffective figure 2.

	Patient 1	Patient 2	Patient 3	Patient 4	Patient 5
Age (years) at implantation	24	22	35	18	25
Documented arrhythmias	Sinus bradycardia, atrial flutter, *NSVT	Sinus bradycardia, ‡VT, *NSVT	Sinus bradycardia, atrial flutter, *NSVT	†SVT, *NSVT	Sinus bradycardia, †SVT, *NSVT, ‡VT
RVEF (%)	25	25	30	35	35
Pre-existing device	Yes	Yes	Yes	No	Yes
Weight (kg)	110.2	106.1	77	67.4	54
Implant	Surgical	Surgical	Transvenous	Transvenous	Transvenous

\*NSVT=non sustained ventricular tachycardia, †SVT=supra-ventricular tachycardia, ‡VT=ventricular tachycardia

Table 1. Salient baseline clinical characteristics of patients receiving defibrillators.

Of the 4 patients with pre-existing pacemakers, 2 were demonstrated to have functional baffle stenosis and therefore underwent lead extraction and stent angioplasty at separate procedures at least 48 hours prior to transvenous insertion of a defibrillator lead. Those patients who had lead extractions and the patient with no pre-existing pacemaker underwent standard transvenous implantation with endocardial defibrillator coils placed via the subclavian vein into the pLV. Two patients with existing pacemakers and no evidence of baffle stenosis on cardiac catheterisation had their existing endocardial (pLV)

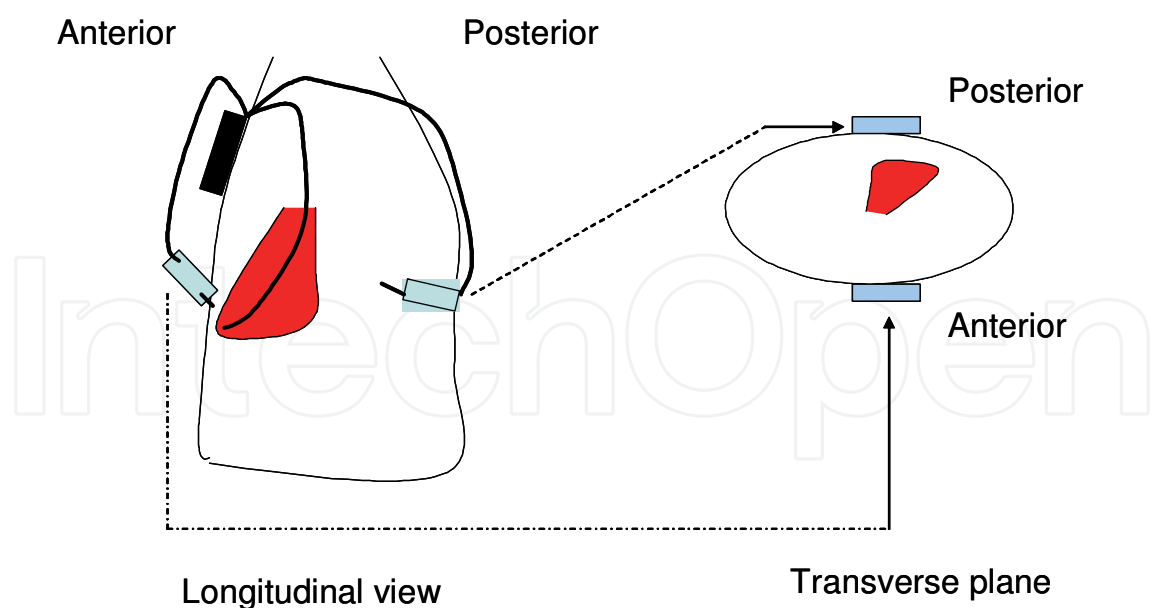


Fig. 2. Diagrammatic view of the placement of the subcutaneous arrays (arrowed) around the chest wall in patient 1 with a sensing lead in the pLV.

pace/sense electrodes conserved; 1 then had epicardial patch electrodes and 1 had subcutaneous arrays implanted at the time of trans-sternal, epicardial pacing lead placement for CRT.

## 2.2 Defibrillation circuits and testing

The patient with subcutaneous arrays, had the electrodes placed in an antero-posterior configuration around the left chest wall with a left sub-pectoral Can implantation (**figure2**). Ventricular fibrillation was induced via the chronic pLV endocardial pace/sense lead and therapies were delivered between the anterior and posterior subcutaneous arrays. A series of 6 inductions were performed with therapies of 25 to 41J but none were successful in terminating VF and external rescue shocks were required. Inclusion of the active Can in the circuit did not improve defibrillation outcome.

One patient underwent epicardial patch electrode placement in the anterolateral and inferior positions over the systemic ventricle. This strategy was successful in defibrillating VF at 25J on the first induction (a 10J safety margin).

The remaining 3 patients underwent standard transvenous system implants. An active Can was placed in the left sub-pectoral region and a defibrillation coil advanced under fluoroscopy to the pLV via the subclavian vein. The first 2 transvenous implants received dual coil leads (as is our standard practice when high DFTs are anticipated) but both had failed initial defibrillation, requiring exclusion of the SVC coil from the circuit. In 1 of these patients, a pLV to Can vector provided effective defibrillation at 25J, and in the other it was also necessary to reverse the polarity of the circuit to achieve this safety margin. This patient underwent 4 VF inductions and subsequently developed pulmonary oedema during the procedure.

## 2.3 Follow up

The median follow-up in all 5 patients was 20 months (range 15-24). A total of 4083 non-sustained tachycardias were documented in the cohort over this period. One patient has

had VT with pre-syncope which was correctly diagnosed and treated by a discharge by the ICD.

## 2.4 Discussion

Mustard patients are at increased risk of SCD defined by sRV dysfunction, heart failure functional status, non-sustained VT and atrial arrhythmias (5). Only 1 patient in the cohort had a preceding out-of-hospital arrest but all patients had documented multiple ventricular ectopics on 24-hour holter analysis. None of the patients received formal electrophysiological studies as we felt that a negative study should not disqualify them. The patients were < 40 years of age and lived productive lives up to the point of referral. The absence of therapies in the majority of the patients (4/5) over 2 years of follow-up does not mean that the decision to implant them was incorrect. The time to the first appropriate therapy in other patient groups with ICDs often exceeds 2 years (16).

It has also not previously been demonstrated that the gold standard treatment for prevention of SCD, namely ICDs, are effective in this population, and given the variation from normal anatomy, efficacy should not be assumed. Appropriate vectors of defibrillation, as determined by electrode placement, are the key determinants of defibrillation success (17). The SVC cavity to pLV vector in particular appears to exclude much of the sRV and septum **figure 3** whilst severe chamber dilatation, common in Mustard patients, is recognised from other populations to be associated with less effective defibrillation (18).

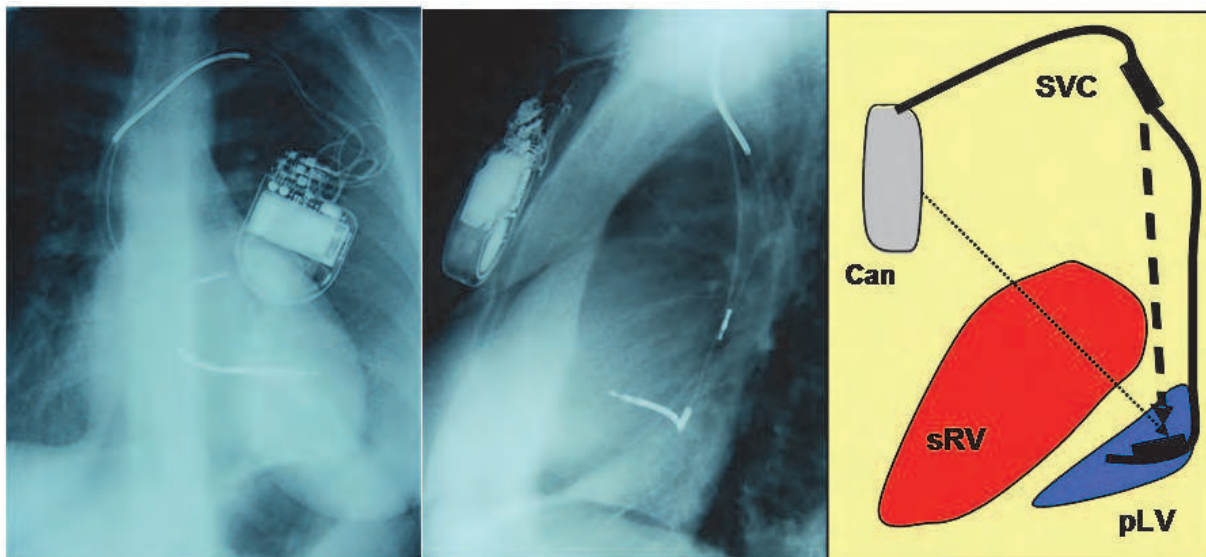


Fig. 3. Electrode positions and defibrillation pathways of a dual coil lead system in a patient post Mustard correction. A dual coil defibrillator lead implanted into the pLV tends to be located more superiorly than when it is in an apical position in the right ventricle. The result is that the proximal electrode rests within the SVC/left subclavian vein. The defibrillation vector between the SVC and pLV thus excludes the major myocardial mass, reducing defibrillation efficacy.

The role of polarity reversal is less well established. Data from randomised trials provides some evidence but no rational explanation, that by inverting vectors, efficacy may be improved in patients (19). However, with a limited number of inductions in any given individual, apparent differences in efficacy may be no more than a reflection of the

probabilistic nature of defibrillation success and we need to be cautious in making finite decisions as regards what will and will not work in individual patients.

The single patient experience with subcutaneous defibrillation was plainly suboptimal with no successful defibrillation achieved. This may be a reflection of the Mustard anatomy or other independent factors that potentially may affect defibrillation efficacy. This patient had a body mass index of 33 and gross cardiomegaly.

Our experience demonstrates that transvenous implantation is feasible but may require interventions such as lead extraction and angioplasty of the atrial baffle to avoid venous pathway obstruction. The optimal defibrillation vector with a transvenous implant appears to be pLV to active Can and as such, single coil leads are preferred. Our experience with subcutaneous arrays alone was unsatisfactory. Efficacy may be improved by selecting patients with a smaller body habitus and by incorporating intra-thoracic electrodes. Epicardial patches require an open chest procedure and may be placed at the time of concomitant epicardial CRT if indicated in the individual patient.

The findings mandate the use of high output devices, regardless of the configuration, in anticipation of compromised defibrillation efficacy in similar patients which ultimately may prove more cost effective than undertaking revision procedures.

## 2.5 Conclusion

Defibrillator implantation in Mustard patients is feasible though challenging. Clinicians planning to implant such patients must be prepared to optimise the systemic venous access of the baffle prior to implantation and then to have strategies in place to tackle high defibrillation thresholds and the decompensation that may result from multiple VF inductions. Endocardial pLV to active Can and epicardial patches are effective defibrillation strategies in this group.

## 3. Cardiac resynchronisation therapy

Although the atrial switch was abandoned in the 1980s for the Jatene (arterial switch) procedure, a considerable number of patients have survived into their third decade of life (20). The right ventricle is not capable of supporting the systemic circulation for this extended period. Patients post Senning or Mustard operations, invariably experience right ventricular failure by the second and third decades of life (4;21). If cardiac transplantation is their only option, these patients face a post operative average life expectancy of just 10 years (22). Coupled with the limited availability of donors, this management plan is suboptimal for these, generally young patients. We present here 3 consecutive cases who had pre-existing dual chamber pacemakers upgraded to CRT/D. Two required a hybrid approach using epicardial leads implanted by surgical thoracotomy while a 3<sup>rd</sup> successfully had an endocardial sRV pace/sense lead implanted. Although the results varied for these cases, they demonstrate plausible alternatives to management.

### 3.1 Case presentations

#### 3.1.1 Case 1

Patient 1 was 110 kg and 22 years old at time of implantation of his CRT/D system (**table 2**). The underlying congenital anomaly of simple transposition was initially temporised by an atrial septostomy soon after birth and then with a Mustard operation at 7 months of age. At 18 years of age he presented with sino-atrial node dysfunction (a common complication



	<b>Patient 1</b>	<b>Patient 2</b>
Age (years) at implantation	22	24
Wight (kg)	110	106
Onset of symptoms	15	16
Initial symptoms	Effort intolerance	Breathlessness & chest pain
Gender	M	M
NYHA	III	III
<b>Drug therapy</b>		
ACE inhibitor	Lisinopril	Lisinopril
Beta Blocker	Bisoprolol	Bisoprolol
Cardiac glycoside	Y	Y
Frusemide	Y	Y
Spironolactone	N	Y
Amiodarone	Y	N
<b>Echo features</b>		
sRV	Dilated. Severely impaired	Dilated, severely impaired
pLV	Moderately impaired	“Normal”
TR	Mild	Mild
MR	Trivial	-
<b>ECG features</b>		
BBB	RBBB	RBBB
AVB	First degree	First degree
QRS duration	120ms	160 ms
CXR Cardiothoracic ratio	0.6	0.7
SAN dysfunction	Sinus bradycardia	Sinus bradycardia
NSVT	Y	Y
VT	N	Y
VF	N	N
SVT	Atrial Flutter (ablated)	N

\*N-No Y-Yes mRV- morphological right ventricle mLV- morphological left ventricle TR-tricuspid regurgitation MR-mitral regurgitation BBB-Bundle branch block AVB-atrioventricular block SAN-sino-atrial node NSVT-non sustained VT VT-ventricular tachycardia VF-ventricular fibrillation SVT-supraventricular

Table 2. Baseline clinical characteristics of 2 patients with Mustard corrections and preexisting pacemakers receiving an upgrade to CRT.

following Mustard surgery) and therefore received a dual chamber pacemaker (Medtronic THERA DR 7968i. Medtronic. Inc., MA). Transthoracic echocardiogram revealed a dilated and myopathic sRV with an EF of 25% and a dp/dt ratio = 438.3 with evidence of asynchronous ventricular contraction. The systemic ventricle (sRV) myocardial performance index was 0.53. An exercise treadmill test showed a suboptimal response with a cardiac

output of 3.9 l/min pre-exercise to 9.0 l/min at maximal exercise. He had an underlying right bundle branch block QRS morphology. Recent evidence from other series also suggest an increase risk of VT/VF and SCD in patients following Mustard procedures presenting with sRV dysfunction and atrial tachyarrhythmias (1). Cardiac resynchronization and defibrillator therapy offered a plausible alternative to delaying cardiac transplantation. The implant was performed via a mini-thoracotomy through the lower part of the previous sternal incision. The chronic atrial and pLV leads were conserved and a steroid eluting pace/sense electrode was sutured to the inferior epicardial surface of the right ventricle (Medtronic 4968). Two single-finger subcutaneous defibrillator arrays (Medtronic 6996) were implanted in an antero-posterior configuration and connected to the defibrillator ports of a Contak RENEWAL 4HE defibrillator (Guidant Inc.). Attempts at biventricular pacing (BVP) were also of limited benefit. A TTE guided optimization of CRT resulted in the sRV being paced 40ms before the pLV. The paced QRS remained predominantly right bundle branch block in morphology but had increased to 200ms from a baseline width of 120ms. Apart from not experiencing a subjective improvement in symptoms, the patient presented with episodes of recurrent paroxysmal atrial flutter documented on holter analysis.

A successful flutter ablation was performed using non-contact mapping (Ensite™, St. Jude Medical). Two lines of block were created extending from the inferior vena cava to the inferior limb of the baffle and also from the tricuspid valve to the pulmonary venous side of the baffle. Despite further adjustment to the paced atrioventricular delay (AVD) and ventricular off-set, there was no improvement in symptoms. At his most recent follow-up doppler parameters suggested atrial pacing provided the optimal configuration (AAIR).

His effort tolerance was quantified objectively on the treadmill using the Bruce protocol and he exercised for 6.58 minutes.

### 3.1.2 Case 2

The second patient (24 years) weighed 106kg, was born with simple d-TGA and a large patent ductus arteriosus which had spontaneously closed by the time of atrial baffle construction at 6 months of age. Thereafter periodic surveillance with TTE revealed a mild stenosis of the inferior limb of the atrial baffle. Onset of dyspnoea and effort related chest pain with diaphoresis occurred at 17 years and was assumed to be due to sRV dysfunction and demand ischaemia after demonstration of unobstructed coronary arteries. Like the previous patient, profound sinus bradycardia was documented on holter monitoring which resulted in pacemaker implantation at the age of 22. Two years later, his effort tolerance deteriorated from NYHA grade II to III/IV with an episode of VT and accompanying syncope. The decision was made to upgrade to a CRT/D. Preceding angiography demonstrated a stenosis in the inferior limb of the atrial baffle for which balloon angioplasty was successfully performed.

The upgrade was performed by surgical thoracotomy, conserving the chronic atrial and ventricular pacing leads (Medtronic 5076). An epicardial steroid eluting electrode (Medtronic 4968) was attached to the inferior epicardial surface of the sRV. The pacing threshold of the sRV epicardial lead at implantation was 5.5v @ 0.5ms, with an R wave measuring 4.6mV and an impedance of 1100 ohms. The epicardial system showed a great variability in pacing parameters over a 9 month follow-up period post procedure (**table3**).

Once again, the atrioventricular delay (AVD) and ventricular pacing off-set was guided by echocardiography and the sRV was paced 40ms ahead of the pLV in the final programming. The patient symptomatically improved to NYHA grade II status.

	sRV epicardial lead		pLV endocardial lead		RA endocardial lead	
	Threshold	Resistance (ohms)	Threshold	Resistance (ohms)	Threshold	Resistance (ohms)
<b>Implant</b>	0.5ms@5.5v	1100	0.2ms@1.5v	448	0.3ms@1.5v	480
<b>1 month*</b>	0.5ms@6.0v	576	0.2ms@1.0v	432	0.4ms@1.0v	496
<b>6 month</b>	0.3ms@5.0v	624	0.4ms@1.2v	464	0.4ms@1.0v	624
<b>9 month</b>	0.3ms@5.0v	648	0.2ms@1.5v	448	0.3ms@1.5v	480

\* follow-up

Table 3. Comparison of pacing parameters of epicardial and endocardial leads at sequential follow-up in patient 2 implanted post Mustard surgery with a hybrid CRT system.

Cardiac resynchronization therapy has dramatically improved the quality of life in patients presenting with grade III and IV NYHA symptoms of heart failure (23). We have demonstrated here its application in two patients with sRV dysfunction using surgically positioned epicardial leads.

It may be argued that preceding angioplasty of significant baffle related stenoses in both patients may have contributed to functional improvement. The baffle angioplasties were performed in both patients as a separate procedure at least 48 hours before device implantation. This was done primarily to reduce the duration of the device implantation procedure but neither patient demonstrated appreciable clinical or echocardiographic benefit from relief of the stenoses on myocardial function in the period leading up to the actual implant.

The RV in a normal heart is a thinner walled and crescent shaped structure, that is not a suitable long term substitute for the left ventricle. The concave intrusion of the septum into the cavity of the RV also provides the optimal geometry for overall RV function (24). If left to chronically support the systemic circulation, the RV hypertrophies and dilates with subsequent flattening of the interventricular septum. The resultant dyskinetic septal motion further worsens the functional impairment of the dysfunctional RV. Resynchronization therapy should therefore serve not only to pace the RV free wall but co-ordinate this with septal motion. This complex anatomical and functional interaction suggests that we need to take greater care in positioning pacing leads over the sRV, to ensure adequate septal and free wall recruitment during biventricular pacing.

From this discussion we can infer why CRT failed in the first patient. The epicardial lead was placed on the sRV at the discretion of the surgeon over its inferior border with no formal guidance. It was only limited by the pacing threshold at the respective site. This arbitrary placement may have been responsible for the non-response. Perhaps a more guided approach such as that suggested by Dekker et al using intra-procedural pressure-volume loop monitoring may have altered the outcome (25).

Epicardial pacing systems have been more frequently associated, than transvenous systems, with higher pacing thresholds, diaphragmatic stimulation, lead fracture and insulation breaks (26). The use of steroid eluting leads, does alleviate some of the deterioration in pacing parameters but this unfortunately did not offer an advantage in the second patient (27). Due to previous surgery, the location of viable myocardium for pacing is difficult and

placement of electrodes on the inferior aspect of both the sRVs was because of limited access to the sRV free wall.

Transvenous attempts at coronary sinus cannulation may also result in failure to deliver a appropriately positioned lead. Mair et al in a comparative study, also demonstrated a higher complication rate with transvenous CS lead placement than with epicardial implantation via a mini-thoracotomy procedure (26). A video-assisted thoroscopy creating a minimally invasive percutaneous approach may be a solution but the option requires expertise and is dependent on centre availability (28). This prompted us to consider endocardial delivery of the pace/sense lead to the sRV in the next case study.

The feasibility and safety of endocardial pacing of the systemic ventricle using a transseptal route to the left ventricle in normally “transposed” hearts was shown by Jais et al in a small series of 11 patients (29). In patients post Mustard correction, this would mean perforation through the atrial baffle or passage through a baffle leak to implant the lead onto the endocardial surface of the sRV followed by life long anticoagulation because of the potential for paradoxical and systemic embolization. Disruption to the atrial structures and interference with the atrioventricular valve may become issues in the long term follow-up of these patients but this remains an option with the benefit of more stable endocardial pacing thresholds.

### 3.1.3 Case 3

A 27 year old female with a Mustard procedure for d-TGA, and subsequent DDDR pacemaker implantation for sinus node dysfunction at age 17years, presented with progressive effort intolerance. Transthoracic echocardiogram and angiography revealed a dilated sRV with systolic dysfunction (EF=23%) and predominant lateral free wall hypokinesia.

Holter monitoring revealed episodes of non-sustained ventricular tachycardia. The 12-lead electrocardiogram (ECG) revealed atrial and ventricular sequential pacing with fused sinus/paced QRS complexes measuring 130ms. She achieved just 4.8 minutes on treadmill testing (Bruce protocol) compared to just 8.4 minutes documented 10 years earlier.

Preceding diagnostic cardiac catheterization revealed severe stenosis of the inferior baffle and a minor leak in the superior baffle communicating with the pulmonary venous atrium. Stent angioplasty of the inferior baffle was performed to relieve the obstruction (**figure 4**).

A multi-electrode (MEA) catheter (Ensite 3000. St. Jude Medical. USA) was then inserted retrogradely across the aortic valve into the sRV and isopotential (voltage) maps were created of the sRV during AAI, DDD pacing (RA+pLV then RA+sRV). Biventricular pacing (BVP) was simulated by pacing from a roving ablation catheter (7F Stinger. Bard. Minneapolis.USA) within the sRV and by triggering sRV pacing after the sensed pLV impulse (**figure 5**). Because of this there was an inherent delay of 20ms after pLV chamber pacing. Atrial pacing (AAI) achieved diffuse and rapid activation of the sRV however Wenckebach’s phenomenon of the atrioventricular node was noted at just 70 beats per minute making constant ventricular pacing necessary. Voltage mapping during pLV apical pacing showed inhomogenous activation of the sRV in that the peak voltage activation waveform failed to involve considerable areas of the sRV free wall. Direct pacing of the endocardial surface of the sRV resulted in diffuse and rapid activation This was achieved from multiple sites on the sRV free-wall endocardium extending from the apex to the base.

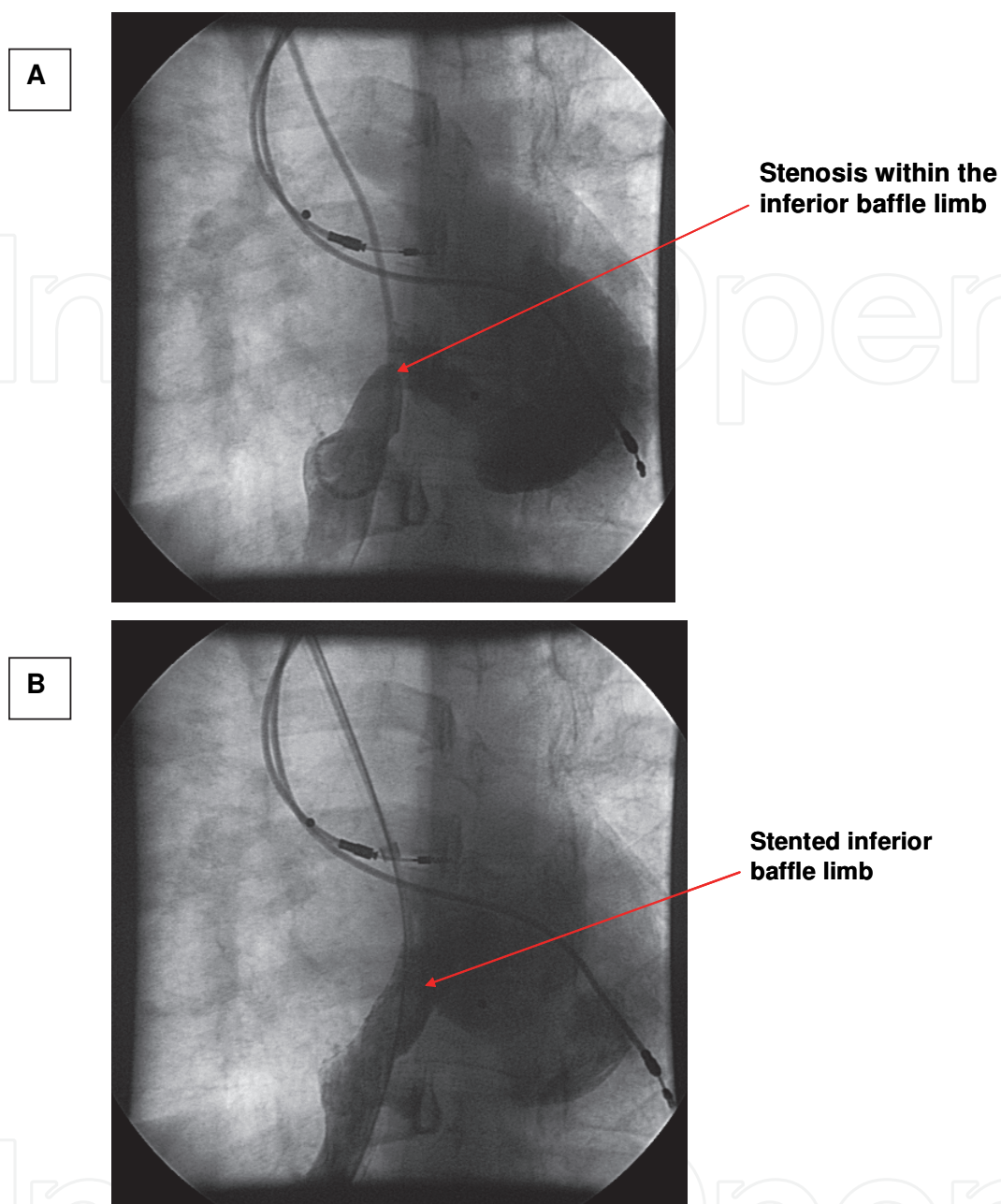


Fig. 4. A. Shows the RA and pLV leads of the existing DDD pacemaker. Contrast injection into the IVC demonstrates a stenosis within the inferior baffle limb but was adequate to allow passage of the pigtail catheter. B. Shows the satisfactory post stent result.

Baffle angioplasty and was initially performed thereafter a 4F lumenless pace/sense active fixation lead ( model 6996, SelectSecure™, Medtronic Inc. ) was deployed using a steerable delivery sheath via a standard left subclavian vein approach with anticoagulation (heparin 1000units/kg maintaining an activated clotting time of  $\pm$  300seconds). The superior limb of the systemic baffle was crossed through the baffle leak and positioned in the antero-basal segment of the sRV (**figure 6**).

Instantaneous intra-arterial blood pressure response was assessed during AAI, DDD (RA+pLV and RA+sRV) and simulated biventricular pacing (BVP) (pLV+ sRV)(2). An arbitrary paced AVD of 110 ms was selected for DDD configurations (**table 5**).

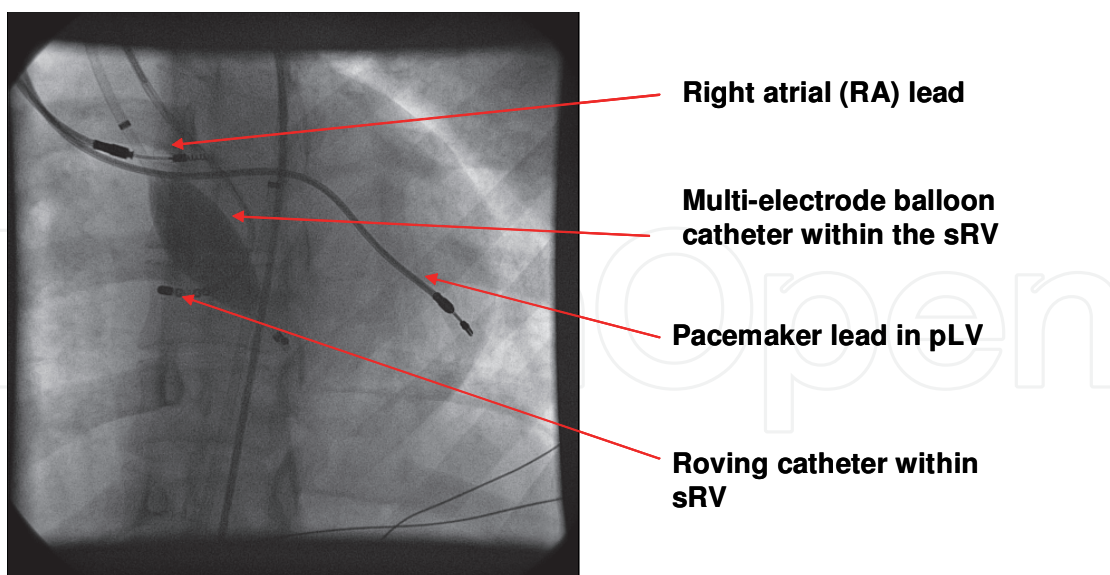


Fig. 5. The MEA catheter is deployed in the sRV. Isopotential maps of the sRV are created from pacing off the RA & pLV leads and from a roving ablation catheter within the sRV.

Despite the shortest activation time of 90ms occurring with AAI pacing, the maximal acute, blood pressure response of 73mmHg( average  $60\pm 9$  mmHg) occurred during BVP (Table 5). An early (1week TTE) and sustained (after 6 months) 43% improvement in EF was also noted (23% to 33%). Effort tolerance improved from NYHA III to II accompanied by a decrease in QRS width from 130 to 120ms during consistent synchronous BVP in DDDR mode. No antitachycardia therapies have thus far been documented.

<i>Blood pressure response during pacing</i>		
	Blood pressure (mmHg)	Mean Blood pressure
AAI	75/43	53
DDD (RA/pLV)*	76/41	55
DDD (RA/sRV)*	78/48	58
BVP (sRV+pLV)	100/58	73
		$60\pm 9$ mmHg
*AVD=110 ms.		

Table 5. Tabulation of the maximal, acute, intra-procedural arterial blood pressure response obtained with each pacing modality. The AVD was arbitrarily set at 110ms.

We have presented here a novel strategy using ventricular activation maps to direct endocardial lead placement in an effort to achieve successful BVP in patients with a Mustard procedure and a failing sRV. The application of CRT has been extrapolated to the adult congenital heart disease population following success in treating patients with

cardiomyopathies. Although no randomised controlled data exists for these patients, there has been documentation in the form of small case series (30). What is apparent is that conventional selection criteria may not apply and that there is variation in technical approaches sometimes requiring a combined endocardial and epicardial system.

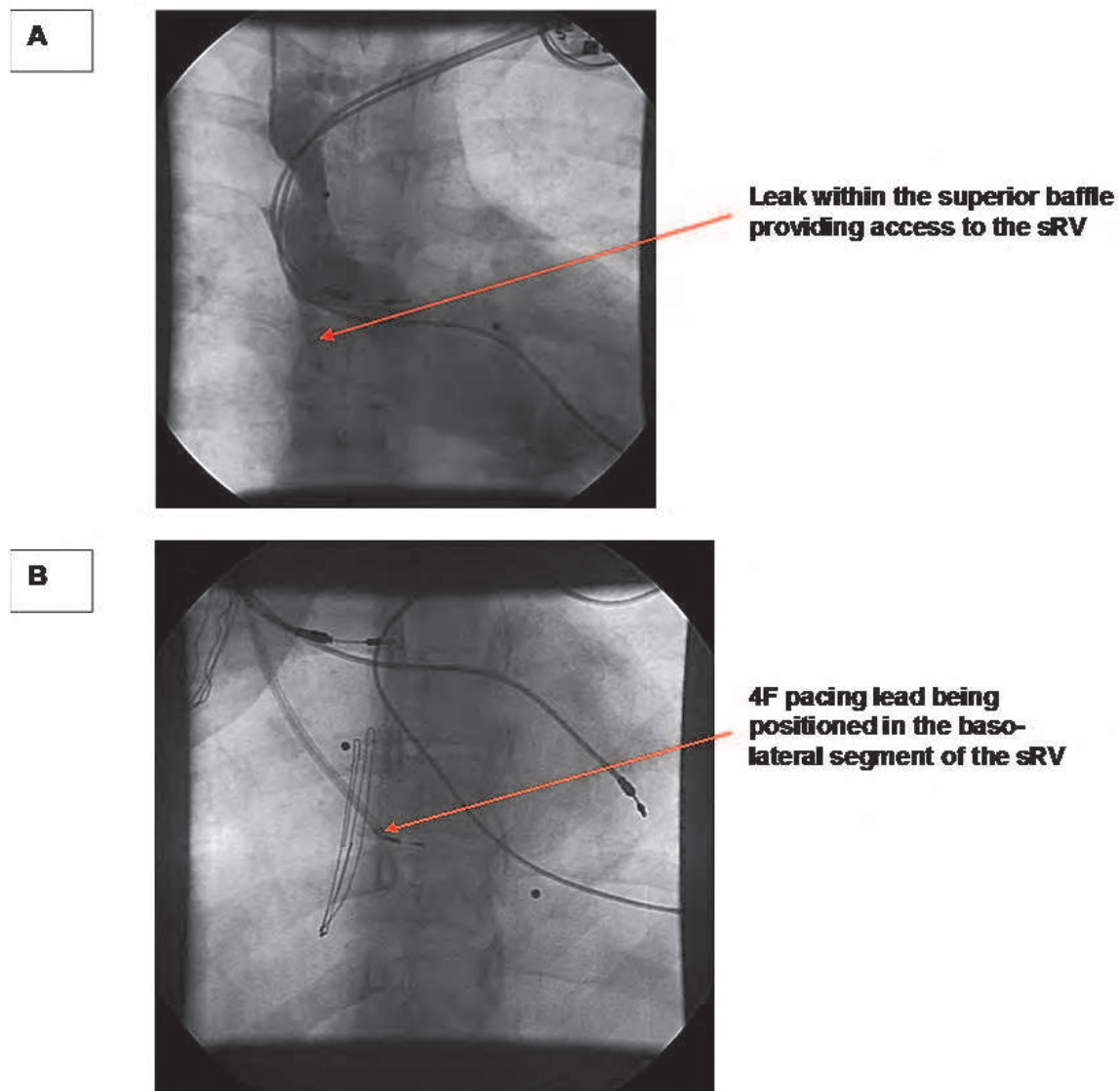


Fig. 6. A. Illustrates a small baffle leak in the superior limb allowing access for a sheath to deliver the 4F pacing lead into the sRV pictures in B.

### 3.2 Conclusion

The advent of atrial redirection surgery heralded potential survival to adulthood for patients with d-TGA who would have otherwise faced inevitable childhood death. However, the late complications arising from this surgery, particularly progressive heart failure and the increase risk of SCD remain challenges for management. The indications and best methods to effect successful CRT/D therapy however remain unknown apart from combined anecdotal evidence. In this patient cohort, we have demonstrated that the pLV to active defibrillator Can was the most successful as was the use of epicardial patches. An

exclusively transthoracic system utilizing subcutaneous electrodes proved unreliable because of the influence of weight in adult patients. A combination of intracardiac, intrathoracic and subcutaneous electrodes is however sometimes necessary to enhance defibrillation efficacy.


The initial experience with CRT using a combined endocardial and epicardial lead system proved inconsistent and may have been because of poor patient selection but also because of suboptimal epicardial lead placement. The use of non contact mapping in addition to echocardiographic criteria was used to define asynchrony and guide endocardial placement of a pacing lead within the sRV. This warranted anticoagulation, but was performed with relative ease.

#### 4. References

- [1] Helbing WA, Hansen B, Ottenkamp J et al. Long-term results of atrial correction for transposition of the great arteries. Comparison of Mustard and Senning operations. *J Thorac Cardiovasc Surg* 1994;108:363-72.
- [2] Poirier NC, Yu JH, Brizard CP, Mee RB. Long-term results of left ventricular reconditioning and anatomic correction for systemic right ventricular dysfunction after atrial switch procedures. *J Thorac Cardiovasc Surg* 2004;127:975-81.
- [3] Konstantinov IE, Alexi-Meskishvili VV, Williams WG, Freedom RM, Van Praagh R. Atrial switch operation: past, present, and future. *Ann Thorac Surg* 2004;77:2250-8.
- [4] Dos L, Teruel L, Ferreira IJ et al. Late outcome of Senning and Mustard procedures for correction of transposition of the great arteries. *Heart* 2005;91:652-6.
- [5] Kammeraad JA, van Deurzen CH, Sreeram N et al. Predictors of sudden cardiac death after Mustard or Senning repair for transposition of the great arteries. *J Am Coll Cardiol* 2004;44:1095-102.
- [6] Warnes CA. Transposition of the great arteries. *Circulation* 2006;114:2699-709.
- [7] Feder E, Meisner H, Buhlmeyer K, Struck E, Sebening F. Operative treatment of TGA: comparison of Senning's and Mustard's operation in patients under 2 years. *Thorac Cardiovasc Surg* 1980;28:7-12.
- [8] Uemura H, Ho SY, Anderson RH et al. Surgical anatomy of the coronary circulation in hearts with discordant atrioventricular connections. *Eur J Cardiothorac Surg* 1996;10:194-200.
- [9] Bashir JG, Frank G, Tyers O, Lampa M, Yamaoka R. Combined use of transesophageal ECHO and fluoroscopy for the placement of left ventricular pacing leads via the coronary sinus. *Pacing Clin Electrophysiol* 2003;26:1951-4.
- [10] Shalaby AA. Utilization of intracardiac echocardiography to access the coronary sinus for left ventricular lead placement. *Pacing Clin Electrophysiol* 2005;28:493-7.
- [11] Roberts PR, Paisey JR, Betts TR et al. Comparison of coronary venous defibrillation with conventional transvenous internal defibrillation in man. *J Interv Card Electrophysiol* 2003;8:65-70.
- [12] Dubin AM, Janousek J, Rhee E et al. Resynchronization therapy in pediatric and congenital heart disease patients: an international multicenter study. *J Am Coll Cardiol* 2005;46:2277-83.
- [13] Diller GP, Okonko D, Uebing A, Ho SY, Gatzoulis MA. Cardiac resynchronization therapy for adult congenital heart disease patients with a systemic right ventricle: analysis of feasibility and review of early experience. *Europace* 2006;8:267-72.



- [14] Mital S, Addonizio LJ, Lamour JM, Hsu DT. Outcome of children with end-stage congenital heart disease waiting for cardiac transplantation. *J Heart Lung Transplant* 2003;22:147-53.
- [15] Bristow MR, Feldman AM, Saxon LA. Heart failure management using implantable devices for ventricular resynchronization: Comparison of Medical Therapy, Pacing, and Defibrillation in Chronic Heart Failure (COMPANION) trial. COMPANION Steering Committee and COMPANION Clinical Investigators. *J Card Fail* 2000;6:276-85.
- [16] Ermis C, Zhu AX, Vanheel L et al. Comparison of ventricular arrhythmia frequency in patients with ischemic cardiomyopathy versus nonischemic cardiomyopathy treated with implantable cardioverter defibrillators. *Am J Cardiol* 2005;96:233-8.
- [17] Stajduhar KC, Ott GY, Kron J et al. Optimal electrode position for transvenous defibrillation: a prospective randomized study. *J Am Coll Cardiol* 1996;27:90-4.
- [18] Gold MR, Khalighi K, Kavesh NG, Daly B, Peters RW, Shorofsky SR. Clinical predictors of transvenous biphasic defibrillation thresholds. *Am J Cardiol* 1997;79:1623-7.
- [19] Schauerte P, Stellbrink C, Schondube FA et al. Polarity reversal improves defibrillation efficacy in patients undergoing transvenous cardioverter defibrillator implantation with biphasic shocks. *Pacing Clin Electrophysiol* 1997;20:301-6.
- [20] Alva C, Horowitz E, Ho SY, Rigby ML, Anderson RH. The feasibility of complete anatomical correction in the setting of discordant atrioventricular connections. *Heart* 1999;81:539-45.
- [21] Roos-Hesselink JW, Meijboom FJ, Spitaels SE et al. Decline in ventricular function and clinical condition after Mustard repair for transposition of the great arteries (a prospective study of 22-29 years). *Eur Heart J* 2004;25:1264-70.
- [22] Politi P, Piccinelli M, Poli PF et al. Ten years of "extended" life: quality of life among heart transplantation survivors. *Transplantation* 2004;78:257-63.
- [23] Bristow MR, Saxon LA, Boehmer J et al. Cardiac-resynchronization therapy with or without an implantable defibrillator in advanced chronic heart failure. *N Engl J Med* 2004;350:2140-50.
- [24] Guarracino F, Cariello C, Danella A et al. Right ventricular failure: physiology and assessment. *Minerva Anestesiol* 2005;71:307-12.
- [25] Dekker AL, Phelps B, Dijkman B et al. Epicardial left ventricular lead placement for cardiac resynchronization therapy: optimal pace site selection with pressure-volume loops. *J Thorac Cardiovasc Surg* 2004;127:1641-7.
- [26] Mair H, Sachweh J, Meuris B et al. Surgical epicardial left ventricular lead versus coronary sinus lead placement in biventricular pacing. *Eur J Cardiothorac Surg* 2005;27:235-42.
- [27] Horenstein MS, Walters H, III, Karpawich PP. Chronic performance of steroid-eluting epicardial leads in a growing pediatric population: a 10-year comparison. *Pacing Clin Electrophysiol* 2003;26:1467-71.
- [28] Furrer M, Fuhrer J, Altermatt HJ et al. VATS-guided epicardial pacemaker implantation. Hand-sutured fixation of atrioventricular leads in an experimental setting. *Surg Endosc* 1997;11:1167-70.
- [29] Jais P, Douard H, Shah DC, Barold S, Barat JL, Clementy J. Endocardial biventricular pacing. *Pacing Clin Electrophysiol* 1998;21:2128-31.
- [30] Janousek J, Tomek V, Chaloupecky VA et al. Cardiac resynchronization therapy: a novel adjunct to the treatment and prevention of systemic right ventricular failure. *J Am Coll Cardiol* 2004;44:1927-31.



## **Cardiac Defibrillation - Mechanisms, Challenges and Implications**

Edited by Prof. Natalia Trayanova

ISBN 978-953-307-666-9

Hard cover, 248 pages

**Publisher** InTech

**Published online** 26, September, 2011

**Published in print edition** September, 2011

The only known effective therapy for lethal disturbances in cardiac rhythm is defibrillation, the delivery of a strong electric shock to the heart. This technique constitutes the most important means for prevention of sudden cardiac death. The efficacy of defibrillation has led to an exponential growth in the number of patients receiving implantable devices. The objective of this book is to present contemporary views on the basic mechanisms by which the heart responds to an electric shock, as well as on the challenges and implications of clinical defibrillation. Basic science chapters elucidate questions such as lead configurations and the reasons by which a defibrillation shock fails. Chapters devoted to the challenges in the clinical procedure of defibrillation address issues related to inappropriate and unnecessary shocks, complications associated with the implantation of cardioverter/defibrillator devices, and the application of the therapy in pediatric patients and young adults. The book also examines the implications of defibrillation therapy, such as patient risk stratification, cardiac rehabilitation, and remote monitoring of patient with implantable devices.

### **How to reference**

In order to correctly reference this scholarly work, feel free to copy and paste the following:

K Michael, B Mayosi, J Morgan and G Veldtman (2011). Expanding Applications of Defibrillators and Cardiac Resynchronization Therapy to Include Adult Congenital Heart Disease, *Cardiac Defibrillation - Mechanisms, Challenges and Implications*, Prof. Natalia Trayanova (Ed.), ISBN: 978-953-307-666-9, InTech, Available from: <http://www.intechopen.com/books/cardiac-defibrillation-mechanisms-challenges-and-implications/expanding-applications-of-defibrillators-and-cardiac-resynchronization-therapy-to-include-adult-cong>

**INTECH**  
open science | open minds

### **InTech Europe**

University Campus STeP Ri  
Slavka Krautzeka 83/A  
51000 Rijeka, Croatia  
Phone: +385 (51) 770 447  
Fax: +385 (51) 686 166  
[www.intechopen.com](http://www.intechopen.com)

### **InTech China**

Unit 405, Office Block, Hotel Equatorial Shanghai  
No.65, Yan An Road (West), Shanghai, 200040, China  
中国上海市延安西路65号上海国际贵都大饭店办公楼405单元  
Phone: +86-21-62489820  
Fax: +86-21-62489821

© 2011 The Author(s). Licensee IntechOpen. This chapter is distributed under the terms of the [Creative Commons Attribution-NonCommercial-ShareAlike-3.0 License](#), which permits use, distribution and reproduction for non-commercial purposes, provided the original is properly cited and derivative works building on this content are distributed under the same license.

IntechOpen

IntechOpen