

We are IntechOpen, the world's leading publisher of Open Access books Built by scientists, for scientists

4,800

Open access books available

122,000

International authors and editors

135M

Downloads

Our authors are among the

154

Countries delivered to

TOP 1%

most cited scientists

12.2%

Contributors from top 500 universities



WEB OF SCIENCE™

Selection of our books indexed in the Book Citation Index
in Web of Science™ Core Collection (BKCI)

Interested in publishing with us?
Contact book.department@intechopen.com

Numbers displayed above are based on latest data collected.

For more information visit www.intechopen.com



Efficacy of Preoperative CT Imaging in Posterior Cervical Spine Surgery

Shiro Imagama and Naoki Ishiguro
*Department of Orthopaedic Surgery,
Nagoya University Graduate School of Medicine
Japan*

1. Introduction

The aging of society has increased the number of cases of cervical spine disorder. Improved surgery, including cervical laminoplasty for posterior decompression, has resulted in favorable outcomes in many cases (Hirabayashi et al. 1981, Kurokawa et al.1983). Instrumentation such as pedicle screws used in lumbar surgery has also been developed for treatment of cervical deformities caused by aging (Abumi et al.1994 & 1997). However, increased use of these surgical methods has also increased the risk of complications (Abumi et al.2000), which must be avoided to obtain good surgical results. Preoperative evaluation using CT imaging is important in cervical spine surgery, since this spine includes the spinal cord and vertebral artery, damage to which has the risk of tetraplegia or may be life threatening (unlike the cauda equina in the lumbar spine). The efficacy and key points of CT imaging for preventing postoperative complications in cervical spine surgery are discussed in this chapter.

2. Preoperative CT imaging in cervical spine surgery

2.1 Posterior decompression surgery (cervical laminoplasty)

2.1.1 Preoperative CT evaluation for safe laminoplasty procedures

Cervical laminoplasty is commonly performed for posterior decompression and gives favorable outcomes. This procedure is simple and effective, but preoperative CT evaluation is important for increasing safety and shortening the operative time. Laminoplasty can be performed using unilateral open door laminoplasty (Hirabayashi et al.1981) or French door laminoplasty (Kurokawa et al.1983). In both procedures, use of an air drill is common to make a gutter on the lamina. Thus, preoperative evaluation of the thickness and extent of sclerosis of the lamina on CT is helpful for making the gutter while avoiding intraoperative iatrogenic injury of the dura mater, nerve root or spinal cord by excessive use of the air drill (Fig.1A,B). Among the C3 to C7 laminae, those at C4 and C5 are generally thin. However, the thickness of each lamina varies with age, gender and disease, and therefore preoperative assessment of the thickness of the lamina is helpful for shortening the operative time. Careful and repeated evaluation of the residual lamina intraoperatively is also important to avoid excessive drilling.

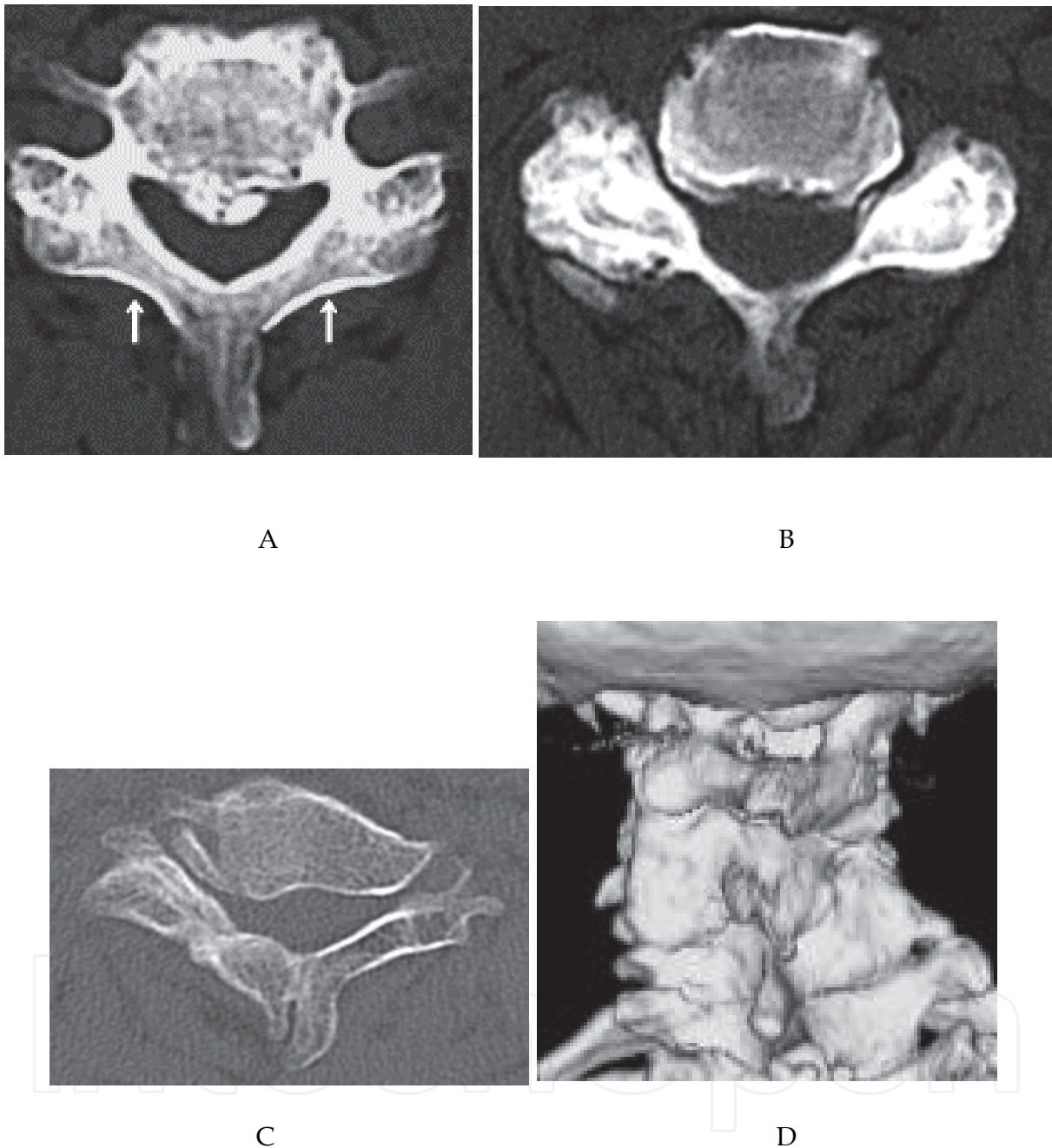


Fig. 1. **Preoperative CT findings.** A. Facet joints had little degeneration, which made it easy to determine the position of the gutter (arrow) B. Since the lamina in this patient was thin, care is required to avoid damage to the dura mater or spinal root during drilling. C, D. In a patient with Klippel-Feil syndrome, the lamina was thick and facet degeneration and fusion can be seen. Spontaneous bony fusion was clear on 3D CT.

Since the gutter is made only at the medial end of the facet joint in laminoplasty (Fig. 1A, arrow), it is important to avoid deformity or degenerative changes of the facet joint and lamina. In patients with cerebral palsy and Klippel-Feil syndrome, facet joints are often

severely degenerated or may have undergone spontaneous fusion (Fig. 1C,1D). In these cases, it may be difficult to identify the position at which the gutter should be made without preoperative evaluation by CT. If the gutter is positioned too laterally, there is a risk of vertebral artery (VA) injury by drilling into the transverse foramen. 3DCT may also be useful for assessment of spontaneous bony fusion (Fig. 1D). Thus, comparison of preoperative CT images with intraoperative findings can avoid disorientation during surgery, while estimation of the lamina thickness on preoperative CT is helpful for use of the air drill.

2.1.2 CT evaluation for predicting a risk of C5 palsy after cervical laminoplasty

C5 palsy is a serious postoperative complication of laminoplasty that can cause paralysis in the upper extremities and severe pain. The incidence of C5 palsy after cervical laminoplasty has ranged from very low to 30% in previous reports (Satomi et al.1994, Wada et al.2001, Chiba et al.2002, Hasegawa et al.2007). C5 palsy has been recognized for 30 years, but preventive and therapeutic methods have yet to be established. Various aspects of the surgical procedure, pathology of the spinal cord, and impairment of the nerve root are implicated as causes of C5 palsy, but its low prevalence in most studies has prevented clarification of the pathology and resultant development of preventive methods.

In a multicenter study performed in 2010, we evaluated radiological findings in patients with C5 palsy (manual muscle test (MMT) score < 3) after cervical laminoplasty and searched for features on preoperative imaging that might help to predict its occurrence (Imagama et al.2010). We reviewed 1858 patients who had undergone cervical laminoplasty in institutes of the Nagoya Spine Group and identified 43 (2.3%) who developed C5 palsy with a MMT (MRC) grade of 0 to 2 in the deltoid, with or without involvement of the biceps, but without loss of muscular strength in any other muscles. These criteria ensured that only cases of definite C5 palsy were included in the analysis. The clinical features and radiological findings were compared for patients with (group P) and without (group C) C5 palsy, using results from plain radiographs, MRI and CT. In this chapter, we focus mainly on the CT findings, which included the width of the intervertebral foramen at C5 (Fig. 2A), the anterior protrusion of the superior articular process of C5 (Fig.2B), the presence of hinge dislodgement, and the position of the bony gutter (Fig. 2C).

CT images were acquired in the horizontal plane of the intervertebral disc. The width of the C5 intervertebral foramen was measured at its narrowest point and the anterior protrusion of the superior articular process of C5 was measured at its most prominent point. The gutter position was expressed as the ratio of the distance between the midline of the vertebral column at C5 and the medial point of the gutter relative to the distance between the midline of the vertebral column at C5 and the most medial part of the facet joint (Fig. 2C). The radiographic measurements (mm) of individual images were adjusted to give the actual length. A Mann-Whitney U test was used for statistical analysis, with $p < 0.05$ taken to indicate significance.

On CT measurements, a difference in width between the intervertebral foramina was found in 20 patients (47%), and in 16 (80%) the side of narrowing corresponded with the side that was paralyzed. In group P, the mean width of the intervertebral foramen was significantly less on the paralyzed side than on the normal side (1.6 vs. 2.1 mm, $p = 0.0043$) (Table 1, Fig. 3).

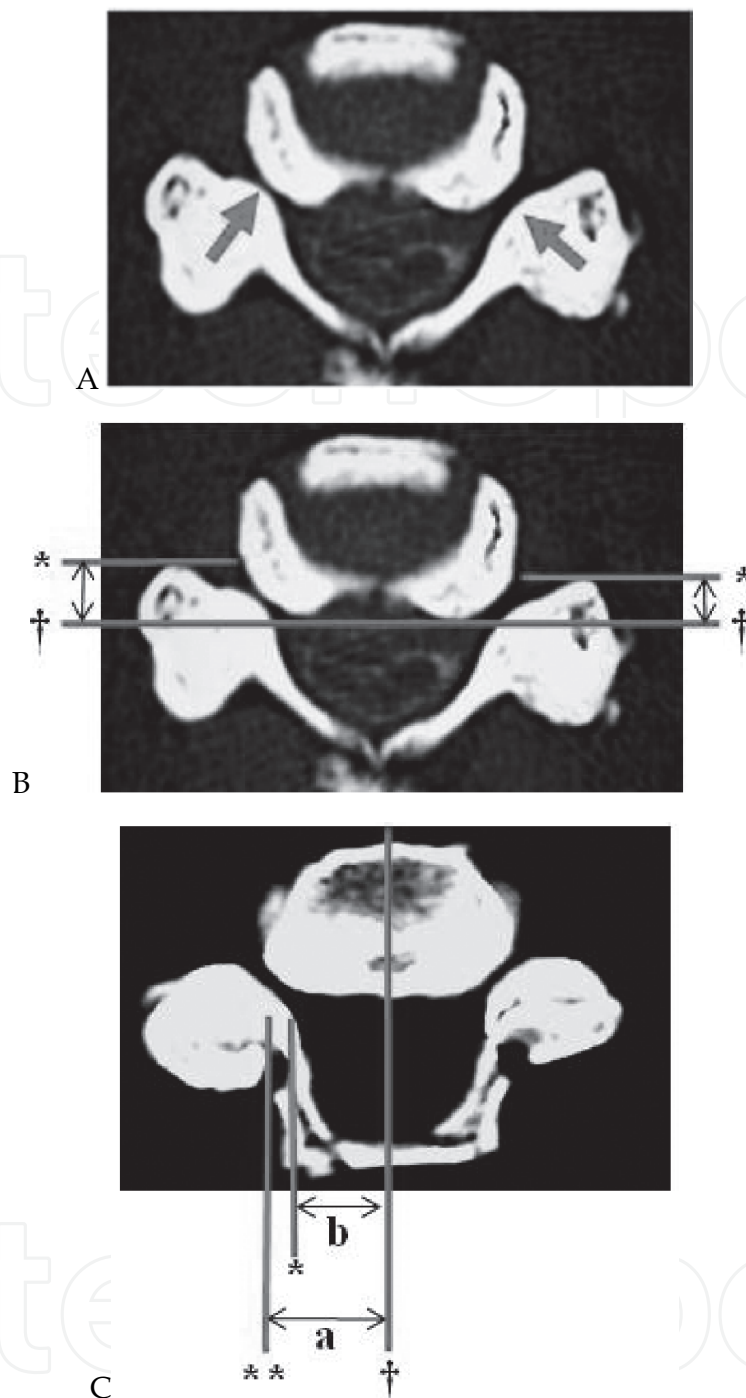


Fig. 2. **Radiological measurements by CT recorded bilaterally.** A) The width of the C5 foramen was measured at the narrowest point (arrow). B) Anterior protrusion of the C5 superior articular process (SAP) (double arrow). † indicates the posterior line of the vertebral column. * indicates the line corresponding to the most prominent site of the C5 SAP parallel to the posterior line of the vertebral column. C) The ratio of the width of the bony gutter and the facet joint, reflecting the position of the bony gutter. † indicates the midline of the vertebral column, * indicates the medial point of the bony gutter, ** indicates the medial point of the facet joint. These lines are vertical to the posterior line of the vertebral column. Distances were measured between † and ** (a), and between † and * (b), and then adjusted to give the actual length.

The mean anterior protrusion of the superior articular process of C5 was significantly greater on the paralyzed side than on the normal side (5.1 *vs.* 4.3 mm, $p = 0.029$). In group C, the mean width of the C5 intervertebral foramen (4.3 mm) was significantly greater and the degree of anterior protrusion of the superior articular process of C5 (3.5 mm) was significantly less than the respective values on the paralyzed or normal side in group P ($p < 0.0001$) (Table 1 and Fig. 4).

	C5 palsy	Control	p value
CT			
Width of the C5 intervertebral foramen (mm)			$p < 0.005^a$
Palsy side (C5 palsy) / right side (control)	1.6 ± 0.15	4.3 ± 0.13	$p < 0.0001^b$
Healthy side (C5 palsy) / left side (control)	2.1 ± 0.22	4.3 ± 0.15	$p < 0.0001^c$
Anterior protrusion of the C5 superior articular process (mm)			$p < 0.05^a$
palsy side (C5 palsy) / right side (control)	5.1 ± 0.38	3.5 ± 0.22	$p < 0.0001^b$
Healthy side (C5 palsy) / left side (control)	4.3 ± 0.39	3.5 ± 0.22	$p < 0.05^c$
Position of the bony gutter (%)			NS ^a
palsy side (C5 palsy) / right side (control)	85.4 ± 2.1	81.6 ± 2.0	NS ^b
Healthy side (C5 palsy) / left side (control)	85.6 ± 3.0	82.4 ± 1.6	NS ^c
MRI			
Number of compression levels	2.9 ± 0.16	2.7 ± 0.09	NS
Most compressive level (C3/4) (cases)	15 (35%)	27 (27%)	NS
HIA (cases)	33 / 43 (77%)	78 / 100 (78%)	NS
HIA level (C3/4) (cases)	8 (24%)	21 (27%)	NS
Focal HIA (cases)	29 (88%)	65 (83%)	NS
Linear HIA (cases)	4 (12%)	13 (17%)	NS
Posterior shift of the spinal cord (C4/5) (mm)	3.9 ± 0.27	3.0 ± 0.21	$p < 0.01$

*Values are given as means and the standard error of the mean.

^a palsy side *vs.* healthy side; ^b palsy side *vs.* control; ^c healthy side *vs.* control

Table 1. Radiological assessment of the C5 palsy and control groups

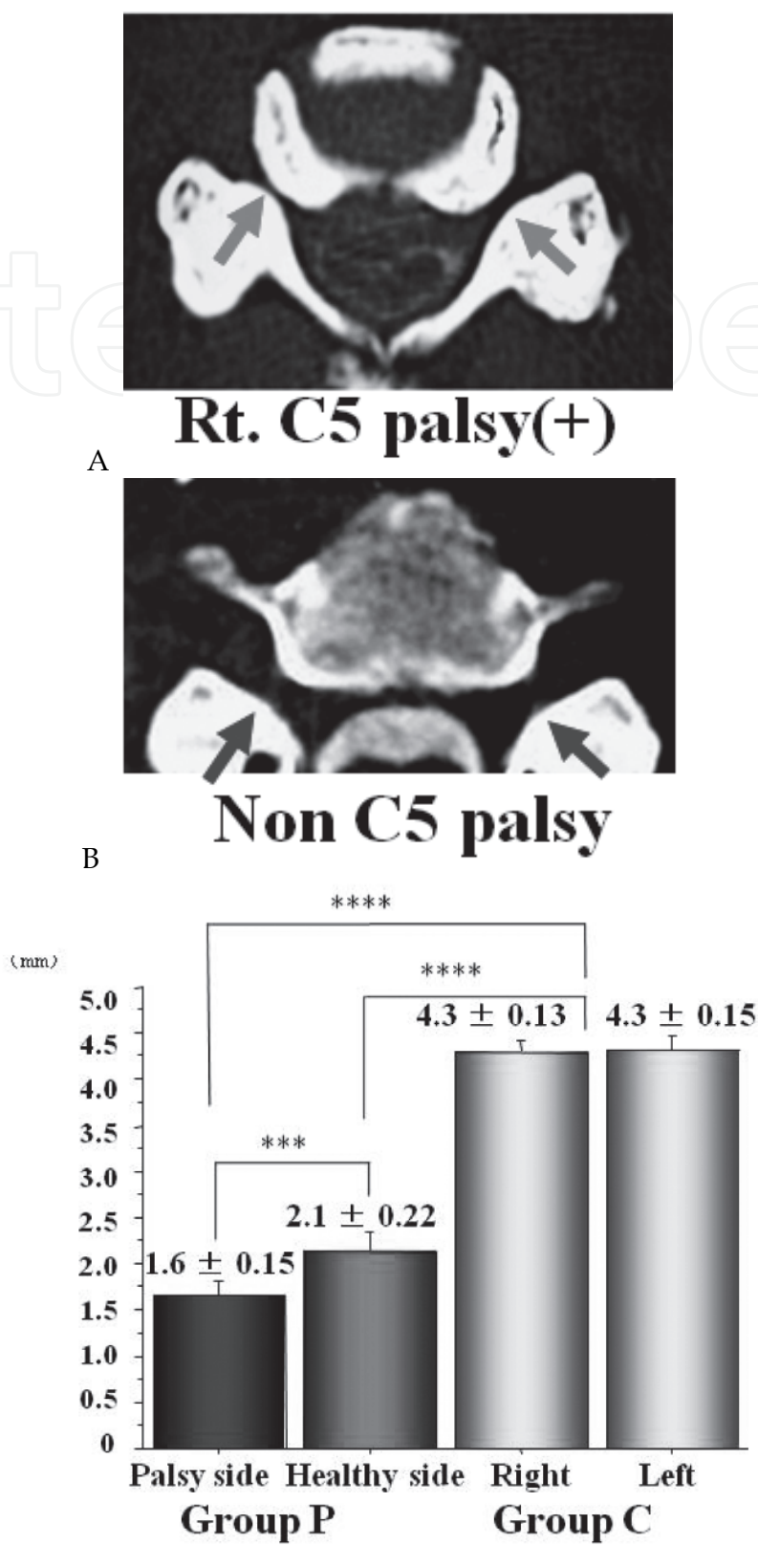


Fig. 3. **Width of the C5 intervertebral foramen.** The width was narrowest on the paralysis side (** $p < 0.005$: palsy side *vs.* normal side, **** $p < 0.0001$ palsy side *vs.* control, **** $p < 0.0001$ normal side *vs.* control).

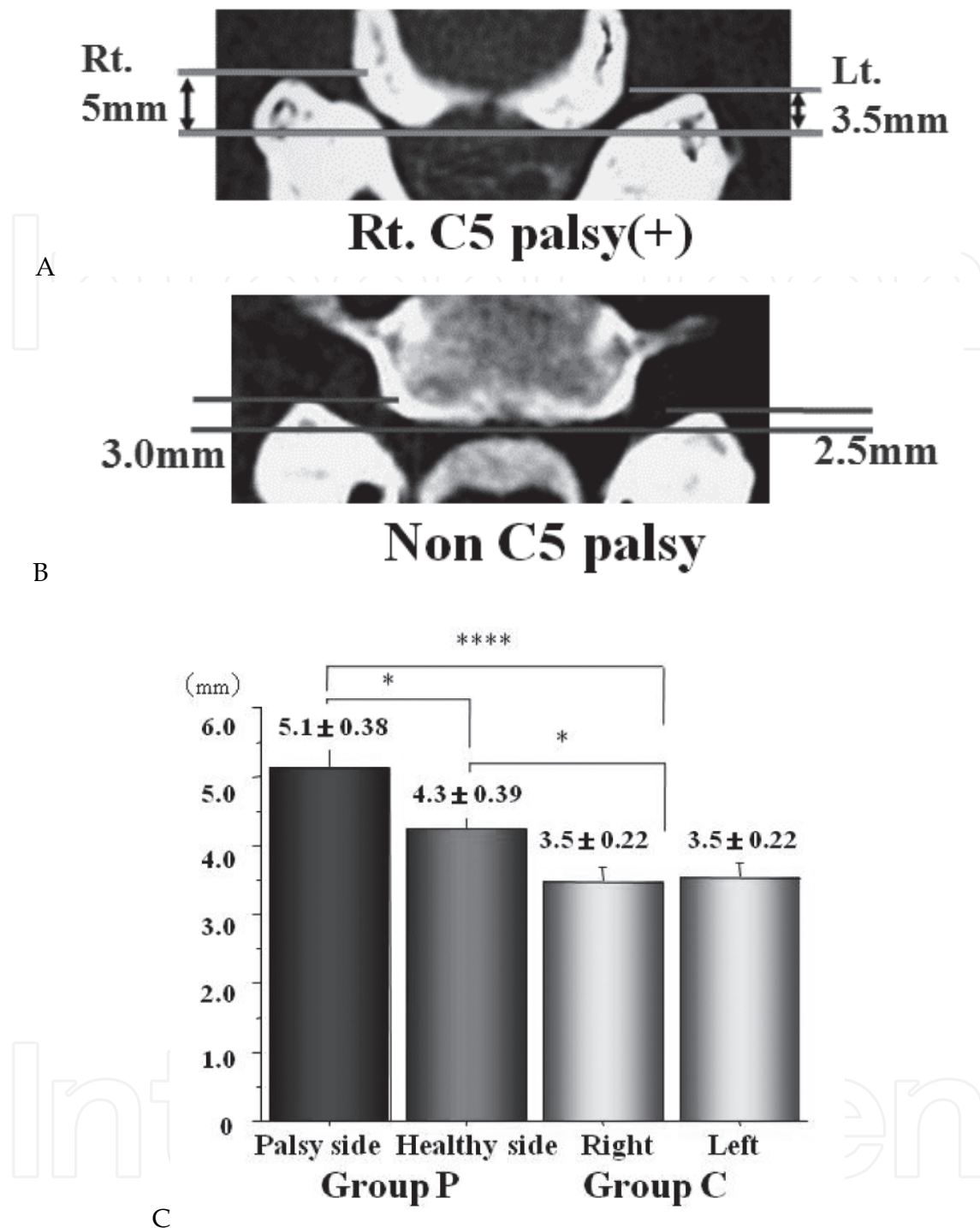


Fig. 4. **Anterior protrusion of the C5 superior articular process.** The protrusion was most prominent on the paralysis side (* $p < 0.05$: palsy side *vs.* normal side, **** $p < 0.0001$ palsy side *vs.* control; * $p < 0.05$ normal side *vs.* control).

In group P the ratios reflecting the position of the bony gutter were 85.4% on the paralyzed side and 85.6% on the normal side, whereas in group C these ratios were 81.6% on the right and 82.4% on the left side, with no significant effect on the development of C5 palsy (Table 1 and Fig. 5). There were no cases of dislodgement of the hinge.

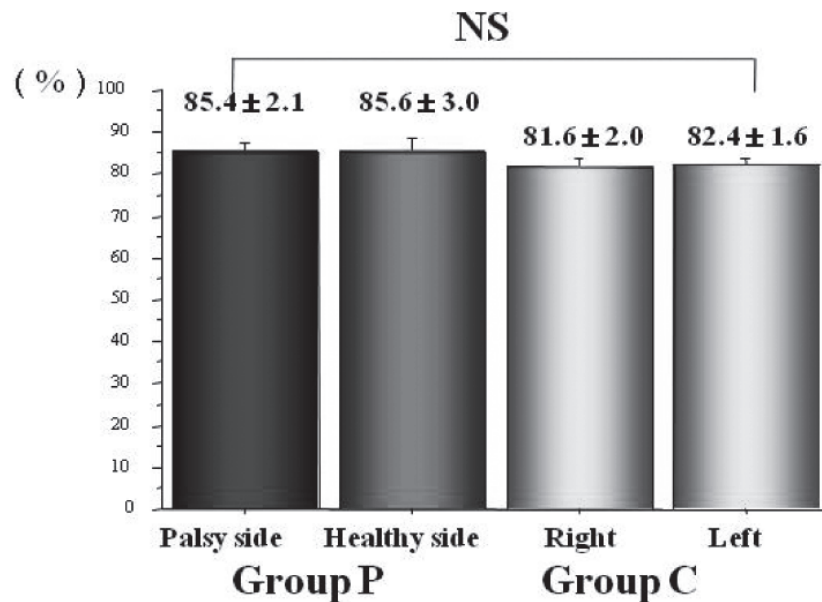


Fig. 5. **Position of the bony gutter.** In group P, the gutter tended to be more lateral than in group C, but there was no significant relationship between the position of the bony gutter and development of C5 palsy.

On MRI, there were no significant differences between the two groups in the number and location of the compressed levels, or in the prevalence and range of the high intensity area. However, the mean postoperative posterior shift of the spinal cord at C4-C5 was 3.9 mm (range: 0 to 7.5 mm) in group P and 3.0 mm (0 to 7.5 mm) in group C ($p = 0.0091$) (Table 1 and Fig. 6). On plain radiographs, there was no significant difference in the cervical lordotic angle, intervertebral angle, local kyphosis angle, cervical alignment, intervertebral instability or listhesis pre- and postoperatively between groups P and C.

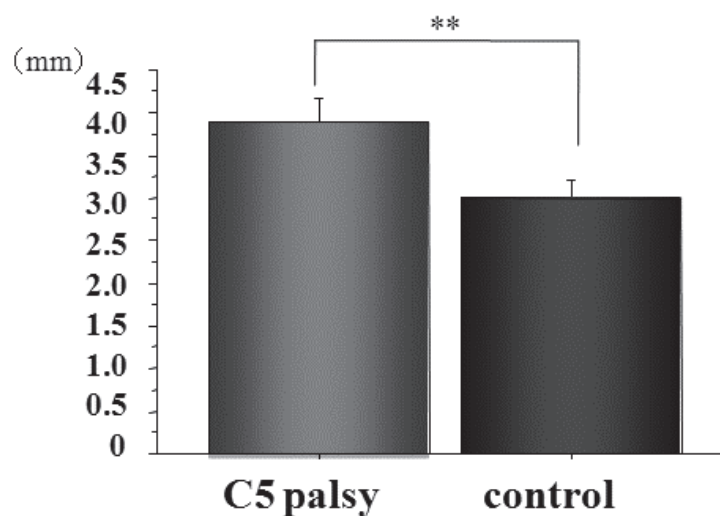


Fig. 6. **Posterior shift of the spinal cord on MRI.** The posterior shift was significantly greater in C5 palsy group (** $p < 0.01$).

These results provided the first imaging evidence of nerve root impairment of C5 palsy using CT and MRI in a multicenter comparative study. Tsuzuki et al. previously suggested that the pathology of C5 palsy includes impairment of the C5 nerve root, based on a demonstration in cadavers that impingement of the nerve root occurs inside the intervertebral joint with backward shifting of the spinal cord after laminoplasty (Tsuzuki et al. 1993). Furthermore, the superior articular process of C5 protrudes in a more anterior direction than those at other levels, the rootlets and root of C5 are shorter than those of other segments, and the C5 segment is usually the point at which the extent of posterior shift of the cord is greatest. These anatomical reasons may account for easier C5 nerve root impingement after laminoplasty. However, radiological evidence of nerve root impingement has not been obtained in previous studies because of the small number of cases and the mixing of patients with C5 palsy with those with paralyses of other nerves. In our study, the significantly greater posterior shift of the spinal cord on MRI in patients with C5 palsy indicated tethering of the nerve root, which might be made worse by the tendency of the bony gutter to adopt a more lateral position in these patients. The CT findings also support this argument. We also found that cases of C5 palsy accompanied by pain in the area of the C5 root accounted for about 80% of those in which root impairment was suspected clinically. This suggests that C5 palsy is more likely to be due to C5 root impairment than to spinal cord pathology.

We speculate that foraminotomy with laminoplasty may be useful for a case in which there is a risk of development of C5 palsy. A significant posterior shift of the spinal cord due to excessive expansion can easily lead to this lesion, and avoidance of tethering of the cord by excessive laminoplasty may prevent postoperative palsy of the C5 nerve root. Most cases of C5 palsy heal after conservative treatment; however, some severe cases do not recover and foraminotomy may be useful to treat patients with C5 palsy associated with severe pain or motor paralysis (MMT = 0 or 1), even after laminoplasty.

2.2 Instrumentation surgery for the posterior cervical spine

2.2.1 Screws in posterior cervical instrumentation

For most degenerative cervical diseases with myelopathy, cervical laminoplasty is sufficient for a good postoperative outcome. However, some patients with cervical kyphosis and/or cervical instability have poor clinical outcomes with posterior decompression surgery only (Abumi et al.1999). In most trauma cases, cervical spine fusion with instrumentation is required. Good correction and fusion can be achieved with instrumentation and this may give good long-term surgical results, even in patients with preoperative cervical spine deformity and cervical instability (Fig. 7A). Recently developed pedicle screws, lateral mass screws and laminar screws have contributed to attainment of strong fixation (Yukawa et al.2006) (Fig. 7B). However, vertebral arteries (VAs) are present in the transverse foramen of the cervical spine and injury to these arteries may cause serious postoperative complications with insertion of these screws. VA injury may increase intraoperative excessive bleeding or postoperative cerebellar infarction due to a thrombus, which may increase mortality. Therefore, careful preoperative evaluation of CT findings is very useful for surgical planning.

2.2.2 Preoperative CT evaluation of the VA for risk management in posterior cervical instrumentation surgery

There is a risk of VA injury when the lamina is exposed, especially at occipital-cervical junctions where the C1 posterior arch is deep and soft tissue is thick. In instrumentation

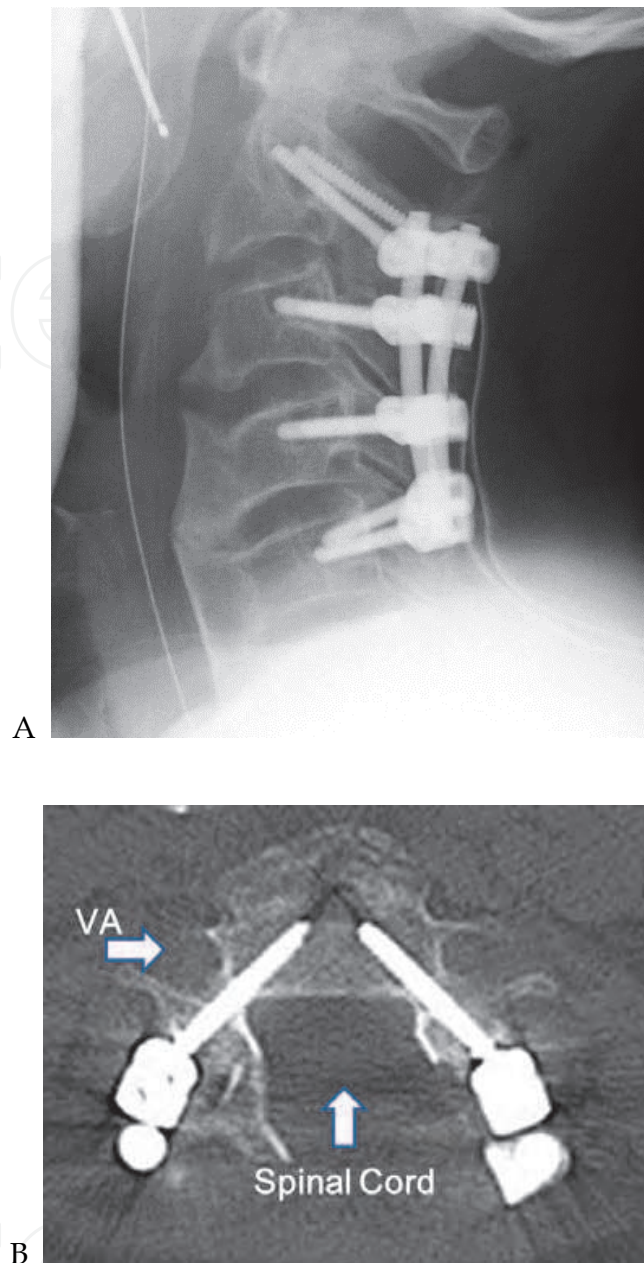


Fig. 7. **Posterior instrumentation surgery for the cervical spine.** A. Postoperative plain radiograph showing good fixation with cervical instrumentation. B. CT showing pedicle screw insertion at C4. A screw was safely placed within the pedicle without injury to the VA and spinal cord.

surgery, more working space for safety and exposure of soft tissue from the cervical spine are required. It is important to define the VA location preoperatively on CT, since the location of the VA varies in individuals. Contrast 3DCT is particularly effective for defining the relationship between the lamina and VA, compared to contrast MR angiography (Fig. 8). If soft tissue is exposed roughly without recognition of the variable VA location, this may lead to VA injury at a very early stage of surgery.

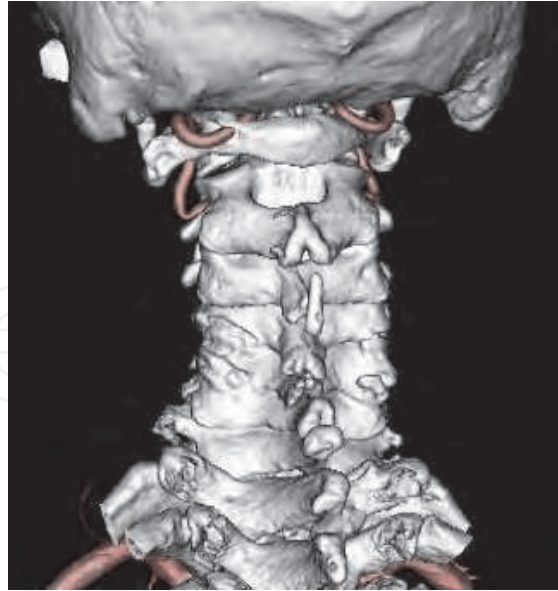

Fig. 8. **Preoperative contrast 3DCT.** 3DCT can be used to define the relationship between the lamina and VA. In this case, there is a risk of left VA injury. 3DCT also clearly revealed facet degeneration at left C4/5 and C5/6.

It is also important to consider anomalies in the C2 transverse foramen when inserting C2 pedicle screws. A high riding VA (a case in which the transverse foramen is located very close to the C2 pedicle) makes it difficult to insert C2 pedicle screws without a high risk of VA injury and the instrumentation should be changed in these cases. Multiplanar reconstruction CT (MPR-CT) images are useful to identify a high riding VA (Fig. 9).

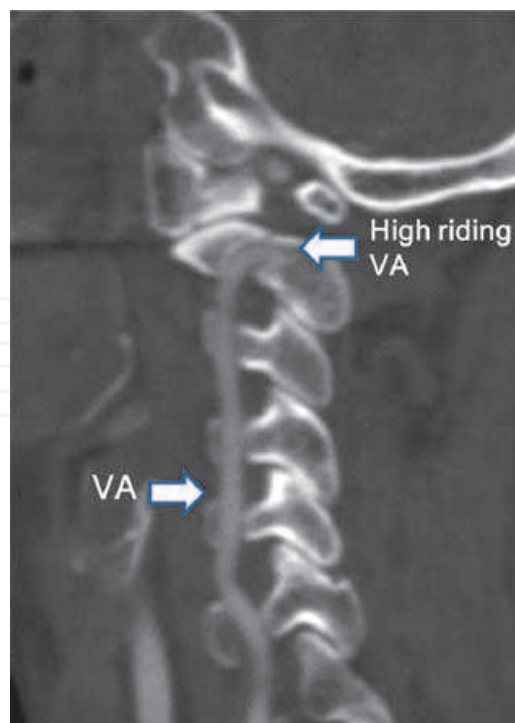


Fig. 9. **High riding VA on preoperative contrast MPR-CT.** This case had a high riding VA at C2 and insertion of a C2 pedicle screw was not performed to avoid VA injury.

For other cervical spine cases, CT findings of the size of the lateral mass and width of pedicles and laminae are very important for achieving successful posterior cervical spine fusion with screw fixation (Fig. 10).

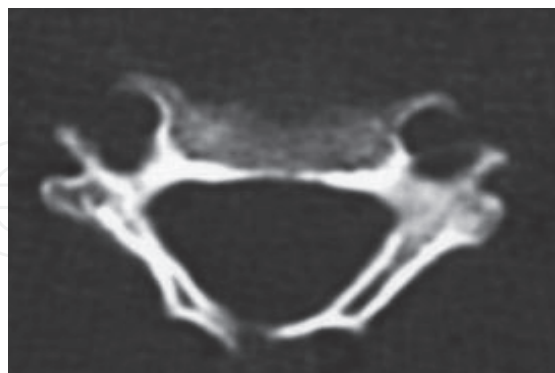


Fig. 10. **Preoperative evaluation of pedicle and lateral mass on CT.** This case had a narrow diameter of the right pedicle with bone sclerosis and a right small lateral mass was present.

For these reasons, evaluation of preoperative CT findings is important for choice of effective and safe anchors for successful cervical instrumentation surgery.

2.2.3 Prediction of the risk of C5 palsy after cervical instrumentation surgery

C5 palsy is also a concern after cervical instrumentation surgery. Several recent studies have shown an increased incidence of postoperative C5 palsy in cases treated with posterior decompression and instrumented fusion (Abumi et al. 2000, Heller et al. 1995, Hojo et al. 2010), with one study showing a rate that was 11.6 times higher than that without instrumentation (Takemitsu et al. 2008). One cause of C5 palsy after instrumented corrective fusion may be iatrogenic foraminal stenosis following correction of cervical alignment. In use of instrumentation for cervical degenerative disease with kyphosis or instability, the aim is both decompression of the spinal cord and forward correction of cervical alignment to a lordotic position. In posterior fusion with instrumentation, the C5 intervertebral foramen may become stenotic after surgery, in addition to the anatomical disadvantages of C5 nerve root impingement after decompression surgery and the apex of cervical lordosis at C5. Therefore, it is important not to overcorrect the cervical deformity and to avoid a compression force between screws, with use of concomitant foraminotomy with instrumented cervical surgery for decompression of the nerve root.

It is difficult to define the appropriate extent of correction to avoid C5 palsy, but we believe that correction to the extent of the preoperative cervical alignment at the cervical extension position may be safe. The effect of foraminotomy for C5 palsy after instrumented cervical surgery is unclear. However, some risk factors for C5 palsy after instrumented cervical surgery were identified by colleagues at our hospital in a review of 84 patients who underwent posterior instrumented fusion using cervical pedicle screws for nontraumatic lesions (unpublished data). The pre- and postoperative width of the C5 intervertebral foramen on CT were significantly narrower in patients that did not develop C5 palsy and postoperative posterior shift of the spinal cord at C4-C5 tended to be greater in those with C5 palsy. These results suggest that concomitant foraminotomy with instrumented cervical spine surgery may be useful for preventing C5 palsy, especially in patients with a narrow C5 foramen preoperatively. Further investigations are needed to examine these issues.

3. Conclusion

In this chapter, we discussed the importance and efficacy of preoperative CT evaluation in posterior cervical spine surgery. Plain CT can reveal detailed bone information, while contrast CT shows the relationship between vascular elements, including the VA, and the spine. The indication of cervical posterior surgery has increased with aging of society and advances in cervical spine surgery. A good surgical outcome is likely in most cases, but preoperative evaluation is important for a good result and avoidance of complications, even in relatively simple procedures such as laminoplasty. There are still problems to resolve in cervical surgery, such as development of C5 palsy, but our CT findings suggest that preventive and therapeutic methods are possible. Thus, CT evaluation is valuable in posterior spine surgery. Further evaluation of the various types of CT imaging (plain, MPR, 3DCT, and contrast) is required to determine the appropriate methods for different types of surgery and disease.

4. Acknowledgement


We are grateful to all the staff of the Nagoya Spine Group for assistance with the multicenter study of C5 palsy.

5. References

- Abumi K, et al. (1994) Transpedicular screw fixation for traumatic lesions of the middle and lower cervical spine: description of the techniques and preliminary report. *J Spinal Disord*;7:19-28.
- Abumi K, Kaneda K. (1997) Pedicle screw fixation for nontraumatic lesions of the cervical spine. *Spine (Phila Pa 1976)*;22:1853-63.
- Abumi K, et al. (1999) Correction of cervical kyphosis using pedicle screw fixation systems. *Spine (Phila Pa 1976)*;24:2389-96.
- Abumi K, et al. (2000) Complications of pedicle screw fixation in reconstructive surgery of the cervical spine. *Spine (Phila Pa 1976)*;25:962-9.
- Chiba K, et al. (2002) Segmental motor paralysis after expansive open-door laminoplasty. *Spine (Phila Pa 1976)*;27:2108-15.
- Hasegawa K, Homma T, Chiba Y. (2007) Upper extremity palsy following cervical decompression surgery results from a transient spinal cord lesion. *Spine (Phila Pa 1976)*;32:E197-202.
- Heller JG, Silcox DH, Sutterlin CE. (1995) Complications of posterior cervical plating. *Spine (Phila Pa 1976)*;20:2442-8.
- Hirabayashi K, et al. (1981) Operative results and postoperative progression of ossification among patients with ossification of cervical posterior longitudinal ligament. *Spine (Phila Pa 1976)*;6:354-64.
- Hojo Y, et al. (2010) A late neurological complication following posterior correction surgery of severe cervical kyphosis. *Eur Spine J*. in press.
- Imagama S, et al. (2010) C5 palsy after cervical laminoplasty: a multicentre study. *J Bone Joint Surg Br*;92:393-400.
- Kurokawa T, Tsuyama N, Tanaka H. (1982) Enlargement of spinal canal by the sagittal splitting of the spinous process. *Bessatsu SeikeiGeka*; 2:234-40.

- Satomi K, et al. (1994) Long-term follow-up studies of open-door expansive laminoplasty for cervical stenotic myelopathy. *Spine (Phila Pa 1976)*;19:507-10.
- Takemitsu M, et al. (2008) C5 nerve root palsy after cervical laminoplasty and posterior fusion with instrumentation. *J Spinal Disord Tech*;21:267-72.
- Tsuzuki N, et al. (1993) Paralysis of the arm after posterior decompression of the cervical spinal cord. I. Anatomical investigation of the mechanism of paralysis. *Eur Spine J*;2:191-6.
- Wada E, et al. (2001) Subtotal corpectomy versus laminoplasty for multilevel cervical spondylotic myelopathy: a long-term follow-up study over 10 years. *Spine (Phila Pa 1976)*;26:1443-7; discussion 8.
- Yukawa Y, et al. (2006) Cervical pedicle screw fixation in 100 cases of unstable cervical injuries: pedicle axis views obtained using fluoroscopy. *J Neurosurg Spine*;5:488-93.

IntechOpen



CT Scanning - Techniques and Applications

Edited by Dr. Karupppasamy Subburaj

ISBN 978-953-307-943-1

Hard cover, 348 pages

Publisher InTech

Published online 30, September, 2011

Published in print edition September, 2011

Since its introduction in 1972, X-ray computed tomography (CT) has evolved into an essential diagnostic imaging tool for a continually increasing variety of clinical applications. The goal of this book was not simply to summarize currently available CT imaging techniques but also to provide clinical perspectives, advances in hybrid technologies, new applications other than medicine and an outlook on future developments. Major experts in this growing field contributed to this book, which is geared to radiologists, orthopedic surgeons, engineers, and clinical and basic researchers. We believe that CT scanning is an effective and essential tools in treatment planning, basic understanding of physiology, and and tackling the ever-increasing challenge of diagnosis in our society.

How to reference

In order to correctly reference this scholarly work, feel free to copy and paste the following:

Shiro Imagama and Naoki Ishiguro (2011). Efficacy of Preoperative CT Imaging in Posterior Cervical Spine Surgery, CT Scanning - Techniques and Applications, Dr. Karupppasamy Subburaj (Ed.), ISBN: 978-953-307-943-1, InTech, Available from: <http://www.intechopen.com/books/ct-scanning-techniques-and-applications/efficacy-of-preoperative-ct-imaging-in-posterior-cervical-spine-surgery>

INTECH
open science | open minds

InTech Europe

University Campus STeP Ri
Slavka Krautzeka 83/A
51000 Rijeka, Croatia
Phone: +385 (51) 770 447
Fax: +385 (51) 686 166
www.intechopen.com

InTech China

Unit 405, Office Block, Hotel Equatorial Shanghai
No.65, Yan An Road (West), Shanghai, 200040, China
中国上海市延安西路65号上海国际贵都大饭店办公楼405单元
Phone: +86-21-62489820
Fax: +86-21-62489821

© 2011 The Author(s). Licensee IntechOpen. This chapter is distributed under the terms of the [Creative Commons Attribution-NonCommercial-ShareAlike-3.0 License](#), which permits use, distribution and reproduction for non-commercial purposes, provided the original is properly cited and derivative works building on this content are distributed under the same license.

IntechOpen

IntechOpen