

# We are IntechOpen, the world's leading publisher of Open Access books Built by scientists, for scientists

4,800

Open access books available

122,000

International authors and editors

135M

Downloads

Our authors are among the

154

Countries delivered to

TOP 1%

most cited scientists

12.2%

Contributors from top 500 universities



WEB OF SCIENCE™

Selection of our books indexed in the Book Citation Index  
in Web of Science™ Core Collection (BKCI)

Interested in publishing with us?  
Contact [book.department@intechopen.com](mailto:book.department@intechopen.com)

Numbers displayed above are based on latest data collected.  
For more information visit [www.intechopen.com](http://www.intechopen.com)



# Cone-Beam Volumetric Imaging in Craniofacial Medicine

IntechOpen

Corega Claudia, Avram Adrian,  
Nocini Pier Francesco and Bertossi Dario  
*Eberhardt-Karls University, Iuliu Hatieganu University,  
University of Verona Germany, Romania,  
Italy*

## 1. Introduction

Few new technological developments have revolutionized medical diagnostics as extensively as has x-ray technology. Even before Wilhelm Conrad Rontgen officially announced his discovery on December 28, 1895, it was used among others by the Austrian physician Guido Holzkecht.

With the development of x-ray computered tomography (CT) in the 1960s and its first use for clinical studies in 1972 by Sir Godfrey Hounsfield, radiological tomography attained widespread use and today is one of the essential imaging techniques in medical radiology. It is a technically mature and clinically widely accepted method and complements classical x-ray panoramic radiography in many areas.

The development of spiral CT and the introduction of multislice detector systems in 1998 further accelerated CT techniques and led to the ability to acquire volume data.

A subsequent development of CT technology, digital volume tomography, as we will refer to it in this bookchapter has been established in recent years. The technology is frequently used in craniofacial radiology because of its characteristic low radiation dose (1-2), high spatial resolution and lower cost compared with CT. Its technology and a lot of possible applications in craniofacial medicine are discussed in this chapter.

Currently voxel-based craniofacial medicine and surgery are becoming increasingly popular. Furthermore they are a popular tool for diagnosing, planning, monitoring and evaluation of craniofacial morphology, growth and various treatment procedures.

The aim of this work is:

- a. to describe the principles of Cone-Beam Tomography
- b. to make a brief description of the existing CBCT devices.
- c. to highlight the use of 3D diagnosis in craniofacial medicine.

## 2. Principles of cone-beam tomography

Image reconstruction in modern computed-assisted imaging techniques such as magnetic resonance imaging (MRI), single-photon emission CT (SPECT) and positron emission tomography (PET) is based on mathematical algorithms that permit axial tomographic imaging of the human body without superimpositioning. The progressive development of

detector technology and reconstruction mathematics and the reduction of radiation exposure have allowed the generation of increasing numbers of single-slice images, particularly in CT.

In contrast to the classical process of radiology, where a single slice is sharply imaged but all other layers in the beam path overlay the desired image, the digital imaging process of CT permits the use of computer-supported reconstruction algorithms to generate image slices of the human body without superimpositions. (El-Mohri, Y et al., 2011)

This is always based on the superimposition-free measurement of the distribution of a tissue layer in a transverse slice. Integrals are measured over this distribution along curves. The separation of the individual slices is performed by the measurement process itself: that is, focus and detector are always in the plane of the slice to be examined, and the electromagnetic beam scans only this slice. Consequently, image reconstruction in the CT process is a two-dimensional issue.

This 2 D issue generates a 3D image and this reconstruction algorithm is based on the one developed by Feldkamp in 1984. The radiation doses are also measured in Sievert or microSievert. Koyama et al., 2010 demonstrated that a conventional CT multislice acquisition is 1,5 to 12,3 times the dose of a CBCT, which equals to 3 -5 panoramic x-rays. (Table 1).

Panoramic x-ray	2,9-9,6
Maxillary CBCT	17,6-656,9
Mandibular CBCT	124,9-250,3
TOTAL	145,4-916,8
CT	50,3

Table 1. Radiation doses in microsievert for various conventional X-ray versus CBCT

These doses are extremely lower if compared to a conventional CT. Especially in orthodontics and maxillo-facial and plastic surgery there is always a need for a combination of CT scans, panoramic and cephalograms, and this can be nowadays achieved in a single step with the CBCT machine. (Kaepler, 2010)

### 3. CBCT devices

The first CBCT machine was a fixed unit and its introduction opened new horizons in the craniofacial medicine. In the operating theaters the use of a CBCT has been restricted to a few cases due to the lack of space for such a machine or due to the efforts required by patient transportation for the image acquisition, not always possible in various pathology.

Once this fixed CT unit has been developed for the craniofacial medicine, the work has been proceeding on a mobile 3D imaging system for use in the operating room. Such a system coupled to a navigation system would be helpful in shortening procedures and preventing complications in complex surgical procedures of the visceral and osseous cranium. This problem was solved by the introduction of CBVI (cone-beam volumetric imaging) into mobile C-arms and permits the integration of the most current Newtom 5G (QR Verona Systems, Italy), Galileos (Sirona, Germany), BrainLAB (USA), Medtronic (USA), Praxim and Stryker (USA) navigation systems. This digital volume tomography with mobile C-arms requires less space, effort and provides better patient access than conventional intraoperative CT scans.

## 4. 3D Diagnosis in craniofacial medicine

In pre- and postnatal development, malformations can affect any part of the head and neck. These malformations can have a genetic or environmental etiology and their diagnosis is of great importance for the dental practitioners. An extensive study of the anatomical features of malformations, possible due to the reduced amount of radionations produced by CBCT, can be useful both for therapeutical and research purpose, providing the basis for a successful treatment plan and setting the anatomical landmarks that may recur in syndromes. ( Bamgbose et al.,2008 )

### 4.1 Abnormalities in tooth number and morphology

These abnormalities justify the use of radiological images in the dental and jaw region but results must be always compared with the clinical findings.

The dental practitioners' task is to correctly assess the information that is obtained in the images in order to set up the necessary therapeutic procedures. The 3D CBCT images supply the additional information and allow a more accurate treatment planning so that the dentist can define the appropriate therapeutic procedures; very often, in fact, radiological findings may significantly differ from the clinical findings, resulting in remarkable changes in clinical treatment planning. (Song et al., 2010 )

### 4.2 Various manifestations of eruption disturbances

Eruption disturbances require an accurate determination of tooth position relative to the adjacent anatomical structures. 3D Diagnosis facilitates this task and also allows a prognosis regarding the course of continuing therapy. In orthodontic treatment planning, the assessment of the position and degree of teeth impaction and ankylosis, bone quality and the spatial relationships with the adjacent dental structures permits a prognosis for the successful orthodontic adjustments. The extent of the surgery required in some cases in order to facilitate the eruption or for extraction purposes can be determined given the characteristics of the malformation (e.g. ankylosis), thus assessing the operative risk. By means of accurate CBCT metric diagnosis, surgery can be optimally prepared and the surgical access can be planned to protect tissue. Depending on the degree of displacement, navigation-guided surgery can be used for a minimally invasive surgical approach. The resulting spatial orientation shortens the surgical time and reduces the degree of postoperative symptoms. In Figure 1 and 2 one might notice the third molar impaction in panoramic digital imaging extracted from CBCT and detail (slice). (Becker et al., 2010 )

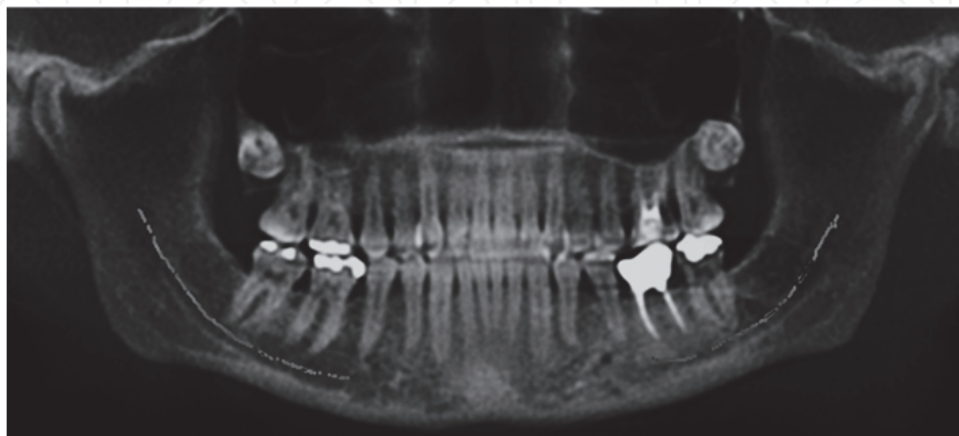


Fig. 1. Third molar impaction in the maxilla

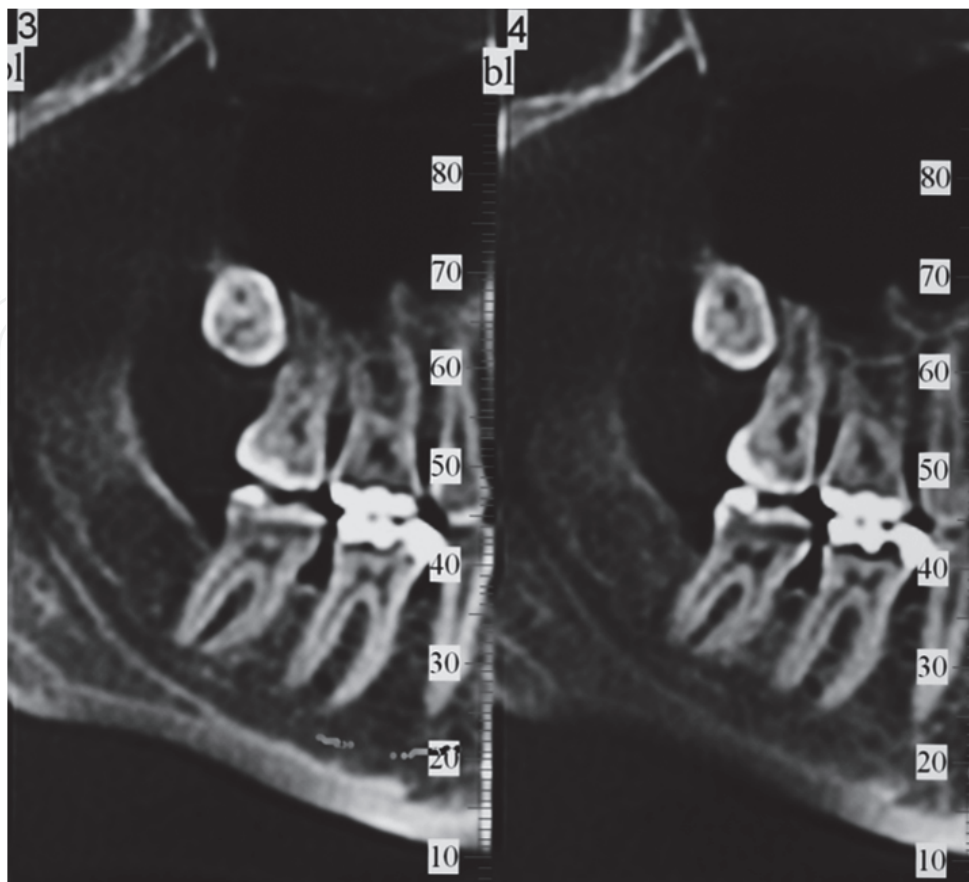


Fig. 2. Third molar impaction (slice detail)

#### **4.3 Cystic changes in the maxilla and the mandible, non-neoplastic lesions, diseases of the maxillary sinus, diseases of the salivary glands, malignant and non-malignant tumors of the maxilla and the mandible**

The broad spectrum of these lesions require precise radiodiagnostic assessment. CBCT permits the individual selection of the planes, meeting the demand for dynamic multiplanar imaging without distortions. In particular, the channel of the inferior alveolar nerve relative to a cyst or a tumor can be visualized with sufficient accuracy for planning mandibular surgery. Given the high contrast of the pathological processes of the maxilla, CBCT is highly suitable for maxillary sinus diagnosis. Although MRI may be more effective in analyzing the bony and soft tissues involvement in this category of pathologies, the details that CBCT can provide concerning the peculiarities of the inferior alveolar nerve are hardly matched by other methods of investigation, regardless of the possible artifacts that may occur due to the interference of dental materials (Rosenberg et al., 2010 ). Fig 3 and 4 highlight the distance from a cystic lesion in a Gorlin-Goltz syndrome to the inferior alveolar nerve , thus facilitating the surgical approach.

#### **4.4 Periodontal diseases and preprosthetic surgery**

CBCT assists in evaluating and analyzing tridimensionally a periodontal disease as well as the preprosthetic surgery situation. Intraosseous defects with one, two, three walls can be distinguished and furcation involvement can be classified. CBCT images are more likely to correspond with the clinical situation for horizontal and vertical bone loss. Unusual features

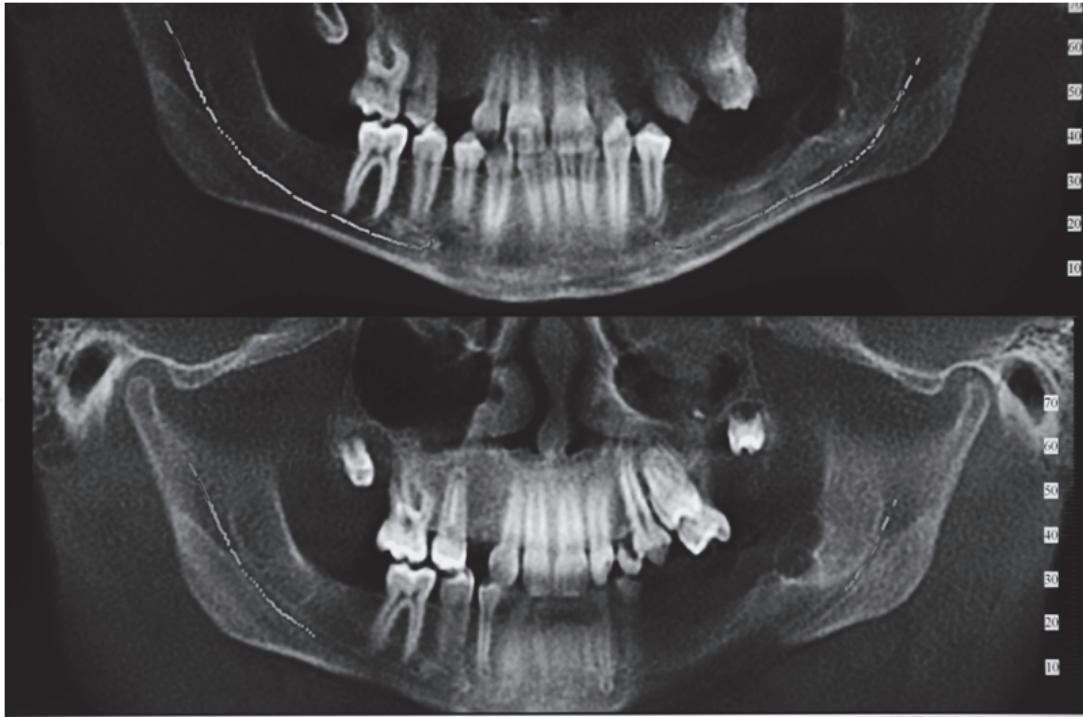


Fig. 3. Distance between the cyst and alveolar nerve in a Gorlin Gotz syndrome

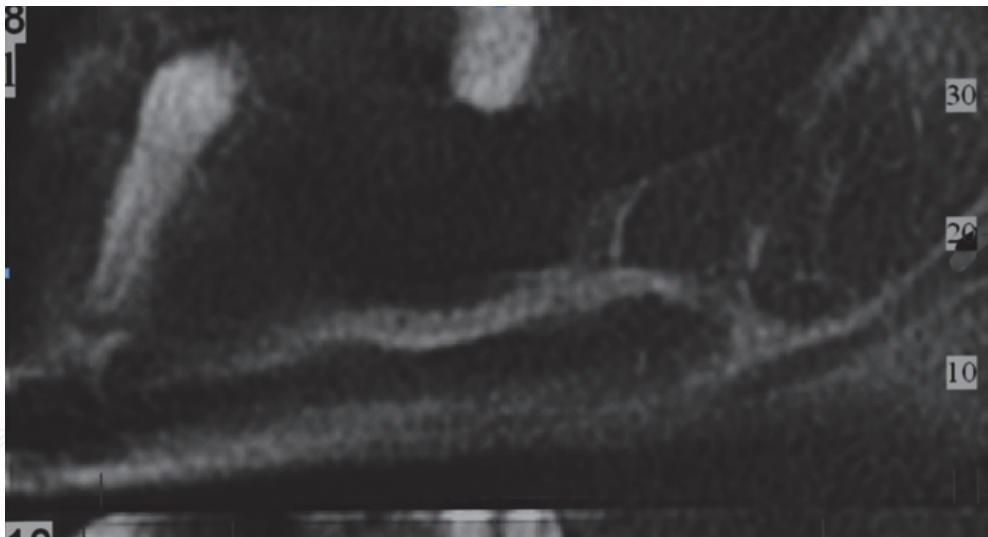


Fig. 4. The distance between the cyst and alveolar nerve in a Gorlin Gotz syndrome (detail)

are more readily identified and localized by radiology and it is more likely to estimate the real dimensions of the defect precisely prior to the surgical procedures, thus conferring to the surgeon a considerable advantage in terms of treatment planning and prevention of complications. The same is for wider bone defects, in which we can observe exactly the mandibular nerve and the maxillary sinuses as well as transverse defects which have to be treated with expansion or grafts without any distortion ( Danfort et al., 2010, Heiland et al., 2008, Boeddinghaus et al., 2008 ).

Maxillary and mandibular bone atrophy is accurately visualised on a 3D reconstruction or in CBCT slices (Fig.5 and 6). The clinical situation after bone grafting is revealed in the same

projection postoperatively ( Fig. 7 and 8). Also CBCT slices reveal details about the extent of mandibular atrophy and the position of the inferior alveolar nerve.

CBCT is used more and more in implant surgery in order to acquire detailed anatomical informations, to produce a 3D stereolitographic model and finally to generate the surgical guide.

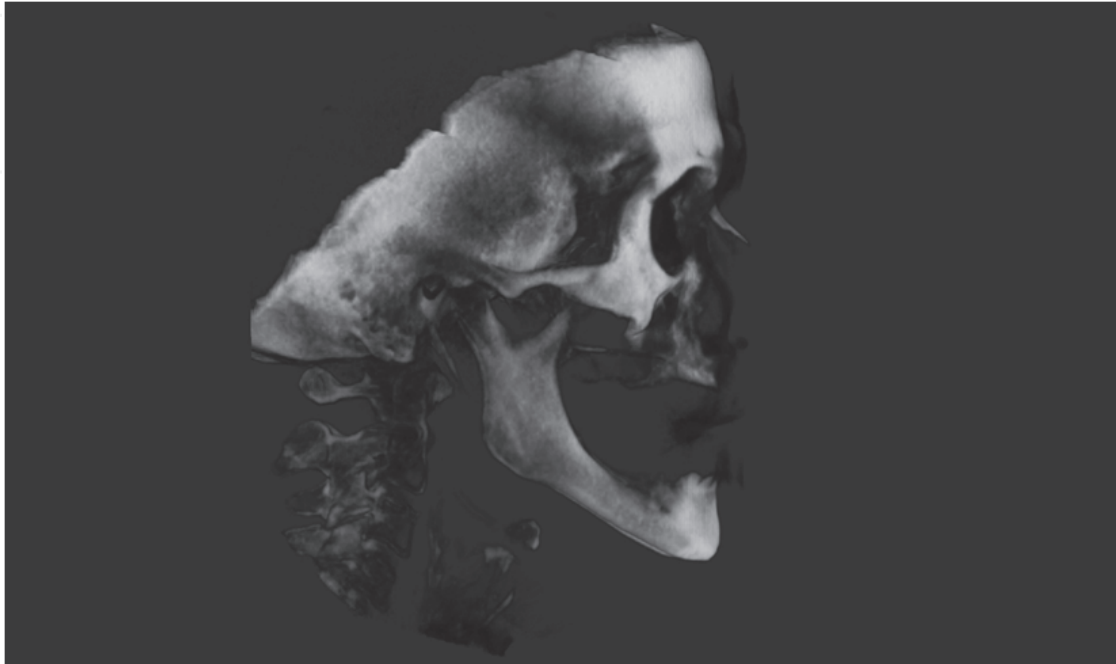


Fig. 5. Maxillary and mandibular bone atrophy- 3D reconstruction

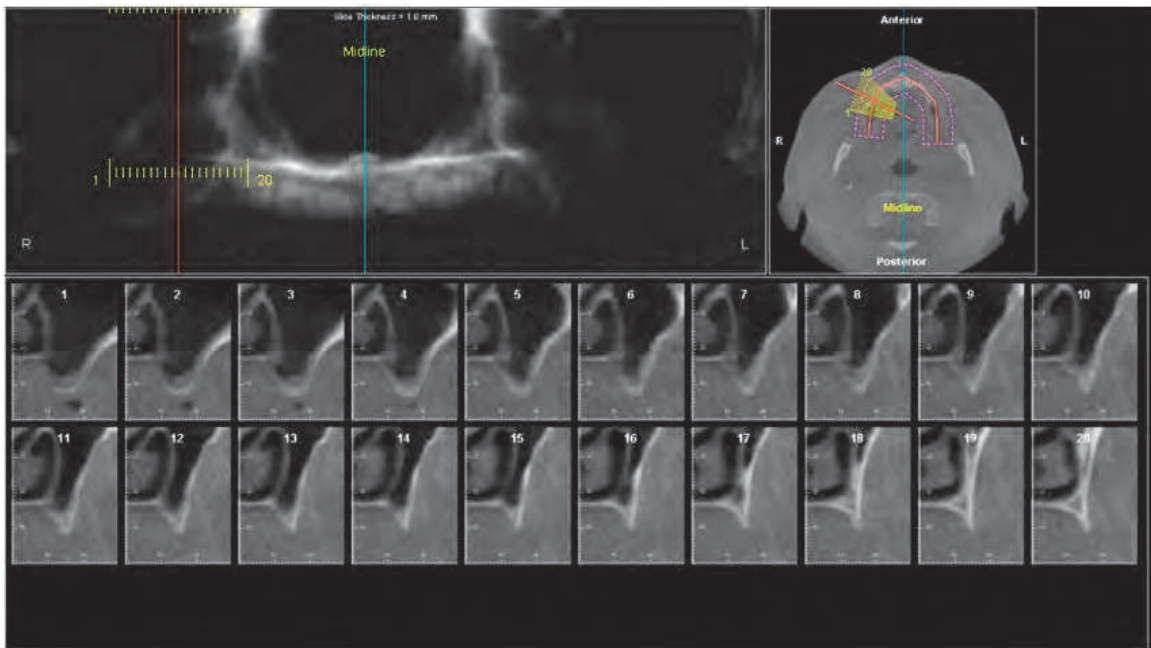


Fig. 6. Bone atrophy of the maxilla (detail)

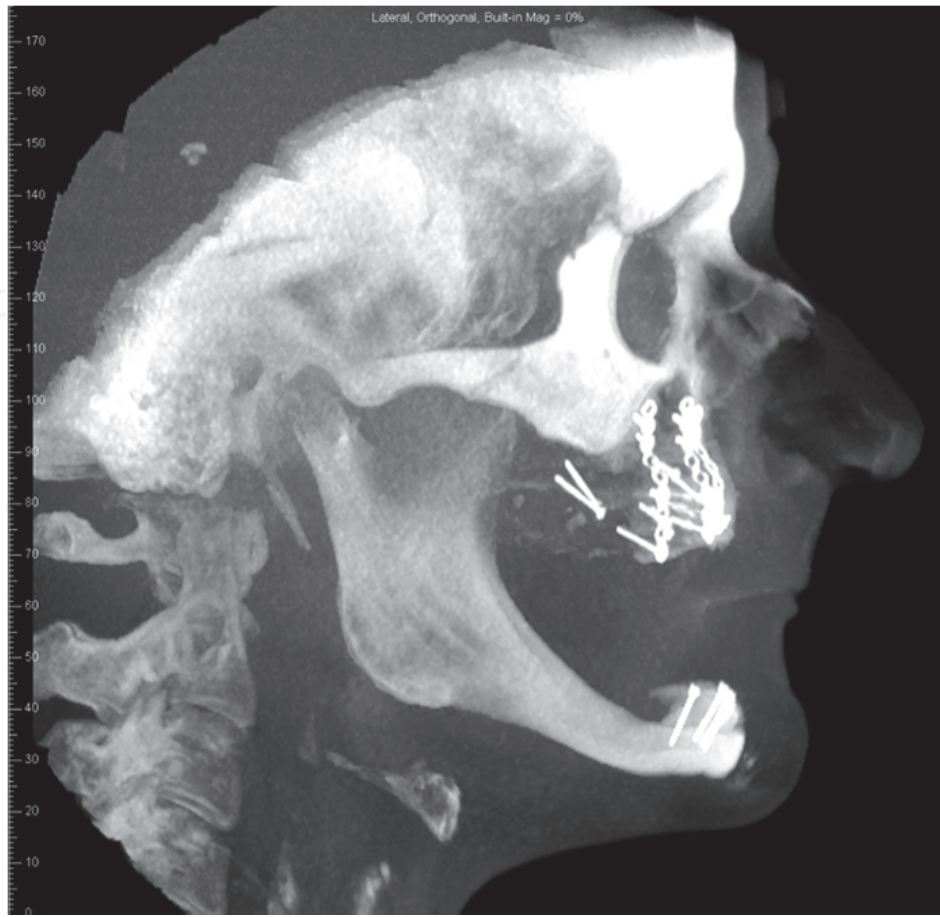


Fig. 7. 3D Reconstruction of the clinical situation after bimaxillary bone grafting

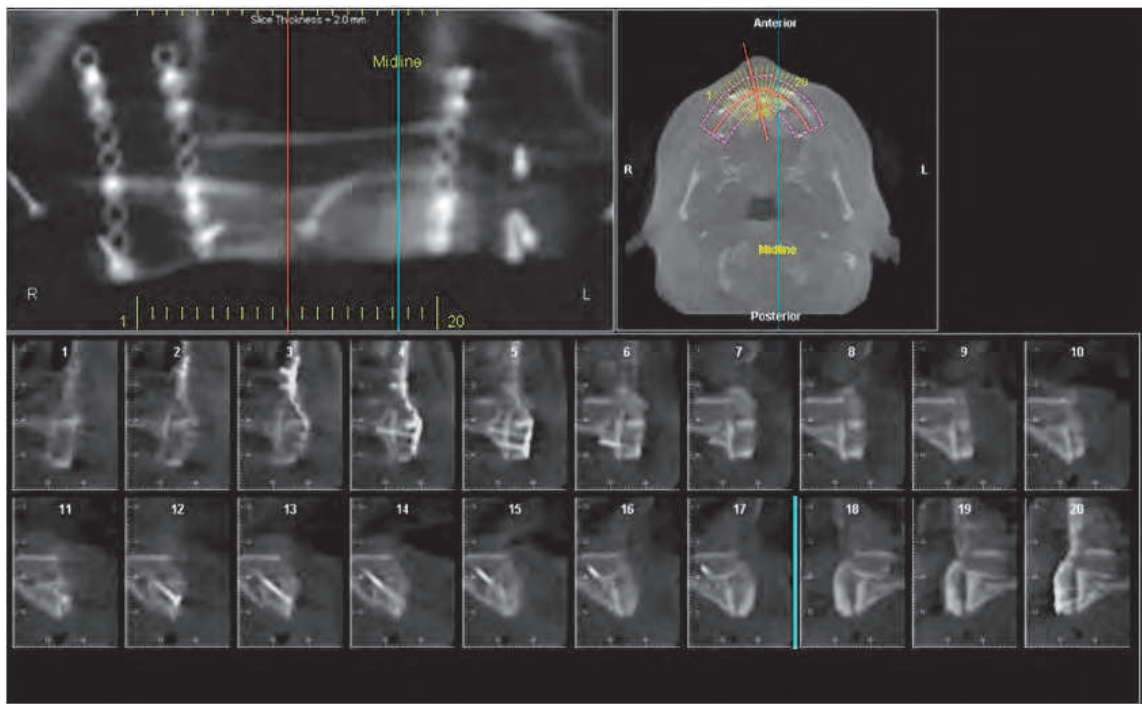


Fig. 8. Maxilla after bone grafting (detail)



#### 4.5 Orthodontic diagnosis and treatment planning

Malocclusions can involve a deviation in tooth position as well as sagittal, vertical and transverse changes in the positional relationship between maxilla and mandible. Each malocclusion can derive from functional, dentoalveolar and skeletal changes. The individual findings obtained in orthodontics permit the establishment of a differential diagnosis and the combination of the individual findings into an overall orthodontic summary, which can be addressed in orthodontic therapy.

Radiographic 3D diagnosis provides the orthodontist with information that might greatly influence the treatment plan. Dentoalveolar malpositions in mesiodistal or buccolingual directions can be precisely evaluated and taken into account in therapeutic planning. Furthermore, the cause of malpositions of groups of teeth can be identified with 3D diagnostics. Both 3D reconstructions of the skull and bidimensional projections can be achieved from a single radiographic exam, with a lower x-ray dose and a more natural shape of soft-tissue facial mask. When examining skeletal deviations, 3D visualization offers new possibilities for evaluating craniofacial structures and will allow a more precise differential diagnosis in the future. Given all the previous considerations and the great values of the achievable data, it is possible to sustain that the use of CBCT as gold-standard for the analysis of the cranio-maxillo-facial region in orthognathic surgery is desirable, since it will permit to merge the advantages of traditional cephalometric studies and new databases that can be developed from the volumetric data collectable ( Lyoid et al., 2011, Tucker et al., 2010, Swennen et al., 2009 ).

A 3D shot of the postsurgical position of the upper maxilla after a Le Fort I osteotomy is possible due to the panoramic view and through a 3D reconstruction based on the CBCT acquisition.

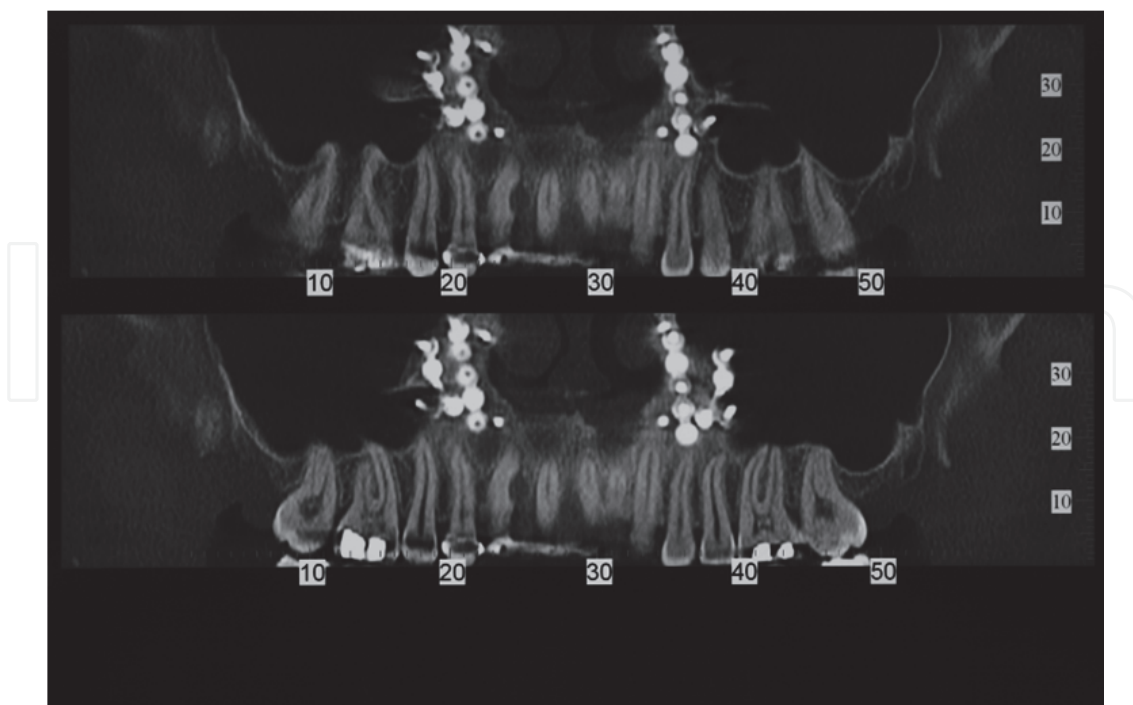


Fig. 9. Panoramic CBCT view of the maxilla after a Le Fort I osteotomy

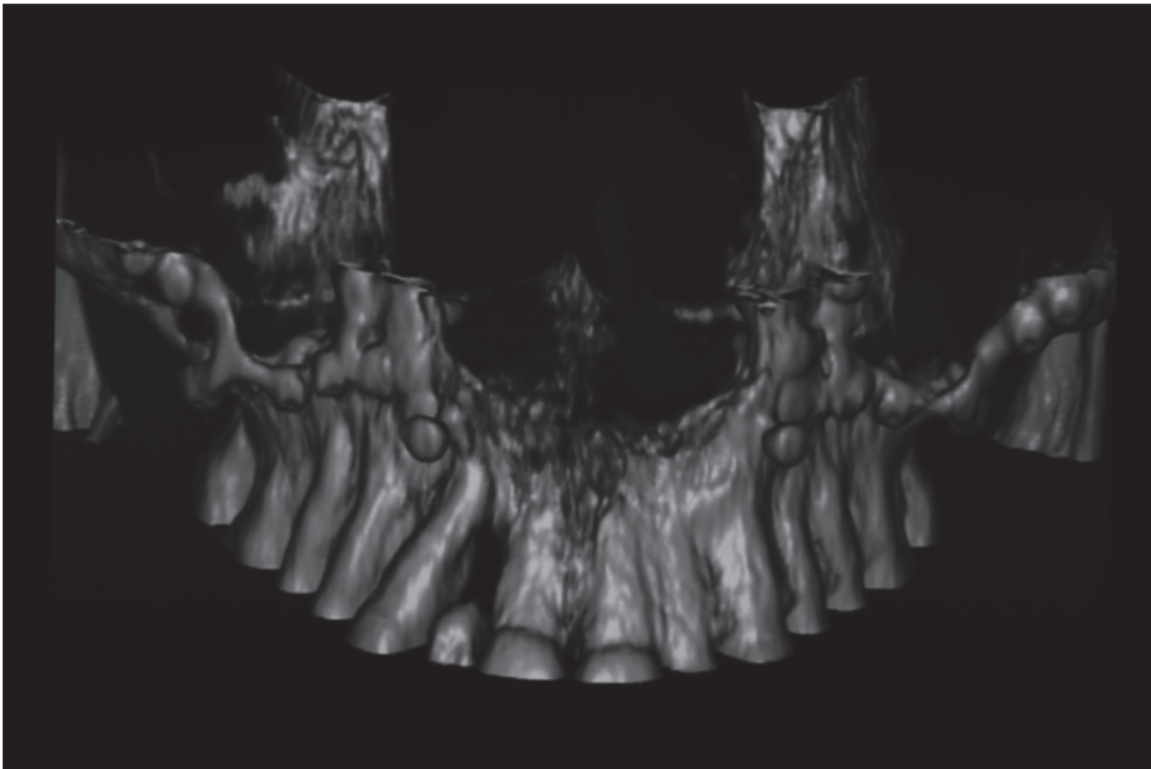


Fig. 10. 3 D view of the maxilla after a Le Fort I osteotomy

#### 4.6 Traumatology

Traumatology is an important part of the craniofacial pathology. Dentoalveolar injuries include tooth fractures and luxations as well as alveolar process fractures and are among the most frequent injuries in the oro-maxillofacial region. In addition to the clinical diagnosis, a 3D radiological diagnosis is also necessary. CBCT combines the three dimensions necessary for diagnostics with the information-rich OPG, displacing classic dental radiological techniques.

Midfacial fractures and mandible fractures require always a 3D radiological diagnosis, since even a combination of various conventional radiological procedures cannot display all fracture lines. CBCT is always preferred to CT, as the radiation exposure is lower. Although the CBCT is characterized by a low-contrast resolution and MRI is still considered the gold standard for the study of soft tissues, the minor amount of radiation exposition and the lesser amount of artifacts due to foreign bodies make CBCT more and more preferred in this kind of pathologies (Melo et al., 2010).

#### 4.7 Diseases of the TMJ

This type of pathology can affect different anatomical structures and hence different tissues. In contrast to most of the other disease of the maxillofacial region, a wide variety of imaging procedures can be used to visualize the affected structures. (Fig.11, Fig.12)

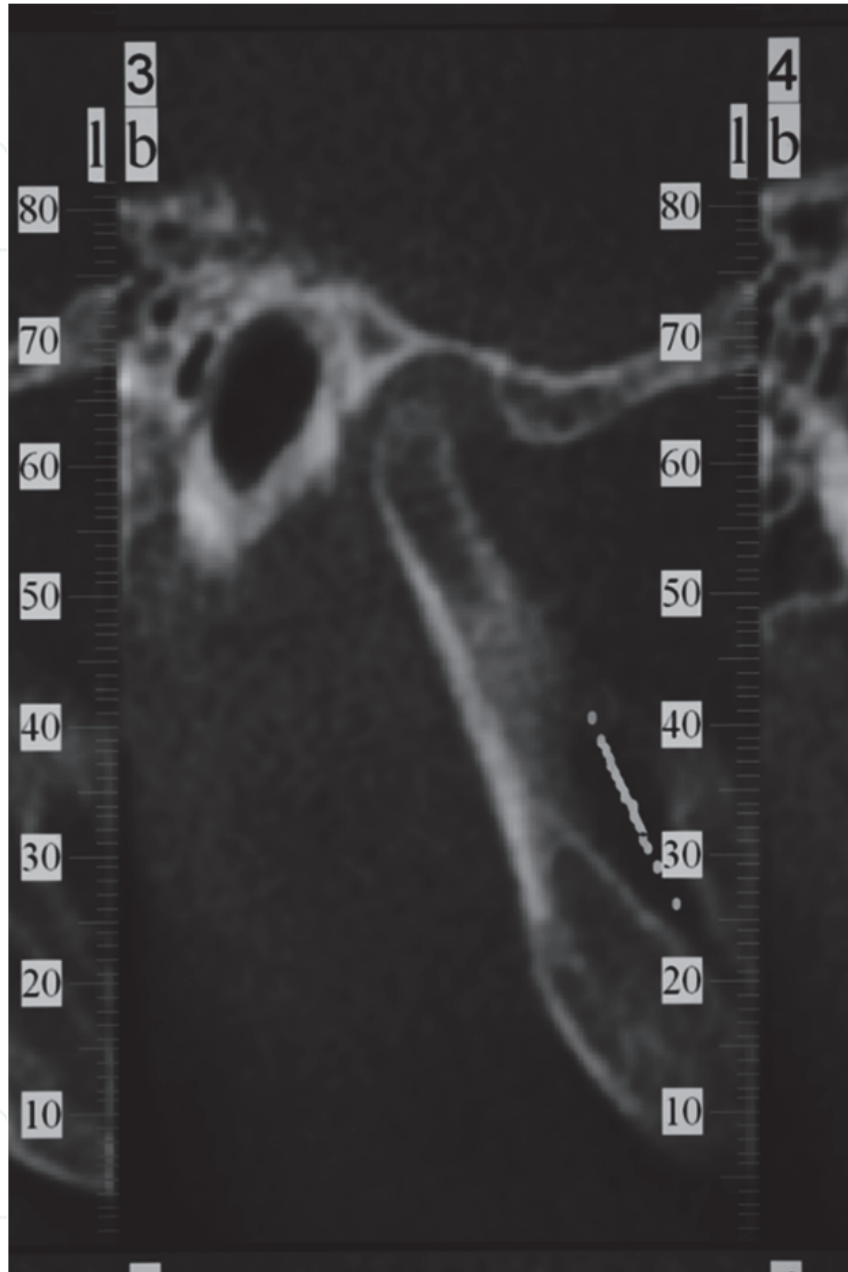


Fig. 11. TMJ arthritis

The use of CBCT allows osseous changes in the temporomandibular joint (TMJ ) to be portrayed at a much higher sensitivity than the conventional radiological techniques. The advantages are a high resolution and the 3D nature of the image. The advent of the CBCT has substantially expanded the options for diagnosing TMJ joint disease, giving the

maxillofacial and plastic surgeons access to 3D information of the region without requiring a radiologist in developmental, primary and secondary acquired diseases of the joint. Moreover, a joint study with CBCT and MRI technique may result in greater accuracy and better timing in diagnosis and treatment, resulting in greater recovery rate for the patient and a higher success rate for the clinician ( Miloglu et al., 2011, Tecco et al., 2010 ). The position of the TMJ joint before and after orthognathic surgery can be visualized and measured on the CBCT scan.

#### **4.8 Craniofacial malformations and syndromes (cleft lip and palate, genetic syndromes)**

CBCT allows anatomically precise informations in 3D to be obtained regarding the type of cleft, the extent of defect and the residual defects after secondary osteoplasty. It also makes treatment planning more effective as the anatomical relations of the cleft are clearly apparent and easier to evaluate than 2D images.

Craniofacial asymmetries, the quality of the bone and the affected structures can be easily detected in CBCT images in various syndromes, thus enabling the orthodontist and the maxillofacial surgeons to establish the timing and the sequences for the specific treatment goals. Anatomical features and landmarks of rare syndromes can be studied and determined with greater precision, conferring on the clinician and on the researcher a valuable tool in terms of early diagnosis and prognosis of the functional recovery of the patient ( Oberoi et al., 2010 )

#### **4.9 Maxillofacial and plastic computer-assisted surgery**

In recent years, computer assisted surgical methods in the head and neck area have been continuously advanced. Initially optical navigation methods were the main focus. Clinical applications pertain nowadays to reconstructive and craniomaxillofacial surgery (CMF surgery).CMF planning modules facilitate a virtual 3D representation using CBVI and CBCT data sets. The diagnosis and examination of the facial asymmetries has been significantly simplified using the 3D imaging, moreover all surgical steps- maxillofacial and plastic procedures can be planned in a virtual environment. With the aid of bone- and tooth-supported cutting and drilling templates drafted on the computer, the so-called "surgi-guides" the results of the planning can be transferred exactly to the in vivo procedure. Surgical splints can be produces using rapid prototyping. Plastic surgery procedures such as rhinoplasty can be also designed using the computer-assisted surgery and the CBCT images. The precision of CBCT and the development of more sophisticated software allowed the rehabilitation of extreme atrophies of the jaws, that would have had otherwise no surgical indication. In effect, only the joint work of the clinician, the radiologist and the technician can merge the surgical skills with the finest definition of the image and the mastery of an intraoperative surgical guide, resulting in the minimization of the clinical failure and in the achievement of clinical success and patient satisfaction even in the most complicated cases. This model is applicable not only in oral surgery, but also in greater surgical reconstruction following oncological or traumatic injury, leaving the room for further technological improvement and for the development of new forms of interdisciplinary cooperation ( Mischkowski et al., 2007 ).

The improvement in the airway diameter can be measured after rhinoplasty and also after soft palate surgical procedures in clefts surgical procedures in clefts.(Fig 12)

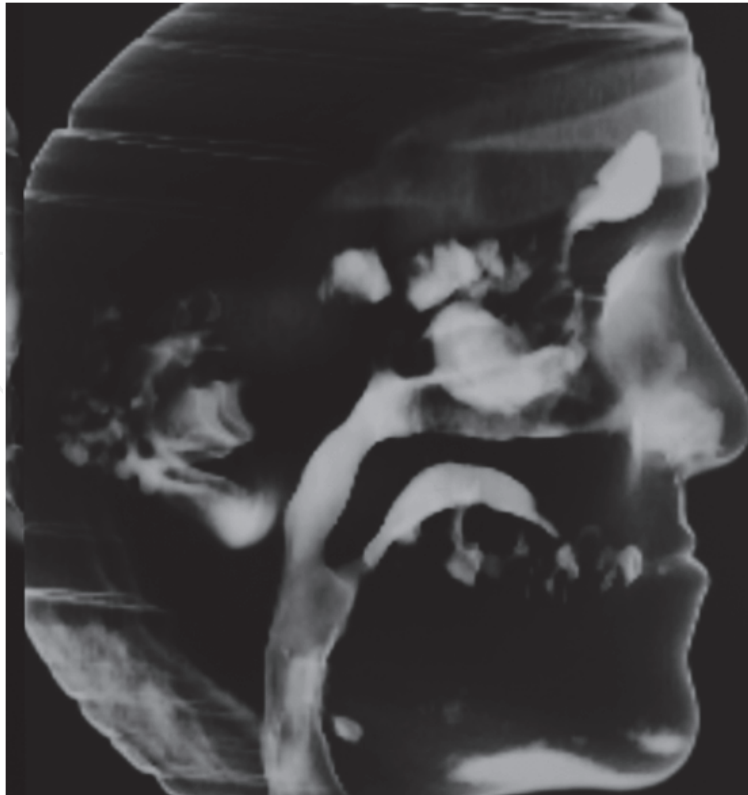


Fig. 12. Airway assesment on CBCT

A detailed surgical approach for functional nasal defects is easy to establish after a CBCT scan. Meanwhile the availability of nasal septal cartilage for grafting the secondary nose defects is extremely precise. ( Fig 13, Fig 14 ).

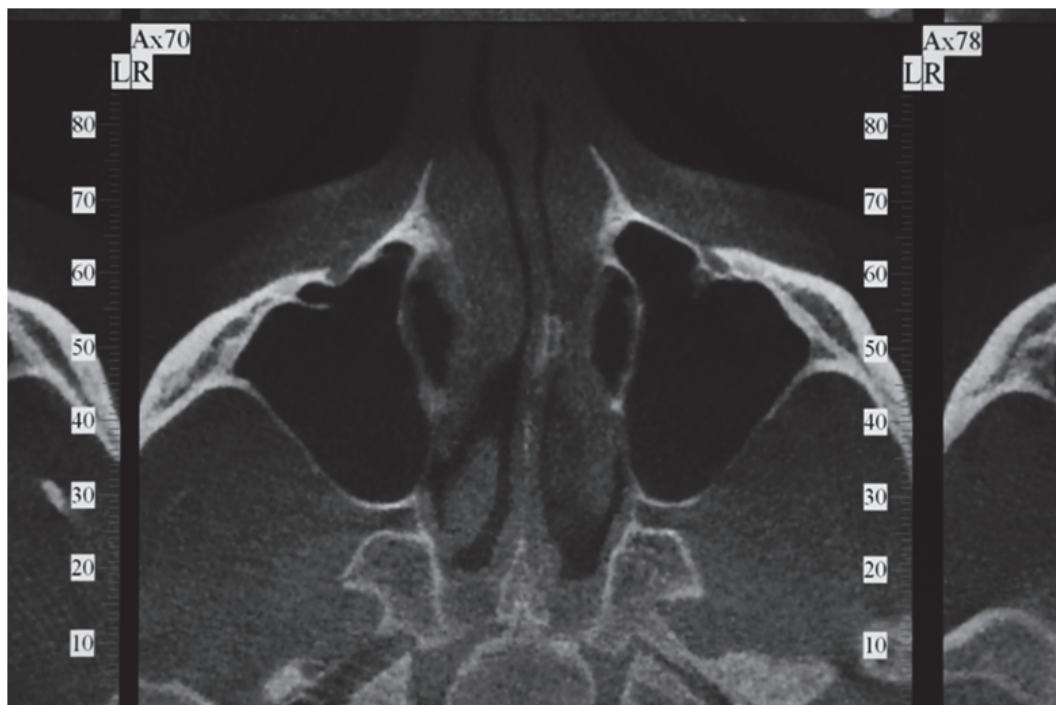


Fig. 13. Nasal septum analysis

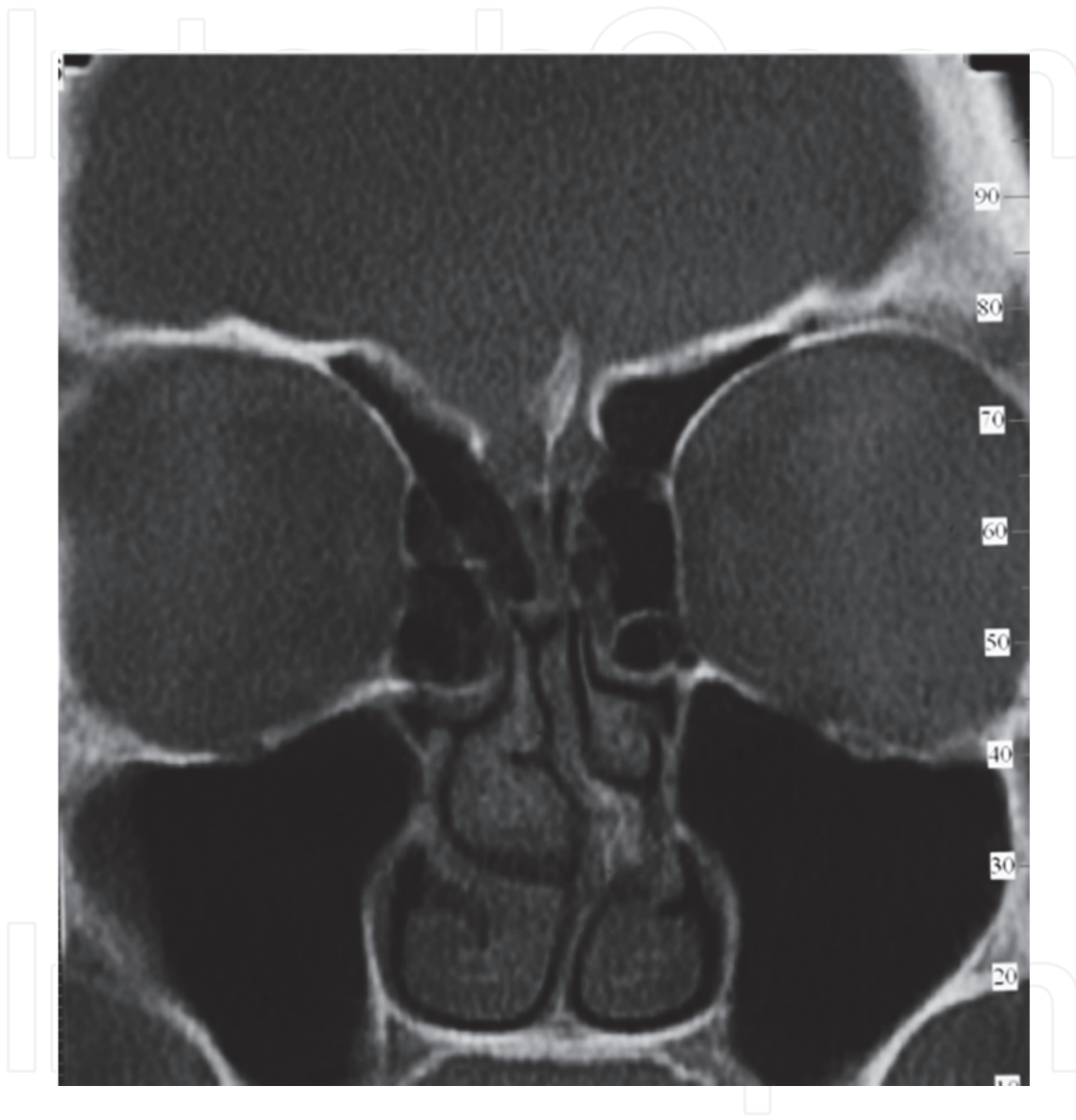


Fig. 14. Nasal septum deviation

The bone contours for cosmetic remodelling can be detected accurately on the CBCT slices. (Fig 15)

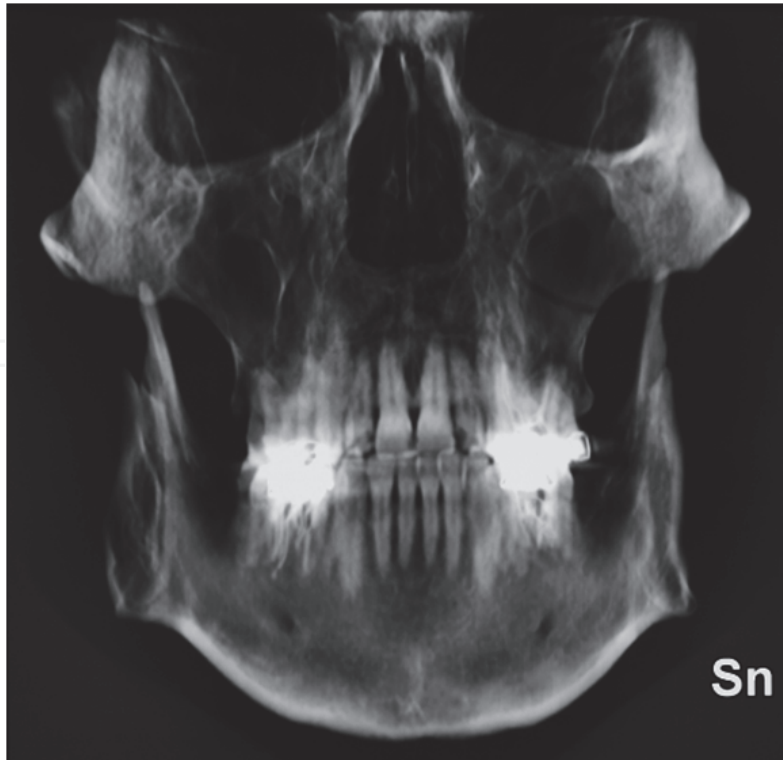
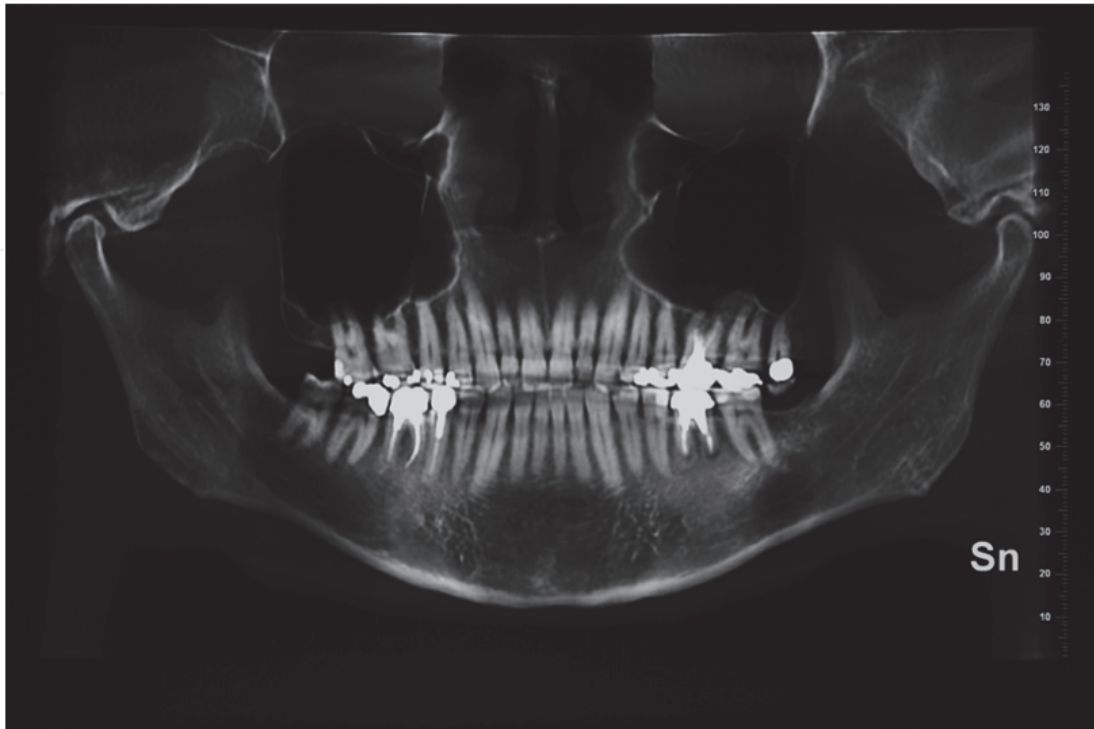


Fig. 15. Bone contours analysis for cosmetic remodelling

## 5. Conclusions

Modern 3D imaging with CBCT facilitates an exact diagnosis and evaluation of all craniofacial pathology and provides a precise tool for diagnosis, treatment planning, monitoring and evaluation of the underlying morphology, of the growth and various modern treatment procedures in dentistry, orthodontics, maxillofacial and plastic surgery. The huge margins of development for the technique and its possible applications in these fields are undoubtedly the forewords for further research and will result in greater advantages and tools for the clinician, with the ultimate increase in patient benefit.


## 6. References

- Bamgbose, BO.; Adeyemo, WL.; Ladeinde, AL.; Ogunlewe, MO.(2008). Conebeam computed tomography (CBCT): the new vista in oral and maxillofacial imaging. *Nig Q J Hosp Med.* 2008 Jan-Mar;18(1):32-5
- Becker, A.; Chaushu, S.; Casap-Caspi, N. (2010) .Cone-beam computed tomography and the orthosurgical management of impacted teeth. *J Am Dent Assoc.* 2010 Oct;141 Suppl 3:14S-8S
- Boeddinghaus, R.; Whyte, A. (2011). Current concepts in maxillofacial imaging. *J Craniofac Surg.* 2011 Mar;22(2):669-73
- Danforth, RA et al. (2003). Cone beam tomography: an imaging option for diagnosis of complex mandibular thord molar anatomical relationships. *J Calif Dent Ass* .2003;31:847-52.
- El-Mohri, Y.; Anthonuk,LE.; Zhao,O.; Jiang, H.; Liu, L. (2011). Low-dose megavoltage cone-beam CT imaging using thick, segmented scintillators. *Phys Med Biol*, Vol 21, 56(6):1509-27
- Heiland, M.; Pohlenz, P.; Blessmann, M.; Werle, H.; Fraederich, M.; Schmelzle, R.; Blake, FA. (2008). Navigated implantation after microsurgical bone transfer using intraoperatively acquired cone-beam computed tomography data sets. *Int J Oral Maxillofac Surg.* 2008 Jan;37(1):70-5
- Kaeppler, G. (2010). Applications of cone beam computed tomography in dental and oral medicine.*Int J Comput Dent.* 2010;13(3):203-19
- Koyama, S.; Aoyama, T.; Oda,N.; Yamauchi-Kawaura, C. (2010) .Radiation dose evaluation in tomosynthesis and C-arm cone-beam CT examinations with an anthropomorphic phantom. *Med Phys.* 2010 Aug;37(8):4298-306.
- Lloyd, TE,; Drage, NA.; Cronin, AJ. (2011). The role of cone beam computed tomography in the management of unfavourable fractures following sagittal split mandibular osteotomy. *J Orthod.* 2011 Mar;38(1):48-54
- Melo, SL.; Bortoluzzi, EA.; Abreu, M Jr.; Corrêa, LR.; Corrêa, M.(2010). Diagnostic ability of a cone-beam computed tomography scan to assess longitudinal root fractures in prosthetically treated teeth. *J Endod* . 2010 Nov;36(11):1879-82
- Miloglu, O.; Yilmaz, AB.; Yildirim,E.; Akgul, HM.(2011). Pneumatization of the articular eminence on cone beam computed tomography: prevalence, characteristics and a review of the literature. *Dentomaxillofac Radiol.* 2011 Feb;40(2):110-4
- Mischkowski, RA.; Pulsfort, R.; Ritter, L.; Neugebauer, J.; Brochhagen, HG.; Keeve, E.; Zöller, JE. (2007). Geometric accuracy of a newly developed cone-beam device for



- maxillofacial imaging. *Oral Surg Oral Med Oral Pathol Oral Radiol Endod.* 2007 Oct;104(4):551-9
- Oberoi, S.; Gill, P.; Chigurupati, R.; Hoffman, WY.; Hatcher, DC.; Vargervik K. (2010). Three-dimensional assesment of the eruption path of the canine in individuals with bone-grafted alveolar clefts using cone-beam computed tomography. *Cleft Palate Craniofac J.* 2010 Sep;47(5):507-12
- Rosenberg, PA.; Frisbie, J.; Lee, J.; Lee, K.; Frommer, H.; Kottal, S.; Phelan, J .; Lin, L.; Fisch, G.(2010). Evaluation of pathologists (histopathology) and radiologists (cone beam computed tomography ) differentiating radicular cysts from granulomas. *J Endod.* 2010 Mar;36(3):423-8
- Song, CK.; Chang, HS.; Min, KS.(2010). Endodontic management of supernumerary tooth fused with maxillary first molar by using cone-beam computed tomography. *J Endod* 2010;13(3):203-19.
- Swennen, GR.; Mollemans, W.; De Clercq, C.; Abeloos, J.; Lamoral, P.; Lippens, F.,; Neyt N.; Casselman, J.; Schutyser, F.(2009). A cone-beam computed tomography triple scan procedure to obtain a three-dimensional augmented virtual skull model appropriate for orthognathic surgery planning. *J Craniofac Surg.* 2009 Mar;20(2):297-307.
- Tecco, S; Saccucci, M.; Nucera, R.; Polimeni, A.; Pagnoni, M.; Cordasco, G.; Festa, F.; Iannetti, G.(2010). Condylar volume and surface in Caucasian young adults subjects. *BMC Med Imaging.* 2010 Dec 31;10:28
- Tucker, S.; Cevidanes, LH.; Styner, M.; Kim, H.; Reyes, M.; Proffit, W.; Turvey, T. (2010). Comparison of actual surgical outcomes and 3-dimensional surgical simulations. *J Oral Maxillofac Surg.* 2010 Oct;68(10):2412-21

IntechOpen



## **CT Scanning - Techniques and Applications**

Edited by Dr. Karupppasamy Subburaj

ISBN 978-953-307-943-1

Hard cover, 348 pages

**Publisher** InTech

**Published online** 30, September, 2011

**Published in print edition** September, 2011

Since its introduction in 1972, X-ray computed tomography (CT) has evolved into an essential diagnostic imaging tool for a continually increasing variety of clinical applications. The goal of this book was not simply to summarize currently available CT imaging techniques but also to provide clinical perspectives, advances in hybrid technologies, new applications other than medicine and an outlook on future developments. Major experts in this growing field contributed to this book, which is geared to radiologists, orthopedic surgeons, engineers, and clinical and basic researchers. We believe that CT scanning is an effective and essential tools in treatment planning, basic understanding of physiology, and and tackling the ever-increasing challenge of diagnosis in our society.

### **How to reference**

In order to correctly reference this scholarly work, feel free to copy and paste the following:

Corega Claudia, Avram Adrian, Nocini Pier Francesco and Bertossi Dario (2011). Cone-Beam Volumetric Imaging in Craniofacial Medicine, CT Scanning - Techniques and Applications, Dr. Karupppasamy Subburaj (Ed.), ISBN: 978-953-307-943-1, InTech, Available from: <http://www.intechopen.com/books/ct-scanning-techniques-and-applications/cone-beam-volumetric-imaging-in-craniofacial-medicine>

**INTECH**  
open science | open minds

### **InTech Europe**

University Campus STeP Ri  
Slavka Krautzeka 83/A  
51000 Rijeka, Croatia  
Phone: +385 (51) 770 447  
Fax: +385 (51) 686 166  
[www.intechopen.com](http://www.intechopen.com)

### **InTech China**

Unit 405, Office Block, Hotel Equatorial Shanghai  
No.65, Yan An Road (West), Shanghai, 200040, China  
中国上海市延安西路65号上海国际贵都大饭店办公楼405单元  
Phone: +86-21-62489820  
Fax: +86-21-62489821

© 2011 The Author(s). Licensee IntechOpen. This chapter is distributed under the terms of the [Creative Commons Attribution-NonCommercial-ShareAlike-3.0 License](#), which permits use, distribution and reproduction for non-commercial purposes, provided the original is properly cited and derivative works building on this content are distributed under the same license.

IntechOpen

IntechOpen