

# We are IntechOpen, the world's leading publisher of Open Access books Built by scientists, for scientists

4,800

Open access books available

122,000

International authors and editors

135M

Downloads

Our authors are among the

154

Countries delivered to

TOP 1%

most cited scientists

12.2%

Contributors from top 500 universities



WEB OF SCIENCE™

Selection of our books indexed in the Book Citation Index  
in Web of Science™ Core Collection (BKCI)

Interested in publishing with us?  
Contact [book.department@intechopen.com](mailto:book.department@intechopen.com)

Numbers displayed above are based on latest data collected.  
For more information visit [www.intechopen.com](http://www.intechopen.com)



## Mycotic Leukonychia in HIV Patients

Patricia Chang<sup>1</sup>, Gabriela Moreno-Coutiño<sup>2</sup> and Roberto Arenas<sup>2</sup>

<sup>1</sup>Hospital General Enfermedades IGSS,

<sup>2</sup>Mycology Section "Dr Manuel Gea González" General Hospital, Mexico City

<sup>1</sup>Guatemala

<sup>2</sup>Mexico

### 1. Introduction

Onychomycosis is the fungal infection of the nail, that can be caused by dermatophytes, *Candida* sp. or non-dermatophyte moulds (NDM). The term *tinea unguium* is a specific form of onychomycosis caused only by dermatophytes and thus, should not be regarded as synonymous. (Odds *et al.*, 1992)

On the other hand, the term leukonychia or white nails has a varied etiology, it can be congenital or acquired, infectious and non-infectious. In the case of onychomycosis, the diseased nail plate has an external origin, which is the fungal invasion that affects secondarily the normally formed nail. This is also known as fungal or mycotic leukonychia (Baran *et al.* 1994).

Onychomycosis, with all the different clinical presentations, is responsible for about 50% of all dystrophic nails and has a prevalence of 3-10% in the general population. Frequency also depends, on geographic conditions and age groups, with an increase in the prevalence in the elderly. It is now becoming more evident that immunosuppressed patients, particularly those living with HIV infection, are at a higher risk of presenting this nail fungal infection, and any clinical presentation is higher compared to the same age group of the general population ( Denning *et al.* 1995; Moreno-Coutiño *et al.*, 2011; Winberg *et al.* 2003).

The first classification of onychomycosis was proposed by Zaias, and is based on the clinical appearance of the nails (Zaias, 1972). He described four clinical types: [1] distal subungual onychomycosis (DSO), [2] white superficial onychomycosis (WSO), [3] proximal subungual onychomycosis (PSO) and [4] *Candida* sp. onychomycosis. Since the publication of this paper, some modifications have been added. In 1998, Baran *et al.* proposed [I] distal and lateral subungual onychomycosis (DLSO), [II] superficial onychomycosis, [III] proximal subungual onychomycosis (PSO), [IV] endonyx onychomycosis and [V] total dystrophic onychomycosis (TDO). The most used these days is the following: DLSO, white superficial onychomycosis (WSO), PSO, *Candida* onychomycosis (paronychia) and TDO (Table 1) , (Baran *et al* 1998). WSO and PSO are also known as mycotic leukonychia. Further subdivisions are included in almost all the categories, and will be discussed further when necessary (Gupta & Summerbell, 1999).

In 1976, English described a classification based on etiology, instead of the clinical aspect of the fungal invasion. The categories are: (a) dermatophytes causing *tinea unguium*, (b) moulds (Non-dermatophyte moulds [NDM]) and (c) yeasts (Crozier *et al.* 1979). At this moment, the

Distal and lateral subungual onychomycosis (DLSO)
Proximal white subungual onychomycosis (PWSO)
Superficial white onychomycosis (SWO)
Total dystrophic onychomycosis (TDO)
Candida paronychia

Table 1. Current clinical classification

current classifications are not being specific enough to describe the clinical picture, etiology or prognostic factors regarding response to treatment (Grossman & Scher, 1990). Fungal or mycotic leukonychia was rather infrequent until the AIDS pandemic. PWSO is the least common form of onychomycosis in the HIV negative population, and DLSO is the most prevalent form of onychomycosis in patients living with HIV/AIDS. Since the identification of this disease in the 1980's, many case reports and studies have been done. Although onychomycosis is not considered an AIDS-defining illness, and its presence is not useful for clinical classification, the presence of fungal leukonychia should alert the physician about possible immunosuppression. However, PSWO heralds advanced HIV disease and can be an early clinical marker of HIV infection (Chang & Arenas, 1995).

For some patients and even some physicians, onychomycosis is not a relevant medical condition. Nonetheless, it can have an important impact on the quality of life, particularly in patients living with HIV/AIDS. This group of patients commonly presents fingernail involvement as well as toenail infection more frequently than the non-immunosuppressed. This fact has negative effect on the quality of life because, unlike feet, hands are exposed all the time (Millikan *et al.*, 1999). Embarrassment, problems in the work area, including unemployment, reduction in social activities, alienation, fear of spreading the disease to others and pain, are the most common complaints (Drake *et al.*, 1999).

In the WHO clinical classification of HIV-associated disease is designed to be used in patients with confirmed HIV infection, the fungal nail infections are considered in clinical stage 2 (mild disease) that usually present with >450 CD4 cell count.

## 2. Epidemiology

According to the WHO, in 2009 the number of people living with HIV was 33.3 million worldwide. During 2009, 2.6 million were infected, and these numbers continue to rise (World Health Organization [WHO], 2009).

The incidence of all clinical forms of onychomycosis in HIV infected patients has slight variations in different countries, as has been noted in several reports. For instance, in Canada as well as in India, the incidence is 24%, 30% in France, and 20 % in Mexico.

Onychomycosis in open population in the USA is between 2-3%, 8.4% in Finland, 2.7% in the UK and 2.6% in Spain. Nonetheless, the Achilles project, the largest study on the prevalence of foot diseases in Europe found a much higher number, of 29.6%. In México, the incidence reported is 30%, but a recent national survey has showed a suspected frequency of 48% (Arenas, Bonifaz, *et al.* 2010). These reports include all age groups, and the numbers are similar to those reported in the HIV infected population, but if we separate the data by age group, the HIV group is younger for such an incidence compared to open population.

Specific epidemiologic data about mycotic leukonychia (WSO and PWSO) is scarce. It was only after the HIV pandemic developed that case reports were published, in the late 80's. Before that time, the clinical presentation of fungal leukonychia was infrequent and the

fungi isolated were mostly NDM. WSO in general population has a prevalence of 1-2% and PWSO 8.3%.

For HIV positive population in 1998, Cribier *et al.* reported a prevalence of 8.5% for fungal leukonychias, Piraccini *et al.* of 9.5%, and Domp Martin *et al.* of 8%. These small numbers contrast with other series such as the one published by Ravnborg *et al.* where 90% of their cases of onychomycosis, were clinically classified as PWSO (Ravnborg *et al.*, 1998). In a report of patients from Canada and Brazil, WSO had prevalence of 3.3% and 5% and for PWSO of 1.5% and 3% respectively. The overall prevalence for onychomycosis in HIV infected patients was reported of 23.2% (Arenas *et al.*, 2010; Cribier *et al.*, 1998; Domp Martin *et al.*, 1990; Gupta *et al.* 2000; Noppakun & Head, 1986; Weismann *et al.* 1988).

Among patients living with HIV/AIDS, onychomycosis is the fourth most common dermatological manifestation, with an incidence of 10-44%, and an estimated prevalence 15-40%. They are clinically more aggressive with rapid spread in finger or toenails (Herranz *et al.*, 1997) particularly in those with a cell count of 450 CD4 or lower. Some authors even report below 370 CD4. This finding suggests that the degree of immunosuppression plays an important role in the development of the disease. On the other hand, a Spanish study on prevalence and characteristics of dermatological diseases in HIV infected patients reported onychomycosis as the third most common dermatoses, particularly the DLSO clinical form, and found no statistical difference in the incidence between patients with <200 CD4 or ≥200 CD4 (Blanes *et al.*, 2010; Piraccini & Tosti, 2004; Singh *et al.*, 2009).

The age group most affected is the one of young adults, between 30 and 40 years of age (mean 36.6), because they are the majority of the HIV infected patients. As the HIV infection in many countries still predominates in the male gender, these comprise the majority of the patients with diagnosis of onychomycosis, with a sex ratio of 9:1 compared to females. However, the male:female ratio varies between countries. Where the infection rates are almost equal between genders, the ratio has been reported of 2:1.

Children in general, are a very low risk group for onychomycosis. The highest prevalence is reported in Latin American Countries as Mexico and Guatemala. In the former country is mainly observed in adolescents of both genders (Gupta *et al.* 1997; Vásquez del Mercado & Arenas, 2008).

The incidence reported varies from 0% in Wales, Finland and USA, 0.16% in Canada and 2.6% in Guatemala. This is thought to be because children have a reduced exposure to fungus, they have spent less time in contaminated environments, their nails grow faster, the nail surface is smaller so it provides less space for invasion, and they also have lower prevalence of tinea pedis which has been acknowledged as an important risk factor. There are no published series of HIV infected children regarding leukonychia.

The multiple studies published in adult population prove that the causative agents of fungal leukonychia, that include dermatophytes, *Candida* spp. and NDM remain the same despite the globalization of infectious diseases and that the worldwide prevalence of all superficial mycotic infections has been rising during the last decade, reaching up to 20-25% of the general population. They have a worldwide distribution, predominate in toenails, particularly caused by moulds. In fingernails, the association of constant contact with water and detergent damages the cuticle, facilitating fungal invasion of the nail plate and the main etiological agent is *Candida* sp. This is frequently seen in women involved in household activities (Arenas, 1990).

The most reported dermatophytes isolated are *Trichophyton rubrum*, *T. mentagrophytes*. Among the isolated NDM were: *Aspergillus niger*, *Cladoaporium* spp, *Scytalidium hyalinum*, *Penicillium* spp and *Gymnoascus dankaliensis*, and *Candida* spp. (Sujushe *et al.*, 2007).

The fungi capable of causing nail plate infection are ubiquitous. Tropical climate, heat and local humidity favor their development (between 25-28°C), as well as personal factors such as occlusive footwear, excessive sweating of feet, nail trauma, nail growth rate and in these particular cases, immunosuppression (table 2) (Elewski, 1998). The poor prognostic factors are: nail plate involvement of more than 50%, matrix area involvement, significant lateral disease, subungual hyperkeratosis >2mm, the presence of longitudinal streaks in the nail, NDM documented infection as well as diminished peripheral circulation. These infections have low tendency to self limitation (Scher *et al.*, 2007; Havlickova *et al.*, 2008).

<450 CD4/ $\mu$ L cell count
No ARV therapy
Occlusive footwear
Repeated trauma in nail apparatus
Tinea pedis, tinea cruris or corporis
Direct family members with onychomycosis

Table 2. Risk factors

### 3. Etiology and pathogenesis

Traditionally it is thought that the route of infection for fungal leukonychia is the dorsal aspect of the nail plate in the case of WSO and the PWSO is believed to originate from invasion through the proximal nail fold. However, controversy exists in both cases and will be further discussed.

The classic presentation of WSO initiates as white superficial patches without distinct edges that may gradually coalesce and invade the entire nail plate. At this point, the surface of the nail becomes uneven, porous and crumbles. *Trichophyton mentagrophytes* var. *interdigitale* is responsible for 90 % of the infections, associated or not to tinea pedis.

Other common pathogens that cause WSO are *T. rubrum* and non dermatophyte moulds (NDM) such as *Aspergillus* spp., *Fusarium* spp., and *Acremonium* spp. (Baran *et al.* 2007; Baran *et al.*, 2004)

According to Baran et al, WSO can be subdivided into:

1. Classical WSO with superficial invasion of the visible portion of the nail plate. Leukonychia presents as patches or striate superficial bands, alternated with normal color and appearance of the nail plate.
2. Clinically similar to the first form described, the difference is that this one originates beneath the proximal nail fold due to invasion of the ventral aspect of its eponychial segment. Usually involves several toenails simultaneously. This form may be confused with PSWO and is frequently seen in the context of HIV infection.
3. WSO with deep invasion of the nail plate that progressed to deep penetration from the superficial aspect of the nail plate with possible extension beneath the nail fold.
4. Mixed forms, where WSO and other forms of onychomycosis coexist independently.

Several factors are involved in the development of SWO. The fungus must possess keratinolytic enzymes that enable it to penetrate the hard keratins of the nail plate. The invasion starts as superficial, but depending on host's and parasites characteristics, the entire depth and/or length of the nail plate may be involved. One of the most important host factors that influence the evolution of the disease is the decreased immune function against the fungus mainly because of the HIV infection, although chemotherapy and systemic steroid therapy may also be accounted responsible in other group of patients. It has been proposed that the low CD4 count affects the resistance to ordinary pathogens even in the avascular nail plate.

Another factor is the genetic background. By genetic predisposition, the nail surface is poorly resistant to the fungal penetration and invasion, so WSO can be considered an autosomal dominant disease. And, of course, as in any other type of onychomycosis, local humidity by occlusive shoes, nail plate thickness and nail plate growth rate, influence the development of the disease (Piraccini & Tosti, 2004).

PWSO is generally caused by dermatophytes, and is seen mainly in immunocompromised patients, especially when many nails are involved. When associated to paronychia, the infectious agent is generally a NMD. The dermatophyte *Trichophyton rubrum* is the most common isolated infectious agent. Other dermatophytes that have been reported to cause PWSO are *T. mentagrophytes* and even *Microsporum canis*. Among the NDM reported are *Aspergillus niger*, *A. sclerotiorum*, and *A. flavus*. (Table 3) (Weinberg, *et al.*, 1999).

<i>T. rubrum</i>	PWSO
<i>T. mentagrophytes</i> var. <i>interdigitale</i>	SWO
<i>Microsporum canis</i>	PWSO
<i>Aspergillus</i> spp	SWO
<i>Fusarium</i> spp.	SWO
<i>Acremonium</i> spp.	SWO
<i>Candida</i> spp	PWSO

Table 3. Most frequently isolated fungus

The most accepted theory for the route of infection in PWSO is the one that states that apparently, the stratum corneum on the ventral aspect of the proximal nail fold is the primary site of fungal invasion. When the fungus reaches the matrix, it mainly spreads to the lower part of the nail plate. However, Baran *et al.* have proposed a new theory. The fungal infection that initiates in the lunula region could be secondary to endogenous reactivation or auto-reinfection from a deeper site instead than from an external source. Based on evidence that dermatophyte antigenemia exists in patients with foot infections, they mention the possibility of reactivation after initial spread and sequestration with systemic dissemination either through retrograde lymphatic or hematogenous spread into the nail matrix and nail bed. Despite the known fact that dermatophytes are normally confined to the keratinous components of the skin and its appendages, some studies have proven that dermatophytes can survive in the bloodstream and lymphatic tissues and this, has led to think that this could explain the peculiar clinical manifestation and evolution of HIV-infected patients that present with PWSO.

This systemic spread theory is supported by the observation of multiple leukonychia transversal bands frequently seen in patients living with HIV/AIDS and PWSO. These bands are separated by histologically normal and micologically negative nail (Baran *et al.*, 2005).

Although poorly understood, as with any other infectious agent, it is clear that the immunological state of the patient plays an important role in the development and evolution of the onychomycosis. Immunological defects other than those affecting T-lymphocyte function, such as defective neutrophil chemotaxis, have also been associated with the appearance of PWSO.

It has been established that patients with HIV and dermatophytic infection are predisposed to suffer a chronic course and even, although very rare, to evolve to invasive disease. The impairment of cell-mediated immunity has been related with these conditions. Changes in the balance between TH1 and TH2 immune responses have been implicated in the progression of dermatophytosis associated to HIV infection (Woodfolk, 2005).

Diverse fungal species as dermatophytes and opportunistic fungi, are frequently cultured from the samples obtained from these patients. The most common remain *T. rubrum* and *T. mentagrophytes* despite their immunocompromised state and the globalization of infections.

This population frequently presents in the same nail plate PSWO associated to WSO. This may be initiated from the distal surface and the proximal nail fold independent one from the other. This is difficult to assess. Regardless of how or where the infection started, the fungus may spread to affect either or both the dorsal and ventral nail surfaces. This may even result eventually in a modification of the clinical presentation. That is, PWSO may turn into a DLSO or TDO. The same is true for WSO, which may convert to PSWO or any other category (Baran *at al.*, 2007; Baran *at al.*, 2004; Hogan, 2006).

Regarding identified risk factors, trauma was the major predisposing factor, followed by diabetes mellitus and peripheral vascular disease. Strong association to *tinea pedis* exists, as toenails are more commonly affected (Surjushe *et al.*, 2007).

#### 4. Clinical signs

The clinical characteristics of onychomycosis in patients living with HIV are commonly recognized because of the extension, rapid evolution and limited response to treatment. (Table 4 & 5).

Usually more than 3 nails involved
Rapid evolution
Mostly toenails
Leukonychia or DLSO
<450 CD4/ $\mu$ L cell count
<i>T. rubrum</i>

Table 4. Clinical presentation of onychomycosis in patients living with HIV/AIDS

	WSO	PWSO
Nail plate appearance	Crumbly	Normal
White patches	Ill defined, irregular shapes multifocal	Distinct border
Localization in nail plate	Any part	Starts at the lunula
Most frequent organism	<i>Trichophyton mentagrophytes</i>	<i>Trichophyton rubrum</i>

Table 5. Differences between WSO and PWSO

HIV seronegative population normally present onychomycosis in one or both first toenails, which differs from patients living with HIV, who present with an atypical number of nails involved, usually more than three, and the first toenails may not be involved. Another important difference with open population is of course, the age group involved that is much younger if they are living with HIV infection.

Another typical characteristic of these patients is that they report a very short evolution, even two or three weeks in which they witness the rapid change in the appearance of their nails. It is not rare to see involvement of both finger and toenails, adding up to 15 or more nails infected. Anyhow, toenail infection remains the main infected area.

*Candida* spp., being a frequent opportunistic infectious agent of immunosuppressed patients, one could expect that candidal paronychia should be a common finding, but it is seldomly found in finger or toenails.

WSO is mostly seen in toenails. The reason for the low incidence on fingernails could be that it is a relatively superficial infection that could easily be washed off. So, even in immunosuppressed patients, the finding of WSO in fingernails is rare (Figure 1).

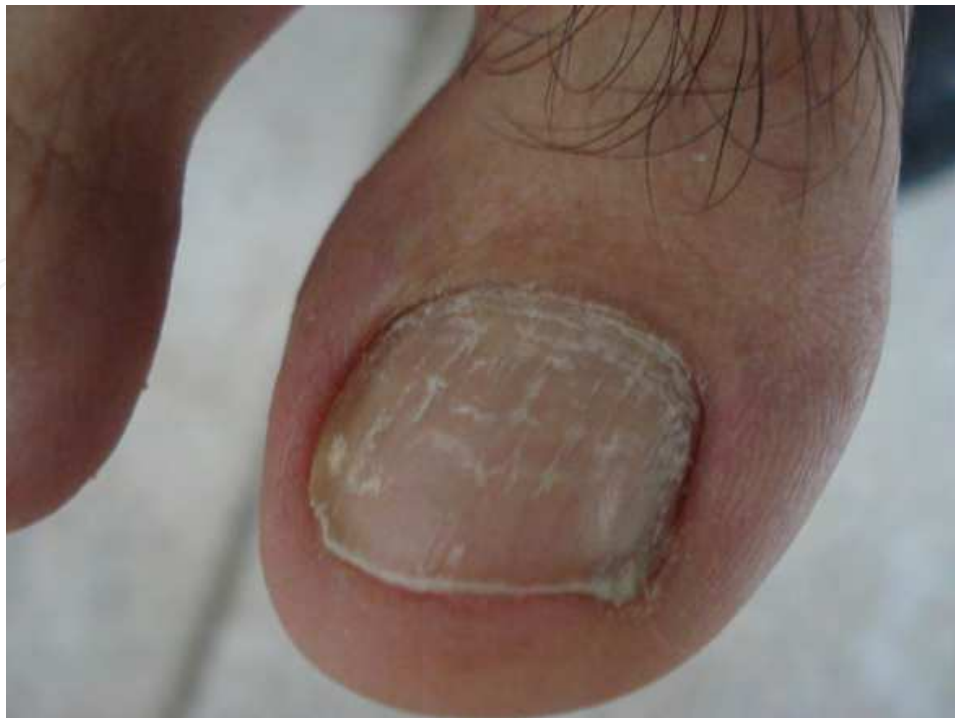

Fig. 1. White superficial onychomycosis



Clinically WSO is seen as opaque white scaly patches, ill defined, irregular and multifocal distributed along the dorsal surface of the nail plate. Each of these plaques corresponds to a fungal colony. Although this is a superficial infection, the nail plate surface looks affected. It is not smooth, but rather irregular and might even be porous and crumbly in some areas.

WSO usually affects toenails, more frequently seen in the first, second and/or third nails. The association to interdigital tinea pedis is common. This clinical form may rapidly evolve to a more deep form of onychomycosis, particularly if associated in that or any other nail to PWSO or DLSO (Figure 2).

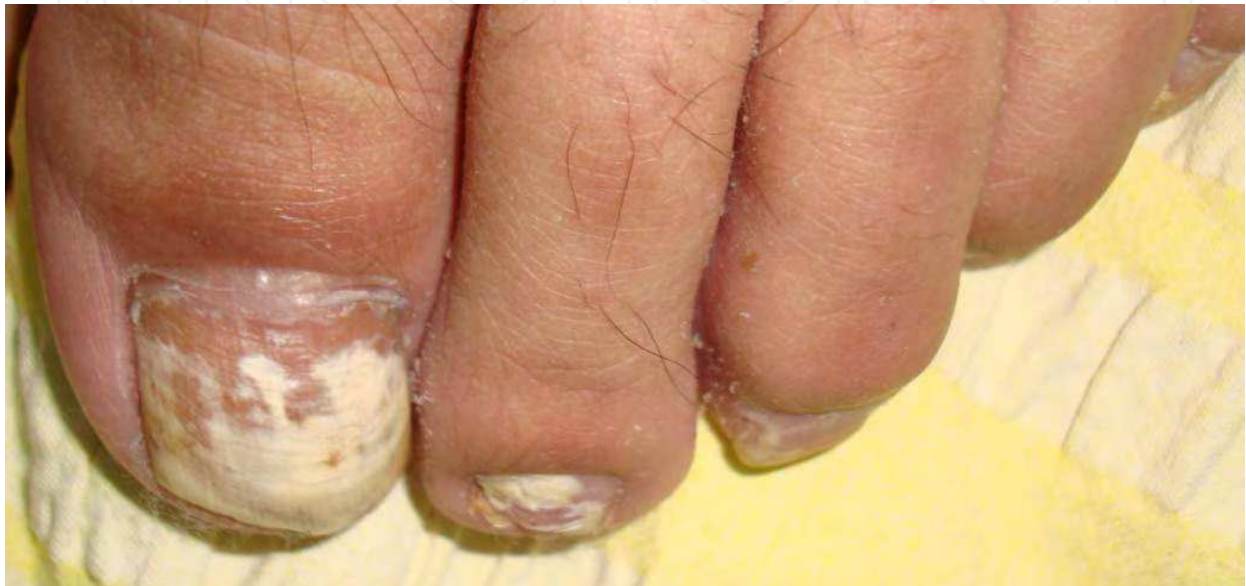

Fig. 2. White superficial onychomycosis and proximal white subungual onychomycosis

If paronychia is associated to WSO, it is generally due to infection of non-dermatophyte moulds (Piraccini & Tosti, 2004).

PWSO is considered by many physicians “the hallmark” of HIV infection. It is certainly true that this clinical form became widely known because of the AIDS pandemic, and although this still remains a rare form of onychomycosis, immunosuppression should be suspected when observed.

This clinical pattern initiates beneath the proximal nail fold, in the area of the lunula. A white, opaque and well defined macula is visible through the nail plate. The cuticle and other periungual tissues are unaffected. It may then continue to spread distally or may remain confined, although it will eventually grow out with the nail.

The most important clinical feature to differentiate it from other invasion patterns is that the nail plate is smooth and looks unaltered in consistency and thickness.

It is common to see different proportions of nail plates affected in the same individual. It can be seen either or in both finger and toenails.

Besides these “classic” characteristics, PWSO may present in a variety of other forms. They may be longitudinal bands of leukonychia of varying thickness, isolated or multiple transverse white bands that may even be a little curved, similar to the natural curvature of the lunula (Figure 3).

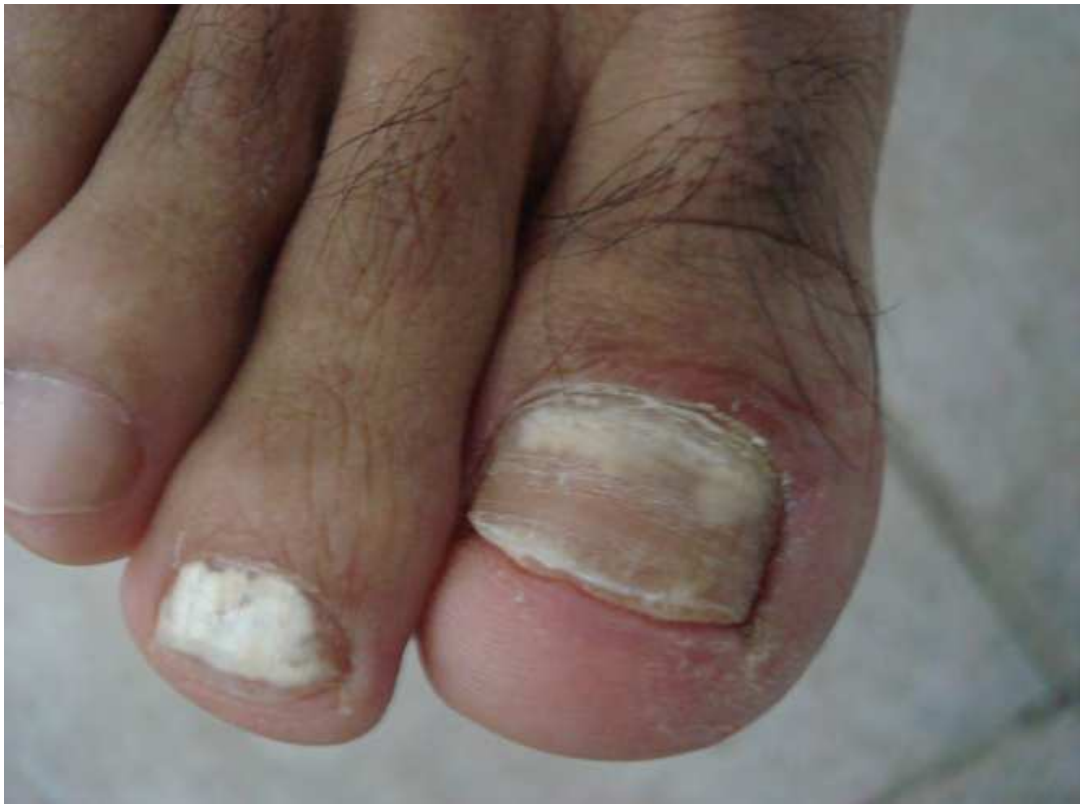

Fig. 3. Proximal white subungual onychomycosis

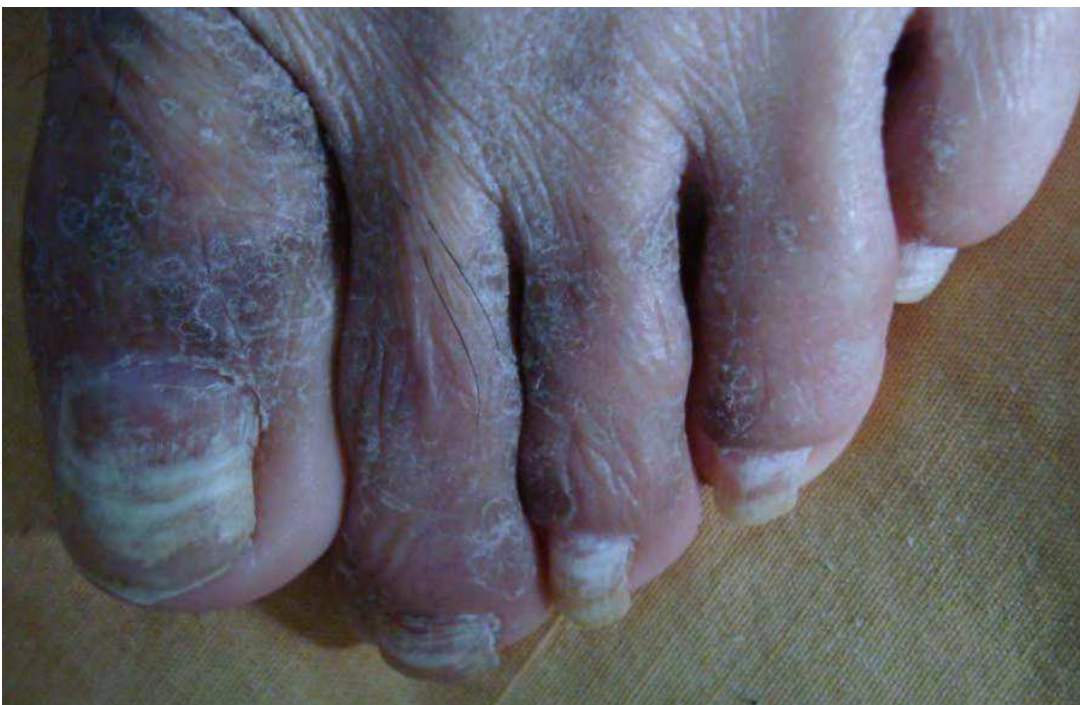

Fig. 4. Leukonychia in transversal bands

As confirmed by histopathology, these transverse bands are separated by normal nail plate, clinically and histologically (Figure 4). Immunosuppressed patients frequently present rapid

development in several digits simultaneously. A study found statistical differences in the incidence of onychomycosis correlated with the stage of AIDS reported. It was of 21% in patients with stage A, 30% with patients in stage B, compared to 54% of patients in stage C ( $p < 0.02$ ) (Baran *at al.*, 2005).

With time, PWSO may evolve to cover the entire nail plate, the original macula may grow out (Figure 5), or DLSO or TDO may develop. These two last clinical presentations are common findings in longstanding onychomycosis infections.

Despite this clinical modification of the appearance of the nail plate and worsening in the appearance of the nail, these infections don't disseminate systemically to other organs other than the nail apparatus, and therefore, are not life threatening infections (Havlickova, 2008).

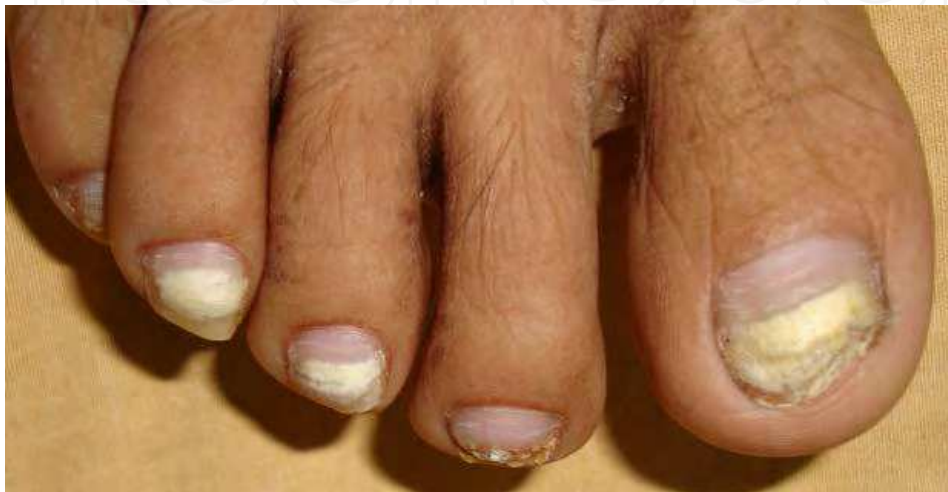

Fig. 5. Proximal white subungual onychomycosis growing out with the nail plate

## 5. Diagnosis

Clinical diagnosis is the many used method by most physicians, particularly non-dermatologists. However, we do not recommend this as the sole method because only 50% of nail dystrophies correspond to onychomycosis, and treatment with oral antifungals should be restricted to those patients where it has been widely justified.

The physical examination of the nails should be complemented with the medical history regarding sports habits such as swimming or running, because of the excessive humidity and repeated trauma to the nail apparatus respectively.

In immunosuppressed patients, complete physical exploration should be performed. Several reports have mentioned that tinea capitis or tinea inguinale can be precursors of onychomycosis by autoinoculation.

### 5.1 Laboratory tests

#### 5.1.1 Direct mounts

Potassium hydroxide 10-20% (KOH) preparation and fungal culture in Sabouraud dextrose and/or Mycosel agar are the most known and used laboratory tests.

KOH mounts have the enormous advantage that one can obtain the result immediately, even during the office visit of the patient. It is painless, non-invasive and has very low cost. The downside to it is that only trained dermatologists, microbiologists or mycologists will be able to recognize the fungal structures in the nail scrapings, and one must have a light microscope at hand.

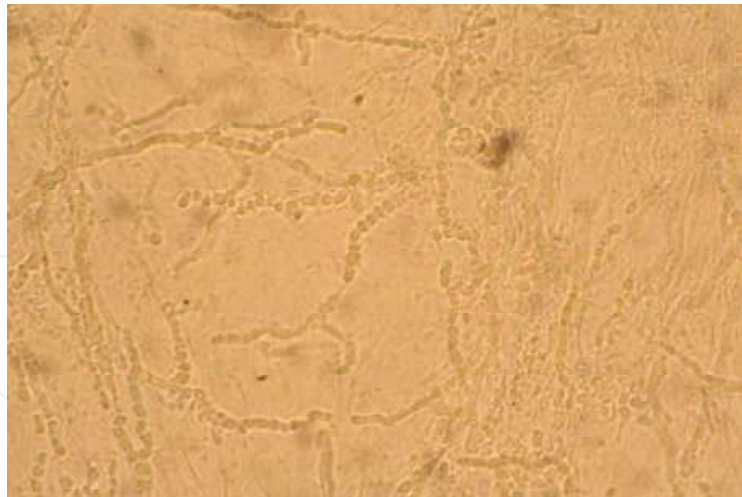


Fig. 6. KOH preparation 40X

The suggested technique for obtaining the sample for any type of onychomycosis is to clean the area with alcohol wipes, and scrape with a curette or a sterile scalpel blade the involved area of the nail. Part of the scale obtained is then placed in a slide with a drop of KOH and a coverslip. Slight heating of the slide's bottom with a match for a few seconds will accelerate the separation of the keratinocytes, facilitating the sample's observation. The rest of the scale will be used for culture. Of course, the clinical characteristics of the nail invasion will determine how the sample should be obtained.

For WSO, we recommend the use of a scalpel blade that should be used to scrape uniformly the affected area of the nail plate.

In the case of PWSO, the sampled area will depend on the localization of the white patch. When the leukonychia is proximal to the nail fold, a 15-scalpel blade is used to "drill" the dorsal area of the nail plate. We discard the first scales obtained, and save the ones from beneath. Much care should be placed in not perforating completely the nail plate's thickness. This would cause bleeding and pain. When the white area is already growing out of the nail, and has reached the distal border, or the leukonychia involves the totality of the nail plate, the sample can be obtained with a small curette, with the technique applied to DLSO, that is, scraping the ventral portion in the free border of the nail plate.

After the sample has been obtained and the mount prepared, the slide is placed in a light microscope and observed at 10X and 40X, where one can look for hyphae (Figure 6), arthroconidia or yeasts. In mycotic white nails fungal elements are usually abundant. After a few hours (3-4) the mount will no longer be useful.

Chlorazol black E is an aid for fungal structure identification. It is an acid stain that binds chitin found in the fungal structures, and not in the keratinocytes. The hyphae and or spores are stained green-blue, facilitating their identification under a light microscope. Studies have found that using Chlorazol black is more cost effective than KOH.

Clacofluor white is another stain employed for the identification of fungi in nail material. It binds to cellulose and chitin. It must be seen under a microscope with UV radiation (fluorescent) which are scarce and expensive. It is rarely used, but yields better results than KOH and Chlorazol black.

The sensibility of KOH mounts has been estimated of 80% (66-95%) and specificity of 72%. (47-72%). Positive and negative predictive values are 88 and 58% respectively. These results

rely mainly on the experience of the observer, and despite the previously described inconvenience, it is still considered the gold standard for the diagnosis of onychomycosis. The sensibility for Chlorazol black has been reported of 94%, making it one of the most cost effective diagnostic tests for onychomycosis (Weinberg *et al.*, 2003; Lilly *et al.*, 2006).

### 5.1.2 Cultures

Culture is the gold standard for accurate identification of the pathogen involved but not for clinical diagnosis. It is routinely performed in mycology laboratories as well as the KOH examination.

In the selection of the culture media we must consider that Sabouraud agar enables growth of dermatophytes but also of opportunistic fungi, and even bacteria. This is useful particularly when non-dermatophyte mould infection is suspected. Sabouraud plus Chloramphenicol and Actidione (Mycosel®) is more specific for dermatophytes since the antibiotics added limit opportunistic and bacterial growth.

The sample is the same as for direct examination. The scales are placed with sterile technique in Sabouraud dextrose and/or Mycosel® agar. The media are incubated at 25°C and are checked for growth once a week during four weeks.

The growth in cultures is observed macro and microscopically. Macroscopically, the number of colonies, color, texture, rate of growth, pigment production and other and characteristics of the strain are noted (Figure 7).



Fig. 7. *T. rubrum* culture

For microscopic identification, mounts are prepared with lactophenol-cotton blue and observed for microconidia, macroconidia, hyphae or spores that will enable us to identify the etiological agent (Figure 8).

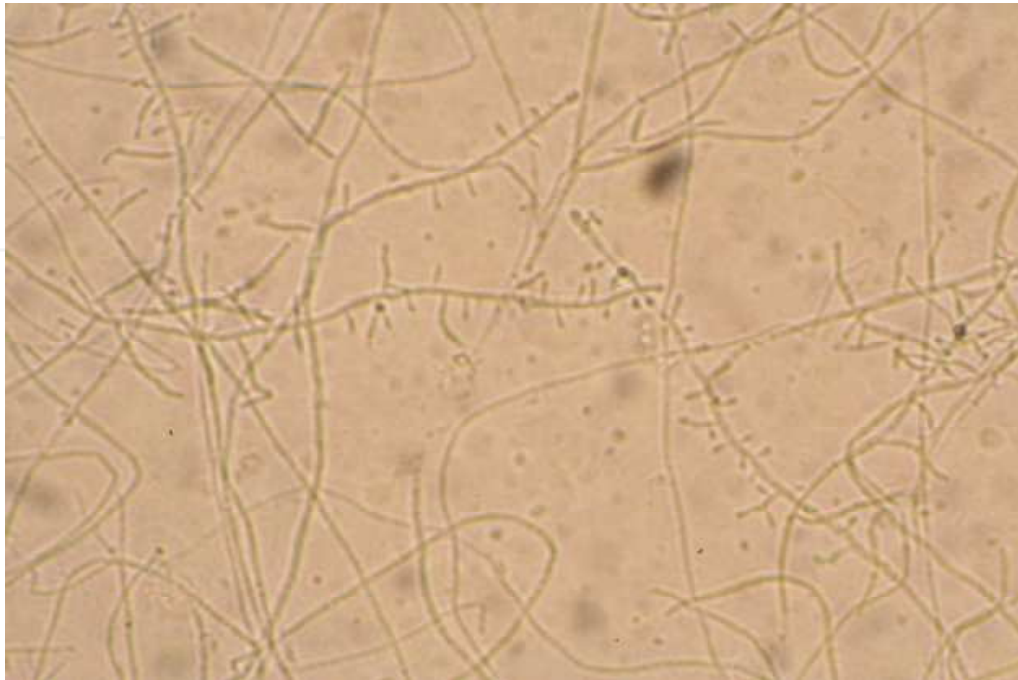

Fig. 8. *T. rubrum* 10X

The correct identification of the fungal species causing onychomycosis will allow the correct selection of the antifungal treatment.

The culture has a sensitivity of 59% (29-59%) and specificity of 82%. Between 30-50% of all cultures will grow, even with a positive direct examination, and it is important to recognize that this doesn't mean that there is no fungal infection. Many factors determine if a culture will grow, such as the sample site and amount of scale taken, viability of the dermatophytes, inoculation technique and storage temperature.

Correlation with KOH and clinical observations are fundamental for proper treatment and follow up.

### 5.1.3 Molecular biology

Some techniques such as polymerase chain reaction (PCR) are highly sensitive and specific for the identification of microorganisms such as fungi. The gene Chitin synthase 1 (CHS1) is shared by the three dermatophyte genera (*Trichophyton*, *Epidermophyton* and *Microsporum*) and can be evaluated in patients with onychomycosis.

This test not only allows the positive identification of fungal elements, it also identifies the fungal species, dermatophytes, non dermatophyte molds or yeasts, even in patients taking oral antifungal treatment.

PCR followed by restriction fragment length polymorphism (RFLP), real time PCR and multiplex PCR assay have been adapted for detection of dermatophytes in clinical specimens.

Maybe in the future at least one of these tests will be the gold standard for diagnosis and fungal species identification. For the moment, these techniques are inaccessible except for some select investigative laboratories (Garg *et al.*, 2009).

## 5.2 Histopathology

Nail plate or nail apparatus biopsy is rarely necessary for diagnosis, although it has been considered by some authors like the most sensitive and specific method for diagnosis. This could be true for those medical settings that lack a mycology laboratory.

The histopathological information that exists regarding the different clinical patterns of fungal invasion of the nail plate has been useful for the clinical classification of onychomycosis and hopefully will help understand more of the physiopathology of the disease.

Hematoxylin and eosin routine stain is performed, but the Peryodic Acid Schiff (PAS) staining technique is the most useful for this tissue (Figure 9). It easily enables the identification of the fungal structures where the hyphae and spores can be identified as eosinophilic structures mixed with the laminated keratinocytes that form the nail plate.

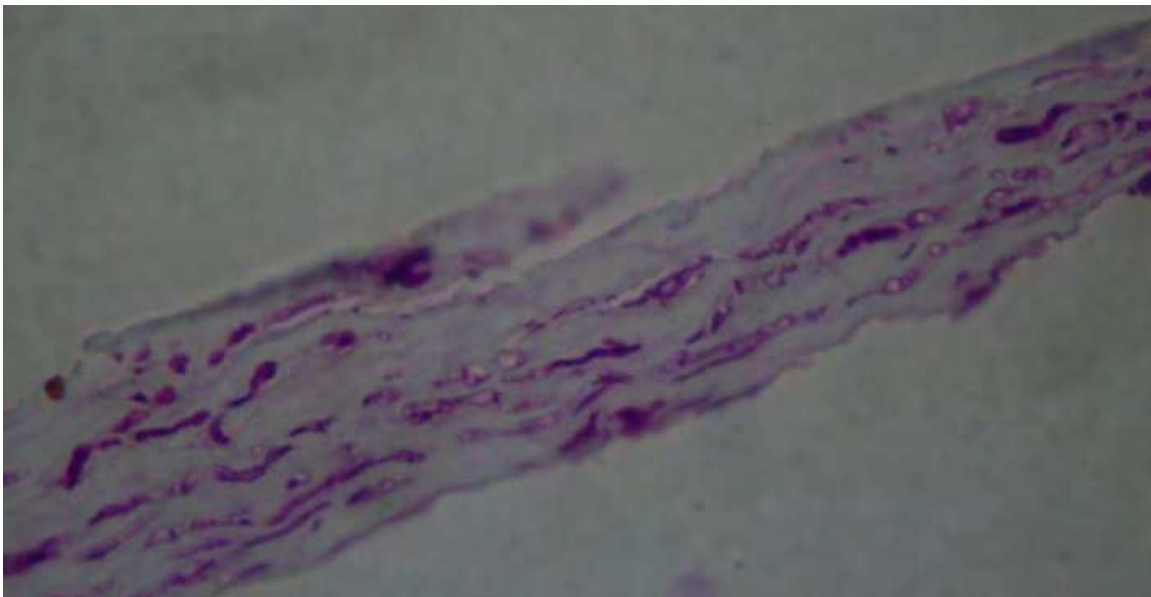


Fig. 9. Fungal structures in nail plate. PAS

The SWO has been identified as a superficial infection of the nail plate in most cases, and only rarely has been reported a “deep” SWO, involving as well the ventral aspect of the nail plate. The usual findings are hyphae and or spores in the dorsal aspect of the nail plate, generally confined to the upper half of the nail plate.

Some authors have suggested that SWO is not always caused by primary dorsal penetration, supported on the fact that sometimes the nail invasion is beneath the upper half that may even reach the ventral aspect of the nail plate. This may depend on the fungal agent involved and its affinity towards keratin and the enzymes required for its destruction.

The involvement in PWSO initiates and commonly remains localized to the ventral aspect of the nail, although progression to invasion of the entire nail plate thickness may also be seen.

Histology of leukonychia in transversal bands demonstrates that the nail is invaded intermittently, with spared areas of healthy nail that correlate to the band of healthy nail observed clinically. This suggests that re-activation may be episodic in these cases (Baran *et al.*, 2005; Moreno-Coutiño *et al.*, 2010; Nandedkar *et al.*, 2005).

Apparently, the etiological agent does not vary the infection pattern in the nail plate. Similar findings have been reported in *T. rubrum* and *M. canis* infected nails, where all the nail plate,

from the matrix to the distal portion, shows invasion by numerous fungal elements, particularly in the ventral aspect of the nail plate.

Piraccini *et al.* evaluated the nail bed, searching for fungal invasion as well, since the principal amount of fungi are found in the part of the nail plate that is in direct contact with the nail bed. The histology showed that there is no fungal invasion of this tissue, and is also devoid of inflammatory changes (Piraccini *et al.*), .

Currently, the study of the nail plate by histology with PAS stain has been reported to have 92% (85-98.85) of sensibility and 72% of specificity, with a positive and negative predictive value of 89.7% and 77% respectively.

## 6. Treatment and outcome

The treatment of onychomycosis, that is a chronic and mostly asymptomatic disease, sometimes is postponed by many reasons, either from part of the physician or the patient.

However, immunocompromised patients such as those living with HIV, search for treatment due to psychosocial reasons. The burden of knowing themselves with the HIV infection, makes them extra-conscious of their appearance, beyond being esthetically acceptable, they seek a healthy appearance.

To choose the adequate antifungal drug, one must consider several factors. Of course, the clinical pattern of onychomycosis is probably the most determinant of all, as will be discussed further. The number of nails involved and the percentage of affection, previous treatments for the fungal infection and for other diseases, allergies, and finally, the socioeconomic status is a very important factor in this group of patients.

Recently, effective antimycotics, in particular terbinafine, was shown to enhance and restore cell-mediated immunity, which potentially improves the therapeutic outcome even for this group of patients

Currently, three main strategies apply: topical, oral and combination treatment. Amorolfine nail lacquer and oral terbinafine are the most effective drugs as monotherapy. However, the best cure rates are obtained with a combination of oral and local therapy (Lecha *et al.* 2005).

Clues to consider:

### 1. Clinical pattern of onychomycosis

As the name describes, WSO is superficial as the infection remains in the dorsal aspect of the nail plate. This is the only one that may be treated with topical medications such as a lacquer or by chemical avulsion of the nail plate. It is important to remember that transungual delivery of the drug is limited by the low permeability of the nail plate, so repeated dosing over a long period is required.

It is a common finding that WSO is combined with any other clinical form of onychomycosis. In this case, the patient must be treated according to the most severe pattern shown.

PWSO varies clinically depending on the time of the diagnosis. This onychomycosis initiates in the matrix area, and as the nail grows, the area involved may grow out too, or the disease may spread to affect the entire nail plate. For this clinical form, the recommended treatment approach is oral antimycotics, such as terbinafine or itraconazole.

General guidelines state that oral treatment is indicated if the matrix area is involved and/or more than 50% of the nail plate is affected.

### 2. Isolated fungi

Specific identification of the fungal pathogen is useful for adequate prescription. Dermatophytes are successfully treated with terbinafine or itraconazole. However, NDM have



not shown a better cure rate if treated with oral antifungals. Terbinafine has no effect over *Candida* sp. infection, so in cases of paronychia, itraconazole is recommended (Hogan, 2006).

### 3. Socioeconomic status

Antifungal medication, particularly oral and lacquer are very expensive, and should be administered continuously for several months. Before prescribing the antifungal, one must consider cost-benefit, availability and accessibility of the treatment.

### 4. Comorbidities and other prescription drugs

Most systemic antifungals potentially have interactions with other drugs.

## 6.1 Antifungals

### 6.1.1 Topical

#### Lacquer

Commercially three different antimycotics are available in lacquer. All of them show similar cure rates, but the continuous application is required for an average of 4 months (Sidou *et al.* 2004; Sigurgeisson *et al.* 2010; Subissi *et al.* 2010).

#### Amorolfine 5%

Is a morpholine derivative with broad spectrum as antifungal agent, including dermatophytes, NDM, and yeasts. It is fungicidal for most species. It rapidly penetrates the nail, and the clearance is slow because it is applied in a non-water soluble film that remains in the nail for a week. This drug is well tolerated and minor local adverse reactions are observed rarely. In vitro, apparently amorolfine synergizes with ketoconazole, griseofulvin and terbinafine.

It is indicated once a week, approximately 6 months. This is the most recommended drug, since it has shown longer remanence on the nail surface, more resistance to chemical trauma from soaps and mechanical aggressions to the nail apparatus, and is the most cost-effective of the lacquers. It is safe and effective as prophylaxis of recurrence in these patients that relapse frequently.

#### Ciclopirox 8%

It has a broad spectrum drug including almost all of the clinically relevant dermatophytes, yeasts and moulds. It is active against azole-resistant *Candida* and even some bacteria. The main antimicrobial activity apparently is by inhibition of the metal dependent enzymes that are responsible for degradation of peroxides within the fungal cell. The fungal resistance to this drug is extremely low and shows a mild anti-inflammatory effect in biochemical and pharmacological models. It is considered to have high affinity to keratin and good nail permeation. As a topical drug, it is devoid of systemic adverse reactions. Mild erythema has seldom been reported (<5% treated patients). This lacquer must be applied every other day the first month, twice a week the second and once a week for one or two more months.

#### Tioconazole 28%

It is an imidazole with activity against moulds and yeasts. This is the least recommended because of its posology and limited effectiveness. The suggested dosage is twice a day during 6-12 months.

#### Chemical avulsion

Chemical destruction of the nail plate with occlusive 40% urea and bifonazole 1% is recommended for patients that have very thickened nail plate, dermatophytoma or when

oral therapy is contraindicated. It is also an effective and low cost adjuvant to oral therapy, particularly in cases of NMD infection or pediatric patients.

Urea is a keratolytic that destroys hydrogen unions. This destruction allows the antifungal to penetrate deeply in the nail plate for better results. Bifonazole is a wide spectrum azolic derivate with activity against yeasts, dermatophytes and NDM, lipophilic and hydrophobic that allows long cutaneous retention of the drug. It is applied under occlusion once a day and the softened nail plate must be removed before reapplying the medication. The most common side effects are local erosion and pain that remit when the treatment is suspended (Arenas, 2001, Carrillo-Muñoz *et al.* 2010).

### 6.1.2 Systemic (oral)

#### Terbinafine

This antimycotic is by far the most widely prescribed oral medication because of its low incidence of drug interactions compared to azoles. Terbinafine is an allylamine that reaches steady-state in the nail matrix and bed in one week, and plasma levels in 10-14 days. Because of its keratinophilic and lipophilic characteristics, this drug persists in the nail apparatus for 24-156 days.

It is fungicidal and fungistatic, with broad spectrum for moulds. Its absorption is not affected by food, is metabolized extensively in the liver and excreted principally in urine. The terminal half life is of 16-22 hr. that may be prolonged in patients with liver or renal impairment, particularly those with <50 mL/min of creatinine clearance or >300 µMol/ of serum creatinine. The most recognized drug interactions are with cimetidine and rifampin. Terbinafine also inhibits the cytochrome P4502D6 (CYP2D6) so caution is recommended when administering CYP2D6 substrates.

The mycological cure rate has been reported 48-90% on different trials, and has always been superior in comparison to placebo, itraconazole, griseofulvin and fluconazole. Only one case of *T. rubrum* resistant to terbinafine has been published.

It can be administered daily 250 mg/3-4 months, or in pulses, 250 mg twice a day for one week each month at least during four months.

No drug interactions have been observed in patients living with HIV/AIDS in several reports (Elewski & Tavakkol, 2005; Osborne *et al.* 2006).

#### Itraconazole

This is a fungistatic drug that diffuses through the matrix and nail bed 3-12 weeks, but then these levels are sustained in the nail plate for several months. It is well tolerated, and less than 3% of the patients report adverse effects. The most common are headache and gastrointestinal symptoms. In skin, rash and pruritus have been seldomly reported.

It is better absorbed if taken with food. It's absorption is reduced by antacids as omeprazole, cimetidine and ranitidine. Because this drug is metabolized in the liver by CYP3A4, the potential for interaction with other drugs is important to consider. Its prescription is contraindicated with antidysrhythmics, antimalarials, benzodiazepines, antipsychotic and statins. Serum levels of warfarin, cisapride and cyclosporine should be monitored in concomitant therapy. Concurrent administration with antidiabetic drugs may cause hypoglycemia. Liver enzyme elevations are reported in 0.3-0.5%.

Specifically in patients living with HIV/AIDS, is important to remember that rifampin and other antituberculous drug may vary serum levels of itraconazole. Protease inhibitors also inhibit CYP3A4, and a dose reduction of itraconazole may be required.

However, despite all the contraindications and precautions, itraconazole is effective in clearing onychomycosis as well as systemic fungal infections commonly seen in this group of patients, so in clinical practice, itraconazole dosage is frequently adjusted to cure both fungal diseases.

The recommended dose for onychomycosis is 200 mg/day or 200 mg twice a day for one week during four months.

### **Fluconazole**

This is another azole, with similar mode of action and drug interactions than itraconazole. It is widely prescribed as prophylaxis for opportunistic fungal infections in immunosuppressed patients. Nonetheless, it is not recommended for onychomycosis treatment, since terbinafine and itraconazole have better cure rates in shorter periods.

### **6.2 Combination therapy**

The combination of topical and systemic treatment increases antifungal spectrum, fungicidal activity and safety. It also reduces treatment duration.

Any lacquer or urea may be combined with systemic antifungals such as terbinafine or itraconazole. The decision must be made considering the clinical pattern, number of nails involved, general health status of the patient and accessibility to the drugs.

Many trials have reported the outcome of combination therapy. The most successful ones are those that include terbinafine or itraconazole. One of them reported that the combination of amorolfine and terbinafine had a 59% success rate compared to 45% in the group of oral terbinafine only. Treatment cost was lower in the combination group. Other combinations find similar results.

Another approach is the combination of oral antifungal with surgical avulsion of the infected nail. One of us has reported a better response rate, combining with terbinafine in pulses. However, we do not recommend this technique as first line of treatment, because it is invasive, painful, and must be performed by a nail surgery expert (Baran *et al.* 2007; Domínguez-Cherit *et al.* 1999).

### **6.3 Observation**

For patients that recently initiated antiretroviral therapy (ARV) we recommend observation for approximately six months. This obeys to several reasons. First of all, because they must accept and tolerate the ARV medications and its side effects which almost all patients refer. Even though most are mild and transient they must adequate their life style to them and wait for the majority of adverse effects to disappear. Another reason is that in our clinical practice, we have observed several times that these patients clinically improve, that is, the area of onychomycosis is reduced, or even cure completely by allowing the immune system restoration with ARV therapy (Tachikawa, *et al.* 1999).

## **7. Differential diagnosis**

Differential diagnosis should be done with any other cause of leukonychia. The list is long and includes congenital and acquired diseases. Among the most common causes in the HIV/AIDS infected patients include frequent skin diseases as dyshidrosis or erythema multiforme, systemic acute infections such as pneumonia, herpes zoster, or even intoxication with lead, antimony, fluoride, androgen therapy, cirrhosis, hyperalbuminemia,

gout, protein deficiency, kidney transplant and renal failure either acute or chronic, parathyroid insufficiency, Hodgkin's disease and intra-abdominal malignancies, cachectic state, peripheral neuropathy, shock, surgery and drugs such as hydroxyurea.

## 8. Conclusions

Fungal leukonychia is common in patients living with HIV/AIDS or those that have any other cause of immunosuppression. However, OSDL continues to be the most prevalent presentation of onychomycosis.

The findings of PWSO or SWO are not synonymous of HIV infection, but should alert the physician of that possibility.

Patients with HIV infection present onychomycosis in a more extensive manner, involving many nails simultaneously and with rapid evolution. This is apparently directly related to a decline in the immune system function.

An adequate approach to diagnosis will allow the best evaluation of each particular case, and on that basis, decide the best option of treatment for the patient. Ideally, every patient must be evaluated by a dermatologist who will take the scales for a KOH direct examination and a mycological culture.

The direct exam with KOH or Chlorazol Black is the best. test for diagnosis and most cost-effective. It should be complemented with a culture, although the possibility of a negative result is high. When the diagnosis is not clear after these tests, or a mycology laboratory is inaccessible, a biopsy of the nail plate, stained with PAS can be performed with high sensibility and specificity for diagnosis.

To determine the treatment, we must always keep in mind the general state and socioeconomic situation. This will allow us to choose the best option in each case.


## 9. References

- Arenas R. 1990. Las onicomycosis. Aspectos clínico-epidemiológicos, micológicos y terapéuticos. *Gaceta Médica de México*;126:84-91, ISSN 00163813
- Arenas R. Dermatophytosis In: Arenas R & Estrada R., 2001. *Tropical Dermatology*. Landes Bioscience, ISBN 1-57059-493-7 USA, pg 2-11
- Arenas R, Bonifaz A, Arce M, Padilla MC, Atoche C, Barba J, Campos P, Fernández R, Mayorga J, Nazar D & Ocampo J. Onychomycosis. 2010. A Mexican survey. *Eur J Dermatol*; 20 (5)Sep-Oct 2010:611-614. ISSN 1167-1122
- Baran R, & Dawber RPR. 1994 Physical signs, In: *Diseases of the nails and their management*. Baran R, & Dawber RPR, PP: 35-81;Blackwell Scientific Publications (2<sup>nd</sup> Edition), ISBN 0-632-03754-7, Spain.
- Baran R, Hay R, & Perrin C. 2004. Superficial white onychomycosis revisited. *JEADV*; 18(5) Sep 2004: 569-571. ISSN 0926-9959
- Baran R, McLoone N, & Hay RJ.2005. Could proximal white subungual onychomycosis be a complication of systemic spread? The lessons to be learned from maladie dermatophytique and other deep infections. *Br J Dermatol* 153(5)Nov 2005: 1023-1025 ISSN 0007-0963
- Baran R, Faergemann J & Hay RJ. 2007. Superficial white onychomycosis-A syndrome with different fungal causes and paths of infection. *J Am Acad Dermatol* 57(5) Nov 2007: 879-882. ISSN 0190-9622

- Baran R, Sigurgeirsson B, de Becker D, Kaufmann R, Lecha M, Faegemann J, Kerrouche N, & Sidou F. 2007. A multicentre, randomized, controlled study of the efficacy, safety and cost-effectiveness of a combination therapy with amorolfine nail lacquer and oral terbinafine compared with oral terbinafine alone for the treatment of onychomycosis with matrix involvement. *Br J Dermatol* 157(1)Jul 2007:149-157 ISSN 0007-0963
- Blanes M, Belichón I, Merino E, Portilla J, Sánchez-Payá J, & Betlloch I. 2010. Prevalencia y características de las dermatosis relacionadas con la infección por VIH en la actualidad. *Actas Dermosifilogr* 101(8); Oct 2010: 702-709. ISSN 0001-7310
- Carrillo-Muñoz AJ, Tur-Tur C, Hernández-Molina JM, Santos P, Cárdenes D, & Giusiano G. 2010. Antifúngicos disponibles para el tratamiento de las micosis ungueales. *Rev Iberam Micol* 27(2):Jun 2010:49-56 ISSN 1130-1406
- Chang P, & Arenas R. 1995. Proximal white subungual onychomycosis in a kidney transplant patient. *Int J Dermatol* 34(8)Aug 1995: 591. ISSN 0011-9059
- Cribier B, Leiva Mena M, Rey D, Partisani M, Fabien V, Lang JM, & Grosshans E.1998. Nail changes in patients infected with human immunodeficiency virus. *Arch Dermatol* 34(10) Oct 1998: 1216-1220.ISSN 0003-987X
- Crozier WJ, & Lavrin LM.1979. An uncommon case of onychomycosis due to *Microsporum canis*. *Australasian Journal of Dermatology* 20(3):Dec 1979:144-146 ISSN 1440-0960
- Denning DW, Evans EGV, Kibbler CC, Richardson MD, Roberts MM, Rogers TR, Warnock DW, & Warren RE. 1995.
- Fungal nail diseases: a guide to good practice (report of a working group of the British Society for Medical Mycology) *BMJ* 311 (7015): Nov 1995: 1277-1281. ISSN 0959-8138
- Drake LA, Patrick DL, Fleckman P, André J, Baran R, Haneke E, Sapède C, & Tosti A. 1999. The impact of onychomycosis on quality of life: Development of an international onychomycosis-specific questionnaire to measure patient quality of life. *J Am Acad Dermatol* 41(2 Pt 1) Aug 1999: 189-196 ISSN 0190-9622
- Domínguez-Cherit J, Teixeira F, & Arenas R. 1999. Combined surgical and systemic treatment of onychomycosis. *Br J Dermatol* 140(4): Apr 1999:778-780 ISSN 0007-0963
- Domp Martin D, Domp Martin A, Deluol AM, Grosshans E, & Coulaud JP. 1990. Onychomycosis and AIDS clinical and laboratory findings in 62 patients. *Int J Dermatol* 29(5): Jun 1990:337-339. ISSN 0011-9059
- Elewski B.1998. Onychomycosis: pathogenesis, diagnosis and management. *Clin Microbiol Rev.* 11(3): Jul 1998:415-429. ISSN 0893-8512
- Elewski B, & Tavakkol A. 2005. Safety and tolerability of oral antifungal agents in the treatment of fungal nail disease: a proven reality. *Ther Clin Risk Management* 1(4): Dec2005:299-306. ISSN 1176-6336
- Garg J, Tilak R, Garg A, Prakash P, Gulati AK & Nath G. 2009. Rapid detection of dermatophytes from skin and hair. *BMC Res Notes* 2 ; Apr 2009:60. ISSN 1756-0500
- Grossman M., & Scher RK. 1990. Leukonychia. Review and classification. *Int J Dermatol* 29(8), Oct 1990: 535-541. ISSN 0011-9059
- Gupta AK, Sibbald RG, & Lynde ChW.1997. Onychomycosis in children: Prevalence and treatment strategies. *J Am Acad Dermatol* 36(3 pt 1); Mar 1997: 395-402 ISSN 01909622

- Gupta AK, & Summerbell RC.1999. Combined distal and lateral subungual and white superficial onychomycosis in the toenails. *J Am Acad Dermatol* 41(6): Dec 1999:938-944 ISSN 0190-9622
- Baran R, Hay RJ, Tosti A, & Haneke E. 1998. A new classification of onychomycosis. *Br J Dermatol* 139(4) Oct 1998:567-571 ISSN 0007-0963
- Gupta AK, Taborda P, Taborda V, Gilmour J, Rachlis A, Salit I, Gupta MA, Mac Donald P, Cooper EA, & Summerbell RC.2000. Epidemiology and prevalence of onychomycosis in HIV-positive individuals. *Int J Dermatol* 39(10) Oct 2000: 746-753 ISSN 0011-9059
- Havlickova B, Czaika VA, & Friedrich M. 2008. Epidemiological trends in skin mycoses worldwide. *Mycoses* 51 suppl 4; Sep 2008:2-15 ISSN 0933-7407
- Herranz P, Garcia J, de Lucas R, Gonzalez J, Peña JM, Diaz R, & Casado M.1997. Toenail onychomycosis in patients with acquired immune deficiency syndrome: treatment with terbinafine. *Br J Dermatol* 137(4) Oct 1997:577-580 ISSN 0007-0963
- Hogan M. 2006. Cutaneous infections associated with HIV/AIDS. *Dermatol Clin* 24(4) Oct 2006: 473-495 ISSN 0733-8635
- Lecha M, Effendy I, Feullhade de Chauvin M, Di Chiacchio N, & Baran R. 2005. Treatment options-development of consensus guidelines. *J Eur Acad Dermatol Venereol Suppl* 1, 2005: 25-33.ISSN 1468-3083
- Lilly KK, Koshnick RL, Grill JP, Khalil ZM, Nelson DB, Warshaw EM. Cost-effectiveness of diagnostic tests for toenail onychomycosis: a repeated-measure, single-blinded, cross-sectional evaluation of 7 diagnostic tests. *J Am Acad Dermatol* 55(4) Oct 2006: 620-626 ISSN 0190-9622
- Millikan LE, Powell DW, & Drake LA. 1999. Quality of life for patients with onychomycosis. *Int J Dermatol* 38: suppl 2:Sep1999:13-16. ISSN 0011-9059
- Moreno-Coutiño G, Toussaint-Caire S, & Arenas R. 2010. Clinical, mycological and histological aspects of white onychomycosis. *Mycoses* 53(2): Mar 2010:144-147 ISSN 0933-7407
- Moreno-Coutiño G, Arenas R, & Reyes-Terán G. 2011. Clinical presentation of onychomycosis in HIV/AIDS: a review of 280 mexican cases. *Indian J Dermatol* 56(1) Jan-Feb 2011:120 ISSN 0019-5154
- Nandedkar-Thomas MA, & Scher RK. 2005. An update in disorders of the nails. *J Am Acad Dermatol* 52(5) May 2005: 877-887 ISSN 0190-9622
- Noppakun N, & Head E. 1986. Proximal white subungual onychomycosis in a patient with acquired immune deficiency syndrome. *Int J Dermatol* 25(9): Nov 1986:586-587 ISSN 0011-9059
- Odds FC, Arai T, Disalvo AF, Evans EG, Hay RJ, Randhawa HS, Rinaldi MG, & Walsh TJ. 1992. Nomenclature of fungal diseases: a report and recommendations from a sub-committee of the international society for human and animal mycology (ISHAM) *J Med Vet Mycol* 30(1): 1992:1-10 ISSN 0268-1218
- Osborne CS, Leitner I, Hofbauer B, Fielding CA, Favre B, & Ryder N. 2006. Biological, biochemical, and molecular characterization of a new clinical Trichophyton rubrum isolate resistant to terbinafine. *Antimicrob Agents Chemother* 50(6); Jun 2006: 2234-2236.ISSN 0066-4804
- Piraccini BM, & Tosti A. 2004. White superficial onychomycosis: epidemiological, clinical and pathological study of 79 patients. *Arch Dermatol* 140(6): Jun 2004:696-701.ISSN 0003-987X

- Piraccini BM, Morelli R, Stinchi C, Tosti A. Proximal subungual onychomycosis due to *Microsporum canis*. *Br J Dermatol* 134(1) Jan 1996: 175-177 ISSN 0007-0963
- Ravnborg L, Baastrup N, & Svejgaard E. 1998. Onychomycosis in HIV-infected patients. *Acta Derm Venereol* 78(2):Mar 1998:151-152 ISSN 0001-5555 Scher RK, Tavakkol A, Sigurgeirsson B, Hay RJ, Joseph WS, Tosti A, Fleckman P, Ghannoum M, Armstrong DG,
- Markinson BC, & Elewski B. 2007. Onychomycosis: diagnosis and definition of cure. *J Am Acad Dermatol* 56(6) Jun 2007:939-944 ISSN 0190-9622
- Sidou F, & Soto P. 2004. A randomized comparison of nail surface remanence of three nail lacquers, containing amorolfine 5%, ciclopirox 8% or tioconazole 28% in healthy volunteers. *Int J Tissue React* 26(1-2) 2004:17-24. ISSN 0250-0868
- Subissi A, Monti D, Togni G, & Mailland F. 2010. Ciclopirox: recent nonclinical and clinical data relevant to its use as a topical antimycotics agent. *Drugs* 70(16) Nov 2010: 2133-2152. ISSN 0968-7637
- Sigurgeirsson B, Olafsson JH, Steinsson JT, Kerrouche N, & Sidou F. 2010. Efficacy of amorolfine nail lacquer for prophylaxis of onychomycosis over 3 years. *J Eur Acad Dermatol Venerol* 24 (8) Aug 2010: 910-915 ISSN 1468-3083
- Singh H, Singh P, Tiwari P, Dey V, Dulhani N, & Singh A. 2009. Dermatological manifestations in HIV-infected patients at a tertiary care hospital in a tribal (Bastar) region of Chhattisgarh, India. *Indian J Dermatol* 54(4); 2009: 338-341 ISSN 0019-5154
- Surjushe A, Kamath R, Oberai C, Saple D, Thakre M, Dharmshale S, & Gohil A. 2007. A clinical and mycological study of onychomycosis in HIV infection. *Indian J Dermatol Venereol Leprol* 73(6): Nov-Dec 2007: 397-401 ISSN 0019-5154
- Tachikawa N, Yasuoka A, & Oka S. 1999. Improvement of Onychomycosis without Antifungal Therapy after Initiation of Highly Active Anti-Retroviral Therapy (HAART) in an HIV-Infected Patient. *Jpn J Infect Dis* 52(6); Dec1999: 245-46. ISSN 1344-6304
- Vásquez del Mercado E, & Arenas R. 2008. Onicomicosis en niños. Estudio retrospectivo de 233 casos mexicanos. *Gac Med Mex* 144(1) Jan-Feb 2008: 7-9 ISSN 00163813
- Weinberg JM, Koestenblatt EK, Don PC, White SM, Stein MN, & Bamji M. 1999. Proximal white subungual onychomycosis in the immunocompetent patient: report of two cases and review of the literature. *Acta Derm Venereol* 79(1) Jan1999: 81-95 ISSN 0001-5555
- Weinberg JM, Koestenblatt EK, Tutrone WD, Tishler HR, & Najarian L. 2003. Comparison of diagnostic methods in the evaluation of onychomycosis. *J Am Acad Dermatol* 49(2); Aug 2003: 193-197 ISSN 0190-9622
- Weismann K, Knudsen EA, & Pedersen C. 1988. White nails in AIDS/ARC due to *Trichophyton rubrum* infection. *Clin Exp Dermatol* 13(1) Jan1988: 24-25. ISSN 0307-6938
- WHO case definitions of HIV for surveillance and revised clinical staging and immunological classification of HIV-related disease in adults and children, 2006 <http://www.who.int/hiv/pub/guidelines/HIVstaging150307.pdf> (April 11, 2011
- Woodfolk JA. 2005. Allergy and dermatophytes. *Clin Microbiol Reviews* 18(1); Jan 2005:30-43. ISSN 0893-8512 [www.who.int/hiv/data/2009\\_global\\_summary.png](http://www.who.int/hiv/data/2009_global_summary.png) January 31<sup>st</sup> 2011
- Zaias N. 1972. Onychomycosis. *Arch Dermatol*.105(2); Feb 197:263-74 ISSN 0003-987X



## **Microbes, Viruses and Parasites in AIDS Process**

Edited by Prof. Vladimír Zajac

ISBN 978-953-307-601-0

Hard cover, 390 pages

**Publisher** InTech

**Published online** 19, October, 2011

**Published in print edition** October, 2011

The main goal in compiling this book was to highlight the situation in Africa in terms of AIDS and opportunistic diseases. Several chapters reveal great poverty, an apocalyptic situation in many parts of Africa. Global migration of people resulted in their exposure to pathogens from all over the world. This fact has to be acknowledged and accepted as African reality. New, unconventional hypotheses, not determined by established dogmas, have been incorporated into the book, although they have not yet been sufficiently validated experimentally. It still applies that any dogma in any area of science, and medicine in particular, has and always will hinder progress. According to some biologists, in the future, AIDS is very likely to occur in a number of variations, as a direct result of the ongoing processes in the global human society. Thus, we urgently need a comprehensive solution for AIDS, in order to be ready to fight other, much more dangerous intruders.

### **How to reference**

In order to correctly reference this scholarly work, feel free to copy and paste the following:

Patricia Chang, Gabriela Moreno-Coutiño and Roberto Arenas (2011). Mycotic Leukonychia in HIV Patients, *Microbes, Viruses and Parasites in AIDS Process*, Prof. Vladimír Zajac (Ed.), ISBN: 978-953-307-601-0, InTech, Available from: <http://www.intechopen.com/books/microbes-viruses-and-parasites-in-aids-process/mycotic-leukonychia-in-hiv-patients>

**INTECH**  
open science | open minds

### **InTech Europe**

University Campus STeP Ri  
Slavka Krautzeka 83/A  
51000 Rijeka, Croatia  
Phone: +385 (51) 770 447  
Fax: +385 (51) 686 166  
[www.intechopen.com](http://www.intechopen.com)

### **InTech China**

Unit 405, Office Block, Hotel Equatorial Shanghai  
No.65, Yan An Road (West), Shanghai, 200040, China  
中国上海市延安西路65号上海国际贵都大饭店办公楼405单元  
Phone: +86-21-62489820  
Fax: +86-21-62489821



© 2011 The Author(s). Licensee IntechOpen. This is an open access article distributed under the terms of the [Creative Commons Attribution 3.0 License](#), which permits unrestricted use, distribution, and reproduction in any medium, provided the original work is properly cited.

IntechOpen

IntechOpen