

We are IntechOpen, the world's leading publisher of Open Access books Built by scientists, for scientists

4,800

Open access books available

122,000

International authors and editors

135M

Downloads

Our authors are among the

154

Countries delivered to

TOP 1%

most cited scientists

12.2%

Contributors from top 500 universities

**WEB OF SCIENCE™**Selection of our books indexed in the Book Citation Index
in Web of Science™ Core Collection (BKCI)

Interested in publishing with us?
Contact book.department@intechopen.com

Numbers displayed above are based on latest data collected.

For more information visit www.intechopen.com

Combinations of Markers Provide Clues to the Underlying Neurodegenerative Disorder in REM Sleep Behavior Disorder

Tomoyuki Miyamoto¹ and Masayuki Miyamoto²

¹*Department of Neurology, Dokkyo Medical University, Koshigaya Hospital,*

²*Department of Neurology, Center of Sleep Medicine, Dokkyo Medical University, Japan*

1. Introduction

REM sleep behavior disorder (RBD) is characterized by dream-enacting behaviors and unpleasant dreams, and presents a risk for self-injury and harm to others due to abnormal REM sleep during which control of muscle tonus is lacking (REM sleep without atonia) (Schenck et al., 1986; Schenck et al., 2002; American Academy of Sleep Medicine 2005). RBD is a heterogeneous disease entity consisting of a variety of manifestations (Schenck et al., 2002; Gagnon et al. 2006; Postuma et al., 2006, 2009; Maetzler et al., 2009). Idiopathic RBD (iRBD), which develops in middle age or later and progresses chronically, in particular is a common clinical manifestation of Lewy body-related syndrome and is regarded as a clinical entity from pathological aspects. For example (Table 1), it has been elucidated that iRBD is often accompanied by soft motor signs, olfactory and color identification deficits, decreased cardiovascular and respiratory changes between REM and Non-REM sleep, reduced cardiac ¹²³I-metaiodobenzylguanidine (123I-MIBG) uptake, impairment of visual memory and visuo-spatial construction revealed by neuropsychological testing, EEG slowing during wakefulness or sleep, and decreased strial dopaminergic innervation and reduced pre-synaptic strial dopamine transporter binding on SPECT or positron emission topography (PET) scans, which are considered as non-motor symptoms of Parkinson's disease (PD) (Becker et al., 2002; Gagnon et al., 2006; Miyamoto et al., 2006; Miyamoto et al., 2008). Furthermore, despite the limited number of pathological reports on iRBD, the characteristics of iRBD have been supported to have a close relationship with Lewy body pathology (Boeve et al., 2007). Therefore, additional clinical features that could distinguish iRBD with Lewy body-related alpha-synucleinopathies from iRBD due to other causes would be helpful in clinical practice.

Transcranial ultrasound imaging of the substantia nigra
 Olfactory dysfunction
 Impairment of visual functions
 Visualization of postganglionic sympathetic cardiac neurons by ¹²³I-metaiodobenzylguanidine (MIBG) scintigraphy
 MRI
 Cognitive decline
 Affective symptoms
 Motor testing
 Sleep disturbance
 REM sleep behavior disorder
 Daytime sleepiness
 Fatigue
 Insomnia

Table 1. Early diagnosis of Parkinson's disease

2. Polysomnography

Loss of REM sleep atonia is the essential hallmark of RBD. Abnormal activity of phasic REM sleep components is essential for the induction of dream-enacting behaviors during REM sleep in iRBD. Motor-behavioral episodes in RBD are significantly more likely to occur in association with phasic than with tonic periods of REM sleep (Figure 1). Excessive tonic and phasic EMG activity during REM sleep has been shown to increase over time in subjects with iRBD (Iranzo et al. 2009). This finding suggests that, in subjects with iRBD, there is an underlying progressive pathologic process damaging the brainstem structures that modulate REM sleep. Out of a group of potential predictive markers, higher % tonic EMG activity was the most predictive of development of PD (Postuma et al. 2009).

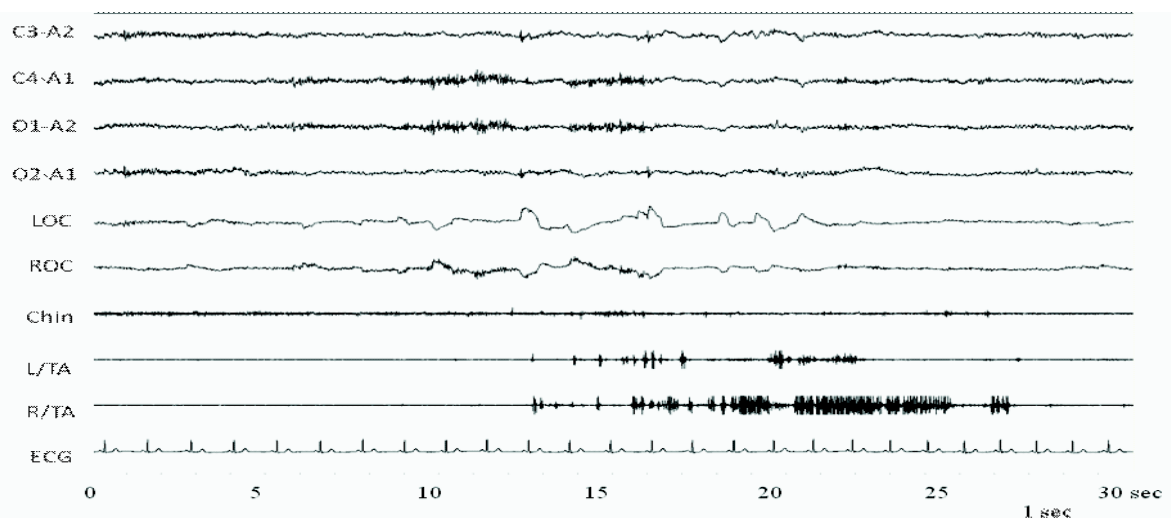


Fig. 1. Stage of RWA in a patient idiopathic REM sleep behavior disorder. The recording shows sustained elevation of submental and tibialis anterior (TA) EMG concomitant with phasic EMG elevation. EEG bears the characteristic feature of REM sleep, low voltage activity with mixed frequency, and EOG demonstrates clusters of rapid eye movements. RWA, REM sleep without atonia; EOG, electrooculogram.

3. Olfactory dysfunction

Olfactory disturbance is present in most PD or pure autonomic failure (PAF) cases (Doty et al., 1995; Goldstein et al., 2009; Silverira-Moriyama et al., 2009). The deficit in olfaction in PD contrasts with previous reports of preserved or only mildly reduced olfaction in patients with atypical parkinsonism such as a tauopathy or multiple system atrophy (MSA) (Doty et al., 1993; Wenning et al., 1995). In dementia patients, neuropathologic studies reported neuronal alterations in several subcortical structures such as the olfactory tract/bulb, anterior olfactory nucleus, orbito-frontal cortex, hippocampus, and amygdala in the olfactory system (Hubbard et al., 2007). Olfactory abnormalities have been reported in Alzheimer's disease (AD), but anosmia appears to be common in dementia with Lewy bodies (DLB) but not in pure AD (McShane et al., 2001). A Lewy body variant of AD had an increased frequency of anosmia compared with "pure" AD (Olichney et al., 2005). Furthermore, olfactory impairment is more marked in patients with mild dementia with Lewy bodies than in those with mild AD (Williams et al., 2009). In addition to reduced odor identification prior to the onset of PD, olfactory dysfunction has been frequently recognized in patients with incidental Lewy body disease (ILBD) (Ross et al. 2006). Also, neuropathological olfactory bulb alpha-synuclein has high specificity and sensitivity for Lewy body formation in confirmed cases of PD and DLB (Beach et al., 2009). On the basis of pathological studies of a large number of autopsy cases, Braak et al. proposed a hypothesis as to the onset and advancement pattern of PD in that the disease developed from the medulla and olfactory bulb and extended to the pons and substantia nigra (SN) (Braak et al., 2003). In the Honolulu-Asia Aging Study of Japanese Americans, 2,267 males without PD and dementia at the time of olfaction testing were followed-up, and more subjects who developed olfactory dysfunction in the first 4-year follow-up period developed PD than those who did not develop olfactory dysfunction (Ross et al., 2008). Another study clinically followed patients with idiopathic hyposmia to determine the percentage of patients who developed idiopathic PD after a 4-year interval. 7% of the individuals with idiopathic hyposmia had developed clinical PD, and 13% presented with abnormalities of the motor system. (Haehner et al., 2007). In a prospective study involving first-degree relatives of PD patients, a low score on three olfactory processing tasks was associated with an increased risk of developing PD within 5 years (Ponsen et al., 2009). The point of view that reduced odor identification is manifested at the very beginning of the development of PD has been supported. These reports indicate that the rhinencephalon may be an area of selective vulnerability for alpha-synuclein accumulation (Sengoku et al., 2008) and iRBD that develops in middle age or after progresses mostly to Lewy body diseases among synucleinopathies such as PD and DLB, which have some pathological features in common. In Fantini's and Postuma's cohorts (Fantini et al., 2006; Postuma et al., 2006), the olfactory deficit as revealed by the University of Pennsylvania Smell Identification Test found in most iRBD patients shares similarities with that described in PD. We also found that reduced odor identification as revealed by the Odor Stick Identification Test for Japanese were similar in patients with iRBD and PD and distinct from a control group (Miyamoto et al., 2009).

4. Color discrimination

Color vision abnormalities are among the non-motor clinical characteristics of PD (Prise et al., 1992; Büttner et al., 1995), and impairments in color discrimination and contrast sensitivity in PD are progressive over time (Diederich et al., 2002). The severity of the axial

motor symptoms has been shown to be more closely related to visual dysfunction than mental function. Most patients with PD showed more marked impairment along the red-green axis than the blue-yellow axis (Oh et al., 2011), and this pattern contrasts with that typically seen in aging-predominant blue-yellow axis deficiency (Archibald et al., 2009). Color discrimination deficits also have been reported in iRBD, a potential forerunner of PD (Postuma et al., 2008). In their prospective study, they found that two potential preclinical markers of neurodegeneration, olfaction and color vision, indeed identify early-stage synucleinopathy-mediated neurodegenerative diseases (Figure 2). Compared to those remaining diseases free, patients destined to develop disease had poorer baseline olfaction and color vision. In most cases, abnormalities are measurable up to at least 5 years before disease onset, and progress slowly in the preclinical stages (Postuma et al., 2011).

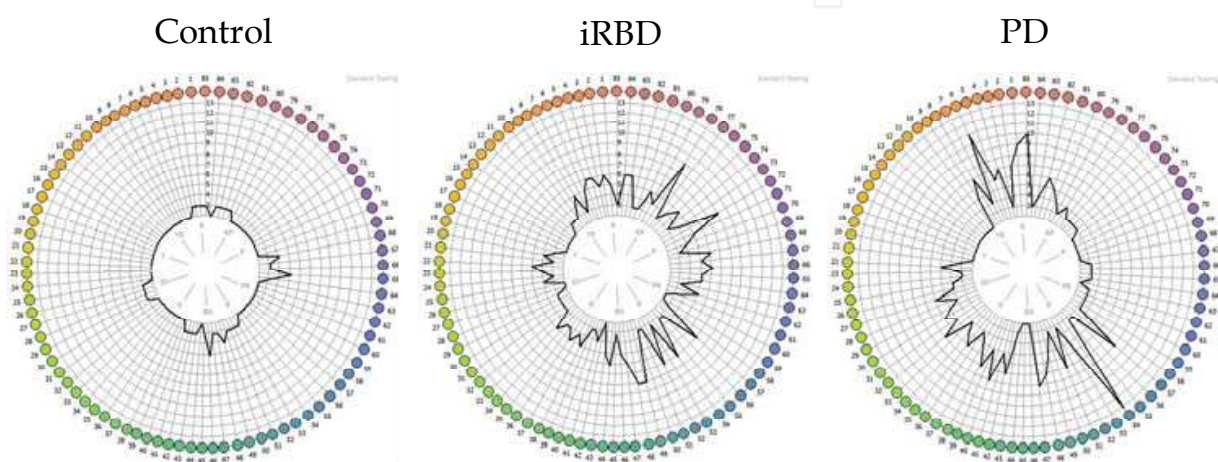


Fig. 2. Farnsworth-Munsell 100 Hue test (FMT).

The total error score for a patient with iRBD or PD was higher than that of a control subject. iRBD, idiopathic REM sleep behavior disorder. PD, Parkinson's disease.

5. Magnetic resonance imaging studies

We detected an increase (compared with reference values from another institution) in the choline/creatine ratio on protein magnetic resonance spectroscopy (1H-MRS) in the pons of a 69-year-old man with iRBD. Since other ratios were normal, the investigators interpreted these findings as demonstrating functional impairment at the cell membrane level (Miyamoto et al., 2000). Iranzo and coworkers performed 1H-MRS in a larger sample of patients with iRBD ($n = 15$) to determine if midbrain or pontine tegmentum abnormalities could be detected compared with matched controls ($n = 15$) (Iranzo et al., 2002). No significant differences in N-acetylaspartate/creatine, choline/creatine, and myoinosito/creatine ratios were found between patients and controls, which they interpreted as suggesting that marked mesopontine neuronal loss or 1H-MRS-detectable metabolic disturbances do not occur in iRBD. Recently, Unger and coworkers described diffusion tensor imaging changes in patients with iRBD (Unger et al., 2010). They found important microstructural abnormalities in the white matter of the brain stem, as well as in the right SN, olfactory region, left temporal lobe, fornix, and the right visual stream of patients with iRBD ($n = 12$), which are known to be involved in REM sleep regulation and/or to indicate neurodegenerative pathology in early PD. In another recent study (Scherfler et al., 2010), Statistical Parametric Mapping localized significant decreases in

fractional anisotropy in the tegmentum of the midbrain and rostral pons and increases in mean diffusivity within the pontine reticular formation overlapping with a cluster of decreased fractional anisotropy in the midbrain. Voxel-based morphometry revealed increases in gray matter densities in both hippocampi of iRBD patients. A concomitant fractional anisotropy decrease and mean diffusivity increase are thought to be correlates of neuronal and myelin damage leading to depletion of barriers restricting water molecular motion. As a result, anisotropy, which is a measure of the degree of alignment of cellular structures within fiber tracts, decreases and the magnitude of diffusion, a measure of extracellular fluid volume, increases. Cortical gray matter volume increases are likely to be related to sprouting of new connections, dendritic spine growth, and modification in the strength of existing connections. Their findings are in line with a [99m]Tc-ethylene cysteinate dimer SPECT study (Mazza et al., 2006) reporting increased cerebral blood flow in the hippocampus of patients with iRBD suggesting hypermetabolism, which would fit the concept of increased gray matter volume in the hippocampus. Further functional imaging studies are warranted to investigate the pathogenesis beyond the structural gray matter density changes and cerebral blood flow increases in the hippocampus in iRBD.

6. Transcranial ultrasound sonography

Enlarged SN hyperechogenicity (SN+) assessed by transcranial ultrasound sonography (TCS) is present in about 90% of PD patients, independent of age and disease stage. SN+ may ultimately be considered an imaging marker for disease progression in PD. It also may be useful as a screening tool to detect individuals at risk for developing PD.

Using age-corrected data, motor signs of PD were shown to begin when the decrease in the percentage of [¹²³I] FP-CIT binding ratios in the putamen was 46-64% (Booij et al., 2001). There was a significant correlation between the extension of the echogenic SN area and striatal β -CIT binding (Weise et al., 2009). They discussed the possibility that extension of SN echogenicity may be a consequence of degeneration of dopaminergic neurons in the SN rather than an independent and mechanistically unrelated phenomenon. ¹⁸Fluoro-DOPA uptake was lowest in patients with PD followed by individuals with SN+ and finally healthy controls without SN+ (Behnke et al., 2009). On the other hand, a lack of correlation between SN echogenicity and striatal FP-CIT uptake was found (Spiegel et al., 2006; Doepp et al., 2008). They hypothesized that the pathogenic substrate of SN+ is different from that associated with degeneration of dopaminergic SN projection neurons. Furthermore, in asymptomatic and symptomatic *parkin* mutation carriers, echogenic SN areas were found to be enlarged (Walter et al., 2004). Brain parenchyma sonography demonstrated SN+ in concordance with abnormal nigrostriatal ¹⁸F-dopa PET in all symptomatic and 3 asymptomatic *Parkin* mutation carriers. Thus, they suggested SN+ as an early marker for detection of preclinical parkinsonism. Moreover, SN+ is a stable marker because the area of echogenicity is not related to the disease stage and was found not to change during the course of disease progression over a 5-year follow-up period (Berg et al., 2005). Thus, SN+ may reflect a pathogenic process that initiates the degeneration of dopaminergic neurons but does not reflect its morphological substrate.

The clinical interest and utility of the findings of our study (Figure 3) are that hyperechogenic alterations in the area of the SN may be suggestive of the existence of preclinical dopaminergic dysfunction and of an underlying neurodegenerative disorder associated with nigrostriatal dysfunction in those with iRBD. Approximately 9% of the healthy population exhibits the same ultrasound signal, which is found in those with

subclinical impairment of the nigrostriatal system as detected by ^{18}F -labeled dopa PET examinations (Berg et al., 1999; Berg et al., 2002; Behnke et al., 2009). SN+ subjects have an approximately twofold probability for the combined occurrence of the risk markers for impaired motor performance and hyposmia versus those with SN− and SN+ is more regularly observed in subjects with higher Unified Parkinson's Disease Rating Scale (UPDRS) motor scores, in particular in subjects with UPDRS scores above 3 (Berg et al., 2010). This observation indicates that the ultrasound feature may serve as a marker for nigrostriatal vulnerability in affected healthy persons or in those in the premotor phase of PD. The frequency of iRBD patients with SN+ was 37.3% (Stockner et al., 2009) or 41.2% (Iwanami et al., 2010). The finding of an increased frequency of SN+ in a subgroup of individuals with an a priori increased risk for PD supports the potential role of SN+ as a risk marker for PD. Our recent study compared FMT-PET findings between patients with iRBD grouped according to the presence or absence of SN+ (Miyamoto et al., in press). 6- ^{18}F -FMT is also a good substrate for aromatic L-amino acid decarboxylase (AADC) but is not metabolized by catechol-O-methyl-transferase. Thus, 6- ^{18}F -FMT uptake has approximately twice the sensitivity of 6- ^{18}F fluoro-L-dopa uptake and more fully represents the extent of AADC activity (Asari et al., 2011). We found that enlarged SN+ in patients with iRBD may be suggestive of nigrostriatal dopaminergic dysfunction as determined by FMT-PET. However, as there was no significant correlation between the area of SN+ and the degree of 6- ^{18}F -FMT uptake, it may be that two parameters have different characteristics from each other. In other words, the area of SN echogenicity is thought to be a stable marker, whereas dopaminergic tracer uptake changes with time. In a recent study (Iranzo et al., 2010), 19% of 43 patients developed a neurodegenerative syndrome such as PD, DLB or MSA 2.5 years after TCS and ^{123}I -FP-CIT SPECT and they noted that combined use of ^{123}I -FP-CIT SPECT and TCS is a potential strategy for early identification of iRBD patients who are at risk for development of a synucleinopathy. They also reported that one case of iRBD who developed MSA had decreased striatal ^{123}I -FP-CIT uptake and normal echogenic SN, and that this discrepancy might be explained by the fact SN+ is less frequent in MSA than in PD and DLB. Even those individuals with iRBD with a normal echogenic SN may be at risk of developing MSA. Therefore we need to follow up iRBD patients with regard to the risk for developing to not only PD or DLB but also MSA.

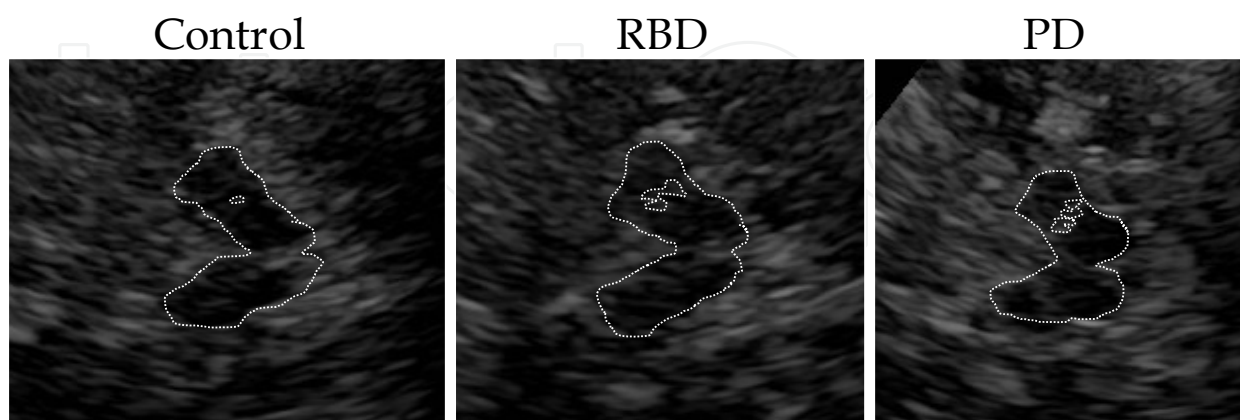


Fig. 3. Typical examples of transcranial ultrasound images of the midbrain encircled by dotted lines in control, iRBD and PD patients. The area of enlarged hyperechogenic substantia nigra signal was encircled on the ipsilateral side for planimetric measurement.

iRBD, idiopathic REM sleep behavior disorder. PD, Parkinson's disease.

7. PET and SPECT

Cognitively normal persons with dream-enactment behavior have a reduced cerebral metabolic rate of glucose (CMRgl) in brain regions known to be metabolically affected by DLB and AD (parietal, temporal, and posterior cingulate cortexes) and in several other regions, including the anterior cingulate cortex. The authors interpreted these findings as supporting further study of dream-enactment behavior as a possible risk factor for the development of DLB (Caselli et al., 2006). In another recent study, four patients were found to have diffuse areas of reduced CMRglc, predominantly in the occipital lobe, which is the preferentially affected region in DLB patients. In contrast, in five patients no such occipital hypometabolism was shown; instead, in those five patients hypometabolism was evident in the left anterior cingulate gyrus (Brodmann area (BA) 24), right frontal lobe (BA 32) and right anterior temporal lobe (BA 38), which are the preferentially affected regions in PD rather than DLB (Fujishiro H et al., 2010). The variability in the [¹⁸F]-FDG PET scans of the present subjects raised the possibility that some iRBD patients with particular patterns may go on to develop PD or DLB. In terms of early intervention, it is important to determine which patterns on the [¹⁸F]-FDG PET scans of iRBD patients are suggestive of underlying prodromal DLB or PD.

A single photon emission computed tomography imaging study showed that PD patients with visual hallucinations had perfusion reductions in the bilateral inferior parietal lobule, inferior temporal gyrus, precuneus gyrus and occipital cortex (Matsui et al., 2006). In a cerebral SPECT study (Shirakawa et al., 2002) that compared iRBD patients with a control group, a statistically significant decrease in blood flow was observed in the upper portion of the frontal lobe on the left and right sides and the pons in the iRBD group. According to another study (Mazza et al., 2006), there was increased perfusion in the pons and putamen bilaterally and in the right hippocampus, and decreased perfusion in frontal and temporoparietal cortices. They concluded that the similarity between the distribution of perfusional impairments found in iRBD and those observed in patients with early PD argues for a common pathophysiologic mechanism for these syndromes in at least the initial stages of these conditions. Our recent study (Hanyu et al., 2010), found decreased regional cerebral blood flow in the parietooccipital lobe (precuneus), limbic lobe, and cerebellar hemispheres in patients with iRBD. Such perfusion abnormalities are also common in patients with confirmed alpha-synucleinopathies (PD, DLB, or MSA).

Thus, based on these findings, as with [¹⁸F]-FDG PET or SPECT findings in iRBD, a close relationship is indicated between PD and DLB, although the phenomenon is not observed constantly with regard to the pathology of iRBD. The results of [¹⁸F]-FDG PET or SPECT studies suggest that iRBD can be a presymptomatic stage of alpha-synucleinopathies.

Striatal binding of DTBZ-PET (Albin et al., 2000) was reduced in iRBD subjects compared with control subjects, suggesting reduced dopaminergic SN neuron numbers. 123I-IPT SPECT (Eisensehr et al., 2000) demonstrated a reduction of striatal dopamine transporter binding in iRBD which is indicative of a presynaptic dopaminergic deficit such as in PD patients. In a recent study (Kim et al., 2010), the dopamine transporter density of the subregions in the majority of RBD patients remained above the lower normal limit, although there was a significant group difference in CIT binding in the putamen between RBD and control subjects. In contrast, CIT binding in each region in most of the PD patients was below the normal range. In our study (Figure 4), a 6-[¹⁸F]-fluoro-meta-tyrosine PET (FMT/PET) template was superimposed onto each individual brain MRI for PD, iRBD, and

control subjects. Regions of interest (ROIs) for the striatum and cerebellum were placed over each brain template. ROIs were manually drawn on the FMT/PET after overlapping with each brain MRI, and the striatal ROI was divided into the putamen and caudate. We proposed that FMT-PET imaging could assess the level of the presynaptic dopaminergic nerve for iRBD, PD, and control subjects. IRBD patients had no signs of parkinsonism and had neuroimaging evidence of an almost intact striatal dopaminergic innervation such as in controls. In contrast, PD patients have parkinsonism by definition and have loss of striatal dopaminergic innervation, as evidenced by decreased striatal uptake. We followed the present case by PET immediately after development of iRBD and at 2.5 years after the first scan (Miyamoto et al., 2010). Nigrostriatal presynaptic dopaminergic function was normal 1 year after the diagnosis of iRBD and decreased by 4 ~ 6% per year, which is similar to that in PD (Nurmi et al., 2003). Nigrostriatal dopaminergic degeneration could be a part of the pathogenesis of RBD, but is not essential for the development of RBD.

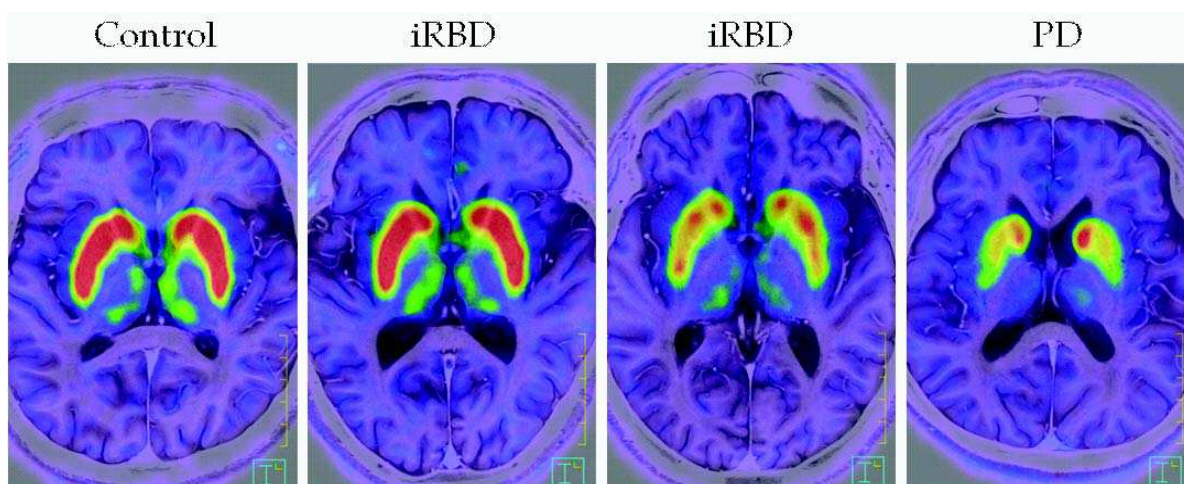


Fig. 4. 6-[18F]-fluoro-meta-tyrosine PET (FMT/PET) template superimposed onto each individual brain MRI for PD, iRBD, or control subjects. IRBD patients have no signs of parkinsonism and have neuroimaging evidence of almost intact striatal dopaminergic innervation such as in controls. Nor do they have reduced uptake such as in PD.

8. Cardiac ^{123}I -MIBG scintigraphy

There is evidence that ^{123}I -MIBG cardiac uptake is markedly reduced in patients with Lewy body diseases such as PD, DLB, and PAF (Courbon et al., 2003; Kashihara et al., 2006; Yoshita et al., 2006). It was reported that cardiac ^{123}I -MIBG imaging could distinguish between clinically diagnosed DLB and AD with high levels of sensitivity and specificity (Yoshita et al., 2006). Interestingly, pathological findings occur even in patients with DLB who have no parkinsonism. Since PAF patients do not have parkinsonism or decreased striatal dopaminergic innervation, and since cardiac noradrenergic denervation occurs in both diseases, the pathogenetic mechanisms of cardiac noradrenergic denervation in Lewy body diseases differ from those producing parkinsonism and nigrostriatal dopaminergic denervation (Goldstein et al., 2009). A reduction in ^{123}I -MIBG uptake in sympathetic terminals was observed in cases with early-phase PD and ILBD irrespective of the presence or absence of remarkable autonomic nerve injury (Courbon et al., 2003). As pathological evidence (Orimo et al., 2007; Orimo et al., 2008; Fujishiro et al., 2008), it has been proven that

the Lewy body is present in cardiac sympathetic nerve postganglionic fibers, and it has been suggested that Lewy body-related pathology potentially causes severe denervation and reduced ^{123}I -MIBG uptake in the cardiac postganglionic sympathetic nerves. The ^{123}I -MIBG studies showed markedly decreased cardiac uptake in PD, DLB and PAF, which is a common feature of Lewy body diseases (Courbon et al., 2003; Kashihara et al., 2006; Yoshita et al., 2006).

We reported markedly reduced cardiac ^{123}I -MIBG uptake in iRBD as well as in PD or DLB (Miyamoto et al., 2006; Miyamoto et al., 2008) (Figure 5). In our recent case report (Miyamoto et al., 2009), we described a small subset of iRBD patients who have relatively preserved uptake at RBD onset, but which then becomes lost over the follow-up period. If RBD precedes MSA, ^{123}I -MIBG uptake is preserved over years; on the other hand, in iRBD patients, progression in the reduction in ^{123}I -MIBG uptake occurs over years.

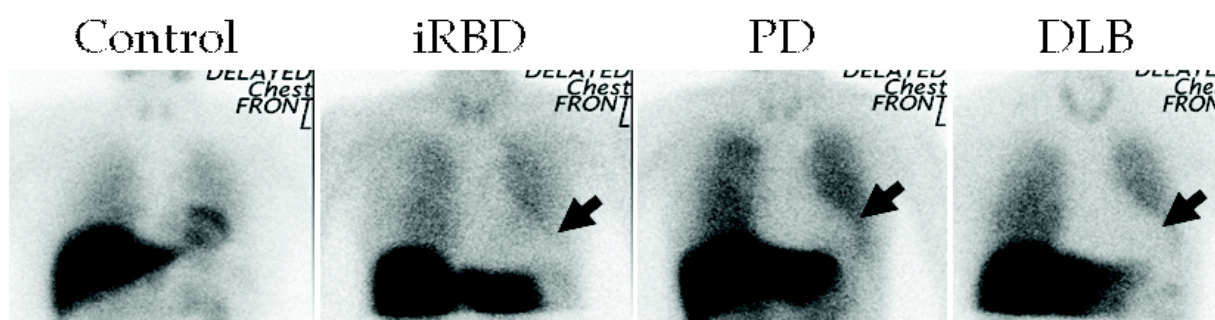


Fig. 5. Idiopathic RBD subject displayed reductions in cardiac ^{123}I -MIBG uptake (arrows) in contrast to a control subject. Uptake was also markedly reduced in a PD or DLB subject (arrows).

9. iRBD and relevance to Lewy body pathology

Men over the age of 50 years who have iRBD are at very high risk for future PD, DLB or MSA several years after the onset of RBD (Schenck et al., 1996; Iranzo et al., 2006; Postuma et al., 2009). Neuropathologic studies at autopsy of cases that had been diagnosed with RBD while alive showed that every case had Lewy bodies (Boeve et al., 2007). For example, cognitive abnormalities appeared 15 years after the onset of RBD and probable DLB was diagnosed, and eventually the presence of Lewy bodies was confirmed pathologically (Turner et al. 2000). Patients with ILBD were shown to have nigrostriatal pathological features that are intermediate between those in pathologically normal persons and those with PD (DelleDonne et al., 2008). Among the study participants with ILBD, decreased striatal dopaminergic immunoreactivity was documented for both tyrosine hydroxylase (TH) and vesicular monoamine transporter 2 (VMAT 2) in comparison with the pathologically normal subjects; the reductions were even greater in those with PD. Also, SN neuronal loss correlated with both striatal VMAT2 and TH. Thus, ILBD probably represents presymptomatic PD rather than nonspecific, age-related alpha-synuclein pathological changes.

In PD, approximately 60% of the nigrostriatal neurons of the SN are degenerated before patients fulfill the clinical criteria of PD (Fearnkey et al., 1991). In some cases of PD, the patient appears to develop cortical disease before the motor signs of “stage 3” disease, whereas iRBD patients with ILBD could be diagnosed after longstanding disease with no evidence of motor or cognitive abnormalities (Uchiyama et al., 1995; Boeve et al., 2007). If

progression of synucleinopathies is not universal, it is essential to understand why. Since a variety of symptoms of PD and disorders resembling PD have been elucidated, Langston (Langston et al., 2006) proposed a “Parkinson’s complex” because parkinsonism would represent only the tip of the iceberg as typically viewed by both clinicians and researchers. However, when the disease process is measured by neuronal degeneration, the presence of Lewy bodies and neuritic pathology are widespread in the central and peripheral nervous systems. From this point of view, iRBD can be positioned as an earlier preclinical stage of PD or DLB or a variant of Lewy body-related alpha-synucleinopathies. To gain such an understanding, it is necessary to extract a group of patients with abnormalities in a combination of markers from among iRBD patients and provide follow-up, considering the possibility that some patients in that group may develop neurodegenerative disease (Figure 6). These steps may help elucidate the possibility that iRBD is part of the spectrum of conditions under the heading of alpha-synucleinopathies, such as PD, DLB, or MSA, or is a subtype of Lewy body-related alpha-synucleinopathy.

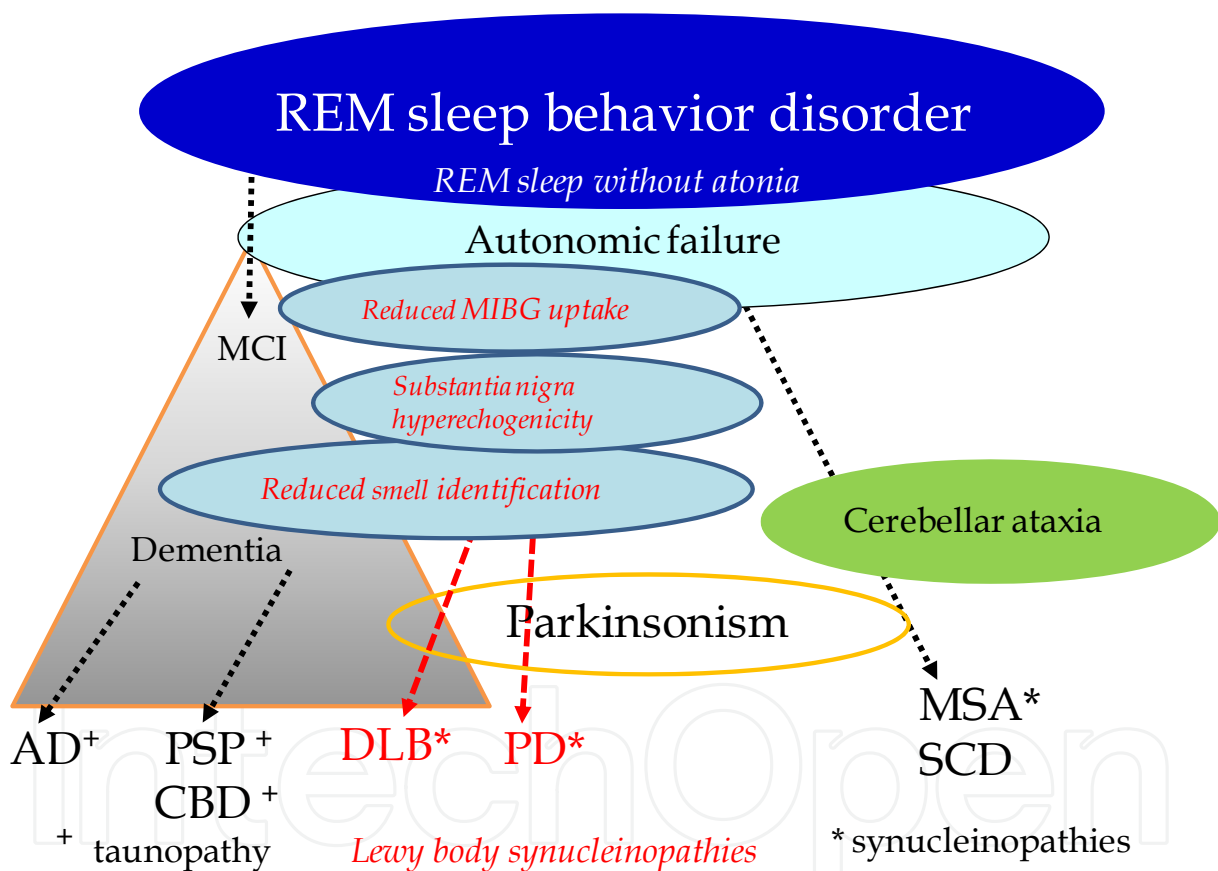


Fig. 6. Combinations of markers for neurodegenerative disease in patients idiopathic REM sleep behavior disorder. A longitudinal study of a large cohort of patients with RBD should identify which marker or combination of markers can predict progression toward a neurodegenerative disorder. The question is, does iRBD progress insidiously to PD, DLB or MSA, or does it remain static?

MCI, mild cognitive impairment, AD, Alzheimer disease, PSP, progressive supranuclear palsy, CBD, corticobasal degeneration, DLB, dementia with Lewy bodies, PD, Parkinson's disease, MSA, multiple system atrophy, SCD, spinocerebellar degeneration, iRBD, idiopathic REM sleep behaviour disorder.

10. Conclusion

Combinations of markers in iRBD were considered for the purpose of diagnosing neurodegenerative diseases such as PD, DLB or MSA at an early stage. Important advances have been made in the diagnosis of PD using imaging methods such as PET/SPECT or cardiac ¹²³I-MIBG scintigraphy. However, while these methods are important in clinical research, they are complex, expensive, not widely available and inappropriate for the routine screening of large populations. Recent advances in the identification of biomarkers in iRBD offer diagnostic opportunities and point the way to new therapeutic strategies.

11. References

- Albin, R.L., Koeppe, R.A., Chervin, R.D., Consens, F.B., Wernette, K., Frey, K.A. & Aldrich, M.S. (2000). Decreased striatal dopaminergic innervation in REM sleep behavior disorder. *Neurology* 55, 1410-1420.
- American Academy of Sleep Medicine. (2005). *International classification of sleep disorders, 2nd ed.: Diagnosis and coding manual*, American Academy of Sleep Medicine, Westchester Illinois, pp. 148-152.
- Archibald, N.K., Clarke, M.P., Mosimann, U.P. & Burn, D.J. (2009). The retina in Parkinson's disease. *Brain* 132, 1128-1145.
- Asari, S., Fujimoto, K., Miyauchi, A., Satou, T., Nakano, I. & Muramastu, S. (2011). Subregional 6-[¹⁸F]fluoro-L-m-tyrosine uptake in the striatum in Parkinson's disease. *BMC Neurology* 11:35.
- Becker, G., Müller, A., Braune, S., Büttner, T., Benecke, R., Greulich, W., Klein, W., Mark, G., Rieke J. & Thümler, R. (2002). Early diagnosis of Parkinson's disease. *J Neurol* 249 Suppl 3:III/40-48.
- Beach, T.G., White, C.L. 3rd, Hladik, C.L., Sabbagh, M.N., Connor, D.J., Shill, H.A., Sue, L.I., Sasse, J., Bachalakuri, J., Henry-Watson, J., Akiyama, H. & Adler, C.H.; Arizona Parkinson's Disease Consortium. (2009). Olfactory bulb alpha-synucleinopathy has high specificity and sensitivity for Lewy body disorders. *Acta Neuropathol* 117, 169-174.
- Boeve, B.F., Dickson, D.W., Olson, E.J., Shepard, J.W., Silber, M.H., Ferman, T.J., Ahlskog, J.E. & Benarroch, E.E. (2007). Insights into REM sleep behavior disorder pathophysiology in brainstem-predominant Lewy body disease. *Sleep Med* 8, 60-64.
- Boeve, B.F., Silber, M.H., Saper, C.B., Ferman, T.J., Dickson, D.W., Parisi, J.E., Benarroch, E.E, Ahlskog, J.E., Smith, G.E., Caselli, R.C., Tippman-Peikert, M., Olsen, E.J., Lin, S.-C., Young, T., Wszolek, Z., Schenck, C.H., Mahowald, M. W., Castillo, P.R., Del Tredici, K.D. & Braak, H. (2007). Pathophysiology of REM sleep behaviour disorder and relevance to neurodegenerative disease. *Brain* 130, 2770-2788.
- Büttner, T., Kuhn, W., Müller, T., Patzold, T., Heidbrink, K., Przuntek, H. (1995). Distorted color discrimination in 'de novo' parkinsonian patients. *Neurology* 45, 386-387.
- Braak, H., Del Tredici, K., Rüb, U., de Vos, R.A.I., Jansen Steur, E.N. & Braak, E. (2003). Staging of pathology related to sporadic Parkinson's disease. *Neurobiol Aging* 24, 197-211.

- Caselli RJ, Chen K, Bandy D, Smilovici O, Boeve BF, Osborne D, Alexander GE, Parish JM, Krahn LE, Reiman EM. A preliminary fluorodeoxyglucose positron emission tomography study in healthy adults reporting dream-enactment behavior. *Sleep*. 2006 Jul 1;29(7):927-33.
- Courbon, F., Brefel-Courbon, C., Thalamas, C., Alibelli, M.J., Berry, I., Montastruc, J.L., Rascol, O. & Senard, J.M. (2003). Cardiac MIBG scintigraphy is a sensitive tool for detecting cardiac sympathetic denervation in Parkinson's disease. *Mov Disord* 18,890-897.
- Diederich, N.J., Raman, R., Leurgans, S., Goetz, C.G. (2002). Progressive worsening of spatial and chromatic processing deficits in Parkinson disease. *Arch Neurol* 59, 1249-1252.
- Diederich NJ, Mayer G, Möller JC, Oertel WH, Knake S. (2010). Diffusion tensor imaging in idiopathic REM sleep behavior disorder reveals microstructural changes in the brainstem, substantia nigra, olfactory region, and other brain regions. *Sleep* 33, 767-773.
- Doty, R.L., Bromley, S.M. & Stern, M.B. (1995). Olfactory testing as an aid in the diagnosis of Parkinson's disease: development of optimal discrimination criteria. *Neurodegeneration* 4,93-97.
- Doty, R.L., Golbe, L.I., McKeown, D.A., Stern, M.S., Lehrach, C.M. & Crawford, D. (1993). Olfactory testing differentiates between progressive supranuclear palsy and idiopathic Parkinson's disease. *Neurology* 43, 962-965.
- Eisensehr, I., Linke, R., Tatsch, K., Kharraz, B., Gildehaus, J.F., Wetter, C.T., Trenkwalder, C., Schwarz, J. & Noachtar, S. (2003). Increased muscle activity during rapid eye movement sleep correlates with decrease of striatal presynaptic dopamine transporters. IPT and IBZM SPECT imaging in subclinical and clinically manifest idiopathic REM sleep behavior disorder, Parkinson's disease, and controls. *Sleep* 26, 507-512.
- Fantini, M.L., Postuma, R.B., Montplaisir, J., et al. (2006). Olfactory deficit in idiopathic rapid eye movements sleep behavior disorder. *Brain Research Bulletin* 70:386-390.
- Fearnley, J.M. & Lees, A.J. (1991). Aging and Parkinson's disease: substantia nigra regional selectivity. *Brain* 114, 2283-2301.
- Fujishiro, H., Frigerio, R., Burnett, M., Klos, K.J., Josephs, K.A., DelleDonne, A., Parisi, J.E., Ahlskog, J.E. & Dickson D.W. (2008). Cardiac sympathetic denervation correlates with clinical and pathologic stages of Parkinson's disease. *Mov Disord* 23, 1085-1092.
- Fujishiro H, Psychogeriatrics 2010 Gagnon, J.F., Postuma, R., Mazza, S., Doyon, J. & Montplaisir, J. (2006). Rapid-eye-movement Sleep behaviour disorder and neurodegeneration diseases. *Lancet Neurol* 5, 424-432.
- Haehner, A., Hummel, T., Hummel, C., Sommer, U., Junghanns, S. & Reichmann, H. (2007). Olfactory loss may be a first sign of idiopathic Parkinson's disease. *Mov Disord* 22, 839-842.
- Hanyu, H, Inoue, Y, Sakurai, H, Kanetaka, H, Nakamura, M, Miyamoto, T, Sasai, T & Iwamoto, T. (2011). Regional cerebral blood flow changes in patients with idiopathic REM sleep behavior disorder. *Eur J Neurol* 18, 784-788.

- Hubbard, P.S., Esiri, M.M., Reading, M., McShane, R. & Nagy, Z. (2007). Alpha-synuclein pathology in the olfactory pathways of dementia patients. *J Anat* 211,117-124.
- Iranzo A, Santamaria J, Pujol J, Moreno A, Deus J, Tolosa E. (2002). Brainstem protonmagnetic resonance spectroscopy in idiopathic REM sleep behavior disorder. *Sleep* 25, 867-870.
- Iranzo, A., Molinuevo, J.L., Santamaría, J., Serradell, M., Martí, M.J., Valldeoriola, F. & Tolosa, E. (2006). Rapid-eye-movement sleep behaviour disorder as an early marker for a neurodegenerative disorder: a descriptive study. *Lancet Neurol* 5, 572-577.
- Iranzo, A., Ratti, P.L., Casanova-Molla, J., Serradell, M., Vilaseca, I. & Santamaria, J. (2009). Excessive muscle activity increases over time in idiopathic REM sleep behavior disorder. *Sleep* 32, 1149-1153.
- Kashihara, K., Ohno, M., Kawada, S. & Okumura, Y. (2006). Reduced cardiac uptake and enhanced washout of 123I-MIBG in pure autonomic failure occurs conjointly with Parkinson's disease and dementia with Lewy bodies. *J Nucl Med* 47, 1099-1101.
- Kim, Y.K., Yoon, I-Y., Kim, J-M., Jeong, S-H., Kim, K.W., Shin, Y-K., Kim, B.S. & Kim, S.E. (2010). The implication nigrostriatal dopaminergic degeneration in the pathogenesis of REM sleep behaviour disorder. *Eur J Neurol* 17, 487-492.
- Langston, J.W. (2006). The Parkinson's complex: parkinsonism is just the tip of the iceberg. *Ann Neurol* 59, 591-596.
- Maetzler, W., Liepelt, I. & Berg, D. (2009). Progression of Parkinson's disease in the clinical phase: potential markers. *Lancet Neurol* 8, 1158-1171.
- Matsui, H., Nishinaka, K., Oda, M., Hara, N., Komatsu, K., Kubori, T. & Udaka, F. (2006). Hypoperfusion of the visual pathway in parkinsonian patients with visual hallucinations. *Mov Disord* 21, 2140-2144.
- McShane, R.H., Nagy, Z., Esiri, M.M., King, E., Joachim, C., Sullivan, N. & Smith, A.D. (2001). Anosmia in dementia is associated with Lewy bodies rather than Alzheimer's pathology. *J Neurol Neurosurg Psychiatry* 70, 739-743.
- Miyamoto, T., Miyamoto, M., Inoue, Y., Usui, Y., Suzuki, K. & Hirata, K. (2006). Reduced cardiac 123I-MIBG scintigraphy in idiopathic REM sleep behavior disorder. *Neurology* 67, 2236-2238.
- Miyamoto, T., Miyamoto, M., Suzuki, K., Nishibayashi, M., Iwanami, M. & Hirata, K. (2008). 123I-MIBG cardiac scintigraphy provides clues to the underlying neurodegenerative disorder in idiopathic REM sleep behavior disorder. *Sleep* 31, 717-723.
- Miyamoto, T., Miyamoto, M., Iwanami, M., Suzuki, K., Inoue, Y. & Hirata, K. (2009). Odor identification as an indicator of idiopathic REM sleep behavior disorder. *Mov Disord* 24:268-273.
- Miyamoto, T., Miyamoto, M., Iwanami, M. & Hirata, K. (2009). Three-year follow-up on the accumulation of cardiac (123) I-MIBG scintigraphy in idiopathic REM sleep behavior disorder. *Sleep Med* 10, 1066-1067.

- Miyamoto, T., Orimo, S., Miyamoto, M., Hirata, K., Adachi, T., Hattori, R., Suzuki, M. & Ishii, K. (2010). Follow-up PET studies in case of idiopathic REM sleep behavior disorder. *Sleep Med* 11, 100-101.
- Miyamoto, M., Miyamoto, T., Kubo, J., Yokota, N., Hirata, K. & Sato, T. (2000). Brainstem function in rapid eye movement sleep behavior disorder: the evaluation of brainstem function by proton MR spectroscopy (1H-MRS). *Psychiatry Clin Neurosci* 54, 350-351.
- Miyamoto, M., Miyamoto, T., Iwanami M., Muramatsu, S., Asari, S., Nakano, I. & Hirata, K. (2011). Preclinical substantia nigra dysfunction in rapid eye movement sleep behavior disorder. *Sleep Med* (in press).
- Nurmi, E., Bergman, J., Eskola, O., Vahlberg, T., Sonninen, P. & Rinne, J.O. (2003). Progression of dopaminergic hypofunction in striatal subregions in Parkinson's disease using [18F]CFT PET. *Synapse* 48, 109-115.
- Oh, Y.S., Kim, J.S., Chung, S.W., Song, I.U., Kim, Y.D., Kim, Y.I. & Lee, K.S. (2011). Color vision in Parkinson's disease and essential tremor. *Eur J Neurol* 18, 577-583.
- Olichney, J.M., Murphy, C., Hofstetter, C.R., Foster, K., Hansen, L.A., Thal, L.J. & Katzman, R. (2005). Anosmia is very common in the Lewy body variant of Alzheimer's disease. *J Neurol Neurosurg Psychiatry* 76, 1342-1347.
- Orimo S., Takahashi A., Uchihara T., Mori F., Kakita A., Wakabayashi K. & Takahashi, H. (2007). Degeneration of cardiac sympathetic nerve begins in the early disease process of Parkinson's disease. *Brain Pathol* 17, 24-30.
- Orimo S., Uchihara T., Nakamura A., Mori F., Kakita A., Wakabayashi K. & Takahashi, H. (2008). Axonal alpha-synuclein aggregates herald centripetal degeneration of cardiac sympathetic nerve in Parkinson's disease. *Brain* 131, 642-650.
- Ponsen, M.M., Stoffers, D., Twisk, J.W., Wolters, ECh. & Berendse, H.W. (2009). Hyposmia and executive dysfunction as predictors of future Parkinson's disease: a prospective study. *Mov Disord* 24,1060-1065.
- Postuma, R.B., Lang, A.E., Massicotte-Marquez, J. & Montplaisir, J. (2006). Potential early markers of Parkinson disease in idiopathic REM sleep behavior disorder. *Neurology* 66, 845-851.
- Postuma, R.B., Gagnon, J.F., Vendette, M., Charland, K. & Montplaisir, J. (2008). Manifestations of Parkinson disease differ in association with REM sleep behavior disorder. *Mov Disord* 15;23, 1665-1672.
- Postuma, R.B., Gagnon, J.F., Vendette, M. & Montplaisir, J.Y. (2009). Markers of neurodegeneration in idiopathic rapid eye movement sleep behaviour disorder and Parkinson's disease. *Brain* 132, 3298-3307.
- Postuma, R.B., Gagnon, J.F., Vendette, M., Fantini, M.L., Massicotte-Marquez, J. & Montplaisir, J. (2009). Quantifying the risk of neurodegenerative disease in idiopathi REM Sleep behavior disorder. *Neurology* 72, 1296-1300.
- Postuma, R.B., Gagnon, J.F., Vendette, M., Desjardins, C. & Montplaisir, J.Y. (2010). Olfaction and color vision identify impending neurodegeneration in rapid eye movement sleep behavior disorder. *Ann Neurol*. 2010 Oct 28. doi: 10.1002/ana.22282.
- Price, M.J., Feldman, R.G., Adelberg, D., Kayne, H. (1992). Abnormalities in color vision and contrast sensitivity in Parkinson's disease. *Neurology* 42, 887-890.


- Ross, G.W., Abbott, R.D., Petrovitch, H., Tanner, C.M., Davis, D.G., Nelson, J., Markesbery, W.R., Hardman, J., Masaki, K., Launer, L. & White, L.R. (2006). Association of olfactory dysfunction with incidental Lewy bodies. *Mov Disord* 21, 2062-2067.
- Ross, G.W., Petrovitch, H., Abbott, R.D., Tanner, C.M., Popper, J., Masaki K., Launer, L. & White, L.R. (2008). Association of olfactory dysfunction with risk for future Parkinson's disease. *Ann Neurol* 63, 167-173.
- Schenck, C.H., Bundlie, S.R., Ettinger, M.G. & Mahowald, M.W. (1986). Chronic behavioral disorders of human REM sleep: a new category of parasomnia. *Sleep* 9, 293-308.
- Schenck, C.H., Bundlie, S.R. & Mahowald, M.W. (1996). Delayed emergence of a parkinsonian disorder in 38% of 29 older men initially diagnosed with idiopathic rapid eye movement sleep behavior disorder. *Neurology* 46, 388-393.
- Schenck, C.H. & Mahowald, M.W. (2002). REM sleep behavior disorder: Clinical, Developmental, and Neuroscience perspectives 16 years after its formal identification in sleep. *Sleep* 25, 120-138.
- Scherfler, C., Frauscher, B., Schocke, M., Iranzo, A., Gschliesser, V., Seppi, K., Santamaria, J., Tolosa, E., Högl, B. & Poewe, W.; SINBAR (Sleep Innsbruck Barcelona) Group. (2011). White and gray matter abnormalities in idiopathic rapid eye movement sleep behavior disorder: a diffusion-tensor imaging and voxel-based morphometry study. *Ann Neurol* 69, 400-407.
- Sengoku, R., Saito, Y., Ikemura, M., Hatsuta, H., Sakiyama, Y., Kanemaru, K., Arai, T., Sawabe, M., Tanaka, N., Mochizuki, H., Inoue, K. & Murayama, S. (2008). Incidence and extent of Lewy body-related alpha-synucleinopathy in aging human olfactory bulb. *Neuropathol Exp Neurol* 67,1072-1083.
- Shirakawa, S., Takeuchi, N., Uchimura, N., Ohyama, T., Maeda, H., Abe, T., Ishibashi, M., Ohshima, Y. & Ohshima, H. (2002). Study of image findings in rapid eye movement sleep behavioural disorder. *Psychiatry Clin Neurosci* 56, 291-292.
- Silveira-Moriyama, L., Mathias, C., Mason, L., Best, C., Quinn, N.P. & Lees, A.J. (2009). Hyposmia in pure autonomic failure. *Neurology* 72, 1677-1681.
- Turner, R.S., D'Amato, C.J., Chervin, R.D. & Blaivas, M. (2000). The pathology of REM sleep behavior disorder with comorbid Lewy body dementia. *Neurology* 55, 1730-1732.
- Uchiyama, M., Isse, K., Tanaka, K., Yokota, N., Hamamoto, M., Aida, S., Ito, Y., Yoshimura, M. & Okawa, M. (1995). Incidental Lewy body disease in a patient with REM sleep behavior disorder. *Neurology* 45, 709-712.
- Unger, M.M., Belke, M., Menzler, K., Heverhagen, J.T., Keil, B., Stiasny-Kolster, K., Rosenow, F., Mazza, S., Soucy, J.P., Gravel, P., Michaud, M., Postuma, R., Massicotte-Marquez, J., Decary, A. & Montplaisir, J. (2006). Assessing whole brain perfusion changes in patients with REM sleep behavior disorder. *Neurology* 67, 1618-622.
- Wenning, G.K., Shephard, B., Hawkes, C., Petrukevitch, A., Lees, A. & Quinn N. (1995). Olfactory function in atypical parkinsonian syndromes. *Acta Neurol Scand* 91, 247-250.
- Williams, S.S., Williams, J., Combrinck, M., Christie, S., Smith, A.D. & McShane, R. (2009). Olfactory impairment is more marked in patients with mild dementia with Lewy

bodies than those with mild Alzheimer disease. *J Neurol Neurosurg Psychiatry* 80, 667-670.

Yoshita, M., Taki, J., Yokoyama, K., Noguchi-Shinohara, M., Matsumoto, Y., Nakajima, K. & Yamada, M. (2006). Value of ¹²³I-MIBG radioactivity in the differential diagnosis of DLB from AD. *Neurology* 66, 1850-1854.

IntechOpen

IntechOpen



Diagnosis and Treatment of Parkinson's Disease

Edited by Prof. Abdul Qayyum Rana

ISBN 978-953-307-465-8

Hard cover, 264 pages

Publisher InTech

Published online 22, September, 2011

Published in print edition September, 2011

Parkinson's disease is diagnosed by history and physical examination and there are no laboratory investigations available to aid the diagnosis of Parkinson's disease. Confirmation of diagnosis of Parkinson's disease thus remains a difficulty. This book brings forth an update of most recent developments made in terms of biomarkers and various imaging techniques with potential use for diagnosing Parkinson's disease. A detailed discussion about the differential diagnosis of Parkinson's disease also follows as Parkinson's disease may be difficult to differentiate from other mimicking conditions at times. As Parkinson's disease affects many systems of human body, a multimodality treatment of this condition is necessary to improve the quality of life of patients. This book provides detailed information on the currently available variety of treatments for Parkinson's disease including pharmacotherapy, physical therapy and surgical treatments of Parkinson's disease. Postoperative care of patients of Parkinson's disease has also been discussed in an organized manner in this text. Clinicians dealing with day to day problems caused by Parkinson's disease as well as other healthcare workers can use beneficial treatment outlines provided in this book.

How to reference

In order to correctly reference this scholarly work, feel free to copy and paste the following:

Tomoyuki Miyamoto and Masayuki Miyamoto (2011). Combinations of Markers Provide Clues to the Underlying Neurodegenerative Disorder in REM Sleep Behavior Disorder, *Diagnosis and Treatment of Parkinson's Disease*, Prof. Abdul Qayyum Rana (Ed.), ISBN: 978-953-307-465-8, InTech, Available from: <http://www.intechopen.com/books/diagnosis-and-treatment-of-parkinson-s-disease/combinations-of-markers-provide-clues-to-the-underlying-neurodegenerative-disorder-in-rem-sleep-beha>

INTECH
open science | open minds

InTech Europe

University Campus STeP Ri
Slavka Krautzeka 83/A
51000 Rijeka, Croatia
Phone: +385 (51) 770 447
Fax: +385 (51) 686 166
www.intechopen.com

InTech China

Unit 405, Office Block, Hotel Equatorial Shanghai
No.65, Yan An Road (West), Shanghai, 200040, China
中国上海市延安西路65号上海国际贵都大饭店办公楼405单元
Phone: +86-21-62489820
Fax: +86-21-62489821

© 2011 The Author(s). Licensee IntechOpen. This chapter is distributed under the terms of the [Creative Commons Attribution-NonCommercial-ShareAlike-3.0 License](#), which permits use, distribution and reproduction for non-commercial purposes, provided the original is properly cited and derivative works building on this content are distributed under the same license.

IntechOpen

IntechOpen