

# We are IntechOpen, the world's leading publisher of Open Access books Built by scientists, for scientists

**4,800**

Open access books available

**122,000**

International authors and editors

**135M**

Downloads

Our authors are among the

**154**

Countries delivered to

**TOP 1%**

most cited scientists

**12.2%**

Contributors from top 500 universities



**WEB OF SCIENCE™**

Selection of our books indexed in the Book Citation Index  
in Web of Science™ Core Collection (BKCI)

Interested in publishing with us?  
Contact [book.department@intechopen.com](mailto:book.department@intechopen.com)

Numbers displayed above are based on latest data collected.

For more information visit [www.intechopen.com](http://www.intechopen.com)



# Trends in Degenerative Aortic Disease: Novel Alternative Therapies for the Treatment of Severe Aortic Stenosis

Javier Gualis, Alejandro Diego, Antonio de Miguel and Mario Castaño  
*Complejo Hospitalario Universitario de León,  
Spain*

## 1. Introduction

Aortic stenosis is the most common valvular disease among the occidental population and it is one of the most important causes of morbidity and mortality in developed countries. It has an incidence of 4% among over 80 years old patients (Charlson E et al., 2006). Its evolution is generally slowly progressive from asymptomatic/mild aortic stenosis to the symptomatic/severe form when survival is dramatically reduced as well as quality of life is importantly impaired. (Iung B et al., 2003)

All along natural history of this disease, patients will consult several times to specialists in order to adjust medical treatment and perform the indicated diagnostic tests. Occasionally in-hospital admittance will be unavoidable and this will necessarily arise into economic resources consumption, that might be assumed by actually over-the-edge and almost bankrupted socio-sanitary policies, at least in the most of developed countries (Varadarajan P, 2006; Pai RG, 2006).

Over more than 40 years, standard treatment for severe symptomatic aortic stenosis has been focused in surgical replacement of the affected valve for a mechanical prosthesis. To achieve this replacement, patient must mandatorily undergo several risky procedures as general anesthesia, median sternotomy, and aortic arch clamping and cardioplegic solution infusion in order to maintain cardiac arrest in diastole during the intervention, with the indispensable cardiopulmonary bypass pumping. (Kvidal P et al., 2000)

Hence, standard surgical therapy has inherent morbi-mortality risks itself that must be carefully evaluated, so this therapy may be not suitable for a subpopulation of candidates because of an excessive high-risk profile. These patients must then admit the natural history of this disease with a terribly poor mid-term prognosis and elevated economic expenses for the system. (Alexander KP et al., 2000)

Socio-sanitary policies need to organize the diagnostic and therapeutic procedures in this cohort of patients in order to obtain the necessary balance that allow an adequate treatment with risk minimization achieving the best possible results with the lowest expenses, optimizing the efficiency in the management of these complex pathology.

In this moment, several therapeutic alternatives are being studied with the aim of the risk reduction in the management of patients with severe aortic stenosis and surgical high-risk profile. These therapies do not pretend to become a substitution of the standard surgical

therapy but a way to reduce the burden of complication and morbidity in the subgroup of patients that cannot be eligible for standard surgery. (Rodés-Cabau et al., 2008)

The present chapter is dedicated to a detailed description of the different therapeutic procedures that are being developed nowadays as an alternative to standard surgical treatment. Special surgical new techniques as low-profile mechanical prosthesis, biological prosthesis (both stented and stentless), homograft and Ross technique (pulmonary autograft in aortic position and homograft in pulmonary position) will not be commented in this chapter.

## **2. Aortic valvuloplasty**

Aortic balloon valvuloplasty is a classical procedure firstly performed in the late fifties and still in use for children affected of congenital aortic stenosis with acceptable results. Its use in degenerative or rheumatic aortic stenosis has been abandoned in the last decades due to its prohibitive mid-term restenosis rates. With good results limited to the first days after procedure, generally approved indications for severe aortic stenosis has been displaced towards a bridging therapy between a critical clinical situation and a surgical replacement that is delayed for any cause. Other previous indications, as palliative therapy among patients that reject surgery, previous to non-cardiac surgery or low gradient aortic stenosis with severely reduced left ventricle ejection fraction are losing their sense with the introduction of transcatheter aortic valve implantation, but all the way this novel therapy requires aortic valve balloon dilatation previously to device implantation, balloon valvuloplasty is not only out of danger of disappear but be clearly reinforced, redirected towards its implication in the TAVI procedure process. (Vahanian A et al., 2004).

## **3. Transcatheter aortic valve implantation: TAVI**

Andersen performed first experimental studies of transcatheter aortic valve implantation in the early nineties (Andersen et al., 1992). Afterwards, in year 2000, Bonhoeffer did the first in-human implantation of a percutaneous prosthesis in pulmonary position (Bonhoeffer P et al., 2000) , but it was not until 2002 when Dr. Alain Cribier performed successfully the first implantation in a patient affected of severe symptomatic aortic stenosis rejected for surgery, obtaining an excellent initial clinical result that led to a fast spreading of the technique and implementation of the devices (Cribier A ., 2002). From this moment on, the development of valvular programs to perform catheter-based aortic stenosis treatment have been increasing exponentially worldwide.

In a summarized way, the procedure consists of the implantation of a biological prosthesis anchored in a metallic stent over the diseased and stenotic native valve using a percutaneous arterial and/or venous access or a transapical access after performing a minithoracotomy. All of these ways to access the aortic valve have the intention to avoid the median sternotomy and the cardiopulmonary bypass with its implicit risks.

First procedures were performed via catheterization of the femoral vein and accessing the right heart and then the aortic valve in an antegrade way through a transeptal puncture. Although this kind of procedure is still performed in selected patients, now the most frequently used technique is the retrograde method through arterial access described by Webb in 2005, using preferably femoral site of puncture, though subclavian or even ascending aorta itself can be performed to reach the aortic valve (Webb JG et al., 2006). The

transapical technique, described by Lichtenstein in 2006, would require surgical access with a minithoractomy and at this moment it is the second preferred method (Lichtenstein SV et al., 2006).

TAVI is a complex technique essentially reserved for very high perisurgical risk patients. It is important to emphasize that, due to its complexity, the learning curve of the technique must be performed following a strict program that minimize the risk of complications. Several groups have compared initial results with those obtained after the first learning curve period. Webb et al reported their experience after the first 168 Edwards Sapien transcatheter aortic valve implantation, both transfemoral (n=113) and transapical (n=55) showing a decrease in 30-days mortality from 14,3% in the first 84 patients to 8,3% in the second half of the sample. Of course, not only the experience acquirement but the technical advances in the device design have contributed to this results improvement (Webb JG et al., 2007). In the same line, Grube et al demonstrated a 73% reduction in 30-days mortality (from 40% to 10,8%) in 102 patients who underwent 18F CoreValve system valve implantation in comparison with an older sample treated with the first generation 25F device (Grube E et al., 2005). This data suggest that, while improvements in the design of the device and the selection of patients keep on growing exponentially, a reduction in the learning curve requirements should be expected for the next generation of devices and future centre incorporations to this alternative technique.

Despite this technical improvements, they will never replace the importance of the learning curve. Himbert et al reported that, in relation with the initial experience of a specific centre, precisely the learning curve is the most important factor related to in-hospital mortality and mid-term survival after this kind of procedures. (Himbert D et al., 2009).

The most important issue for the generalization of these techniques is the indispensable device development carried out by the medical industry. The experimental tests performed by the different research and development programs have the goal of optimizing results by minimizing complications in the access site, increasing durability, improving flexibility and navigability of devices, developing non-traumatic guide-wires and catheters and low-profile stents that allow the active fixation of the valve and its homogeneous expansion in order to avoid paravalvular leaks and, at the end, improve general clinical results in terms of morbidity and mortality.

There are several devices commercialized, the most used are the Medtronic CoreValve® Transcatheter Aortic Valve Implantation System (Medtronic Inc, Minneapolis, USA) and the Edwards Sapien® Transcatheter Heart Valve system (Edwards Lifesciences Inc., Irvine, USA).

CoreValve first implantation was reported for Grube et al in 2005 and obtained the CE mark in 2007. More than 10.000 devices have been already successfully implanted in more than 34 countries, and recently a clinical trial has been approved by the Food and Drugs Administration to evaluate its results in the USA. At this time, this device is designed for a transarterial retrograde approach implantation. This device is made up of a porcine pericardium valve fixed to an auto-expandable nitinol stent designed to anchor both the outflow tract of the left ventricle and the ascending aorta. It is commercialized in two sizes: 26mm (indicated for aortic annulus between 20 and 23mm) and 29mm (for annulus between 23 and 27mm). It is delivered through a 18F sheath so it is intended to be used in patients with femoral artery diameters over 6mm.



The Core Valve

The new Edwards Lifescience device, the Sapien-XT valve, can be delivered by an arterial or venous access site (anterograde or retrograde technique) as well as by a transapical approach; it has the CE mark since 2007 and has the FDA investigational device exemption for the PARTNER US trial. Like the CoreValve system, more than 10,000 devices have been implanted all around the world with promising initial results. It is constructed with a bovine pericardium valve sewed to a balloon expandable chromium-cobalt stent to be anchored to the calcified native aortic annulus. Three sizes are commercialized: 23mm (for aortic annulus between 18 and 21mm), 26mm (for aortic annulus between 21 and 25mm) and the recently added 29mm size for annulus over 25mm. The femoral sheath is 18F for the smaller size and 19F for the 26, and the transapical sheath is 22F for the smaller, 24F for the 26mm size and 26F for the 29mm. No femoral system has been designed yet for the 29mm valve.



The Edwards Sapien XT valve

### 3.1 Indications

Initially, these devices were only approved as compassionate therapy for non operable patients with severe symptoms (NYHA class IV dyspnea or angina), but after the initial results achieved, the indications of these proceedings are extending to any patient with symptomatic severe aortic stenosis and specific contraindication for cardiac surgery or very high perioperative risk profile. It is reasonable to think that, as the technique is consolidating, the screening of patients for TAVI should follow the general

recommendations for the management of patients with degenerative aortic stenosis reported by the scientific societies. (Vahanian A et al., 2007,2008)

### **3.1.1 General indications of aortic valve replacement for aortic stenosis following the European Society of Cardiology clinical guidelines**

1. Patients with severe aortic stenosis and presence of any symptoms (Recommendation class IB).
2. Asymptomatic patients with severe aortic stenosis and systolic dysfunction (LVEF <50%) not attributable to other cause (IC).
3. Asymptomatic patients with severe aortic stenosis and exercise test that shows lowering of arterial systolic pressure under basal levels (IIaC).
4. Asymptomatic patients with severe aortic stenosis and severe calcification of the valve and a progression of the aortic peak velocity >0,3m/s per year (IIaC).
5. Patients with low gradient severe aortic stenosis (<40mmHg) with systolic dysfunction (LVEF<40%) and contractile reserve (IIaC).
6. Asymptomatic patients with severe aortic stenosis and exercise test that shows complex ventricular arrhythmias (IIbC).
7. Asymptomatic patients with severe aortic stenosis and left ventricle hypertrophy (>15mm) in case of no arterial hypertension (IIbC).
8. Patients with low gradient (<40mmHg) severe aortic stenosis and systolic dysfunction with no contractile reserve (IIbC).

\*Severe aortic stenosis is defined as a valvular area <1cm<sup>2</sup> (<0,6cm<sup>2</sup>/m<sup>2</sup> of body surface area) or a mean gradient >50mmHg with normal flow situation. Special evaluation is required in case of low flow situations.

### **3.1.2 Contraindication for conventional aortic valve replacement**

1. High co-morbidity: elderly patients, left ventricle dysfunction, pulmonary hypertension, chronic obstructive pulmonary disease, renal failure, cerebrovascular disease, peripheral artery disease or any other circumstances evaluated following EuroSCORE (European System for Cardiac Operative Risk Evaluation) or STS (Society of Thoracic Surgeons) scales that leads to very high-risk profiles.
2. Excessive technical complexity: multiple re-interventions or porcelain aorta.

### **3.1.3 Absence of specific contraindications for transcatheter aortic valve implantation**

In case of aortic valve replacement indication with contraindication for standard surgery or very high-risk patient, TAVI should be considered. If TAVI is indicated, because of slightly better mid-term clinical results (CITA), transarterial retrograde technique would be the preferred technique over the transapical approach, but always after taking into account the experience and/or preferences of the center.

- *General contraindications:*

1. Aortic annulus smaller than 18mm or bigger than 27mm.
2. Bicuspid or unicuspid aortic valve.
3. Asymmetric severe valve calcification (*bulky* calcification) that might lead to high risk of coronary ostia occlusion during implantation.
4. Severe symptomatic coronary artery disease not suitable for percutaneous revascularization.

5. Active infective endocarditis.
6. Hypertrophic Obstructive Myocardopathy.
  - *Contraindications for transfemoral access:*
    1. Excessive tortuosity of the ilio-femoral axis.
    2. Previous aorto-bifemoral by-pass surgery.
    3. Small iliac or femoral artery diameter (<6-8mm depending on the device).
    4. Severe angulation of proximal ascending aorta or the valvular plane.
    5. Severe atheromatosis of ascending aorta or aortic arch, aortic coarctation, aneurism or dissection of descending thoracic aorta or abdominal aorta, specially if wall thrombus is present.
      - \*In case of TAVI indication and contraindication of femoral access, subclavian access might be considered.
      - \*\*In case of femoral/subclavian access contraindication, transapical access might be considered.
  - *Contraindications for transapical access:*
    1. Previous cardiac surgery on left ventricle apex.
    2. Paricardium calcifications.
    3. Chronic respiratory insufficiency that contraindicates minithoracotomy.
    4. Apical thrombus in left ventricle.

### 3.2 TAVI program development

Before starting a new transcatheter program is essential to proceed with the organization of a local heart team that must be formed by two cardiothoracic surgeons, two interventional cardiologists, an echocardiographer, an anesthesiologist, two dedicated nurses, and a perfusionist. Problem-solving skills and learning ability are essential, as it is the collaboration among the different departments and units involved in order to front the complications that will arise during the learning curve.

Because of the elevated costs of the device, the difficulty of the technique and the high-risk profile of the candidates, specific learning courses realization is mandatory, as well as continuing training all along the team assistance trajectory. Industry demands, for both CoreValve and Sapien devices, a 15 procedures period in which the presence of a proctor that leads and trains the heart team is recommended before the achieving of the accreditation as an independent unit.

Patient screening must be performed with exquisite care as the success or failure of the starting program could depend on the results of the initial cases. We must never forget that elective therapy for severe aortic stenosis is still surgical replacement, and only when surgery is contraindicated or very risky TAVI can be considered. TAVI indication must be established after consensus between the heart team dedicated to this technique and the clinical cardiologist responsible of the candidate and not only clinical but economic criteria must be taken into account as the elevated expenses that this procedures involve requires the proper selection that may lead to optimal clinical long term results, both in terms of survival expectancy and quality of live.

Bullesfeld et al reported that pre-procedure patient functional class, assessed by Karnofsky index, was the only in-hospital survival predictor after CoreValve implantation. This fact comes to point again the main importance that an exhaustive screening process has in terms of late clinical results, and so in terms of efficiency (Bullesfeld L et al., 2009).

### 3.3 Additional diagnostic tests

Usual imaging complementary tests performed before TAVI are transthoracic echocardiography, transesophageal echocardiography, cardiac catheterization and coronary angiography and CT-scan and/or C-MRI. In addition to confirmation of aortic stenosis severity, detailed basic information is required regarding (Delgado V et al., 2010):

- Valve morphology (tricuspid or bicuspid, extend of calcification).
- Annulus diameter.
- Left ventricular outflow tract (LVOT) morphology.
- Morphology of the aortic root (sinuses and their relation to extensive valve calcification)
- Distance between coronary arteries and annulus (relation to sinus morphology and extensive valve calcification).
- Size, pathology (complex plaques, aneurysm) and course (kinking) of the entire aorta.
- Size, pathology (calcification) and course (tortuosity) of iliac and femoral arteries.

The consolidation of transcatheter aortic valve implantation procedures in the common practice will be related to the results obtained. Imaging techniques improvements and its application during the procedure can help to obtain better results. 3D-Transesophageal echocardiography will contribute with valuable information about device positioning, valve function and relation between the prosthesis and the coronary ostia and the aortic root. It is especially valuable in the assessment of leaflets calcifications that might cause early in-procedure complications during the valve deployment and will help the operator to find the proper positioning at the same time that allows identifying perivalvular leaks and guiding corrective manoeuvres in order to gain final prosthetic normal function and optimal performance. (Ng AC et al., 2010)

DynaCT is being introduced in the most advanced hybrid catheterization laboratories, adding a new tool that offers incomparable information about aortic root configuration and relations among the different structures involved in TAVI procedures, but at this moment, it is only available in a very few centres and, however in the next future it may become the usual guiding diagnostic tool, it cannot be considered as a standard requirement at this moment. (Kempfert J et al., 2009)

### 3.4 Operating room

The ideal place to perform these complex techniques is called hybrid operating room or hybrid catheterization laboratory, were both, optimal x-ray imaging facilities and surgical treatment of the room adequate for cardiopulmonary by-pass, join together in order to minimize the risk of complications and adopt the necessary therapeutic measures in case of their presentation. The elevated cost of these hybrid rooms and the considerably big space that require make them to be out of reach for many centers, so several portable x-ray devices are being approved for its use into standard operating rooms.

### 3.5 Complications

Most often complication that may present in the early post-procedure period are: valve malposition, peri-prosthesis leak, acute aortic regurgitation and acute lung oedema, device embolization, low cardiac output heart failure with hemodynamic support requirements, conventional surgery conversion with in-pump connection, vascular access complications



including vessel rupture, dissection and/or acute occlusion, stroke, myocardial infarction, coronary ostia occlusion, atrioventricular block and renal failure.

*Valve malposition and valve embolization:*

Valve malposition and valve embolization are classical complications very related to the different teams learning curve and the technical improvements in the deployment devices. They have been drastically reduced from initial series (approximately 6%) to the incidence reported in the pate trials (approximately 2%). (Walther T et al., 2007)

*Peri-prosthesis leak:*

Peri-prosthesis leak is due to absence of complete apposition of the device to the aortic annulus caused by lack of homogeneous expansion and it is one of the most common complications and the most important factor related to post-procedural aortic regurgitation. This valve regurgitation, when it is severe, can generate acute hemodynamic instability and acute lung oedema (that also may appear after pre-implantation balloon valvuloplasty) and it is one of the most important issues to improve in order to achieve a real advance in this technique (Cribier A et al., 2006).

*Vascular access complications:*

Vascular access major complications are still over 10% in the majority of the series reported despite the results improvements. Experience with the CoreValve system indicates that transporter catheter diameter reduction has great impact in the reduction of these complications (from over 20% to 5% in the last registries). In addition to this, 22F catheter maintenance for Edwards Sapiens system lead to a stabilization in the incidence of vascular complication despite the operators experience gaining. Anyway, it seems that, at least in the SOURCE registry, vascular complications do not determine higher 30-days mortality incidence. This suggests that the presence of highly prepared teams with experience in the treatment of these vascular complications may limit their impact in peri-procedural mortality.

It is important to advice that not only transfemoral technique is related to access complications as transapical access has also been associated with serious access complications as ventricular tear or severe bleeding during apex reparation. (Dumont E et al., 2009, Rodés-Cabau J et al., 2010)

*Stroke:*

Stroke, because of its terrible consequences for the patient, it has been another major concern of this technique. Stroke incidence has been kept below 5% in the majority of series; that is quite inferior to the expected incidence in an octogenarian population who undergo standard cardiac surgery with aortic clamping. This supports the idea that conventional aortic replacement surgery with cardiopulmonary by-pass and aortic clamping has a higher risk of stroke than these newer techniques despite the necessity of big sized aggressive devices that must navigate the aortic arch during implantation. It is important to remark here that transapical access avoids the manipulation of these catheters in the aorta and last trials have reported a tendency towards a stroke incidence reduction, so many centres have given priority to this access when severe aortic atheromatosis or porcelain aorta are present (Grube E et al., 2008; Rodés-Cabau J et al., 2010).

*Myocardial infarction:*

Assessing the incidence of myocardial infarction as a complication of TAVI is a very difficult objective as myocardial infarction definitions are quite variable among different trials and registries. Incidence vary from 0,2 to 17,5% depending on the definition given. In terms of severity and device-related myocardial infarction, the most important pathophysiological

condition that must be watched is the occlusion of a coronary ostium secondary to calcified native valve leaflets displacement, much more frequent than ostium jailing phenomenon caused by the stent struts. Several groups have remark the importance of adequate assessment of the distance between the aortic annulus and coronary ostia to avoid this dramatic complication, especially in cases with severe calcified native valve. Predicting periprocedural myocardial infarction secondary to previous coronary disease would be much more difficult. Actually approved devices producers recommend the prophylaxis of this complication by coronary angiography and eventually percutaneous coronary intervention that should be performed at least 48 hours before TAVI. (Kapadia Sr et al., 2009; Bagur R., 2010; Wood D et al., 2009)

*Atrioventricular block:*

Atrioventricular block and need for pacemaker implantation has shown to be related to a low positioning of the valve that leads to His bundle conduction system injury. Incidence of permanent pacemaker implantation requirements after transcatheter valve implantation may vary among registries, but it looks clear that is much more frequent after CoreValve implantation in comparison with the Sapien system (10-33% vs <7%. (Piazza N et al., 2008; Grube E et al., 2008). This difference is explained by the design characteristics of the CoreValve: the bigger length of the prosthesis favours under-aortic annulus anchorage and the nitinol autoexpandable alloy determines an additive progressive expansion of the stent after the deployment, with the subsequent risk of electric conduction system injury.

With such a high-risk of AV block, emphasis in the search for predictors that can anticipate the need for permanent pacemaker has been done. Jilalihawi et al recently reported the presence of previous left-bundle atrioventricular block, a ventricular septum bigger than 17mm or a non-coronary leaflet bigger than 8mm as a predictor for pacemaker requirement with a 75% sensibility and 100% specificity. (Jilalihawi H et al., 2009) Nevertheless, more studies with bigger sample sizes are needed before making definitive recommendations about prophylactic measures focused on avoiding this important, although rarely lethal, complication.

Advances in the knowledge of the aetiology and pathophysiologic generation of the atrioventricular block with different transcatheter valves will help to optimize final results. Alternative septum membranous anchorage systems that facilitate implantation on the native annulus and reduction of the terminal outflow tract cross-section size should be the key for improving results.

*Renal failure and haemodialysis requirements:*

Aregger et al evaluated the incidence of renal failure in a 54 patients cohort of CoreValve or Sapien implantation (Aregger F et al., 2009). The majority of the patients achieved an improvement in the creatinine serum levels after the procedure, but renal failure reached a 28% and 7,4% required haemodialysis during hospitalization. Bagur et al have recently reported a renal failure incidence of 11,7% after the Edwards Sapien device implantation, with a 4-fold in-hospital mortality increase (Bagur R et al., 2010). Curiously, in the same paper, incidence of acute renal failure among patients with previous chronic renal failure was lower in the group of TAVI than in the group of standard surgical valve replacement (9,2 vs 25,9%; haemodialysis requirements: 2,5 vs 8,7%).

### **3.6 Evidence**

Degenerative aortic stenosis is a pathological process with stable prognosis and well known history for years, it can be considered as a "classical" heart disease and it has experimented

very few advances during the past decades. Surgical valve replacement has shown itself as an excellent therapy and no alternative has arisen until the development of transcatheter valve implantation, and it has started its journey as a marginal palliative alternative for non-operable patients, so virtually no field for multicentre randomized double-blinded clinical trial that provide statistically reliable information that can guide evidence-based recommendations. Hence, the beginnings of transcatheter aortic valve implantation could be described at least as “complicated” and many difficulties have been overcome before achieving the minimal necessary strength before reaching the clinical trials era that now we are observing.

After initial heroic implantations performed by Cribier, Grub, Bonhoeffer or Webb, first experience was evaluated in several observational multicentre studies like SOURCE, REVIVE, REVIVE II and REVIVAL (Kodali SK et al., 2011). These studies reported valuable information about feasibility and safety of the technique with promising clinical results, but clinical randomized trials are needed before extracting definite conclusions about the true clinical benefits of transcatheter aortic valve implantation.

The SOURCE trial was a post-commercialization study in which the participation of 34 European centres that included a total of 463 patients with severe symptomatic aortic stenosis who underwent transfemoral aortic valve implantation because of severe comorbidities that made standard surgical therapy contraindicated or too risky. Immediate success of the procedure was achieved in 95,6% and 30-days after procedure survival was 93,7% in the whole cohort and 88,6% among patients who suffered vascular access complications. Other common complications reported were: pacemaker implantation (6,7%), aortic regurgitation > grade 2 (3,2%), device malposition (1,7%) and coronary occlusion (0,7%). There was no device embolization event. (Wendler O et al., 2010; Thomas M et al., 2010)

After the initial results achieved during the first era and the spreading of the technique, major adverse cardiovascular events, in-hospital admittances, post-procedural functional class, complications, costs and quality of life are issues that must be contrasted not only against medical conservative therapy but also against conventional surgical treatment in this subset of high risk patients (but still considered operable). If clinical results still remain positive, long term follow-up and durability might be considered in order to extend clinical indication to lower risk profile patients.

After these first promising results it seems to be reasonable to affirm that TAVI is a feasible alternative to standard surgery for very high-risk patients, that allows offering them better expectation of survival and quality of life than a conservative pharmacological strategy.

In general, multicenter registries have included more than 2000 patients with an overall success over 90% and a 30-days mortality <10%, a definite step in order to confirm the feasibility, safety and efficacy of this technique as an alternative to surgical standard replacement in the subgroup of high-risk or prohibitive risk patients. At this point, direct comparison with surgical replacement does not look like a non-reachable objective, at least for the subgroup of patients in the frontier of the cardiopulmonary by-pass surgery indication (risk high enough to consider alternatives but not so much to be firmly rejected). This issue is the aim of the next generation of clinical trials involving TAVI.

In this way, the PARTNER trial pretends to give the response to these questions that initial practice arose. During the first part of this trial, patients with a diagnosis of severe

symptomatic aortic stenosis and rejected for surgery were randomly assigned into two groups: standard pharmacological conservative therapy or transcatheter aortic valve implantation. The results of this first step were reported in October 2010 and they showed a one-year mortality of 30,7% in the TAVI group vs 50,7% in the conservative therapy arm. Differences in hospital admission needs were as well statistically significant (42,5% in the TAVI group vs 71,6% in the conservative group) and a benefit in terms of functional class was observed too (NYHA class III/IV of 25,2% in TAVI group vs 58% in the pharmacological group), however, the incidence of stroke showed to be higher in the TAVI group (5% vs 1,1%) so they did vascular complications. (León MB et al., 2010)

Second part of PARTNER trial is actually on course and will try to compare the results of severe symptomatic aortic stenosis patients with very-high risk surgical profile randomly assigned into a group of standard surgical valve replacement or TAVI. Clinical events are being collected and publications of the results are expected for this year. They probably will guide the final clinical recommendations in the management of this complicated subgroup of patients.

Many individual and multicentre trials are on course at this moment trying to evaluate the efficiency of TAVI. As it is a novel technique in continuous evolution, European societies have recently published the guidelines to define the main endpoints that must be recorded in order to perform a conceptual standardization, that may serve as a reference for future comparisons among different studies and avoid possible biases.

A medicine based clinical practice and the rational application of these novel techniques (doing the essential exhaustive screening in order to select the best candidates to gain clinical benefit) will balance the performing of these promising procedures with more or less demonstrated results and the enormous commercial pressure that these devices development and researching suffer. We cannot forget the international economic situation that we are witnessing at this moment and we must show ourselves with clinical common sense enough to ensure maximum efficiency. If this is not guaranteed, exaggerated expenses and bad clinical results might lead to fail in the introduction of promising innovations before they are really tested.

As transcatheter aortic valve implantation techniques are spreading, newer indications for their use are extending with excellent initial results. That is the case of biological aortic prosthesis degeneration after conventional cardiac surgery. The anchoring of the transcatheter valve over the degenerated prosthesis seems to be quite safe and facilitate the treatment of patients that cannot undergo a surgical reintervention. We must wait until large series results to be reported before extract conclusions, but this is an obvious new field for the application of TAVI that can give response to an emerging problem as the population of developed countries keeps on aging.

### **3.7 Mid and long term follow-up results**

There are relatively few data about mid and long-term follow-up results after transcatheter aortic valve implantation. The one-year survival after transfemoral implantation has reached 80% or over in the most recent registries like SOURCE. It is interesting to remark the late publication in this sense of Webb et al where the majority of deaths that appear after 30 days are demonstrated to be non-cardiac related. This fact underlines again the main importance of making a proper patient selection in order to achieve good long-term results. Canadian multicentre experience (Rodés-Cadau J et al., 2010), that included transfemoral

and transapical access, demonstrated that the presence of extra-cardiac comorbidities as renal failure or chronic obstructive pulmonary disease were two of the most importantly late mortality related factors. Finally, with the available data until date, no structural damage has been found yet in the mid-term follow up.

Recent long-term results of a single centre have been reported with the transfemoral CoreValve system in 450 patients. Pre-procedure logistic EuroSCORE was over 20% in >90% of the cohort. Early in-hospital mortality has been decreasing during last two years until stabilization in 6%. Other in-hospital complications have decreased as well with the exemption of pacemaker requirements that stabilizes in 39%. Stroke appeared in 1,6% of the patients. One-year survival was 60% with the 25F device, 79% with the 21F and 84% with the 18F, remarking the critical importance that the design improvement holds.

Transapical procedures have been related to one-year survival rates <80%, even in recent registries as SOURCE, probably due to higher risk basal characteristics of patients selected for this approach. Lichtenstein et al reported their initial experience in seven severe aortic stenosis patients that presented bad vascular access and severe comorbidities (Lichtenstein et al., 2006). Valve was implanted through a minimal thoracic incision and apex puncture without cardiopulmonary by-pass. There was no early mortality or valve dysfunction in this report. One year later, Walther et al reported their initial experience in a 30 patients cohort. Valve implantation was successfully implanted in 29 and one patient required cardiac surgery conversion with median sternotomy. After these reports, the possibility for an alternative access route when lack of vascular access is present was demonstrated. The same late author reported the experience of 4 centres that treated 59 patients with a mean EuroSCORE of  $24 \pm 14\%$  intended for Edwards-Sapien transcatheter heart valve implantation. Procedure was performed successfully in 53 patients when 4 patients required sternotomy and standard surgery conversion. Early in-hospital mortality was 13,6% and no prosthesis dysfunction was observed. (Walther T et al 2007)

Out of Europe, four American centres also reported their initial experience with the first 40 Edwards-Sapien implantation tries. The valve was successfully implanted in 35 patients. 30-days mortality was 17,5% and in a 143 days follow-up 6 more patients died, so Kaplan-Meier curves showed survival rates of  $81,8 \pm 6,2\%$  at one month, and  $71,7 \pm 7,7\%$  at 3 months.

The PARTNER EU registry included 69 severe aortic stenosis patients with serious comorbidities, high-risk surgical profile (mean logistic EuroSCORE  $33,8 \pm 14,7\%$ ) and poor vascular access. Technical device implantation success was achieved in 91%. 30-days mortality was 18,8%; stroke 2,9%, conversion to standard surgery 2,9% and permanent pacemaker 4,4%. On-year survival was 50% and an important improvement in functional class was recognized for the majority of patients.

The largest cohort of transapical Edwards-Sapien implantation is the one in the SOURCE registry, with 575 patients. Mean logistic EuroSCORE was 29,2% and primary procedure success was reached in 92,8%. Conversion to standard surgery was reported in 3,5%, severe aortic regurgitation in 5,9% and valve malaposition in 1,4%. 30-days mortality was 10,3%, stroke 2,9% and permanent pacemaker implantation 7,3%.

Medical industry has found in TAVI an open door for alternative treatment demands, so many companies are promoting research and developing of newer devices at this moment. Sadra Lotus, Direct Flow, Sorin Perceval, 3F Endurance Valve, LPI Repositionable, Lutter Valve, Heart Leaflet Technologies, Aortech and Artx valves may serve as an example.

Summarizing, we are now witnessing the beginning of a new era in the development of therapies for patients affected of aortic stenosis. The rigorous selection of patients and the

rigorous obtaining of clinical data from trials and registries will determine the permanence and rising of this highly promising short of therapies.

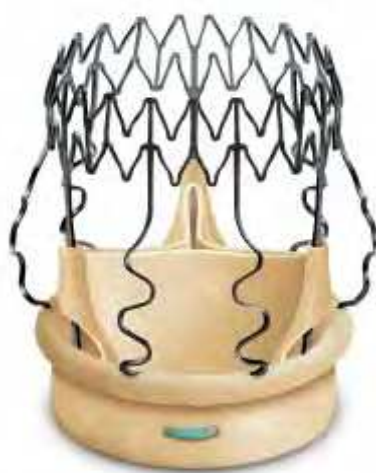#### 4. Sutureless biological aortic valve surgical replacement

Clinical short and long term results of conventional aortic valve replacement have been clearly established along the last decades. At this moment, medical industry is developing a new short of biological aortic valve prosthesis that, despite the standard cardiopulmonary by-pass and aortic clamping need, they hold the advantage of a sutureless implantation system that leads to a faster surgery with less on-pump time with the evident benefits in terms of surgical risks. Interesting alternative application of sutureless valves is the redo surgery (re-interventions after prosthesis dysfunction). In this short of surgery, as it is always complex and risky, reducing aortic clamping time is essential, so these sutereless valves may offer an inestimable help by accelerating the valve insertion process. In case of biological dysfunctional prosthesis, sutereless valves allow a valve-in-valve implantation without the extraction of the previous dysfunctional valve. This procedure is performed by deployment of the sutureless valve within the pre-implanted valve stent-annulus, avoiding this way the risks involved in prosthesis removal (aortic root and annulus manipulation and prolonging clamping time).

This kind of prosthesis generate very low hemodynamic gradient because they are constructed over a low profile metallic stent, with a similar structure to transcatheter-deployable devices. This advantage improves valve hemodynamics and may contribute to ventricular mass regression.

The commercial bid of this group of prosthesis is based on its capacity to reduce the aggression of standard surgery, favouring the realization of progressively less invasive surgical techniques (ministernotomy, minithoracotomy, robotic surgery...) and the adding value of its contribution on the researching and development of future transcatheter devices.

Sorin's Perceval and 3F's Enable are the more promising models at this moment. The companies involved in the production of this prosthesis are those who may point the aim of this technique: development of newer transcatheter devices or really improve standard surgery results.(Shrestha M et al., 2009, Aymard T et al., 2010)



Perceval Sorin Valve



Enable 3F Valve

### 5. Apicoaortic conduits

Surgical aortic valve replacement by median thoracotomy under cardiopulmonary bypass is, as mentioned above, the standard therapy for severe aortic stenosis that has proven superiority to conservative pharmacological therapy. Many times, however, this treatment cannot be performed because of different technical, anatomic or clinical problems that the patient may present, as it could be porcelain aorta or tiny aortic annulus. Aortic valve conduits, also known as apicoaortic conduits, are a sort of devices designed in the sixties to give an alternative in these situations. Apicoaortic conduits connect the left ventricle apex with the descending thoracic aorta, relieving the intraventricular pressure by allowing the blood flow to find a way out of the heart without fighting against the aortic valve resistance. Because the operation was technically difficult, it had fallen into disuse, but, with the introduction of technically easier and less invasive procedures performed by minithoracotomy, this alternative offers clear advantages over standard valve replacement (avoidance of sternotomy, cardiopulmonary bypass, cardioplegic cardiac arrest, native valve debridement, conduction system injury, aortic cannulation, and aortic cross-clamping) and arises as another option in addition to transcatheter aortic valve implantation as alternative therapy for high risk patients. This technique offers the possibility to choose from a big variety of valve models and sizes, it



Aorto-apical conduit Medtronic Hancock

has proven long-term efficacy and durability, involves lower peri-procedural stroke risk and has no incremented AV block or paravalvular leak risks. As disadvantage, it commonly requires cardiopulmonary bypass pump, though some off-pump cases have been reported (Vassiliades TA Jr et al 2003; Hirota M et al; Chahine JH et al., 2009)

## 6. Conclusions

As the developed countries population continues its progressive aging, number of patients grows as the majority of cases, with the subsequent increase in co-morbidities and risk profile worsening. In the other hand, technical improvements and innovation in newer devices design and performance make these alternatives more and more attractive. In this scenario, the data reported by big clinical trials as PARTNER may result in a deep revolution in degenerative aortic stenosis management, where minimal invasive procedures arise as the procedures of choice for this high-risk population. We must wait until definitive publications in this way before introducing any change in the clinical practice guidelines, but at this moment we can be quite confident about the fact these novel techniques “are here to stay”

## 7. References


- Andersen HR, Knudsen LL, Hasenkam JM. Transluminal implantation of artificial heart valves. Description of a new expandable aortic valve and initial results with implantation by catheter technique in closed chest pigs. *Eur Heart J*. 1992 May;13 (5):704-708.
- Alexander KP, Anstrom KJ, Muhlbaier LH, Grosswald RD, Smith PK, Jones RH, et al. Outcomes of cardiac surgery in patients >80 years; results from the National Cardiovascular Network. *J Am Coll Cardiol*. 2000 Mar; 35 (3):731-8.
- Aregger F, Wenaweser P, Hellige GJ, Kadner A, Carrel T, Windecker S, et al. Risk of acute kidney injury in patients with severe aortic valve stenosis undergoing transcatheter valve replacement. *Nephrol Dial Transplant*. 2009 Jul;24 (7):2175-9.
- Aymard T, Kadner A, Walpoth N, Göber V, Englberger L, Stalder M, Eckstein F, Zobrist C, Carrel T. Clinical experience with the second-generation 3f Enable sutureless aortic valve prosthesis. *J Thorac Cardiovasc Surg*. 2010 Aug;140(2):313-6
- Bagur R, Webb JG, Nietlispach F, Dumont E, De Larocheillère R, Doyle D, et al. Acute kidney injury following transcatheter aortic valve implantation: predictive factors, prognostic value, and comparison with surgical aortic valve replacement. *Eur Heart J*. 2010 Apr;31(7):865-74.
- Bagur R, Dumont E, Doyle D, Larose E, Lemieux J, Bergeron S, et al. Coronary ostia stenosis following transcatheter aortic valve implantation. *JACC Cardiovasc Interv*. 2010 Feb; 3:253-5.
- Bonhoeffer P, Boudjemline Y, Saliba Z, Merckz J, Yacine A, Bonnet D, et al. Percutaneous replacement of pulmonary valve in a right ventricle to pulmonary-artery prosthetic conduit with valve dysfunction. *Lancet*. 2000 Oct 21;356:1403-5.
- Buellesfeld L, Wenaweser P, Gerckens U, Mueller R, Sauren B, Latsios G, et al. Transcatheter aortic valve implantation: predictors of procedural success – the Siegburg-Bern experience. *Eur Heart J*. 2010 Apr;31(8):984-91.



- Chahine JH, El-Rassi I, Jebara V. Apico-aortic valved conduit as an alternative for aortic valve re-replacement in severe prosthesis-patient mismatch. *Interact Cardiovasc Thorac Surg.* 2009 Oct;9(4):680-2.
- Charlson E, Legedza ATR, Hamel MB. Decision-making and outcomes in severe symptomatic aortic stenosis. *J Heart Valve Dis.* 2006 May;15 (3):312-321.
- Cribier A, Eltchaninoff H, Bash A, Borenstein N, Tron C, Bauer F, Derumeaux G, Anselme F, Laborde F, Leon MB. Percutaneous transcatheter implantation of an aortic valve prosthesis for calcific aortic stenosis: first human case description. *Circulation.* 2002 Dec 10;106:3006-3008.
- Cribier A, Eltchaninoff H, Tron C, Bauer F, Agatiello C, Nercolini D, et al. Treatment of calcific aortic stenosis with the percutaneous heart valve. Mid-term follow-up from the initial feasibility studies: the French experience. *J Am Coll Cardiol.* 2006 Mar 21;47:1214-23.
- Delgado V, Ng AC, Shanks M, van der Kley F, Schuijf JD, van de Veire NR, Kroft L, de Roos A, Schalij MJ, Bax JJ. Transcatheter aortic valve implantation: role of multimodality cardiac imaging. *Expert Rev Cardiovasc Ther.* 2010 Jan;8(1):113-23.
- Dumont E, Lemieux J, Doyle D, Rodés-Cabau J. Feasibility of transapical aortic valve implantation fully guided by transesophageal echocardiography. *J Thorac Cardiovasc Surg.* 2009 Oct ;138:1022-4.
- Grube E, Buellesfeld L, Mueller R, Sauren B, Zickmann B, Nair D, et al. Progress and current status of percutaneous aortic valve replacement results of three device generations of the CoreValve Revalving system. *Circ Cardiovasc Interv.* 2008 Dec;1:167-75.
- Grube E, Laborde JC, Zickmann B, Gerckens U, Felderhoff T, Sauren B, et al. First report on a human percutaneous transluminal implantation of a self-expanding valve prosthesis for interventional treatment of aortic valve stenosis. *Catheter Cardiovasc Interv.* 2005 Dec;66:465-9.
- Himbert D, Descoutures F, Al-Attar N, Iung B, Ducrocq G, Détaint D, et al. Results of transfemoral or transapical aortic valve implantation following a uniform assessment in high-risk patients with aortic stenosis. *J Am Coll Cardiol.* 2009 Jul 21;54:303-11.
- Hirota M, Oi M, Omoto T, Tedoriya T. Apico-aortic conduit for aortic stenosis with a porcelain aorta; technical modification for apical outflow. *Interact Cardiovasc Thorac Surg.* 2009 Oct;9(4):703-5.
- Iung B, Baron G, Butchart EG, Delahaye F, Gohlke-Barwolf C, Levang OW, Tornos P, Vanoverschelde JL, Vermeer F, Boersma E, Ravaud P, Vahanian A. A prospective survey of patients with valvular heart disease in Europe: the Euro Heart Survey on Valvular Heart Disease. *Eur Heart J.* 2003 Jul; 24 (13):1231-1243.
- Jilaihawi H, Chin D, Vasa-Nicotera M, Jeilam M, Spyt T, Ng GA, et al. Predictors for permanent pacemaker requirement after transcatheter aortic valve implantation with the CoreValve bioprosthesis. *Am Heart J.* 2009 Apr;157:860-6.
- Kapadia SR, Svensson L, Tuzcu M. Successful percutaneous management of left main trunk occlusion during percutaneous aortic valve replacement. *Catheter Cardiovasc Intervent.* 2009 Jun 1;73:966-72
- Kvidal P, Bergström R, Hörte LG, Ståhle E. Observed and relative survival after aortic valve replacement. *J Am Coll Cardiol.* 2000 Mar; 35 (3):747-56.

- Kempfert J, Falk V, Schuler G, Linke A, Merk D, Mohr FW, Walther T. Dyna-CT during minimally invasive off-pump transapical aortic valve implantation. *Ann Thorac Surg.* 2009 Dec;88(6):2041.
- Kodali SK, O'Neill WW, Moses JW, Williams M, Smith CR, Tuzcu M, Svensson LG, Kapadia S, Hanzel G, Kirtane AJ, Leon MB. Early and Late (One Year) Outcomes Following Transcatheter Aortic Valve Implantation in Patients With Severe Aortic Stenosis (from the United States REVIVAL Trial). *Am J Cardiol.* 2011 Apr 1;107(7):1058-64.
- Ng AC, Delgado V, van der Kley F, Shanks M, van de Veire NR, Bertini M, Nucifora G, van Bommel RJ, Tops LF, de Weger A, Tavilla G, de Roos A, Kroft LJ, Leung DY, Schuijf J, Schalij MJ, Bax JJ. Comparison of aortic root dimensions and geometries before and after transcatheter aortic valve implantation by 2- and 3-dimensional transesophageal echocardiography and multislice computed tomography. *Circ Cardiovasc Imaging.* 2010 Jan;3(1):94-102.
- Leon MB, Smith CR, Mack M, Miller DC, Moses JW, Svensson LG, Tuzcu EM, Webb JG, Fontana GP, Makkar RR, Brown DL, Block PC, Guyton RA, Pichard AD, Bavaria JE, Herrmann HC, Douglas PS, Petersen JL, Akin JJ, Anderson WN, Wang D, Pocock S; PARTNER Trial Investigators. Transcatheter aortic-valve implantation for aortic stenosis in patients who cannot undergo surgery. *N Engl J Med.* 2010 Oct 21;363(17):1597-607.
- Pai RG, Kapoor N, Bansal RC, Varadarajan P. Malignant natural history of asymptomatic severe aortic stenosis: benefit of aortic valve replacement. *Ann Thorac Surg.* 2006 Dec; 82 (6):2116-2122.
- Piazza N, Onuma Y, Jesserun E, Kint PP, Maugenest AM, Anderson RH, et al. Early and persistent intraventricular conduction abnormalities and requirements for pacemaking after percutaneous replacement of the aortic valve. *JACC Cardiovasc Interv.* 2008 Jun;1:310-6.
- Rodés-Cabau J, Dumont E, DelaRochelière R, Doyle D, Lemieux J, Bergeron S, et al. Feasibility and initial results of percutaneous aortic valve implantation including selection of the transfemoral or transapical approach in patients with severe aortic stenosis. *Am J Cardiol.* 2008 Nov;102 (9):1240-4.
- Rodés-Cabau J, Webb JB, Anson C, Ye J, Dumont E, Feindel C, et al. Transcatheter aortic valve implantation for the treatment of severe symptomatic aortic stenosis in patients at very high or prohibitive surgical risk. Acute and late outcomes of the multicenter Canadian experience. *J Am Coll Cardiol.* 2010 Mar 16;55:1080-90.
- Shrestha M, Folliguet T, Meuris B, Dibie A, Bara C, Herregods MC, Khaladj N, Hagl C, Flameng W, Laborde F, Haverich A. Sutureless Perceval S aortic valve replacement: a multicenter, prospective pilot trial. *J Heart Valve Dis.* 2009 Nov;18(6):698-702.
- Thomas M, Schymik G, Walther T, Himbert D, Lefèvre T, Treede H, Eggebrecht H, Rubino P, Michev I, Lange R, Anderson WN, Wendler O. Thirty-day results of the SAPIEN aortic Bioprosthesis European Outcome (SOURCE) Registry: A European registry of transcatheter aortic valve implantation using the Edwards SAPIEN valve. *Circulation.* 2010 Jul 6;122(1):62-9.
- Varadarajan P, Kapoor N, Bansal RC, Pai RG. Clinical profile and natural history of 453 nonsurgically managed patients with severe aortic stenosis. *Ann Thorac Surg.* 2006 Dec; 82 (6):2111-2115.

- Vahanian A, Palacios IF. Percutaneous approaches to valvular disease. *Circulation*. 2004 April 6;109:1572-9.
- Vahanian A, Baumgartner H, Bax J, Butchart E, Dion R, Filippatos G, Flachskampf F, Hall R, Jung B, Kasprzak J, Nataf P, Tornos P, Torracca L, Wenink A; Guidelines on the management of valvular heart disease: The Task Force on the Management of Valvular Heart Disease of the European Society of Cardiology. Task Force on the Management of Valvular Heart Disease of the European Society of Cardiology; ESC Committee for Practice Guidelines. *Eur Heart J*. 2007 Jan;28(2):230-68.
- Vahanian A, Alfieri O, Al-Attar N, Antunes M, Bax J, Cormier B, Cribier A, De Jaegere P, Fournial G, Kappetein AP, Kovac J, Ludgate S, Maisano F, Moat N, Mohr F, Nataf P, Piérard L, Pomar JL, Schofer J, Tornos P, Tuzcu M, van Hout B, Von Segesser LK, Walther T; Transcatheter valve implantation for patients with aortic stenosis: a position statement from the European Association of Cardio-Thoracic Surgery (EACTS) and the European Society of Cardiology (ESC), in collaboration with the European Association of Percutaneous Cardiovascular Interventions (EAPCI). European Association of Cardio-Thoracic Surgery; European Society of Cardiology; European Association of Percutaneous Cardiovascular Interventions. *Eur Heart J*. 2008 Jun;29(11):1463-70.
- Vassiliades TA Jr. Off-pump apicoaortic conduit insertion for high-risk patients with aortic stenosis. *Eur J Cardiothorac Surg*. 2003 Feb;23(2):156-8.
- Walther T, Simon P, Dewey T, Wimmer-Greinecker G, Falk V, Kasimir MT, et al. Transapical minimally invasive aortic valve implantation. Multicenter experience. *Circulation*. 2007 Sep 11;116:1240-5.
- Webb JG, Chandavimol M, Thompson CR, Ricci DR, Carere RG, Munt BI, Buller CE, Pasupati S, Lichtenstein S. Percutaneous aortic valve implantation retrograde from the femoral artery. *Circulation*. 2006 Feb 14;113:842-850.
- Webb JG, Pasupati S, Humphries K, Thompson C, Altwegg L, Moss R, Sinhal A, Carere RG, Munt B, Ricci D, Ye J, Cheung A, Lichtenstein SV. Percutaneous transarterial aortic valve replacement in selected high-risk patients with aortic stenosis. *Circulation*. 2007 Aug 14;116:755-763.
- Wendler O, Walther T, Nataf P, Rubino P, Schroefel H, Thielmann M, Treede H, Thomas M. Trans-apical aortic valve implantation: univariate and multivariate analyses of the early results from the SOURCE registry. *Eur J Cardiothorac Surg*. 2010 Aug;38(2):119-27.
- Wood D, Tops LF, Mayo JR, Pasupati S, Schalij MJ, Humphries K, et al. Role of multislice computed tomography in transcatheter aortic valve replacement. *Am J Cardiol*. 2009 May 1;103:1295-301.



## **Aortic Valve Stenosis - Current View on Diagnostics and Treatment**

Edited by Dr. Petr Santavy

ISBN 978-953-307-628-7

Hard cover, 146 pages

**Publisher** InTech

**Published online** 22, September, 2011

**Published in print edition** September, 2011

Currently, aortic stenosis is the most frequent heart valve disease in developed countries and its prevalence increases with the aging of the population. Affecting 3-5 percent of persons older than 65 years of age, it makes a large personal and economical impact. The increasing number of elderly patients with aortic stenosis brings advances in all medical specialties dealing with this clinical entity. Patients previously considered too old or ill are now indicated for aortic valve replacement procedures. This book tries to cover current issues of aortic valve stenosis management with stress on new trends in diagnostics and treatment.

### **How to reference**

In order to correctly reference this scholarly work, feel free to copy and paste the following:

Javier Gualis, Alejandro Diego, Antonio de Miguel and Mario Castaño (2011). Trends in Degenerative Aortic Disease: Novel Alternative Therapies for the Treatment of Severe Aortic Stenosis, Aortic Valve Stenosis - Current View on Diagnostics and Treatment, Dr. Petr Santavy (Ed.), ISBN: 978-953-307-628-7, InTech, Available from: <http://www.intechopen.com/books/aortic-valve-stenosis-current-view-on-diagnostics-and-treatment/trends-in-degenerative-aortic-disease-novel-alternative-therapies-for-the-treatment-of-severe-aortic>

# **INTECH**

open science | open minds

### **InTech Europe**

University Campus STeP Ri  
Slavka Krautzeka 83/A  
51000 Rijeka, Croatia  
Phone: +385 (51) 770 447  
Fax: +385 (51) 686 166  
[www.intechopen.com](http://www.intechopen.com)

### **InTech China**

Unit 405, Office Block, Hotel Equatorial Shanghai  
No.65, Yan An Road (West), Shanghai, 200040, China  
中国上海市延安西路65号上海国际贵都大饭店办公楼405单元  
Phone: +86-21-62489820  
Fax: +86-21-62489821

© 2011 The Author(s). Licensee IntechOpen. This chapter is distributed under the terms of the [Creative Commons Attribution-NonCommercial-ShareAlike-3.0 License](#), which permits use, distribution and reproduction for non-commercial purposes, provided the original is properly cited and derivative works building on this content are distributed under the same license.

IntechOpen

IntechOpen