

We are IntechOpen, the world's leading publisher of Open Access books Built by scientists, for scientists

4,800

Open access books available

122,000

International authors and editors

135M

Downloads

Our authors are among the

154

Countries delivered to

TOP 1%

most cited scientists

12.2%

Contributors from top 500 universities



WEB OF SCIENCE™

Selection of our books indexed in the Book Citation Index
in Web of Science™ Core Collection (BKCI)

Interested in publishing with us?
Contact book.department@intechopen.com

Numbers displayed above are based on latest data collected.
For more information visit www.intechopen.com



Magnetic Resonance Tractography in Neuroradiological Diagnostic Aspects

Jaroslaw Paluch, Jaroslaw Markowski, Tatiana Gierek,
Przemyslaw Pencak, Malgorzata Witkowska, Maciej Kajor,
Agnieszka Gorzkowska and Agnieszka Piotrowska
*Medical University of Silesia in Katowice
Poland*

1. Introduction

Diffusion tensor imaging (DTI) is a Magnetic Resonance (MR) method used for analysis of diffusion anisotropy in central nervous system (CNS). It provides the anatomic details of brain white matter. At present, it is also a very useful method in neuro-radiology, providing morphological markers of disease progression or reaction to treatment [1]. In the last 10-15 years, the studies concerning magnetic resonance imaging technique focused more on the phenomenon of diffusion in living tissues [2]. The graphic representation of diffusion in MR is a pretty valuable observation method when dealing with nervous tissue structures, and due to its non-invasive character [2, 3] it is perfectly suited for assessment of brain throughout its development, from birth until reaching complete biological maturity, and further on to elderly age and senility. Human brain, from the embryonic stage on, is subject to transformations due to development, differentiation, and proliferation of neurons, improvement of synaptic junctions, while maintaining those junctions is related to a long process of myelination, lasting until 25 years of age [4]. Diffusion imaging in magnetic resonance investigation (DT-MRI) allowed for calculations of nerve fibre pathways, within the properly arranged structure of the white matter of brain.

2. Discussion of the method: mathematical and physical aspect

Diffusion is a process based on the movement of particles of a substance dissolved in the solution, all well as movement of particles of the very solution (medium) [6], leading to levelling of concentrations of substrates contained in the solution (of liquid or gas). That phenomenon is related to the chaotic movement of particles of the solution, depending on the thermal energy of the system, also labelled as 'random movement of particles' also - historically "Brownian movements" [4]. In human body structures anisotropic centres are usually present, the nature of which results mainly from the fact of occurrence of many membranes, both cellular ones, and intracellular ones, which interfere with free diffusion. Human body may be divided into many centres, one different from another, which may be classified as one of the three basic areas, namely: extracellular space, intracellular space, third space. Extracellular space is characterized by isotropy and relatively high values of diffusion coefficient [4]. Due to the homogeneous properties of the basilar medium

(extracellular fluid), and proportionally large (in comparison with translocations of particles due to chaotic thermal motion) distances between cell membranes. Intracellular space, due to the medium (cytosol, formerly referred to as cytoplasm), as well as the occurrence of numerous cellular and intracellular membranes, as well as their arrangement (spatial arrangement in the form of "dense packing"), is anisotropic and has a relatively lower level of effective diffusion coefficient (absolute level of diffusion of the medium, corrected due to the barriers present) [2]. Some of the existing processes may cause reduction of the extracellular space, in favour of intracellular space, which is followed by changes in averaged values of the diffusion coefficient within the voxel. The third space is anisotropic, while the diffusion coefficient value depends on the composition of the medium (e.g. mucous serous content, purulent content, etc.) [4].

The bio-structure of brain belongs to anisotropic structures, thus the diffusion tensor is used to describe the coefficient of diffusion (highly differentiated, depending on the location and direction), instead of single scalar value [7]. The tensor, being a mathematical concept, independent on the selection of the coordinate system is, to simplify, similar to the notion of "vector". It enables presentation of physical quantity, the value of which depends on direction. The application of diffusion tensor allows to provide an approximate description of the distribution of diffusion coefficient values, taking into account its direction in anisotropic spaces.

Complementing the theoretical model, which solely takes diffusion into consideration, by phenomena occurring in the bio-structures, perfusion and micro-circulation among others, influencing the size of signal change in the sequence utilizing diffusion coding gradients, led to the formulation of the notion of "apparent diffusion coefficient" (ADC), calculated and presented in the form of ADC maps [4]. The principle has been assumed that in diffusion-weighted imaging (DWI), areas of low diffusion are shown as bright ones. However, in interpreting them, one should always take into account the b value. In case of low values of b, the image contrast is strongly dependent on the time of transverse relaxation, T. That phenomenon is called T shining (T-dependent shining) [2].

Data calculated from measurements taken with the application of at least two sequences, with different values of b, is used for developing of ADC images. The contrast in ADC images is in proportion to diffusion – tissues with low diffusion are shown as dark areas, whereas tissues or spaces with high diffusion are encoded as bright ones [4]. In humans, anisotropic areas prevail, where the multi-directional differentiation of diffusion calls for more complex description, in the form of diffusion tensor. For the purpose of computing the tensor, it is indispensable to take measurements of diffusion in at least six, at best nine or more (in newest MRI system up to 265) directions.

Besides the notion of "diffusion coefficient", also the notion of "diffusivity" is used [3], being correspondent to diffusion per time unit. One of the values used for describing the diffusion tensor is a scalar value of total diffusion, labelled as "trace" (D), as well as mean diffusivity (MD), being dependent on the former. Both those values represent the total value of diffusion in a given point in space, yet do not contain any information about its differentiation depending on direction.

To express the level of anisotropy of the examined structure, the notion of fractional anisotropy (FA) is applied, which is a scalar quantity, and has values in the 0-1 range. The value of 0 corresponds to isotropic structure, whereas the value of 1 to a structure, in which diffusion is possible in one direction only [2, 4]. Due to the degree of organization, the white

matter of brain has high values of FA (the highest in the *corpus callosum* and pyramidal tracts), as well as relatively low value of MD. The grey matter is characterized by relatively low values of FA and MD [4, 8]. For cerebrospinal fluid, very low values of FA are typical (close to 0), at the same time the MD values occur to be high. There are different ways of imaging the diffusion tensor (DTI) distribution. Among the most popular ones are the MD images in various shades of grey, FA images in grey shading scale, and colour-coded FA images and tractography. There is a rule, according to which in FA mapping using scale of grey, the areas of high anisotropy are presented as bright, whereas isotropic centres – as dark. In case of parametric colour-coded FA maps, the colour is determined by the direction of the maximum component of diffusion tensor (red: right-left, green: forward-backward, blue: up-down), while the intensity depends on the FA value [4, 5]. In tractography, the algorithm of plotting the tract of fibres from a selected point is used, based on the principle of continuity of voxels, as well as selection of every next point, depending on the direction determined by the dominating component of diffusion tensor in the current voxel [6]. In other words, starting with the initial point, the line goes towards the maximum diffusion, until it encounters the first voxel [1]. Then it changes the direction to the maximum diffusion of the next new voxel. That process is continued until the critical end moment is reached [4]. The end point may be a relatively low level of anisotropy, indicating the necessity of terminating the tract in the white matter. Depending on the starting point, one can code the colours for specific tracts, thus the multi-coloured imaging [3, 8]. It should be remembered that the hypothetical tract of fibres, plotted in tractography, results from a mathematical model developed on the basis of diffusion tensor, averaged for a given voxel, not from the actual fibre route [2, 4].

3. Application of DTI – MR

Tractography, treated as a way of imaging nerve tracts, has been used in clinical studies and diagnostics of brain diseases [5]. Tractography techniques enable showing the structures in white matter, and nerve tract [7, 9]. That allowed, among other things, to study the tracts running in the major point of connection between cerebral hemispheres, which is the *corpus callosum*, and to discover new tracts between distant regions [1, 3, 6, 10], as well as development of a 3D model of nerve fibre bundles [5, 11]. Changes in fractional anisotropy or mean diffusivity in brain diseases enable accurate location of topical lesion. Finding out, which nerve tracts are visible, one may determine the degree of development and progression of the disease, as well as to select the intervention method [12]. That has been used in studies on epilepsy [13], where the impairment of nerve tract connections in both hemispheres have been shown. Also in neuro-oncology, radiological imaging by means of tractography provides information about the functions of specific nerve tracts, as well as their relations with the tumour being subject of surgical intervention [10]. That has found applications for pre-surgical mapping of tracts, as well as planning the scope and type of surgical intervention [12]. In Poland, neuro-surgical procedures are already carried out with simultaneous following the functions of nerve tracts. Thanks to modern software for tractography, available since December 2008, it was possible to visualize in real time – during the surgical procedure of tumour excision – the activity and functions of nerve fibres. The data obtained were subsequently utilized by the system for neuro-surgical navigation,

to enable more precise excision of tumour, which significantly enhanced the safety of surgical procedure, and reduced the risk of complications [12].

Tractography also allowed imaging of lesions in the brain in patients with multiple sclerosis (SM), as well as with amyotrophic lateral sclerosis (Charcot's disease), where changes in diffusion and anisotropy, degeneration of cortico-spinal tract became visible [13]. Moreover, that type of investigation allows to diagnose not only changes related to defect, but also increased compensatory myelinization in case of brain with unilateral injury. Tractography served the purpose of proving the possibility of fibre regeneration or change in the of nerve tract around the place of lesion in experimental studies carried out on Apes with injury of a part of brain [11]. DT-MRI adreno-leucodystrophy allows to identify degenerated white matter, which is not possible in conventional magnetic resonance (MR) [2]. The paper describing the results of studies on Alzheimer's disease, describes using the DT-MRI method for independent imaging of the degree of defect of white matter, by measuring diffusivity and anisotropy, in comparison with control [14].

To sum up, tractography enables reconstruction of the alignment of nerve fibres, in colourful 3D projection, in accordance with the highest level of diffusivity, fibres that connect one region with another in the brain [2, 11, 15]. It is based on imaging the diffusion tensor, and is a quickly developing method of examining the central nervous system [1]. In order to validate that technique, objective methods are required, which compare white matter tracts, as well as diameters of alignment of tracts in biological assays [2]. It is essential to be aware of the limitations resulting from application of that method. Due to the fact that the size of voxel is a few millimetres [13] it may contain dozens of thousands of axons with different arrangement/ arrangement [3, 6, 13]. What is more, one should take into account the fact that the image of fibre alignment (track) does not provide the answer about the direction of the fibres [8, 13]. In case of fibres having similar size, yet oriented in opposite directions, no path will be marked. In turn, when a pathway having bigger size passes next to smaller tracts, it may happen that the latter will be imaged as part of the former pathway, and true data about the alignment will be lost [1]. Difficulties may also arise from differentiating between crossing pathways, which form a bigger route [3]. The direction that we get image of is then analogical, despite differences in anisotropy. The interpenetration of pathways also distorts the regular/ regular image provided by DT-MRI [10]. It would seem that voxel size reduction would allow avoiding the limitations [10]. Unfortunately, that will increase costs and extend the examination time [3], which is connected with the occurrence of artefacts resulting from breathing, flow of fluids in brain, as well as eye movement, or movement of the entire head during examination [2].

In future, the method of diffusion imaging in MRI may be applied in other tissues containing fibres, such as heart, where it would provide information concerning correct development of the organ or diagnosing of the disease [1, 2]. The application of fibre tract visualization methods with the application of contrast media, such as manganite, together with DT-MRI shall provide additional possibilities in both diagnosing diseases, as well as observation of regular brain structures, as well as structures of other fibrous tissues. That, in turn, will explain the dependency of connections with central and peripheral nervous systems [1].

DT-MRI is a method of imaging the structures of brain white matter [1, 5]. Disclosure of the connection system allows to get the understanding of how the brain organization works, it

also provides information on irregularities in those structures [16]. Dissemination of that method shall enable imaging nerve tract connections in the entire body.

In otolaryngological diagnosing, particularly in otoneurological diagnosing, the following application possibilities are perceived:

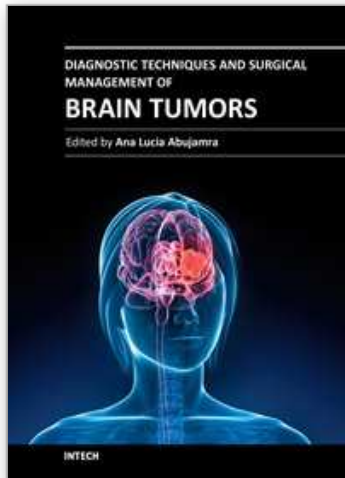
- assessment of hearing, olfactory, and gustatory tracts, in the aspect of physiological development;
- disturbances in functions of tracts belonging to senses in the course of neurodegenerative diseases (Alzheimer's disease, Parkinson's disease, atherosclerotic syndromes, diabetes, metabolic diseases, neuropathies of renal origin);
- diagnostics in patients with peripheral or central lesion of the organ of hearing, before surgical treatment, as well as post-surgery monitoring;
- determination of morphological parameters on the basis of analysis of hearing tract image, in the treatment of patients with cochlear implants and bone anchored hearing aid (BAHA).

4. References

- [1] Basser PJ, Pajevic S, Pierpaoli C, Duda J, Aldroubi A. In vivo fiber tractography using DT-MRI data. *Magn Reson Med*. 2000 Oct;44(4):625-32.
- [2] Melhem ER, Mori S, Mukundan G, Kraut MA, Pomper MG, van Zijl PC. Diffusion tensor MR imaging of the brain and white matter tractography. *AJR Am J Roentgenol*. 2002 Jan;178(1):3-16.
- [3] Watts R, Liston C, Niogi S, Uluğ AM. Fiber tracking using magnetic resonance diffusion tensor imaging and its applications to human brain development. *Ment Retard Dev Disabil Res Rev*. 2003;9(3):168-77.
- [4] Walecki J., Pawłowska- Detko A., Adamczyk M., Rola współczesnych metod obrazowania w rozpoznaniu i monitorowaniu otępienia. *Polaski Przegląd Neurologiczny* 2007; 3,2.
- [5] Yamada K, Kizu O, Mori S, Ito H, Nakamura H, Yuen S, Kubota T, Tanaka O, Akada W, Sasajima H, Mineura K, Nishimura T. Brain fiber tracking with clinically feasible diffusion-tensor MR imaging: initial experience. *Radiology*. 2003 Apr;227(1):295-301.
- [6] Maddah M, Mewes AU, Haker S, Grimson WE, Warfield SK. Automated atlas-based clustering of white matter fiber tracts from DTMRI. *Med Image Comput Comput Assist Interv*. 2005;8(Pt 1):188-95.
- [7] Behrens T.E.J., Johansen Berg H., Jbabdi S., Rushworth M.F.S., Woolrich M.W. Probabilistic diffusion tractography with multiple fibre orientations: What can we gain? *Neuroimage* 2007 (34): 144-155.
- [8] Behrens T.E.J., Johansen Berg H., Woolrich M.W., Smith S.M., Wheeler- Kingshott C.A., Boulby P.A. Non- invasive mapping of connections between human thalamus and cortex using diffusion imaging. *Nat- Neurosc* 2003, Jul; 6(7), 750-7.
- [9] Corouge I., Gouttard S., Gerig G. Towards a shape model of white fiber bundles using diffusion tensor MRI. *Interantion symposium on Biomedical Imaging* 2004 Vol 1, 334-347.
- [10] Lazar M, Weinstein DM, Tsuruda JS, Hasan KM, Arfanakis K, Meyerand ME, Badie B, Rowley HA, Haughton V, Field A, Alexander AL. White matter tractography using diffusion tensor deflection. *Hum Brain Mapp*. 2003 Apr;18(4):306-21.

- [11] Maddah M., Wells W.M., Warfield S.K., Westin C., F., Eric W., Grimson L.A.: A spation model of White Matter Fiber Tracts
- [12] http://web.mit.edu/mmaddah/www/mahnaz_ISMRM2007_clusteringfibertracts.pdf.
- [13] Witwer BP, Moftakhar R, Hasan KM, Deshmukh P, Haughton V, Field A, Arfanakis K, Noyes J, Moritz CH, Meyerand ME, Rowley HA, Alexander AL, Badie B. Diffusion-tensor imaging of white matter tracts in patients with cerebral neoplasm. *J Neurosurg.* 2002 Sep;97(3):568-75.
- [14] Johansen-Berg H, Behrens TE. Just pretty pictures? What diffusion tractography can add in clinical neuroscience. *Curr Opin Neurol.* 2006 Aug;19(4):379-85. Review.
- [15] Taoka T, Iwasaki S, Sakamoto M, Nakagawa H, Fukusumi A, Myochin K, Hirohashi S, Hoshida T, Kichikawa K. Diffusion anisotropy and diffusivity of white matter tracts within the temporal stem in Alzheimer disease: evaluation of the "tract of interest" by diffusion tensor tractography. *AJNR Am J Neuroradiol.* 2006 May;27(5):1040-5.
- [16] Catani M, Jones DK, Donato R, Ffytche DH. Occipito-temporal connections in the human brain. *Brain.* 2003 Sep;126(Pt 9):2093-107. Epub 2003 Jun 23.
- [17] Lazar M., Weinstein D., Hasan K., Alexander A.L. Axon tractography with tensorlines. *Proc. Intl. Soc. Mag. Reson. Med.* 8, 2000.

IntechOpen



Diagnostic Techniques and Surgical Management of Brain Tumors

Edited by Dr. Ana Lucia Abujamra

ISBN 978-953-307-589-1

Hard cover, 544 pages

Publisher InTech

Published online 22, September, 2011

Published in print edition September, 2011

The focus of the book *Diagnostic Techniques and Surgical Management of Brain Tumors* is on describing the established and newly-arising techniques to diagnose central nervous system tumors, with a special focus on neuroimaging, followed by a discussion on the neurosurgical guidelines and techniques to manage and treat this disease. Each chapter in the *Diagnostic Techniques and Surgical Management of Brain Tumors* is authored by international experts with extensive experience in the areas covered.

How to reference

In order to correctly reference this scholarly work, feel free to copy and paste the following:

Jaroslav Paluch, Jaroslav Markowski, Tatiana Gierek, Przemyslaw Pencak, Malgorzata Witkowska, Maciej Kajor, Agnieszka Gorzkowska and Agnieszka Piotrowska (2011). Magnetic Resonance Tractography in Neuroradiological Diagnostic Aspects, *Diagnostic Techniques and Surgical Management of Brain Tumors*, Dr. Ana Lucia Abujamra (Ed.), ISBN: 978-953-307-589-1, InTech, Available from: <http://www.intechopen.com/books/diagnostic-techniques-and-surgical-management-of-brain-tumors/magnetic-resonance-tractography-in-neuroradiological-diagnostic-aspects>

INTECH

open science | open minds

InTech Europe

University Campus STeP Ri
Slavka Krautzeka 83/A
51000 Rijeka, Croatia
Phone: +385 (51) 770 447
Fax: +385 (51) 686 166
www.intechopen.com

InTech China

Unit 405, Office Block, Hotel Equatorial Shanghai
No.65, Yan An Road (West), Shanghai, 200040, China
中国上海市延安西路65号上海国际贵都大饭店办公楼405单元
Phone: +86-21-62489820
Fax: +86-21-62489821

© 2011 The Author(s). Licensee IntechOpen. This chapter is distributed under the terms of the [Creative Commons Attribution-NonCommercial-ShareAlike-3.0 License](#), which permits use, distribution and reproduction for non-commercial purposes, provided the original is properly cited and derivative works building on this content are distributed under the same license.

IntechOpen

IntechOpen