

We are IntechOpen, the world's leading publisher of Open Access books Built by scientists, for scientists

4,800

Open access books available

122,000

International authors and editors

135M

Downloads

Our authors are among the

154

Countries delivered to

TOP 1%

most cited scientists

12.2%

Contributors from top 500 universities



WEB OF SCIENCE™

Selection of our books indexed in the Book Citation Index
in Web of Science™ Core Collection (BKCI)

Interested in publishing with us?
Contact book.department@intechopen.com

Numbers displayed above are based on latest data collected.

For more information visit www.intechopen.com



Severe Calcific Aortic Valve Stenosis and Bleeding: Heyde's Syndrome

Giampaolo Zoffoli et al.*

Department of Cardiac Surgery, Venezia-Mestre, Italy

1. Introduction

In 1958 Dr. Edward C. Heyde, an internist living and working in Vancouver, WA, first reported in a letter to the *New England Journal of Medicine*, 10 cases of calcific aortic stenosis and gastrointestinal bleeding. The association between severe calcific aortic stenosis and iron deficiency anemia due gastrointestinal bleeding, from colonic angiodysplasia was described as Heyde syndrome. A letter appearing shortly after confirmed an odd ratio of almost 3.0 between the two diseases. (1)

In the same year Goldman noted that within the population of severe aortic stenosis there was a three fold higher prevalence of gastrointestinal bleeding, and few years later Cattell published a more drastic position, due to the the fact that patient with aortic stenosis could bleed from a lesion in the ascending colon which has not been demonstrated by the pathologist, and recommended blind right haemicolectomy as a treatment for recurrent anaemia.

Dystrophic calcification of heart valves was first described by dr. Monckeberg in 1904.

With the advent of the extracorporeal circulation discovered by Gibbon in 1954, applied to cardiac surgery operations, a new frontiere for valve disease was achieved, and valve therapy radically changed in those years, in favour of valve replacement.

Unfortunately for many years the association between these two condition has been underestimated and it has not been verified with a methodological approach until the '80s, when Greenstein and King reported in two different publications this association between aortic stenosis and bleeding. (2,3).

In a first attempt to treat this syndrome, an empirical approach was used with blood transfusion; but in those years it has been noticed that, after aortic valve replacement, there was a complete cessation of the bleeding, and the restoring of the normal gastrointestinal mucosa.

By 1987, 30 cases of upper and lower gastrointestinal angiodysplasia had been cured by AVR. Angiodysplasia might remain visible at endoscopy even after AVR, but only 1 of the 30 cases ever developed recurrent gastrointestinal bleeding.

Patients with Heyde syndrome who are treated by intestinal resection generally continue to bleed from other sites, while AVR usually cures the clotting disorder and anaemia. A

*Domenico Mangino, Andrea Venturini, Angiolino Asta, Alberto Terrini, Chiara Zanchettin, Francesco Battaglia and Elvio Polesel

Department of Cardiac Surgery, Venezia-Mestre, Italy

retrospective study of 91 patients with aortic stenosis and chronic unexplained gastrointestinal bleeding revealed that bleeding ceased in 93% of patients treated by valve replacement, compared with 5% of those managed surgically, with or without bowel resection.

We have to remember that prosthetic valves may encroach on valvular orifices causing mild stenosis (patient-prosthesis mismatch).

It is important to consider the possible presence of Heyde syndrome if metallic AVR is being considered, as there is a need for lifelong anticoagulation subsequently.

Despite the small interest within the scientific community, this syndrome has been a matter of debate but no explanation for this link has been found.

Aortic stenosis is now the most acquired valvular lesion in the elderly. The prevalence of critical aortic stenosis is 1-2% at 75 years, rising to 6% at 85 years.

Angiodysplasia is present in 3% of population that undergo to colonoscopies, and may occur anywhere in the gastrointestinal tract, but is most common in the ascending colon, especially in the cecum (37%).

Several studies have tried to define prevalence and etiopathology of this syndrome, but results remained unclear so far, because aortic stenosis may be easily detected in later symptomatic stages, while colon angiodysplasia will not always result in anemia, or routine investigations may not reveal that they are the cause of a patient's anemia, and it is likely that many mild cases remain undiagnosed.

Some early studies on Heyde syndrome showed a correlation of a typical murmur of aortic stenosis with idiopathic gastrointestinal bleeding, while later studies have used echocardiographic and endoscopic diagnoses. Colonoscopy is the most common investigation used to visualise the colon, but colonoscopic diagnoses are usually used in retrospective studies. Many studies have not distinguished bleeding from non-bleeding angiodysplasia.

According to Yoshida and co-workers, in a recent study, severe aortic stenosis is found in up to 15–25% of patients with repeated bleeding.(22) Mehta *et al.* investigated 29 patients with gastrointestinal angiodysplasia detected on endoscopy with echocardiography, but found no cases of aortic stenosis.(23) Similarly, Oneglia *et al.* investigated 59 patients and found that only one had aortic stenosis.(24)

In a prospective, case-matched study of 40 patients who were found to have angiodysplasia, Bhutani and colleagues found no increased prevalence of aortic stenosis. (25)

Pate and colleagues studied 3.8 million discharge summaries retrospectively, and found a significant association ($P < 0.0001$) between aortic stenosis and gastrointestinal bleeding presumed to be due to angiodysplasia. Age was statistically significant as a confounding factor, as patients who had been diagnosed with both conditions were older than patients with only one or neither ($P < 0.0001$). In another retrospective case-note study of 3,623 patients with either aortic or mitral stenosis, gastrointestinal bleeding was found to be significantly more common in the aortic stenosis group ($P < 0.001$).

In a study of patients diagnosed with angiodysplasia of the gastrointestinal tract over a 10-year period, echocardiography significantly correlated with aortic stenosis but not with mitral stenosis. Significant aortic stenosis was 2.6 times more common than in controls, and severe aortic stenosis was 4.1 times more common than in the general population. The study included patients diagnosed by angiography as well as endoscopy in contrast to the study of Bhutani *et al.*

Only several years later the letter from dr. Heyde, this haemorrhagic syndrome, basically an acquired coagulopathy, was associated with acquired type 2A von Willebrand syndrome, which is characterised by the loss of the largest multimers of von Willebrand factor. (4,5,6)

Proteolysis of von Willebrand factor as it passes through the stenotic valve is one of the proposed causes of the bleeding. High shear forces can induce structural changes in the shape of the von Willebrand factor molecule, leading to exposure of the bond between amino acids Tyr842 and Met843, which is sensitive to the action of a specific von Willebrand protease. (8,9,10)

This results in proteolysis of the highest-molecular-weight multimers of von Willebrand factor, which are the most effective in platelet-mediated hemostasis under conditions of high shear stress. (11)

Yoshida and colleagues showed electrophoretic deficits of large multimers of vWF in patients with aortic stenosis which resolved postoperatively, but no differences in pre- and postoperative vWF were found in patients with severe mitral regurgitation. (22)

In mild to moderate cases of von Willebrand disease, a therapy based on Desmopressin (DDAVP), that releases Factor VIII storage pools, is used with a moderate success.

The concept of proteolysis of the highest-molecular-weight multimers of von Willebrand factor, under conditions of high shear stress, is further supported by the recent demonstration that this biologic abnormalities can be corrected by valve replacement. (12,13,14)

So many authors have hypothesised that acquired von Willebrand syndrome could be a common feature in patients with aortic stenosis. Moreover Vincentelli et al. argue that severe forms of Heyde's syndrome might be sufficient reason for aortic valve replacement, even if the stenosis is otherwise clinically unimportant and is not likely to cause complications. (16)

In 1971, Boss and Rosenbaum described distension of vessels in the intestinal mucosa in post-mortem cases of aortic stenosis and attributed the blood loss to this (26). Low-grade chronic hypoxia may stimulate reflex sympathetic vasodilation and smooth muscle relaxation, progressing to true ectasia of vessel walls.

Another theory is that colonic mucosal hypoxia might be caused by cholesterol emboli from the aortic valve or by the altered pulse waveform in aortic stenosis. Angiodysplasia have been described in hypertrophic cardiomyopathy, in which is also found alteration of the pulse waveform.

Several studies comparing cases of aortic and mitral valve stenosis have shown a higher prevalence of gastrointestinal bleeding in the former. Other valvular lesions might cause chronic hypoxia in the intestinal mucosa, but do not induce altered pulse waveforms. Some found no association of aortic stenosis with angiodysplasia but found a high frequency of colonic polyps and tumours whereas others have suggested that Heyde syndrome is the end result of senile degeneration of both aortic valvular and gastrointestinal mucosal tissue.

In an elderly patient with established aortic stenosis, development of iron deficiency anaemia should raise the possibility of Heyde syndrome. Initial investigations should explore other possibilities such as underlying gastrointestinal malignancy, coeliac disease or nutritional deficiency. The presence of angiodysplasia on sigmoidoscopy or colonoscopy (figure 1) or a failure of the investigations to find any clear site of gastrointestinal bleeding, should raise the possibility of Heyde syndrome. For patients in whom initial investigations show no abnormality, angiodysplasia may be diagnosed by capsule endoscopy.

Patients presenting with gastrointestinal bleeding should be examined carefully for aortic stenosis and there should be a low threshold for arranging echocardiogram in patients with normal colonoscopies or proven arteriovenous malformations.

In vWS-2A, routine screening tests for vWS are usually normal. The gold standard is gel electrophoresis of vWF. vWS-2A is characterised by absence of large vWF multimers seen on SDS-agarose electrophoresis. The sensitivity of various tests for vWS-2A has been ranked as

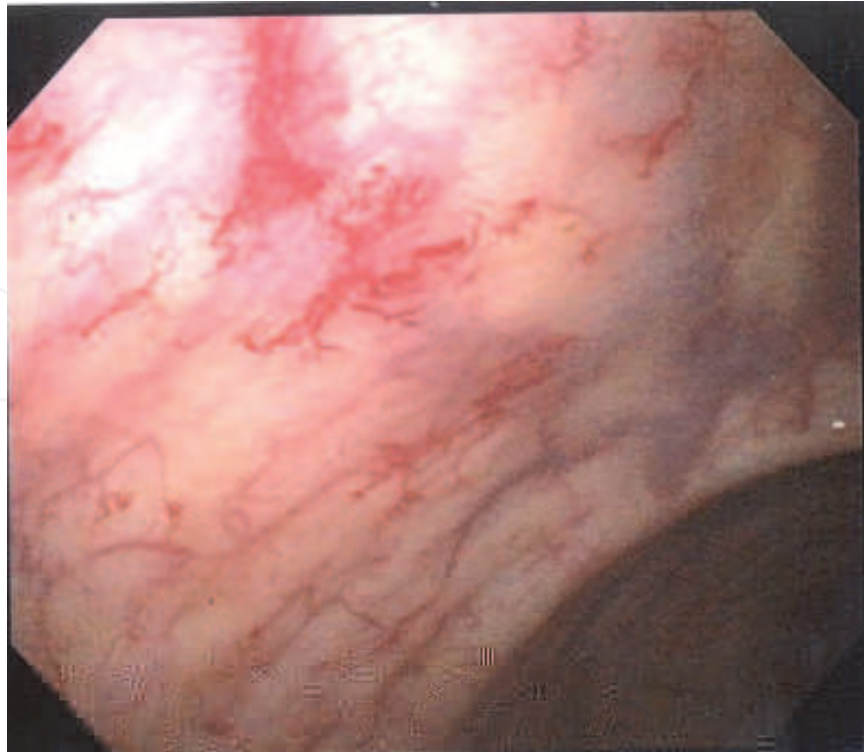


Fig. 1. Colonoscopy showing the presence of angiodysplasia.

follows: gel electrophoresis (most sensitive), PFA-100 closure time, skin bleeding time, vWF ristocetin cofactor activity and vWF antigen level (least sensitive).

So many authors nowadays affirm that Heyde syndrome refers to a triad of aortic stenosis, acquired coagulopathy (von Willebrand syndrome type IIA) and anemia due to bleeding from intestinal angiodysplasia or from an idiopathic site. (21)

The purpose of the present study is to evaluate the prevalence and the determinants of haemostatic abnormalities in patients with aortic stenosis and their clinical consequences.

2. Materials and methods

Between January 2005 and January 2009, 588 patients underwent aortic-valve replacement (AVR) for degenerative calcific aortic stenosis in our Institution.

312 patients (53%) underwent AVR alone, in 91 patients (15.6%) was associated a mitral valve procedure, and in 32.2% (188 patients) a concomitant coronary artery by-pass graft procedure was performed. 18 patients (3%) presented an history of haemorrhage, which causes seemed to be unexplained. We took into consideration this population that presented the association of gastrointestinal bleeding and severe aortic stenosis, in which we would hypothesised that an acquired von Willebrand syndrome could be present as a determinant of haemostatic abnormalities. Four (22%) of these 18 patients had an intestinal resection previous to cardiac surgery, with persisting gastrointestinal bleeding at six months after resection.

3. Screening bleeding diathesis

Only bleeding during the six months preceding evaluation was taken into account. Bleeding symptoms were evaluated by the use of a standardised screening questionnaire. The same evaluation was repeated six months postoperatively in the group positive for bleeding.

4. Echocardiographic evaluation

Using an HP Sonos 5500 echocardiographic system, an investigator assessed the haemodynamic performance of the aortic valve by transthoracic echocardiography at base line and at seven days and six months postoperatively. The mean and peak transvalvular pressure gradients were calculated with the modified Bernoulli equation, and the effective orifice area (EOA) was calculated by the continuity equation. At seven days and six months postoperatively, a mismatch between the patient and prosthesis was defined as an indexed EOA of less than 0.85 cm² per square meter of body-surface area. The echocardiographic data are presented in Table 1.

Variable	Severe Aortic Stenosis
Max Gradient(mmHg)	73.3 +/- 12.7
Effective orifice area (cm ²)	0.67 +/- 0.1
Indexed effective orifice area (cm ² /m ² of body surface area)	0.39 +/- 0.16
Ejection fraction (EF) %	55 +/- 7

Table 1. Mean (+/- SD) Echocardiographic data

5. Blood collection and laboratory assays

In patients with severe aortic stenosis associated to an history of haemorrhage, blood samples were collected the day before surgery, seven days, and six months after surgery. Plasma von Willebrand factor antigen was measured by immunoturbidimetry. Functional analysis of von Willebrand factor was performed by measuring its collagen-binding activity with an enzyme-linked immunosorbent assay,¹⁵ with the use of equine type 1 collagen (Horm, Nycomed). The ratio between collagen binding and von Willebrand factor antigen was calculated (the normal value is greater than 0.7).

Event	N° of patients
Epistaxis	12
Gingivorrhagia	14
Gastrointestinal Haemorrhage	16
Ecchymosis	6

Table 2. Hemorrhagic disorders

6. Results

Mean age were 75.5 years, 50% of patients were male; all patients were operated of AVR alone, mean effective orifice area was 0.67 cm², with an average maximum gradient of 73.3 mmHg +/- 12.7mmHg, and a mean ejection fraction (EF) of 55% +/-7.

6.1 Prevalence of pre-operative bleeding

18 patients of 588 (3%) had episodes of bleeding in the six months before surgery. Epistaxis occurred in 12 patients, gingivorrhagia in 14, gastrointestinal haemorrhage in 14, and 6 patients had episodes of spontaneous ecchymosis. 12 of 18 patients had an history of major bleeding (epistaxis, gastrointestinal) that needed transfusion.

6.2 Base-line biologic data

At base line, before operation, levels of von Willebrand factor antigen were normal in all patients (more than 0.5 IU per milliliter).

6.3 Surgical treatment

All patients received a biologic prosthesis porcine valve (Medtronic Hancock II) or a pericardial bioprosthesis (Edwards Magna). No mechanical prosthesis were implanted. Anticoagulant therapy for three months were given at 9 patients (50%), in the other 9 patients 100 mg per day of Acetylsalicylate Acid was started first, without anticoagulant.

7. Immediate postoperative results

The median blood loss 24 hours after valvular replacement was 550 ml (range, 250 to 2120). The postoperative blood loss in patients with preoperative history of bleeding was almost the same than in those without previous episodes. No patients underwent re-operation for bleeding after surgery. No patients died at 30 days follow up.

The levels of von Willebrand factor antigen were normal pre-operatively, at six days and at six months after surgery, in all patients examined.

7.1 Six months follow-up

All patients were analysed at six months follow-up. No valve stenosis or other valve malfunction that required reoperation were detected.

In no one patient was observed epistaxis or gastrointestinal haemorrhage or any other kind of bleeding episodes at six months follow-up. No valve mismatch between patients and prosthesis was observed. The platelet counts were normal, (except for the patient that had pre-operative trombocitemia). No correlation between type of prosthesis (pericardial or porcine) and changes in haemostatic values was found, and there was no effects correlated to the anticoagulant therapy which nine patients (50%) underwent for three months.

8. Discussion

The objective of this study was to evaluate the frequency and determinants of acquired von Willebrand syndrome in consecutive patients undergoing valve replacement for severe aortic stenosis presenting a concomitant history of bleeding. Investigation showed that bleeding (mostly from the gastrointestinal mucosa, or epistaxis) was present in about 3% percent of the patients with severe aortic stenosis, although some authors reported a strongly higher prevalence (up to 20%). (16)

Veyradier and colleagues have shown that vascular malformations, such as angiodysplasia, are at high risk of bleeding in patients with aortic stenosis, since effective haemostasis in these high-shear-stress lesions requires the presence of high-molecular-weight multimers of von Willebrand factor. (6) However we observed that von Willebrand factor abnormalities weren't present in our series, and there was no correlation with the pressure gradient and the stenosis-induced shear stress, indicating that von Willebrand factor abnormalities are not related to the severity of aortic stenosis. This disaccording with other authors that linked haemostatic defect to direct proteolysis of the largest multimers of von Willebrand factor. (16) We demonstrated that the relation between severe aortic stenosis and bleeding is present in a considerable quote of patients (3%).


In our series we used only biologic valve prosthesis, and no correlation between type of prosthesis (pericardial or porcine) and changes in haemostatic values was found. There was no effects correlated to the anticoagulant therapy which nine patients (50%) underwent for three months. As long as a mismatch between patient and prosthesis is avoided, whether mechanical prostheses can be safely implanted in patients who have a history of severe bleeding remains debatable. Additional studies are required to confirm that preoperative hemorrhagic syndrome does not have to be considered in deciding between a biologic and a mechanical valve substitute in patients with aortic stenosis.

In our series all patients had a surgical grade of stenosis, with high trans-valvular gradients, and the most important finding was that no one of them had higher surgical bleeding after valve replacement. We didn't notice a straight correlation between pre-operative and post-operative bleeding, but probably all patients with severe aortic stenosis without valve replacement are also at high risk for bleeding during noncardiac surgery. Those patients who have an history of bleeding, mostly from the gastrointestinal mucosa, or an history of epistaxis, have to sustain many admissions to the Hospital, with many exams or surgical operations to control bleeding and its complications. However, the therapeutic possibilities for the control of bleeding are limited. (17) At the present time, it is well accepted that patients with severe aortic stenosis who become symptomatic require aortic-valve replacement. (18) However, only cardiac symptoms are considered in the evaluation of the indications for valve replacement. (19) As suggested by some authors, the best correction for bleeding in those patients is probably achieved by valve replacement. (13) Further prospective studies are needed to determine whether haemostatic disturbances should be taken into account in the indications for valve replacement. Warkentin and colleagues recently reported long-lasting correction (lasting more than 10 years) of clinical and biologic hemostatic abnormalities in two patients who had undergone surgical treatment of severe aortic stenosis with acquired von Willebrand syndrome and bleeding. (20) In our patients no more episodes of bleeding were reported after surgery, even in the group with anticoagulants. In consideration of the very low mortality and morbidity of the procedure, and considering that at a six month follow-up all patients were still free from bleeding episodes, we consider that the best correction for bleeding in those patients is probably achieved by valve replacement.

9. References

- [1] Heyde EC. Gastrointestinal bleeding in aortic stenosis. *N Engl J Med* 1958;259:196-196.
- [2] Greenstein RJ, McElhinney AI, Reuben D, Greenstein AJ. Colonic vascular ectasias and aortic stenosis: coincidence or casual relationship? *Am J Surg* 1986;151:347-351.
- [3] King RM, Pluth JR, Giuliani ER. The association of unexplained gastrointestinal bleeding with calcific aortic stenosis. *Ann Thorac Surg* 1987;44:514-516.
- [4] Warkentin TE, Moore JC, Morgan DG. Aortic stenosis and bleeding gastrointestinal angiodysplasia: is acquired von Willebrand's disease the link? *Lancet* 1992;340:35-37.
- [5] Gill JC, Wilson AD, Endres-Brooks J, Montgomery RR. Loss of the largest von Willebrand factor multimers from the plasma of patients with congenital cardiac defects. *Blood* 1986;67:758-761.
- [6] Veyradier A, Balian A, Wolf M, et al. Abnormal von Willebrand factor in bleeding angiodysplasias of the digestive tract. *Gastroenterology* 2001;120:346-353.
- [7] Federici AB, Rand JH, Bucciarelli P, et al. Acquired von Willebrand syndrome: data from an international registry. *Thromb Haemost* 2000;84:345-349. [Erratum, *Thromb Haemost* 2000;84:739.]

- [8] Tsai HM, Sussman II, Nagel RL. Shear stress enhances the proteolysis of von Willebrand factor in normal plasma. *Blood* 1994;83:2171-2179.
- [9] Dent JA, Berkowitz SD, Ware J, Kasper CK, Ruggeri ZM. Identification of a cleavage site directing the immunochemical detection of molecular abnormalities in type IIA von Willebrand factor. *Proc Natl Acad Sci U S A* 1990;87:6306-6310.
- [10] Siediecki CA, Lestini BJ, Kottke-Marchant KK, Eppell SJ, Wilson DL, Marchant RE. Shear-dependent changes in the three-dimensional structure of human von Willebrand factor. *Blood* 1996;88:2939-2950.
- [11] Sugimoto M, Matsui H, Mizuno T, et al. Mural thrombus generation in type 2A and 2B von Willebrand disease under flow conditions. *Blood* 2003;101:915-920.
- [12] Cappell MS, Lebowitz O. Cessation of recurrent bleeding from gastrointestinal angiodysplasias after aortic valve replacement. *Ann Intern Med* 1986;105:54-57.
- [13] Anderson RP, McGrath K, Street A. Reversal of aortic stenosis, bleeding gastrointestinal angiodysplasia, and von Willebrand syndrome by aortic valve replacement. *Lancet* 1996;347:689-690.
- [14] Pareti FI, Lattuada A, Bressi C, et al. Proteolysis of von Willebrand factor and shear stress-induced platelet aggregation in patients with aortic valve stenosis. *Circulation* 2000;102:1290-1295.
- [15] Favalaro EJ, Henniker A, Facey D, Hertzberg M. Discrimination of von Willebrandt's disease (vWD) subtypes: direct comparison of von Willebrandt factor: collagen binding assay (VWF:CBA) with monoclonal antibody (MAB) based von Willebrandt factor-capture system. *Thromb Haemost* 2000;84:541-7.
- [16] Vincentelli A, Susen S, Le Tourneau T, Six I, Fabre Olivier, Juthier F, Bauters A, Decoene C, Goudemand J, Prat A, Jude B. Acquired von Willebrand Syndrome in aortic stenosis. *N Engl J Med*, July 24, 2003.
- [17] Veyradier A, Jenkins CS, Fressinaud E, Meyer D.: Acquired von Willebrand syndrome: from pathophysiology to management. *Thromb Haemost* 2000;84:175-82.
- [18] Carabello BA. Aortic stenosis. *N Engl J Med* 2002;346:677-82.
- [19] Bonow RO, Carabello B, de Leon AC, et al. ACC/AHA guidelines for the management of patients with valvular heart disease: executive summary: a report of the American College of Cardiology/American Heart Association Task Force on Practice Guidelines (Committee on Management of Patients with Valvular Heart Disease). *J Heart Valve Dis* 1998;7:672-707.
- [20] Warkentin TE, Moore JC, Morgan DG. Gastrointestinal angiodysplasia and aortic stenosis. *N Engl J Med* 2002;347:858-9.
- [21] Massyn M.W., Khan S.A., Heyde syndrome: a common diagnosis in older patients with severe aortic stenosis. *Age and ageing* 2009;38: 267-270.
- [22] Yoshida K, Tobe S., Kawata M, et al.: Acquired and reversible von Willebrand disease with high shear stress aortic valve stenosis. *Ann Thorac Surg* 2006;81:490-4.
- [23] Mehta PM, Heinsimer JA, Bryg RJ, et al. Reassessment of the association between gastrointestinal arteriovenous malformations and aortic stenosis. *Am J Med* 1989;86:275
- [24] Oneglia C, Sabatini T, Rusconi C, et al. Prevalence of aortic valve stenosis in patients affected by gastrointestinal angiodysplasia. *Eur J Med* 1993;2:75-8.
- [25] Bhutani MS, Gupta SC, Markert RJ, et al. A prospective controlled evaluation of endoscopic detection of angiodysplasia and its association with aortic valve disease. *Gastrointest Endosc* 1995;42:398-402.
- [26] Boss EG, Rosenbaum JM, Bleeding from the right colon associated with aortic stenosis. *Am J Dig Dis* 1971;16:269-75.



Aortic Stenosis - Etiology, Pathophysiology and Treatment

Edited by Dr. Masanori Hirota

ISBN 978-953-307-660-7

Hard cover, 254 pages

Publisher InTech

Published online 10, October, 2011

Published in print edition October, 2011

Currently, aortic stenosis (AS) is the most prevalent valvular disease in developed countries. Pathological and molecular mechanisms of AS have been investigated in many aspects. And new therapeutic devices such as transcatheter aortic valve implantation have been developed as a less invasive treatment for high-risk patients. Due to advanced prevalent age of AS, further discovery and technology are required to treat elderly patients for longer life expectancy. This book is an effort to present an up-to-date account of existing knowledge, involving recent development in this field. Various opinion leaders described details of established knowledge or newly recognized advances associated with diagnosis, treatment and mechanism. Thus, this book will enable close intercommunication to another field and collaboration technology for new devices. We hope that it will be an important source, not only for clinicians, but also for general practitioners, contributing to development of better therapeutic adjuncts in the future.

How to reference

In order to correctly reference this scholarly work, feel free to copy and paste the following:

Giampaolo Zoffoli, Domenico Mangino, Andrea Venturini, Angiolino Asta, Alberto Terrini, Chiara Zanchettin, Francesco Battaglia and Elvio Polesel (2011). Severe Calcific Aortic Valve Stenosis and Bleeding: Heyde's Syndrome, Aortic Stenosis - Etiology, Pathophysiology and Treatment, Dr. Masanori Hirota (Ed.), ISBN: 978-953-307-660-7, InTech, Available from: <http://www.intechopen.com/books/aortic-stenosis-etiology-pathophysiology-and-treatment/severe-calcific-aortic-valve-stenosis-and-bleeding-heyde-s-syndrome>

INTECH
open science | open minds

InTech Europe

University Campus STeP Ri
Slavka Krautzeka 83/A
51000 Rijeka, Croatia
Phone: +385 (51) 770 447
Fax: +385 (51) 686 166
www.intechopen.com

InTech China

Unit 405, Office Block, Hotel Equatorial Shanghai
No.65, Yan An Road (West), Shanghai, 200040, China
中国上海市延安西路65号上海国际贵都大饭店办公楼405单元
Phone: +86-21-62489820
Fax: +86-21-62489821

© 2011 The Author(s). Licensee IntechOpen. This is an open access article distributed under the terms of the [Creative Commons Attribution 3.0 License](#), which permits unrestricted use, distribution, and reproduction in any medium, provided the original work is properly cited.

IntechOpen

IntechOpen