

# We are IntechOpen, the world's leading publisher of Open Access books Built by scientists, for scientists

4,800

Open access books available

122,000

International authors and editors

135M

Downloads

Our authors are among the

154

Countries delivered to

TOP 1%

most cited scientists

12.2%

Contributors from top 500 universities



WEB OF SCIENCE™

Selection of our books indexed in the Book Citation Index  
in Web of Science™ Core Collection (BKCI)

Interested in publishing with us?  
Contact [book.department@intechopen.com](mailto:book.department@intechopen.com)

Numbers displayed above are based on latest data collected.  
For more information visit [www.intechopen.com](http://www.intechopen.com)



# Transcatheter Aortic Valve Implantation: New Hope for Inoperable and High-Risk Patients

Kentaro Hayashida and Thierry Lefèvre  
*Institut Cardiovasculaire Paris Sud, Massy,  
France*

## 1. Introduction

Calcified aortic stenosis is the most frequently reported valvular disease in our industrialized countries. This pathology is mainly observed in elderly patients with 3% prevalence after the age of 70.

As a result of increasing life expectancy and the post war baby boom phenomenon, we can expect a “granny and granddad boom” in the years to come. Without surgical aortic valve replacement (SAVR), the prognosis of severe symptomatic aortic stenosis (AS) is poor and is associated with a short life expectancy after symptom onset (Bonow, Carabello et al. 2008). Although SAVR has been regarded as the gold standard treatment for severe AS for several decades (Bonow, Carabello et al. 2006; Vahanian, Baumgartner et al. 2007), many patients do not undergo surgical treatment as this therapeutic option is deemed to carry excessive risk by the patient’s family or by his physician, cardiologist or even the surgeon because of advanced age and the presence of co-morbidities. Indeed, many studies have shown that 25% to 50% of symptomatic patients with severe AS do not receive surgical treatment. For instance, in the study by Lung et al. (Lung, Baron et al. 2003) 31.8% of eligible patients were not referred for SAVR.

Balloon valvuloplasty (BAV) was introduced by Cribier et al in 1986, to support the concept of mechanical dilatation of severely calcified aortic valve (Cribier, Savin et al. 1986) for inoperable patients. Despite initial improvement of symptoms observed immediately after the procedure (NHLBI Balloon Valvuloplasty Registry Participant. 1991), it was associated with high mortality, complication and recurrence rates (Safian, Berman et al. 1988). Because of its poor long term outcome (about 50% survival at 1 year and 20% at 3 years) (Otto, Mickel et al. 1994; Lieberman, Bashore et al. 1995), this procedure was performed in a dwindling number of cases, mainly as a bridge to SAVR in patients with poor hemodynamic status or in patients requiring urgent non cardiac surgery .

Percutaneous catheter-based systems for the treatment of aortic valve stenosis were assessed in experimental animal models (Andersen, Knudsen et al. 1992) for several years before Cribier et al successfully designed a percutaneous transcatheter implantation system for an aortic valve prosthesis. They reported their first human case in 2002 using an antegrade transseptal approach with local anesthesia and mild sedation (Cribier, Eltchaninoff et al. 2002). Subsequently, this system was developed by Edwards Lifesciences, for use via either a retrograde transfemoral approach (TF) with a new deflectable delivery system or a

transapical approach (TA). In 2004, Grube et al carried out the first-in-man percutaneous implantation of the CoreValve self-expanding valve prosthesis for severe AS and the initial experience of 25 cases was reported in 2005 (Grube, Laborde et al. 2006). Transcatheter aortic valve implantation (TAVI) is no longer an emerging technology for the treatment of patients with severe AS who are at high risk or ineligible for conventional surgery. It has become a valid treatment option addressing an unmet clinical need (Figure 1). TAVI and aortic valvuloplasty are now integrated into the potential therapeutic strategies applicable to patients with severe aortic stenosis carrying a high surgical risk and a heart team approach has become essential to implementing this procedure (Figure 2).

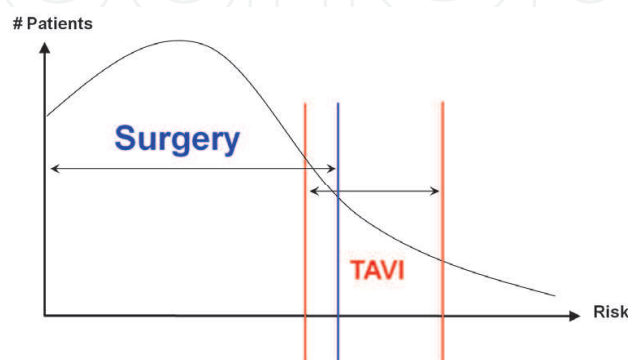


Fig. 1. TAVI addresses an unmet clinical need

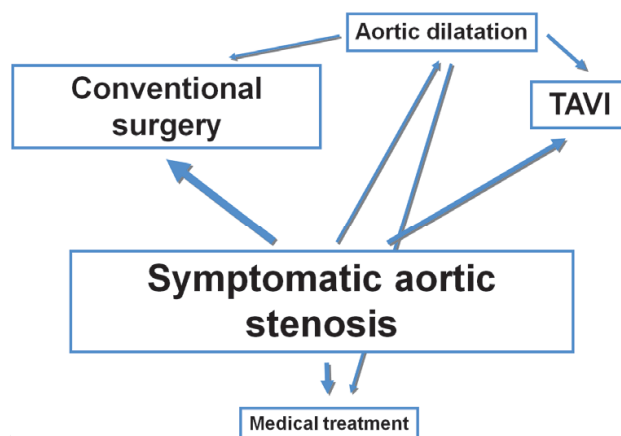


Fig. 2. Heart team approach is essential for TAVI

## 2. Clinical studies

### 2.1 Cribier-Edwards, Edwards-Sapien valve

The Edwards-Sapien (ES) valve is a trileaflet valve mounted on a balloon-expandable stent. The first-generation valve was made of polyurethane and the second-generation of bovine pericardium (Figure 3). After the pilot study involving six cases treated via the antegrade transvenous approach (Cribier, Eltchaninoff et al. 2004), initial feasibility studies (I-REVIVE and RECAST) were conducted in Rouen (Eltchaninoff, Tron et al. 2007) in 36 patients treated via both the antegrade and retrograde TF approaches. The retrograde delivery system was refined by Webb et al. and the results of the first 18 cases reported in 2006 showed improved procedural success and 30-day mortality (Webb, Chandavimol et al. 2006).



Fig. 3. The 1st generation Edwards valve  
Balloon expandable bioprosthesis  
Stainless steel  
23, 26 mm  
Bovine pericardium  
Thermafix preparation  
Flex delivery system  
Retrograde or Trans-apical approach  
22 or 24 Fr femoral sheath

The first procedure via the TA approach was performed in 2005 and the initial clinical experience was reported in 2006 (Lichtenstein, Cheung et al. 2006). CE Mark for both TF and TA delivery systems with the same valve was obtained for this device in 2007. In total, 9 clinical trials and registries were completed from first-in-man to CE Mark. After CE Mark approval, a post-market registry (SOURCE) was conducted in Europe (Thomas, Schymik et al. 2010; Wendler, Schymik et al. 2010). In the United States, the PARTNER US trial (an FDA approved, two-cohort, four-arm multicenter trial with the second-generation Edwards valve) was initiated in 2007, and the results obtained in cohort B demonstrated that TF-TAVI not only reduces dramatically the risk of death from any cause compared to standard therapy (Leon, Smith et al. 2010), but also improves significantly the quality of life. The results of cohort A comparing TF / TA-TAVI with SAVR met the primary endpoint of the study, demonstrating the noninferiority of TAVI compared to conventional aortic valve replacement in terms of all-cause mortality (Smith and Leon 2011). At 30 days, deaths from any cause were numerically lower in the TAVI group by intention to treat (3.4% vs 6.5%), however, this was not statistically significant. At one-year follow-up, the mortality rate in both groups was nearly identical (24.2% vs 26.8%). The PARTNER 2 trial which has a similar design is currently assessing the third-generation Edwards valve. A comparable study evaluating the Corevalve is about to start in the United States.

## 2.2 Medtronic CoreValve revalving system

The Medtronic CoreValve revalving system (Medtronic Inc., Minneapolis, MN, USA) is a trileaflet porcine pericardium valve mounted on a self-expanding nitinol frame. The first-in-man clinical feasibility study (n = 14) was performed in 2004 with the first generation 25-Fr device. From 2005 to 2006, consecutive safety and efficacy studies (n = 65) were conducted using the second-generation 21-Fr device. The third-generation device (Figure 4) was developed in order to provide a lower profile system (18-Fr), which received CE Mark in 2007 (Grube, Schuler et al. 2007; Piazza, Grube et al. 2008).



Fig. 4. The CoreValve Revalving™ System

Self-expandable bioprosthesis

Nitinol

26 and 29 mm

Porcine Péricardium

Retrograde approach

18 Fr sheath

## 3. Current devices and procedures

### 3.1 Edwards Sapien XT valve

#### 3.1.1 Design

The Edwards-Sapien valve has three bovine pericardium leaflets, mounted on a balloon-expandable tubular frame with high radial force in order to obtain uniform leaflet coaptation and to maintain an effective orifice area. As with all surgical Edwards bioprostheses, the leaflets are prepared using the Thermafix technology. The stent of the last generation, SAPIEN XT, is made of a cobalt-chromium alloy (Figure 5), and the delivery system (Novaflex) has been improved in order to reduce the profile to 18 Fr for the 23 mm valve and 19 Fr for the 26 mm valve (the former retroflex delivery system was 22 and 24 Fr, respectively). A 29 mm valve has been recently introduced (only for the TA approach in 2011) and a 20 mm valve will be available in the near future.

### 3.1.2 Procedures

The two main approaches for the Edwards Sapiens valve are the TF and TA routes. Careful screening of the ilio-femoral access by CT scan and/or selective ilio-femoral angiography from different orthogonal planes is crucial for optimal selection of the approach site. The decision to proceed with TF approach depends on minimal lumen diameter, calcification



Figure 5: The 2<sup>nd</sup> Generation Edwards: Sapiens XT valve :

Balloon expandable bioprosthesis

Cobalt chromium

23, 26, 29 mm

Bovine pericardium

Thermafix preparation

Novaflex delivery system

Retrograde and trans-apical approach

18 or 19 Fr femoral sheath

and tortuosity of ilio-femoral access, and presence of debris in the aorta. CT scan and/or transoesophageal echocardiography is an important part of the screening phase. The TA approach may be applied to patients with insufficient or risky vascular access. However, the presence of respiratory insufficiency or a hostile thorax must be taken into account. A novel, minimally invasive approach involving the direct puncture of the ascending aorta is currently being evaluated.

The TF approach requires arterial access via the femoral artery by insertion of the sheath using direct puncture or surgical cut-down of the common femoral artery. The Novaflex delivery system is advanced through the sheath into the aorta. The Sapien XT valve is then mounted on the balloon in the aorta, by pulling back the balloon underneath the valve. The system is advanced into the annulus position whilst avoiding direct contact with the aorta using the flex system. The valve position should subsequently be confirmed by aortography from perpendicular projection and the valve should be deployed under rapid pacing (180 to 240 beat/min.) in order to control blood pressure below 40 mmHg, and avoid migration of the valve during deployment. Closure of the femoral artery access is performed by ligation of the pre-deployed sutures of a Prostar XL device or two Proglide devices, or by surgical closure. In the early experience, surgical closure was adapted to the previously used 22- or 24-fr sheaths. Gradual sheath down-sizing contributed to the generalization of the "true percutaneous approach" using direct puncture of the femoral artery and closure with a suture-mediated device (Kahlert, Al-Rashid et al. 2009; Van Mieghem, Nuis et al. 2010; Hayashida, Lefevre et al. 2011) as well as the possibility of using local anesthesia.

TA-TAVI is performed using the current Ascendra 2 system inserted into the left ventricle (LV) via the apex. A double purse string is placed on the LV apex with mini anterior thoracotomy at the fifth or sixth intercostal space. The sheath is advanced into the LV cavity, followed by the insertion of the valve prosthesis after predilatation (Lichtenstein, Cheung et al. 2006). The valve is positioned under aortography guidance from a perpendicular projection and deployed with rapid pacing as in transfemoral procedures.

### **3.2 Medtronic CoreValve revalving system**

#### **3.2.1 Design**

The CoreValve revalving system is a self-expanding multilevel support frame with a tri-leaflet porcine pericardial tissue valve. A multilevel self-expandable Nitinol frame retains the tissue valve in place with high hoop strength. This high strength frame serves to preserve the anatomy of the valve, and stabilize the orifice area. The device is anchored by the high radial force area in the aortic annulus and by the low radial force area in the ascending aorta.

This device is currently available in sizes of 26 mm for annuli of between 20 and 23 mm, 29 mm for annuli between 23 and 27 mm. In the near future, a 32 mm valve will be available for annuli between 27 and 29 mm.

The delivery system is an over-the-wire catheter system. The distal part of the catheter has an 18-fr housing capsule which contains the valve prosthesis, and both sizes of bioprostheses can be accommodated by this delivery system. “The Accutrak delivery system” has been recently developed to reduce friction between the metal frame and the delivery system, thus preventing valve migration into the LV, and ensuring more accurate positioning of the bioprosthesis.

#### **3.2.2 Procedures**

This device can be implanted via three potential approaches: the TF, the transsubclavian, and the transaortic approaches.

Like the Sapien valve, the Corevalve can be implanted via the TF approach using an ilio-femoral vascular access. The delivery system is advanced over a stiff wire into the LV cavity, with subsequent slow release of the bioprosthesis by turning the microknob under fluoroscopic guidance. Several aortographies should be performed to ensure that the valve is positioned correctly during deployment.

The transsubclavian route is a potential alternative in cases where the femoral access is not sufficient. Surgical cut-down is performed for subclavian access, followed by sheath insertion into the ascending aorta. The delivery system is advanced to the aortic annulus as with the TF approach. This approach has been shown to be at least as safe as the TF approach in registries conducted in Italy and the UK (Petronio, De Carlo et al. 2010; Moynagh, Scott et al. 2011).

The transaortic approach is implemented in patients in whom no other access options are available (Latsios, Gerckens et al. 2010). This approach requires a mini-sternotomy, and direct puncture of the ascending aorta under visual and fluoroscopic guidance (Latsios, Gerckens et al. 2010). The rest of the procedure is similar to the TF approach.

The advantage of this self-expandable system is that it avoids traumatic dilatation of the annulus. The full retrievability of the bioprosthesis into the sheath is also advantageous in cases of valve migration before disconnection of the metal anchor of the frame from the delivery system. The relatively smaller delivery system is also beneficial for patients with a >21mm annulus (18 Fr in CoreValve vs 19 Fr in Sapien valve) and borderline ilio-femoral access.

## 4. Optimal patient selection

Patients with symptomatic severe AS are considered candidates for TAVI if they have a high logistic EuroSCORE (European System for Cardiac Operative Risk Evaluation score) or STS score (the Society of Thoracic Surgeons Score), or if surgery is deemed to be of excessive risk due to significant comorbidities, or if other risk factors not captured by these scoring systems (eg, porcelain aorta, severe thoracic distortion, severe liver disease, pre-dialysis renal insufficiency etc...) are present.

The decision to proceed with TAVI should be discussed by a dedicated heart team including cardiologists, interventional cardiologists, cardiovascular surgeons, anesthesiologists, and specialists in cardiac imaging. The role of geriatricians is crucial in borderline cases. The main concerns for optimal patient selection are: 1) annulus diameter of the native valve, 2) arterial access, and 3) diameter of the ascending aorta (Wenaweser and Windecker 2010).

### 4.1 Annulus diameter

#### 4.1.1 Annulus size to define a valve prosthesis size

Annulus size is a crucial parameter for selection of the appropriate type and size of valve. The annulus diameter criteria for Edwards valve are 18 to 21mm for the 23mm valve and 21 to 24.5mm for the 26mm device. In 2011, a 29mm valve covering 24.5 to 27mm annuli has been launched for the TA approach exclusively. The 20mm valve is currently being developed. For the CoreValve, a 26mm valve is used for 20 to 23mm annuli and a 29mm valve for 23 to 27mm annuli (Grube, Schuler et al. 2007). A 32mm valve should be available in the near future. All currently available valves can be used to treat most patients with annulus sizes ranging from 18 to 27 mm.

#### 4.1.2 Imaging modalities for annulus diameter measurement

Four modalities are available for measuring the aortic annulus: Transesophageal echocardiography (TEE), transthoracic echocardiography (TTE), invasive aortography and cardiac computed tomography (CT) scan (Wenaweser and Windecker 2010). TEE has been considered as the gold standard method for measuring the annulus size (Hutter, Opitz et al. 2010), due to its better imaging quality compared to TTE and lower degree of inter-observer variability, however it represents only 1 dimension in the antero-posterior view. TTE is mainly

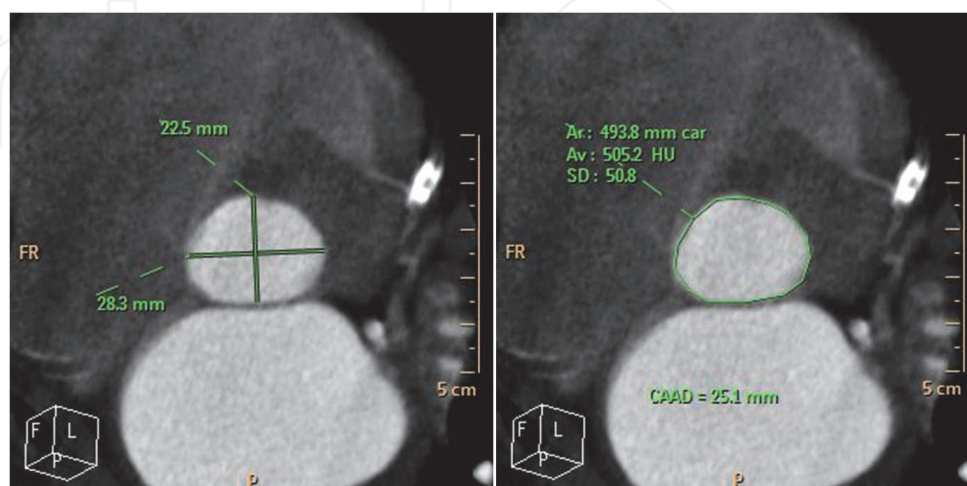


Fig. 6. MSCT and measurement of the annulus diameter



used for screening in order to exclude extremely small or large annuli or in instances where TEE is not applicable, due to its reduced imaging quality. Invasive aortography reflects the coronal view of the CT scan image. The fact that the aortic valve annulus is oval-shaped, rather than round-shaped must be taken into account when measuring the annulus size. CT scan is also a useful tool for measurement of the aortic annulus, providing appreciation of the oval shape of the annulus with high imaging quality. Due to its oval shape the annulus size measured by CT coronal view is larger than by sagittal view (Schultz, Moelker et al. 2010).

One solution would be to measure the circumference or the surface of the annulus and use the theoretical diameter deduced from this measurement for selection of the valve (Figure 6). TEE (Figure 7) or MSCT (Figure 8) assessment of the patient is essential in order to detect potential aortic debris which could preclude the use of the transfemoral route.

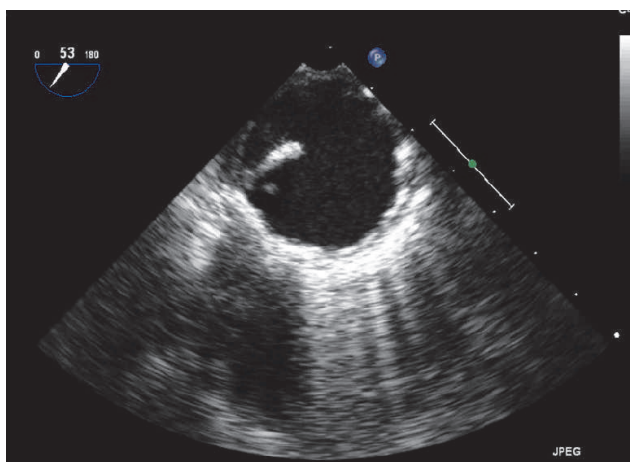


Fig. 7. Transoesophageal echocardiography and aortic debris

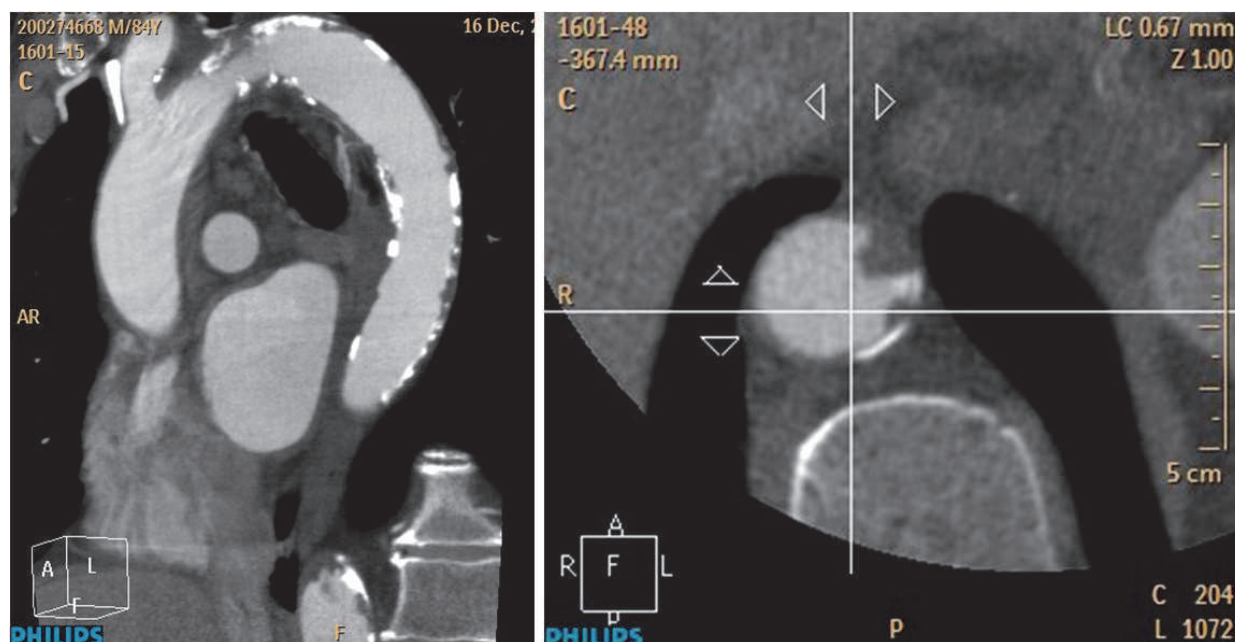


Fig. 8. MSCT and aortic debris

#### 4.2 Arterial access

The assessment of the ilio-femoral vessels can be performed by selective ilio-femoral angiography from 2 orthogonal planes, or multislice computed tomography (MSCT). Renal dysfunction is frequent in these patients and it is important not to cumulate several explorations requiring contrast media over a short period of time. For this reason we perform a selective angiogram of the ilio-femoral axes during coronary angiography. The radial approach is used preferentially in order to preserve any future femoral access for TAVI. MSCT is a useful tool for appraising the anatomy of the arterial access site. Such criteria as minimal lumen diameter (MLD), degree of calcification and tortuosity of the ilio-femoral access are essential in determining patient eligibility for the TF approach. We established that the ratio between “sheath outer diameter” and “MLD of femoral artery” (SFAR) predicts the occurrence of major vascular complications and the cut-point of this ratio which best predicts vascular complications (Table 1) is 1.05 (Hayashida, Lefevre et al. 2011). In non-calcified ilio-femoral vessels, the SFAR may be increased to 1.10 and conversely decreased to 1.00 in calcified arteries. Using this SFAR threshold, the minimal femoral artery diameter necessary for the 19 and 18 Fr introducer sheaths was calculated to be 6.8 and 6.5 mm respectively in non-calcified ilio-femoral vessels, and 7.5 and 7.2 mm respectively in calcified ilio-femoral vessels (Hayashida, Lefevre et al. 2011). While these measurements represent more restrictive criteria than previously recommended (Eltchaninoff, Kerkeni et al. 2009; Ducrocq, Francis et al. 2010; Tchetché, Dumonteil et al. 2010; Thomas, Schymik et al. 2010), alternative approaches (TA, transthoracic, transsubclavian or retroperitoneal) should be considered in patients with borderline femoral artery diameters following careful vascular screening with selective ilio-femoral angiography or, if possible, MSCT.

| Sheath/Femoral artery ratio (SFAR) | ≥ 1.05 (n = 55)   | < 1.05 (n = 72)   | p value           |
|------------------------------------|-------------------|-------------------|-------------------|
| <b>Any vascular complication</b>   | <b>23 (41.8%)</b> | <b>12 (16.7%)</b> | <b>&lt; 0.001</b> |
| <b>VARC Major</b>                  | <b>17 (30.9%)</b> | <b>5 (6.9%)</b>   | <b>0.001</b>      |
| VARC Minor                         | 6 (10.9%)         | 7 (9.7%)          | 0.827             |
| Femoral artery complication        | 15 (27.3%)        | 9 (12.5%)         | 0.035             |
| <b>Iliac artery complication</b>   | <b>11 (20.0%)</b> | <b>2 (2.8%)</b>   | <b>0.002</b>      |
| <b>30-day mortality</b>            | <b>10 (18.2%)</b> | <b>3 (4.2%)</b>   | <b>0.016</b>      |

Table 1. SFAR predict VARC major vascular complications

#### 4.3 Others

Dimensions beyond 45 mm are considered to be an indication for replacement of the ascending aorta and constitute, therefore, a contraindication for CoreValve implantation, as the upper part of the frame supports the stability of the bioprosthesis. Recent myocardial infarction, severe pulmonary dysfunction (avoiding thoracotomy and intubation), and the presence of apical thrombus are considered contraindications for TA-TAVI. A bicuspid aortic valve is also considered a relative contraindication for TAVI. However, the annulus

size and anatomy (eccentricity index) which can be accurately assessed by MSCT is more important than the bicuspidity itself and some patients have been successfully treated using the Edwards valve or Corevalve (Wijesinghe, Ye et al. 2010).

## **5. Complications, their management and avoidance**

Complications of TAVI can be classified as cardiac or non-cardiac. Appropriate patient selection, thorough knowledge of each device and well-mastered technique based on adequate experience are important to avoid these complications.

### **5.1 Cardiac complications**

#### **5.1.1 Aortic regurgitation**

##### **Acute aortic regurgitation**

It may occur after balloon dilatation. This relatively rare complication is poorly tolerated and may lead to cardiogenic shock within a few minutes, so it is crucial to identify the problem and implant the valve as soon as possible. For this reason, the valve should always be ready at the time of balloon predilatation.

##### **Paravalvular leak**

Though of no clinical consequence, minor paravalvular regurgitation is a common occurrence with current transcatheter valve devices. However, significant paravalvular regurgitation has been reported as an independent predictor of mortality between 30-day and 1-year in the Italian multicenter study of the CoreValve bioprosthesis (Tamburino, Capodanno et al. 2011). In the initial experience, significant paravalvular leaks were observed in many cases after implantation of the first-generation balloon-expandable bioprosthesis (Cribier, Eltchaninoff et al. 2002; Cribier, Eltchaninoff et al. 2004). However, the incidence of moderate to severe aortic regurgitation has been reduced in recipients of the Sapien or CoreValve bioprosthesis (Grube, Schuler et al. 2007; Walther, Simon et al. 2007; Webb, Pasupati et al. 2007) mainly by better screening of the annulus size and selection of over-sized valves. Low aortic diastolic pressure (40-50 mmHg) is the initial sign of significant aortic regurgitation. The causes of significant aortic regurgitation are; 1) undersizing of the valve due to underestimation of the annulus size, 2) incorrect positioning of the bioprosthesis, and 3) underexpansion of the valve. Bioprosthesis/annulus discordance was reported as an independent predictor of significant aortic regurgitation (Detaint, Lepage et al. 2009) thus annulus measurements and prosthesis sizing are critical in order to avoid post procedure paravalvular leak. Correct positioning of the bioprosthesis can be achieved with increasing experience and technical enhancement of the device. Adequate long time inflation of the balloon (approximately 5 seconds) is recommended in order to avoid underexpansion of the balloon-expandable bioprosthesis. Optimal evaluation of paravalvular leak immediately after valve implantation is essential in order to address this issue during the procedure. In cases of significant paravalvular leak, post balloon dilatation using the same balloon with an extra 1 or 2 cc can be a useful option. However, the long-term outcome of this procedure in terms of prosthesis durability is currently unknown.

#### **5.1.2 Valve malpositioning**

Valve positioning is one of the most challenging steps of the procedure, even with all necessary precautions and substantial operator experience. Valve migration after

deployment is generally the result of incorrect positioning or pacing failure leading to an effective ventricular contraction during deployment. In cases of valve migration into the aorta, the wire should be secured in order to keep the valve in a coaxial position and prevent it from flipping over and obstructing antegrade flow. The migrated valve can be positioned in the descending thoracic aorta by a partially inflated balloon or a goose-neck snare. However, care should be taken to avoid forceful repositioning of the valve as this may cause aortic dissection or rupture.

### **5.1.3 Coronary occlusion**

Coronary occlusion may occur due to the shifting of the bulky calcified native leaflet toward the left main ostium. The main predictors are a short distance between the annulus and left main ostium, and small dimension of the sinus of Valsalva. It may also occur due to an excessively high implantation of the CoreValve, though this is a rare occurrence (<1%) in recipients of the Sapien as well as the CoreValve (Piazza, Grube et al. 2008; Lefevre, Kappetein et al. 2010). For the Sapien valve, preventive protection of the coronary ostium with a coronary guidewire and guiding catheter during TAVI may be effective in the presence of bulky calcified leaflets. Even though the presence of open cells over a coronary ostium is well-tolerated, selective coronary cannulation may prove difficult because of the stent struts jailing the coronary ostium. Preprocedural cardiac CT scan or aortography with simultaneous balloon valvuloplasty may help to detect any potential risk of coronary occlusion. A >10 mm distance between the annulus and the left main is recommended in order to avoid this complication (Wenaweser and Windecker 2010).

### **5.1.4 Annulus and aortic root rupture**

Though rupture of the aortic annulus is an infrequently observed complication in TAVI (Himbert, Descoutures et al. 2009; Zajarias and Cribier 2009; Wendler, Schymik et al. 2010) as well as aortic valvuloplasty procedures (Hayes, Holmes et al. 1989), this complication (about 0.5%) can be fatal as it may rapidly result in cardiac tamponade and lead to catastrophic hemodynamic collapse in a few minutes. Excessive balloon dilatation, aggressive valve oversizing and extensive annular calcification may increase the incidence of this complication. Less aggressive balloon valvuloplasty and valve oversizing are recommended in the presence of markedly calcified annular and subannular tissues or an unusually small aortic root.

### **5.1.5 Heart block**

Atrioventricular (AV) block is a known complication of surgical aortic valve replacement (Dawkins, Hobson et al. 2008) which occurs in 4 to 8% of cases. Heart block can also occur after TAVI, presumably due to continuous compression of the conduction system located in the LV outflow tract and interventricular septum. After Edwards valve implantation, AV block occurs in 2 to 7% of cases, usually immediately after the procedure (Piazza, Onuma et al. 2008; Vahanian, Alfieri et al. 2008). As the occurrence of AV block may be transient, it is recommended that pacemaker placement should not be considered until after 24 hours.

The lower "skirt" structure of the CoreValve lies within the left ventricular outflow tract and exerts continuous pressure on the left bundle branch (Khawaja, Rajani et al. 2011), leading to a subsequent new onset of left bundle branch block. The risk of AV block extends beyond the procedure duration up to day 4. Temporary pacemaker should be secured for at

least 48 hours and continuous monitoring for 4 days is recommended in patients who have not received a permanent pacemaker. When AV Block occurs during the procedure after Corevalve implantation, it is not necessary to wait for potential recovery as pacemaker implantation is a definite indication in such cases. Previous studies have reported a higher incidence of permanent pacemaker (PPM) implantation in recipients of the CoreValve (18% to 40%) (Jilaihawi, Chin et al. 2009; Khawaja, Rajani et al. 2011) compared to the Sapien valve (1.8% and 7.0%) (Sinha, Altwegg et al. 2008; Godin, Eltchaninoff et al. 2010; Lefevre, Kappetein et al. 2010; Leon, Smith et al. 2010). Predictors of PPM requirement have been reported as periprocedural atrioventricular block, balloon predilatation, use of the larger (29 mm) CoreValve prosthesis, interventricular septum diameter, prolonged QRS duration in the UK collaborative study (Khawaja, Rajani et al. 2011) and pre-existing right bundle branch block (Piazza, Onuma et al. 2008; Roten, Wenaweser et al. 2011). The main predictor seems to be the level of implantation of the valve into the left ventricle.

Operators continue to endeavour to implant the valve in a relatively high position in order to reduce the risk of AVB. The new delivery system, Accutrak, should improve the accuracy of Corevalve deployment.

#### **5.1.6 Specific complications of TA approach**

Direct access to the left ventricle is obtained through an intercostal minithoracotomy and severe bleeding may occur at the end of the procedure. This seems to be related to technical problems during preparation of the access. Large deep stitches are recommended in order to avoid this problem. Apical pseudoaneurysm was reported as a specific complication of this approach (Masson, Kovac et al. 2009). Post procedural low-grade bleeding may result in cardiac tamponade and require further repair. Pleural effusion is also not uncommon. Mitral valve injury can also occur because of the nature of this procedure through the left ventricle. In some instances, the wire from the apex to the aorta can be pushed inadvertently behind the mitral chordae and create acute mitral regurgitation during manipulation of the introducer leading to cardiogenic shock. When identified, the problem is easily solved by pulling back the wire and rewiring the aorta whilst avoiding the mitral chordae.

### **5.2 Non-cardiac complications**

#### **5.2.1 Vascular complications**

Vascular complications are among the most frequent and serious complications of TF-TAVI, and have been associated with significantly increased patient morbidity and mortality (Webb, Chandavimol et al. 2006; Piazza, Grube et al. 2008; Rodes-Cabau, Webb et al. 2010). To date, vascular complications have been described in 8%-30.7% of Edwards valve recipients (Webb, Altwegg et al. 2009; Ducrocq, Francis et al. 2010; Lefevre, Kappetein et al. 2010; Leon, Smith et al. 2010; Rodes-Cabau, Webb et al. 2010; Tchetché, Dumonteil et al. 2010; Thomas, Schymik et al. 2010), and 1.9%-16% of CoreValve patients (Piazza, Grube et al. 2008; Bleiziffer, Ruge et al. 2009; Tchetché, Dumonteil et al. 2010; Van Mieghem, Nuis et al. 2010). In an effort to standardize the reporting of TAVI data, the Valve Academic Research Consortium (VARC) has recently developed a consensus on TAVI-related endpoints (Leon, Piazza et al. 2011), including a uniform definition of vascular complications. In our prospective series of TF-TAVI patients (85% Edwards and 15% Corevalve), we observed a vascular complication rate of 27.6% (VARC definition), including major vascular complications in 17.3% (Hayashida, Lefevre et al. 2011). We also found that

the occurrence of major vascular complications was a strong predictor of 30-day mortality (multiplying the risk of 30-day death by 4) and that major vascular complications were predicted by SFAR, center experience and the presence of femoral calcifications (Hayashida, Lefevre et al. 2011). Iliac perforation is a more severe potential vascular complication of TF-TAVI, because it may lead to retroperitoneal hemorrhage and hemodynamic collapse. In our study, all iliac complications were classified as VARC major complications (Hayashida, Lefevre et al. 2011). Careful screening of vascular access and multimodality approach is crucial for selection of vascular access for TAVI. With technological advances, down-sizing of the device should be associated with further reductions in the risk of vascular complications in the future.

### 5.2.2 Cerebro-vascular complications

The incidence of clinically apparent cerebrovascular embolism (CE) complicated by TAVI is reported to be between 1.7% and 6.9% (Grube, Schuler et al. 2007; Webb, Pasupati et al. 2007; Webb, Altwegg et al. 2009; Rodes-Cabau, Webb et al. 2010; Thomas, Schymik et al. 2010). Two reports described a lower incidence of clinically apparent stroke in patients undergoing TA-TAVI compared to those with TF-TAVI (Bleiziffer, Ruge et al. 2009; Himbert, Descoutures et al. 2009). However, these findings have not been confirmed by other large studies (Table 2) including both TF and TA approaches (Webb, Altwegg et al. 2009; Kahlert, Knipp et al. 2010; Rodes-Cabau, Webb et al. 2010; Thomas, Schymik et al. 2010).

| Studies                                   | Stroke rate (%) | Studies                       | Stroke rate (%) |
|---|-----------------|-------------------------------|-----------------|
| PARTNER EU TF                             | 3.2             | FRANCE Corevalve              | 4.5             |
| PARTNER EU TA                             | 2.9             | Belgian Registry<br>Corevalve | 3.4             |
| SOURCE TF                                 | 2.4             | German Registry<br>Corevalve  | 2.6             |
| SOURCE TA                                 | 2.6             | UK Registry Corevalve         | 4.0             |
| FRANCE TA                                 | 2.8             | Italian Registry<br>Corevalve | 1.7             |
| FRANCE TF                                 | 4.2             | <b>AVR high-risk*</b>         | <b>2.8</b>      |
| PARTNER US<br>Belgian Registry<br>Edwards | 6.9<br>3.1      |                               |                 |

Table 2. Risk of Stroke after TAVI procedures

In a study using diffusion-weighted magnetic resonance imaging (DW-MRI), TF-TAVI was associated with >70% incidence of new cerebral lesions following the procedure (Ghanem, Muller et al. 2010; Kahlert, Knipp et al. 2010) and there was also no difference between the TF and TA approaches (Rodes-Cabau, Webb et al. 2010). There are further data allowing comparison between TAVI and conventional SAVR (Kahlert, Knipp et al. 2010). Indeed, one report showed that despite a higher incidence of new foci of DW-MRI in the TAVI group (84% vs 48%,  $p = 0.011$ ), the volumes of these lesions were significantly smaller after TAVI than after SAVR and no differences in clinically apparent stroke were evidenced. (Kahlert, Knipp et al. 2010). In the PARTNER US trial, a significant increase in any stroke was observed (5.5 vs 2.4%,  $p=0.04$ ), but the combined endpoint of death or stroke at one year

were similar (26.5 vs 28.0% respectively). The etiologies of procedural stroke are likely to be atheroembolism from the ascending aorta or the aortic arch, calcific embolism from the aortic valve, thromboembolism from catheters, air embolism from LV cannulation, and prolonged hypotension. Repeated or overly aggressive valvuloplasty may be associated with an increased risk of embolization of calcific material from the aortic valve (Isner 1991) and should be avoided.

### 5.2.3 Acute kidney injury

Renal function and the development of acute kidney injury (AKI) are important factors influencing the outcome of patients after invasive procedures, such as percutaneous coronary intervention or cardiac surgery (Chertow, Levy et al. 1998; Lok, Austin et al. 2004). AKI has been observed in 12% to 28% of patients undergoing TAVI and is associated with a 4-fold increase in post-procedural mortality (Aregger, Wenaweser et al. 2009; Bagur, Webb et al. 2010; Sinning, Ghanem et al. 2010). AKI after TAVI is related to an increased mortality risk in the short and mid-term, independent of whether renal function returns to baseline or not (Sinning, Ghanem et al. 2010). Although the mechanism of AKI after TAVI remains unknown, pre- and post-procedural impaired hemodynamics and hypotension caused by low ejection fraction, valvuloplasty and valve deployment, embolization of aortic debris during catheter manipulation, and amount of contrast media in these patients with poor renal function may be among the main causes.

## 6. Patient outcomes

Procedural success rates have steadily improved from 82% (Cribier, Eltchaninoff et al. 2006) in the initial antegrade approach to more than 95% in recent reports of both available bioprostheses (Coeytaux, Williams et al. 2010; Yan, Cao et al. 2010).

These data show that the procedure of TAVI is now reaching relative maturity.

A review of the literature involving 84 reports on both bioprostheses, showed an overall 30-day survival rate of 89% (Coeytaux, Williams et al. 2010). In the early reports of TAVI, 30-day survival was around 50-60% in recipients of the Edwards valve (Cribier, Eltchaninoff et al. 2004; Cribier, Eltchaninoff et al. 2006). Increased operator experience and device enhancement may account for the recent improvements in the outcome of TAVI patients. In patients implanted with the Sapien valve, 30-day survival is currently between 88 and 94% via the TF approach (Webb, Pasupati et al. 2007; Lefevre, Kappetein et al. 2010; Rodes-Cabau, Webb et al. 2010; Thomas, Schymik et al. 2010) and 81% to 92% via the TA route (Walther, Simon et al. 2007; Walther, Falk et al. 2008; Lefevre, Kappetein et al. 2010; Thomas, Schymik et al. 2010).

In recipients of the CoreValve via the TF approach, 30-day survival is 89 to 93% (Grube, Buellesfeld et al. 2008; Piazza, Grube et al. 2008; Piazza, van Gameren et al. 2009; Tamburino, Capodanno et al. 2011). It is noteworthy that the recent publication of 2 registries conducted in the UK and Italy in patients who underwent transsubclavian-TAVI using the CoreValve showed excellent short-term survival of 100% (Petronio, De Carlo et al. 2010; Moynagh, Scott et al. 2011). These results require further confirmation in large prospective and controlled registries.

The predictors of 30-day mortality are identified as logistic EuroSCORE, experience, low left ventricular ejection fraction, need for hemodynamic support during the procedure,

conversion to open heart surgery, cardiac tamponade, major vascular complication, acute kidney injury and diabetes mellitus, (Wendler, Walther et al. 2010; Tamburino, Capodanno et al. 2011)

Survival rates at 1 year ranging from 69 to 85% have been reported (Webb, Altwegg et al. 2009; Coeytaux, Williams et al. 2010; Lefevre, Kappetein et al. 2010; Leon, Smith et al. 2010; Sinning, Ghanem et al. 2010; Yan, Cao et al. 2010). The predictors of late mortality are mainly related to comorbidities and reported as logistic EuroSCORE, STS score, age, severe mitral regurgitation, anemia, prior stroke, pulmonary disease, pulmonary hypertension, post procedural paravalvular leak  $\geq 2$ , and chronic kidney disease (Walther, Simon et al. 2007; Piazza, Grube et al. 2008; Himbert, Descoutures et al. 2009; Leon, Smith et al. 2010; Rodes-Cabau, Webb et al. 2010; Sinning, Ghanem et al. 2010).

## 7. Valve performance

The hemodynamic performance of the valve is very promising and seems so be superior to surgical valves with a lower gradient and larger valve area. In the cohort A of the PARTNER US trial (21) the valve area was  $1.4 \pm 0.5$  in the SAVR group compared to  $1.6 \pm 0.5$  ( $p=0.004$ ) in the TAVI group. Paravalvular leak remains a problem which should be solved in the future. Mild to moderate aortic regurgitation was observed in 12% of cases in this study.

## 8. Future perspectives

### 8.1 Wider application of TAVI

Until now, the indications for TAVI have been symptomatic severe AS with a EuroSCORE  $>20\%$ , STS score  $>10\%$  or instances where surgery is deemed to carry excessive risk due to significant comorbidities or contraindications. Recently, the results of the cohort B of the PARTNER US trial have demonstrated that, compared to standard medical therapy, TF-TAVI using the Sapien valve significantly reduces the rates of death from any cause and repeat hospitalization (Leon, Smith et al. 2010). In this landmark study, TAVI treatment of 5 patients resulted in one life being saved at one-year follow-up compared to medical treatment. The fact that one life was saved out of 5 patients treated is unparalleled in the history of medicine.

The benefit of TAVI in terms of mortality was observed in all predefined subgroups (Figure 9). Quality of life was also dramatically improved, as shown in Figure 10. Cohort A of this study comparing TF-TAVI vs conventional surgical aortic valve replacement (SAVR), and TA-TAVI vs SAVR has been recently published (Smith and Leon 2011) and demonstrated the noninferiority of TAVI compared to conventional aortic valve replacement in terms of all-cause mortality in high-risk patients. With respect to the CoreValve, SURTAVI, a multicenter, randomized clinical trial comparing the CoreValve with SAVR in patients with "intermediate" risk will start enrolling patients in Europe in 2011. PARTNER 2 will also explore the outcome of the third-generation Edwards valve in patients with intermediate risk in the United States.

### 8.2 Valve in valve technique

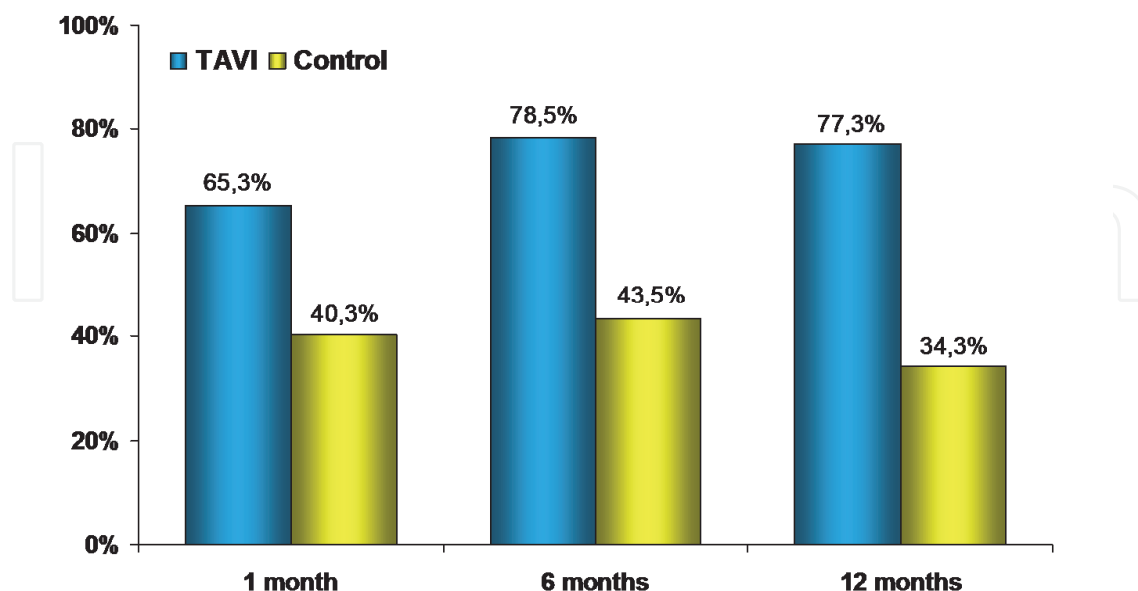
Percutaneous treatment of degenerated bioprostheses (Klaaborg, Egeblad et al. 2009; Webb, Wood et al. 2010) in patients at high risk for repeat surgery is currently being evaluated and seems very promising (Figure 11).



| Subgroup                    | TAVI (%)<br>n=179 | Standard Rx (%)<br>n=179 | RR (95% CI) | RR (95% CI)       | NNT | P interaction |
|-----------------------------|-------------------|--------------------------|-------------|-------------------|-----|---------------|
| Overall                     | 30.7              | 49.7                     |             | 0.62 (0.47, 0.81) | 5   |               |
| Age < 85                    | 29.2              | 51.1                     |             | 0.57 (0.39, 0.83) | 5   |               |
| Age > 85                    | 32.5              | 48.3                     |             | 0.67 (0.46, 0.98) | 6   | 0.54          |
| Female gender               | 30.9              | 48.4                     |             | 0.64 (0.44, 0.92) | 6   |               |
| Male gender                 | 30.5              | 51.2                     |             | 0.60 (0.40, 0.88) | 5   | 0.80          |
| Body-mass Index <25         | 38.6              | 52.9                     |             | 0.73 (0.52, 1.02) | 7   |               |
| Body-mass index >25         | 24.0              | 46.7                     |             | 0.51 (0.34, 0.78) | 4   | 0.20          |
| STS score <11               | 23.7              | 42.1                     |             | 0.56 (0.36, 0.88) | 5   |               |
| STS score >11               | 38.4              | 54.9                     |             | 0.70 (0.51, 0.96) | 6   | 0.44          |
| LV ejection fraction < 55   | 36.6              | 61.1                     |             | 0.60 (0.43, 0.83) | 4   |               |
| LV ejection fraction >55    | 26.4              | 36.4                     |             | 0.73 (0.46, 1.14) | 10  | 0.50          |
| Pulmonary hypertension      | 26.1              | 45.5                     |             | 0.57 (0.36, 0.92) | 5   |               |
| No pulmonary hypertension   | 35.4              | 49.4                     |             | 0.72 (0.50, 1.03) | 7   | 0.47          |
| Mitral regurgitation ≥3+    | 32.3              | 46.5                     |             | 0.70 (0.51, 0.95) | 7   |               |
| Mitral regurgitation <3     | 23.7              | 60.5                     |             | 0.39 (0.21, 0.73) | 3   | 0.09          |
| Severe COPD                 | 29.1              | 48.1                     |             | 0.60 (0.44, 0.83) | 5   |               |
| No severe COPD              | 36.8              | 54.3                     |             | 0.68 (0.41, 1.11) | 6   | 0.70          |
| Prior CABG or PCI           | 27.8              | 47.1                     |             | 0.59 (0.38, 0.93) | 5   |               |
| No prior CABG or PCI        | 27.4              | 54.3                     |             | 0.50 (0.34, 0.75) | 4   | 0.60          |
| Peripheral vascular disease | 28.2              | 52.2                     |             | 0.54 (0.39, 0.75) | 4   |               |
| No peripheral vasc. Disease | 37.0              | 42.2                     |             | 0.88 (0.54, 1.43) | 19  | 0.10          |

The consensus on TAVI-related endpoints published by the Valve Academic Research Consortium (VARC) (Leon, Piazza et al. 2011) should be useful for comparing new studies.

Fig. 9. All-cause mortality in PARTNER US (Subgroup Analysis)



\* Improvement  $\geq 10$  points vs. baseline using Kansas City Cardiomyopathy Questionnaire

Fig. 10. Quality of life Improvement in PARTNER US\*

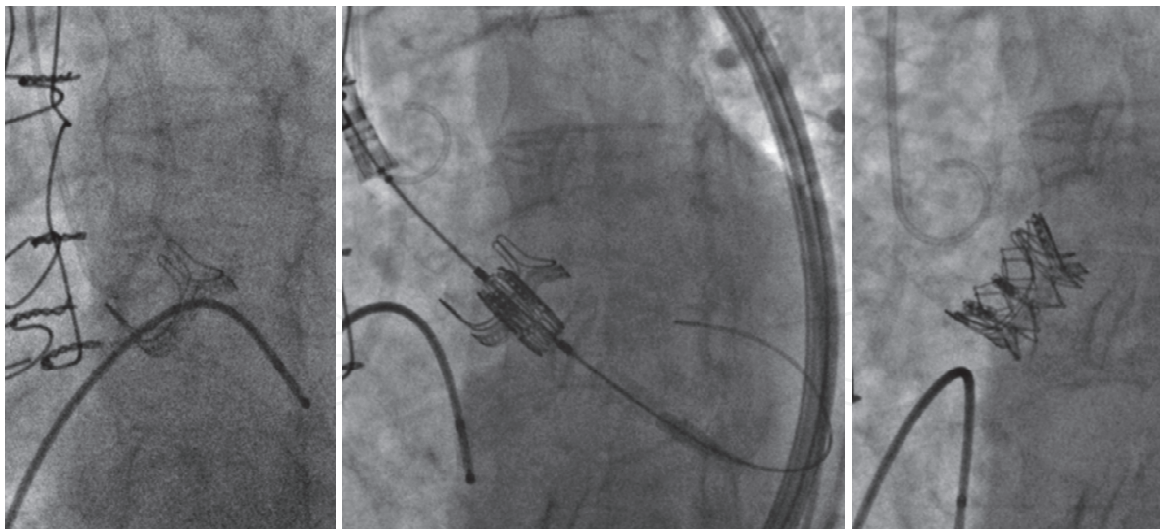


Fig. 11. Valve in valve technique

This new approach is likely to bring radical changes to the management of our patients in the years to come regarding which type of valve should be selected (mechanical or bioprosthesis) for conventional surgery. Indeed, the possibility of implanting a percutaneous valve in patients who have already received a surgical bioprosthesis may become a valid option. Currently, surgical bioprostheses have a 15- to 20-year durability.

### 8.3 New devices

A number of new devices are currently undergoing early clinical evaluation. The main improvement axes for enhancement of transcatheter valve technology are reduction in the delivery catheter size, a decrease in risks of paravalvular leaks, as well as facilitation of accurate positioning and retrieval (Low, Bolling et al. 2008; Schofer, Schluter et al. 2008; Falk, Schwammenthal et al. 2009; Treede, Tubler et al. 2010). The Sadra Lotus valve (Boston Scientific, USA), Direct Flow (Direct Flow Medical, USA), JenaClip (JenaValve, Germany), Engager (Medtronic, USA), St Jude (St Jude Medical, USA), Directflow and Symetis are examples of new valves. Although these valves have been the object of initial animal and even clinical studies, further evaluations in larger multicenter trials are needed.

## 9. Conclusion

The objective of this review was to describe state-of-the-art TAVI, as well as future perspectives. TAVI procedures are being carried out worldwide with encouraging results and reduced procedural risk and mortality. Although long-term data are required, short- and mid-term outcome of TAVI is comparable with that of conventional surgery in high-risk AS patients. As a result of increased experience and enhanced technology, TAVI is currently emerging as a new hope in our aging society for the growing number of elderly patients with severe AS.

## 10. Acknowledgments

The authors would like to thank Mrs. Catherine Dupic for her assistance in the preparation of this manuscript.

## 11. Disclosures

Dr T. Lefèvre is proctor for Edwards TAVI.

## 12. Reference


- Andersen, H. R., L. L. Knudsen, et al. (1992). "Transluminal implantation of artificial heart valves. Description of a new expandable aortic valve and initial results with implantation by catheter technique in closed chest pigs." *Eur Heart J* 13(5): 704-8.
- Aregger, F., P. Wenaweser, et al. (2009). "Risk of acute kidney injury in patients with severe aortic valve stenosis undergoing transcatheter valve replacement." *Nephrol Dial Transplant* 24(7): 2175-9.
- Bagur, R., J. G. Webb, et al. (2010). "Acute kidney injury following transcatheter aortic valve implantation: predictive factors, prognostic value, and comparison with surgical aortic valve replacement." *Eur Heart J* 31(7): 865-74.
- Bleiziffer, S., H. Ruge, et al. (2009). "Survival after transapical and transfemoral aortic valve implantation: talking about two different patient populations." *J Thorac Cardiovasc Surg* 138(5): 1073-80.
- Bonow, R. O., B. A. Carabello, et al. (2008). "2008 focused update incorporated into the ACC/AHA 2006 guidelines for the management of patients with valvular heart disease: a report of the American College of Cardiology/American Heart Association Task Force on Practice Guidelines (Writing Committee to revise the 1998 guidelines for the management of patients with valvular heart disease). Endorsed by the Society of Cardiovascular Anesthesiologists, Society for Cardiovascular Angiography and Interventions, and Society of Thoracic Surgeons." *J Am Coll Cardiol* 52(13): e1-142.
- Bonow, R. O., B. A. Carabello, et al. (2006). "ACC/AHA 2006 guidelines for the management of patients with valvular heart disease: a report of the American College of Cardiology/American Heart Association Task Force on Practice Guidelines (writing committee to revise the 1998 Guidelines for the Management of Patients With Valvular Heart Disease): developed in collaboration with the Society of Cardiovascular Anesthesiologists: endorsed by the Society for Cardiovascular Angiography and Interventions and the Society of Thoracic Surgeons." *Circulation* 114(5): e84-231.
- Chertow, G. M., E. M. Levy, et al. (1998). "Independent association between acute renal failure and mortality following cardiac surgery." *Am J Med* 104(4): 343-8.
- Coeytaux, R. R., J. W. Williams, Jr., et al. (2010). "Percutaneous heart valve replacement for aortic stenosis: state of the evidence." *Ann Intern Med* 153(5): 314-24.
- Cribier, A., H. Eltchaninoff, et al. (2002). "Percutaneous transcatheter implantation of an aortic valve prosthesis for calcific aortic stenosis: first human case description." *Circulation* 106(24): 3006-8.
- Cribier, A., H. Eltchaninoff, et al. (2006). "Treatment of calcific aortic stenosis with the percutaneous heart valve: mid-term follow-up from the initial feasibility studies: the French experience." *J Am Coll Cardiol* 47(6): 1214-23.
- Cribier, A., H. Eltchaninoff, et al. (2004). "Early experience with percutaneous transcatheter implantation of heart valve prosthesis for the treatment of end-stage inoperable patients with calcific aortic stenosis." *J Am Coll Cardiol* 43(4): 698-703.

- Cribier, A., T. Savin, et al. (1986). "Percutaneous transluminal valvuloplasty of acquired aortic stenosis in elderly patients: an alternative to valve replacement?" *Lancet* 1(8472): 63-7.
- Dawkins, S., A. R. Hobson, et al. (2008). "Permanent pacemaker implantation after isolated aortic valve replacement: incidence, indications, and predictors." *Ann Thorac Surg* 85(1): 108-12.
- Detaint, D., L. Lepage, et al. (2009). "Determinants of significant paravalvular regurgitation after transcatheter aortic valve: implantation impact of device and annulus discongruence." *JACC Cardiovasc Interv* 2(9): 821-7.
- Ducrocq, G., F. Francis, et al. (2010). "Vascular complications of transfemoral aortic valve implantation with the Edwards SAPIEN prosthesis: incidence and impact on outcome." *EuroIntervention* 5(6): 666-72.
- Eltchaninoff, H., M. Kerkeni, et al. (2009). "Aorto-iliac angiography as a screening tool in selecting patients for transfemoral aortic valve implantation with the Edwards SAPIEN bioprosthesis." *EuroIntervention* 5(4): 438-42.
- Eltchaninoff, H., C. Tron, et al. (2007). "[Aortic bioprosthesis implanted percutaneously: three year follow up]." *Arch Mal Coeur Vaiss* 100(11): 901, 904-8.
- Falk, V., E. E. Schwammenthal, et al. (2009). "New anatomically oriented transapical aortic valve implantation." *Ann Thorac Surg* 87(3): 925-6.
- Ghanem, A., A. Muller, et al. (2010). "Risk and fate of cerebral embolism after transfemoral aortic valve implantation: a prospective pilot study with diffusion-weighted magnetic resonance imaging." *J Am Coll Cardiol* 55(14): 1427-32.
- Godin, M., H. Eltchaninoff, et al. (2010). "Frequency of conduction disturbances after transcatheter implantation of an Edwards Sapien aortic valve prosthesis." *Am J Cardiol* 106(5): 707-12.
- Grube, E., L. Buellesfeld, et al. (2008). "Progress and current status of percutaneous aortic valve replacement: results of three device generations of the CoreValve Revalving system." *Circ Cardiovasc Interv* 1(3): 167-75.
- Grube, E., J. C. Laborde, et al. (2006). "Percutaneous implantation of the CoreValve self-expanding valve prosthesis in high-risk patients with aortic valve disease: the Siegburg first-in-man study." *Circulation* 114(15): 1616-24.
- Grube, E., G. Schuler, et al. (2007). "Percutaneous aortic valve replacement for severe aortic stenosis in high-risk patients using the second- and current third-generation self-expanding CoreValve prosthesis: device success and 30-day clinical outcome." *J Am Coll Cardiol* 50(1): 69-76.
- Hayashida, K., T. Lefevre, et al. (2011). "Transfemoral Aortic Valve Implantation: New Criteria to Predict Vascular Complications." *J. Am. Coll. Cardiol. Interv.* in press.
- Hayes, S. N., D. R. Holmes, Jr., et al. (1989). "Palliative percutaneous aortic balloon valvuloplasty before noncardiac operations and invasive diagnostic procedures." *Mayo Clin Proc* 64(7): 753-7.
- Himbert, D., F. Descoutures, et al. (2009). "Results of transfemoral or transapical aortic valve implantation following a uniform assessment in high-risk patients with aortic stenosis." *J Am Coll Cardiol* 54(4): 303-11.
- Hutter, A., A. Opitz, et al. (2010). "Aortic annulus evaluation in transcatheter aortic valve implantation." *Catheter Cardiovasc Interv* 76(7): 1009-19.

- Isner, J. M. (1991). "Acute catastrophic complications of balloon aortic valvuloplasty. The Mansfield Scientific Aortic Valvuloplasty Registry Investigators." *J Am Coll Cardiol* 17(6): 1436-44.
- Iung, B., G. Baron, et al. (2003). "A prospective survey of patients with valvular heart disease in Europe: The Euro Heart Survey on Valvular Heart Disease." *Eur Heart J* 24(13): 1231-43.
- Jilaihawi, H., D. Chin, et al. (2009). "Predictors for permanent pacemaker requirement after transcatheter aortic valve implantation with the CoreValve bioprosthesis." *Am Heart J* 157(5): 860-6.
- Kahlert, P., F. Al-Rashid, et al. (2009). "Vascular access site complications after percutaneous transfemoral aortic valve implantation." *Herz* 34(5): 398-408.
- Kahlert, P., S. C. Knipp, et al. (2010). "Silent and apparent cerebral ischemia after percutaneous transfemoral aortic valve implantation: a diffusion-weighted magnetic resonance imaging study." *Circulation* 121(7): 870-8.
- Khawaja, M. Z., R. Rajani, et al. (2011). "Permanent Pacemaker Insertion After CoreValve Transcatheter Aortic Valve Implantation: Incidence and Contributing Factors (the UK CoreValve Collaborative)." *Circulation* 123(9): 951-60.
- Klaaborg, K. E., H. Egeblad, et al. (2009). "Transapical transcatheter treatment of a stenosed aortic valve bioprosthesis using the Edwards SAPIEN Transcatheter Heart Valve." *Ann Thorac Surg* 87(6): 1943-6.
- Latsios, G., U. Gerckens, et al. (2010). "Transaortic transcatheter aortic valve implantation: a novel approach for the truly "no-access option" patients." *Catheter Cardiovasc Interv* 75(7): 1129-36.
- Lefevre, T., A. P. Kappetein, et al. (2010). "One year follow-up of the multi-centre European PARTNER transcatheter heart valve study." *Eur Heart J* 32(2): 148-57.
- Lefevre, T., A. P. Kappetein, et al. (2010). "One year follow-up of the multi-centre European PARTNER transcatheter heart valve study." *Eur Heart J*.
- Leon, M. B., N. Piazza, et al. (2011). "Standardized endpoint definitions for transcatheter aortic valve implantation clinical trials a consensus report from the valve academic research consortium." *J Am Coll Cardiol* 57(3): 253-69.
- Leon, M. B., C. R. Smith, et al. (2010). "Transcatheter aortic-valve implantation for aortic stenosis in patients who cannot undergo surgery." *N Engl J Med* 363(17): 1597-607.
- Lichtenstein, S. V., A. Cheung, et al. (2006). "Transapical transcatheter aortic valve implantation in humans: initial clinical experience." *Circulation* 114(6): 591-6.
- Lieberman, E. B., T. M. Bashore, et al. (1995). "Balloon aortic valvuloplasty in adults: failure of procedure to improve long-term survival." *J Am Coll Cardiol* 26(6): 1522-8.
- Lok, C. E., P. C. Austin, et al. (2004). "Impact of renal insufficiency on short- and long-term outcomes after cardiac surgery." *Am Heart J* 148(3): 430-8.
- Low, R. I., S. F. Bolling, et al. (2008). "Direct flow medical percutaneous aortic valve: proof of concept." *EuroIntervention* 4(2): 256-61.
- Masson, J. B., J. Kovac, et al. (2009). "Transcatheter aortic valve implantation: review of the nature, management, and avoidance of procedural complications." *JACC Cardiovasc Interv* 2(9): 811-20.
- Moynagh, A. M., D. J. Scott, et al. (2011). "CoreValve transcatheter aortic valve implantation via the subclavian artery: comparison with the transfemoral approach." *J Am Coll Cardiol* 57(5): 634-5.

- NHLBI Balloon Valvuloplasty Registry Participant (1991). "Percutaneous balloon aortic valvuloplasty. Acute and 30-day follow-up results in 674 patients from the NHLBI Balloon Valvuloplasty Registry." *Circulation* 84(6): 2383-97.
- Otto, C. M., M. C. Mickel, et al. (1994). "Three-year outcome after balloon aortic valvuloplasty. Insights into prognosis of valvular aortic stenosis." *Circulation* 89(2): 642-50.
- Petronio, A. S., M. De Carlo, et al. (2010). "Safety and efficacy of the subclavian approach for transcatheter aortic valve implantation with the CoreValve revalving system." *Circ Cardiovasc Interv* 3(4): 359-66.
- Piazza, N., E. Grube, et al. (2008). "Procedural and 30-day outcomes following transcatheter aortic valve implantation using the third generation (18 Fr) corevalve revalving system: results from the multicentre, expanded evaluation registry 1-year following CE mark approval." *EuroIntervention* 4(2): 242-9.
- Piazza, N., Y. Onuma, et al. (2008). "Early and persistent intraventricular conduction abnormalities and requirements for pacemaking after percutaneous replacement of the aortic valve." *JACC Cardiovasc Interv* 1(3): 310-6.
- Piazza, N., M. van Gameren, et al. (2009). "A comparison of patient characteristics and 30-day mortality outcomes after transcatheter aortic valve implantation and surgical aortic valve replacement for the treatment of aortic stenosis: a two-centre study." *EuroIntervention* 5(5): 580-8.
- Rodes-Cabau, J., J. G. Webb, et al. (2010). "Transcatheter aortic valve implantation for the treatment of severe symptomatic aortic stenosis in patients at very high or prohibitive surgical risk: acute and late outcomes of the multicenter Canadian experience." *J Am Coll Cardiol* 55(11): 1080-90.
- Roten, L., P. Wenaweser, et al. (2011). "Incidence and predictors of atrioventricular conduction impairment after transcatheter aortic valve implantation." *Am J Cardiol* 106(10): 1473-80.
- Safian, R. D., A. D. Berman, et al. (1988). "Balloon aortic valvuloplasty in 170 consecutive patients." *N Engl J Med* 319(3): 125-30.
- Schofer, J., M. Schluter, et al. (2008). "Retrograde transarterial implantation of a nonmetallic aortic valve prosthesis in high-surgical-risk patients with severe aortic stenosis: a first-in-man feasibility and safety study." *Circ Cardiovasc Interv* 1(2): 126-33.
- Schultz, C. J., A. D. Moelker, et al. (2010). "Cardiac CT: necessary for precise sizing for transcatheter aortic implantation." *EuroIntervention* 6 Suppl G: G6-G13.
- Sinhal, A., L. Altwegg, et al. (2008). "Atrioventricular block after transcatheter balloon expandable aortic valve implantation." *JACC Cardiovasc Interv* 1(3): 305-9.
- Sinning, J. M., A. Ghanem, et al. (2010). "Renal function as predictor of mortality in patients after percutaneous transcatheter aortic valve implantation." *JACC Cardiovasc Interv* 3(11): 1141-9.
- Smith, C. R. and M. B. Leon, et al (2011). "Comparison of transcatheter and surgical aortic valve replacement for aortic stenosis in patients at high-risk for operation." *N Engl J Med* in press.
- Tamburino, C., D. Capodanno, et al. (2011). "Incidence and predictors of early and late mortality after transcatheter aortic valve implantation in 663 patients with severe aortic stenosis." *Circulation* 123(3): 299-308.
- Tchetche, D., N. Dumonteil, et al. (2010). "Thirty-day outcome and vascular complications after transarterial aortic valve implantation using both Edwards Sapien and Medtronic CoreValve bioprostheses in a mixed population." *EuroIntervention* 5(6): 659-65.

- Thomas, M., G. Schymik, et al. (2010). "Thirty-day results of the SAPIEN aortic Bioprosthesis European Outcome (SOURCE) Registry: A European registry of transcatheter aortic valve implantation using the Edwards SAPIEN valve." *Circulation* 122(1): 62-9.
- Treede, H., T. Tubler, et al. (2010). "Six-month results of a repositionable and retrievable pericardial valve for transcatheter aortic valve replacement: the Direct Flow Medical aortic valve." *J Thorac Cardiovasc Surg* 140(4): 897-903.
- Vahanian, A., O. Alfieri, et al. (2008). "Transcatheter valve implantation for patients with aortic stenosis: a position statement from the European Association of Cardio-Thoracic Surgery (EACTS) and the European Society of Cardiology (ESC), in collaboration with the European Association of Percutaneous Cardiovascular Interventions (EAPCI)." *Eur Heart J* 29(11): 1463-70.
- Vahanian, A., H. Baumgartner, et al. (2007). "Guidelines on the management of valvular heart disease: The Task Force on the Management of Valvular Heart Disease of the European Society of Cardiology." *Eur Heart J* 28(2): 230-68.
- Van Mieghem, N. M., R. J. Nuis, et al. (2010). "Vascular complications with transcatheter aortic valve implantation using the 18 Fr Medtronic CoreValve System: the Rotterdam experience." *EuroIntervention* 5(6): 673-9.
- Walther, T., V. Falk, et al. (2008). "Transapical minimally invasive aortic valve implantation; the initial 50 patients." *Eur J Cardiothorac Surg* 33(6): 983-8.
- Walther, T., P. Simon, et al. (2007). "Transapical minimally invasive aortic valve implantation: multicenter experience." *Circulation* 116(11 Suppl): I240-5.
- Webb, J. G., L. Altwegg, et al. (2009). "Transcatheter aortic valve implantation: impact on clinical and valve-related outcomes." *Circulation* 119(23): 3009-16.
- Webb, J. G., M. Chandavimol, et al. (2006). "Percutaneous aortic valve implantation retrograde from the femoral artery." *Circulation* 113(6): 842-50.
- Webb, J. G., S. Pasupati, et al. (2007). "Percutaneous transarterial aortic valve replacement in selected high-risk patients with aortic stenosis." *Circulation* 116(7): 755-63.
- Webb, J. G., D. A. Wood, et al. (2010). "Transcatheter valve-in-valve implantation for failed bioprosthetic heart valves." *Circulation* 121(16): 1848-57.
- Wenaweser, P. and S. Windecker (2010). "Anatomical suitability for transcatheter aortic valve implantation with complementary roles for 2 rivals." *JACC Cardiovasc Interv* 3(8): 867-9.
- Wendler, O., G. Schymik, et al. (2010). "Development of a risk score for transcatheter aortic valve implantation. 1-year outcomes from over 1000 patients in the SOURCE registry." *ESC Congress*.
- Wendler, O., T. Walther, et al. (2010). "Trans-apical aortic valve implantation: univariate and multivariate analyses of the early results from the SOURCE registry." *Eur J Cardiothorac Surg* 38(2): 119-27.
- Wijesinghe, N., J. Ye, et al. (2010). "Transcatheter aortic valve implantation in patients with bicuspid aortic valve stenosis." *JACC Cardiovasc Interv* 3(11): 1122-5.
- Yan, T. D., C. Cao, et al. (2010). "Transcatheter aortic valve implantation for high-risk patients with severe aortic stenosis: A systematic review." *J Thorac Cardiovasc Surg* 139(6): 1519-28.
- Zajarias, A. and A. G. Cribier (2009). "Outcomes and safety of percutaneous aortic valve replacement." *J Am Coll Cardiol* 53(20): 1829-36.



## **Aortic Stenosis - Etiology, Pathophysiology and Treatment**

Edited by Dr. Masanori Hirota

ISBN 978-953-307-660-7

Hard cover, 254 pages

**Publisher** InTech

**Published online** 10, October, 2011

**Published in print edition** October, 2011

Currently, aortic stenosis (AS) is the most prevalent valvular disease in developed countries. Pathological and molecular mechanisms of AS have been investigated in many aspects. And new therapeutic devices such as transcatheter aortic valve implantation have been developed as a less invasive treatment for high-risk patients. Due to advanced prevalent age of AS, further discovery and technology are required to treat elderly patients for longer life expectancy. This book is an effort to present an up-to-date account of existing knowledge, involving recent development in this field. Various opinion leaders described details of established knowledge or newly recognized advances associated with diagnosis, treatment and mechanism. Thus, this book will enable close intercommunication to another field and collaboration technology for new devices. We hope that it will be an important source, not only for clinicians, but also for general practitioners, contributing to development of better therapeutic adjuncts in the future.

### **How to reference**

In order to correctly reference this scholarly work, feel free to copy and paste the following:

Kentaro Hayashida and Thierry Lefèvre (2011). Transcatheter Aortic Valve Implantation: New Hope for Inoperable and High-Risk Patients, *Aortic Stenosis - Etiology, Pathophysiology and Treatment*, Dr. Masanori Hirota (Ed.), ISBN: 978-953-307-660-7, InTech, Available from: <http://www.intechopen.com/books/aortic-stenosis-etiology-pathophysiology-and-treatment/transcatheter-aortic-valve-implantation-new-hope-for-inoperable-and-high-risk-patients>

**INTECH**  
open science | open minds

### **InTech Europe**

University Campus STeP Ri  
Slavka Krautzeka 83/A  
51000 Rijeka, Croatia  
Phone: +385 (51) 770 447  
Fax: +385 (51) 686 166  
[www.intechopen.com](http://www.intechopen.com)

### **InTech China**

Unit 405, Office Block, Hotel Equatorial Shanghai  
No.65, Yan An Road (West), Shanghai, 200040, China  
中国上海市延安西路65号上海国际贵都大饭店办公楼405单元  
Phone: +86-21-62489820  
Fax: +86-21-62489821



© 2011 The Author(s). Licensee IntechOpen. This is an open access article distributed under the terms of the [Creative Commons Attribution 3.0 License](#), which permits unrestricted use, distribution, and reproduction in any medium, provided the original work is properly cited.

IntechOpen

IntechOpen