

# We are IntechOpen, the world's leading publisher of Open Access books Built by scientists, for scientists

**4,800**

Open access books available

**122,000**

International authors and editors

**135M**

Downloads

Our authors are among the

**154**

Countries delivered to

**TOP 1%**

most cited scientists

**12.2%**

Contributors from top 500 universities



**WEB OF SCIENCE™**

Selection of our books indexed in the Book Citation Index  
in Web of Science™ Core Collection (BKCI)

Interested in publishing with us?  
Contact [book.department@intechopen.com](mailto:book.department@intechopen.com)

Numbers displayed above are based on latest data collected.

For more information visit [www.intechopen.com](http://www.intechopen.com)



# Rapid Prototyping in Correction of Craniofacial Skeletal Deformities

Libin Zhou and Yanpu Liu

*Department of Oral and Maxillofacial Surgery, School of Stomatology,  
Fourth Military Medical University  
China*

## 1. Introduction

The skull of a human being, comprising two parts: the cranium and the maxillofacial bone, is a bony structure in the head that forms a cavity for the brain and supports the structures of the face. The functions of the skull include protection of the brain, fixing the position of the eyeballs and ears, compositing the oral cavity and airway. Bone deformities in the craniofacial area, including acquired deformities (such as defects result from oncological resection and trauma, and micrognathia syndrome after mandibular condyle injuries), and congenital deformities (various craniofacial syndromes, such as hemifacial microsomia) will create tremendous cosmetic and functional handicaps (Mehta & Deschler, 2004).

Such deformities heavily affect the patients' quality of life and pose a vast challenge to craniofacial surgeons. Various methods, including autogenous bone grafting (free bone grafting and vascularised grafting of compound tissue flaps), and alloplastic and allogeneic materials, have met with limited success (Boyne, 1973; Tideman et al., 1998; Samman et al., 1999). To achieve satisfactory esthetic and functional reconstruction using the traditional methods remains extremely challenging.

At present most of the mandible restoration implants are fabricated by hand forming technique (Boyne, 1973; Tideman et al., 1998; Samman et al., 1999; Eufinger et al., 1997; Stojadinovic et al., 1999). The method involves pre-bending the reconstruction plate on the stereolithography model to cover the defect. Bone graft also was traditionally adapted on the sterilized stereolithography model during the operation to reconstruct the facial defect. The precision of fit and durability of implant mainly relies on the abilities of the technicians and surgeons.

Rapid prototyping refers to a group of techniques that are used to produce stereolithographical models based on digital images, including reverse engineering (RE), computer-aided design (CAD), rapid prototyping (RP), etc. RE is a viable approach to create a 3-dimensional virtual model of an existing physical part by measuring an object using 3-dimensional scanning technologies such as laser scanners, structured light digitizers, computed tomography (CT) or magnetic resonance (MR). CAD takes advantage of computer technology to aid in the design and, especially, the drafting (technical and engineering drawing) of a part or product. It is both a visual (or drawing) and symbol-based method of communication whose conventions are particular to a specific technical field. RP takes CAD files and transforms them into thin, virtual, horizontal cross-sections.

Stereoscopic lithography carries out layer by layer according to the virtual structure to build up the physical model. This process allows the production of geometrically complex shaped models that otherwise would be impossible to produce.

Use of the rapid prototyping in the craniofacial area has been extensive. It has been used primarily as a means of evaluation of the craniofacial deformity, preoperative planning, surgical simulation, guiding surgical procedures, postoperative evaluation, and longitudinal follow-up for outcome assessment, using tactile models derived from patient computerized tomography (CT) data.

The following flowchart (fig.1) reveals the conventional approach to manufacture a custom implant for reconstruction of a mandibular defect. It starts from the CT scanning of the patient's skull. The CT images are imported into the CAD software and modified as a surface. The surface is then converted to an STL file, which converts the surface to triangles (triangulation). The surface can then be fed to the RP machine. A mandible implant is then produced by manually shaping the titanium plate on the surface of the 3D stereolithography model. The resulting shaped titanium plate is then directly used to bridge the residual mandibular blocks (Tideman et al., 1998; Samman et al., 1999; Eufinger et al., 1997; Stojadinovic et al., 1999).

However, the potential to intimately control the microstructure and the overall macroscopic shape of the implants makes RP an ideal process for fabricating individual implant which is more important and promising in offering simpler and more rapid surgical implementations.

A new approach has been developed to design the mandible reconstruction implant from Computer Aided Design (CAD) (fig.2). The proposed approach includes serial steps: CT data acquisition, medical image processing - 3D reconstruction, design of the custom titanium implant, Rapid Prototyping, rehearsal of surgery and implant fitting evaluation and production of titanium implant (Singare et al., 2004; Zhou et al., 2011; Zhou et al., 2010).

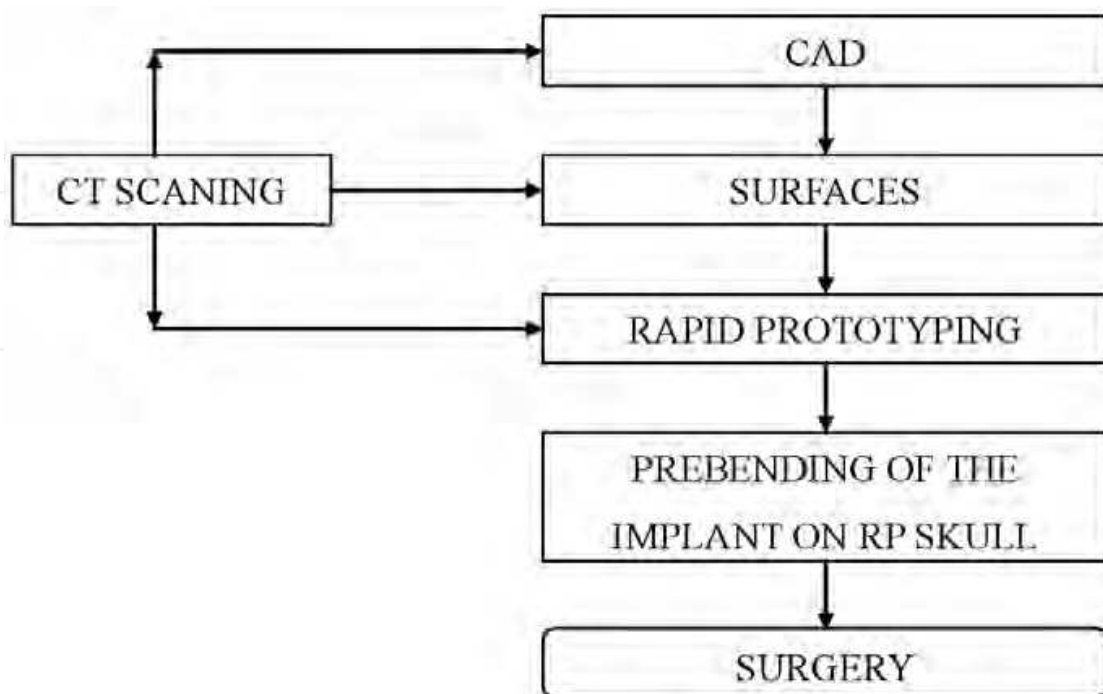


Fig. 1. The approach to manufacture a custom implant for a mandibular defect patient

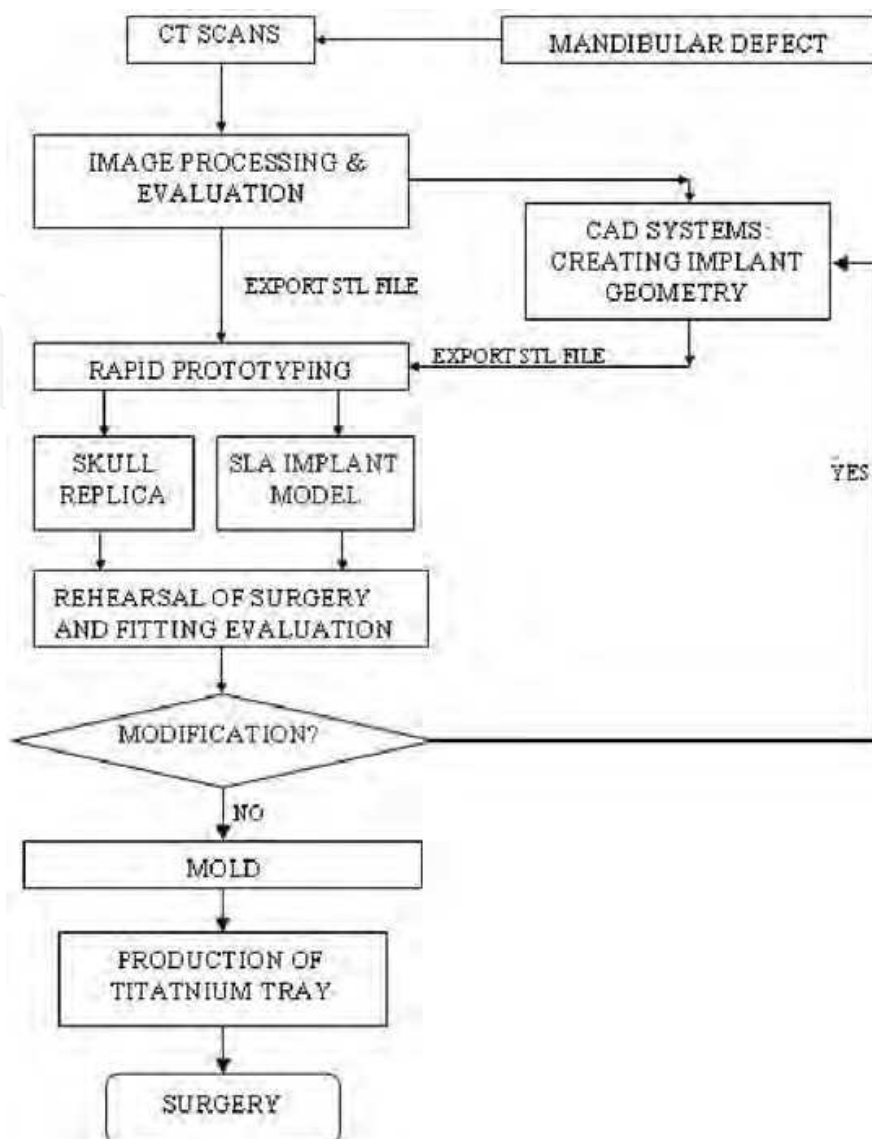


Fig. 2. Computer-aided geometric modeling for the manufacturing of custom implants

### 1.1 CT data acquisition

CT data acquisition was performed by the spiral volumetric technique (Picker MX8000). Suitable CT parameters for data acquisition were as follows: zero degree gantry, a resolution of  $512 \times 512$  pixel reconstruction matrix image, 1.3 mm slice thickness and a slice reconstruction interval of 0.6mm.

The scan data are recorded according to the DICOM Norm (a standard of data formatting and of communication used in medical imagery).

### 1.2 Medical image processing-segmentation and 3D reconstruction

The 2D image slices from the CT scans were imported into the Materialise's Interactive Medical Imaging Control System (Mimics). A thresholding and region growing technique were used to extract the contour of the skeleton from the CT data. After removing the soft tissue, a 3-D region-growing technique is then used to isolate the skeletal part of the head from the CT dataset.

A 3D image is reconstructed and visualized. The skull data was converted to a mesh based surface representation (STL) format and was then download to an RP machine to fabricate the skull replica.

### **1.3 Design of the custom titanium implant**

Customized bone grafting trays were designed using Geomagic studio, version 6.0 (Raindrop Geomagic, Research Triangle Park, NC). Different techniques are applied for individual cases, including mirroring the non-defect side, implant design from other skull CT data and geometry modeling. The designs of different implant are to be elaborated in each case report.

### **1.4 Rapid prototyping**

The CAD model of the skeleton structure and the bone grafting tray were then transferred in a stereolithography (STL) format, and input to a laser stereolithographic rapid prototyping system, LPS 600, to manufacture the skull models and customized implants. The model was sliced into 0.1 mm layer thickness, and then processed through a layer by layer building process. A physical resin model was thus obtained.

### **1.5 Rehearsal of surgery and implant fitting evaluation**

The RP model makes a clear view about the defect and allow for a surgeon to gain operative experience and get a clear view of the specific demands required for such an operation.

Preoperative rehearsal of surgery via fitting the physical model of the custom tray with the patient's skull replica facilitates the optimal placement for the prosthesis onto the residual mandible; thereby evaluate the quality of the custom tray. This could reduce the operation time, and allow for modification of the surgical plans and the implants.

### **1.6 Production of titanium implant**

To obtain a biocompatible titanium tray, the prototyped resin model of the tray was embedded with a high temperature resistant phosphate investment material. After successive drying and dipping, the resin model was burn out in an oven, at a temperature of 300-600°C. This led to a casting mold and a titanium tray was cast using this model. The titanium tray was then subject to post processing: trimming, sandblasting and drilling, among others.

## **2. Clinical applications**

### **2.1 Case study: Unilateral mandible defect (fig. 3)**

A 24-year-old man with an adamantoma on the left mandibular angle and ramus was admitted. The surgical plan was to make a block resection treatment to cure the tumor, and to repair the defect with a rapid prototyped tray.

The CT data of the patient's skull was acquired and the computer assisted design of the tray was based on the mirror imaging technique.

Since the defect only involved the left side of the mandible. It was decided to mirror the undamaged right side onto the left side. To mirror the non-affected side image, a reference plan is needed. Usually, the center-plane can be established by the landmark of the anatomy structure, such as maxillary and mandibular adjacent point of central incisors, nasion, nasal

septum, the central point of the sella turcica, etc (Zhou et al., 2010). It can also be established based on the midpoints of the symmetric landmarks, such as the orbital cavity, the condyles, the temporomandibular joint glenoid fossa, opposite teeth, etc. Generally, cranium and maxillas and zygomas are more stable than mandible, since the latter will displace easily after unilateral bone resection or overgrowth in one side. Sometimes, to identify

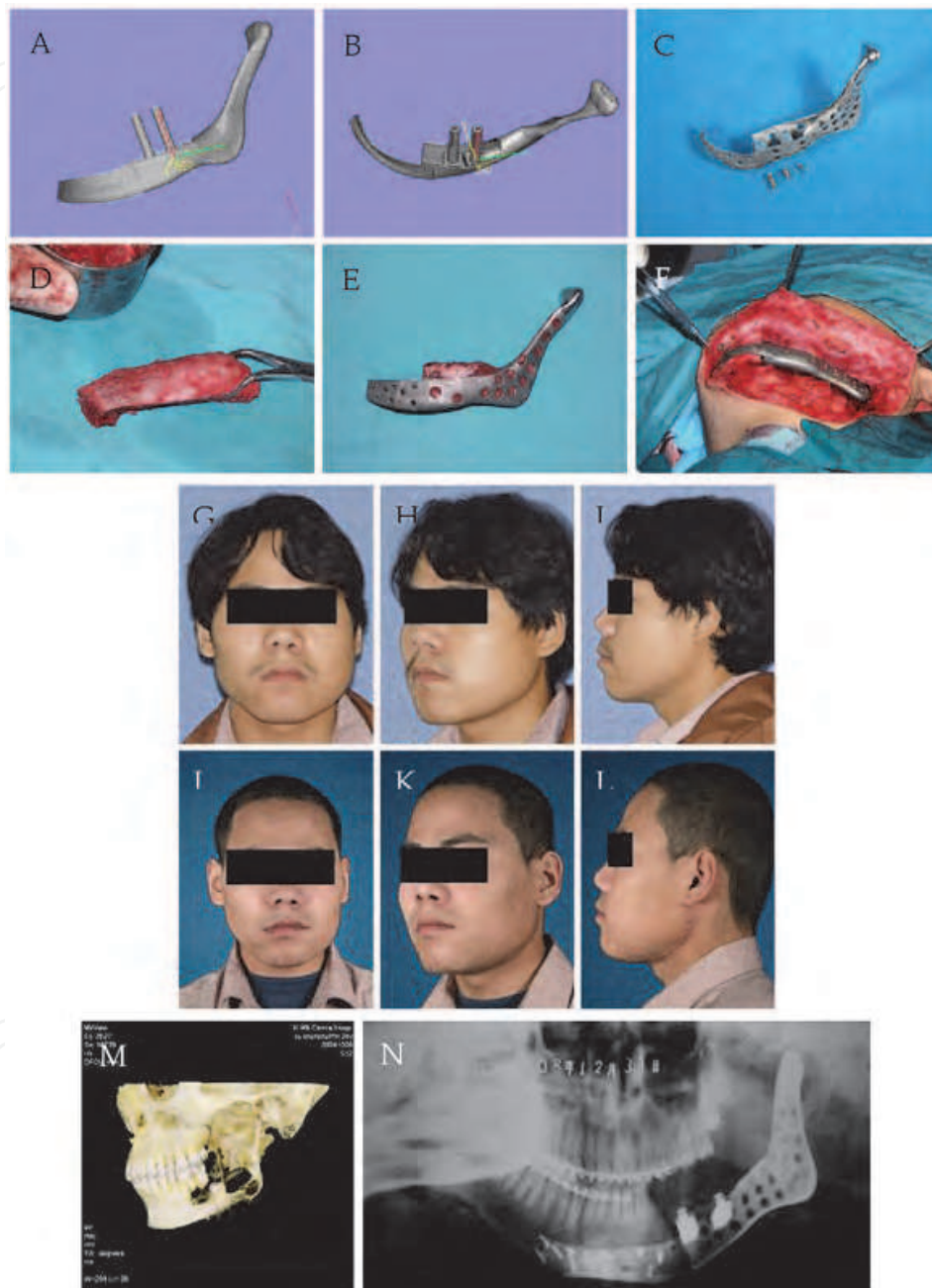


Fig. 3. (A&B) the design of the tray. (C) the titanium tray. (D-F) intraoperative photos, D, shaping the iliac bone graft, E, marrow-cancellous bone grafts packed in the tray and bone blocks covered the tray, F, the tray-bone graft complex was fixed onto the mandible to restore the defect. (G-L) pre- and post-operative facial appearance of the patient. (M) preoperative 3D view of the skull, tumor on the left mandible. (N) postoperative X-ray view of the reconstructed mandible.

the mirror plane is a great challenge. For the deformity only affect a part of the facial or cranial bone, the unaffected normal part can be used to establish and adjust for the mirror plane.

A suitable mirror plane could be obtained by trial and error. A reference plane that allows maximum overlap between the mirrored image and the native image of the normal part of the skull after mirroring can be considered to be the mirror plane.

After mirroring, the mirrored symmetric structure is considered to be the target contour to be restored. Then the mirror image was used to design the implant geometry. And footplates were designed based on the residual mandible ends.

The implant was manufactured by RP process. The SLA model was used to cast the titanium tray. And the implant was sterilized and prepared for the surgery.

The reconstructive surgery was performed via an extraoral approach. The residual mandible end was exposed and the bone bed was prepared, the tray was fitted onto the mandible and highly accurate match was observed. Autologous ilium was harvested from the anterior iliac crest. Crushed bone marrow-cancellous bone particles were densely packed into the tray and a cortical-cancellous bone block was placed on the top to cover entire tray. The cortical bone was drilled and secured on the top of the tray by two dental fixture implants. The tray-bone graft complex was then fixed onto the mandible with titanium screws. The wound was then closed. Satisfactory facial appearance and normal occlusion were restored. Over denture was made to rehabilitate the occlusion.

## **2.2 Case study: Unilateral cranium defect (fig. 4)**

A patient with a huge unilateral cranium defect, involving the left parietal, temporal, frontal and sphenoid bone, due to traffic accident trauma was admitted for reconstruction.

Using the same mirroring technique, cranium prosthesis was designed and manufactured, to protect the intracranial contents. An implantation surgery was performed, with taking good care of the brain. Using the prototyped prosthesis, symmetric cranium was restored, via a straight approach. The general appearance and radiologic picture demonstrated the symmetry.

In conclusion, the computer assisted design and rapid prototyping technique facilitate the reconstructive surgery. By applying the mirroring method, excellent symmetry can be restored for the asymmetric skeletal defect.

## **2.3 Case study: Mandibular retraction (fig. 5)**

A 28-year-old woman with a mandibular retraction needed chin augmentation. A chin augmentation of 6 mm was predicted by cephalometric analysis. And an individual prosthesis was designed and manufactured.

By using the same technology in case study one, a 3D reconstructed CT data was generated (MIMICS). The defect couldn't be reconstructed by mirror imaging technique. The patient's 3D mandible CT data was measured and these measurements data were used to select a similar mandible. A skull model of a healthy woman with normal mandible contour was selected and used to design the implant geometry.

The CAD design of the implant was based on the normal mandible data used as a template to create an anatomically correct mandibular contour. The inner surface of the implant was based on the anatomic structure of the chin surface, which allow for an easy placement of the implant onto the chin.

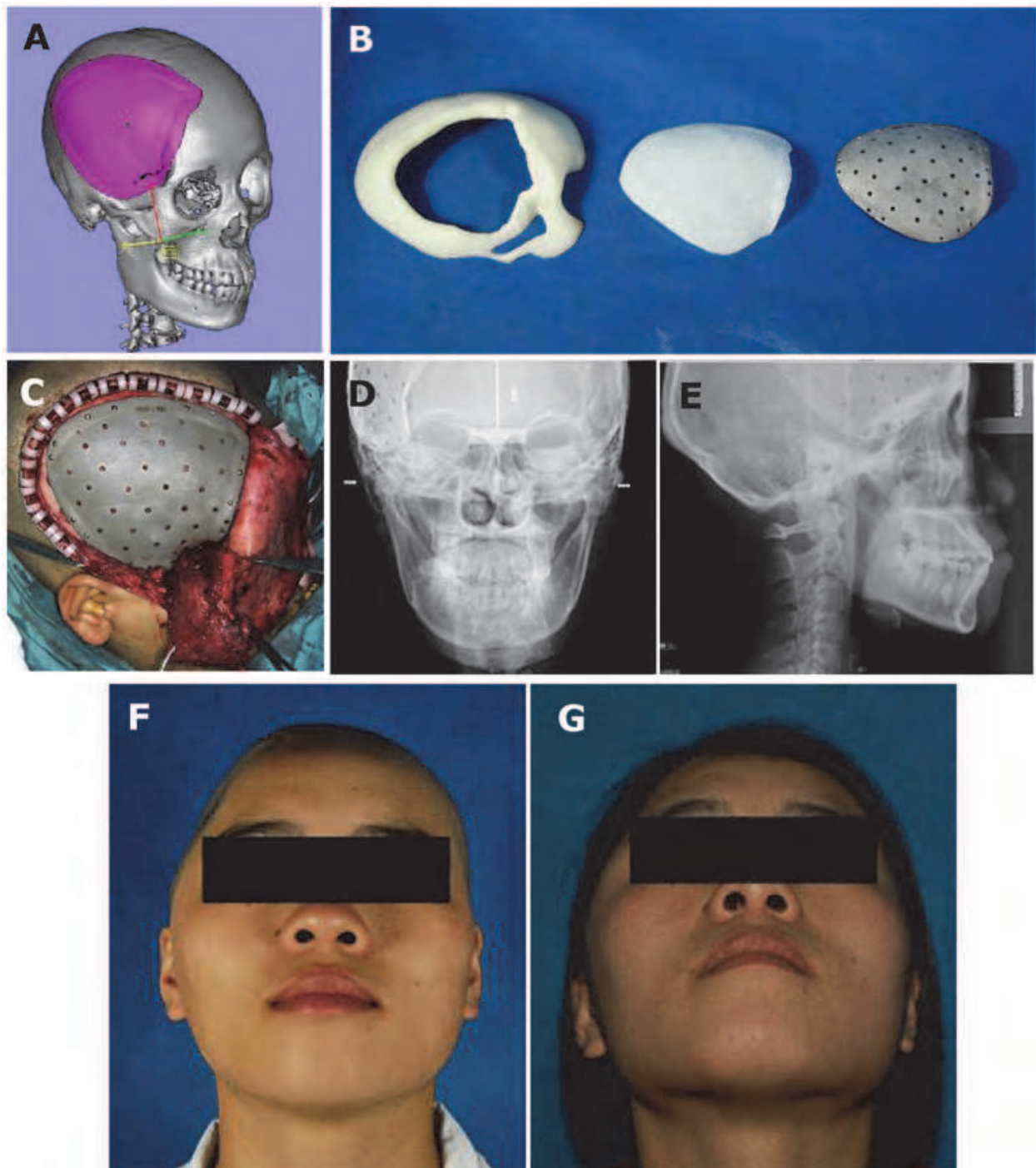


Fig. 4. (A) the design of the cranium prosthesis. (B) the resin model of the cranium and prosthesis, and the titanium prosthesis. (C) intraoperative photo: the fixation of the prosthesis to the cranium to repair the defect. (D&E) postoperative X-ray view of the skull., F, expose the chin, G, place the prosthesis. (F&G) pre- and post-operative facial appearance of the patient.

A three-dimensional model was manufactured by using a rapid prototyping machine and the prototype was used to cast the titanium implant. The prosthesis manufactured using rapid prototyping technology resulted in simple surgical implantation and better facial



contour. This technique can also be used to reconstruct segmental defect in the chin region and to cure hemifacial microsomia.

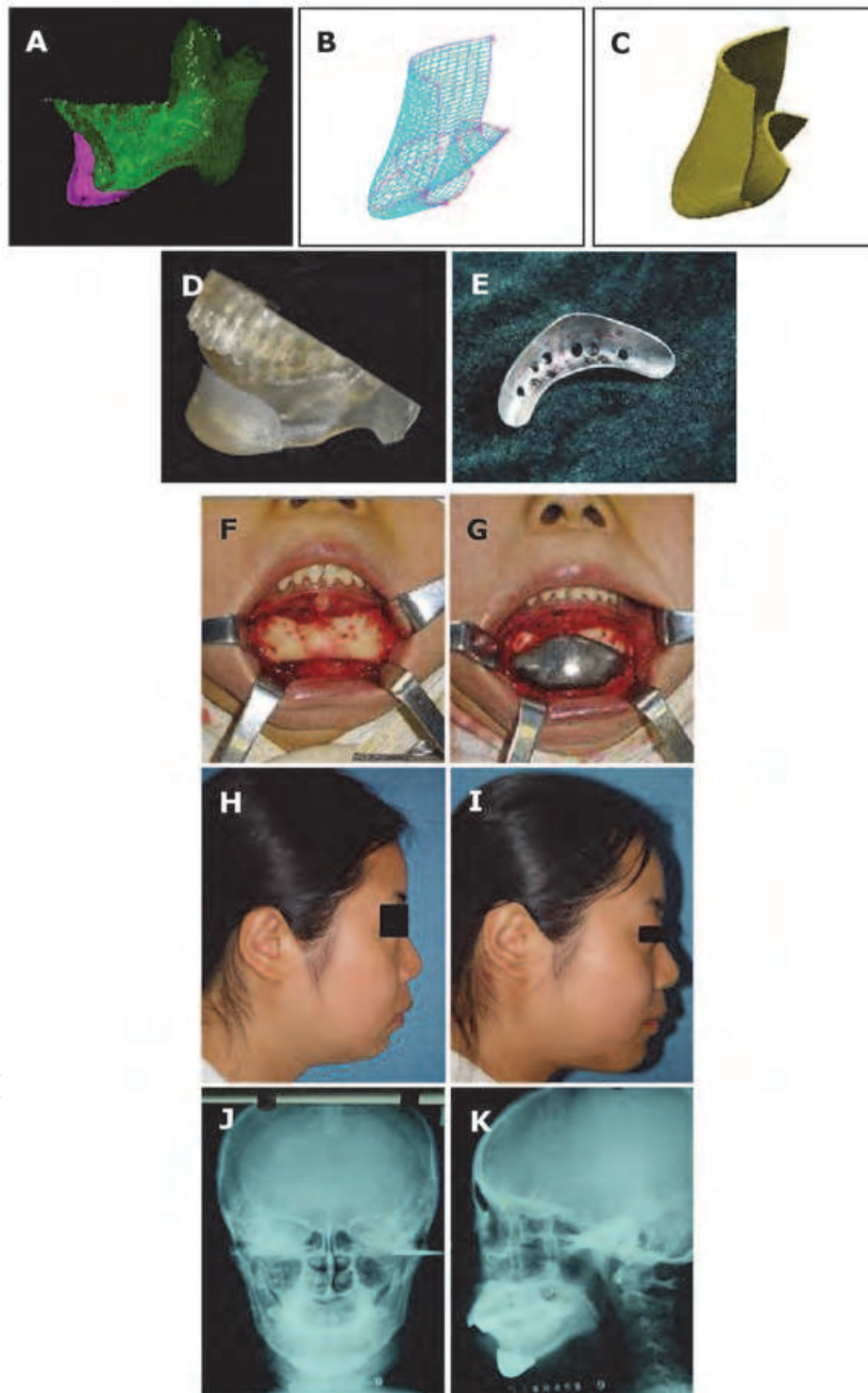


Fig. 5. (A-C) the design of the chin prosthesis. (D) resin model of the prosthesis. (E) the titanium chin prosthesis. (F&G) intraoperative photos, F, expose the chin, G, place the prosthesis. (H&I) pre- and post-operative facial appearance of the patient. (J&K) postoperative X-ray view of the reconstructed mandible.

### 3. Results

We compared the skull model and the CT scan data and found that the physical model's dimension was in agreement with the CT scan data and the error was less than 0.3%.

The prototyped models, the skull and the implant, were used to evaluate the design and the surgical planning. It was found that the physical tray made from virtual data, fitted perfectly with the exact replica of the patient's skull anatomy. Furthermore, an adequate symmetry of the jaw was obtained. The surgical planning was accurate and was facilitated by the RP model.

The custom titanium implants were well fitted in patients. In all cases, the implants were just inserted and fixed by screws, so that the duration of the surgery was reduced with the aid of the customized implants.

No complications were observed except that the cancellous bone packed in the grafting tray was absorbed after a period of time as shows in fig.3N.

### 4. Conclusions

We introduced the technology of manufacturing individual reconstructive prosthesis for craniofacial bone defects. This technology involves implant shape design in CAD environment from CT data, fabrication of the physical model by rapid prototyping process, creating the mold from the prototype, and then cast of the titanium implant. Clinical studies demonstrated that this new method can create accurate implant for bone various defects. We conclude that, with the development of the relative techniques of RP, perfect individual implants can be manufactured. Also the RP technique facilitates the reconstruction surgery and makes it more controllable and accurate. Satisfactory aesthetics and functional rehabilitation of craniofacial deformities can be achieved, that otherwise would remain difficult.

### 5. Acknowledgment


We appreciate the assistance by the Institute of Advanced Manufacturing Technology, Xi'an Jiaotong University, in designing and manufacturing the individual implants.

### 6. References

- Mehta RP. & Deschler DG. (2004). Mandibular reconstruction in 2004: an analysis of different techniques. *Current Opinion in Otolaryngology & Head and Neck Surgery*, Vol 12, No.4, (August 2004), pp. 288-2893, ISSN 1068-9508
- Boyne PJ. (1973). Methods of osseous reconstruction of the mandible following surgical resection. *Journal of Biomedical Materials Research*, Vol 7, No.195, (1973), pp. 195-204, ISSN 1549-3296
- Tideman H., Samman N. & Cheung LK. (1998). Functional reconstruction of the mandible: a modified titanium mesh system. *International Journal of Oral and Maxillofacial Surgery*, Vol.27, No.5, (October 1998), pp. 339-345, ISSN 1399-0020
- Samman N., Luk W., Chow T., Cheung L., Tideman H. & Clark R. (1999). Custom-made titanium mandibular reconstruction tray. *Australian Dental Journal*, Vol.44, No.3, (September 1999), pp. 195-199, ISSN 0045-0421

- Eufinger H., Wehmöller M. & Machtens E. (1997). Individual prostheses and resection templates for mandibular resection and reconstruction. *British Journal of Oral and Maxillofacial Surgery*, Vol.35, No.6, (December 1997), pp. 413-418, ISSN 0266-4356
- Stojadinovic S., Eufinger H., Wehmöller M. & Machtens E. (1999). One-step resection and reconstruction of the mandible using computer-aided techniques--experimental and clinical results. *Mund Kiefer Gesichtschir*, Vol.3, (May 1999), pp. S151-153, ISSN 1432-9417
- Singare S., Dichen L., Bingheng L., Yanpu L., Zhenyu G. & Yaxiong L. (1997). Design and fabrication of custom mandible titanium tray based on rapid prototyping. *Medical Engineering & Physics*, Vol.26, No.8, (October 2004), pp. 671-676, ISSN 1350-4533
- Zhou L., Zhao J., Shang H., Liu W., Feng Z., Liu G., Wang J. & Liu Y. (2011). Reconstruction of Mandibular Defects Using a Custom Made Titanium Tray in Combination with Autologous Cancellous Bone. *Journal of Oral and Maxillofacial Surgery*, Vol.69, No.5, (May 2011), pp. 1508-1518, ISSN 0278-2391
- Zhou L., Shang H., He L., Bo B., Liu G., Liu Y., & Zhao J. (2010). Accurate reconstruction of discontinuous mandible using a reverse engineering/computer-aided design/rapid prototyping technique: a preliminary clinical study. *Journal of Oral and Maxillofacial Surgery*, Vol.68, No.9, (September 2010), pp. 2115-2121, ISSN 0278-2391

IntechOpen



## **Advanced Applications of Rapid Prototyping Technology in Modern Engineering**

Edited by Dr. M. Hoque

ISBN 978-953-307-698-0

Hard cover, 364 pages

**Publisher** InTech

**Published online** 22, September, 2011

**Published in print edition** September, 2011

Rapid prototyping (RP) technology has been widely known and appreciated due to its flexible and customized manufacturing capabilities. The widely studied RP techniques include stereolithography apparatus (SLA), selective laser sintering (SLS), three-dimensional printing (3DP), fused deposition modeling (FDM), 3D plotting, solid ground curing (SGC), multiphase jet solidification (MJS), laminated object manufacturing (LOM). Different techniques are associated with different materials and/or processing principles and thus are devoted to specific applications. RP technology has no longer been only for prototype building rather has been extended for real industrial manufacturing solutions. Today, the RP technology has contributed to almost all engineering areas that include mechanical, materials, industrial, aerospace, electrical and most recently biomedical engineering. This book aims to present the advanced development of RP technologies in various engineering areas as the solutions to the real world engineering problems.

### **How to reference**

In order to correctly reference this scholarly work, feel free to copy and paste the following:

Libin Zhou and Yanpu Liu (2011). Rapid Prototyping in Correction of Craniofacial Skeletal Deformities, *Advanced Applications of Rapid Prototyping Technology in Modern Engineering*, Dr. M. Hoque (Ed.), ISBN: 978-953-307-698-0, InTech, Available from: <http://www.intechopen.com/books/advanced-applications-of-rapid-prototyping-technology-in-modern-engineering/rapid-prototyping-in-correction-of-craniofacial-skeletal-deformities>

**INTECH**  
open science | open minds

### **InTech Europe**

University Campus STeP Ri  
Slavka Krautzeka 83/A  
51000 Rijeka, Croatia  
Phone: +385 (51) 770 447  
Fax: +385 (51) 686 166  
[www.intechopen.com](http://www.intechopen.com)

### **InTech China**

Unit 405, Office Block, Hotel Equatorial Shanghai  
No.65, Yan An Road (West), Shanghai, 200040, China  
中国上海市延安西路65号上海国际贵都大饭店办公楼405单元  
Phone: +86-21-62489820  
Fax: +86-21-62489821

© 2011 The Author(s). Licensee IntechOpen. This chapter is distributed under the terms of the [Creative Commons Attribution-NonCommercial-ShareAlike-3.0 License](#), which permits use, distribution and reproduction for non-commercial purposes, provided the original is properly cited and derivative works building on this content are distributed under the same license.

IntechOpen

IntechOpen