

We are IntechOpen, the world's leading publisher of Open Access books Built by scientists, for scientists

4,800

Open access books available

122,000

International authors and editors

135M

Downloads

Our authors are among the

154

Countries delivered to

TOP 1%

most cited scientists

12.2%

Contributors from top 500 universities



WEB OF SCIENCE™

Selection of our books indexed in the Book Citation Index
in Web of Science™ Core Collection (BKCI)

Interested in publishing with us?
Contact book.department@intechopen.com

Numbers displayed above are based on latest data collected.

For more information visit www.intechopen.com



Robot-Assisted Radical Prostatectomy

Jorn H Witt, Vahudin Zugor, Christian Wagner,
Andreas Schutte and Apostolos P Labanaris
*Department of Urology and Pediatric Urology,
Prostate Center Northwest, St. Antonius-Hospital, Gronau,
Germany*

1. Introduction

Over the last decade, robot-assisted radical prostatectomy (RARP) has become a common used surgical procedure for the treatment of prostate cancer (PCa) (35,41). Nowadays, it is considered the dominant approach to radical prostatectomy (RP) in the United States, in European countries such as Belgium and Sweden as well as in other regions where health economic conditions permit (2,12,29).

2. Anatomical considerations

The aim of radical prostatectomy is not only to achieve optimal oncological outcomes but also to preserve the functional aspects of continence and potency (23). In order to achieve this goal, a profound understanding of the prostate anatomy as well as the pelvic anatomy of the surrounding structures is mandatory. Especially, regarding the functional aspects of continence and potency, the ongoing understanding of the anatomical structures and functional principles will surely lead to new unknown aspects in the future. Walz et al have described the contemporary anatomy of the prostate and its surrounding structures in detail in 2010 (37).

3. Patient selection

Patient selection is the same as for the open or standard laparoscopic variants of RP and has been previously described in evidence-based guidelines. Patients exhibiting a clinically localized disease, an expected negative surgical margin status and an individual life expectancy of more than 10 years are three principle indications to perform RP (10,39).

4. Patient preparation

Bowel preparation is used in most institutions and can be achieved with a mild laxative or rectal preparation by enema (34). The surgical field is shaved from the pubic bone to the xiphoid. We prefer preparation of the umbilicus with an alcoholic swab two hours before the procedure and a single shot perioperative antibiotic prophylaxis.

5. Port placement

The port placement is shown in figure 1. Either Verres needle or camera port placement under direct vision in "Hasson technique" is a possible. We prefer the Hasson technique with minilaparotomy and camera port placement above or on the left side of the umbilicus under vision. After establishment of the pneumoperitoneum the robotic and assistant ports are placed under direct vision. After prior abdominal surgery a standard laparoscopic or robotic assisted adhesiolysis could be necessary. Alternatively to the transperitoneal approach, which is being preferred in our institution, an extraperitoneal approach is possible and may be considered in patients with history of e.g. peritonitis (17). The ports are then usually placed about 2cm lower than in the transperitoneal approach. After port placement the patient is placed in a 30 - 40 degrees Trendelenburg position (in case of extraperitoneal approach 20 degrees Trendelenburg is adequate) (28). The patient side cart of the robot is docked and the instruments are inserted under direct vision.

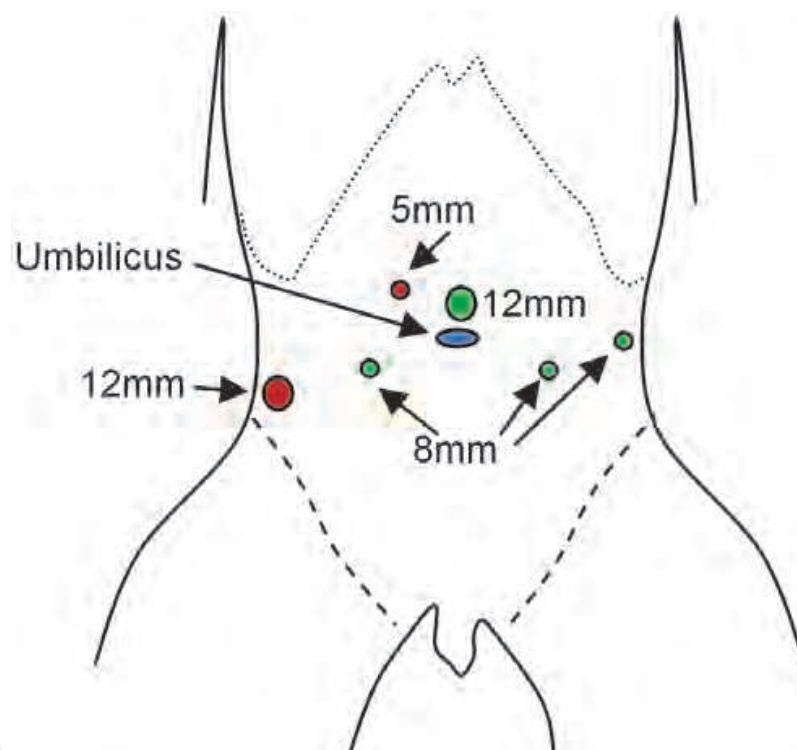


Fig. 1. Port placement

6. Preparation of cavum rectii and ventral aspect of the prostate

The preparation begins in the midline, close to the umbilicus, by incising the peritoneum and releasing the bladder from the ventral abdominal wall. On both sides the ligamenta umbilicale mediale are dissected after coagulation. The lateral limit of the preparation is the vas deferens at the crossing above the iliac artery. We use a monopolar scissor on the right hand as well as a P.K. dissector for preparation and bipolar coagulation on the left hand. On the third arm we use for retraction purposes a Prograsp. The procedure could also be performed with the use of only two robotic instrument arms, but leads to the need for a second assistant to apply the appropriate traction needed to the structures. In our opinion the use of all three robotic instrument arms is very useful. The preparation is then

continued to the pubic bone and the symphysis. The periprostatic fat is removed and separately send to the pathologist revealing in some cases lymph nodes.

7. Incision of the endopelvic fascia

The endopelvic fascia is prepared on both sides and incised, beginning at the base (figure 2). The pelvic floor muscles are separated on both sides from the prostate. In selected cases, the endopelvic fascia on the side where PCa was not detected through the biopsy, can be left intact. The incision of the endopelvic fascia allows better vision of the contour of the prostate and is in our hands preferred in most cases. The preparation is performed apically to the pubovesicle ligaments which are incised close to the prostate.

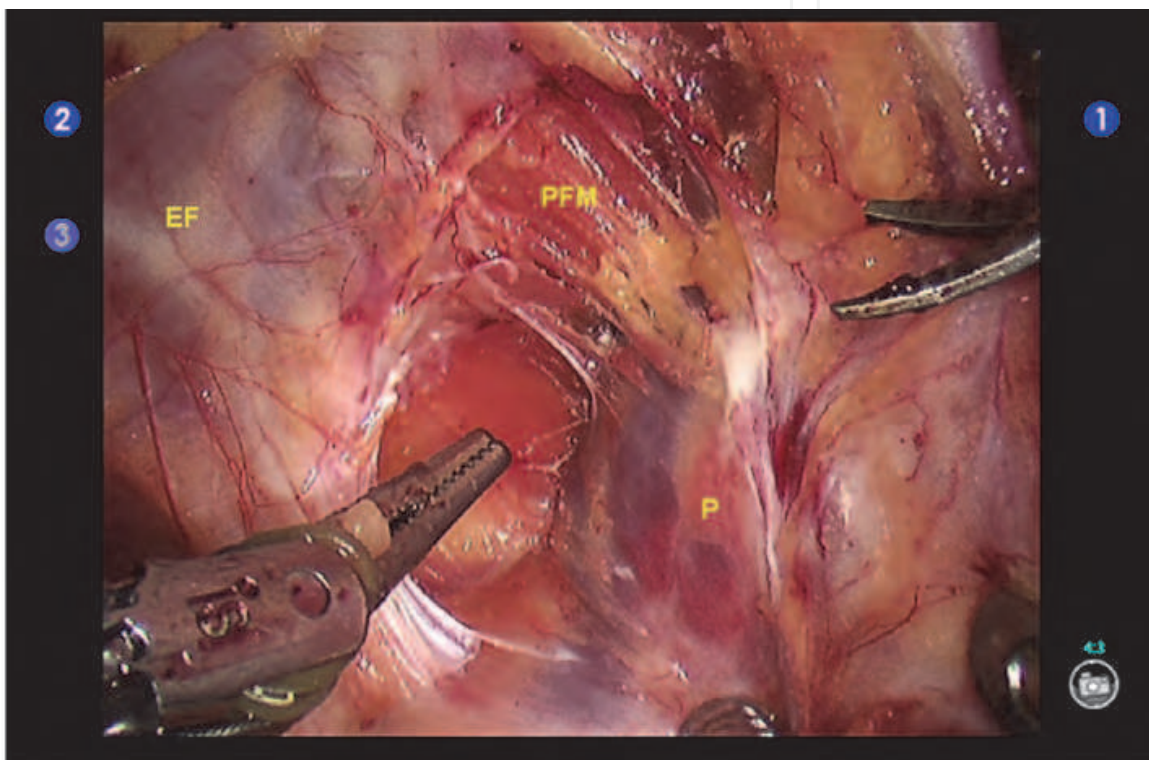


Fig. 2. Incision of the endopelvic fascia on the left side (EF = endopelvic fascia, PFM = pelvic floor muscle, P = Prostate)

8. Dorsal vascular complex

The dorsal vascular complex (DVC) is exposed and ligated with a 2/0 monofilic polyglyconate suture on a CT1 needle. Also stapling techniques or a none suturing techniques have been described (32). For better exposure of the apex during the further preparation and for less bleeding we prefer the suturing of the DVC.

9. Suspension stitch

With the same needle and suture we perform a suspension stitch of the DVC and the pubovesicle ligaments at the periest of the symphysis. Some authors found that this maneuver leads to a better result in early continence. Although the level of evidence for this

manoeuvre is not high, it could also be considered as a back up stitch for the DVC. Then a third stitch is additionally performed close to the bladder neck on the dorsal aspect of the prostate. This suture allows better visualization of the bladder neck for the preparation that follows.

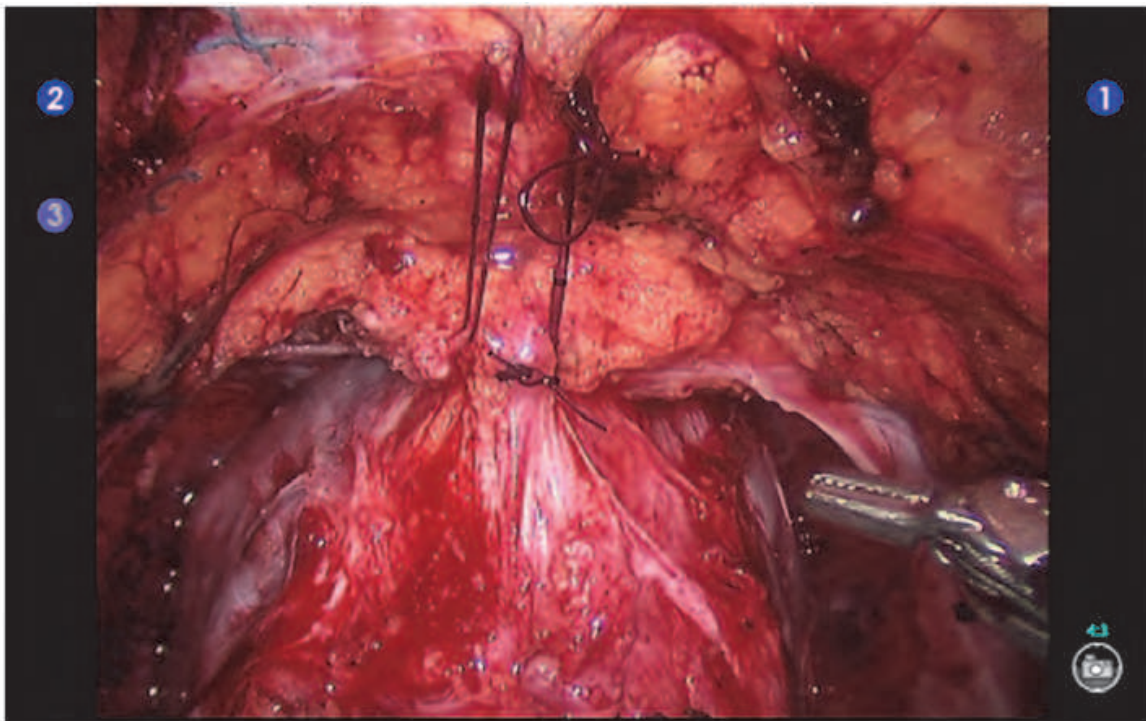


Fig. 3. Suspension stitch

10. Bladder neck preparation

The preparation is now continued between the prostate and bladder. The bladder neck is exposed by identifying its longitudinal muscular fibers. Lateral to the bladder neck, veins of the DVC can be identified and coagulated or clipped. We usually use 5 or 10 mm Hemolock clips. In most cases, arteries are also present lateral to the bladder neck, which can be as well coagulated or clipped. The Prograsp is in this step of the procedure a very useful device by keeping traction on the bladder in the cranial direction. In most cases a bladder neck sparing procedure is possible (14). After preparation of the bladder neck, the bladder neck is dorsally incised and the catheter elevated ventrally above the symphysis. Then the dorsal aspect of the bladder neck is incised and the bladder released from the prostate. Incision of the prostate with median lobe should be excluded by identifying the "drop off" phenomenon (Figure 5). The view inside the bladder should be in the dorsal direction. If this is not the case a median lobe should be considered. In case of a bladder neck sparing procedure the orifices usually don't have to be identified. After previous TURP or in patients with a large median lobe, a bladder neck sparing procedure is not possible. Similar situations may be encountered in locally advanced cancers into the bladder. Excision of the bladder up to the orifices in order to achieve a negative surgical margin status is possible. In such cases a consecutively stenting of the ureters and bladder neck reconstruction may be necessary.

11. Preparation of the vas deferens and the seminal vesicles

After releasing the bladder from the prostate the vesicoprostatic muscle is identified. This structure has longitudinal fibers between the region of the trigonum and the prostate ventrally of the level of the vas deferens. Due to the fact that the neurovascular structures, which are important for the erectile function, may be close to the seminal vesicles, this muscle should be incised cold.

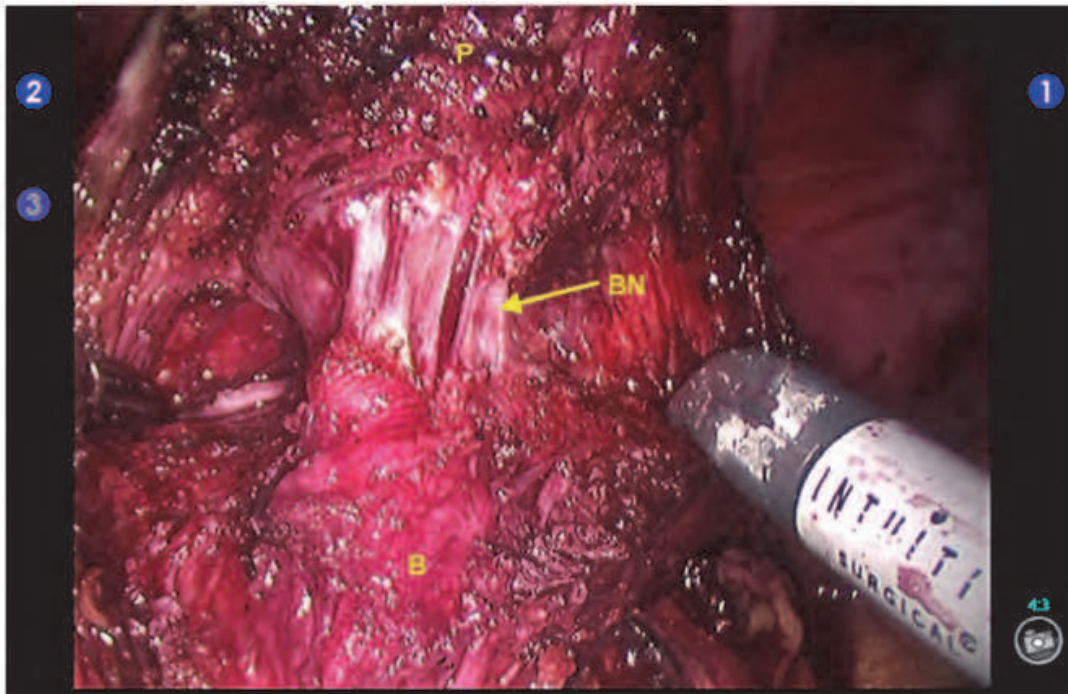


Fig. 4. Bladder neck preparation (B = bladder, BN = bladder neck, P = prostate)

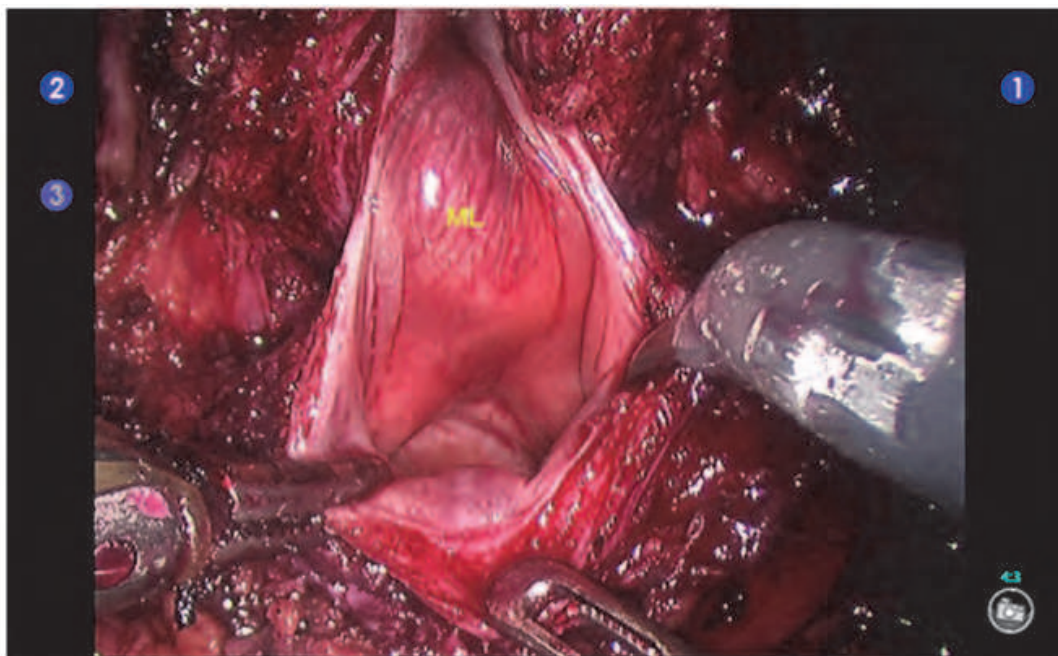


Fig. 5. Drop off (ML = median lobe)

Likewise, all further steps of the procedure are performed without the use of thermal energy to avoid damage of the neurovascular structures, especially in patients with a good erectile function. After the incision of the vesicle prostatic muscle the vas deferens can be identified and lifted up with the Prograsp. With this maneuver the preparation of the seminal vesicles is simplified (Figure 6). From the medial side of the vas deferens the seminal vesicle fascia can be incised and the preparation can be performed to the tips of the seminal vesicles. The vas deferens is then clipped and the seminal vesicle is lifted up in a ventral direction for further preparation. The vessels in the region of the tips of the seminal vesicles are clipped and divided. Preparation is performed on both sides laterally and until the base of the prostate is reached. Usually, laterally to the seminal vesicles, an additional small artery can be identified and should be clipped. Some authors have described the technique of leaving the tips of the seminal vesicles inside to protect the neurovascular structures at the tips of the seminal vesicle.

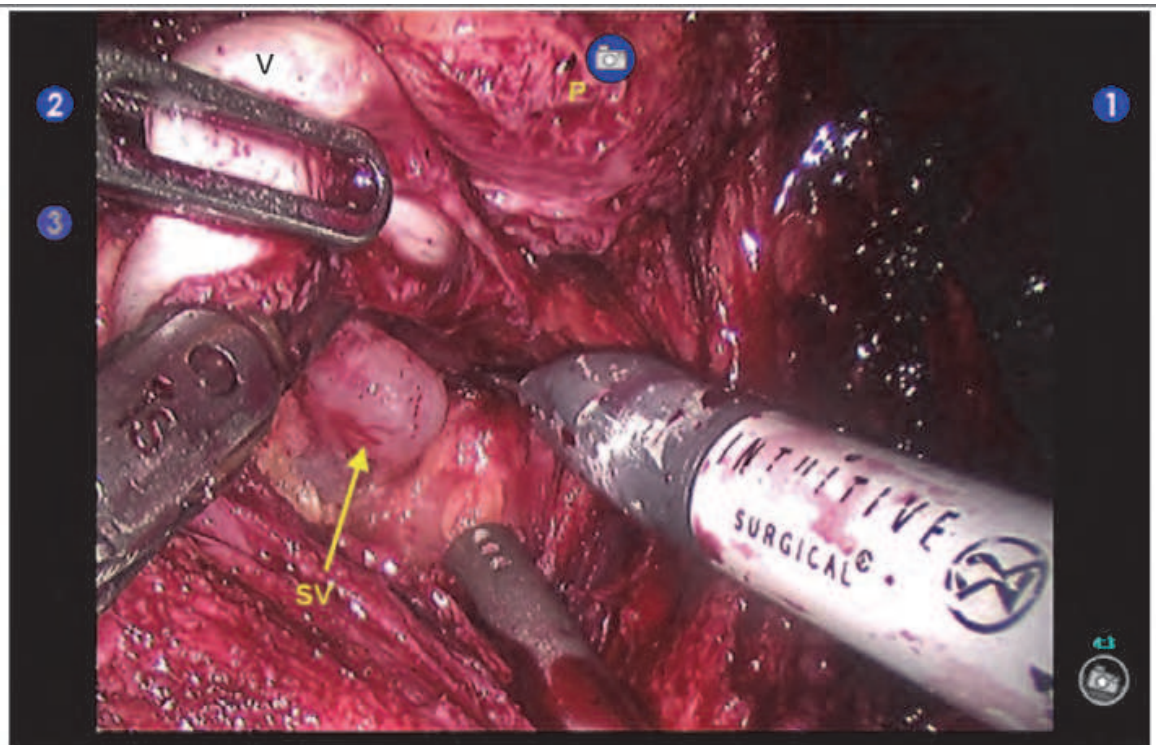


Fig. 6. Seminal vesical preparation on the left side (P = prostate, SV = seminal vesicle, V = Vas)

12. Dorsal preparation of the prostate

At this point the left seminal vesicle is pulled in cranioventrally direction with the Prograsp instrument, the same manoeuvre is performed with a French grasper by the assistant on the right side. The dorsal prostatic fascia, also known as the Denonvilliers fascia, is identified and incised. The dorsal prostatic fascia is in most situations a multilayer fascia and especially in low risk cancer situations can be left on the rectum. This technique gives an additional dorsally support which may help to achieve a good early continence situation. Preparation is performed until the apex of the prostate is reached.

13. Pedicles and neurovascular structures (bundle)

At this point the right base of the prostate is lifted with the Prograsp in left lateral direction and the right pedicle is exposed. In cases where a nerve sparing procedure is possible the lateral prostatic fascia is incised ventrally on the prostate and the preparation of the pedicle is performed close to the base of the prostate. The prostatic blood supply is identified and clipped. Afterwards the neurovascular structures are separated from the prostate by leaving the capsule of the prostate intact. These neurovascular structures are located on the lateral aspect of the prostate, often starting high ventrally and covering the prostate to the dorsal side. In most cases these important structures have the shape of a veil or sheath covering the whole lateral aspect of the prostate. In our opinion the term bundle should be avoided. In low risk patients the preparation can be performed close to the prostate in an interfascial approach (Figure 7), in medium risk patients the preparation can be performed in an interfascial way by leaving the small artery which travels laterodorsally on the prostate on the specimen. If an extraprostatic extension is visible or in high risk patients a wide resection of the neurovascular structures should be performed. Likewise, the same steps are performed on the left side. Here the Prograsp is used as a hook to retract the bladder. The tableside assistant uses the French grasper to lift the prostate in cranial and lateral direction. Alternatively the release of the neurovascular structures can be performed in a retrograde way, similar to the retropubic radical prostatectomy.

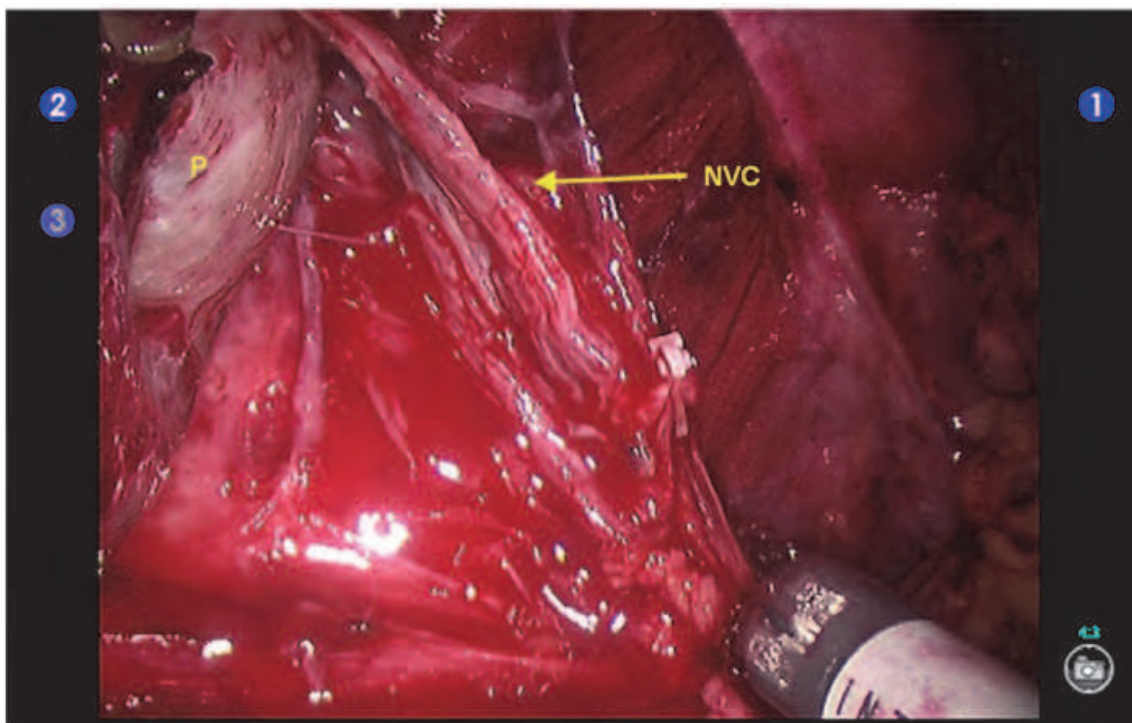


Fig. 7. Released neurovascular complex (NVC = neurovascular complex, P = prostate)

14. Apical dissection

At this point the prostate remains only fixed on the urethra and the dorsal vascular complex. Traction is supplied on the prostate in a cranially direction and the dorsal vascular complex is divided. It is of crucial importance to respect the shape of the prostate to preserve as much

as possible functional tissue of the urethra and the surrounding structures for good early continence and also late continence results (31). The urethra is exposed ventrally (Figure 8) and laterally on both sides and then incised on the ventrally half of the circumference. The catheter is removed and the dorsal part of the urethra divided. Remaining adhesions at the level of the dorsal prostatic fascia are finally divided. The specimen is then placed in a retrieval bag. In cases of lymph node dissection, the removal of the nodes can be performed prior to the anastomosis, thus allowing the placement of all dissected specimens in one retrieval bag.

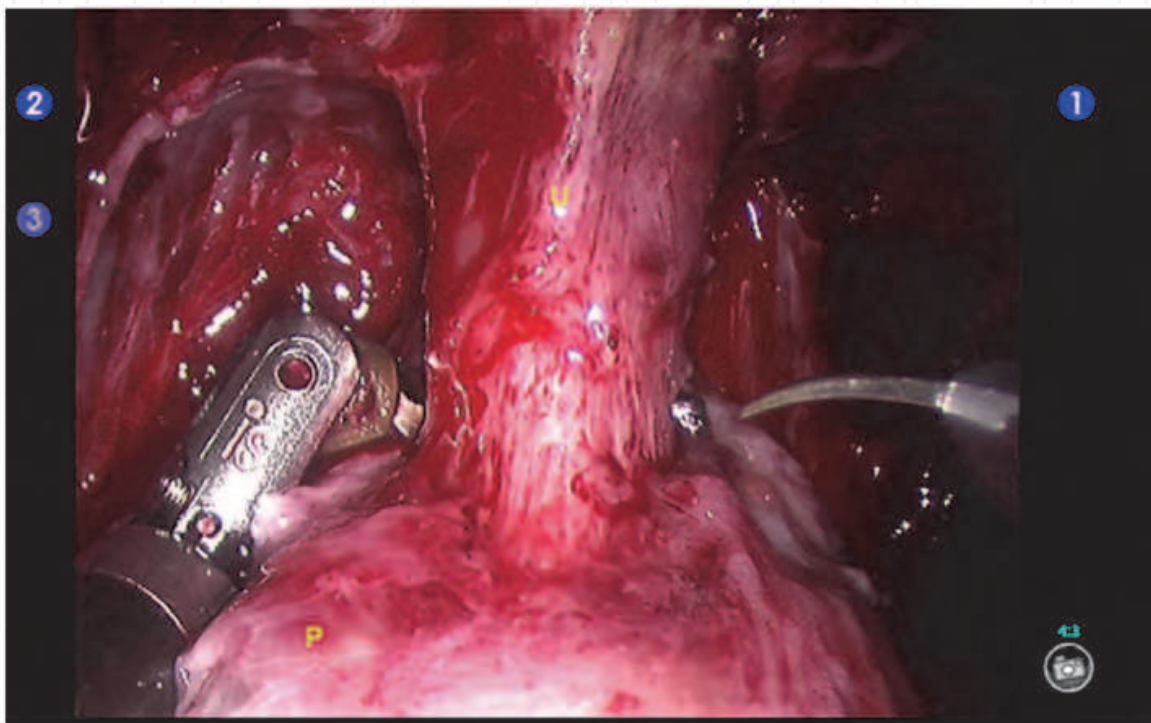


Fig. 8. Apical preparation (P = prostate, U = urethra)

15. Anastomosis

The anastomosis can be performed in a single knot technique or as preferred in our hands and most other institutions in a running suture technique. We use a 19cm double armed barbed suture (polyglyconate 4-0 on an RB1 needle). The first two stitches of the anastomosis are performed at 5 o'clock on the bladder, followed by a stitch at the urethra at 5 o'clock in an inside-out fashion followed by a 6 o'clock stitch outside-in on the bladder, followed by a stitch on the same position at the urethra. After performing a third stitch on the bladder side at 7 o'clock the bladder is approximated to the urethra. In order to achieve a better dorsal stabilization, the dorsal prostatic fascia at the urethral side as well as at the level of the seminal vesicles, is also included during anastomosis (dorsal reconstruction).

A dorsal reconstruction can be also performed solitary. Nevertheless, when comparing both techniques we did not find any differences in postoperative continence results as well as strictures or leakage at day 3-5. The anastomosis is then continued on the left side up to approximately 11 o'clock. The barbed wire can be pulled only in one direction so the approximation of the structures is easier to perform. Alternatively the use of a monofilic

polyglyconate suture (3-0) is also possible. Afterwards the right side part of the anastomosis is performed in a similar fashion. The two parts of the suture are then knotted together to complete the anastomosis. At the end of the procedure checking of all possible bleeding sites after reducing the intraabdominal pressure should be performed. We also check the anastomosis by filling the bladder with 200cc of saline. If there is any doubt that the anastomosis might be insufficient, a drain should be placed, in all other cases this is not necessary.

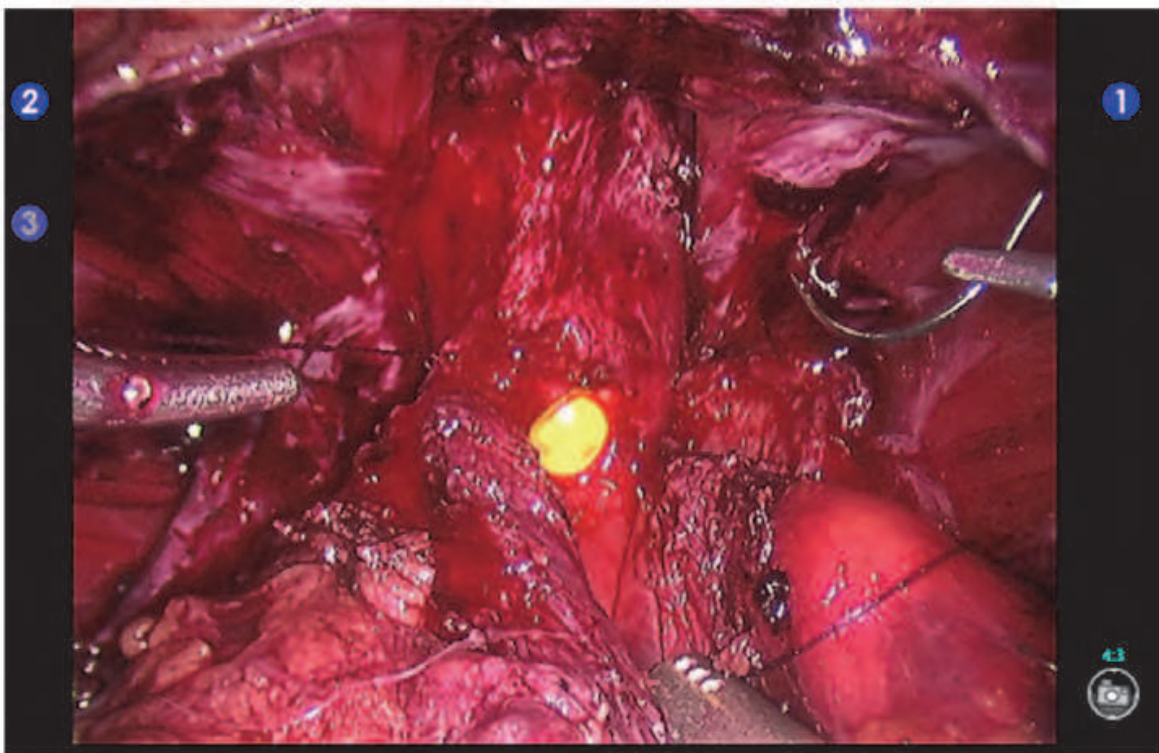


Fig. 9. Anastomosis: left side complete, beginning of the right side.

16. Special considerations

16.1 Bladder neck reconstruction

In cases where a bladder neck sparing procedure is not possible and the bladder neck is wide, a bladder neck reconstruction is necessary. This is often the case after TURP and may also be evident in a large median lobe or in advanced cancer situations with the need of a partial bladder excision. Although several techniques of bladder neck reconstruction have been described, it can be performed in a tennis-racket fashion like as in open surgery, ventrally at the end of the anastomosis or, as we prefer, lateral on both sides. Alternatively also a ventral bladder neck reconstruction is possible. In our opinion the most important goal of the bladder neck reconstruction is not the adjustment of the diameter of the bladder neck to the urethra but the lateralization of the orifices from the anastomosis. For this reason we prefer a both side lateral bladder neck reconstruction beginning on each lateral aspects of the bladder neck in a continuous fashion with 3-0 polyglyconate monofilic suture. In this running suture technique the orifices will be lateralized from the side of the anastomosis.

16.2 Stenting of the ureters

In situations where it is necessary to resect the bladder near to the orifices a stenting of the ureters should be considered. This could be done easily by placing a hydrophilic stiff guide wire into the ureter up to the pyelon and stenting the ureter afterwards with the double J-stent. The aforementioned described bladder neck reconstruction should be performed afterwards. The stent could be left in place for 2 - 4 weeks or could also be removed after the bladder neck reconstruction has been performed.

17. Lymph node dissection

In situations where lymph node dissection is necessary, the nodes can be removed at the beginning of the procedure, before performing the anastomosis or at the end of the procedure. We usually perform the lymph node dissection after the removing of the prostate, this allows us to use a possible waiting time for frozen sections to perform the lymph node dissection. The lymph nodes on the external iliac artery, the external iliac vein and the fossa obturatoria are removed. The lymphatic vessels should be clipped. In T3 cancers also an extended lymph node dissection up to the aortic bifurcation could be easily performed in a transperitoneal approach (42). Care should be taken of the obturator nerve, the ureters and additional obturatoric vessels which can be found in many cases.

18. Postoperative care

At the end of the procedure we change the transurethral catheter, in selected cases also a suprapubic tube could be inserted and the transurethral catheter can be removed on the first postoperative day. The patient should be mobilized on the day of surgery, on the first postoperative day the time of mobilization should reach 6 hours. All drains and i.v. tubes are removed on day one in most of the patients. Only the transurethral catheter is left in place. By suturing the skin and with an additional gluing of the skin the patient can take a shower on the first postoperative day. The patient can be discharged from the medical point of view on postoperative day 1 (38). We usually discharge the patient on day 6 postoperatively after removing of the catheter on day 5. We also perform routinely a cystogram, but with a extravasation rate of lower than 3% a cystogram can also be reserved for special situations. We administer a laxans on postoperative day 1 and also prescribe pelvic floor exercises. The patient is advised avoiding heavy lifting (more than 10kg) and cycling for 4 weeks.

19. Complications

19.1 Intraoperative complications

A bowel lesion, especially in patients who have a history of prior surgery, may occur and can be repaired by suturing easily. Rectal injuries, a typical complication observed in retroperitoneal RP, is very rare with an incidence of less than 0.2% in our series. In case of a small bowel or a rectal injury and an intraoperative repair we place a drain, but don't change the postoperative procedure.

Intraoperative lesion of iliac vein or artery can be repaired directly and the repair is robotic-assisted usually no problem.

Clipping of the obturator nerve during lymphadenectomy may happen, especially on the left side, titanium clips can be removed easily, Hemolock clips must be cut with a hook scissor on the opposite end of the lock. If this is done no permanent damage of the nerve will occur.

At the end of the procedure all possible sites of bleeding (pedicles, dorsal vascular complex, and iliac vessels) should be checked before undocking the robot by reducing the intraperitoneal pressure to zero. The trocars should be removed under direct visions to check for bleeding from trocar sites. All trocar sites larger than 8mm should be closed at the level of the fascia. This avoids port-site hernias.

19.2 Postoperative complications

19.2.1 Urinary extravasation

If the cystogram shows an extravasation the catheter is left inside for additional 10 days, the catheter can then be removed with or without an additional cystogram (8). If there is a large urinary extravasation with urine in the peritoneal cavity there is a high risk of peritonitis, in these cases a stenting of the ureters and maybe an additional percutaneous drainage of the ureters may be necessary. If there is any doubt of a urinary peritonitis this should be performed immediately. Depending on the case, and although endoscopic management of this situation is possible, open surgery should also be considered.

19.2.2 Postoperative bleeding

In hemodynamic instable patients a postoperative bleeding should be considered and can be evaluated by ultrasound or CT-scan (8). Laparoscopic, robotic assisted or open revision may be necessary to remove the hematoma and take care of the bleeding.

19.2.3 Postoperative subileus

In about 5% of the patients, bowel movement back to normal conditions is delayed (30). This could be avoided by earlier mobilization of the patient, oral fluid intake of about 2.5 litres per day and administering a laxative. In our series, the need of surgical intervention for this phenomenon was never observed.

19.2.4 Early port hernia

Port-site hernias lead to pain at the site of the hernia and could be diagnosed with a CT-scan (25). Open or laparoscopic repair is necessary. We never encountered early port-site hernias since we close the fascia in all ports larger than 8mm.

19.2.5 Late port hernias

Late port-site hernias may occur especially in the site of the specimen removal, usually a mesh repair is required (24).

19.2.6 Non-recognized bowel injuries

The clinical symptoms of an unrecognized bowel injury are often milder than in open surgery. Pain and tension is often found in the port-site close to the injury (13). Open surgical repair is usually required.

20. Conclusion

Robotic assisted radical prostatectomy is a widely used and standardized procedure with excellent oncological and functional results, especially in experienced hands (9,19). The magnification of 10 to 20 times, the excellent degrees of freedom for movement of the

instruments and the intuitive handling of the machine are advantages compared with the open or standard laparoscopic approaches (7,27,33,36). Although evidence for better oncological and functional results are still unproven robotic assisted radical prostatectomy (1,3,15,21,26,39) is in many countries now the standard of care for the surgical removal of the prostate (4,6,22). Transfusion rates are lower and return to normal activity is shorter in RARP (5,16,20). In addition, complex situations like salvage RP or a history of rectum extirpation are no longer a contraindication for RARP (11,18).


In the future the development of new instruments and the possibility of the use of simultaneous imaging will lead to more possibilities and maybe also to better results.

21. References

- [1] Atug F, Castle EP, Woods M, Srivastav SK, Thomas R, Davis R. Transperitoneal versus extraperitoneal robotic-assisted radical prostatectomy: is one better than the other? *Urology*. 2006 Nov;68(5):1077-81.
- [2] Badani KK, Kaul S, Menon M. Evolution of robotic radical prostatectomy: assessment after 2766 procedures. *Cancer*. 2007 Nov 1;110(9):1951-8.
- [3] Barocas DA, Salem S, Kordan Y, Herrell SD, Chang SS, Clark PE, Davis R, Baumgartner R, Phillips S, Cookson MS, Smith JA Jr. Robotic assisted laparoscopic prostatectomy versus radical retropubic prostatectomy for clinically localized prostate cancer: comparison of short-term biochemical recurrence-free survival. *J Urol*. 2010 Mar;183(3):990-6.
- [4] Bolenz C, Gupta A, Hotze T, Ho R, Cadeddu JA, Roehrborn CG, Lotan Y. Cost comparison of robotic, laparoscopic, and open radical prostatectomy for prostate cancer. *Eur Urol*. 2010 Mar;57(3):453-8.
- [5] Carmignani L, Pavesi M, Picozzi S. Comparison of transfusion requirements between open and robotic-assisted laparoscopic radical prostatectomy. *BJU Int*. 2011 Mar;107(5):853-4
- [6] Cathelineau X, Sanchez-Salas R, Barret E, Rozet F, Vallancien G. Is laparoscopy dying for radical prostatectomy? *Curr Urol Rep*. 2008 Mar;9(2):97-100.
- [7] Coelho RF, Chauhan S, Palmer KJ, Rocco B, Patel MB, Patel VR. Robotic-assisted radical prostatectomy: a review of current outcomes. *BJU Int*. 2009 Nov;104(10):1428-35.
- [8] Coelho RF, Palmer KJ, Rocco B, Moniz RR, Chauhan S, Orvieto MA, Coughlin G, Patel VR. Early complication rates in a single-surgeon series of 2500 robotic-assisted radical prostatectomies: report applying a standardized grading system. *Eur Urol*. 2010 Jun;57(6):945-52.
- [9] Correa JJ, Pow-Sang JM. Optimizing cancer control and functional outcomes following robotic prostatectomy. *Cancer Control*. 2010 Oct;17(4):233-44.
- [10] Douaihy YE, Sooriakumaran P, Agarwal M, Srivastava A, Grover S, Mudaliar K, Rajan S, Lawlor A, Leung R, Tewari A. A cohort study investigating patient expectations and satisfaction outcomes in men undergoing robotic assisted radical prostatectomy. *Int Urol Nephrol*. 2010 Aug 11. [Epub ahead of print]
- [11] Eandi JA, Link BA, Nelson RA, Josephson DY, Lau C, Kawachi MH, Wilson TG. Robotic assisted laparoscopic salvage prostatectomy for radiation resistant prostate cancer. *J Urol*. 2010 Jan;183(1):133-7

- [12] Finkelstein J, Eckersberger E, Sadri H, Taneja SS, Lepor H, Djavan B. Open Versus Laparoscopic Versus Robot-Assisted Laparoscopic Prostatectomy: The European and US Experience. *Rev Urol*. 2010 Winter;12(1):35-43.
- [13] Fischer B, Engel N, Fehr JL, John H. Complications of robotic assisted radical prostatectomy. *World J Urol*. 2008 Dec;26(6):595-602.
- [14] Freire MP, Weinberg AC, Lei Y, Soukup JR, Lipsitz SR, Prasad SM, Korke F, Lin T, Hu JC. Anatomic bladder neck preservation during robotic-assisted laparoscopic radical prostatectomy: description of technique and outcomes. *Eur Urol*. 2009 Dec;56(6):972-80.
- [15] Frota R, Turna B, Barros R, Gill IS. Comparison of radical prostatectomy techniques: open, laparoscopic and robotic assisted. *Int Braz J Urol*. 2008 May-Jun;34(3):259-68
- [16] Gainsburg DM, Wax D, Reich DL, Carlucci JR, Samadi DB. Intraoperative management of robotic-assisted versus open radical prostatectomy. *JSL*. 2010 Jan-Mar;14(1):1-5.
- [17] Gettman MT, Hoznek A, Salomon L, Katz R, Borkowski T, Antiphon P, Lobontiu A, Abbou CC. Laparoscopic radical prostatectomy: description of the extraperitoneal approach using the da Vinci robotic system. *J Urol*. 2003 Aug;170(2 Pt 1):416-9.
- [18] Ginzburg S, Hu F, Staff I, Tortora J, Champagne A, Salner A, Shichman SJ, Kesler SS, Wagner JR, Laudone VP. Does prior abdominal surgery influence outcomes or complications of robotic-assisted laparoscopic radical prostatectomy? *Urology*. 2010 Nov;76(5):1125-9. Epub 2010 Aug 13.
- [19] Herrell SD, Smith JA Jr. Robotic-assisted laparoscopic prostatectomy: what is the learning curve? *Urology*. 2005 Nov;66(5 Suppl):105-7.
- [20] Kordan Y, Barocas DA, Altamar HO, Clark PE, Chang SS, Davis R, Herrell SD, Baumgartner R, Mishra V, Chan RC, Smith JA Jr, Cookson MS. Comparison of transfusion requirements between open and robotic-assisted laparoscopic radical prostatectomy. *BJU Int*. 2010 Oct;106(7):1036-40.
- [21] Laurila TA, Huang W, Jarrard DF. Robotic-assisted laparoscopic and radical retropubic prostatectomy generate similar positive margin rates in low and intermediate risk patients. *Urol Oncol*. 2009 Sep-Oct;27(5):529-33.
- [22] Lowrance WT, Tarin TV, Shariat SF. Evidence-based comparison of robotic and open radical prostatectomy. *ScientificWorldJournal*. 2010 Nov 16;10:2228-37. Review.
- [23] McCullough TC, Barret E, Cathelineau X, Rozet F, Galiano M, Vallancien G. Role of robotics for prostate cancer. *Curr Opin Urol*. 2009 Jan;19(1):65-8.
- [24] Murphy D, Challacombe B, Elhage O, Dasgupta P. Complications in robotic urological surgery. *Minerva Urol Nefrol*. 2007 Jun;59(2):191-8.
- [25] Murphy DG, Kerger M, Crowe H, Peters JS, Costello AJ. Operative details and oncological and functional outcome of robotic-assisted laparoscopic radical prostatectomy: 400 cases with a minimum of 12 months follow-up. *Eur Urol*. 2009 Jun;55(6):1358-66.
- [26] Ou YC, Yang CR, Wang J, Cheng CL, Patel VR. Comparison of robotic-assisted versus retropubic radical prostatectomy performed by a single surgeon. *Anticancer Res*. 2009 May;29(5):1637-42.
- [27] Patel VR, Coelho RF, Chauhan S, Orvieto MA, Palmer KJ, Rocco B, Sivaraman A, Coughlin G. Continence, potency and oncological outcomes after robotic-assisted radical prostatectomy: early trifecta results of a high-volume surgeon. *BJU Int*. 2010 Sep;106(5):696-702.

- [28] Phong SV, Koh LK. Anaesthesia for robotic-assisted radical prostatectomy: considerations for laparoscopy in the Trendelenburg position. *Anaesth Intensive Care*. 2007 Apr;35(2):281-5.
- [29] Scales CD Jr, Jones PJ, Eisenstein EL, Preminger GM, Albala DM. Local cost structures and the economics of robot assisted radical prostatectomy. *J Urol*. 2005 Dec;174(6):2323-9.
- [30] Sharma NL, Shah NC, Neal DE. Robotic-assisted laparoscopic prostatectomy. *Br J Cancer*. 2009 Nov 3;101(9):1491-6.
- [31] Shikanov SA, Eng MK, Bernstein AJ, Katz M, Zagaja GP, Shalhav AL, Zorn KC. Urinary and sexual quality of life 1 year following robotic assisted laparoscopic radical prostatectomy. *J Urol*. 2008 Aug;180(2):663-7.
- [32] Singh I, Hemal AK. Robotic-assisted radical prostatectomy in 2010. *Expert Rev Anticancer Ther*. 2010 May;10(5):671-82.
- [33] Srivastava A, Grover S, Sooriakumaran P, Joneja J, Tewari AK. Robotic-assisted laparoscopic prostatectomy: a critical analysis of its impact on urinary continence. *Curr Opin Urol*. 2011 May;21(3):185-94.
- [34] Starnes DN, Sims TW. Care of the patient undergoing robotic-assisted prostatectomy. *Urol Nurs*. 2006 Apr;26(2):129-36.
- [35] Sterrett SP, Jarrard DF. Robotic assisted laparoscopic radical prostatectomy: evolution and outcomes. *Minerva Urol Nefrol*. 2008 Mar;60(1):31-9.
- [36] Shikanov SA, Zorn KC, Zagaja GP, Shalhav AL. *Urology*. 2009 Sep;74(3):619-23. Trifecta outcomes after robotic-assisted laparoscopic prostatectomy.
- [37] Walz J, Burnett AL, Costello AJ, Eastham JA, Graefen, M, Guilloneau, B, Manon, M, Montorsi, F, Myers RP, Rocco B, Villers A. A critical analysis of the current knowledge of surgical anatomy to optimization of cancer control and preservation of continence and erection in candidates for radical prostatectomy. *European Urology* 2010, (57) 179-192.
- [38] Watts R, Botti M, Beale E, Crowe H, Costello AJ. Patient outcomes in the acute recovery phase following robotic-assisted prostate surgery: a prospective study. *Int J Nurs Stud*. 2009 Apr;46(4):442-9.
- [39] Williams SB, Hu JC. Salvage robotic assisted laparoscopic radical prostatectomy: indications and outcomes. *World J Urol*. 2010 Nov 21. [Epub ahead of print]
- [40] Wilson T, Torrey R. Open versus robotic-assisted radical prostatectomy: which is better? *Curr Opin Urol*. 2011 May;21(3):200-5.
- [41] Wolfram M, Bräutigam R, Engl T, Bentas W, Heitkamp S, Ostwald M, Kramer W, Binder J, Blaheta R, Jonas D, Beecken WD. Robotic-assisted laparoscopic radical prostatectomy: the Frankfurt technique. *World J Urol*. 2003 Aug;21(3):128-32.
- [42] Yee DS, Katz DJ, Godoy G, Nogueira L, Chong KT, Kaag M, Coleman JA. Extended pelvic lymph node dissection in robotic-assisted radical prostatectomy: surgical technique and initial experience. *Urology*. 2010 May;75(5):1199-204.



Laparoscopy - An Interdisciplinary Approach

Edited by Dr. Ivo Meinhold-Heerlein

ISBN 978-953-307-299-9

Hard cover, 146 pages

Publisher InTech

Published online 12, September, 2011

Published in print edition September, 2011

Over the last decades an enormous amount of technical advances was achieved in the field of laparoscopy. Many surgeons with surgical, urological, or gynaecological background have contributed to the improvement of this surgical approach which today has an important and fixed place in the daily routine. It is therefore comprehensible to compose a book entitled laparoscopy serving as a reference book for all three disciplines. Experts of each field have written informative chapters which give practical information about certain procedures, indication of surgery, complications and postoperative outcome. Wherever necessary, the appropriate chapter is illustrated by drawings or photographs. This book is advisable for both beginner and advanced surgeon and should find its place in the libraries of all specialties – surgery, urology, and gynecology.

How to reference

In order to correctly reference this scholarly work, feel free to copy and paste the following:

Jorn H Witt, Vahudin Zugor, Christian Wagner, Andreas Schutte and Apostolos P Labanaris (2011). Robot-Assisted Radical Prostatectomy, Laparoscopy - An Interdisciplinary Approach, Dr. Ivo Meinhold-Heerlein (Ed.), ISBN: 978-953-307-299-9, InTech, Available from: <http://www.intechopen.com/books/laparoscopy-an-interdisciplinary-approach/robot-assisted-radical-prostatectomy>

INTECH
open science | open minds

InTech Europe

University Campus STeP Ri
Slavka Krautzeka 83/A
51000 Rijeka, Croatia
Phone: +385 (51) 770 447
Fax: +385 (51) 686 166
www.intechopen.com

InTech China

Unit 405, Office Block, Hotel Equatorial Shanghai
No.65, Yan An Road (West), Shanghai, 200040, China
中国上海市延安西路65号上海国际贵都大饭店办公楼405单元
Phone: +86-21-62489820
Fax: +86-21-62489821

© 2011 The Author(s). Licensee IntechOpen. This chapter is distributed under the terms of the [Creative Commons Attribution-NonCommercial-ShareAlike-3.0 License](#), which permits use, distribution and reproduction for non-commercial purposes, provided the original is properly cited and derivative works building on this content are distributed under the same license.

IntechOpen

IntechOpen