

We are IntechOpen, the world's leading publisher of Open Access books Built by scientists, for scientists

4,800

Open access books available

122,000

International authors and editors

135M

Downloads

Our authors are among the

154

Countries delivered to

TOP 1%

most cited scientists

12.2%

Contributors from top 500 universities



WEB OF SCIENCE™

Selection of our books indexed in the Book Citation Index
in Web of Science™ Core Collection (BKCI)

Interested in publishing with us?
Contact book.department@intechopen.com

Numbers displayed above are based on latest data collected.
For more information visit www.intechopen.com



Gastrointestinal Complications of Abdominal Aortic Aneurysms

Emmeline Nugent and Paul Neary
*National Surgical Training Centre, Royal College of Surgeons in Ireland
Ireland*

1. Introduction

Although the gastrointestinal complications that occur secondary to repair of an aortic abdominal aneurysm (AAA) are uncommon they are associated with a significant increase in patient morbidity and mortality and therefore they warrant discussion. The gastrointestinal complications that we plan to review in detail in this chapter are ischaemic colitis, abdominal compartment syndrome, secondary aorto-enteric fistula, chylous ascites and ileus. We are also going to briefly discuss peptic ulcer disease, acute cholecystitis and acute pancreatitis and their relationship with AAA surgery.

Throughout the chapter we describe the incidence, aetiology, pathology, associated risk factors, diagnosis and management for each potential gastrointestinal complication in an evidence based manner.

Over the last two decades a new technique, endovascular surgery (EVAR), has been introduced as an alternative option for the management of an abdominal aortic aneurysm. The traditional approach, open repair, has long been regarded as a durable, effective procedure that is associated with a low rate of rupture with long-term follow up. However, the evolution of endovascular surgery has promised benefits when compared to the traditional approach. The advantages of the endovascular approach include a faster recovery time post-operatively and a reduction in the morbidity and mortality rates that occur with this condition. It also allows elderly patients and patients with co-morbidities that previously would have been considered unfit for surgery to undergo aneurysm repair in a safe manner. As part of our review of gastrointestinal complications following AAA repair, in this chapter we examine the impact, if any, that endovascular surgery has had on the type and frequency of these complications since its introduction.

2. Ischaemic colitis

2.1 Incidence

Ischaemic colitis is an infrequent but devastating complication following AAA repair. The intestinal mucosa is very sensitive to ischaemia and a sufficient reduction in blood flow can lead to this damaging condition. In ischaemic colitis it is only the mucosa of the bowel that is injured, the full thickness of the bowel wall remains unharmed.

The incidence of ischaemic colitis post open and elective repair of AAA is 1-3% (Van et al, 2000). The incidence following EVAR is similar. However the risk of ischaemic colitis

increases to 10% in cases of open repair of a ruptured AAA. If routine post-operative colonoscopy is performed to screen for this condition the rate of detection dramatically rises to 9% for elective repair and has been reported to be found in up to 60% of patients following surgery for a ruptured aneurysm (Chen et al, 1996).

2.2 Aetiology

Any reduction in blood flow to the bowel wall mucosa can result in ischaemic colitis. With surgery for an AAA a reduction in blood flow can occur secondary to a reduction in circulating blood volume which can result, for example, due to blood loss or in a state of low cardiac output. Vasoconstriction of the splanchnic circulation occurring as part of the physiological response of the body to shock or due to the administration of vasopressive medication also results in a reduction of blood flowing to the bowel mucosa. Occlusion of the inferior mesenteric artery (IMA) or the internal iliac artery can lead to a reduction in blood flow to the bowel wall. This can arise due to external compression that occurs during operative repair, for example trauma caused by retraction, the intentional occlusion of the IMA that is associated with EVAR, or due to thrombus formation, arthero-embolisation or a haematoma formation.

In endovascular repair it has been proposed that ischaemic colitis could be attributed to the dislodgement of debris from the sac of the aneurysm during wire and graft manipulation. It has been suggested however, that the EVAR approach may reduce the severity of ischaemic colitis but there is currently a lack of conclusive data to support this (Elmarsay et al, 2000). Certainly a recent study has shown that there is at the very least no significant difference in the rates of ischaemic colitis following the open and EVAR approach (Bosch et al, 2010).

2.3 Pathology

During the fasting state the gastrointestinal tract only receives 20% of the overall cardiac output. This increases to 35% post-prandially, and of this, the mucosa receives 70% of the blood supply. The colon differs from the small bowel structurally, a difference that accounts for its greater susceptibility to a reduced blood flow volume. Firstly the sub-mucosal vascular plexuses are much more extensive in the small bowel when compared to the large bowel and secondly the large bowel has no villi and therefore it has no counter-current mechanism. In the case of hypotension or with a low cardiac output the micro-vascular arcades are the ones to suffer as they are (i) the last to get blood and (ii) in cases of shock the physiological response is to shunt blood away from the splanchnic circulation. The splenic flexure in particular is vulnerable to ischaemia as it is part of the "watershed" area - this is the area of the colon where the superior mesenteric artery and IMA both supply but are reliant on collaterals to bridge the gaps in-between. Within a fifteen minute window a reduction in blood flow leading to ischaemia can demonstrate structural changes in the mucosa. After three hours mucosal sloughing will be evident and after six hours transmural necrosis will manifest.

There are two main factors that cause structural damage, (i) hypoxia, due to a reduction in blood flow and (ii) reperfusion injury.

There are three steps in the pathophysiological process leading to ischaemic colitis; fluid loss, reperfusion injury and vasoconstriction of the splanchnic vasculature.

1. Fluid Loss: The amount of fluid lost during aortic surgery is considerable. Animal experiments have demonstrated that up to a third of circulating fluid (plasma) may be

lost after superior mesenteric artery occlusion (Geroulakos & Cherry, 2002). With a reduction in blood flow, the injured bowel loses its absorptive function while the crypt cells are spared and continue to secrete. Intraluminal exudation causes a further reduction in blood volume and distension of the bowel wall. The bowel becomes oedematous and there is transudation of fluid into the peritoneal cavity. When the arterial flow is then restored and blood flow returns to the gastrointestinal tract reactionary haemorrhage can occur into the bowel lumen.

2. Reperfusion injury: Anaerobic metabolism and acidosis trigger an inflammatory cascade. The main damaging effects of activating this cascade are caused by the production of free radicals (superoxide, peroxide and hydroxyl). The colonic mucosa is rich in the enzyme xanthine dehydrogenase which results in the production of reactive oxygen species and free radicals. The release of these free radicals causes a release of cytokines and platelet activating factor, which in turn activate and stimulate the release of monocytes, neutrophils and endothelin 1 (ET-1), which is a potent vasoconstrictor. The activation of polymorphonuclear leukocytes causes a systemic inflammatory response. The final result is end organ damage affecting the respiratory system, the renal system and leading to bone marrow failure. Further massive losses of fluid volume could result from disseminated intravascular coagulation (DIC) and the widespread increase in vascular permeability that this can bring.
3. Splanchnic vasoconstriction: Vasoconstriction can persist following revascularisation rendering perfusion inadequate.

The ischaemic colon loses its barrier function rapidly leading to invasion by luminal bacteria and endotoxin absorption. This takes place over a period of at least 24 hours. The mucosa sloughs off into the lumen which causes peristalsis, diarrhoea and bleeding. In the most severe of cases it leads to portal pyaemia and death. Less severe cases result in multi-organ damage and failure.

Three progressive stages of ischemic colitis are described (i) Grade 1: transient mucosal ischaemia, (ii) Grade II: mucosal and muscularis involvement which may result in healing with fibrosis and stricture formation (iii) Grade III: transmural ischaemia and infarction which results in gangrene and perforation. The mortality rate reaches 90% in patients with bowel infarction.

When comparing open surgery to EVAR it is likely that there is a different pathophysiological pattern at play. In EVAR there is no manipulation of the bowel which reduces the risk of trauma. As a result abdominal hypertension and compartment syndrome as a cause of ischaemic colitis is unlikely. Reperfusion injury to the bowel is also unlikely as the period of time during the operation when the aorta is occluded is short. It had been thought that sacrificing the IMA may account for ischaemic colitis in endovascular repair. However, it is now believed that preserving IMA patency may not be as important as previously thought. With EVAR there is a risk of micro-embolisation due to dislodging the thrombus or the arteromatous plaque during wire and graft manipulation and placement.

2.4 Risk factors

There are a number of factors that have been established as associated with a greater chance of ischaemic colitis. They can be divided into pre, peri or intra and post-operative risk factors (table 1).

	Risk Factors
Pre-operative	Ruptured AAA
	Mean systolic blood pressure <80mmHg
	Length of time spent hypotensive
	High disease severity score
	Age
	Female
Peri or intra-operative	Blood loss >2000ml
	Operating time >4 hours
	Body temperature <35 degrees
	Length of time aorta is cross-clamped
	Hospital case volume
	Internal iliac artery ligation
	Aortobifemoral grafting
Post-operative	Renal impairment
	Neutrophilia
	Metabolic acidosis
	Ionotropic support
	Bloody diarrhoea

Table 1. Risk Factors for Ischaemic Colitis (Bjorck et al, 1996; Neary et al, 2007; Perry et al, 2008; Becquemin et al, 2008; Levison et al, 1999)

Patients undergoing emergency AAA repair or that develop shock peri-operatively are at the greatest risk of developing ischaemic colitis. Here the incidence increases from 1-3% to 30% (Levison et al, 1999).

The type of surgical approach has not been found to be an independent predictor of ischaemic colitis. This has been challenged in particular with respect to the patency of the IMA. IMA patency has been demonstrated not to be associated with an increased risk of ischaemic colitis (Senekowitsch et al, 2006). This has been shown in open surgery where routine re-implantation of the IMA was compared to no re-implantation and in EVAR where the IMA is routinely blocked off. To date the importance of hypogastric artery patency has not been established in both open and EVAR repair. However, it does seem that it is not emerging as a significant risk factor (Geraghty et al, 2004).

2.5 Diagnosis

Ischaemic colitis can be seen at the time of open AAA repair. When this occurs a colectomy may need to be performed and the overall outcome for the patient is generally poor.

The mean time to diagnosis ischaemic colitis post-operatively is 5.5 days. In patients where a bowel resection is required there is an overall mortality rate of 80-90%. The sigmoid colon is the most commonly affected segment of large bowel followed by the rectum.

Presenting features are often insidious and include diarrhoea which may or may not be bloody and abdominal pain out of keeping with the clinical signs. The diagnosis often requires a high index of suspicion with specific investigations to confirm it. A high index of

suspicion should be had in patients with persistent hypotension post-operatively, an elevated lactate, creatinine, leucocytes and other signs that point towards sepsis.

Features to be aware of on plain abdominal x-ray are non-specific and include; fluid levels, toxic colon dilation, intramural air and free air due to perforation. In severe clinical cases intra-portal air may be present. A barium enema may demonstrate thumb-printing which is present as a result of mucosal oedema. CT (contrast enhanced computed tomography) or MRI scans in the early stages may be normal or may show non-specific signs such as mucosal thickening or oedema. As ischaemic colitis progresses, scanning typically demonstrates a circumferential symmetrical wall thickening with fold enlargement. It may be useful to consider looking at the visceral arteries with MRA.

Endoscopy demonstrates a diagnostic accuracy of 92% (Assadian et al, 2008). But a histological diagnosis is the gold standard. On endoscopy there may be blood visible in the bowel lumen. If there is a suspicion that the colon may be ischaemic biopsies should be taken, even if the mucosa appears normal. In mild cases of ischaemic colitis the mucosa appears pale with petechiae, whereas in severe colitis the mucosa appears blue or black in colour and there may be slough or ulceration. Histological features on biopsy include; hyalinization of the lamina propria, atrophic appearing micro-crypts, lamina propria haemorrhage, full thickness mucosal necrosis and a diffuse distribution of pseudomembranes.

In the acute phase there is necrosis of the superficial epithelium and haemorrhage into the lamina propria. The intestinal crypts are spared. This stage is reversible, but it may progress. In the organising phase there is ulceration and associated granulation tissue formation without the presence of marked inflammatory changes. Iron deposits can be found also. The healed phase demonstrates architectural distortion of the crypts and a transmural fibrosis. Another diagnostic approach is an exploratory laparotomy.

In the setting of ischaemia these patients are at risk of developing pseudomembranous colitis. This is further exacerbated by the administration of prophylactic antibiotics.

Although postoperative clinical assessment with physical examination and laboratory tests is unreliable in predicting ischemic colitis, several intra-operative methods have demonstrated a certain degree of promise. These include inferior mesenteric artery stump pressure measurements, trans-serosal tissue oxygen tension measurements (tPO₂), laparoscopy, and tonometry. Pulse oximetry could be another potentially helpful tool to monitor the colon for evidence of ischaemia (Yilmaz et al, 1999). Of these assessments, selective ligation of the IMA on the basis of intraoperative bowel inspection, colonic mesenteric Doppler signals, and IMA stump pressure have been the most encouraging. However, these techniques detect intra-operative changes and they may not accurately reflect or predict subsequent ischemic events.

Colonoscopy remains the diagnostic procedure of choice for assessing ischemic colitis.

2.6 Management

Early detection and treatment of ischaemic colitis is very important. The condition if diagnosed in the initial stages can be reversed.

Conservative management of ischaemic colitis can be employed if the ischaemia is not transmural and there is no evidence of multi-organ damage, the patient is clinically stable and they have no signs of peritonitis. Grade I and II bowel ischaemia can be treated with antibiotic therapy, intravenous fluids, bowel rest, and surveillance colonoscopy. Grade III

ischaemia warrants an immediate laparotomy in an effort to decrease the mortality associated with this condition (Champagne et al, 2004). At laparotomy the ischaemic segment should be resected with both bowel ends being brought out as stomas. Patients that require an immediate laparotomy and bowel resection do worse in terms of outcome and have a significantly higher mortality risk. Surveillance colonoscopy is very important in the early grades of ischaemia and should be carried out at regular intervals as the ischaemia may become more extensive at any stage.

Although ischaemic colitis may be subclinical and only discovered on colonoscopy and biopsy it is still a significant condition, because despite resolution of the ischaemia, the gut mucosal barrier will have been altered. This allows the passage of bacteria and endotoxins into the portal circulation thereby causing sepsis and multi-organ failure. The true incidence of ischaemic colitis is probably much higher than the clinically evident incidence (Welch et al, 1998). Welch and colleagues performed a study where they scoped patients post-operative AAA repair and they found a very high rate of asymptomatic ischaemic colitis (30%) (Welch et al, 1998).

The monitoring of intra-abdominal pressure post-operatively is justified as an increase in intra-abdominal hypertension is associated with colonic ischaemia (Djavani et al, 2009). This approach can therefore allow early detection and treatment of ischaemic colitis. Another preventative approach, the effectiveness of which remains debatable is the role of re-implanting the IMA (Mitchell & Valentine, 2002). Arguments against this technique include the increased risk of bleeding from the anastomosis, the technically demanding nature of this procedure, and the increase in intra-operative time that it is associated with.

Major cardiac, respiratory and renal complications are associated with ischaemic colitis (Becquemin et al, 2008). Therefore it is easy to understand the seriousness of this gastrointestinal complication following AAA repair. A further complication of ischaemic colitis that presents at a late stage is a stricture of the colon. A stricture typically presents with features of subacute obstruction.

Overall there has been no difference in mortality demonstrated for ischaemic colitis occurring following open repair or endovascular surgery.

3. Abdominal Compartment Syndrome

3.1 Incidence

Abdominal compartment syndrome (ACS) occurs when a fixed compartment, defined by myofascial elements, becomes subject to increased pressure, leading to ischemia and organ dysfunction. ACS is the worst potential outcome that can occur with an elevation in intra-abdominal pressure (IAP). It is thought to be the most common cause of intestinal hypoperfusion and it also has significance in the setting of AAA repair. The incidence of ACS has been reported to be approximately 5 -18% in patients that do not undergo IAP monitoring and this increases to >10% when IAP is monitored. The incidence seems to be similar irrespective of whether open or EVAR repair is performed (Bjork et al, 2008; Bosch et al, 2010). The incidence is significantly greater in patients following a ruptured AAA (30%) and the associated mortality in this case can be up to 70% (Maker et al, 2009; Mehta, 2010). The diagnosis of abdominal compartment syndrome post AAA repair is a recognised prognostic indicator and is associated with an overall mortality rate of greater than 50%.

3.2 Aetiology

In open repair of an AAA the most significant contributors to an elevation in intra-abdominal pressure and subsequent development of ACS are manipulation of the intestines and mesenteric retraction occurring as a routine part of surgery.

The aetiology of ACS following endovascular repair is somewhat different. Factors associated with intra-abdominal hypertension following endovascular surgery include; (i) a retroperitoneal hematoma resulting in a space occupying lesion, (ii) continuous bleeding from the lumbar and inferior mesenteric arteries into the disrupted aneurysm sac or surrounding retroperitoneal tissues; this may be exacerbated by the systemic inflammatory response and associated coagulopathy that occurs in patients, in particular, those that have undergone emergency repair due to rupture, and (iii) similarly the increase in microvascular permeability that can lead to visceral and soft tissue oedema following ruptured AAA (Mehta, 2010).

3.3 Pathology

ACS is classified (Grade I-IV) based on the level of intra-abdominal pressure (table 2). In the critically ill patient without an AAA repair a normal IAP is considered to be 5-7mmHg. Grade I and II, where the IAP is between 12 and 20mmHg, can lead to impairment of renal function. This is followed by progressive dysfunction of all other organ systems.

Grade	Intra-abdominal Pressure (mmHg)
I	12-15
II	16-20
III	21-25
IV	>25

Table 2. Grading of Intra-abdominal Pressure according to WSACS Guidelines

A raised IAP of 20mmHg or more results in a reduction in the venous return to the heart and a decreased cardiac output. An increase in abdominal pressure also reduces venous flow to the various intra-peritoneal organs. Overall the outcome is that there is a reduction in perfusion of the various visceral organs resulting in bowel ischaemia. Mild cases of ischaemic colitis create an increase in intestinal permeability but in extreme cases bowel infarction can result.

The risk of increased IAP and therefore ACS has been proposed to be less in cases of endovascular repair. Studies have shown that EVAR is associated with less of a rise in inflammatory markers post-operatively when compared to open repair, a factor that as a consequence reduces the risk of a raised IAP and ACS (Junnarkar et al, 2003).

3.4 Risk factors

Risk factors for the development of intra-abdominal hypertension are multiple and can be divided into pre-operative, peri- or intra-operative and post-operative risk factors (table 3).

Studies have demonstrated that on comparing emergency open repair of a ruptured AAA to EVAR for a ruptured AAA, that those patients having open surgery had a significantly higher IAP post-operatively (Maker et al, 2009).

	Risk Factors
Pre-operative	Ruptured AAA
	Systolic blood pressure <70mmHg (>20 minutes)
	Haemoglobin <8 g/dl
	Shock
Peri- or intra-operative	Volume of blood loss
	Transfusion (platelet/>6 units red packed cells)
	>5 litres of intra-venous fluid
	Temperature <35 degrees
	Aortic occlusion balloon
	Time aorta cross-clamped
	Elevated activated partial thromboplastin time
Post-operative	Length of ICU stay
	PEEP score
	SIRS score
	pH <7.3

Table 3. Risk Factors for Intra-abdominal Hypertension

3.5 Diagnosis

Intra-abdominal pressure typically is at the highest level within 48 hours post-operatively. Using intra-vesical pressure to monitor for intra-abdominal hypertension is central to the diagnosis of IAP and ACS. Intra-vesical pressure directly corresponds to IAP making this an easy to use diagnostic modality. In monitoring pressure levels readings should be taken on an hourly basis. A standard Foley catheter is placed in the bladder and measurements are taken with volume priming of 25mls of normal saline in the supine position during end expiration. The mid-axillary line serves as the zero reference point. Other parameters that warrant monitoring include the hourly urine output, lactate dehydrogenase levels and other markers of metabolic acidosis and respiratory function.

3.6 Management

The management approach for IAP needs to be proactive because if left untreated it may progress to ACS. Once there is a suspicion that ACS may develop prompt and concise management of the condition is warranted.

Some studies have reported avoiding the use of anti-coagulants, such as systemic heparin, in particular after EVAR in an attempt to reduce and limit the on-going bleeding that can occur from collateral vessels as a result of this procedure (Mehta, 2010). The thought process behind this is that continuous bleeding from collateral vessels can lead to a rise in IAP post-operatively. Other factors to consider are care with fluid administration and a trial of neuromuscular blockade in patients with the milder grades of raised IAP as a conservative approach.

Prevention is better than cure, and there is variance in the importance given to IAP monitoring. Certain centres measure IAP both intra-operatively and post-operatively on an

hourly basis. With a raised IAP, regardless of the presence of other associated risk factors, there is a drive towards recommending that these patients undergo decompression laparotomy (Mehta, 2010). Other studies have examined the role of leaving the abdomen open as a routine prophylactic measure against ACS. The open abdomen technique post AAA repair to safeguard against ACS was first described by Fietsman (Fietsman et al, 1989). It has a particularly relevant role following open repair for a ruptured aneurysm. Recording an intra-operative abdominal pressure of 12mmHg or above is described as an indication for this (Mayer et al, 2009). Here, it has been shown that in cases of ruptured AAA there is a 30% reduction in mortality associated with ACS using this technique (Mayer et al, 2009).

Management of ACS involves a decompression laparotomy as a matter of urgency. With this there are a number of different options available for further management. One option is the use of a plastic bag (Bogota bag) and a conventional secondary dressing as a temporary closure measure. Another option for temporary closure is the use of a vacuum-assisted closure (VAC) system (V.A.C., KCI International Inc, Amstelveen, The Netherlands). The exact underlying pathophysiological manner in which vacuum assisted closure devices work is not completely understood. It has been demonstrated that vacuum-assisted closure devices do exert anti-microbial activity (Morykwas et al, 1997) and they also stimulate granulation tissue formation (Moisidis et al, 2004; Morykwas et al, 2001). The device is thought to prevent abdominal wall retraction and as a result adds stability to the abdominal wall. In addition a vacuum-assisted closure device drains the excess intra-peritoneal fluid faster than a Bogota bag and therefore results in a faster decrease in IAP. This assists the patient in their recovery process and it also allows earlier closure of the abdomen.

The decision on the type of temporary closure device to use is made based on factors such as the volume of the intra-abdominal organs protruding from the abdomen following decompression laparotomy and a worry that bowel ischaemia leading to necrosis may occur in the patient. The use of a simple sterile plastic drape or bag allows for direct visualisation of the bowel and other intra-abdominal contents and is a convenient manner of observing for impending bowel ischaemia in a patient where this is a significant concern. A Bogota bag serves the same purpose, however it also has extra reserve capacity in that it allows for further intra-abdominal swelling to take place without impacting on venous return to the heart and general visceral perfusion (Mayer et al, 2009). In cases where a simple plastic bag or drape or the Bogota bag has been employed these temporary closure devices can be changed to a VAC closure device or a zip device at a later stage. This is generally undertaken when the patient is clinically stable, their organ dysfunction is improving and their intra-abdominal pressure remains stable or is decreasing. In patients with a VAC or zip device a high level of monitoring of IAP is required to ensure that the patient doesn't deteriorate and develop ACS again (Mayer et al, 2009).

The use of temporary closure devices or a staged or delayed closure in general is associated with an increased risk of ventral hernias, incisional hernias and fistulas.

A situation may arise where eventual direct closure of the abdomen is not feasible. This can occur in patients with a prolonged history of unresolving ACS that may have been complicated with infection. The options available at this stage include; the formation of a bilateral anterior rectus abdominus sheath turnover flap (Kushimoto et al, 2007). However, in the vast majority of cases the abdomen can be closed successfully after a median of ten days post laparotomy.

A delay in managing ACS is associated with a high mortality. It is also closely linked with ischaemic colitis. This in itself in patients who require a delayed decompression laparotomy and mesh closure is reported at 40%, compared with 6% in patients with early mesh abdominal closure for open ruptured AAA repair.

4. Secondary Aorto-enteric Fistula

4.1 Incidence

Secondary aortoenteric fistula (SAF) is one of the most dreaded of aortic graft complications. The incidence of SAF has increased since the introduction of prosthetic graft materials. It was first described by Brock in 1953 after homograft aortic repair (Walker et al, 1986).

The incidence has been reported as being between 0.3 – 2.0% (Kuestner et al, 1995; Menawat et al, 1997). There is a very high rate of surgical mortality associated with this complication with rates of 25 – 90% reported (Kuestner et al, 1995; Menawat et al, 1997). Heberer is credited with the first successful repair of such a fistula in 1957 (Walker et al, 1986). Overall the outcome associated with this complication is generally poor. It does occur in the endovascular setting but to a lesser extent (Bergqvist et al, 2008).

4.2 Aetiology

With open repair of AAA the aetiology is attributed to the formation of a pseudoaneurysm at the graft anastomosis, subclinical graft infection or mechanical factors related to the graft. In the case of EVAR the formation of a secondary fistula is related to mechanical stent failure, or, distortion or migration of the stent (Janne et al, 2000; Norgren et al, 1998). Endotension has also been described to play a role. It can cause pressure necrosis of the wall of the aneurysm and the small bowel. Endotension, accelerating pressure necrosis, can occur secondary to an undetected or a subclinical endoleak or secondary to the transmission of pressure through a sealed thrombus (Ueno et al, 2006).

SAF is a rarer occurrence after endovascular repair as the adventitia of the aorta remains undisturbed. With EVAR there is no suture line or anastomosis and it is at these points where a fistula typically is found following open surgery.

4.3 Pathology

Injury to the bowel during dissection allows for fibrous contact between the bowel wall and the graft. This can result in a repetitive synchronous pulse traumatic injury. Mechanical erosion of prosthetic material into adjacent bowel most commonly occurs due to the lack of interposed retroperitoneal tissue or it can be associated with the excessive pulsation of a redundantly placed graft (Armstrong et al, 2005). The presence of an underlying graft infection, for example, staph epidermidis biofilm infection, can also lead to inflammatory adhesions and erosion (Bandyk et al, 1984).

The classical position of a SAF is described as being between the proximal aortic graft and the fourth part of the duodenum.

4.4 Risk factors

Risk factors for the formation of an aortoenteric fistula include; ruptured AAA repair, haematoma associated with surgical repair, thrombosis and wound infection. Other associated factors are male gender, increasing age and having an inflammatory or mycotic aneurysm.

With EVAR the most common complications are; endoleak and a migrated or kinked stent graft (Haussegger et al, 1999). These complications in turn add to the risk of developing a fistula. Coil embolization of an endoleak has also been reported as causing fistulae (Bertges et al, 2003).

4.5 Diagnosis

There is often a delay between the presentation and diagnosis of a SAF. The average interval between symptoms and presentation has been reported to be 47 days (range 8 – 180 days) (Armstrong et al, 2005). This is due to most investigative tests being negative or inconclusive. It is therefore very important to have a high index of suspicion for this condition. A poorer outcome is associated with a delay in recognition, diagnosis and definitive management.

There are two main patterns of presentation; bleeding and infection. A high index of suspicion is particularly required if the patient presents with what is known as a herald gastrointestinal bleed. Patients can also present with chronic melena, hematemesis or weight loss. However the typical presentation is with a herald bleed followed by a period of stability and then massive exsanguination and cardiovascular collapse. Patients presenting with symptoms and signs of sepsis can have fever, weight loss, an elevated white blood cell count and c-reactive protein, and abdominal or back pain indicating a retroperitoneal abscess.

Investigations include endoscopy, angiography and contrast studies. Angiography may be negative and at most show a small nipple at the anastomosis. The sensitivity of OGD for diagnosing a secondary aortoenteric fistula is less than 25%. Signs to be aware of on OGD include; fresh blood in the distal duodenum (often a paediatric colonoscope is required to advance this far), and visualising the graft in the base of the duodenal ulcer. To optimise diagnosis from CT investigation a high resolution, spiral, thin slice (3-5 mm) should be performed. On CT examination findings include; an obvious direct communication, loss of retroperitoneal soft tissue interposed between the overlying bowel and the proximal aortic graft, perigraft air and oedema. In patients following endovascular repair it often presents as a re-expanding AAA with associated inflammatory changes around the abdominal aorta (Ueno et al, 2006).

SAF can present as a late complication. The median time from primary operation to presentation has been reported to be two years (Bergqvist et al, 2008). One third of these patients that present late with the condition have been treated for hypovolemic shock at some stage prior to diagnosis. This again underlines the importance of having a high index of suspicion for this clinical complication.

4.6 Management

A number of different operative approaches in the management of this complication have been described. Laparotomy is often performed in an emergent situation with the aim being to control bleeding, repair the fistula site, look for the source of infection and to reconstruct the vasculature. Primary repair may be useful in an elderly patient where you don't wish to subject them to a prolonged period of ischaemia due to aortic cross clamping. But this course of action doesn't address the underlying potential problem of a subclinical graft infection.

Traditionally, the management of SAF has involved the creation of an extra-anatomic bypass, with total excision of the graft and over-sewing of the aortic stump (Kuestner et al,

1995). The main objective of this type of surgery is to reduce the risk of infection. The bypass is usually tunnelled through non infected remote tissue planes that are generally axillobifemoral. The procedure itself has associated risks. The mortality rate is high at greater than 40%. There is a risk of a stump blow out rate of 16% and graft loss rates at one year of approximately 60%. Other associated complications include limb loss, and pelvic ischemia. It has also been reported to be the approach associated with the lowest mortality; however, this may be due to confounding factors such as performing the procedure in patients that are relatively hemodynamically stable and with little co-morbidity (Bergqvist et al, 2008).

Endovascular grafting has been successfully reported as a less invasive approach (Suzuki et al, 2005; Schlensak et al, 2000; Chuter et al, 2000). Endovascular grafting has also been successfully used as a temporary measure to control life threatening gastrointestinal bleeding allowing patient stability to be achieved. Endovascular repair is of benefit when the clinical status of the patient or their co-morbidities precludes open surgical intervention. This approach does not solve the underlying problem of the communication tract however. There have been reports on the use of N-butylcyanoacrylate in attempting to obliterate the tract (Finch & Heathcock, 2002). In the setting of an infection it is obviously a questionable method.

Other options that have been reported in the literature are omental patching and homografts. It is queried that both these approaches may have a role in controlling for post-operative infection (Vogt & Turina, 1999; Montgomery & Wilson, 1996). Staged procedures and the more conservative in situ graft replacement with antibiotic coated grafts have also been reported (Kavanagh et al, 2006; Reilly et al, 1987; Kieffer et al, 2004; Walker et al, 1986). In situ repair and revascularisation are associated with better outcomes in comparison to extra-anatomic bypass.

Following operative intervention a course of broad spectrum antibiotics covering for enteric flora is required. This is required in particular after graft replacement. The placement of a feeding jejunostomy at the time of operation should also be considered (Chenu 2009).

The risk of secondary rupture of the abdominal aorta following treatment for an aorto-enteric fistula has been reported as being between 9 and 17% (Kuestner et al, 1995; Menawat et al, 1997; Bergqvist et al, 1996). These figures add to the significant overall mortality risk associated with this complication.

5. Chylous ascites

5.1 Incidence

Chylous ascites is an unusual postoperative complication that can lead to significant mechanical, nutritional, and immunologic consequences for the patient. It can present following AAA repair. The incidence of chylous ascites following AAA repair has been reported to be between 0.03 – 0.1% (Pabst et al, 1993). The true incidence of this complication however is unknown as knowledge of it has mainly relied on case reports of which there have been 40 published to date in the literature.

5.2 Aetiology

It is hypothesised that dissection around the proximal infra-renal abdominal aorta can cause traumatic damage to the intestinal lymphatics and their recipients; the left lateral-aortic lymph nodes and the cisterna chyli. It is thought that cross clamping of the aorta may also contribute to the traumatic damage of the lymphatic system.

5.3 Pathology

There is a significant variation in the anatomy of the lymphatic channels in the abdomen. This can make it difficult to identify with ease the cisterna chyli and the other lymphatic channels. Identifying the lymphatic channels is made more difficult in the fasting state as there is a minimal amount of lymphatic fluid circulating through them. As a result they are easily lacerated during dissection. This can lead to stasis, fibrosis and rupture of the lymphatic channel into the aneurysmal wall which in turn can lead to the formation of an internal lymphatic fistula between the cisterna chyli or other main lymphatic trunks and the peritoneal cavity. It has been demonstrated that a partial or lateral tear in the cisterna chyli is less likely to heal and more likely to result in chylous ascites when compared to a complete transection, as a complete transection is more likely to spontaneously retract and seal itself off (McKenna & Stevick, 1983).

5.4 Risk factors

Chylous ascites occurs in 81% of cases secondary to AAA repair. Risk factors include upper or extensive dissection of the retroperitoneal space, difficult dissection following rupture of an AAA, an inflammatory aneurysm and previous abdominal aortic surgery. The presence of a proximal obstruction to the drainage of lymph from the abdomen is also an associated risk factor.

5.5 Diagnosis

Chylous ascites typically presents two weeks after AAA repair (Olthof et al, 2008). The mean presentation has been found to be 18.4 days (Sanger et al, 1991, Bahner & Townsend, 1990). The most common signs and symptoms at presentation are abdominal distension and ascites following resumption of oral diet. The presence of intra-peritoneal fluid is confirmed by abdominal CT or ultrasound. The definitive diagnosis requires paracentesis. This reveals a lypaemic, sterile fluid which is milky in colour. Analysis of the fluid sample should demonstrate an alkaline pH, a total protein level of greater than 3 g/dl, total fat content between 0.4 and 4.0 g/dl and a predominance of lymphocytes on differential white blood count. If the patient is mechanically ventilated the diagnosis should be suspected in the presence of gradually progressing abdominal hypertension.

Other characteristic clinical features include a low serum albumin and a profound decrease in absolute lymphocyte count secondary to sequestration of lymphocytes into the ascitic fluid.

5.6 Management

The mortality rate associated with this condition has been reported to be as high as 18.5% (Garrett et al, 1989). However the literature also reports resolution in 60% of cases.

The goal of management is to reduce lymphatic flow. This is achieved with therapeutic paracentesis combined with either total parenteral nutrition (TPN) or a medium chain triglyceride rich diet. For the first 14 days the patient should be kept nil per mouth and they should receive TPN. This is followed by a diet high in medium chain triglycerides. When this is commenced the TPN is weaned gradually. Abdominal girth measurement can aid monitor patient progress.

Second line treatment consists of placement of a peritoneovenous shunt. The main concern associated with shunt placement is sepsis. Operative ligation of the damaged lymphatic channel is another option. When operative ligation is undertaken it is important to ensure that the exact lymphatic leak is identified. This is difficult if the lymph fluid is clear. The use

of dye or feeding the patient cream pre-operatively have both been reported as aiding this process (Uchinami et al, 2005). Both these interventions are usually reserved for patients where conservative management has failed. Successful laparoscopic repair of the damaged lymphatic system has also been reported (Uchinami et al, 2005). The benefit of this approach is that it doesn't require as invasive surgery as open ligation and it reduces the risk of sepsis associated with shunt placement. Overall chylous ascites typically settles with the appropriate management.

6. Ileus

6.1 Incidence

Post-operative ileus is the most common complication to occur following abdominal surgery of any description. It is a problem that is difficult to prevent and is without solution. In the case of abdominal aortic repair it is both the most frequent gastrointestinal complication and overall post-operative complication. It occurs in up to 10% of patients (Sicard et al, 1995). On the other end of the spectrum mechanical obstruction of the small bowel, in particular, the duodenum, after abdominal aortic surgery is rare. Major studies have demonstrated that of patients undergoing AAA repair, small bowel obstruction occurred in 2.9%, with greater than 40% requiring operative intervention (Siporin et al, 1993).

6.2 Aetiology

Intra-operative handling of the bowel, and tissue trauma are thought to be the main causes of post-operative ileus. The use of foreign materials for example gauze swabs, the formation of haematomas and aneurysmal sac seromas also contribute. Superior mesenteric artery syndrome, where the duodenum is compressed between the retroperitoneum and the superior mesenteric artery as a result of a retroperitoneal haematoma is associated with ileus. This can also progress to mechanical bowel obstruction if left untreated. Adhesions however, are the most common cause of mechanical bowel obstruction.

6.3 Pathology

Many studies suggest that ileus is the result of an inhibition of intestinal contractility (Smith et al, 1977). Other studies show continued but uncoordinated contractions (Dauchel et al, 1976). The jejunum has been shown to be the main area of small bowel affected by a change in the pattern of bowel contractility following AAA repair (Miedema et al, 2002).

Oedema of the bowel wall results in ileus. The bowel wall becomes oedematous secondary to dissection, manipulation trauma and direct handling of the small bowel intra-operatively. This in turn stimulates an inflammatory cascade which is thought to cause an increase in the sympathetic response to the gastrointestinal tract.

There are two approaches the surgeon can take in open repair of an AAA; transabdominal and retroperitoneal. The transabdominal approach has been reported to be associated with a greater percentage of prolonged ileus and bowel obstruction post-operatively (Kudo et al, 2004) when compared with the retroperitoneal approach.

6.4 Risk factors

Studies have demonstrated that the longer the operative time and the greater the volume of intra-operative blood loss the greater the correlation with post-operative ileus and

specifically the delayed passage of flatus (Miedema et al, 2002). Other factors that have also been found to be associated with post-operative ileus include hypoalbuminaemia, hypoproteinaemia and the presence of additional gastro-intestinal pathologies such as pancreatitis post-operatively. The length of the abdominal skin incision for abdominal aortic aneurysm repair has been determined to impact on the presence of ileus and time to return to normal diet. Hiromatsu and colleagues established that those patients with a skin incision of less than 15cm had a significantly smaller incidence of ileus when compared to a group of patients that had a skin incision of greater than 20cm (Hiromatsu et al, 2007). Laparoscopic repair has also demonstrated a shorter period of ileus and a quicker return to diet when compared to open repair (Coggia et al, 2005).

6.5 Diagnosis

Postoperative ileus is classically characterized by impaired intestinal motility and transit, absence of the passage of flatus, diminished bowel sounds, abdominal distension and intestinal dilatation. A patient with ileus typically presents with abdominal pain, nausea, and vomiting. On examination the abdomen is often distended and tender. The signs and symptoms typically are present within 24-48 hours post-operatively or when the patient attempts a return to fluids and diet. It can also present up to two weeks post the procedure. Imaging such as plain x-rays of the abdomen and contrast studies aid in determining the extent of the ileus or obstruction. In the case of a non-resolving ileus or a suspected bowel obstruction a CT scan allows the underlying cause to be determined. If on CT scanning a cause is not found then it is most likely an adhesion that is causing the problem (Tessier et al, 2003).

A prolonged post-operative ileus is a significant contributor to postoperative morbidity and mortality (Johnson, 1989). This is particularly true of non-ruptured AAA repair. The presence of post-operative ileus slows the patients return to normal function. It results in a delayed discharge and is associated with the risk of other morbidities.

6.6 Management

Initial management should be conservative and involves the placement of a nasogastric (NG) tube which is left on free drainage and intravenous hydration. The patient should remain nil per mouth until the symptoms settle and drainage from the NG is minimal.

Determining the underlying cause can aid in planning management. If a specific cause is known for example, a haematoma, this should be drained or treated to allow resolution of symptoms. Where the symptoms do not settle after a period of greater than two weeks, typically operative intervention is required. Often the procedure is adhesiolysis. This in turn however increases the risk of wound infection and dehiscence, general sepsis and fistula formation post-operatively.

Some surgeons place a NG tube at the time of surgery in an effort to reduce nausea and vomiting. This is not evidence based but more associated with traditional practice.

Studies have examined the use of novel bioresorbable materials made from chemically modified hyaluronate acid and carboxymethylcellulose. These materials form a physicochemical barrier to prevent adhesion between adjacent tissue surfaces for up to seven days after surgery (Kudo et al, 2004).

The vast majority of patients (>80%) that are managed conservatively settle within a two week window and do not require surgical intervention (Tessier et al, 2003). Patients that

ultimately require surgical intervention do so after a median duration of ten days conservative management (Tessier et al, 2003).

7. Acute pancreatitis

7.1 Incidence

Acute pancreatitis is a rare but recognised complication of AAA surgery. The true incidence of this condition is unknown and has been reliant on the reporting of case series in the surgical literature. It has been stated that the incidence is approximately 0.7% in open repair (Hashimoto & Walsh, 1999). In the presence of diabetes the incidence increases to 5% (Ryan et al, 2002). There has only been one case report, which the authors are aware of, to date with EVAR (James et al, 2008). One of the factors affecting the under-reporting of this complication is the often associated lack of a rise in amylase levels that can be found in particular with severe cases of pancreatitis.

7.2 Aetiology

The aetiology of acute pancreatitis specifically following AAA repair is not clear. One proposed theory is that of micro-emboli entering the pancreatic circulation leading to ischemia of the pancreas post-operatively (James et al, 2008). Another proposed aetiology is whereby aortic cross clamping, especially at the level of the supra-renal aorta, can result in peri-operative trauma which in turn leads to trauma and an inflammatory response.

7.3 Pathology

The spectrum of acute pancreatitis that has been described following AAA repair has varied from mild pancreatitis to more severe cases that are associated with pancreatic necrosis and a high mortality rate. In greater than 75% of known cases the pancreatitis was mild and the patients experienced a full recovery. Those patients however, that develop severe pancreatitis have been reported in one review as having a 100% mortality (Hashimoto & Walsh, 1999). This was due to multi-organ dysfunction and pancreatic necrosis. Conversely, as a point of interest, abdominal aortic aneurysms have been diagnosed following acute pancreatitis. This phenomenon is thought to be related to the release of enzymes such as elastase that cause lysis of the elastic component of the arterial vessel wall.

7.4 Risk factors

There are two known associated risk factors; (i) emergency surgery following a ruptured AAA and (ii) having diabetes mellitus (Ryan et al, 2002).

7.5 Diagnosis

The diagnosis of acute pancreatitis post-operatively is frequently associated with a delay. A raised amylase level often is just seen in mild cases of pancreatitis. In more severe cases of acute pancreatitis the amylase level can remain normal. Severe cases are usually picked up after a period of unexplained sepsis in a clinically deteriorating patient (Hashimoto & Walsh, 1999). On average severe cases of acute pancreatitis are diagnosed approximately two weeks following the initial aortic aneurysm surgery. Therefore a high index of suspicion is required for this complication in patients that develop signs and symptoms of sepsis post-operatively. The diagnosis is made using CT imaging. Features seen on CT include; diffuse

or segmental pancreatic enlargement, irregularity or heterogeneity and lobularity of the pancreas, and obliteration of the peri-pancreatic fat planes. CT also allows areas of pancreatic necrosis to be detected. The presence of necrosis significantly impacts on the prognosis for the patient and is associated with a high rate of mortality.

7.6 Management

The management of acute pancreatitis following AAA repair adheres to the general supportive treatment protocol of bowel rest and intravenous fluid therapy, analgesia and nutritional support. Close monitoring for sepsis and multi-organ failure is also of importance. Regular CT scanning should be employed to monitor for disease progression and to screen for pancreatic necrosis. Assessment of severity should be carried out using pre-defined criteria such as Ranson and APACHE II severity scores. This allows modification of management protocols and risk stratification.

The mortality rate has been reported as ranging from 40% to an absolute level of 100% in severe cases of acute pancreatitis (Hashimoto & Walsh, 1999). With respect to preventing the development of acute pancreatitis post-operatively one proposition has been to perform an incidental cholecystectomy in patients with known cholelithiasis at the time of AAA repair (Hashimoto & Walsh, 1999). However, this intervention may be somewhat excessive as overall, acute pancreatitis, is a rare gastrointestinal complication of AAA surgery.

8. Acute colecystitis

8.1 Incidence

The incidence of acute cholecystitis has been reported as varying between 0.3 – 18% (Cadot et al, 2002). Overall acute cholecystitis complicating AAA repair is accepted to be a rare event.

8.2 Aetiology

Cholesterol crystallisation occurs in association with atherosclerotic disease. Patients with an AAA often will have atherosclerosis and therefore are predisposed to cholesterol gallstones. Often these are asymptomatic and therefore undiagnosed pre AAA repair. Embolization of cholesterol crystals can lead to ischaemia of the gallbladder which in turn is a cause of cholecystitis. Low flow states, such as hypovolaemia, may also cause gallbladder wall ischaemia and therefore cholecystitis. Following AAA surgery patients may also be at risk of developing acalculus cholecystitis.

8.3 Pathology

Cholecystitis may occur secondary to the presence of gallstones which can obstruct the cystic duct or other parts of the biliary tree or it may occur in the absence of calculi (acalculus cholecystitis). Acalculus cholecystitis is more commonly found in critically ill patients and has a higher morbidity and mortality rate associated with it when compared to gallstone disease. It is also associated with a higher incidence of gallbladder perforation and gangrene. In the setting of AAA surgery the main pathophysiological process is thought to be due to bile stasis and the increased lithogenicity of bile. AAA patients are more predisposed to acalculus cholecystitis because of increased bile viscosity due to dehydration and blood loss. In patients that have a prolonged recovery where there is a delay in the return to normal diet a decrease in cholecystokinin-induced gallbladder contractions may result leading to bile stasis and a risk of cholecystitis.

8.4 Risk factors

Male gender, increasing age, emergency surgery, post-operative sepsis and hypotension or hypovolaemia are risk factors for acalculus cholecystitis. The presence of gallstones pre-operatively is a risk factor for calculus acute cholecystitis.

8.5 Diagnosis

Patients classically complain of right upper quadrant pain, nausea, vomiting and fever and on examination have abdominal tenderness, deranged liver function tests and an elevated white blood cell count. Having a high index of suspicion for acalculus disease is important as this complication has a worse prognosis and requires a more aggressive approach to treatment. The imaging modality of choice is ultrasound scanning. Features of gallbladder disease include; thickening of the gallbladder wall (>3mm), the presence of stones and pericholecystitic fluid.

Acute acalculous cholecystitis is the most common postoperative biliary complication after aortic surgery. The diagnosis should be entertained in patients with signs of abdominal sepsis after aortic surgery, especially those with a complicated postoperative course. Even if acute acalculous cholecystitis is diagnosed with ease, mortality remains high (Hagino et al, 1997).

8.6 Management

Acute cholecystitis is managed with intravenous fluid therapy, antibiotics and analgesia. The definitive treatment involves either (i) removal of the gallstones through ERCP or surgical removal of the gallbladder or (ii) the performance of a percutaneous cholecystostomy, which may be the treatment method of choice in patients that are otherwise too ill for surgical intervention.

There are centres that recommend a pre procedure cholecystectomy in patients with known cholelithiasis. The reasoning for this is that symptomatic gallbladder disease post-operatively is a significant contributor to morbidity and mortality when it occurs in a patient post AAA repair (D'Angelo et al, 1999).

9. Peptic Ulcer Disease

9.1 Incidence

The incidence of peptic ulcer disease (PUD) directly related to AAA repair is rare to begin with (0.9%) and its incidence has been further reduced by the routine incorporation of proton pump inhibitors (PPI's) into the management protocols of patients following AAA surgery (Achouh et al, 2006). In the literature there is a paucity of information on peptic ulcer disease associated with AAA, with the majority of reports having been published before the new millennium.

9.2 Aetiology

PUD after AAA surgery is theorized to be associated with (i) a decrease in gastric mucosal blood flow and (ii) the consumptive coagulopathy that can occur due to blood loss and the systemic inflammatory response that results from an AAA (Konno et al, 1991). This is particularly true following emergency surgery for a ruptured aneurysm and in patients with underlying co-morbidities pre-operatively.

9.3 Pathology

It has been found that a reduction in blood flow to the gastric mucosa and a rise in the prostaglandin content of the gastric mucosa both contribute to the development of PUD post AAA repair (Konno et al, 1994).

9.4 Risk factors

Risk factors include; previously treated PUD, ruptured AAA repair, coagulopathy (such as thrombocytopenia, altered thromboplastin time, reduction in fibrinogen levels), the volume of blood lost and the presence of DIC or SIRS post-operatively.

9.5 Diagnosis

In a patient with suspected PUD an OGD should be performed allowing direct visualisation of the peptic ulcer. At OGD biopsies should be taken to test for H. Pylori bacteria. OGD also allows for complications of PUD such, as bleeding, to be effectively managed.

9.6 Management

Symptomatic PUD, where the patient complains of epigastric pain, reflux symptoms and nausea can be treated with a course of PPI's. If H. Pylori is found to be present the patient requires a course of triple therapy. Active bleeding from a peptic ulcer needs to be expediently managed. This can be done at endoscopy using the injection of adrenaline to control bleeding. Surgical intervention is nowadays rarely necessary.

In the era before the regular use of PPI's, PUD in the setting of AAA repair was associated with a significant mortality, with reports of a mortality rate up to 30% (Achouh et al, 2006). Thankfully, although PUD may complicate the post-operative recovery pathway of the patient its overall morbidity and mortality has been significantly reduced.

10. Conclusion

All of the gastrointestinal complications discussed in this chapter require us, as physicians, to have a high index of suspicion for and knowledge of, following repair of an AAA. Although some of the complications we have detailed are rare in incidence they impact significantly on patient outcome, morbidity and mortality. The key gastrointestinal complications to be aware of following AAA surgery are ischaemic colitis, abdominal compartment syndrome and ileus. The introduction of EVAR has had a positive impact on the rate of some gastrointestinal complications, in other cases it has led to different pathophysiological pathways. As our knowledge base relies on literature reports it remains as yet to be seen what the full impact of endovascular surgery will have on outcomes following AAA repair in both the elective and emergent setting.

11. References

Achouh PE, Madsen K, Miller CC 3rd, Estrera AL, Azizzadeh A, Dhareshwar J, Porat E & Safi HJ (2006). Gastrointestinal complications after descending thoracic and thoracoabdominal aortic repairs: a 14-year experience. *J Vasc Surg.* Vol. 44, No. 3, pp. 442-6.

- Armstrong PA, Back MR, Wilson JS, Shames ML, Johnson BL, & Bandyk DF (2005). Improved outcomes in the recent management of secondary aortoenteric fistula. *J Vasc Surg*, Vol. 42, pp. 660-6.
- Assadian A, Senekowitsch C, Assadian O, Hartleb H, & Hagmüller GW (2008). Diagnostic accuracy of sigmoidoscopy compared with histology for ischemic colitis after aortic aneurysm repair. *Vascular*. Vol. 16, No. 5, pp. 243-7.
- Bahner Jr DR, & Townsend R (1990). Chylous ascites after ruptured abdominal aortic aneurysm. *Contemp Surg*, Vol. 36, pp. 37-9.
- Bandyk DF, Berni GA, Thiele BL, & Towne JB (1984). Aortofemoral graft infection due to *Staphylococcus Epidermidis*. *Arch Surg*, Vol. 119, pp. 102-8.
- Becquemin JP, Majewski M, Fermani N, Marzelle J, Desgrandes P, Allaire E, & Roudat-Thoraval F (2008). Colon ischemia following abdominal aortic aneurysm repair in the era of endovascular abdominal aortic repair. *J Vasc Surg*, Vol. 47, pp. 258-63.
- Bergqvist D, Björckman H, Bolin T, Dalman P, Elfstrom J, Forsberg O, Johansen L, Karacagil S, Karlqvist PA, Lanne T, Plate G, Ribbe E, Spangen L, Stenbeck J, Thomsen M, Wiklund B, & Angquist KA (1996). Secondary aorto-enteric fistulae - changes from 1973 to 1993. *Eur J Vasc Endovasc Surg*, Vol, 11, pp. 425-8.
- Bergqvist D, Björck M, & Nyman R (2008). Secondary aortoenteric fistula after endovascular aortic interventions: a systematic literature review. *J Vasc Interv Radiol*. Vol. 19, No. 2, Pt. 1, pp. 163-5.
- Bertges DJ, Villella ER, & Makaroun MS (2003). Aortoenteric fistula due to endoleak coil embolization after endovascular AAA repair. *J Endovasc Ther*, Vol, 10, pp. 130-135.
- Björck M, Wanhainen A, Djavani K, & Acosta S (2008). The clinical importance of monitoring intra-abdominal pressure after ruptured abdominal aortic aneurysm repair. *Scand J Surg*. Vol. 97, No. 2, pp. 183-90.
- Björck M, Bergqvist D, & Troëng T (1996). Incidence and clinical presentation of bowel ischaemia after aortoiliac surgery--2930 operations from a population-based registry in Sweden. *Eur J Vasc Endovasc Surg*. Vol. 12, No. 2, pp. 139-44.
- Bosch TJA, Teijink JA, Willigendael EM, & Prins MH (2010). Endovascular aneurysm repair is superior to open surgery for ruptured abdominal aortic aneurysms in EVAR-suitable patients. *J Vasc Surg*. Vol. 52, No. 1, pp. 13-8.
- Cadot H, Addis MD, Faries PL, Carroccio A, Burks JA, Gravereaux EC, Morrissey NJ, Teodorescu V, Sparacino S, Hollier LH, & Marin ML (2002). Abdominal aortic aneurysmorrhaphy and cholelithiasis in the era of endovascular surgery. *Am Surg*, Vol. 68, No. 10, pp. 839-843.
- Champagne BJ, Darling RC, Daneshmand M, Kreienberg PB, Lee EC, Mehta M, Roddy SP, Chang BB, Paty PS, Ozsvath KJ, & Shah DM (2004). Outcome of aggressive surveillance colonoscopy in ruptured abdominal aortic aneurysm. *J Vasc Surg*, Vol. 39, pp. 792-6.
- Chen JC, Hildebrand HD, Salvian AJ, Taylor DC, Strandberg S, Myckatyn TM, & Hsiang YN (1996). Predictors of death in nonruptured and ruptured abdominal aortic aneurysms. *J Vasc Surg*, Vol. 24, pp. 614-20.
- Chenu C, Marcheix B, Barcelo C, & Rousseau H (2009). Aorto-enteric Fistula After Endovascular Abdominal Aortic Aneurysm Repair: Case Report and Review. *Eur J Vasc Endovasc Surg*. Vol. 37, pp. 401-40.

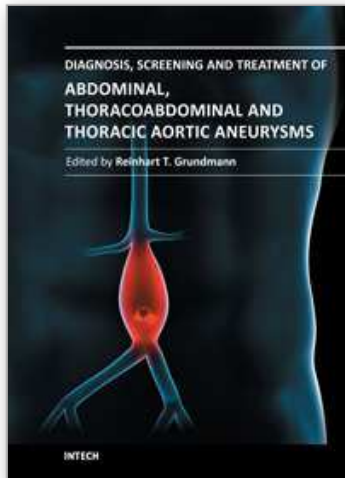
- Chuter TA, Lukaszewicz GC, Reilly LM, Kerlan RK, Faruqi R, Sawhney R, Wall SD, Canto C, LaBerge JM, Gordon RL, & Messina LM (2000). Endovascular repair of a presumed aortoenteric fistula: late failure due to recurrent infection. *J Endovasc Ther.* Vol. 7, pp. 240-4.
- Coggia M, Javerliat I, Di Centa I, Alfonsi P, Colacchio G, Kitzis M, & Goeau-Brissonniere O (2005). Total laparoscopic versus conventional abdominal aortic aneurysm repair: A case-control study. *J Vasc Surg.* Vol. 42, No. 5, pp. 906-910.
- D'Angelo AJ, Kline RG, Faust GR, & Cohen JR (1999). Cholecystectomy during abdominal aortic aneurysm repair in patients with gallstones. *Vasc Surg.* Vol. 33, No. 6, pp. 705-710.
- Dauchel J, Schang JC, Kachelhoffer J, Eloy R, & Grenier JF (1976). Gastrointestinal and myoelectric activity during the postoperative period in man. *Digestion,* Vol. 14, pp. 293-303.
- Djavani K, Wanhainen A, Valtysson J, & Bjorck M (2009). Colonic ischaemia and intra-abdominal hypertension following open repair of ruptured abdominal aortic aneurysm. *BJS,* Vol. 96, pp. 621-627.
- Elmarasy NM, Soong CV, Walker SR, Macierewicz JA, Yusuf SW, Wenham PW, & Hopkinson BR (2000). Sigmoid ischemia and the inflammatory response following endovascular abdominal aortic aneurysm repair. *J Endovasc Ther.* Vol. 7, pp. 21-30.
- Fietsam R Jr, Villalba M, Glover JL, & Clark K (1989). Intra-abdominal compartment syndrome as a complication of ruptured abdominal aortic aneurysm repair. *Am Surg.* Vol. 6, pp. 396-402.
- Finch L, & Heathcock B (2002). Emergent treatment of a primary aorto-enteric fistula with N-butyl 2-cyanoacrylate and endovascular stent. *J Vasc Interv Radiol.* Vol. 13, pp. 841-843.
- Garrett HE Jr, Richardson JW, Howard HS, & Garrett HE (1989). Retroperitoneal lymphocele after abdominal aortic surgery. *J Vasc Surg,* Vol. 10, pp. 245-53.
- Geraghty PJ, Sanchez LA, Rubin BG, Choi ET, Flye MW, Curci JA, Thompson RW, & Sicard GA (2004). Overt ischemic colitis after endovascular repair of aortoiliac aneurysms. *J Vasc Surg.* Vol. 40, pp. 413-8.
- Geroulakos G, & Cherry Jr KJ. (2002) *Diseases of the visceral circulation.* Chapter: Ischaemic Colitis. Pages: 193 - 207. Arnold Publishers. ISBN 0340807229(hb). Great Britain.
- Hagino RT, Valentine RJ, & Clagett GP (1997). Acalculous cholecystitis after aortic reconstruction. *J Am Coll Surg.* Vol. 184, No. 3, pp. 245-248.
- Hashimoto L, & Walsh RM (1999). Acute pancreatitis after aortic surgery. *Am Surg.* Vol. 65, No. 5, pp. 423-426.
- Hausegger KA, Tiesenhausen K, Karaic R, Tauss J, & Koch G (1999). Aortoduodenal fistula: a late complication of intraluminal exclusion of an infrarenal aortic aneurysm. *J Vasc Interv Radiol,* Vol. 10, pp. 747-750.
- Hiromatsu S, Egawa N, Hosokawa Y, Ishihara K, Yokokura H, Tanaka A, & Aoyagi S (2007). A shorter skin incision technique for the repair of infrarenal abdominal aortic aneurysms. *Surg Today.* Vol. 37, No. 2, pp. 97-102.
- James AD, Anderson HJ, Edwards R, & Sandison AJ (2008). Pancreatitis as a Complication of Endovascular Aneurysm Repair. *Eur J Vasc Endovasc Surg,* Vol. 35, pp. 310-311.

- Janne d'Othee B, Soula P, Otal P, Cahill M, Joffle F, Cerene A, & Rousseau H (2000). Aorto-duodenal fistula after endovascular stent graft of an abdominal aortic aneurysm. *J Vasc Surg*, Vol. 31, pp. 190-5.
- Johnson KW (1989). Multicenter prospective study of non-ruptured abdominal aortic aneurysm. Part II. Variables predicting morbidity and mortality. *J Vasc Surg*, Vol. 9, pp. 437-47.
- Junnarkar S, Lau LL, Edrees WK, Underwood D, Smye MG, Lee B, Hannon RJ, & Soong CV (2003). Cytokine activation and intestinal mucosal and renal dysfunction are reduced in endovascular AAA repair compared to surgery. *J Endovasc Ther*. Vol. 10, pp. 195-202.
- Kavanagh DO, Dowdall JF, Younis F, Sheehan S, Mehigan D, & Barry MC (2006). Aorto-enteric fistula: changing management strategies. *Ir J Med Sc*. Vol. 175, No. 1, pp. 40-44.
- Kieffer E, Gomes D, Chiche L, Fleron MH, Koskas F, & Bahnini A (2004). Allograft replacement for infrarenal aortic graft infection: early and late results in a 179 patients. *J Vasc Surg*, Vol. 39, pp. 1009-17.
- Konno H, Kaneko H, Maruo Y, Tatuo T, Nobuhiko N, Nakamura S, & Baba S (1994). Prevention of gastric-ulcer or acute gastric-mucosal lesions accompanying bleeding after abdominal aortic-aneurysm surgery. *W J Surg*, Vol. 18, No. 6, pp. 944-947.
- Konno H, Sakaguchi S, & Hachiya T (1991). Bleeding peptic-ulcer after abdominal aortic-aneurysm surgery. *Arch Surg*, Vol. 126, No. 7, pp. 894-897.
- Kudo FA, Nishibe T, Miyazaki K, Murashita T, Nishibe M, & Yasuda K (2004). Use of Bioresorbable Membrane to Prevent Postoperative Small Bowel Obstruction in Transabdominal Aortic Aneurysm Surgery. *Surg Today*, Vol. 34, pp. 648-651.
- Kuestner LM, Reilly LM, Jicha DL, Ehrenfeld WK, Goldstone J, & Stoney RJ (1995). Secondary aortoenteric fistula: contemporary outcome with use of extraanatomic bypass and infected graft excision. *J Vasc Surg*, Vol. 21, pp. 184-96.
- Kushimoto S, Yamamoto Y, Aiboshi J, Ogawa F, Koido Y, Yoshida R, & Kawai M (2007). Usefulness of the bilateral anterior rectus abdominis sheath turnover flap method for early fascial closure in patients requiring open abdominal management. *World J Surg*, Vol. 1, pp. 2-8.
- Levison JA, Halpern VJ, Kline RG, Faust GR, & Cohen JR (1999). Perioperative predictors of colonic ischemia after ruptured abdominal aortic aneurysm. *J Vasc Surg*, Vol. 1, pp. 40-5.
- Makar RR, Badger SA, O'Donnell ME, Loan W, Lau LL, & Soong CV (2009). The effects of abdominal compartment hypertension after open and endovascular repair of a ruptured abdominal aortic aneurysm *J Vasc Surg*, Vol. 49, pp. 866-72.
- Mayer D, Rancic Z, Meier C, Pfammatter T, Veith FJ, & Lachat M (2009). Open abdomen treatment following endovascular repair of ruptured abdominal aortic aneurysms. *Vasc Surg*, Vol. 50, pp. 1-7.
- McKenna R, & Stevick CA (1983). Chylous ascites following aortic reconstruction. *Vasc Surg*, Vol. 17, pp. 143-9.
- Mehta M (2010). Endovascular aneurysm repair for ruptured abdominal aortic aneurysm: The Albany Vascular Group approach. *J Vasc Surg*, Vol. 52, pp. 1706-12.

- Menawat SS, Gloviczki P, Serry RD, Cherry KJ Jr, Bower TC, & Hallett JW Jr (1997). Management of aortic graft-enteric fistulae. *Eur J Vasc Endovasc Surg*, Vol. Suppl A, pp. 74-81.
- Miedema BW, Schillie S, Simmons JW, Burgess SV, Liem T, & Silver D (2002). Small bowel motility and transit after aortic surgery. *J Vasc Surg*, Vol. 36, pp. 19-24.
- Mitchell KM, & Valentine RJ (2002). Inferior mesenteric artery reimplantation does not guarantee colon viability in aortic surgery. *J Am Coll Surg*. Vol. 194, No. 2, pp. 151-5.
- Moisidis E, Heath T, Boorer C, Ho K, & Deva AK (2004). A prospective, blinded, randomized, controlled clinical trial of topical negative pressure use in skin grafting. *Plast Reconstr Surg*, Vol. 4, pp. 917-22.
- Montgomery RS, & Wilson SE (1996). The surgical management of aortoenteric fistulas. *Surg Clin North Am*, Vol. 76, pp. 1147-57.
- Morykwas MJ, Argenta LC, Shelton-Brown EI, & McGuirt W (1997). Vacuum-assisted closure: a new method for wound control and treatment: animal studies and basic foundation. *Ann Plast Surg*, Vol. 6, pp. 553-62.
- Morykwas MJ, Falser BJ, Pearce DJ, & Argenta LC (2001). Effects of varying levels of subatmospheric pressure on the rate of granulation tissue formation in experimental wounds in swine. *Ann Plast Surg*, Vol. 5, pp. 547-51.
- Neary P, Hurson C, Briain DO, Brabazon A, Mehigan D, Keaveny TV, & Sheehan S (2007). Abdominal aortic aneurysm repair and colonic infarction: a risk factor appraisal. *Colorectal Disease*, Vol. 9, No. 2, pp. 166-172.
- Norgren L, Jernby B, & Engellau L (1998). Aortoenteric fistula caused by a ruptured stent-graft: a case report. *J Endovasc Surg*, Vol. 5, pp. 269-72.
- Olthof E, Blankensteijn JD, & Akkersdijk GJM (2008). Chyloperitoneum Following Abdominal Aortic Surgery. *Vasc*, Vol. 16, No. 5, pp. 258-262.
- Pabst TS, McIntyre KE Jr, Jr., Schilling JD, Hunter GC, & Bernhard VM (1993). Management of Chyloperitoneum After Abdominal Aortic Surgery. *Am J Surg*, Vol. 66, pp. 194-199.
- Perry RJT, Martin MJ, Eckert MJ, Sohn VY, & Steele SR (2008). Colonic ischemia complicating open vs endovascular abdominal aortic aneurysm repair. *J Vasc Surg*, Vol. 48, pp. 272-7.
- Rayan SS, Hamadan AD, Campbell DR, Akbari CM, Hook SC, Skillman J, LoGerfo FW, & Pomposelli FB Jr (2002). Is diabetes a risk factor for patients undergoing open abdominal aortic aneurysm repair? *Vasc Endovascular Surg*, Vol. 36, No. 1, pp. 33-40.
- Reilly LM, Stoney RJ, Goldstone J, & Ehrenfeld WK (1987). Improved management of aortic graft infection: the influence of operation sequence and staging. *J Vasc Surg*, Vol. 5, pp. 421-31.
- Sanger R, Wilmshurst CC, & Clyne CAC (1999). Chylous ascites following aneurysm surgery. *Eur J Vasc Surg*, Vol. 5, pp. 689-92.
- Schlensak C, Doenst T, Spillner G, Blum U, Geiger A, & Beyersdorf F (2000). Palliative treatment of a secondary aortoduodenal fistula by stent graft placement. *Thorac Cardiovasc Surg*, Vol. 48, pp. 41-2.
- Senekowitsch C, Assadian A, Assadian O, Hartleb H, Ptakovsky H, & Hagmüller GW (2006). Replanting the inferior mesentery artery during infrarenal aortic aneurysm repair: Influence on postoperative colon ischemia. *J Vasc Surg*, Vol. 43, pp. 689-94.

- Sicard GA, Reilly JM, Rubin BG, Thompson RW, Allen BT, Flye MW, Schechtman KB, Young-Beyer P, Weiss C, & Anderson CB (1995). Transabdominal versus retroperitoneal incision for abdominal aortic surgery: report of a prospective randomized trial. *J Vasc Surg*, Vol. 21, pp. 174-81.
- Siporin K, Hiatt JR, & Treiman RL (1993). Small bowel obstruction after abdominal aortic surgery. *Am Surg*, Vol. 59, pp. 846-9.
- Smith J, Kelly KA, & Weinshilboum RM (1977). Pathophysiology of postoperative ileus. *Arch Surg*, Vol. 112, pp. 203-9.
- Suzuki S, Imoto K, Uchida K, Haskiyama N, & Takanashi Y (2005). Endovascular Repair of a Presumed Aortoduodenal Fistula. *Ann Thorac Cardiovasc Surg*, Vol. 11, pp. 424-8.
- Tessier DJ, & Brophy CM (2003). Causes, diagnosis, and management of duodenal obstruction after aortic surgery. *J Vasc Surg*, Vol. 38, pp. 186-9.
- Uchinami M, Morioka K, Doi K, Nakamura T, Yoshida M, & Tanaka K (2005). Retroperitoneal laparoscopic management of a lymphocele after abdominal aortic surgery: A case report. *J Vasc Surg*, Vol. 42, No. 3, pp. 552-555.
- Ueno M, Iguro Y, Nagata T, & Sakata R (2006). Aortoenteric Fistula After Endovascular Stent Grafting for an Abdominal Aortic Aneurysm: Report of a Case. *Surg Today*. 2006; Vol. 36, pp. 546-548.
- Van DH, Creemers E, & Limet R (2000). Ischemic colitis following aortoiliac surgery. *Acta Chir Belg*, Vol. 100, pp. 21-7.
- Vogt PR, & Turina MI (1999). Management of infected aortic grafts: development of less invasive surgery using cryopreserved homografts. *Ann Thorac Surg*, Vol. 67, pp. 1986-9.
- Walker WE, Cooley DA, Duncan JM, Hallman JL, Ott DA, & Reul GJ (1986). The management of aortoduodenal fistula by in situ replacement of the infected abdominal aortic graft. *Ann Surg*, Vol. 205, pp. 727-32.
- Welch M, Baguneid MS, McMahon RF, Dodd PD, Fulford PE, Griffiths GD, & Walker MG (1998). Histological study of colonic ischaemia after aortic surgery. *Br J Surg*. Vol. 85, No. 8, pp. 1095-8.
- Yilmaz EN, Vahl AC, van Rij G, Nauta SHM, Brom HLF, & Rauwerda JA (1999). Endoluminal pulse oximetry of the sigmoid colon and the monitoring of the colonic circulation. *Cardiovascular Surg*, Vol. 7, No. 7, pp. 7

IntechOpen



Diagnosis, Screening and Treatment of Abdominal, Thoracoabdominal and Thoracic Aortic Aneurysms

Edited by Prof. Reinhart Grundmann

ISBN 978-953-307-466-5

Hard cover, 414 pages

Publisher InTech

Published online 12, September, 2011

Published in print edition September, 2011

This book considers mainly diagnosis, screening, surveillance and treatment of abdominal, thoracoabdominal and thoracic aortic aneurysms. It addresses vascular and cardiothoracic surgeons and interventional radiologists, but also anyone engaged in vascular medicine. The high mortality of ruptured aneurysms certainly favors the recommendation of prophylactic repair of asymptomatic aortic aneurysms (AA) and therewith a generous screening. However, the comorbidities of these patients and their age have to be kept in mind if the efficacy and cost effectiveness of screening and prophylactic surgery should not be overestimated. The treatment recommendations which will be outlined here, have to regard on the one hand the natural course of the disease, the risk of rupture, and the life expectancy of the patient, and on the other hand the morbidity and mortality of the prophylactic surgical intervention. The book describes perioperative mortality after endovascular and open repair of AA, long-term outcome after repair, and the cost-effectiveness of treatment.

How to reference

In order to correctly reference this scholarly work, feel free to copy and paste the following:

Emmeline Nugent and Paul Neary (2011). Gastrointestinal Complications of Abdominal Aortic Aneurysms, Diagnosis, Screening and Treatment of Abdominal, Thoracoabdominal and Thoracic Aortic Aneurysms, Prof. Reinhart Grundmann (Ed.), ISBN: 978-953-307-466-5, InTech, Available from:

<http://www.intechopen.com/books/diagnosis-screening-and-treatment-of-abdominal-thoracoabdominal-and-thoracic-aortic-aneurysms/gastrointestinal-complications-of-abdominal-aortic-aneurysms>

INTECH
open science | open minds

InTech Europe

University Campus STeP Ri
Slavka Krautzeka 83/A
51000 Rijeka, Croatia
Phone: +385 (51) 770 447
Fax: +385 (51) 686 166
www.intechopen.com

InTech China

Unit 405, Office Block, Hotel Equatorial Shanghai
No.65, Yan An Road (West), Shanghai, 200040, China
中国上海市延安西路65号上海国际贵都大饭店办公楼405单元
Phone: +86-21-62489820
Fax: +86-21-62489821

© 2011 The Author(s). Licensee IntechOpen. This chapter is distributed under the terms of the [Creative Commons Attribution-NonCommercial-ShareAlike-3.0 License](#), which permits use, distribution and reproduction for non-commercial purposes, provided the original is properly cited and derivative works building on this content are distributed under the same license.

IntechOpen

IntechOpen