

We are IntechOpen, the world's leading publisher of Open Access books Built by scientists, for scientists

4,800

Open access books available

122,000

International authors and editors

135M

Downloads

Our authors are among the

154

Countries delivered to

TOP 1%

most cited scientists

12.2%

Contributors from top 500 universities



WEB OF SCIENCE™

Selection of our books indexed in the Book Citation Index
in Web of Science™ Core Collection (BKCI)

Interested in publishing with us?
Contact book.department@intechopen.com

Numbers displayed above are based on latest data collected.

For more information visit www.intechopen.com



Late Complications Following Aortic Aneurysm Repair

Michiel L.P. van Zeeland and Lijckle van der Laan
*Department of Vascular Surgery, Amphia Hospital
 The Netherlands*

1. Introduction

Abdominal aortic aneurysm affects 5-10 % of men and 1,3% of women (Cosworth & Leng, 2007). Current treatment of aortic aneurysm is going through rapid changes. The first successful open repair with a homograft was performed in 1951 (Dubost et al. 1952). Initially, the aneurysm wall was completely removed which could lead to major complications. Creech modified the technique and combined repair with a graft with aneurysmorhaphy which simplified the technique and improved results (Creech, 1966). Late complications after open surgical repair are infrequent but also poorly monitored. It is generally assumed that if patients have survived this major surgical procedure, few complications occur. Endovascular aneurysm repair (EVAR) is gaining popularity since the mid-nineties (Parodi et al., 1991). Despite major technical improvements in endografts, follow-up is essential after endovascular repair. Recent studies reported up to 40% of aneurysms growing after EVAR, even in recent years (2004-2008) (Schanzer et al., 2011). These growing aneurysms pose the vascular surgeon for new clinical problems which sometimes require unorthodox interventions. An overview of late complications of both open and endovascular abdominal aortic aneurysm repair is given along with specific solutions from the literature and our own experience. Table 1 summarizes the late complications and estimated incidence from the literature.

Common late complications after aortic aneurysm repair		Estimated Incidence	
Open repair	Graft related	Anastomotic aneurysm	1-10%
		Graft occlusion	<1%
		Infection	0.2-2%
	Non-graft related	Aortoenteric fistula	0.3-2.5%
		Incisional herniae	30-90%
		Small bowel obstruction	Unknown *
		Sexual dysfunction	Up to 80%
		Buttock claudication	Unknown
EVAR**	Graft related	Infection	1-3%
		Migration, kinking, occlusion	1-14%
		Rupture	1-9%

*Single Study showed 2.6% (Siporin et al., 1993), **Endovascular Aneurysm Repair.

Table 1. Late complications after aneurysm repair

2. Late complications after open aneurysm repair

2.1 Graft related complications

Late complications after successful AAA repair are infrequent. Anastomotic aneurysms are infrequent in the literature (1-10%), but this might be an underestimation due to a lack of follow-up. Repair can be performed open or endovascular. Infectious complications are also rare after open AAA repair. An infected aortic prosthesis represents one of the most difficult challenges for the vascular surgeon today. Diagnosis is usually obvious but occasionally unclear even after extensive clinical and radiological investigations. Mortality and amputation rates continue to be high. Various treatment options will be discussed, from definitive surgical repair to a non-operative approach comprised of drainage and long term antibiotic treatment. Our own unpublished data on non-operative management will be presented. Aortoduodenal fistulae can present with hemorrhage or as an infected prosthesis. Treatment is also extremely challenging for the vascular surgeon with high mortality rates. Graft thrombosis is infrequent and usually caused by coexistent iliac occlusive disease.

2.1.1 Anastomotic aneurysm

2.1.1.1 Incidence of anastomotic aneurysm

Plate et al published on of the earliest reports on late complications (Plate et al., 1985). A study of over 1000 AAA patients with 6 year follow-up showed anastomotic aneurysms but no fistula. Forty-nine true, 14 anastomotic, and five dissecting aneurysms were detected in 59 patients 5 years after the initial aneurysm repair. These aneurysms were located in the thoracic (24), thoracoabdominal (five), or abdominal aorta (11), and in the iliac (six), femoral (17), popliteal (four), and renal arteries (one). Only one of 26 patients presenting with a rupture of one of these secondary aneurysms survived. There was a significant association between preoperative hypertension and recurrent aneurysm. The authors suggest that subsequent vascular disease, including recurrent aneurysms and graft complications, cause significant late morbidity and mortality after repair of abdominal aortic aneurysm. They suggest that careful follow-up and adequate control of hypertension may allow reduction in morbidity and an improvement in late survival. Hertzner et al. reported much less graft-related complications(0.4%) with 5-year follow-up, although only clinically evident (as opposed to computed tomography scan-detected) events were considered (Hertzner et al., 2002). Conrad et al. described a cohort of 540 open non-ruptured AAA repairs (Conrad et al.,2007). 152 Of them had follow-up CT scans which revealed 13 graft-related complications identified in 11 patients, including 7 anastomotic pseudoaneurysms (4 proximal and 3 distal). Three of the four proximal and two of the three distal cases underwent open operative repair. The remaining two were observed because of concomitant co morbidities. Hallett reported a 9.4% graft-related complication rate (mostly anastomotic pseudoaneurysms) after open AAA repair at an average follow-up of 5.8 years with late surveillance imaging on most patients (Hallett et al., 1997). Finally, Biancari et al. report of a 15.4% late graft-related complication rate with a median follow-up of 8 years (Biancari et al., 2002). This is significantly worse than the previous reports and may be related to the inclusion of ruptured AAA repairs. Edwards et al. set out to examine late follow-up of aortic surgery (Edwards et al., 1992). They performed ultrasonography of 111 patients and discovered eleven paraanastomotic aneurysms, including 7 pseudoaneurysms and 4 true aneurysms of the adjacent aorta. The majority were seen after 7 years.

2.1.1.2 Surgical management of anastomotic aneurysm

Surgical treatment of anastomotic pseudoaneurysm is a technically challenging procedure and requires dissection through previous scarred operative sites in patients who are likely to have more co morbidity than those with primary aortic surgery. As a result, mortality and morbidity rates of aortic redo surgery are higher than those associated with primary prosthetic reconstructions (van Herwaarden et al., 2004; Mulder et al., 1998; Treiman et al., 1988). Allen et al. reported an overall 73% major postoperative complication rate and an operative mortality rate of 21% in 29 patients who were treated for anastomotic aneurysms of the abdominal aorta (Allen et al., 1993). Endovascular treatment of anastomotic aneurysms after aortic surgery seems a promising technique. Small series have been published on the subject. Yuan et al. constructed endovascular grafts from PTFE sutured to Palmaz stents and treated 10 patients with 12 aneurysms. No mortality occurred and 1 wound hematoma was observed. After a mean of 16 months of follow-up, no graft related complications occurred. Van Herwaarden treated 14 patients with either anastomotic or iliac aneurysms after previous aortic repair, using commercially available stent grafts. Eleven patients recovered without sequelae and 3 patients required a second intervention (2 open and 1 endovascular) after 12 months follow-up (Van Herwaarden et al., 2004). The authors warned us for the placement of a tube endovascular graft in a normal graft body. For better columnar strength, bifurcated stents should be used.

Ruptured (para)anastomotic aneurysms are even more challenging for the vascular surgeon. The mortality rate of patients with ruptured (para)anastomotic aneurysm arriving in the hospital is very high. Endovascular repair has been described in a few cases (Syfrodas et al., 2008). Our group also described an already unresponsive patient in severe hemorrhagic shock who was treated with an aortic occlusion balloon for hemodynamic stabilization and subsequent stent placement to exclude a ruptured iliac aneurysm. The patient recovered uneventfully (Menke et al., 2010).

In conclusion, for (para)anastomotic aneurysms, endovascular treatment seems to have advantages over open repair with good mid-term results.

2.1.2 Graft occlusions

Large series mention few graft occlusions after open aneurysm repair. Hallett et al. reported 6 graft thromboses after 10 years of follow-up of 307 grafts (Hallett et al., 1997). One tube occluded, the others were bifurcated. Conrad et al. performed CT scanning of 152 of 540 open repairs. There were four graft limb occlusions in the bifurcated grafts that were treated with open thrombectomy and revision of the distal (femoral) anastomosis (Conrad et al., 2007). The Dutch Randomized Endovascular Aneurysm Repair (DREAM) trial followed 178 open and 173 EVAR cases and found a total of 3 occlusions after open repair and 12 after EVAR (De Bruin et al., 2011). The long term outcome of the EVAR 1 trial showed 22 graft thromboses in 1216 repairs, 2 after open and 20 after EVAR (Greenhalgh et al., 2010).

Treatment of graft thrombosis can be performed open or endovascular. Usually, stenosis of the distal anastomosis is the cause. Open repair and revision of the distal anastomosis is required in these cases. We recommend the use of a graft thrombectomy catheter. Intra-arterial thrombolysis is increasingly used in graft acute thrombosis with good results. Also, recent reports on ultrasound-accelerated thrombolysis are promising (Schrijver et al., 2011).

2.1.3 Graft infection and management

2.1.3.1 Incidence and diagnosis of graft infection

Aortic vascular graft infection is an infrequent complication of aortic surgery. Large series showed an incidence of 0.2-2% graft infections after open aortic surgery (Hallett et al., 1997; Hertzner et al., 2002). The DREAM trial reported no graft infections in open repair and 2 after EVAR (De Bruin et al., 2010). Conrad followed 540 aortic grafts and described two graft infections which were identified and treated with graft removal (Conrad et al., 2007). Diagnosis is suspected with, fever, elevated serum CRP and leukocyte count and fluid collections around the graft on CT scan, in the absence of other possible causes of fever. Confirmation of the diagnosis is through culture of a micro-organism from the area of the graft. In unclear cases, FDG-PET-CT has proven to be a useful tool in the work-up for diagnosis of aortic graft infection (Bruggink et al., 2010).

2.1.3.2 Microbiology of graft infection

It has been proposed to divide the spectrum of aortic graft infections into early and late presentations (Bandyk, 2002). Early infections usually present within the first 3 months after implantation and spread rapidly whereas late infections usually occur after this period and tend to be more confined with respect to extent of infection. Most commonly, both types are initiated during graft implantation via contamination from patient skin flora. Early <4 months graft infection generally is caused by *S. aureus* or Gram-negative bacteria and frequently originates from a failure of primary wound healing. The presence of hematoma, lymphatic fistula, and devitalized tissue increase the risk for graft infection and should be treated aggressively with wound exploration, debridement, and primary wound closure. The majority (>80%) of graft infections are diagnosed more than 4 months after graft implantation. These infections are most commonly with *S. Epidermidis*, which produce a low-grade infection with a polysaccharide biofilm (slime-like appearance). Other pathogens include *Escherichia coli*, *Pseudomonas spp.*, *Proteus*, *Salmonella* and *Klebsiella pneumoniae*, *Listeria Monocytogenes* and *Corynebacteriae* (own unpublished data). These pathogens are most likely to have colonized the graft after implantation. Whenever possible, pathogen(s) should be identified before treatment, permitting bactericidal-level antibiotics to be administered pre- and postoperatively. If the infecting organism has not been isolated, broad-spectrum antibiotics should be given. When *S. aureus* or *S. epidermidis* is the most likely pathogen, parenteral therapy with a first- or second-generation cephalosporin and vancomycin are appropriate. Once operative cultures have isolated all infecting organisms, treatment should be modified based on antibiotic susceptibility testing of the recovered strains. No evidence is available on the duration of antibiotic administration after treatment by graft excision, but at least 4 weeks of systemic antibiotics is recommended in the literature. After in situ prosthetic replacement or prosthetic graft preservation procedures, long-term antibiotic therapy is recommended (parenteral antibiotics for 6 weeks, followed by oral antibiotics for to 6 months) (Bandyk, 2002). On the other hand, our personal experience is that some patients require life-long antibiotics. We have encountered cases where on cessation of antibiotic treatment, fever returned and subsided again after restarting antibiotic treatment.

2.1.3.3 Surgical management of graft infection

Excision of the infected aortic prosthesis and extra-anatomic bypass grafting through a noninfected field has been the most common treatment for patients with aortic graft

infection. Results of the use of this approach have gradually improved since its introduction by Blaisdell et al. in 1970, particularly after the observation of Reilly et al. that staged extra-anatomic bypass grafting followed by graft excision was associated with lower mortality and improved initial limb salvage (Blaisdell et al., 1970; Reilly et al., 1987). Seeger et al. reported a series of 36 cases with infected aortic prosthesis. Four patients (11%) died in the postoperative period, and two patients died during follow-up as a direct consequence of extra-anatomic bypass grafting and aortic graft removal (one died 7 months after extra-anatomic bypass graft failure, one died 36 months after aortic stump disruption). One additional patient died 72 months after failure of a subsequent aortic reconstruction, so that the overall treatment-related mortality was 19%, whereas overall survival by means of life table analysis was 56% at 5 years. No amputations were required in the postoperative period, but four patients (11%) required amputation during follow-up. 5 patients had some form of axillopopliteal reconstruction, 3 of which occluded within one year and all were occluded after 5 years. This group abandoned axillopopliteal reconstructions and performed in situ replacement if outflow problems existed (Seeger et al., 2000).

Aortic graft infection can also be treated with simultaneous aortic graft excision and in situ aortic graft replacement with a variety of new aortic grafts (an autogenous graft, a homograft or a new prosthetic graft). Clagett et al. and Nevelsteen et al. have reviewed the use of autogenous grafts constructed from deep femoral veins to treat 41 and 15 patients with infected aortic grafts. Postoperative mortality rates were 10% and 7%, respectively, in these studies, and early amputation rates were 5% and 7%. Furthermore, Clagett reported that primary and secondary graft patency rates at 5 years were 83% and 100%, 5-year limb salvage was 86%, and significant lower extremity edema was uncommon (Clagett et al., 1997; Nevelsteen et al., 1995). A Dutch group produced excellent results with spiralised great saphenous veins as an aortic replacement for and infected prosthesis (van Zitteren et al. 2011). They treated 5 patients and reported no deaths and no amputations after 13 months of follow up.

2.1.3.4 Non-operative management of graft infection in the compromised patient

In some cases, graft removal is not feasible because of poor clinical condition of the patient after emergency aneurysm repair, a hostile abdomen or severe co-morbidity. Different methods of preserving the infected graft have been attempted. We have described two patients with infected grafts, unfit for immediate graft removal. The first was treated only by specific antibiotic treatment and the second was treated with percutaneous drainage and antibiotic treatment aimed at the cultured microorganism. To date, both patients are alive. One is on life-long antibiotic therapy (own unpublished data, Figures 1 and 2).

Calligaro et al. reported a 20 year experience with nine patients unfit for graft explantation. Principles of treatment were percutaneous or operative drain placement into retroperitoneal abscess cavities and along the graft, with instillation of antibiotics three times daily, repeated debridement of infected groin wounds, and intravenous antibiotic therapy for at least 6 weeks. They concluded that partial or complete graft preservation combined with aggressive drainage and groin wound debridement is an acceptable option for treatment of infection involving an entire aortic graft in selected patients with prohibitive risks for total graft excision. This treatment may be compatible with long-term survival and protracted absence of signs or symptoms of infection (Calligaro et al., 2003).

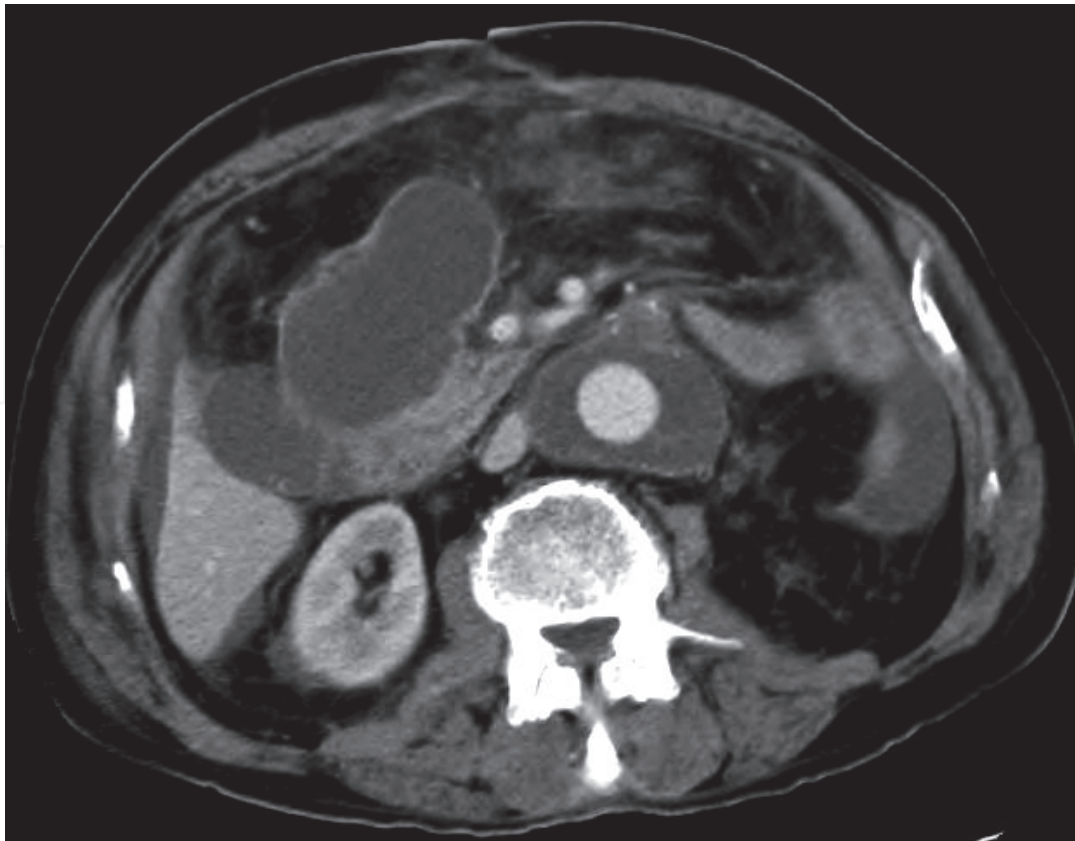


Fig. 1. Abdominal CT angiography shown an abscess and perigraft fluid.

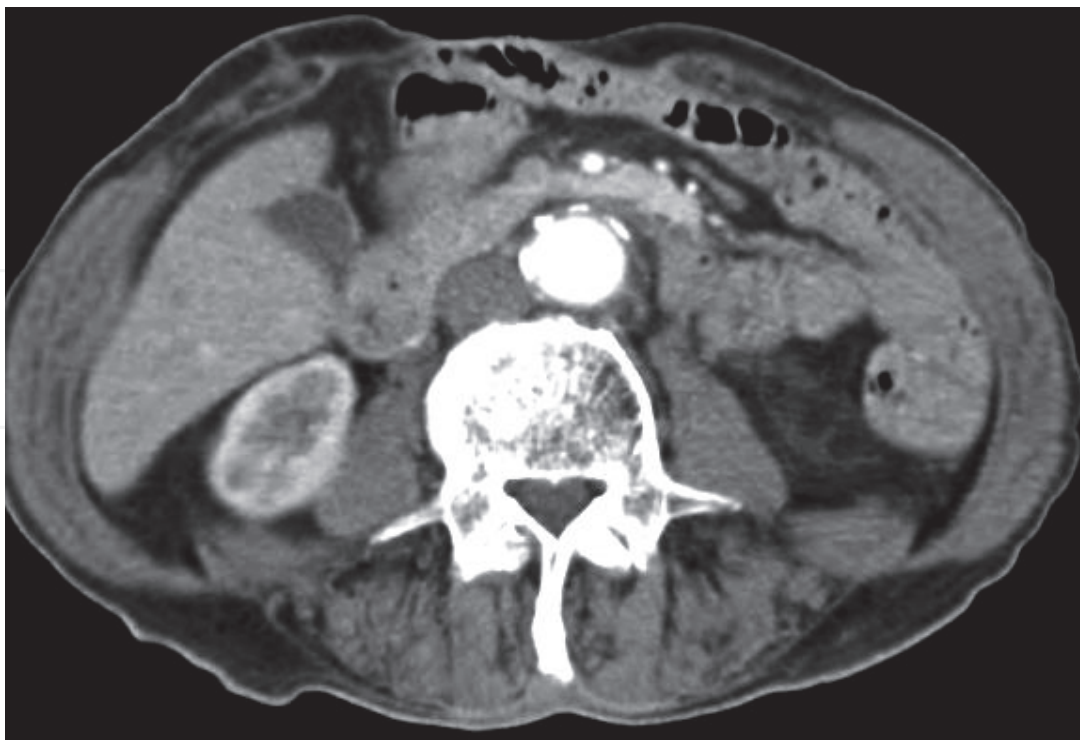


Fig. 2. Abdominal CT angiography after percutaneous drainage of abscess and 2 years of antibiotic treatment.

In conclusion, the treatment of the patient with an infected graft is a major challenge. The fitness of the patient is the most important factor in management, while virulence of the micro-organism is another factor. In young, fit patients, graft removal and in situ repair seems the most durable option. Extra-anatomic repair can be a less invasive procedure for the compromised patient. In severely compromised patients or those with a hostile abdomen, conservative management is feasible.

2.1.4 Aortoenteric fistula

Secondary aortoenteric fistulae complicate 0.3%-2.5% of all open aortic surgical procedures (Plate 1985, Bergquist 1987). On presentation, upper gastro-intestinal bleeding, hemorrhagic shock and fever may be present. Diagnosis is confirmed with gastroduodenoscopy and CT angiography. Despite prompt open repair, secondary aortoenteric fistula remains a very lethal condition with mortality rates up to 50% (Kakkos, 2011).

A small series by Kuestner et al. described extra-anatomic bypass followed a few days thereafter by graft removal. Aortic stump blow out is a feared complication, and occurred in 9.1%. The major amputation rate was also 9.1%. Total mortality was as high as 27% (Keustner, 1993). Results are comparable with similar surgical management of infected prosthesis. Because of poor outcome, other attempts have been made to treat this complication. As with infected prosthesis, in situ repairs as described by Nevelsteen et al. and Clagett et al. have reasonable results.

Kakkos et al. recently published a comparison of open versus endovascular treatment of aortoenteric fistulae. Eight patients were treated with EVAR and 17 with open repair, of which 12 with extra-anatomical bypass and graft removal. There was a short term survival benefit after EVAR (0% mortality) and open repair (35% mortality). This difference had disappeared after two years because of excess recurrent disease in the EVAR group. The authors conclude that EVAR might be used in the future as a bridge to definitive repair (Kakkos et al., 2011)

2.2 Non-graft related complications

The magnitude of laparotomy related late complications has been poorly appreciated until recently. This is probably because of lack of proper follow-up. Nowadays, more attention has focused on non-vascular complications of open AAA repair. Giles et al. did an excellent survey on more than 40,000 Medicare beneficiaries after open repair or EVAR in the United States. Readmissions and reinterventions were 7.0 per 100 person-years after open repair. Laparotomy-related reinterventions had a considerably high 30-day mortality rate of 8.5% (Giles et al. 2011). This illustrates the major impact on health caused by laparotomy for open aortic repair.

2.2.1 Incisional hernia

Incisional hernia is an often underestimated complication after open abdominal aortic aneurysm repair

Incidences as high as 90% after midline laparotomy are reported in the literature after surgery for aneurysm (Fassiadis et al., 2005). This was with routine use of ultrasound and not all hernia demanded treatment. Others report lower incidence: 30% (Holland et al., 1996). The cause of high incidence of hernia after aneurysm surgery is thought to be a

consequence of a connective tissue disorder. Transverse incisions have shown fewer hernias and may have the same exposure of the aorta (Fassiadis et al., 2005). A recent report from the UK showed the feasibility of a minilaparotomy for open aortic aneurysm repair (Hafez et al., 2011). They performed a 10 cm transverse supraumbilical laparotomy in 83 non-obese patients with AAA and reported a low mortality rate of 2.4% and only 2 incisional hernias. This excellent result is most likely a single surgeon experience. Besides that, the technique required 3 years to develop. A recent trial showed less incisional hernia with primary mesh closure of laparotomy after elective AAA repair (Bevis et al., 2010). In our experience, midline laparotomy is still the standard approach in open aneurysm repair. Especially in the setting of a vascular teaching hospital, we need maximum exposure of the aorta. Further research is required to determine the overall applicability of different techniques to minimize the morbidity of incisional hernia.

2.2.2 Small bowel obstruction

After laparotomy, incidence of small bowel obstruction (SBO) is estimated at 5-30%, depending on type of surgery. (Barmparas et al. 2010) After aortic surgery the literature is scarce and major trials do not report readmissions for SBO or reoperations. SBO in the immediate postoperative phase relatively infrequent after aortic surgery. An incidence of 2.6% is mentioned with a reoperation rate of 41%. (Siporin et al. 1993). De Bruin et al. described 2 immediate and 1 late bowel obstruction after open aneurysm repair (De Bruin et al., 2010). According to Crowson et al. the overall rate of gastrointestinal complications after infrarenal aortic aneurysm repair is 6.6%. In their series of 472 aortic aneurysm repairs, a small bowel obstruction developed after surgery in only two patients, caused by adherence to the aneurysmal sac and a deep tension suture having pierced the small bowel, respectively. (Crowson et al., 1984). More long-term data are not available for SBO after aortic surgery.

An unusual cause of SBO is duodenal obstruction, which has been described in the literature in case reports. This can be caused by the postoperative development of a retroperitoneal hematoma after aneurysm repair. (Tessier et al., 2003; Rijken & Butzelaer, 1996)

2.2.3 Sexual dysfunction

In the first edition of Rutherford's Vascular Surgery, the potential impact of aortic surgery on postoperative sexual function was not even mentioned. Nowadays, we recognize the importance of preserving blood flow to the internal iliac arteries and avoiding injury to the autonomic nerves flanking the aortoiliac bifurcation. Beyond these basic principles, however, we remain rather ignorant of the impact of vascular surgery on sexual function. Erectile dysfunction is frequently reported after open aneurysm repair, in tube and bifurcated grafts up to 83%. Obtaining meaningful data on this subject is difficult because of poor response rates to questionnaires (Lee et al., 2000). A prospective study from Netherlands showed that both EVAR and open elective AAA repair have an impact on sexual function in the early postoperative period but the recovery to the preoperative level was faster with EVAR than after OR (Prinssen et al., 2004).

2.2.4 Buttock claudication

Buttock claudication has been warned for when both internal iliacs are interrupted in open as well as endovascular aneurysm repair. A study by Mehta described the single center

experience of 48 cases with both internal iliacs sacrificed during open repair or EVAR. Forty-one percent developed buttock claudication but after one year, only 14% still complained. The article describes high ligation of the internal iliac and preservation of side branches of external iliac and femoral vessels as well as systemic heparinisation as possible contributors to their good results in this controversial technique. (Mehta et al., 2004)

2.3 Long term survival

Survival after AAA repair is largely dependent on co morbidities. After open surgery, 6-year survival is approximately 70%. Not surprisingly, systemic complications of atherosclerosis cause most late deaths after AAA repair. Myocardial infarction, cerebrovascular events in other aneurysms are the major causes of death. Vascular complications account for two thirds of late deaths following aneurysm repair. Cancer is the second cause of late mortality (10-15%), followed by pulmonary disease. In 1985, Plate et al. followed up 1,112 patients who underwent abdominal aortic aneurysm repair. Follow-up, ranging from six to 12 years, was complete in 1,087 patients (97.7%). The most frequent cause of late deaths was coronary artery disease (45.6%) and significant morbidity related to the peripheral vascular system had developed in 94 patients, and led to 8.4% (48 patients) of all late deaths (Plate et al., 1985).

3. Late complications after endovascular aneurysm repair

With the start of endovascular repair, initiated with the first report by Parodi in 1991, a new era of aneurysm repair had started (Parodi et al., 1991). The first randomized trials comparing endovascular with open aneurysm repair have not been published until 2004. Two recently published randomized trials comparing the effectiveness of open surgical and endovascular repair for the treatment of abdominal aortic aneurysms have demonstrated a significantly lower mortality rate for patients undergoing EVAR. However, the initial short-term survival advantage for patients undergoing EVAR was lost after long-term follow-up. A significant proportion of the late deaths of patients undergoing EVAR were due to aneurysm rupture. These concerning findings raise questions about the effectiveness and durability of EVAR to prevent death caused by abdominal aortic aneurysm rupture. (De Bruin et al., 2010; Greenhalgh et al., 2004)) Late aneurysm-related complications are more frequent after endovascular repair and pose the vascular surgeon for different challenges.

3.1 Infectious complications

Infectious complications are equally frequent after endovascular and open repair, and affects about 1-3% of patients. Management principles are similar to those of any infected prosthesis. However, the treatment depends on the patients' condition and the virulence of the micro-organism. Both open surgical repair with graft removal and non-operative treatment are feasible. Mortality remains very high.

3.1.2 Surgical technique of stent graft removal from the aorta

A specific problem of graft removal is the suprarenal fixation of stents at the renal arteries. Our group reported a new method of removing an infected endoprosthesis from the abdominal aorta using a wire cutter. Three months after placement of an endovascular abdominal endoprosthesis for a ruptured aneurysm, the patient returned with an infection

of the aortic endoprosthesis. The endoprosthesis had been fixed with barbs and hooks above the renal arteries and was surgically explanted by using a wire cutter to cut the hooks. The bare suprarenal stent was left in place. The patient was discharged one month after stent removal, and was treated with oral antibiotics for another ten weeks. At one year follow-up the patient showed no clinical, biochemical, or radiological signs of infection. A Zenith endoprosthesis requires a dangerous procedure because the hooks of the bare stent are engaged into the supra-renal aorta. This case report documented a new technique to safely remove an infected endoprosthesis with the help of a wire cutter (Dolmans et al. 2009). Another group from the Netherlands described a different technique using the barrel of a syringe with the top end removed to slide over the endoprosthesis cranially to withdraw the hooks from the aortic wall (Koning et al. 2006).

3.2 Device related complications

3.2.1 Endoleak

Up to 23-36% patients require a reintervention after endovascular repair. This is most frequently because of an endoleak. Endoleak is defined as persistent blood flow outside the lumen of the endoluminal graft but within the aneurysm sac, as determined by an imaging study. Endoleaks will not be discussed here, as they are dealt with in another chapter.

3.2.2 Stent migration, kinking and occlusion

Long-term results of EVAR are now being published more and more. Long term results of randomised trials show 1-10% graft problems such as kinking, migration and occlusion after 6 years of follow up (De Bruin et al. 2010, Greenhalgh et al. 2010). A large study of secondary procedures after EVAR described 13.6 % migration and 7.4% limb occlusion (Mehta et al., 2010). Despite technical improvement in endovascular devices, device failures continue to occur in recent studies.

Waasdorp et al. studied the importance of iliac fixation to secure endograft fixation (Waasdorp et al. 2009). 154 Talent™ stent grafts were followed up with serial CT imaging. Proximal endograft migration occurred in 32 of 154 patients (21%) at a follow-up duration of 32; 13 migrations required treatment (8%). Migration was more frequent in patients treated with aorto-uniiliac devices than bifurcation devices. The migrator group had significantly shorter proximal and distal endograft fixation lengths. By multivariate regression analysis, proximal and distal endograft fixations were significant predictors for endograft migration at follow-up.

In our clinic we observed that in 66 Zenith® (COOK MEDICAL INC., Bloomington, IN, USA) stentgrafts, nine out of 12 complications which required reintervention were due to problems with one of the leg extensions. This was the first study that clearly specified the percentage of problems with leg extensions in EVAR with one specific device (75%). We advise that during placement of a Zenith endovascular graft, extra attention should be paid to optimal placement of the leg extensions (Bindsbergen van et al., 2008).

3.2.3 Aneurysm rupture after EVAR

Rupture after EVAR is the ultimate failure of this treatment. Giles et al. reported 0.13 ruptures per 100 person-years after EVAR versus 0.01 after open repair (Giles et al., 2011). Mehta described 8.6% aneurysm rupture after EVAR with a mean follow up of 29 months (Mehta et al. 2010). Half of these ruptures were treated endovascular and half with open

repair. Mortality was 7% vs. 25% respectively without statistical significance. Some have proposed that previous EVAR protects your patient from hemodynamic instability and improves survival in case of rupture. 30-day mortality was 28.5 % in previously treated patients and 38.7% in primary ruptures. This was not a significant difference (Coppi et al., 2009). Others claim the opposite: more mortality after previous EVAR. Kelso et al. reported 19% mortality and 9% excluding ruptures (Kelso et al., 2010). Recently, Schanzer reported an alarming increase in aneurysm size after EVAR in 40% of cases (Schanzer et al., 2011). This percentage increased in time during the study period (1999-2008). The authors suggested a liberalization of the instructions for use as a possible cause for this increase. Growing aneurysm diameter is sign of incomplete exclusion of the aneurysm and can therefore predict rupture.

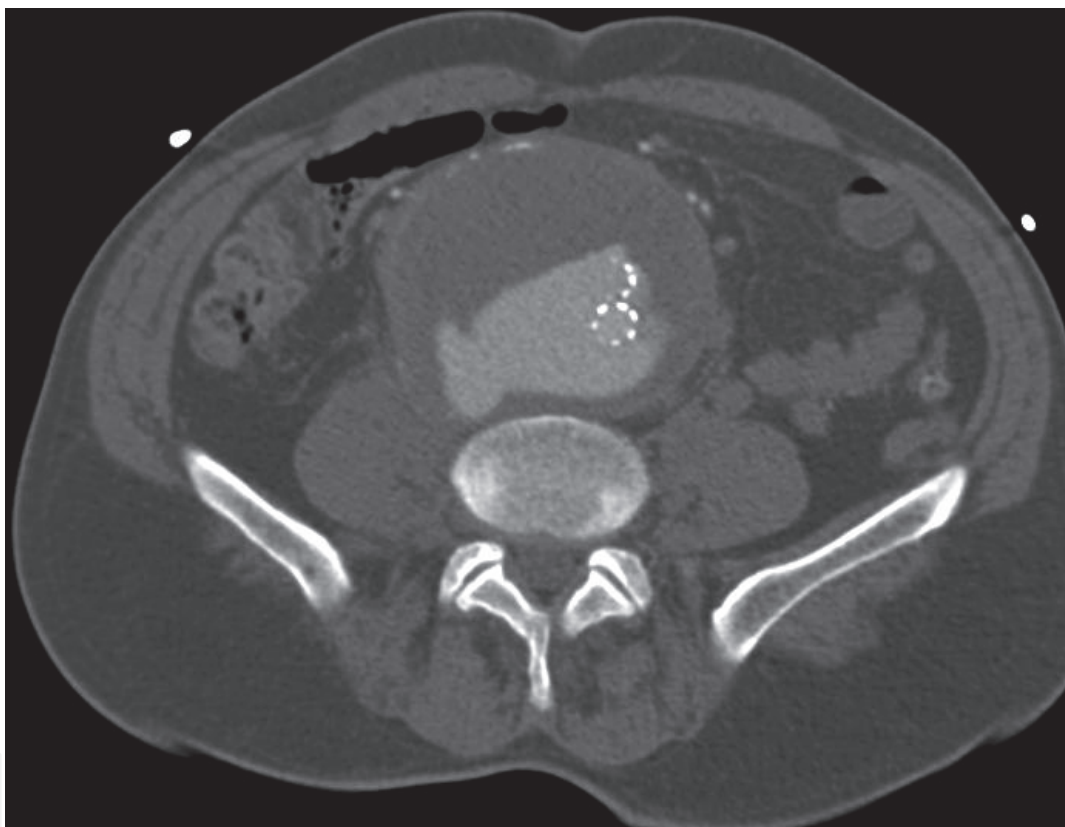

Fig. 3. A symptomatic aortic aneurysm 4 years after placement of uniliac stent-graft for RAAA. Notice the type 3 endoleak as two parts of the graft are not connected.

In conclusion, EVAR is increasingly popular in current vascular practice, although questions keep rising on the durability of EVAR in the long term. In our practice EVAR will be first choice in most elective AAA patients with favorable anatomy. Young patients (<65 years) will be considered for open repair even with favorable EVAR anatomy. On the other hand, in vascular cripples with unfavorable anatomy, we do go outside de instructions for use of EVAR. Long term results of two European randomized trials have shown no benefit after 2 years and an increase in secondary procedures 4 years after EVAR (De Bruin et al. 2010, Greenhalgh et al., 2010). Therefore, the chances for the vascular surgeon of having to perform reoperative surgery on previously treated aneurysms, open or endovascular, will increase in the future.

3.4 Follow-up after endovascular repair

As shown in the previous paragraph, follow-up is necessary after endovascular aneurysm repair to detect complications before rupture. The optimal follow-up regimen is under debate in the literature, as little is known about how current endovascular grafts will perform in the future. Different imaging studies are being used. CT angiography is the gold standard, sometimes combined with plain abdominal x-ray. Because of increasing awareness of the disadvantages of CT scanning, other follow-up regimens are currently under study. Abdominal duplex ultrasound scanning (plain or contrast-enhanced), combined with plain abdominal x-ray are a reasonable alternative. Aneurysm size, endoleak type I and III can be detected with duplex. Despite its low positive predictive value, Manning et al. found duplex ultrasound to be a sensitive test for the detection of clinically significant endoleaks. Given concerns about cumulative radiation exposure and cost the authors see a future for ultrasound in follow-up of stable aneurysms after EVAR.

There is currently no consensus on the optimal follow up regimen. In our clinic, we still perform CT scanning combined with plain abdominal x-ray. In the future, duplex scanning may play a role in follow up.

4. Conclusion

This overview shows that late complications after open aortic aneurysm repair are an important health issue. Especially considering the fact that elective aneurysm repair is a procedure performed on asymptomatic patients. Late complications after open repair should not be underestimated, in light of the high mortality of re-interventions. Endovascular solutions for late complications of open repair such as pseudoaneurysm are promising. On the other hand, major concerns about the durability of EVAR appeared in recent studies. This indicates that there is still a role for open repair. However, we believe that endovascular repair will expand even more in the near future. With an ageing population and increasing rates of endovascular repair, the vascular surgeon will probably encounter more late endovascular complications. The challenge for the current vascular surgeon lies in the prevention and detection of these complications. Familiarity with both open and endovascular techniques give the future vascular surgeon the possibility to manage these complications adequately.

5. References

- Allen, R., Schneider, J. & Longenecker, L. (1993). Paraanastomotic aneurysms of the abdominal aorta, *Journal of Vascular Surgery*. Vol. 18, No. 3, (September 1993), pp. 424-432
- Bandyk, D. (2002). Antibiotics – Why so many and when should we use them? *Seminars in Vascular Surgery*, Vol. 15, No. 4, (December 2002), pp. 268-274
- Barmparas, G., Branco, B. & Schnüriger, B. (2010). The Incidence and Risk Factors of Post-Laparotomy Adhesive Small Bowel Obstruction. *Journal of Gastrointestinal Surgery*, Vol.14, No. 10, (October 2010), pp. 1619-1628
- Bergqvist, D., Alm, A. & Claes, G. (1987). Secondary aortoenteric fistulas - an analysis of 42 cases. *European Journal of Vascular Surgery*, Vol. 1, No. 1, (February 1987), pp. 11-18

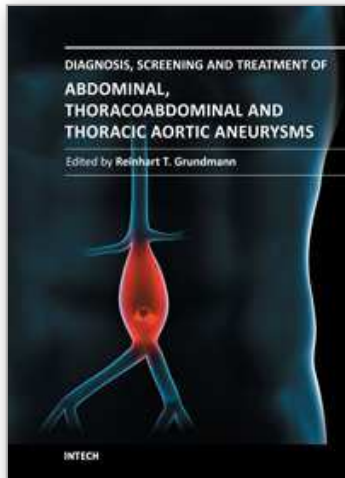
- Bevis P., Windhaber, R. & Lear, P. (2010). Randomized clinical trial of mesh *versus* sutured wound closure after open abdominal aortic aneurysm surgery. *British Journal of Surgery*, Vol. 97, No. 10, (October 2010), pp. 1497-1502
- Biancari F., Ylonen, K. & Anttila, V. (2002). Durability of open repair of infrarenal abdominal aortic aneurysm: a 15-year follow-up study. *Journal of Vascular Surgery*, Vol. 35, No. 1, (January 2002), pp. 87-93
- Bindsbergen van, L., Dolmans, D. & Van der Laan, L. (2008) Endovascular aneurysm repair with Zenith graft. Complications caused by leg extensions. *Journal of Cardiovascular Surgery (Torino)*, Vol. 49, No. 3, pp. 311-316
- Blaisdell, F., Hall, A. & Lim, R. (1970). Aorto-iliac arterial substitution utilizing subcutaneous grafts. *Annals of surgery*, Vol. 172, No. 5, (November 1970), pp. 775-80.
- Bruggink, J., Glaudemans, A. & Saleem, B. (2010). Accuracy of FDG-PET-CT in the diagnostic work-up of vascular prosthetic graft infection. *European Journal of Vascular and Endovascular Surgery*, Vol. 40 Pp. 348-354.
- Calligaro, K., Veith, F. & Yuan, J. Intra-abdominal aortic graft infection: complete or partial graft preservation in patients at very high risk. *Journal of Vascular Surgery*, Vol. 38, No. 6, (December 2003), pp. 1199-1205
- Chaikof, E., Blankensteijn J. & Harris, H. for the Ad Hoc Committee for Standardized Reporting Practices in Vascular Surgery of The Society for Vascular Surgery/American Association for Vascular Surgery. (2002). Reporting standards for endovascular aortic aneurysm repair. *Journal of Vascular Surgery*, Vol. 35, No. 5, (May 2002), pp. 148-60
- Clagett, G., Valentine R. & Hagino R. (2007). Autogenous aortoiliac/femoral reconstruction from superficial femoral-popliteal veins: feasibility and durability. *Journal of Vascular Surgery*, Vol. 25, No. 2, (February 1997), pp. 255-270
- Conrad, M., Crawford, R. & Pedraza, J. (2007). Long-term durability of open abdominal aortic aneurysm repair *Journal of Vascular Surgery*, Vol. 46, No. 4, (October 2007), pp. 669-675
- Coppi, G., Gennai, S. & Saitta, G. (2009). Treatment of ruptured abdominal aortic aneurysm after endovascular abdominal aortic repair: A comparison with patients without prior treatment *Journal of Vascular Surgery*, Vol. 49, No. 3. (March 2009), pp. 582-588
- Cosford, P. & Leng, G. (2007). Screening for abdominal aortic aneurysm. *Cochrane Database Systematic Review*, Vol. 18, No. 2, (April 2007), D002945
- Creech O. (1966). Endo-aneurysmorrhaphy and treatment of aortic aneurysm. *Annals of Surgery* Vol. 164, No. 6, (December 1966), pp. 935-946
- Crowson, M., Fielding, J. & Black, J. (1984). Acute gastrointestinal complications of infrarenal aortic aneurysm repair. *British Journal of Surgery*, Vol. 71, No. 11, (November 1984), pp. 825-828
- De Bruin J., Baas, A. & Buth, J. (2010). Long-term outcome of open or endovascular repair of abdominal aortic aneurysm. *New England Journal of Medicine*, Vol. 362, No. 20, (May 2010) pp. 1881-1889
- Dolmans D., Ho G. & Van Der Laan L. (2009). Surgical removal of an infected aortic endoprosthesis using a wire cutter. *Journal of Cardiovascular Surgery (Torino)*, Vol. 50, No.3, (June 2009), pp. 411-414
- Dubost C, Allary, M. & Oeconomos, N. (1952). Resection of an aneurysm of the abdominal aorta: reestablishment of the continuity by a preserved human arterial graft, with

- result after five months. *AMA Archives of Surgery*, Vol. 64, No. 3, (March 1952), pp. 405-8
- Edwards, J., Teehey, S. & Zierler, R. (1992). Intraabdominal paraanastomotic aneurysms after aortic bypass grafting. *Journal of Vascular Surgery*, Vol. 15, No. 2, (February 1992), pp. 344-350
- Greenhalgh, R., Brown, L. & Kwong, G. EVAR Trial Participants. (2004). Comparison of endovascular aneurysm repair with open repair in patients with abdominal aortic aneurysm (EVAR trial 1), 30-day operative mortality results: randomised controlled trial. *The Lancet*, Vol. 364, No. 9437, (September 2004), pp. 843-848
- Greenhalgh, R., Brown, L. & Powell, J. The United Kingdom EVAR Trial Investigators. (2010). Endovascular versus open repair of abdominal aortic aneurysm. *The New England Journal of Medicine*, Vol. 362, No. 20 (May 2010), pp. 1863-1871
- Fassiadis, N., Roidl, M. & Andrews, S. (2005). Randomized clinical trial of vertical or transverse laparotomy for abdominal aortic aneurysm repair. *British Journal Surgery*, Vol. 92, No. 10, (October 2005), pp. 1208-11
- Giles, K., Landon, B & Cotterill, P. (2011). Thirty-day mortality and late survival with reinterventions and readmissions after open and endovascular aortic aneurysm repair in Medicare beneficiaries. *Journal of Vascular Surgery*, Vol. 53, No. 1, (January 2011), pp. 6-13
- Sfyroeras, G., Lioupis G. & Bessias, N. (2008). Endovascular Treatment of a Ruptured Para-Anastomotic Aneurysm of the Abdominal Aorta. *Cardiovascular Intervention Radiology*, Vol. 31, Suppl. 2, (July 2008) pp. S79-S83
- Hafez, H. Makhosini, M. & Abbassi-Ghaddi, N. (2011). Transverse minilaparotomy for open abdominal aortic aneurysm repair. *Journal of Vascular Surgery*, Vol. 53, No. 6, (June 2011), pp. 1514-1519
- Hallett, J., Marshall, D. & Petterson T. (1997). Graft-related complications after abdominal aortic aneurysm repair: reassurance from a 36-year population-based experience. *Journal of Vascular Surgery*, Vol. 25, No. 2, (February 1997), pp. 277-284, discussion 285-286
- Hertzer, N., Mascha, E. & Karafa, M. (2002). Open infrarenal abdominal aortic aneurysm repair: the Cleveland Clinic experience from 1989 to 1998. *Journal of Vascular Surgery*, Vol. 35, No. 6, (June 2002), pp. 1145-1154
- Herwaarden van, J., Waasdorp, E. & Bendermacher, B. (2004). Endovascular Repair of Paraanastomotic Aneurysms after Previous Open Aortic Prosthetic Reconstruction. *Annals of Vascular Surgery*, Vol. 18, No. 3, (May 2004), pp. 280-286
- Holland, A., Castleden, W. & Norman, P. (1996). Incisional hernias are more common in aneurysmal disease. *European Journal of Vascular and Endovascular Surgery*, Vol. 12, No. 2, (August 1996), pp. 196-200
- Kakkos, S., Antoniadis, P. & Klonaris, C. (2011). Open or endovascular repair of aortoenteric fistulas? A multicentre comparative study. *European Journal of Vascular and Endovascular Surgery*, Vol. 41, No. 5, (May 2011), pp. 625-634
- Kelso, R., Lyden, S. & Butler, B. (2009). Late conversion of aortic stent grafts. *Journal of Vascular Surgery*, Vol. 49, No. 3 (March 2009), pp. 589-595
- Koning, O., Hinnen, J-W. & van Baalen, J. (2006). Technique for safe removal of an aortic endograft with suprarenal fixation. *Journal of Vascular Surgery*, Vol 43, No. 4, (April 2006), pp. 855-857

- Kuestner, L., Reilly, L., & Jicha, D. (1995). Secondary aortoenteric fistula: contemporary outcome with use of extraanatomic bypass and infected graft excision. *Journal of Vascular Surgery*, Vol. 21, No. 2, (February 1995), pp. 184-195, discussion 195-196
- Lee, E., Kor, D. & Kuskowski, M. (2000). Incidence of Erectile Dysfunction after Open Abdominal Aortic Aneurysm Repair, *Annals of Vascular Surgery*, Vol. 14, No. 1, (January 2000), pp. 13-19
- Manning, B., O'Neill, S. & Haider, S. (2009). Duplex ultrasound in aneurysm surveillance following endovascular aneurysm repair: a comparison with computed tomography aortography. *Journal of Vascular Surgery*, Vol. 49, No. 1, (January 2009), pp. 60-65
- Mehta, M., Veith, F., & Darling C. (2004). Effects of bilateral hypogastric artery interruption during endovascular and open aortoiliac aneurysm repair. *Journal of Vascular Surgery*, Vol. 40, No. 4, (October 2004), pp. 698-702
- Mehta, M., Sternbach, Y. & Taggert, J. (2010). Long-term outcomes of secondary procedures after endovascular aneurysm repair. *Journal of Vascular Surgery*, Vol. 52, No. 6, (December 2010), pp. 1442-1448
- Menke, V., Castenmiller, P. & Van der Laan, L. (2010). Stent Grafting a Ruptured Para-anastomotic Iliac Aneurysm. *Vascular and Endovascular Surgery*, Vol. 44, No. 6, (August 2006), pp. 479-482
- Mulder, E.; van Bockel, J. & Maas, J. (1998). Morbidity and mortality of reconstructive surgery of noninfected false aneurysms detected long after aortic prosthetic reconstruction. *Archives of Surgery*, Vol. 133, No. 1, pp. (January 1998), pp. 45-49
- Mussa, F., Hedayati, N. & Zhou, W. (2007). Prevention and treatment of aortic graft infection. *Expert Review of Anti-Infective Therapy*, Vol. 5, No. 2, (April 2007), pp. 305-315
- Nevelsteen, A., Lacroix, H. & Suy, R. (1995). Autogenous reconstruction with the lower extremity deep veins: an alternative treatment of prosthetic infection after reconstruction surgery for aortoiliac disease. *Journal of Vascular Surgery* Vol. 22, No. 2, (August 1995), pp. 129-34
- Parodi, J., Palmaz, J. & Barone, H. (1991). Transfemoral intraluminal graft implantation for abdominal aortic aneurysm. *Annals of Vascular Surgery*, Vol. 5, No. 6, (November 1991), pp. 491-499
- Prinssen, M., Buskens, E. & Nolthenius, R. (2004). Sexual dysfunction after conventional and endovascular AAA repair: Results of the DREAM trial. *Journal of Endovascular Therapy*, Vol. 11, pp.613-20.
- Prinssen, M., Verhoeven E. & Buth J. (2004). A randomized trial comparing conventional and endovascular repair of abdominal aortic aneurysms. *The New England Journal of Medicine*, Vol. 351, No. 16, (October 2004), pp. 1607-1618
- Reilly, M., Stoney, R. & Goldstone, J. (1987). Improved management of aortic graft infection: the influence of operation sequence and staging. *Journal of Vascular Surgery*, Vol. 5, No. 3 (March 1987), pp. 421-431
- Schanzer, A., Greenberg, R. & Hevelone, N. (2011). Predictors of abdominal aortic aneurysm sac enlargement after endovascular repair, *Circulation*, Vol. 123, (April 2011), E-pub ahead of print may 2011
- Schrijver, A., Reijnen, M. & van Oostayen, J. (2011). Initial Results of Catheter-Directed Ultrasound-Accelerated Thrombolysis for Thromboembolic Obstructions of the

- Aortofemoral Arteries: A Feasibility Study. *Cardiovascular Intervention Radiology*. (May 2011) [Epub ahead of print]
- Seeger, J., Pretus, H. & Welborn, M. (2000). Long-term outcome after treatment of aortic graft infection with staged extraanatomic bypass grafting and aortic graft removal. *Journal of Vascular Surgery*; Vol. 32, No. 3, (September 2000), pp. 451-461
- Siporin, K., Hiatt, K. & Treiman, R. (1993). Small bowel obstruction after abdominal aortic surgery. *The American Surgeon*, Vol. 59, No. 12, (December 1993), pp. 846-849
- Tessier, D. & Brophy, C. (2003). Causes, diagnosis, and management of duodenal obstruction after aortic surgery. *Journal of Vascular Surgery*, Vol. 38, No. 1, (July 2003), pp. 186-189
- Treiman, G., Weaver, F. & Cossman, D. (1988). Anastomotic false aneurysms of the abdominal aorta and the iliac arteries. *Journal of Vascular Surgery*, Vol. 8, No. 3, (September 1988), pp. 268-273
- Waasdorp, E., de Vries, J. & Sterkenburg, A. (2009). The association between iliac fixation and proximal stent-graft migration during EVAR follow-up: mid-term results of 154 Talent devices, *European Journal of Vascular and Endovascular Surgery*, Vol. 37, No. 6, (June 2009), pp. 681-687
- Yuan, J., Marin, M. & Veith, F. (2009). Endovascular grafts for noninfected aortoiliac anastomotic aneurysms (1997), *Journal of Vascular Surgery*, Vol. 26, No. 2, (June 2009), pp. 210-221
- Zitteren van, M., Steenhoven van der, T. & Burger, D. (2011). Spiral vein reconstruction of the infected abdominal aorta using the greater saphenous vein: preliminary results of the Tilburg experience, *European Journal of Vascular and Endovascular Surgery*, Vol. 41, No. 5, (May 2011), pp. 637-646. URL: <http://www.spiralvein.org>

IntechOpen



Diagnosis, Screening and Treatment of Abdominal, Thoracoabdominal and Thoracic Aortic Aneurysms

Edited by Prof. Reinhart Grundmann

ISBN 978-953-307-466-5

Hard cover, 414 pages

Publisher InTech

Published online 12, September, 2011

Published in print edition September, 2011

This book considers mainly diagnosis, screening, surveillance and treatment of abdominal, thoracoabdominal and thoracic aortic aneurysms. It addresses vascular and cardiothoracic surgeons and interventional radiologists, but also anyone engaged in vascular medicine. The high mortality of ruptured aneurysms certainly favors the recommendation of prophylactic repair of asymptomatic aortic aneurysms (AA) and therewith a generous screening. However, the comorbidities of these patients and their age have to be kept in mind if the efficacy and cost effectiveness of screening and prophylactic surgery should not be overestimated. The treatment recommendations which will be outlined here, have to regard on the one hand the natural course of the disease, the risk of rupture, and the life expectancy of the patient, and on the other hand the morbidity and mortality of the prophylactic surgical intervention. The book describes perioperative mortality after endovascular and open repair of AA, long-term outcome after repair, and the cost-effectiveness of treatment.

How to reference

In order to correctly reference this scholarly work, feel free to copy and paste the following:

Michiel L.P. van Zeeland and Lijckle van der Laan (2011). Late Complications Following Aortic Aneurysm Repair, Diagnosis, Screening and Treatment of Abdominal, Thoracoabdominal and Thoracic Aortic Aneurysms, Prof. Reinhart Grundmann (Ed.), ISBN: 978-953-307-466-5, InTech, Available from: <http://www.intechopen.com/books/diagnosis-screening-and-treatment-of-abdominal-thoracoabdominal-and-thoracic-aortic-aneurysms/late-complications-following-aortic-aneurysm-repair>

INTECH
open science | open minds

InTech Europe

University Campus STeP Ri
Slavka Krautzeka 83/A
51000 Rijeka, Croatia
Phone: +385 (51) 770 447
Fax: +385 (51) 686 166
www.intechopen.com

InTech China

Unit 405, Office Block, Hotel Equatorial Shanghai
No.65, Yan An Road (West), Shanghai, 200040, China
中国上海市延安西路65号上海国际贵都大饭店办公楼405单元
Phone: +86-21-62489820
Fax: +86-21-62489821

© 2011 The Author(s). Licensee IntechOpen. This chapter is distributed under the terms of the [Creative Commons Attribution-NonCommercial-ShareAlike-3.0 License](#), which permits use, distribution and reproduction for non-commercial purposes, provided the original is properly cited and derivative works building on this content are distributed under the same license.

IntechOpen

IntechOpen