

We are IntechOpen, the world's leading publisher of Open Access books Built by scientists, for scientists

4,800

Open access books available

122,000

International authors and editors

135M

Downloads

Our authors are among the

154

Countries delivered to

TOP 1%

most cited scientists

12.2%

Contributors from top 500 universities



WEB OF SCIENCE™

Selection of our books indexed in the Book Citation Index
in Web of Science™ Core Collection (BKCI)

Interested in publishing with us?
Contact book.department@intechopen.com

Numbers displayed above are based on latest data collected.

For more information visit www.intechopen.com



Treatment of Epilepsy Secondary to Neurocysticercosis

Humberto Foyaca-Sibat and Lourdes de Fátima Ibañez-Valdés
*Walter Sisulu University, Faculty of Health Sciences,
Nelson Mandela Academic Hospital, Division of Neurology,
South Africa*

1. Introduction

Lack of curative treatment in most of neurological disorder has been a permanent frustration for almost all of us. Fortunately, good news about novel therapeutic approaches and its excellent responses are gradually arriving and today we can celebrate some therapeutic advances such as: cytokines-based therapies for immune-mediated inflammatory myopathies; myoclonal antibodies for the treatment of certain types of immune-mediated inflammatory neuropathies, myopathies, and T-cell mediated disorders; enzyme replacement therapy for Pompe's disease. Non-ergoline dopamine agonist and deep-brain stimulation of subthalamic nucleus and the globus pallidus internus in Parkinson disease, and immunomodulatory agents for multiple sclerosis among others and some exciting therapeutic approaches will come very soon for example: antisense oligonucleotides in Duchenne muscular dystrophy. Stem-cell therapy and gene therapy for inherited neuromuscular disorders, up-regulation of fetal isoforms in hereditary disorders such as: myophosphorylase deficiency, and novel forms of neuromodulation. Unfortunately, for treatment of epilepsy secondary to neurocysticercosis (NC) no therapeutic advances has been reported and apart from carbamazepine (CBZ) and valproic acid (VA) no other antiepileptic drug (AED) has proven better efficacy. Although, levetiracetam seems to be as well as CBZ and VA it is not available in rural clinics and in most of the public hospitals from developing countries where NC is endemic. Therefore, several millions of epileptic patients cannot reach levetiracetam worldwide.

Pharmacoresistance in developed countries, lack of AED or poor access to the AED in developing countries continue playing an important role in the high prevalence of difficult-to-control adult epilepsy and are even more 45% of the epileptic population continue experience regular seizures then the only choice that we have is to improve treatment approaches to NC hoping that it may contribute to a better control of epilepsy.

Neurocysticercosis is the leading cause of epilepsy in developing countries and it is becoming one of the most common causes of epilepsy in developed countries due to globalization. It is a preventable and potentially eradicable neurological disorder. [Roman 2000]. At the present moment, treatment of NC in patients presenting epilepsy still has some controversial aspects (Goldberg, 1984; Moodley & Moosa, 1989; Kramer, 1990; Rajshekhar, 1991; Carpio et al. 1995). Apart from dosages of anti-parasitic drugs and its duration; whether or not to use albendazole or praziquantel and how to use it, as part of the treatment for NC, is not certain. Based on findings from other researchers and our

results, we will establish a clear-cut guideline for the best management of this problem in this chapter.

Tenia solium is transmitted among humans and between humans and pigs. Taeniosis is acquired only by humans after eating raw or undercooked pork meat contaminated with cysticerci, the larval form of parasite. When ingested, the cysticerci migrate to the intestine of humans where they establish and become adults. These adult worms shed eggs in human feces that can infect other humans and pigs by direct contact or by indirect contamination of water or food. In developing countries, pigs are often allowed to roam freely and they can easily eat human feces. Ingested eggs result in larvae migrating to different parts of the pig or the human and forming cysts. A principle site of migration in humans is the CNS. Human NC occurs when the cysts develop in the brain or spinal cord. Seizures are the most common clinical presentation of NC, affecting from 66% to 90% of cases (Carpio & Hauser, 2002; Wallin & Kurtzke; 2004). In addition to acute seizures and epilepsy, NC can manifest with severe headaches, obstructive hydrocephalus, chronic meningitis, symptoms intracranial hypertension, and dementia (Prabhakar & Singh, 2002). Based on the stage of the intracerebral parasite on CT/MRI, then NC can be classified as "active": when scolex of parasite is visible within a cyst on imagenology, colloidal stage: when the cyst is filled with turbid fluid and there is an intense inflammatory response in the surrounding parenchyma also in imagenology, and calcified or "inactive": when parasite remnants form a mineralized granuloma (Bhigjee & Rosemberg, 2006).

The manner in which NC presents clinically and the severity of the symptoms (from asymptomatic to severe) are thought to depend both on the location of the cysts in the brain (e.g., intraventricular, parenchymal, subarachnoid), their developmental stage and the types and degree of immune response stimulated by the cysts (Garcia & Del Brutto, 2000, 2005; Chavarria *et al.*, 2005; Uddin *et al.*, 2005; Bhigjee & Rosemberg, 2006). The initial vesicular stage is usually not associated with an inflammatory response as you can see in Figure 1, which typically occurs later when the cyst degenerates (colloidal stage) by natural causes or due to antiparasitic effect. Astrocytes would play an important role in initiating the immune response to a degenerating cysterici by secreting chemokine in response to TNF- α from monocytes stimulated by larval antigen (Uddin *et al.*, 2005). Over-expression of the immune response stimulated by degenerating cysterici, which is characterized primarily by a Th1-type cytokine profile, can result in chronic inflammation and granuloma formation of the type seen in NC patients with calcified lesions (Uddin *et al.*, 2005). More severe symptoms were shown to be associated with an increased number of inflammatory cells in the CNS of patients with NC (Chavarria *et al.*, 2005). Acute seizures can be seen associated with vesicular or colloidal cysts whereas epilepsy is often found in association with calcified cysts (Bhigjee & Rosemberg, 2006). The incubation period of cysticercosis is extremely variable (Prabhakar & Singh, 2002), and the proportion of infected cases who develop NC is unknown (Bern *et al.*, 1999; Carpio & Hauser, 2002).

The duration of NC-associated symptoms and the proportion of cases with full recovery from symptoms with or without treatment remain ill-defined (Bern *et al.*, 1999; Prabhakar & Singh, 2002). The prevalence of epilepsy in Sub-Saharan Africa has been estimated to be two to three times higher than that found in industrialized countries, a difference that may be attributed, in part, to NC (Preux & Druet-Cabanac, 2005).

Diagnostic criteria for NC have been well-established based on Imagenology. Categories of absolute criteria (patognomonic) are acceptable when the histological demonstration of the parasite from a biopsy of the brain or spinal cord lesion is made, or cystic lesion showing the head of the parasite (scolex) on CT or MRI is seen, or when sub retinal parasites can be visualized by funduscopy examination. In places where a CT scan is not available, plain X

rays of muscular tissues in the limbs showing “cigar shape” calcifications or plain skull X rays with intracranial calcifications (between 1 to 10 mm of diameter) can be useful to support the diagnosis; other options such as Major, Minor or Epidemiological criteria's can be reviewed in the original article (Del Brutto et al., 2001).

1.1 Should be treated neurocysticercosis in epileptic patients?

Neurocysticercosis is a zoonotic infection of central nervous system (CNS) caused by the larval stage (*Cysticercus cellulose*) of the pig tapeworm *Taenia Solium* and it is the most common helminth to produce CNS infection in human beings. Some authors consider anti-parasitic treatment as a cause epilepsy and recommend do not use it. Researches supporting the theory of “non-antiparasitic drugs” basically defend four hypotheses: First, the sudden destruction of parasites may trigger an inflammatory reaction that precipitates seizures and transient neurologic effects, mostly headache and vomiting. Second, in a considerable number of patients, neurocysticercosis is clinically silent, producing only occasional seizures that are easy to manage with anticonvulsive therapy; thus, exposing these patients to the risk of adverse reactions to cysticidal therapy may be unnecessary. Third, in some cases, the cysticerci will be adequately eliminated either by the host's immune response or by spontaneous regression. Finally, the physical elimination of a parasite, objectively confirmed by neuroimaging studies, does not in itself mean that the patient's neurologic dysfunction will improve. (Sotelo, 2004).

Serum levels of phenytoin and carbamazepine may also be lowered as the result of simultaneous praziquantel administration (Bettencourt et al., 1992). It is also true that *T solium* may remain asymptomatic from months to years until a diagnosis is made incidentally when neuroimaging study is performed. Symptoms and signs are related both to the parasite which can show a different biological pattern from one place to another and to the inflammatory-immunological response of the host (Foyaca-Sibat & Ibañez-Valdés, 2002, 2008). The introduction of praziquantel (PZQ) by Robles, (1979) and albendazole (ABZ) by Escobedo, (1987) as specific antiparasitic agents was enthusiastically adopted by most of our medical community; it's represented the beginning of a revolutionary process to eradicate NC. Nevertheless, some authors reported cases series where they noted that some types of parenchymal NCC can resolve on imaging studies without being treated with antiparasitic drugs soon after the initial descriptions of successful use of praziquantel and albendazole in neurocysticercosis were done (Miller, 1983; Mitchell, 1988)

We studied 3 762 epileptic patients from rural areas with well documented NC during the past 14 years and our experience clearly indicates that anti-parasitic medication can be prescribed in most of epileptic patients.

1.1.1 From our previous studies

From June 1999 to July 2001, one hundred eighty nine patients fulfilling the clinical criteria of uncontrolled epileptic seizures due to NC were identified prospectively for the study among patients referred to neurology clinic at Umtata General Hospital (South Africa) from rural clinics. Most of those patients presented with an associated HIV infection, pulmonary tuberculosis and some of them a history of haematuria probably due to schistosomiasis.

After the CT scan of the brain, eligible patients (n=163) had active and/or chronic forms of NC and uncontrolled tonic-clonic generalized seizures in spite of taking the regular antiepileptic treatment (phenytoin 300 mg orally at night). After neurological evaluation of all participants, nobody had previous history of neurological disorder apart from epilepsy and those with concomitant disorders such: metabolic disorders, cerebrovascular diseases, meningoenchephalitis, and head injuries were excluded. No patients receiving treatment for

any other disease requiring immunomodulatory agents within the past six months were admitted to the study.

Other exclusion criteria included alternative cause for intracranial calcifications or suspicion of tuberculomas, pyogenic brain abscesses, mycotic granulomas, and primary or metastatic brain tumors. Apart from antiepileptic drugs, steroids medications and anti-parasite treatment, other concomitant treatment was prohibited for patient while participating in the study. The study was designed as: a randomized, placebo-controlled double blind clinical trial over a redesigned 1-years period. Patients were assigned to receive 400 mg of phenytoin every night, 40 mg of prednisone orally during five days, and one day treatment with 100 mg/Kg of praziquantel divided in four doses to be given every two hours (group 1) or only 400 mg of phenytoin at night during the same period of time (group 2) according to block-randomization procedure.

1.1.2 Outcomes measures

Response to antiepileptic medication and an associated anti-parasite treatment were assessed with the neurology UGH scale in which 0 is the lowest: no change, I: equivalent to decreased frequency of seizures II: diminished frequency and duration of seizures III: the highest free of seizures Each patient received the same supporting treatment and was encouraged to eat a rich carbohydrate meal and were evaluated throughout the study by the same personnel. Two-side t. Test was used to analyses the primary outcome measure between baseline and the end of the treatment.

1.1.3 Results and comments

Absolute criteria for NC based on neuroimaging studies were present in all selected patients considering the cystic lesion with scolex as pathognomonic.

The efficacy analysis included 71 patients (36 males and 35 females, mean age 38,27, years, range 13 to 59) treated with phenytoin/praziquantel/prednisone (PPP) and 72 (32 women and 40 men, mean age 49,28 years, range 13 to 62) with phenytoin (P) only. A mild improvement in both groups at the beginning was observed but at baseline no difference in UGH scale was found between groups treated with PPP and a group treated with P (PPP 0.06 ± 1.02 versus P 0.02 ± 0.09 , $p=0.56$). One month after the treatment with praziquantel, improvement was seen when comparing UGH scale results between two different groups (mean SE, 0.74 ± 0.14 versus -0.2 ± 0.2 , 0.63 ± 0.25 , mean difference \pm SE; $p=0.005$). In the PPP group 73 % improved in frequency and duration of epileptic attacks. We found that odds ratio of 0.74 in P group, and 0.43 in PPP with 82 % of the confidence interval (See table I)

In 2001 we have not a clear idea about HIV/AIDS and its role in the pathogenesis of epilepsy and that conclusion was not 100% confident. Therefore, years later we designed another study to investigate this factor and our finding will be discussed later in this chapter.

2. Approach to patients presenting epileptic seizures and neurocysticercosis

Some colleagues still have problems with differentiated epileptic seizures from epilepsy. Remember that epilepsy is a chronic brain disorders characterized by epileptic seizures while seizures can be caused or triggered by other causes no related to chronic brain pathology and they are not recurrent in absent of those causes. Hypoglycemia is a good example as a cause of epileptic seizures. Seizures respond well to a single antiepileptic, and the seizure recurrence rate is low in cases with single lesions; those with multiple, persistent or calcified lesions usually have recurrent seizures. (Singhi, 2011)

After the seizure of whatever cause finish, patients are probably groggy, tired, experiencing local or generalized headache, muscle pains, and cognitive dysfunction.

General guidelines for immediate care of patients presenting tonic-clonic generalized seizures (TCGS) due to NC does not differ from general guidelines to approach patients with TCGS seizures due to other cause. Below, please find 15 valuable recommendations for the general population to support epileptic patients:

1. Stay calm and protect the person experiencing the seizure
2. Make sure he/she is breathing normally and keep the person's airway open
3. Remove dangerous objects that the person might hit during the seizure
4. Check his/her awareness by asking questions
5. Turn the person onto his/her side. Do not hold down
6. Inform to the patient, family, relatives or friends about what happened
7. Loosen tight neckwear to ease breathing.
8. Do not shake the person or shout and cushion the person's head
9. Please describe to the doctor the ictal event.
10. Do not insert any object in the person's mouth.
11. Stay with the person until the seizure ends and he or she is completely alert.
12. Offer to call a taxi, a friend, or a relative to help the person get home safely
13. Do not restrain a person during a seizure unless there is a danger
14. Allow them to do what they want to do
15. Talk to patient in a soft voice to reassure them

In patients presenting seizures lasting more than 20 minutes or recurrent fits without regaining their normal level of conscious in between, a diagnosis of status epilepticus should be considered. Below, please find a list of 11 medications that can be used to control seizures from most of etiologies.

1. Lorazepam (Ativan): 0.1 mg/kg at 2 mg/min
2. Diazepam (Valium), 10-20mg at 2-5 mg/min (Alt)
3. Clonazepam (Klonopin) 0.5-1.0 mg three times a day up to 0.025 mg/kg; 1 mg/5 min (Alt)
4. Phenytoin (Dilantin): 15-20 mg/kg not exceeding 50 mg/min in adults. Slow infusion rate if hypotension occurs
5. Valproic acid (Epilim; Episenta): 20-25 mg/kg over 5-10 min followed by 2 mg/kg/h
6. Phosphenytoin : 15-20 mg/kg of phenytoin equivalents at 100-150 mg/min
7. Phenobarbital : 10-20 mg/kg at 100 mg/min (Re)
8. Midazolam : Loading dosage 0.15-0.2 mg/kg. Maintenance dosage: 0.1-0.4 mg/kg/h (Alt)
9. Thiopental : 100-250mg bolus over 20 seconds then further 50mg boluses every 2-3 min until seizure control, followed by infusion to maintain burst suppression, usually at 3-5 mg/kg/h (Re)
10. Propofol : LD: 2 mg/kg, MD: 6-12 mg/kg/h (Alt)
11. Pentobarbital (LD: 12 mg/kg, MD: 5 mg/kg/h (Re)
12. LD: loading dose; MD: maintenance dose; Alt: alternative; Re: Refractory

Note how long the seizure lasts and symptoms that occurred so you can get a diagnosis. If you see someone having a non-convulsive seizure, remember that the person's behavior is not intentional. The person may wander aimlessly or unusual gestures. In some epileptic patients you should consider some alarming signals for saving lives. Below find another 15 recommendations.

2.1 When do I be alarmed?

1.	When there are signs of cardiac or respiratory disturbances
2.	When the person does not begin breathing again
3.	When a patient does not return to consciousness after the seizure stops.
4.	When another seizure starts before the person regains consciousness.
5.	When the person is pregnant, or ethanol abused, or has diabetes mellitus.
6.	When the seizure happened in water or other dangerous situation
7.	When the seizure lasts more than five minutes (Most seizures last less than three minutes)
8.	When a patient has hypoglycaemia and electrolytes imbalance
9.	When the person has two or more seizures in a row.
10.	When the person has injuries from the seizure.
11.	When seizures are accompanied by progressive worsening headache
12.	When there is associate nausea, vomiting and diplopia
13.	When there is prolonged post ictal manifestations
14.	When seizures are characterized by laryngeal constrictions, dysphagia and perioral paresthesia.
15.	When a patient presents comorbid mental health disorders

This is a first seizure or you think it might be. If in doubt, check to see if the person has a medical identification card or jewelry stating that they have epilepsy or a seizure disorder. Timing the seizure using a watch is helpful because a brief seizure may seem longer than it is, so by the time an emergency medication is ready to be administered; chances are the seizure is over.

2.2 Epilepsy diagnosis and treatment

Epilepsy is a chronic brain disorder characterized by recurrent seizures with or without associate abnormal behavioral and other neuropsychiatric manifestations.

About 80% of these cases can be easily treated with medication or surgery, while the remaining patients currently intractable. In some cases, usually involving children and adolescents, symptoms may simply end.

Before diagnosing epilepsy, a thorough review of medical records of past seizures is consulted and blood tests are run to ensure that epilepsy is indeed the reason the seizures are occurring.

Epilepsy is diagnosed by clinical assessment and its can be supported by:

- Brain imaging
- Electroencephalogram.

Brain imaging is the most useful tool for clinically assessing epilepsy. When combined with symptom observation epilepsy experts are able to confidently diagnosis the type of epilepsy

and make a recommendation about how to treat the condition. The imaging techniques used to assess brain function vary but include CT (computed tomography) scans, fMRI (functional magnetic resonance imaging), or the non-visual EEG which yields graphs of electrical activity.

3. Approach to patients with epilepsy and neurocysticercosis

As mentioned in the introduction, the first line of defense against epilepsy is a pharmaceutical option as prescribed by their doctor. This is the least imposing on the patient and more often than not proves effective. Treatment approaches to epilepsy secondary to NC is almost the same used in epilepsy due to other conditions. Below, are listed all medications more and less commonly used. We included a brand and a generic name because the generic usually is cheaper, sometimes by quite a lot.

3.1 Pharmacological treatment

Treatment of epilepsy secondary to NC differs from treatment of other causes only for the management of the underlying aetiology therefore we prescribe same anti-epileptic drugs (AED). List of medications used you can see as follow:

Narrow-spectrum AEDs	Broad-spectrum AEDs
phenytoin (Epanutin) ++	valproic acid (Epilim) +
carbamazepine (Tegretol) (Degranol) (Carbatrol) +	lamotrigine (Lamictal) ++
phenobarbital (Luminal) ++	topiramate (Topamax) +++
oxcarbazepine (Trileptal) +++	zonisamide (Zonegran) +++
gabapentin (Neurontin) ++	clonazepam (Klonopin) ++
pregabalin (Lyrica) +++	levetiracetam (Keppra) +++
lacosamide (Vimpat) +++	rufinamide (Banzel) +++
vigabatrin (Sabril) +++	

AED commonly used+ AED used from time to time++ Drugs never used+++ (In our setting)

In our experience carbamazepine (Tegretol,) is a favorite partial seizure medicine. It affects sodium channels, and inhibits rapid firing of brain cells. Long-acting forms such as Carbatrol or Tegretol-XR can be given once a day while valproic acid is the ideal one for every type of motor seizures and seems to be that sodium valproate is safe and effective in HIV-positive patients on concurrent HAART (Yacoob, 2010). In our experience, generic medicine (CBZ for example) usually works well, but it may not generate the same blood levels as do the brand name or an alternative generic medicine and many patients are able to identified different effect and their seizures are not well controlled. We do recommend to epileptic patients to refill their medications form the same manufacturer and to our health professionals to educate their patient about this knowledge's.

When AED has approval for monotherapy or its benefit seems to exceed the risk, it is the best way of treatment. Side effects seen more often are: blurred vision, stomach upset, headaches, fatigue, dizziness, unsteadiness, and cognitive dysfunction. If valproic acid increases replication of the HIV virus or not it is not certain. Therefore, we recommend do not prescribe valproic acid in HIV-positive patients until this problem be completely clarified.

Weight gain tends to occur with	Weight loss tends to occur with
valproic acid (Depakote)	topiramate (Topamax),
gabapentin (Neurontin)	zonisamide (Zonegran)
pregabalin (Lyrica)	felbamate (Felbatol).
carbamazepine (Tegretol, Carbatrol).	

In endemic areas for NC once the drug has kept the patient seizure-free no less than five years then we recommend that the patient cease its use.

3.2 Surgery

The second option for treating epilepsy due to NC is usually surgery to remove giant subarachnoid cysts, to perform ventricular-peritoneal shunts in IV-NC or to remove the part or parts of the brain malfunctioning that are causing the uncontrolled seizures which is a very uncommon situation.

Patients presenting uncontrolled fits and focal neurological signs due to associate stroke secondary to infective vasculitis are unsuitable for surgery.

3.3 Implantation

A third treatment for epilepsy due to NC is device implantation. For patients from rural places with high level of poverty, where local government and health authorities have other health priorities this procedure is practically unreachable. A vagus nerve stimulator is a fairly recent biomedical technology to help control seizures. Once implanted, the device stimulates the vagus nerve which can reduce the frequency of seizures by 30% on average if patients continue taking their antiepileptic medication post-implantation.

Also from our personal experience, most of epileptic patients with NC respond very well to phenytoin, valproic acid or carbamazepine for control of their seizures and that is fully enough. We prefer valproic acid as a drug of choice for focal or generalized motor or myoclonic seizures in HIV-negative patients and carbamazepine for patients presenting focal complex seizures. Most of our general practitioner prescribes phenytoin more than other AED because it is inexpensive and is almost always available.

3.4 Comments

In our study the total scores at baseline in both groups were similar securing adequacy of randomization and the mild improvement observed was in relation with increased dosage of phenytoin. Our report provides documentation that PZQ, prednisone (PRED) and phenytoin (PPP) were effective in patients with NC and recurrent seizures. Using an UGH score as the primary outcome variable, we found a statistically significant difference between PPP and P. Therefore we have hypothesized about the advantages to combine the antiepileptic drug and antiparasitic medication for patients with recurrent seizures and NC mainly in endemic areas for cysticercosis; clinical manifestation of NC is related to the inflammatory-immunological response of the patient when the parasite is degenerating or dying as result of cysticidal therapy influenced by the number of viable cysts, size and stage of the lesions, site of the cyst in the intracranial region, and the amount of re-infections along the time. However many patients remain asymptomatic and the risk of intracranial infection after *T. solium* egg or proglotides ingestion depend on the combination of

immunological status of the patient, the biological characteristic of the parasite, geographical and atmospherically conditions. It also serves to explain clinical differences and different results with the same treatment from one place to another. In places where NC is endemic, other parasitic zoonoses of the brain and retroviral infections co-exist, then regular cycles of praziquantel and/or albendazole and prednisone should be done precede by CT scan/MRI of the brain and fundoscopy. If patients presenting more than cysts, fundoscopy shows intraocular parasite, or patient present signs of meningoencephalitis treatment should be evaluated by a specialized health professional. This cycle should be repeated until that region will be covered by a good primary health care system, adequate level of employment and cash income, safe and clean water, proper toilet facilities, proper refuse disposal, electricity, telecommunication, good health education program, reform of animal husbandry technique, vaccination of pigs against *Taenia Solium* and poverty eradicated. (Foyaca-Sibat & Del Rio, 2007)

The main measure to prevent Taeniosis from measly pork meat could be summarized as follows:

Cook meat until the juices run clear or to an internal temperature of 60° C.
Freeze pork less than 15 cm thick for 20 days at -15oC to kill any worms.
Do not allow hogs to eat uncooked carcasses of other pigs.
Clean meat grinders thoroughly if you prepare your own ground meats.
Make people aware that braai, curing (salting), drying, smoking, or microwaving pork meat does not consistently kill parasites.

Studies about treatment of NC in human beings have shown an increased level of IgG, interleukin-2, and neopterin in the CSF of these patients after being treated with praziquantel. Elevate eotaxin and interleukin-5 in serum and elevated interleukin-5 and interleukin-6 concentration in the CSF has been reported as well (Foyaca & Ibañez, 2003).

In immunodepressed patients by HIV infections or any other similar condition the parasite can produce more damage on the nervous tissue because there can remain viable for a longer period of time compared with non-immunodepressed patient. About 10 years ago he has hypothesized that in those patients there is one particular stage of the parasite called "critical stage" (Foyaca-Sibat et al., 2001) which is between its vesicular stage and colloid stage, where the releasing of taeniaestatin (serine proteinase inhibitor) is increased or is less destroyed, and the prostaglandins and cytokines production from the glial cells are importantly affected therefore a global cortical neuronal dysfunction is present affecting the mitochondrial activity and its ATP production, disturbance of neuronal membrane metabolism leading to recurrent paroxysmal activity but whether or not the parasite is affected by other condition needs further research.

In pigs affected by NC there is no evidence of seizure disorder probable because their neuronal membrane works differently and their mitochondrial system and supporting cell play a different role or simply because sodium and potassium pump works differently, we do not know. Therefore, deeper investigations on porcine cysticercosis probably help to know more about the human brain and the pathophysiology of epilepsy secondary to NC.

In patients with insular epilepsy (laryngeal constriction, dysphagia, and peribuccal paresthesiae) and viable cysts on the insular lobe anti-parasitic medication can cause local insult dysfunction leading to neurogenic heart and sudden unexpected death of epilepsy.

Therefore it should give with extreme caution. (Foyaca-Sibat & Ibañez-Valdés, 2006). In epileptic patients due to disseminate cysticercosis with cardiac involvement, cysticidal drugs should be used with caution because the risk of associate cardiac dysfunction; presence of subcutaneous cysticercosis may help suspecting that condition. (See figure 1)

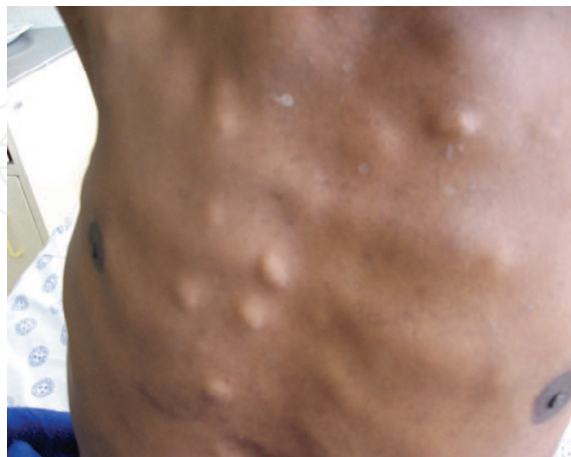

Fig. 1. Shows disseminate subcutaneous cysticercosis

4. Conclusion

Although treatment of NC continues to be debated, in epileptic patients should be treated with cysticidal medicines which are inexpensive and no complications have been reported (Foyaca, Ibañez & Mashiyi 2004). Below, you can see our recommendations:

ABZ: 800mg daily (up to 30mg/kg) plus 40mg of prednisone daily for no less than a week for IV-NC and SA-NC. With extreme caution if cysts at least 50 mm in diameter and hydrocephalus is present (*)	PZQ: 100mg/kg plus 40 mg of prednisone during two weeks or more for intraperanchymal-NC and failure to ABZ (**)	PRED: 60-100 mg (***) daily for insular-NC, ocular-NC, disseminate-NC with cardiac involvement, more than 50 cysts (****) SA-NC, and meningoencephalitis follow by ABZ/PZQ after improvement.	In refractory NC, ABZ and PZQ should be combined and can be used for a longer period of time until Imagenology does not show active cysts
---	---	---	---

(*) Intensive medical treatment can be effective in patients with neurocysticercosis characterized by giant cysts. Neurosurgery may be required only when there is an imminent risk of death (Proaño, 2001; Göngora-Rivera, 2006).

(**) A combination therapy for albendazole and praziquantel was statistically comparable to sole therapy with albendazole in eradicating lesions and preventing seizures. (Kaur et al., 2009)

(***) Using corticosteroids at higher dosages bring the inconvenience that destruction of the parasite is delayed probable because most of necessary immunocomponents to participate are affected.

(****) The combination of albendazole and surgical maneuvers to reduce intracranial pressure is a safe and effective method for treating severe NC (more than 100 cysticerci) proceed by higher doses of PRED; CT scans of the brain can be useful for its differential diagnosis. (See figure 2). The fatal prognosis is reported when more than 1 000 viable cysts are present (Yuan et al., 2004).

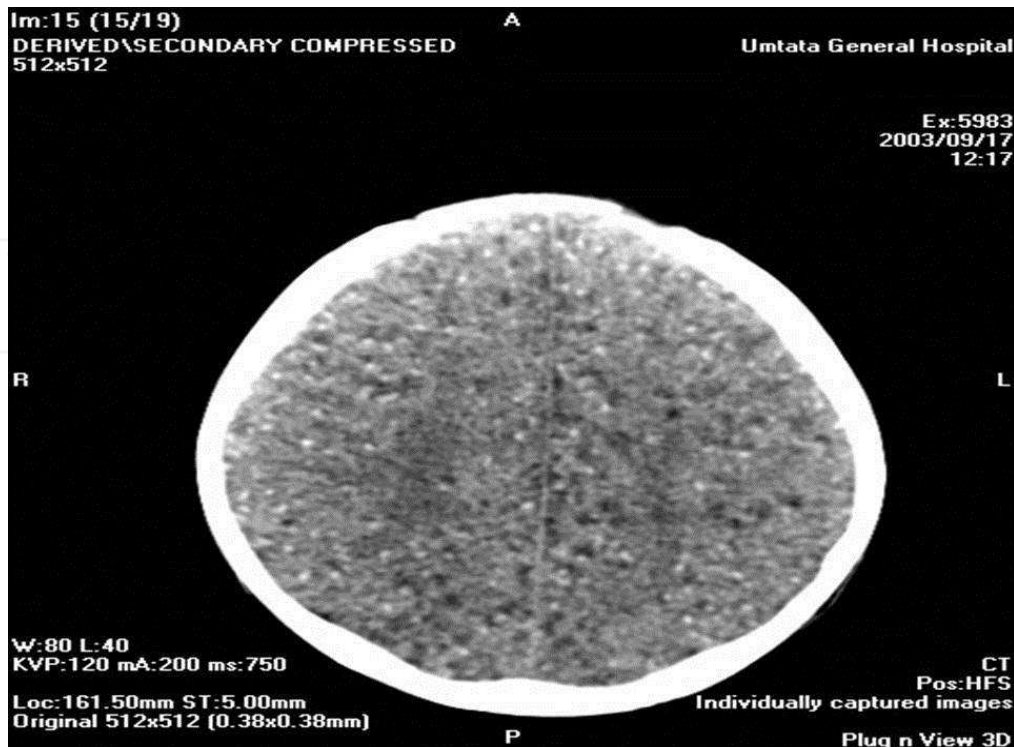

Fig. 2. CT scans of the brain show severe NC.

Both drugs (PZQ/ABZ) have similar equivalent efficacy and greatly improve the therapeutics of cysticercosis. (Sotelo, 1988)

If patients from endemic areas, whom have not well control of epileptic fits but not active cyst are seen on Imagenology, despite calcified-NCC with peripheral edema could explain the presence of seizure disorder, we personally recommend:

One day treatment with praziquantel at doses of 100mg/kg/day divided in four dosages at 2/3 hours interval plus 40 mg of prednisone for three days every three to six months, for epileptic patients living in the endemic areas if there is not contraindication but funduscopy looking for ocular cysticercosis should be performed before treatment.

5. Treatment of refractory epilepsy secondary to neurocysticercosis

Refractory epilepsy is uncommon in patients with intraparenchymal NC and when these patients do not respond to the first line anti-epileptic drugs other causes should be investigated. (Ibañez-Valdés & Foyaca-Sibat, 2006). Looking into other causes of refractory epilepsy we studied the first 100 consecutive patients attending to Epilepsy and NC clinic at Nelson Mandela Academic Hospital in South Africa presenting more than eight epileptic seizures per month were confirmed by neuroimaging techniques (CT and/or MRI), EEG and ELISA for the detection of antibody to cysticerci of *Taenia solium*. Selecting criteria and criteria for exclusion were established as follows:

5.1 Subject inclusion criteria

Step 1.	Patients suffering from focal seizures (FS) or tonic-clonic generalized seizures (TCGS) according to the ILAE classification of epileptic seizures, whether or not secondarily generalized.
Step 2.	Diagnosed with epilepsy for no less than one year prior to be selected for this study
Step 3.	Epilepsy documented clinically and by paroxysmal activity on EEG.
Step 4.	Multiple 2-10 mm intracranial calcifications with or without peripheral edema on imagenology
Step 5.	Patient under regular treatment and good compliance for at least two months before the selection
Step 6.	Presenting at least eight FS with or without generalization or six TCGS per month
Step 7.	Patients between 13 to 75 years old, weighed more than 50 kg
Step 8.	Signed and dated written informed consent.

5.2 Subject exclusion criteria

Pregnant patients or who are lactating.
Subjects whose seizures cannot reliably be counted on a regular basis due to their fast and repetitive occurrence, severe or moderate mental retardation and illiterate peoples unable to report seizures.
History of stroke, cerebral schistosomiasis, current intracranial mass, progressive cerebral disease or any other progressive neurodegenerative disease.
History of poor compliance, pseudo seizures, neuropsychiatric problems.
Normal CT scans of the brain.

5.3 Results and comments

Eleven patients with NC, uncontrolled epilepsy and intracranial structural lesions were identified. Three had arachnoids cysts. Schizencephaly was confirmed in two, six patients presented SA-NC (Figure 3) and in four radiological signs of neuro-AIDS were documented (Figure 4). NC and associated neuron-AIDS was the commonest cause of uncontrolled epilepsy in this series (Table I). Arachnoids cysts often are an incidental finding on imaging and, usually, patients are asymptomatic even if the cyst is quite large. The most commonly associated clinical features are headache, calvarial bulging, and seizures, with focal neurological signs occurring less frequently.

The so-called racemose variety occurs in the ventricles or basal cisterns and is characterized by abnormal growth of cystic membranes with degeneration of the parasite's head (scolex) (Bickerstaff, 1952; Rabiela, 1989). Diagnosis is based on imagenology (See figure 3). These cases follow a progressive course, and even after ventricular shunting, the membranes or inflammatory cells and proteins frequently block the shunt.

Controversy surrounds the treatment of arachnoids cysts. Some clinicians advocate treating only patients with symptomatic cysts while others believe that even in asymptomatic patients, cysts should be decompressed to avoid future complications. The most effective surgical treatment appears to be excision of the outer cyst membrane and cystoperitoneal shunting.

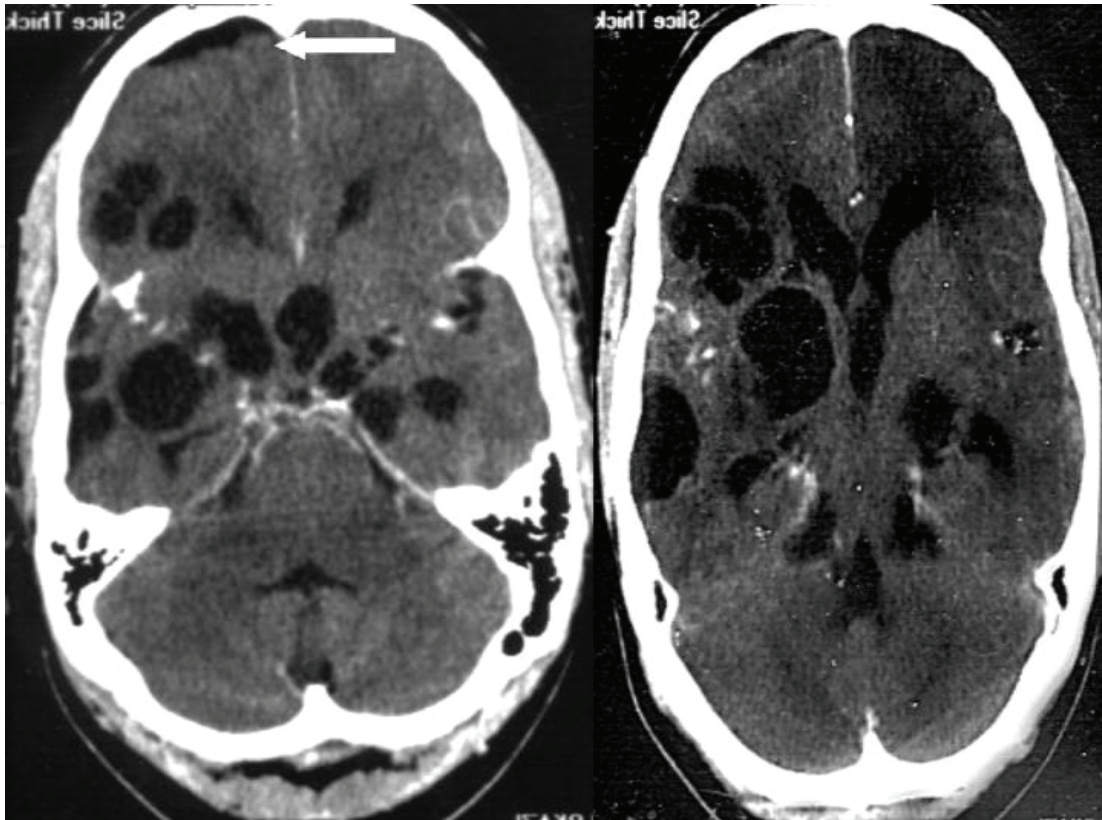


Fig. 3. CT scans of the brain show SA-NC (Racemose's presentation)

Since the cyst membrane is thin and the fluid is isodense with the cerebrospinal fluid, uninfamed extraparenchymal cysticerci are usually not visible on CT and may only reveal subtle, indirect findings on MRI. Between 60% and 85% of parenchyma brain cysticerci are killed after standard courses of treatment, with most trials showing a higher parasitocidal effect of albendazole. (García, 2002). Cysts of the middle cranial fossa (50%) may compress the tip of the temporal lobe, displacing it in the occipital direction. This has been described as temporal lobe agenesis, although there is doubt as to the existence of a true temporal lobe agenesis. Pathologists believe that a malformation of the brain causing selective agenesis of the temporal does not exist. However, middle cranial fossa cysts are linked to ipsilateral chronic subdural hematomas. Rarely, they may communicate with the subdural space, forming a slight extension over the hemispheric surface. At the present moment, information about refractory epilepsy and SA-NC in HIV/AIDS patients is not available in the medical literature.

5.4 Conclusions

In absent of ischemic stroke or other intracranial infection:	SA-NC in HIV/AIDS patients should be considered as an important cause of refractory epilepsy.
---	--

6. Treatment failure and its consequences

Albendazole has better penetration into cerebrospinal fluid; its concentration is not affected when given with steroids (Jung, 1990; Kim, 1999) and it is cheaper than praziquantel.

In our experience most of epileptic patients with active NC respond very well to first course of PZQ (two weeks) or ABZ (one week) if they have less than 10 cystic lesions (sometimes less than 20) in the parenchyma tissue (Foyaca-Sibat & Ibañez-Valdés, 2002). Single small enhancing computer tomography lesions (SSECTL) of the brain with or without peripheral edema, as a solitary cysticercus granuloma can be a benign form of parenchymal neurocysticercosis (P-NC) and it is considered to be the most common etiology for SSECTL. (See figure 4)

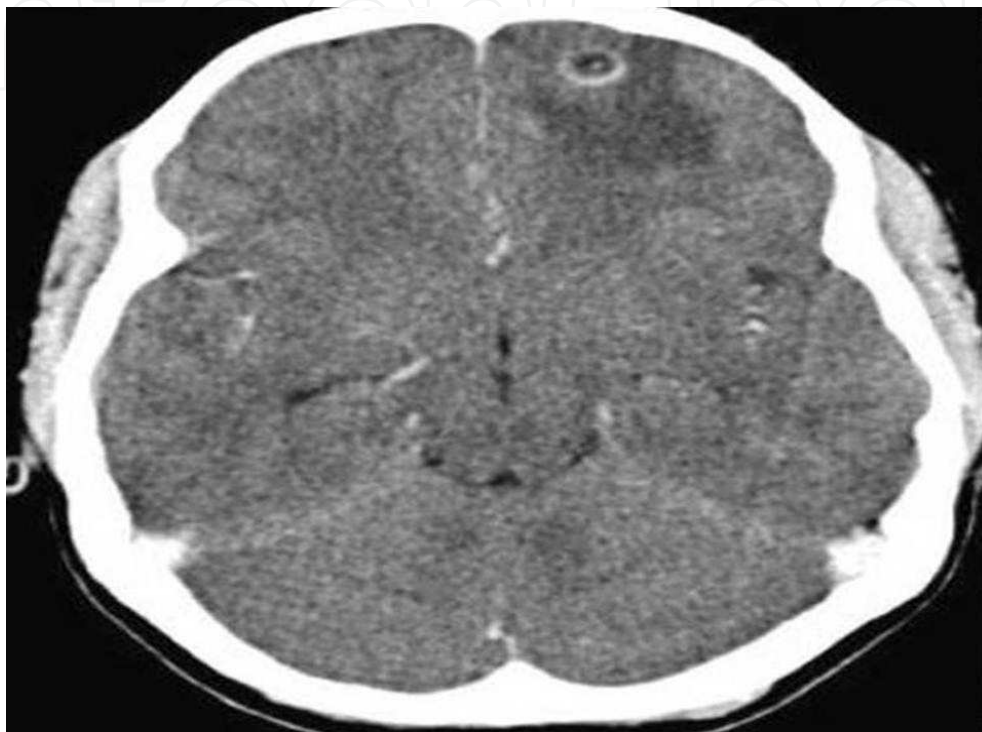

Fig. 4. CT scans of the brain show SSECTL on the left frontal lobe with perilesional oedema

In patients presenting with seizures due to single viable parenchymal neurocysticercosis, albendazole hastens the resolution of SSECTL if treatment is given in the early phase of the illness (Thussu, 2008). For patients with intraventricular NC (IV-NV) the medication of choice is ABZ even in HIV-positive patients (Foyaca-Sibat & Ibañez-Valdés, 2003). However subarachnoid neurocysticercosis (SA-NC) shows a poor response to anti-parasitic medication and some authors reported not adequate response to ABZ, at all (Bandres et al., 1992; White et al., 1992; Del Brutto, 1997; Cardenas et al., 2010). Cysts in the basal cisterns can cause an inflammatory reaction, fibrosis and progressive thickening of the leptomeninges at the base of the brain. In approximately 75% of the cases, there is a progressive obstacle that impedes the normal CSF circulation; resulting in obstructive hydrocephalus therefore we consider ventricular and basal cisternal locations as malignant forms of NC.

The stages of NC before cited, are not seen in the IV-NV or SA-NC (multilocular cyst resembling a bunch of grapes or racemose) at the suprasellar, Sylvian and quadrigeminal cisterns where ABZ or PZQ does not show a good efficacy. Although resistance of cysticerci to ABZ in humans has never been reported, it may occur as it has been observed

in other related parasites (Bannur, 2001). Unfortunately, a well-designed clinical trial for SA-NC has not been published and the cause of the parasite's resistance to treatment, despite the ABZ treatment, remains unknown. We also have hypothesized about the immunological condition of the host, biology of the *T solium*, pharmacological limitation of the anti-parasitic drugs at subarachnoid space, and even environmental factors. These non-responsive cases are not the most often but their severity should encourage controlled studies to evaluate new forms of medical intervention and management. Therefore, new therapeutic approaches should be developed. Perhaps, combining ABZ/PZQ with ivermectine, nitazoxanide or tizoxanide will bring better results but because no evidence has been delivered, to perform a well-designed randomized, double-blind placebo clinical trial is mandatory, before to deliver this recommendation. Seven recommendations should be considered in all cases:

1.	Guidelines for treatment of NC must be individualized in terms of the number and location of viable cysts.
2.	Growth of a parenchymal cysticercus is not a common event and may be life-threatening.
3.	Active cystic lesions deserves active management, either with antiparasitic drugs or by surgical excision and epilepsy must be controlled
4.	In epileptic patients with intracranial hypertension secondary to NC, the priority is to manage the raised intracranial pressure before considering any other form of therapy.
5.	Antiparasitic drug treatment is never the main priority in the setting of elevated intracranial pressure
6.	Antiepileptic drugs are the principal therapy for seizures in NC.
7.	Prophylaxis of recurrent infection based on the adequate primary health care system and good health education is mandatory.

6.1 Current situation

Conspicuously absent in the case reports available in the current medical literature are the following research questions: What is the prevalence of SA-NC in epileptic patients? Is SA-NC a risk factor for ischemic stroke (IS) in epileptic population? Does HIV comorbidity increases the stroke frequency in patients infected with NC? These questions were not answered before, therefore the main aim of this study is to explore this inquiry and propose new hypotheses for future study.

6.2 Material and method

We did a cross-sectional study of patients diagnosed with NC from January 1999 to December 2003 at Umtata General Hospital and from January 2004 to January 2010 at Nelson Mandela Academic Hospital from the rural areas selected for a case control-study under the project: "Epilepsy and Neurocysticercosis" All patients were classified into one of the two respective sample groups according to presence and type of NC, all cases presented focal or generalized recurrent motor seizures and were grouped in A= (SA-NC), B= (P-NC) or C= (chronic headache).

6.2.1 Inclusion criteria

All patients from group A met the following selection criteria:

1.	A positive serology ELISA test for cysticercosis
2.	CT/MRI images of the brain with intravenous contrast or gadolinium enhancement consistent with definitive evidence of cystic lesion (isolate or racemose) in the subarachnoid space without hydrocephalus and suitable to evaluate: <ul style="list-style-type: none"> • Focal arachnoiditis, when there was contrast enhancement in only one cerebral basal cistern. • Bilateral cystic lesions with diffuse arachnoiditis, in which contrast enhancement involved several basal cisterns. • Ischemic infarction, in which the number and location of cerebral lesions were analyzed and classified as superficial, deep no lacunar (>16 mm), and deep lacunar (<15 mm) at the basal ganglia, without an associate cardiac-embolic disease.
3.	Demographic, and associated stroke was analyzed in accordance with the presence of SA-NC.
4.	Recurrent epileptic motor seizures with good compliance

From the large number of patients with NC in our database we selected only a number of patients in group B similar to group A regarding age and gender to assure a better statistical analysis and under an absolute diagnosis of intraperanchymal NC (both active and calcified at the same time) and epilepsy.

All patients received 800 mg of ABZ and 40 mg of PRED per os daily during the ten days as part of the routine treatment for NC and 600 mg of carbamazepine daily.

6.2.2 Exclusion criteria

• Gross modifiable risk factors for stroke.
• Heart problems or signs of infective vasculitis.
• Suspicion of primary or secondary vascular disease
• Cognitive or sensory deterioration
• Lack of check-ups (NC/SA-NC/Stroke) for more than eleven months
• IV-NC and/or associate hydrocephalus
• Terminal illnesses, serious psychological illnesses
• Active addictions to psychoactive substances
• Younger than 13 years old
• Pregnancy
• Lived more than six months outside of our territory.
• HIV/AIDS in stage IV
• No written consent

6.2.3 Ethical aspects

Written informed consent forms were administered in the first contact with the eligible patients following verbal agreement for participation. All patients were provided

information on the study's purpose and procedures in addition to ethical considerations, including and the participant's right to intimacy, anonymity, confidentiality, withdrawal, and information. Due to the large proportion of illiteracy among our population, oral consent observed and confirmed by an impartial witness were necessary in some cases. For patients selected between 1999 and 2002 only oral informed consent was taken.

All investigators completed the CITI training - course on the Protection of Human Research. All are sworn to the Hippocratic Oath and committed to respecting the norms of good clinical practice, as well as the requirements of the Helsinki Declaration.

Methods for patient selection and information processing was approved by clinical governance at Umtata General Hospital, and the research protocol was evaluated and approved by Mthatha Hospital Complex, University of Transkei, and Walter Sisulu University IRB and the respective Ethical Committees (UGH:0001/99, UNITRA:0018/05, and WSU:0068/09).

6.2.4 Data analysis

All statistical analyses were conducted using Statistical Package for the Social Sciences (SPSS) version 16.0 for Windows (SPSS Inc., Chicago, Ill). Analyses were performed using an intention to treat bias. A descriptive analysis and an analysis of baseline comparison between the studies groups were performed for all study variables. To investigate the potential associations between ischemic stroke outcomes and the variability of NC group-type, prevalence odds ratios at 95% confidence intervals were calculated.

6.2.5 Results

Out of a total of 280 eligible patients asked to participate, six patients refused to participate at the baseline evaluation. Two out of the six patients agreed to participate during their follow-up appointment, and their data are included here (n=276).

Group A (n=133), 70 males (52.6%) and 63 females (47.4%). Group B (n=143), 67 males (46.9%) and 76 females (53.1%). In total: 137 males (49.6%) and 139 females (50.4%).

Mean age of group A: 38.63 years (13-82, SD 16.93) and group B: 37.27 years (13-80. SD 15.43). In total, 153 serial CT/MR scans with at least 1 scan (range = 1 to 2) per subject were available in group A and 167 CT/MRI scans in group B, over the 10-years study period.

In total, six patients (3.2%) with good clinical response anti-parasitic treatment developed an ischemic stroke (IS) while 31 (36.0%) patients with poor response developed an IS (OR: 16.11) (6.57-39.47, IC: 95%). See table 1

Response to ABZ		Stroke		Total	
		Yes	No		
Clinical Response	Yes	Count	6	184	190
		% within Clinical Response	3.2%	96.8%	100.0%
	No	Count	31	55	86
		% within Clinical Response	36.0%	64.0%	100.0%
Total		Count	37	239	276
		% within Clinical Response	13.4%	86.6%	100.0%

Table 1. Clinical response

The risk to develop stroke was 2.82 times more in group A compared with group B. This suggests that although co-infection with HIV increases the risk of IS, the location of NC in the brain is a better predictor of IS risk than comorbidity status when there is not a good response to anthelmintic medicine. Taking into consideration the HIV status of patients by groups we found 40% of patients presented ischemic stroke (group A) and the risk to develop an IS among groups A and B is almost three times more.

In group A, 19 (44.2%) patients responded poorly to anti-parasite treatment and developed an ischemic stroke. OR: 15.29, (4.99-46.83 IC 95%) while 12 (27.9%) from group B presented similar situation. OR: 15.63, (3.79-64.42, IC 95%). (See table 2 and 3)

Response to ABZ			Stroke		Total
			Yes	No	
Clinical Response	Yes	Count	4	86	90
		% within Clinical Response	4.4%	95.6%	100.0%
	No	Count	19	24	43
		% within Clinical Response	44.2%	55.8%	100.0%
Total		Count	23	110	133
		% within Clinical Response	17.3%	82.7%	100.0%

Table 2. Group A

Response to ABZ			Stroke		Total
			Yes	No	
Clinical Response	Yes	Count	2	98	100
		% within Clinical Response	2.0%	98.0%	100.0%
	No	Count	12	31	43
		% within Clinical Response	27.9%	72.1%	100.0%
Total		Count	14	129	143
		% within Clinical Response	9.8%	90.2%	100.0%

Table 3. Group B

After comparing all groups with similar age, gender and HIV-positive status the risk to develop an IS increase to more than seven times in patients presenting SA-NC over the control group and almost four times in patients presenting intraperanchymal NCC.

6.2.6 Imagenological changes after cysticidal treatment

Twenty nine (31.9%) patients from both groups did not present imagenological changes after treatment and developed ischemic stroke. OR: 9.85 (4.36-22.28, IC 95%). See table 4.

Only eight (4.3%) patients with SA-NC (Group A) presenting unequivocal imagenological changes after treatment and IS while 29 (31.9%) patients from the same group did not present changes and developed IS. In this group we found: OR= 13.15 (4.32-40.00, IC 95%).

In group B, 10 (22.2%) patients did not present imagenological changes after treatment and developed IS and OR= 6.21 (1.92-20.00, IC 95%).

Response to ABZ		Stroke		Total
		Yes	No	
Imagenology Changes	Yes	Count 8	177	185
		% within Imagenology Changes 4.3%	95.7%	100.0%
No		Count 29	62	91
		% within Imagenology Changes 31.9%	68.1%	100.0%
Total		Count 37	239	276
		% within Imagenology Changes 13.4%	86.6%	100.0%

Table 4. Imagenology changes. Group A

6.2.7 Discussion and conclusion

Commodity of *T solium* and HIV in epileptic patients would be expected to occur more frequently because of the increasing frequency of HIV infection in endemic areas of cysticercosis. However, little is known about the influence of HIV infection on the frequency of epileptic seizures and the clinical course of cysticercosis. Giant cysts and racemose forms of neurocysticercosis seem to be more frequent in HIV-infected patients and may be secondary to an uncontrolled parasitic growth because of an impaired cell-mediated immune response. At present we believe that toxins released by the cysticercus cause inflammatory changes on the perforating arteries (toxic vasculitis) at the subarachnoid space rather than as a direct effect on the parasite (mechanical compression). In our study, only one patient died from Group A and that low mortality rate may be related to the exclusion of patients with subarachnoid cysticercosis growing to giant size causing mass effect and obstructive hydrocephalus with mechanical compression. The disease course in SA-NC has been often long in duration and cysticerci continue to grow and proliferate through tissue and epilepsy control was diminished in HIV patient with an associated SA-NC and cerebrovascular complication as we expected. Strengths of this study include the large sample size, geographically distinct locations of the participating clinics, and potential feasibility of its replication. Weaknesses of this study include the omission of a number of variables that may have contributed to the analysis, especially CD-4 level and MR images.

Epileptic patients with an associated SA-NC and HIV infection have a higher risk to develop ischemic stroke if antiparasitic treatment is not effective enough.

7. Way forward

At the present moment, we are investigating the effect modification of HIV-associated CNS diseases by parasitic zoonoses in the Eastern Cape Province; South Africa (Carabin & Foyaca-Sibat, 2011) and a clinical trial on cerebral toxocariasis and NC will be performed.

8. Acknowledgment and source of funding

We like to thanks to all veterinarian researches working on this field.

We also want to thank to all radiologists and radiographers from Nelson Mandela Academic Hospital and Inkhosi Albert Luthuli Central Hospital in South Africa for their contribution to this study.

Special thanks are due to the Cuban Ministry of Health and Institute of Tropical Medicine "Pedro Kouri", and authorities of Nelson Mandela Academic Hospital, School of Medicine, Faculty of Health Sciences and Directorate: Research Development from Walter Sisulu University for their kind support. Finally, we wish to declare publicly our eternal and deepest gratitude to Lorna María Foyaca García, Fátima Susana Foyaca Ibañez and Thabo Humberto Foyaca Ibañez for their delight support.

Hereby, we acknowledge financial support from the Directorate of Research Development, Walter Sisulu University in South Africa, University of Oklahoma, and South African Medical Research Council. The founder had no role in study design, data collection and analysis, decision to publish, or preparation of the manuscript.

9. References

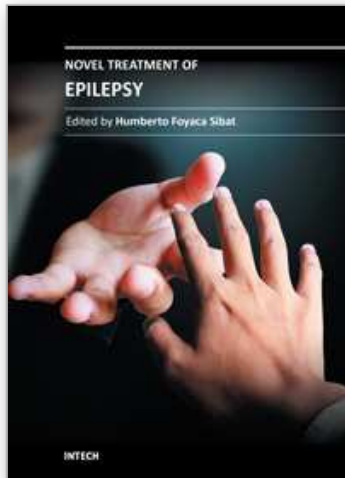
- Arpino C, Castelli Gattinara G, Piergili D, et al. (1990) *Toxocara* infection and epilepsy in children: a case-control study. *Epilepsia* 31:33-36.
- Bandres JC, White AC Jr, Samo T, Murphy EC, Harris RL. (1992) Extraparenchymal neurocysticercosis: report of five cases and review of management. *Clin Infect Dis.* 15:799-811.
- Bannur U, Rajshekhar V. (2001) Cisternal cysticercosis: a diagnostic problem, short report. *Neurol India.* 49(2):206-20
- Bittencourt, P. R. M., C. M. Gracia, R. Martins, A. G. Fernandes, H. W. Diekmann, and W. Jung. (1992) Phenytoin and carbamazepine decrease oral bioavailability of praziquantel. *Neurology* 42:492-495
- Bickerstaff C, Hughes B, Smith W. (1952) The racemose form of cerebral cysticercosis. *Brain* 75:1-18.
- Bern C, Garcia HH, Evans C, Gonzalez AE, Verastegui M, Tsang VC, Gilman RH. (1999) Magnitude of the disease burden from neurocysticercosis in a developing country. *Clin Infect Dis.* 29:1203-1209.
- Bhigjee AI and Rosemberg S. (2006) Optimizing therapy of seizures in patients with HIV and cysticercosis. *Neurol* 67(Suppl 4):S19-S22.
- Carabin H, Krecek RC, Cowan LD, Michael L, Foyaca-Sibat H, Nash T, Willingham AL(2006) Estimation of the monetary burden of *Taenia solium* cysticercosis in the Eastern Cape, South Africa". *Trop. Med. Int. Health.*(ISSN: 1360-2276).11: 906-916.
- Cárdenas C, Carrillo-Mezo R, Jung H, Sciutto E, Soto Hernandez JL, Fleury A. (2010) Subarachnoidal Neurocysticercosis non-responsive to cysticidal drugs: a case series. *BMC Neurol.* 10: 16.
- Carpio, A., F. Santillan, P. Leon, C. Flores, and W. A. Hauser. (1995). Is the course of neurocysticercosis modified by treatment with antihelminthic agents? *Arch. Intern. MED* 155:1982-1988
- Carpio A and Hauser WA. (2002) Neurocysticercosis and epilepsy. *In: Singh G and Prabhakar S. Taenia solium* cysticercosis. From basic to clinical science. New York: CAB International. 211-20pp
- Chavarria A, Fleury A, Garcia E, Marquez C, Frogoso G, Sciutto E. (1997) Relationship between the clinical heterogeneity of neurocysticercosis and the immune-inflammatory profiles. Analysis of 17 patients. *J Neurol Neurosurg Psychiatry.* 62:659-661
- Del Brutto OH. (1998) Albendazole therapy for subarachnoid cysticerci: clinical and neuroimaging.

- Del Brutto OH, Rajshekhar V, White AC, Tsang VCW, et al (2001) Proposed diagnosis criteria for neurocysticercosis. *Neurology* 57:177-181
- Escobedo F, Penagos P, Rodriguez J, and J. Sotelo. (1987) Albendazole therapy for neurocysticercosis. *Arch. Intern. Med.* 147:738-741.
- Evans CWE, Garcia HH, Hartnell A, et al. Elevated concentrations of eotaxin and interleukin-5 in human neurocysticercosis. *Infect Immun* 1998;66:4522-4525.
- Foyaca-Sibat H, Ibañez-Valdés LdeF, Fernandez-Mena C. "Neurocysticercosis in Critical Stage". Third International Congress of Critical Care Medicine on Internet. IBSN 0007-A5342-XL2001 Available online from:
<http://www.uninet.edu/cimc2001/comunicaciones/foyaca.html>
- Foyaca-Sibat H, "Tapeworm and the brain" *Journal of Sciences of Africa* 2002;1:5-12
<http://www.scienceofafrica.co.za/2002/june.worn.htm>
- Foyaca-Sibat H, Ibañez-Valdés LdeF. Clinical trial of praziquantel and prednisone in rural patients with neurocysticercosis presenting recurrent epileptic attacks" *The Internet Journal of Neurology* 2002; 2:41-50. Full article available at the URL:
http://www.ispub.com/journal/the_internet_journal_of_neurology/volume_1_number_2_39/article/clinical_trial_of_praziquantel_and_prednisone_in_rural_patients_with_neurocysticercosis_presenting_with_recurrent_epileptic_attacks.html
(Last review Jan 13, 2011)
- Foyaca Sibat H, Ibañez-Valdés L de F, Vascular dementia type Binswanger's disease in patients with active neurocysticercosis. *Electron Biomed / Electron J Biomed* 2003;1(1):32-42. Full article available at the URL:
<http://biomed.uninet.edu/2003/n1/foyaca.html>
- Foyaca-Sibat H, Ibañez-Valdés LdeF "Intraventricular neurocysticercosis in HIV patients" *The Internet Journal of Neurology* 2003;2 (1): 23-31 Full article available at the URL:
http://www.ispub.com/journal/the_internet_journal_of_neurology/volume_2_number_1_37/article/intraventricular_neurocysticercosis_in_hiv_positive_patients.html. (Last review on January 25, 2011)
- Foyaca-Sibat H, Ibañez-Valdés LdeF."Pseudoseizures and Epilepsy in neurocysticercosis" *Electron J Biomed* 2003;2(2):20-29. Full article available at the URL:
<http://www.uninet.edu/reb/2003/n2/2foyaca.html>
- Foyaca-Sibat H, Ibañez-Valdés LdeF "Neurocysticercosis in HIV-positive patients" *The Internet Journal of Infectious Diseases.* 2003;2(2):15-23. Full article available at the URL:
<http://www.ispub.com/ostia/index.php?xmlFilePath=journals/ijn/current.xml>
- Foyaca-Sibat H, Ibañez-Valdés LdeF, Mashiyi MK. Disseminate cysticercosis. One-day treatment in a case. *Rev Electron Biomed / Electron J Biomed* 2004;3:39-43. Full text available at URL:
<http://biomed.uninet.edu/2004/n3/foyaca-n.html>
- Foyaca-Sibat H, Ibañez-Valdés LdeF. "Pseudoseizures and Epilepsy in neurocysticercosis: some advices to Family Doctors" *The Internet Journal of Neurology.* 2004;2(2):4-17. Full article available at the URL:
http://www.ispub.com/journal/the_internet_journal_of_neurology/volume_2_number_2_h34/article/pseudoseizures_and_epilepsy_in_neurocysticercosis_some_advice_for_family_doctors.html
- Foyaca-Sibat H, Ibañez-Valdés LdeF" Clinical trial of praziquantel and prednisone in rural patients with neurocysticercosis presenting recurrent epileptic attacks" *The Internet Journal of Neurology* 2002;2:41-50 Full article is available at the URL:
http://www.ispub.com/journal/the_internet_journal_of_neurology/volume

- [_1_number_2_39/article/clinical_trial_of_praziquantel_and_prednisone_in_rural_patients_with_neurocysticercosis_presenting_with_recurrent_epileptic_attacks.html](#) [last review done on February 3, 2011]
- Ibañez-Valdés LdeF, Foyaca-Sibat H. Refractory epilepsy in neurocysticercosis. *The Internet Journal of Neurology* 2006;5(2):34-41. Full article available at the URL: http://www.ispub.com/journal/the_internet_journal_of_neurology/volume_5_number_2_19/article/refractory_epilepsy_in_neurocysticercosis.html
- Foyaca-Sibat H, Ibañez-Valdés LdeF : Occipital Lobe Syndrome Due To Giant Intraparenchymal Neurocysticercosis . *The Internet Journal of Neurology*. 2006; volume 5 number 2. Full text is available at the URL: http://www.ispub.com/journal/the_internet_journal_of_neurology/volume_5_number_2_19/article/occipital_lobe_syndrome_due_to_giant_intraparenchymal_neurocysticercosis.html
- Foyaca-Sibat H, Ibañez-Valdés LdeF. Insular Neurocysticercosis: Our Finding and Review of the Medical Literature. *The Internet Journal of Neurology* 2006 volumen 5 number 2. Full article available at the URL: http://www.ispub.com/journal/the_internet_journal_of_neurology/volume_5_number_2_19/article/insular_neurocysticercosis_our_findings_and_review_of_the_medical_literature.html
- Foyaca-Sibat H, RIA Del Rio: "Epilepsy, Neurocysticercosis and, Poverty at Mphumaze and Marhambeni Locations, in South Africa". *The Internet Journal of Neurology* (ISSN: 1531-295X). 2007;7(1):8-14. Full article available at the URL: http://www.ispub.com/journal/the_internet_journal_of_neurology/volume_7_number_1_7/article/epilepsy_neurocysticercosis_and_poverty_at_mphumaze_and_marhambeni_locations_in_south_africa.html
- Foyaca-Sibat H, Del Rio- Romero AI: "Prevalence of Epilepsy in an endemic area for neurocysticercosis in South Africa". *The Internet Journal of Neurology*. (ISSN: 1531-295X). 2008;9(1):8-18. Full article available at the URL: http://www.ispub.com/journal/the_internet_journal_of_neurology/volume_9_number_1_6/article/prevalence_of_epilepsy_in_an_endemic_area_for_neurocysticercosis_in_south_africa.html
- Foyaca-Sibat H Cowan LD, Carabin H, Serrano-Ocaña G, Krecek RC, Willingham A. "Accuracy of serological exam for the diagnosis of neurocysticercosis in outpatients with epilepsy, Eastern Cape Province, South Africa" *PLOS Neglected Trop.Dis.* Dec.2009; 3 (3): 1-7
- Foyaca-Sibat H, Ibañez-Valdés LdeF. "Pseudoseizures and Epilepsy in neurocysticercosis" *Electron J Biomed* 2003;2(2):20-29. Full article available at the URL: <http://www.uninet.edu/reb/2003/n2/2foyaca.html>
- Foyaca-Sibat H, Ibañez-Valdés LdeF "Neurocysticercosis in HIV-positive patients" *The Internet Journal of Infectious Diseases* 2003;2(2):15-23. Full article available at the URL: <http://www.ispub.com/ostia/index.php?xmlFilePath=journals/ijn/current.xml>
- Foyaca-Sibat H, Ibañez-Valdés LdeF. "Pseudoseizures and Epilepsy in neurocysticercosis: some advices to Family Doctors" *The Internet Journal of Neurology* 2004;2(2):4-17. Full article available at the URL: <http://www.ispub.com/ostia.index.xmlFilePath=journals/ijn/current.xml>
- Garcia HH and Del Brutto OH. *Taenia solium* cysticercosis. *Infect Dis Clin North Amer* 2000; 14:97-119.

- García HH, Evans C, Nash T, Takayanagui O, Clinton White A et al. Current Consensus Guidelines for Treatment of Neurocysticercosis *Clinical Microbiology Reviews* 2002; 15(4):747-756
- Garcia HH and Del Brutto OH. Neurocysticercosis: updated concepts about an old disease. *Lancet Neurol* 2005;4:653-661.
- Goldberg, M. A. 1984. Praziquantel for cysticercosis of the brain parenchyma. *N. Engl. J. Med.* 311:732-734
- Göngora-Rivera F, Soto-Hernández JL, González Esquivel D, Cook HJ, Márquez-Caraveo C, Hernández Dávila R, Santos-Zambrano J. Albendazole trial at 15 or 30 mg/kg/day for subarachnoid and intraventricular cysticercosis. *Neurology.* 2006;66:436-438.
- Jung H, Hurtado M, Medina M, Sanchez M, and Sotelo J. Dexamethasone increases plasma levels of albendazole. *J. Neurol.*1990; 237:279-280
- Jung H, Hurtado M, Medina M, Sanchez M, and Sotelo J. Plasma and cerebrospinal fluid levels of albendazole and praziquantel in patients with neurocysticercosis. *Clin. Neuropharmacol.* 1990;13:559-564
- Kaur S, Singhi P, Singhi S, Khandelwal N. Combination therapy with albendazole and praziquantel versus albendazole alone in children with seizures and single lesion neurocysticercosis: a randomized, placebo-controlled double blind trial. *Pediatr Infect Dis J.* 2009 May;28(5):403-6.
- Kim, S. K., K. C. Wang, S. H. Paek, K. S. Hong, and B. K. Cho. 1999. Outcomes of medical treatment of neurocysticercosis: a study of 65 cases in Cheju Island, Korea. *Surg. Neurol.* 1999;52:563-569
- Kramer, L. D. 1990. Antihelminthic therapy for neurocysticercosis. *Arch. Neurol.* 47:1059-1060
- Little SE. Parasitic zoonoses: parasites transmitted from cats and dogs to children. *Contemporary Pediatrics* 2003;5:1-21
- Miller B, Grinnell V, Goldberg MA, and Heiner D. Spontaneous radiographic disappearance of cerebral cysticercosis: three cases. *Neurology* 1983;33:1377-1379.
- Mitchell W G and Crawford TO Intraparenchymal cerebral cysticercosis in children: diagnosis and treatment. *Pediatrics* 1988; 82:76-82.
- Moodley, M., and A. Moosa. 1989. Treatment of neurocysticercosis: is praziquantel the new hope? *Lancet* i:262-263
- Nicoletti A, Bartoloini A, Reggio A, et al. Epilepsy, cysticercosis, and toxocariasis. A population-based case-control study in rural Bolivia. *Neurology* 2002;58:1256-1261.
- Nicoletti A, Bartolini A, Sofia V, Mantella A, Nsengiyumva G, Frescaline G, Preux P-M. Epilepsy and toxocariasis : a case-control study in Burundi. *Epilepsia* 2007;48 :894-899.
- Nicoletti A, Sofia V, Mantella A, Vitale G, Contrafatto D, Sorbello V, Biondi R, Preux P-M, Garcia HH, Zappia M, Bartolini A. Epilepsy and toxocariasis: a case-control study in Italy. *Epilepsia* 2008;49:594-599.
- Prabhakar S, Singh G. Neurocysticercosis: an overview of clinical presentations. *In: Singh G and Prabhakar S. (eds.) Taenia solium cysticercosis. From basic to clinical science.* New York: CAB International; 2002 : pp. 169-176.
- Preux P-M and Druet-Cabanac M. Epidemiology and aetiology of epilepsy in sub-Saharan Africa. *Lancet Neurol* 2005; 4:21-31.
- Proaño JV, Madrazo I, Avelar F, López-Félix B, Díaz G, Grijalva I. Medical treatment for neurocysticercosis characterized by giant subarachnoid cysts. *N Engl J Med.* 2001 Sep 20;345(12):879-85.

- Rabiela T, Rivas A, Flisser A. Morphological types of *Taenia solium* cysticerci. *Parasitol. Today* 1989;5:357-359.
- Rajshekhar, V. 1991. Etiology and management of single small CT lesions in patients with seizures: understanding a controversy. *Acta Neurol. Scand.* 84:465-470
- Robles C and Chavarría M. Presentación de un caso clínico de cisticercosis cerebral tratado medicamente con un nuevo fármaco: praziquantel. *Salud Pública Mex.* 1979;21:603-618
- Roman G, Sotelo J, Del Brutto O, Flisser A, Dumas M, Wadia N, Botero D, Cruz M, Garcia H, de Bittencourt PRM, Trelles L, Arriaga C, Lorenzana P, Nash TE, Spina-Franca A. A proposal to declare neurocysticercosis and international reportable disease. *Bull WHO* 2000; 78:399-406.
- Singhi P. Neurocysticercosis. *Therapeutic Advances in Neurological Disorders* January 26, 2011 1756285610395654. Full text available at URL: <http://tan.sagepub.com/content/early/2011/01/23/1756285610395654> (last review on February 13, 2011)
- Sotelo J, Escobedo F, Penagos P. Albendazole vs Praziquantel for Therapy of Neurocysticercosis. A Controlled Trial. *Arch Neurol.* 1988;45(5):532-534.
- Sotelo J. Neurocysticercosis – Is the Elimination of Parasites Beneficial? *N Engl J Med* 2004; 350:280-282
- Thussu A, A Chattopadhyay A, I M S Sawhney I, Khandelwal N. Albendazole therapy for single small enhancing CT lesions (SSECTL) in the brain in epilepsy. *J Neurol Neurosurg Psychiatry* 2008;79:272-275
- Uddin J, Garcia HH, Gilman RH, Gonzalez AE, Friedland JS. Monocyte-astrocyte networks and the regulation of chemokine secretion in neurocysticercosis. *J Immunol* 2005; 175:3273-3281.
- Yacoob Y, et al. Sodium valproate and highly active antiretroviral therapy in HIV positive patients who develop new onset seizures. *Seizure: Eur J Epilepsy* (2010), doi:10.1016/j.seizures.2010.09.09 (In press)
- Yuan Z, Ren HJ, Ding YZ, Zhang JS, Wang WP, Wu XL, Qiu MD. Clinical study about treatment of severe neurocysticercosis. *Sheng Chong Bing Za Zhi.* 2004;22(4):213-7.
- Wallin MY and Kurtzke JF. Neurocysticercosis in the United States: review of an important emerging infection. *Neurology* 2004; 63:1559-1564.
- White AC Jr, Samo T, Murphy EC, Harris RL. Extraparenchymal neurocysticercosis: report of five cases and review of management. *Clin Infect Dis.* 1992;15:799-811.



Novel Treatment of Epilepsy

Edited by Prof. Humberto Foyaca-Sibat

ISBN 978-953-307-667-6

Hard cover, 326 pages

Publisher InTech

Published online 22, September, 2011

Published in print edition September, 2011

Epilepsy continues to be a major health problem throughout the planet, affecting millions of people, mainly in developing countries where parasitic zoonoses are more common and cysticercosis, as a leading cause, is endemic. There is epidemiological evidence for an increasing prevalence of epilepsy throughout the world, and evidence of increasing morbidity and mortality in many countries as a consequence of higher incidence of infectious diseases, head injury and stroke. We decided to edit this book because we identified another way to approach this problem, covering aspects of the treatment of epilepsy based on the most recent technological results *in vitro* from developed countries, and the basic treatment of epilepsy at the primary care level in rural areas of South Africa. Therefore, apart from the classic issues that cannot be missing in any book about epilepsy, we introduced novel aspects related with epilepsy and neurocysticercosis, as a leading cause of epilepsy in developing countries. Many experts from the field of epilepsy worked hard on this publication to provide valuable updated information about the treatment of epilepsy and other related problems.

How to reference

In order to correctly reference this scholarly work, feel free to copy and paste the following:

Humberto Foyaca-Sibat and Lourdes de Fátima Ibañez-Valdés (2011). Treatment of Epilepsy Secondary to Neurocysticercosis, *Novel Treatment of Epilepsy*, Prof. Humberto Foyaca-Sibat (Ed.), ISBN: 978-953-307-667-6, InTech, Available from: <http://www.intechopen.com/books/novel-treatment-of-epilepsy/treatment-of-epilepsy-secondary-to-neurocysticercosis>

INTECH
open science | open minds

InTech Europe

University Campus STeP Ri
Slavka Krautzeka 83/A
51000 Rijeka, Croatia
Phone: +385 (51) 770 447
Fax: +385 (51) 686 166
www.intechopen.com

InTech China

Unit 405, Office Block, Hotel Equatorial Shanghai
No.65, Yan An Road (West), Shanghai, 200040, China
中国上海市延安西路65号上海国际贵都大饭店办公楼405单元
Phone: +86-21-62489820
Fax: +86-21-62489821

© 2011 The Author(s). Licensee IntechOpen. This chapter is distributed under the terms of the [Creative Commons Attribution-NonCommercial-ShareAlike-3.0 License](#), which permits use, distribution and reproduction for non-commercial purposes, provided the original is properly cited and derivative works building on this content are distributed under the same license.

IntechOpen

IntechOpen