

We are IntechOpen, the world's leading publisher of Open Access books Built by scientists, for scientists

4,800

Open access books available

122,000

International authors and editors

135M

Downloads

Our authors are among the

154

Countries delivered to

TOP 1%

most cited scientists

12.2%

Contributors from top 500 universities



WEB OF SCIENCE™

Selection of our books indexed in the Book Citation Index
in Web of Science™ Core Collection (BKCI)

Interested in publishing with us?
Contact book.department@intechopen.com

Numbers displayed above are based on latest data collected.

For more information visit www.intechopen.com



Lead Extraction in Congenital Heart Disease Patients – Indications, Technique and Experience

Philip Chang, Miguel Salazar, Michael Cao and David Cesario
*Keck School of Medicine at U.S.C
USA*

1. Introduction

Implantation of pacemakers and implantable cardioverter defibrillators (ICDs) are common procedures associated with very low complication rates(1-3). Device therapy is frequently used in the management of adult congenital heart disease (ACHD) patients given the high prevalence of arrhythmic complications encountered in this population. The ACHD population continues to grow at a rapid pace. It is estimated that there are currently more surviving adults with severe congenital heart disease (CHD) than children(4). The prevalence of arrhythmias and conduction disorders in adults with surgically treated CHD as well as those with specific congenital defects associated with conduction system abnormalities has led to an increasing need for implantable devices (both pacemakers and ICDs) in these patients (5). Unfortunately, as the indications for device implantation in patients with CHD have increased, so have the rate of device related infections and other complications leading to a growth in referrals for lead extraction in this expanding patient population(6-8). A thorough understanding of the role that lead extraction plays in this growing subgroup of patients is therefore critical for any implanting and extracting practitioner.

2. Specific challenges in the adult CHD population

At times patients with complex CHD in need of a permanent implantable device (pacemaker or ICD) require epicardial lead placement. This is due to complex anatomy or vascular limitations that prevent access to the venous circulation or due to the presence of intracardiac shunts that may increase the risk of embolic events with intracardiac leads. However, successful transvenous lead placement is often possible in patients with CHD, and these procedures are done with increasing frequency in the cardiac catheterization laboratory(9; 10). Transvenous lead systems are preferable to epicardial leads due to their generally lower capture thresholds and their greater durability and longevity(11). Procedural risk and peri-procedural morbidity is also significantly reduced with a transvenous approach. Yet, many patients with CHD are young and anatomic considerations often place additional stress on leads requiring multiple device pulse generator or lead replacements over time(12). Both lower age at implantation and a diagnosis of CHD have been associated with increased risks of lead failure over time(13).

3. Lead extraction indications

In adults with CHD, as well as in the general population of patients with implantable devices, the main indications for lead extraction include lead fracture, venous stenosis with associated superior vena cava (SVC) syndrome, infection and patient discomfort related to implanted materials. Lead malfunction rates in the published literature - ICD leads in particular - range from 16 to 20% at 10 years(14; 15). Although this rate may not hold true for all modern leads, it is of significance in patients with CHD since many receive implants at an early age and have a cumulative risk of developing device-related complications.

Over the past decade, due to expanded indications for ICDs and a resultant dramatic increase in the number of devices implanted, the incidence of device infections has been rising(16; 17). Infection of any of the components of the device system can lead to sepsis and death. Prompt extraction of the entire device system coupled with intravenous antibiotics is a viable and effective treatment option to prevent these complications.

4. General experience

For the reasons stated above, transvenous leads are now favored over epicardial leads in the pediatric and young adult CHD population. Published data on lead extraction in CHD patients is steadily growing but currently consists of single-center experiences with patient numbers far smaller than typical adult studies.(6; 18; 19) Due to the extreme heterogeneity of the ACHD population, interventions such as device extraction are often generalized to the entire CHD population, as the number of each individual defect type is often too small for meaningful comparison and reporting. We have summarized, in table format, the three largest published reports on lead extraction in ACHD patients published to date (Table 1)(10; 19; 20).

	Number of patients	Number of leads	Number of leads Removed	Technique	Mean duration of lead implantation	Indication	Minor complication	Major complications	Deaths
Cecchin et al.	144	203	162 (80%)	Laser and Torsion device.	7.6 ± 4.3 years	Infection (8%); Lead failure (65%); Device upgrade (12.5%)	2.80%	2.80%	None
Khairy et al.	16	23	21(91%)	Laser	9.0 ± 5.2 years	Infection 44%; Lead failure 25%; Device upgrade 25%; pain 6%	N/A	1 (6.3%)	None
Cooper et al.	14	21	20 (95%)	Laser	42.0 ± 18.9 months	Lead failure (93%)	3 required transfusions	None	None

Table 1.

5. Planning the procedure

The ACHD population presents several unique challenges to physicians planning a device extraction. Before bringing these patients to the electrophysiology (EP) lab, the operator

needs to become extremely familiar with the patient, their anatomy, the device and leads. A thorough understanding of the patient's anatomy and device history is paramount to all other aspects of the procedure. Understanding the anatomy in an adult with CHD includes knowing the original defect, previous surgeries and interventions performed on the patient, residual defects, chamber sizes, and vascular connections.

In addition to the standard history, physical exam and chest x-ray (posterior-anterior and lateral) to assess the number and relative locations of the lead(s), a detailed review of previous surgical reports, echocardiography reports, advanced imaging studies, and clinical progress notes should be done in preparation for lead extraction in CHD patients. Echocardiography remains a standard component in the anatomical evaluation of CHD patients and transthoracic and transesophageal modalities should be used to assess for residual intracardiac shunts, valve function, chamber sizes, and basic lead courses and locations. We routinely perform trans-esophageal echocardiograms (TEEs) prior to or during our device extractions. This is particularly important in ACHD patients for several reasons. Pre-procedural TEEs can confirm the diagnosis of device infection and define large vegetations on the leads that may contra-indicate percutaneous extraction, particularly in patients with intra-cardiac shunts. Given, the risk of cerebral emboli in such patients, these devices are often best removed through open surgical extraction. Cardiac computed tomography (CT) is quickly becoming an important tool in the care of ACHD patients by providing excellent images for anatomic and functional features of CHD. Additionally, venous anatomy and patency can also be assessed with cardiac CT. Finally, angiography can be performed at the time of the device procedure to further assess for venous patency, baffle obstruction or baffle leaks.

Not only will CHD patients with devices have a broad variety of defects but their device and lead implant history may be equally complicated. Some CHD patients carry a long history of device-related procedures dating back to early childhood years with epicardial systems, subcutaneous leads and arrays, pericardial leads, and transvenous implants together with their associated generator changes. For others who have undergone transvenous implantation, it is possible to encounter patients with multiple leads and venous obstruction. The operator also needs to be familiar with the lead itself including its fixation mechanism and type of insulation material. The manufacturer and their representatives can be valuable assets in obtaining this information. Interrogation of the device prior to the procedure will also reveal whether the patient is dependent on its pacing functions in order to determine if a temporary pacemaker will need to be placed during the procedure. At times, careful device interrogation may show apparent recovery of intrinsic atrio-ventricular conduction and that the patient has not been device dependent. Such patients may not require immediate re-implantation and can be closely monitored to assess their current pacing requirements. Any decision to delay or forego device re-implantation must be weighed against the possibility that conduction disease can progress over time in patients with CHD and that transient or permanent conduction block can recur over time. At the time of the procedure, interrogation of all the leads must be done. This is particularly important if a lead is to be re-used.

In ACHD patients with infected device systems, a pre-procedural consultation with an infectious disease specialist may be warranted to provide recommendations for proper intravenous antibiotic therapy and timing of device re-implantation if patients are device dependent.

The decision to perform complex lead extractions or to abandon leads is another important consideration in CHD device procedures. Venous access and patency remain great concerns in ACHD patients with devices and this may lead the electrophysiologist to undertake complex extractions on multiple leads in an effort to preserve the vascular space and previously implanted lead courses, knowing that these patients will likely return several additional times in the future for similar procedures. Laser and RF extraction sheaths should be present and easily available during CHD lead extractions.

Additionally, ACHD patients are at increased risk for extraction related complications. Surgical support should always be coordinated before CHD lead extractions and measures should be in place in the event that emergent surgical intervention is required. Interventional cardiology involvement should also be in place in the event of certain complications and to provide expertise in the event that leaks or stenoses require balloon dilation, stenting or percutaneous device closure. Patch and baffle leaks or tears can occur during extraction resulting in the acute mixing of blood pools to varying extents depending on the size of the tear. Certain leaks may be amenable to percutaneous device closure while others may require surgical intervention. Patients should be counseled on these possibilities and the potential involvement of surgeons or interventional cardiologists to address them. Combined procedures involving both the electrophysiologist and interventional cardiologist can be arranged to facilitate transvenous device procedures that otherwise would have been contraindicated given anatomic limitations in CHD patients(21).

6. Specific anatomic lesions

6.1 Transposition of the Great Arteries

Transposition of the great arteries (TGA) is a defect where the usual right ventricle (RV)-pulmonary artery (PA) and left ventricle (LV)-aorta relationships are reversed such that the RV is in continuity with the aorta while the LV is anatomically connected to the main PA (See Figure 1). In general, there are 2 types of transposition that include this reversed ventricle-to-great artery relationship. The first form, commonly referred to as “D-TGA”, involves an otherwise structurally normal heart with isolated transposition of the great vessels off the ventricles. The second form, frequently called “L-TGA” or congenitally corrected transposition of the great arteries (CCTGA), involves transposed great arteries with additional atrial-to-ventricular transposition such that the right atrium empties into a morphologic LV while the left atrium empties into a morphologic RV.

Surgical repair of both forms of TGA can involve an atrial switch procedure, either of the Mustard or Senning variety (See Figure 2). In general, the atrial switch involves baffling blood from the superior and inferior vena cavae, within the atria, over to the left sided atrio-ventricular (AV) valve and ventricle. Pulmonary venous return is routed within the atria to empty into the right sided AV valve and ventricle(22). The current approach to the repair of D-TGA involves the arterial switch procedure where the aorta, coronary arteries and PA are removed from their respective ventricles and switched such that the aorta and coronaries are connected to the LV while the PA is anastomosed to the RV, thereby restoring normal ventricle-great artery continuity. Atrial switches are still incorporated in combination with an arterial switch procedure in the so-called “double switch” procedure for anatomical repair of CCTGA.

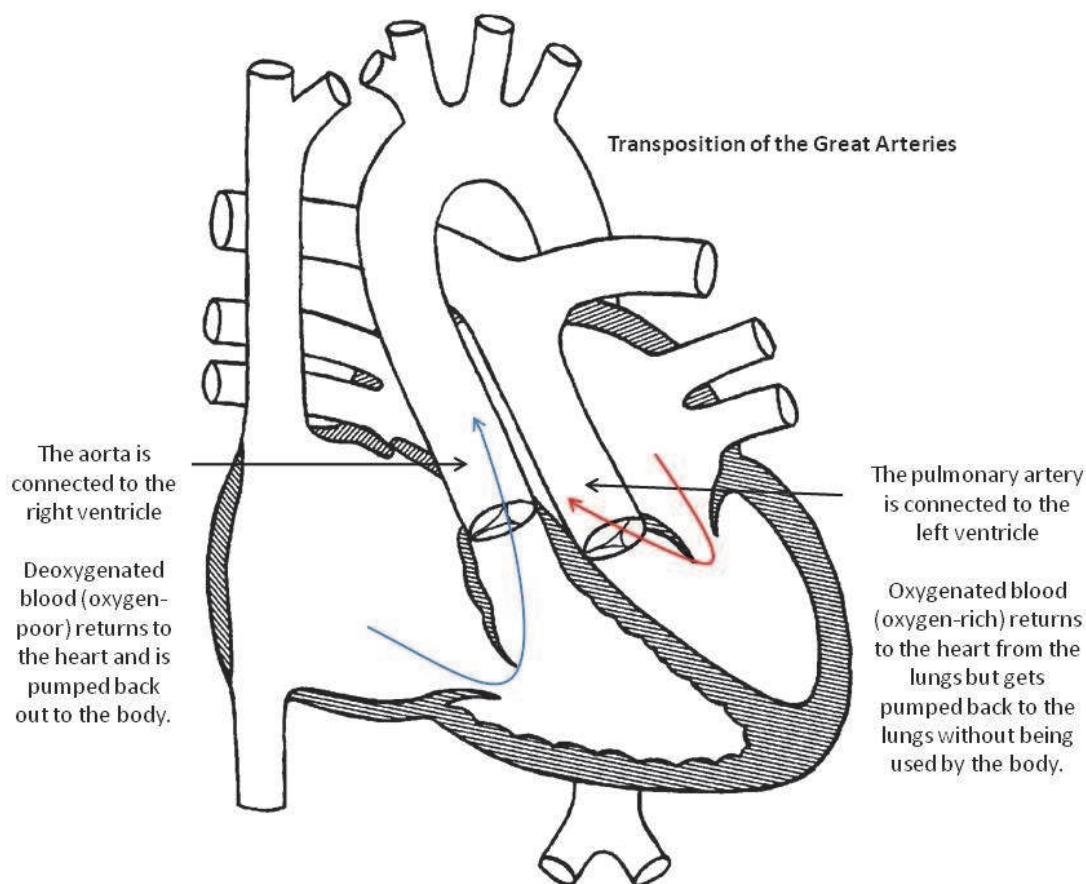


Fig. 1. Transposition of the Great Arteries.

Arrhythmias are frequently encountered in TGA patients who have undergone atrial switch procedures. Sinus node dysfunction and atrial arrhythmias are often encountered in atrial switch patients and can be addressed with device implantation and/or catheter ablation(23). Ventricular arrhythmias and risk of sudden death have been addressed with ICD implantation in palliated TGA patients and have been associated with compromised systemic RV function(8).

Atrial baffles present an element of complexity to lead implantation and extraction. The traditional approach of placing the atrial lead in the right atrial appendage or along the lateral right atrial wall is no longer possible. Leads are generally placed through the SVC and atrial baffle over to the left atrial wall. A location along the lateral atrial wall or in the left atrial appendage where reasonable sensing and pacing thresholds are achieved is selected for active lead fixation. In similar fashion, the ventricular lead also courses through the baffle to the left sided AV valve and is fixated in the left sided ventricle.

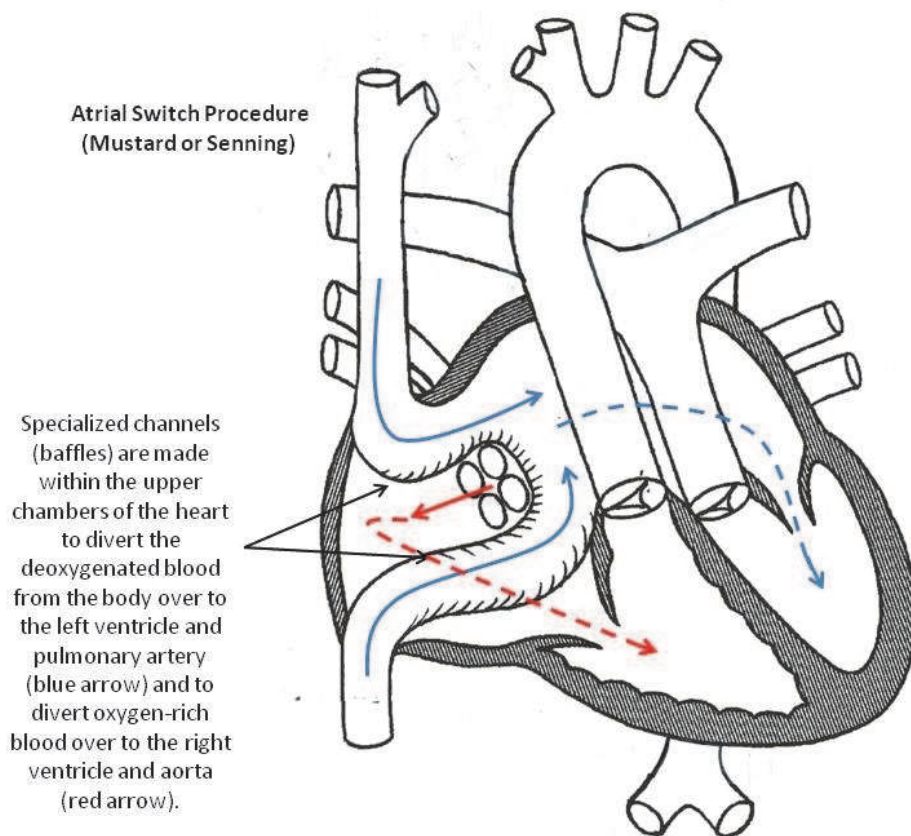


Fig. 2. Atrial Switch Procedure.

6.2 Tetralogy of Fallot

Tetralogy of Fallot (TOF) is among the most common forms of cyanotic CHD encountered in pediatric patients. In the current surgical era, complete repair is frequently undertaken in early infancy. The defect consists of a primary abnormality in ventricular septal formation where the conal or outflow region of the ventricular septum is mal-aligned relative to the rest of the ventricular septum and anteriorly deviated into the space normally occupied by the right ventricular outflow tract. This defect results in positioning of the aorta over the crest of the ventricular septum (overriding aorta) and the formation of a large ventricular septal defect (VSD) coupled with varying degrees of right ventricular outflow tract obstruction. The RV undergoes compensatory hypertrophy completing the fourth component of TOF.

Complete surgical repair consists of closure of the VSD with various materials along with a variety of interventions to augment the size of the right ventricular outflow tract. This often involves a right ventriculotomy incision, resection of obstructive muscle bundles in the sub-pulmonary region, and trans-annular incisions and patch placement to increase the effective size of the pulmonary valve and main pulmonary artery segment. While

ventricular level shunting and outflow tract obstruction are generally eliminated, patients are left with varying degrees of pulmonary insufficiency and impaired right ventricular hemodynamics.

It is well recognized that repaired TOF patients are at risk for a variety of arrhythmic disturbances. Atrial arrhythmias and sinus and AV node dysfunction are not infrequent. Ventricular arrhythmias related to macroreentry around incisions and patches and poor ventricular hemodynamics have been well described(24; 25).

Lead extraction in repaired TOF patients can generally follow a similar approach to that in non-CHD patients. Special attention should be given to previous device and surgical histories. Many patients have undergone prior device implants with resultant vascular obstruction and others have undergone old approaches to device management with separate pacemaker and ICD systems implanted at the same time to address bradycardia and ventricular arrhythmias or sudden death risk. Therefore, assessing vascular access becomes an important part of pre-procedural planning and great care must be taken to preserve transvenous access for the placement of new leads.

6.3 Septal and AV Canal defects

Patients with atrial and ventricular septal defects are usually repaired in early childhood with excellent outcomes. Those with atrio-ventricular canal (AVC) defects comprise a spectrum of patients with variable long-term outcomes.

Atrial septal defects (ASDs) come in several varieties, the most common being the secundum ASD where a septal hole exists that is enclosed circumferentially by atrial septal tissue. This defect is easily repaired through patch closure or primary suture closure during surgery or through percutaneous means with a variety of deployable devices. Primum type and sinus venosus type defects are more complicated forms of ASDs. In sinus venosus ASDs, the septal defect is located adjacent to the caval junctions with the atrium. Anomalous pulmonary venous return is frequently associated with sinus venosus ASDs and surgical repair is needed and often involves baffling of the anomalous pulmonary venous blood flow back to the left atrium. In primum type ASDs the defect is located inferiorly with the lower rim being bounded by the AV valve itself.

Ventricular septal defects (VSDs) can involve any part of the ventricular septum and may come in the form of isolated holes in the septum, mal-alignment types as in TOF, or deficiencies in the septum related to abnormal formation of the AVC and incorporation of embryologic endocardial cushion tissue into the ventricular septum. Defects in the membranous septum occur most frequently followed by muscular septal defects, both of which can usually be addressed through surgical patch closure. AVC type VSDs involve deficiencies of the inlet ventricular septum and the superior border of the defect involves the AV valve. Surgical closure is the dominant way of addressing VSDs however, percutaneous device-based methods can be employed to close certain types of muscular and membranous defects.

AVC defects represent a group of septal defects that are associated with varying degrees of AV valve anomalies (See Figure 3). Partial AVC defects consist of a primum type ASD with a cleft mitral valve. Transitional AVC defects involve a primum type ASD, small or occluded VSD component, and abnormal left and right AV valves. Complete AVC defects involve a large septal defect that spans both the atrial and ventricular septae and a single, common AV valve. Surgical repair of such defects requires an extremely experienced surgeon who will be able to separate and re-create the AV valves and their supporting valve architecture while also closing the atrial and ventricular septal defects.

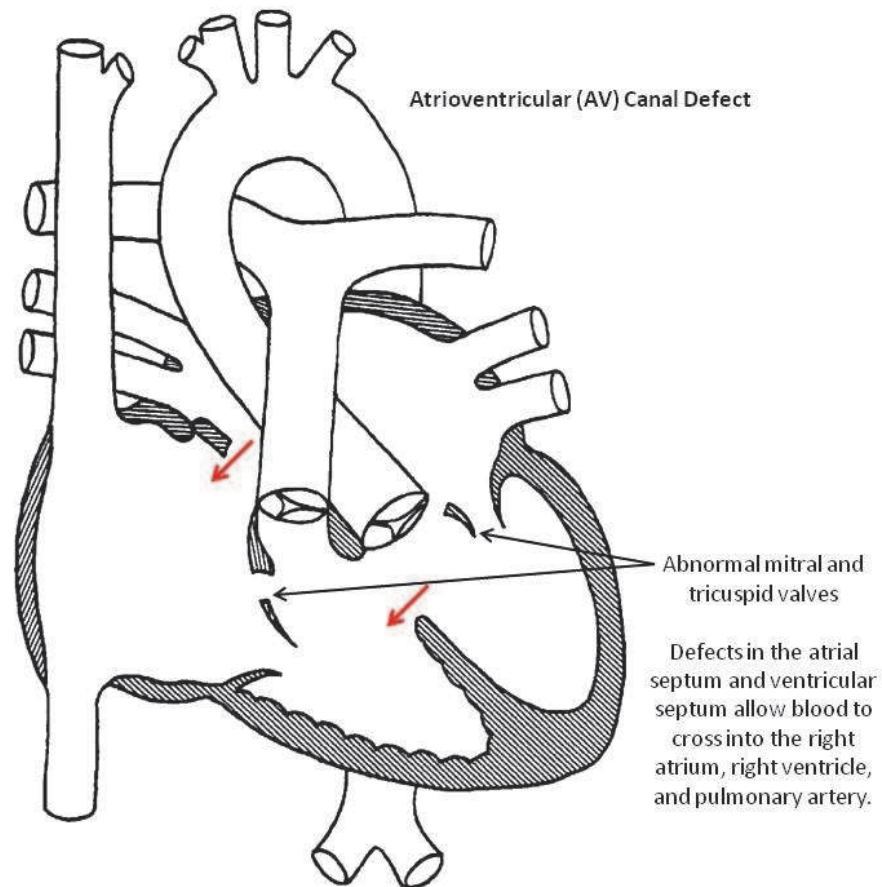


Fig. 3. AV Canal Defect.

Arrhythmias and conduction system disease can arise in septal defect patients. Prior cardiac surgery with an atriotomy incision and cannulation for cardiopulmonary bypass can result in sinus node dysfunction. AV node dysfunction occurred in the earlier surgical era of VSD repairs as the conduction system fibers ran close to the defects and were often injured by patches and/or suture material. Finally, in AVC type defects, the conduction system is inferiorly displaced, which also makes it prone to surgical trauma during repair attempts.

Lead extraction in patients with standard forms of atrial or ventricular septal defects can be undertaken in a manner similar to non-CHD patients. Repaired AVC defect patients can have unique anatomical features related to abnormal AV valve architecture and large ventricular septal patches. Finally, pre-procedural imaging is critical to determine the presence or absence of residual septal shunting after surgical repair.

6.4 Complex lesions (single ventricle hearts)

Patients with severe forms of CHD involving single ventricle anatomy and physiology often require device-based therapies to treat sinus or AV node dysfunction and to treat and prevent lethal arrhythmias. Single ventricle patients are palliated surgically with an eventual Fontan procedure where systemic venous blood is channeled directly to the pulmonary arterial tree (See Figure 4). The single ventricle is isolated and used to pump

exclusively to the systemic circulation. Fontan circulation involves the passive flow of systemic venous blood back to the lungs and is dependent on low vascular resistance within the pulmonary vasculature to promote venous return. Multiple forms of the Fontan procedure have been devised with most patients in the current surgical era having either a lateral tunnel or extra-cardiac Fontan conduit placed to channel inferior vena caval blood flow to the lungs. Superior caval blood is channeled to the lungs through a bidirectional Glenn anastomosis where the SVC is removed from the right atrium and connected in an end-to-side fashion to the right pulmonary artery. Classic Fontan patients have a direct anastomosis of the right atrium to the pulmonary arteries. Lateral tunnel and classic Fontan variants maintain an anatomical connection of the right atrial tissue with the systemic venous pathway.

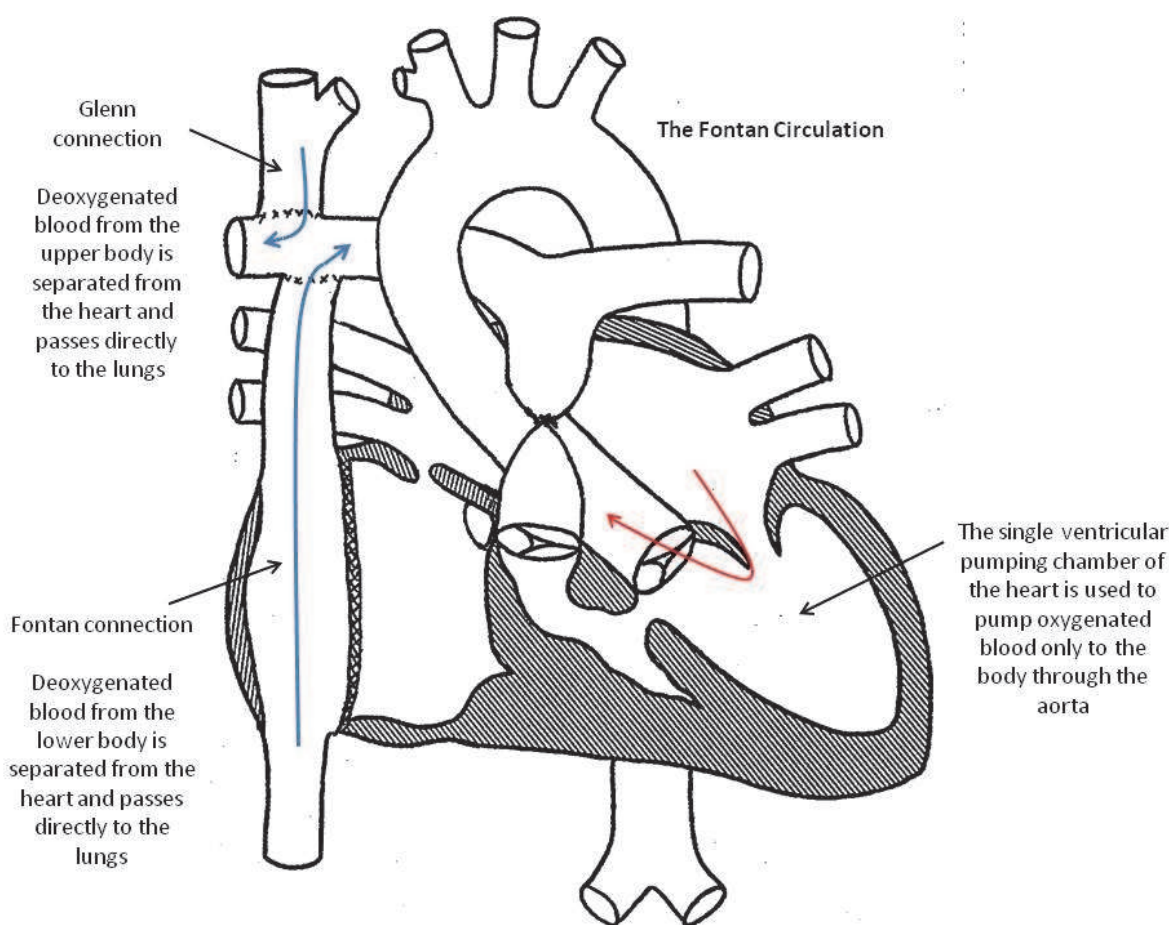


Fig. 4. The Fontan Circulation.

Pacemaker and ICD therapy in Fontan patients is frequently applied through epicardial routes with few patients having transvenous atrial leads(26; 27). Therefore, device procedures will predominantly involve sternotomies with direct visualization to sever old leads and place new leads in a different location on the myocardium. Transvenous atrial leads have occasionally been used in Fontan patients with isolated sinus node disease, particularly those with lateral tunnel or classic Fontan forms that permit venous to atrial

access for lead placement. For patients with transvenous atrial leads, extraction can be performed but careful attention must be paid to risks of thromboembolic complications, risks of conduit tears, and bleeding. In addition, placement of a new transvenous atrial lead may be challenging given a lack of reasonable endomyocardial targets with good sensing and pacing thresholds.

7. General technique for lead extraction using the implant vein

If the patient is pacemaker dependent, a temporary wire can be inserted from the groin or from the contra-lateral internal jugular or subclavian veins. Our center has found that placement of a temporary screw-in lead attached to an externally placed pacemaker pulse generator similar to what is implanted under the skin (tempo-permanent device) can be a useful tool in device dependent patients requiring extraction secondary to infection. This approach allows patients to have stable back-up pacing while receiving intravenous antibiotics and remaining ambulatory on the floor, until they are cleared for permanent device re-implantation.

To begin the extraction procedure, a small incision is made at the site of the previous pulse generator. Careful dissection is then undertaken in an effort to free up the leads and the device from the pocket. Dissection is performed along the leads all the way down to the suture sleeves which are cut and removed.

The dissected leads are then disconnected and tested. Further dissection is then undertaken to the venous entry point. Straight stylets are then inserted down the central lumen of each lead and an unsecured figure of eight stitch is done around the lead bodies to aid in hemostasis. If the lead is an active fixation lead, an attempt at retracting the fixation screw should be made. We have frequently used a laser sheath for these complex extraction cases. In preparation for laser lead extraction, the dissected lead is cut with heavy scissors. A sizing tool is inserted into the lead's inner coil to help select the appropriate size of locking stylet. Next, the locking stylet is introduced and advanced to the distal part of the lead and expanded. This stylet will be used to provide counter traction from the proximal part of the lead. Additionally, we tie a suture around the insulation and lead body and pass this suture through the laser sheath to provide further tension on the distal end of the lead. The laser sheath alone, or in combination with its outer Teflon sheath, is then inserted over the lead. Under fluoroscopic guidance, the sheath is carefully guided to the vein-lead interface. Staying coaxial to the lead, the laser sheath is advanced while counter-traction is kept on the lead with the locking stylet and the suture. Serial laser pulses are delivered during laser sheath advancement to heat the tissue and aid in the lysis of adhesions. The outer sheath can also be advanced into the vein and carefully rotated to help disrupt adhesions. Additionally, significant scarring and calcifications can develop along the leads, especially as they course through baffles. (See Figure 5) Baffle stenosis can be present and involve existing pacemaker or defibrillator leads, thereby necessitating baffle stenting and increasing the difficulty of extraction and re-implantation(28; 29). Dense calcifications may limit the efficacy of laser applications and careful dissection through these regions may require blunt dissection with the laser sheath and/or outer sheath and necessitates that the operating physician exhibit great patience and care during this portion of the procedure. This advancement is continued until the lead body is free or the sheath is advanced all the way down to the myocardial tissue where the lead is fixated. The same procedure is repeated for each lead to be removed.

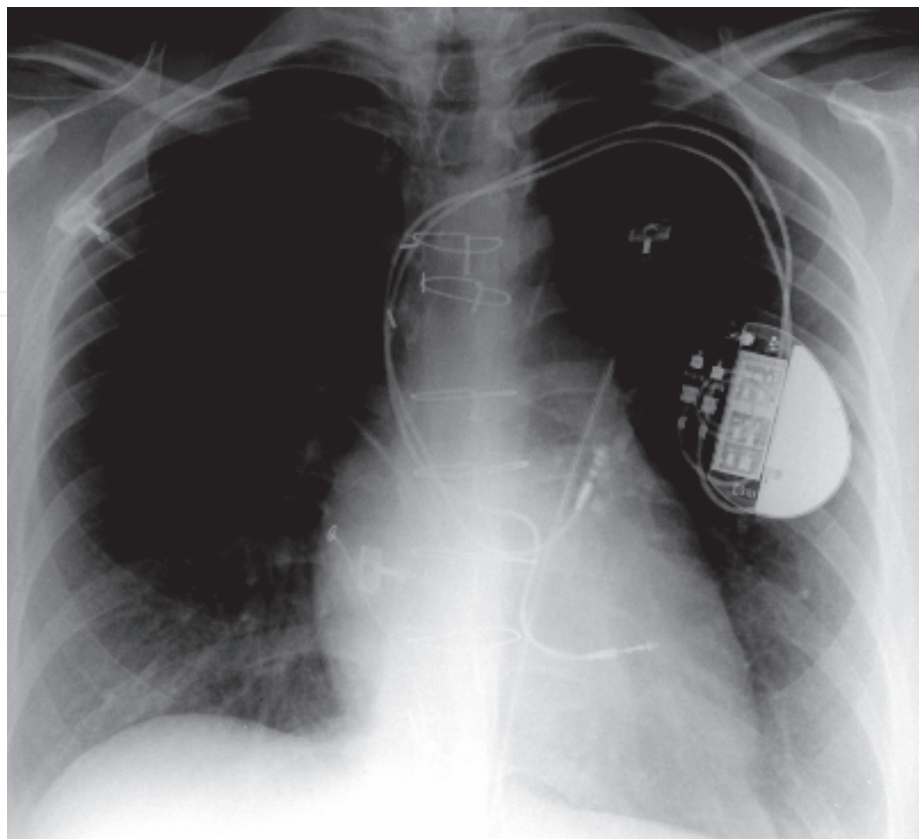


Fig. 5. A PA chest X-ray demonstrating a ventricular lead coursing through the systemic baffle in a patient with D-Transposition of the great arteries.

In the case of system infections, proper debridement of the pocket is also recommended, with complete removal of the capsule and debridement and removal of any scar tissue. The pocket should be thoroughly irrigated with antibiotic solution. In most patients the pocket can be loosely closed with interrupted sutures to allow drainage, unless there is gross pus present in the pocket. In such cases, a Jackson-Pratt drain is placed in the pocket and delivered through a healthy portion of tissue below the incision. The pocket is then sutured with interrupted and evenly spaced non-absorbable sutures. Alternatively, if there is great concern over abscess formation and re-accumulation of pus, the wound can be left open and packed with antibiotic soaked gauze and allowed to heal by secondary intention.

As many referrals for lead extraction are secondary to lead or device infection, the timeline for re-implantation in these patients becomes critical. As a general rule, the white blood cell count needs to be within normal limits or trending down and blood cultures need to be negative for at least 48 hours before considering re-implantation of a new system. These guidelines are not standard though and will vary from center to center. The duration of intravenous antibiotic treatment after re-implantation depends on the type of bacterium cultured, but generally lasts for 4-6 weeks. Input from an infectious disease consultant regarding duration of antibiotic therapy and optimal timing for re-implantation is essential.

8. Operator experience

Analysis of lead extraction outcomes suggests that the frequency of complete procedural success improves dramatically after the first 10 procedures have been performed. Lower

complication rates are associated with a prior experience of 30 procedures. The complication rate tends to keep improving after the first 30 procedures as the operator gains further experience.

There is no specific data for the CHD population, but since the rate of complications appears to be similar, these general guidelines may also apply. In general it is probably best that extractions in patients with CHD be done at centers with the necessary expertise and experience in both complex lead extractions and the management of adults with CHD.

9. Complications

The overall published complication rate for CHD patients undergoing lead extraction is consistently low (10; 19; 20). The rate of major complications varies from 2.8 to 21% (10; 20). Major complications include induction of ventricular fibrillation and cardiac perforation with risk of tamponade. Minor complications include pocket hematoma, superficial infection and excessive bleeding requiring transfusion.

10. Conclusions

Adults with CHD and implanted devices present unique challenges to the practitioner performing lead extractions. While the general indications for lead extraction and the technical aspects of the procedure are similar in both CHD patients and those with structurally normal hearts, close attention needs to be paid to several features of CHD patients. First the electrophysiologist must be aware of the specific CHD defect in each patient and the associated ramifications of prior surgical- and catheter-based interventions, complex device histories, and the importance of preserving the vascular space. Overall, the use of laser sheaths to assist in lead extraction has greatly increased the safety and efficacy of this procedure in both the general population and adults with CHD(19; 30). There remains a relative paucity of published data on device extraction in ACHD patients. However, the published reports suggest that device extraction is a safe and efficacious procedure in this patient population.

Due to the highly variable anatomic substrates and additional complexities, all ACHD device extractions require meticulous pre-procedural planning. Comprehensive review of the clinical and surgical history, inclusion of appropriate advanced imaging studies, incorporation of available tools as well as involvement of surgical and interventional services should all be routinely practiced to ensure successful outcomes while minimizing morbidity in a patient population that has had substantial exposure to medical and surgical interventions in the past.


11. References

- [1] Ellenbogen KA, et al. 2003. Complications arising after implantation of DDD pacemakers: the MOST experience. *Am J Cardiol.* 92, 740-741.
- [2] Bailey SM, Wilkoff BL. 2006. Complications of pacemakers and defibrillators in the elderly. *Am J Geriatr Cardiol.* 15, 102-107.
- [3] Poole JE, et al. Complication rates associated with pacemaker or implantable cardioverter-defibrillator generator replacements and upgrade procedures: results from the REPLACE registry. *Circulation.* 122, 1553-1561.

- [4] Marelli AJ, et al. 2007. Congenital heart disease in the general population: changing prevalence and age distribution. *Circulation*. 115, 163-172.
- [5] Ih S, et al. 1983. The location and course of the atrioventricular conduction system in common atrioventricular orifice and in its related anomalies with transposition of the great arteries--A histopathological study of six cases. *Jpn Circ J*. 47, 1262-1273.
- [6] Cesario D, et al. 2009. Device extraction in adults with congenital heart disease. *Pacing Clin Electrophysiol*. 32, 340-345.
- [7] Perloff JK, Warnes CA. 2001. Challenges posed by adults with repaired congenital heart disease. *Circulation*. 103, 2637-2643.
- [8] Gatzoulis MA, et al. 1999. Outpatient clinics for adults with congenital heart disease: increasing workload and evolving patterns of referral. *Heart*. 81, 57-61.
- [9] Gammage MD. 2000. Pacing approaches to the patient with a univentricular heart and the factors associated with choice of pacing site. *Pacing Clin Electrophysiol*. 23, 144.
- [10] Khairy P, et al. 2007. Laser lead extraction in adult congenital heart disease. *J Cardiovasc Electrophysiol*. 18, 507-511.
- [11] Radbill AE, et al. System survival of nontransvenous implantable cardioverter-defibrillators compared to transvenous implantable cardioverter-defibrillators in pediatric and congenital heart disease patients. *Heart Rhythm*. 7, 193-198.
- [12] Shah A, et al. 2006. Stable atrial sensing on long-term follow up of VDD pacemakers. *Indian Pacing Electrophysiol J*. 6, 189-193.
- [13] Fortescue EB, et al. 2004. Patient, procedural, and hardware factors associated with pacemaker lead failures in pediatrics and congenital heart disease. *Heart Rhythm*. 1, 150-159.
- [14] Hardeland R. 2009. Neuroprotection by radical avoidance: search for suitable agents. *Molecules*. 14, 5054-5102.
- [15] Hauser RG, et al. 2008. Safety and efficacy of transvenous high-voltage implantable cardioverter-defibrillator leads in high-risk hypertrophic cardiomyopathy patients. *Heart Rhythm*. 5, 1517-1522.
- [16] Uslan DZ, Baddour LM. 2006. Cardiac device infections: getting to the heart of the matter. *Curr Opin Infect Dis*. 19, 345-348.
- [17] Voigt A, et al. Continued rise in rates of cardiovascular implantable electronic device infections in the United States: temporal trends and causative insights. *Pacing Clin Electrophysiol*. 33, 414-419.
- [18] Friedman RA, et al. 1996. Lead extraction in young patients with and without congenital heart disease using the subclavian approach. *Pacing Clin Electrophysiol*. 19, 778-783.
- [19] Cooper JM, et al. 2003. Implantable cardioverter defibrillator lead complications and laser extraction in children and young adults with congenital heart disease: implications for implantation and management. *J Cardiovasc Electrophysiol*. 14, 344-349.
- [20] Cecchin F, et al. Lead extraction in pediatric and congenital heart disease patients. *Circ Arrhythm Electrophysiol*. 3, 437-444.
- [21] Daehnert I, et al. 2001. Echocardiographically guided closure of a patent foramen ovale during pregnancy after recurrent strokes. *J Interv Cardiol*. 14, 191-192.
- [22] Konstantinov IE, et al. 2004. Atrial switch operation: past, present, and future. *Ann Thorac Surg*. 77, 2250-2258.

- [23] Kanter RJ, Garson A, Jr. 1997. Atrial arrhythmias during chronic follow-up of surgery for complex congenital heart disease. *Pacing Clin Electrophysiol.* 20, 502-511.
- [24] Khairy P, et al. Arrhythmia burden in adults with surgically repaired tetralogy of Fallot: a multi-institutional study. *Circulation.* 122, 868-875.
- [25] Walsh EP, et al. 1988. Late results in patients with tetralogy of Fallot repaired during infancy. *Circulation.* 77, 1062-1067.
- [26] Takahashi K, et al. 2009. Permanent atrial pacing lead implant route after Fontan operation. *Pacing Clin Electrophysiol.* 32, 779-785.
- [27] Welisch E, et al. A single institution experience with pacemaker implantation in a pediatric population over 25 years. *Pacing Clin Electrophysiol.* 33, 1112-1118.
- [28] Undavia M, et al. 2008. Laser lead extraction and baffle stenting to facilitate dual chamber implantable defibrillator upgrade in a patient with L-transposition of the great arteries status-post Senning/Rastelli repair: a case report and review of literature. *Pacing Clin Electrophysiol.* 31, 131-134.
- [29] Chan AW, et al. 2002. Percutaneous treatment for pacemaker-associated superior vena cava syndrome. *Pacing Clin Electrophysiol.* 25, 1628-1633.
- [30] Wilkoff BL, et al. 1999. Pacemaker lead extraction with the laser sheath: results of the pacing lead extraction with the excimer sheath (PLEXES) trial. *J Am Coll Cardiol.* 33, 1671-1676.

IntechOpen



Cardiac Pacemakers - Biological Aspects, Clinical Applications and Possible Complications

Edited by Prof. Mart Min

ISBN 978-953-307-639-3

Hard cover, 194 pages

Publisher InTech

Published online 06, September, 2011

Published in print edition September, 2011

Clinical usage of artificial pacing dates back to 1958, when the battery powered cardiac pacemakers became available. Modern implantable pacemakers are the complicated electronic devices operating 10 years continuously without battery exchange. Though the development of devices is not a primary topic of the book, certain efforts towards developing of biologic pacemakers through tissue engineering and studying of cell synchronization are discussed. The main attention is paid to implementations of pacemakers in different medical situations oriented towards widening the clinical indications for implanting the cardiac pacemakers. New methods and devices in cardiac resynchronization therapy (CRT) have received particular attention. Placing of pacing electrodes has been treated soundly. Furthermore, emerging of complexities and complications in new clinical situations and other safety problems have been discussed thoroughly. The authors have derived the used information from their own clinical practice and experiences of their medical colleagues. These and other pragmatic features can be acknowledged as the most valuable asset of the book.

How to reference

In order to correctly reference this scholarly work, feel free to copy and paste the following:

Philip Chang, Miguel Salazar, Michael Cao and David Cesario (2011). Lead Extraction in Congenital Heart Disease Patients – Indications, Technique and Experience, *Cardiac Pacemakers - Biological Aspects, Clinical Applications and Possible Complications*, Prof. Mart Min (Ed.), ISBN: 978-953-307-639-3, InTech, Available from: <http://www.intechopen.com/books/cardiac-pacemakers-biological-aspects-clinical-applications-and-possible-complications/lead-extraction-in-congenital-heart-disease-patients-indications-technique-and-experience>

INTECH
open science | open minds

InTech Europe

University Campus STeP Ri
Slavka Krautzeka 83/A
51000 Rijeka, Croatia
Phone: +385 (51) 770 447
Fax: +385 (51) 686 166
www.intechopen.com

InTech China

Unit 405, Office Block, Hotel Equatorial Shanghai
No.65, Yan An Road (West), Shanghai, 200040, China
中国上海市延安西路65号上海国际贵都大饭店办公楼405单元
Phone: +86-21-62489820
Fax: +86-21-62489821

© 2011 The Author(s). Licensee IntechOpen. This chapter is distributed under the terms of the [Creative Commons Attribution-NonCommercial-ShareAlike-3.0 License](https://creativecommons.org/licenses/by-nc-sa/3.0/), which permits use, distribution and reproduction for non-commercial purposes, provided the original is properly cited and derivative works building on this content are distributed under the same license.

IntechOpen

IntechOpen