

# We are IntechOpen, the world's leading publisher of Open Access books Built by scientists, for scientists

**4,800**

Open access books available

**122,000**

International authors and editors

**135M**

Downloads

Our authors are among the

**154**

Countries delivered to

**TOP 1%**

most cited scientists

**12.2%**

Contributors from top 500 universities



**WEB OF SCIENCE™**

Selection of our books indexed in the Book Citation Index  
in Web of Science™ Core Collection (BKCI)

Interested in publishing with us?  
Contact [book.department@intechopen.com](mailto:book.department@intechopen.com)

Numbers displayed above are based on latest data collected.

For more information visit [www.intechopen.com](http://www.intechopen.com)



# Retinal Nerve Fibre Layer Thinning in Alzheimer Disease

Panitha Jindahra and Gordon T Plant  
*Neuro-Ophthalmology Department*

*The National Hospital for Neurology and Neurosurgery  
UK*

## 1. Introduction

Alzheimer disease (AD) is a progressive neurodegenerative disorder characterised by impaired memory and cognitive function. A proportion of patients present with visual symptoms which could result from either anterior or posterior visual pathway dysfunction. Retinal and optic nerve abnormalities have in recent years been studied intensively in Alzheimer disease (AD) and are reviewed in this chapter.

## 2. Evidence of retinal nerve fibre layer thinning in AD

### 2.1 Histological evidence

Retinal ganglion cell (RGC) degeneration or optic neuropathy is one of the features of AD that has been identified in several histological, imaging, and electroretinogram (ERG) studies. Analyses of neuronal numbers in the RGC layer of severe AD patients and age-matched control subjects have revealed extensive neuronal loss throughout the entire retina in AD when compared with control eyes: the mean (RGC) number is 696,871 in AD which is significantly less than that of the controls (1,095,904) representing a loss of 36% ( $p < 0.004$ ) (Blanks et al., 1996b). The findings are in good agreement with other histological studies (Hinton et al., 1986; Sadun & Bassi, 1990; Trick et al., 1989) and compatible with diminished contrast sensitivity which may be secondary to afferent visual pathway dysfunction in AD patients (Crow et al., 2003). A post-mortem study revealed widespread optic nerve fibre degeneration with thinning of the retinal nerve fibre layer and reduced ganglion cell numbers in AD patients aged 76-89 years (Hinton et al., 1986), any potential correlation with the degree of cognitive impairment was not studied. In one study the axonal loss was prominent in the posterior part of the optic nerve suggesting that the process involved may be one of retrograde degeneration of the retinal ganglion cell axons (Sadun & Bassi, 1990). Neurons in the ganglion cell layer (GCL) in AD patients are reduced by 25-40% throughout the entire retina (Blanks et al., 1996b). The greatest density of RGCs is located in the macular region and the total numbers of ganglion cell fibres in the fovea/parafovea are reduced by 25% ( $p < 0.001$ ) in AD as compared to normal eyes (Blanks et al., 1996a). The loss in the central retina is greatest in the temporal area, which is surprisingly different from that found in the periphery (Blanks et al., 1996a). The neuronal loss reaches its peak in the superior and inferior quadrants of the peripheral retina (Blanks et al., 1996b). Unlike what is found in normal ageing, the RGC loss in AD is not related to age (Blanks et al., 1996a, 1996b). It was also found that both small- and

large-diameter RGC fibres are affected equally throughout the retina in AD eyes in some studies (Blanks et al., 1996b; Curcio & Drucker, 1993) but only large M-cell degeneration has been identified by the others (Sadun & Bassi, 1990; Trick et al., 1989; Blanks et al., 1989; Miller, 1990). The total number of astrocytes in the GCL was found to be 16% greater in the AD patients than in controls but the increase did not reach statistical significance (Blanks et al., 1996b). The ratio of astrocytes to neurons in the GCL is significantly raised in the AD retinas, resulting from both an increase in astrocytes and the decrease in neurons (Blanks et al., 1996b). A study comparing patients with at least a 4 year history of severe AD aged 67-86 years and age-matched controls revealed no significant difference in the number of RGCs (Curcio & Drucker, 1993). This is not the only study to find no significant difference in RGC number between AD patients and controls (Davies et al., 1995). It is notable that there is no data whether AD patients in this review are familial or sporadic type.

## 2.2 Imaging evidence

By employing fundus photography, RNFL degeneration was observed in AD patients as compared to age-matched control subjects (Hedges et al., 1996; Tsai et al., 1991). A study utilizing scanning laser ophthalmoscopy (SLO) has demonstrated a reduction of optic nerve fibres in AD patients when compared to age-matched controls (Danesh-Meyer et al., 2006). However, another SLO study showed no difference (Kergoat et al., 2001). It was shown that there was no significant difference in mean overall RNFL thickness and RNFL thickness in each quadrant between the AD and age-matched controls. The patients selected for this study were classed as mild to moderate dementia with a range of mini mental-state examination of 11-29 (mean 21.57) and a mean duration of 3 years. Optical coherence tomography (OCT) has been recently developed and has found wide application in neurology and ophthalmology both in the clinic and in research (Jindahra et al., 2009). It has been employed to measure RNFL thickness in several AD studies. In AD eyes, the mean of overall peripapillary (Parisi et al., 2001, 2003; Iseri, et al., 2006; Paquet et al., 2007; Lu et al., 2010; Valenti, 2007) and macular RNFL thickness (Paquet et al., 2007) as well as the mean of total macular volume (Paquet et al., 2007) measured by OCT are lower when compared with age-matched control subjects. It has been proposed that the retinal involvement might have occurred early in the course of the disease as the peripapillary RNFL loss is identified in mild cognitive impairment (MCI) (Paquet et al., 2007). The reduction of RNFL thickness is statistically significant in MCI (Paquet et al., 2007), mild AD (Parisi, 2003; Iseri et al., 2006; Paquet et al., 2007), and moderate to severe AD (Parisi, 2003; Iseri et al., 2006; Paquet et al., 2007), compared to controls. No difference was found between the results observed in MCI and mild AD patients (Paquet et al., 2007) but the measurements of RNFL thickness seen in moderate to severe cases are significantly thinner than those in MCI cases (Paquet et al., 2007). The RNFL thickness was found to be thinner than the controls in all four quadrants in MCI (Paquet et al., 2007) and AD cases (Parisi et al., 2001, 2003; Paquet et al., 2007). However in one study the temporal quadrant was unaffected (Iseri et al., 2006) and significant thinning was found only in the superior quadrant in mild to moderate AD cases compared with controls in a study and a case report (Berisha et al., 2007; Valenti, 2007). Yet another study, the RNFL was found to be significantly thinner than in normal subjects in the superior and inferior quadrants in AD patients and hence the patients no longer showed the double peak RNFL pattern (Lu et al., 2010). The thinning in the nasal and temporal quadrants did not reach statistical significance (Lu et al., 2010). It seems that the retinal damage due to AD may be localized preferentially to the vertical quadrants (Lu et al., 2010)

and as such may be considered to mimic the pattern seen in glaucoma (Figure 1, Table 1 & 2). By using OCT it has been shown that the reduction in total macular volume is highly related to the severity of cognitive impairment (MMSE) (Iseri et al., 2006).

Study	n	Country	OCT	Age Mean (± SD)	MMSE mean (± SD)
AD(Berisha 07)	9 subjects	USA	OCT 3000	74.3(±3.3)	23.8(± 5.1)
AD(Parisi 01)	17 eyes	Italy	Stratus OCT	70.37(±6.1)	16.4 (11.27-19.05)
AD (Iseri 06)	28 eyes	Turkey	OCT 3000	70.1(±9.7)	18.5(±6.3)
AD (Lu 10)	22 subjects	China	OCT 3000	73(±8)	N/A
Healthy (Savini 10)	8 eyes	Italy	Stratus OCT version 4.0	N/A	N/A
Healthy (Berisha 07)	8 subjects	USA	OCT 3000	74.3(±5.8)	29.5(±0.5)
Healthy (Parisi 01)	14 eyes	Italy	Stratus OCT	N/A	N/A
Healthy ((Iseri 06)	30 eyes	Turkey	OCT 3000	65.1(±9.8)	29.4(±0.6)
Healthy (Lu 10)	22 subjects	China	OCT 3000	68 (±9)	N/A
Healthy (Bowd 00)	30 eyes/subjects	USA	OCT 2000	N/A	N/A
Healthy (Bock 10)	405 eyes/203 subjects	Germany	OCT 3000	N/A	N/A
Glaucoma (Bowd 00)	29 eyes/subjects	USA	OCT 2000	N/A	N/A
OHT (Bowd 00)	28 eyes/subjects	USA	OCT 2000	N/A	N/A
Glaucoma (Bock 10)	39 eyes/22 subjects	Germany	OCT 3000	N/A	N/A

Table 1. Demographic data of subjects in the studies shown in Figure 1 (N/A = not available).

Study	refractive error	best VA	IOP (mmHg)	perimetry	disc appearance
AD(Berisha 07)	(-6) to (+6)	>=20/60	14.4±SD 4.2	N/A	vertical CDR 0.5±0.2
AD(Parisi 01)	(-3) to (+3)	>=8/10	<18	N/A	N/A
AD (Iseri 06)	(-3) to (+3)	>= 5/10	<22	normal	normal
AD (Lu 10)	N/A	logMar 0.4±0.2 LE 0.33±0.19 RE	15.4±1.2 LE 15.5±1.3 RE	N/A	CDR 0.53±0.2 (LE) 0.5±0.16 (RE)
Healthy (Savini 10)	(-3) to (+3)	>20/25	<21	N/A	normal
Healthy (Berisha 07)	(-6) to (+6)	>=20/60	13.3±SD 3.5	N/A	vertical CDR 0.49±0.13
Healthy (Parisi 01)	N/A	N/A	N/A	N/A	N/A
Healthy ((Iseri 06)	(-3) to (+3)	>= 5/10	<22	normal	normal
Healthy (Lu 10)	N/A	logMar 0.65±0.3LE 0.66±0.22 RE	15.4±1.4 LE 15.3±1.3 RE	N/A	CDR 0.38±0.1 (LE) 0.35±0.1(RE)
Healthy (Bowd 00)	N/A	>=20/40	<=22	normal	normal
Healthy (Bock 10)	N/A	N/A	N/A	N/A	N/A
Glaucoma (Bowd 00)	N/A	>=20/40	>=24	abnormal	glaucomatous changes
OHT (Bowd 00)	N/A	>=20/40	>=24	normal	normal
Glaucoma (Bock 10)	(-10) to (+6)	N/A	<22	N/A	N/A

Table 2. Ophthalmic examination of subjects in the studies shown in Figure 1

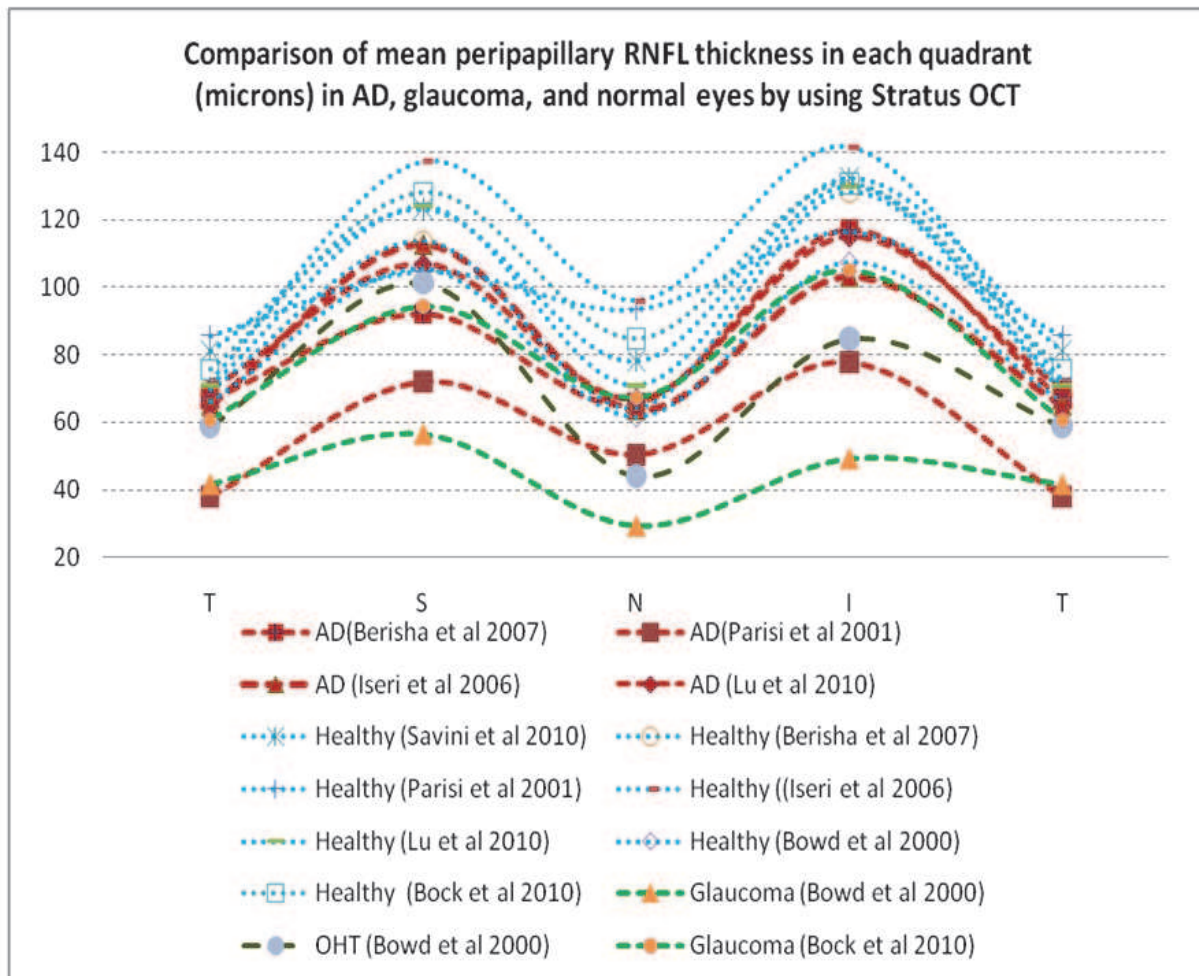


Fig. 1. A comparison of mean peripapillary RNFL thickness in each quadrant of AD, glaucoma, ocular hypertension (OHT) and normal eyes. See Tables 1 and 2 for details of the cohorts in each study.

### 2.3 Electrodiagnostic evidence

The results of electrodiagnostic testing are conflicting. ERG studies have failed to demonstrate changes in AD patients (Justino et al., 2001; Kergoat et al., 2001, 2002; Davies et al., 1995). Scotopic and photopic electroretinograms and oscillatory potentials in patients with mild Alzheimer disease were compared with normal individuals in one study (Justino et al., 2001). The amplitude and latency of a and b waves in mild AD patients were normal, reflecting intact function of the outer retina. The oscillatory potentials were also unremarkable in this study. Pattern electroretinogram (PERG) recordings have shown a significant delay in P50 and N95 implicit times and reduction in both P50 and N95 amplitudes in mild to severe AD when compared with the results obtained in control eyes (Parisi et al, 2001, 2003). This might indicate that the dysfunction lies in both ganglionic and preganglionic elements (Parisi et al, 2001, 2003). The delayed P50 and N95 implicit times and the reduced P50 and N95 amplitudes are significantly correlated with the reduced overall

mean of the RNFL thickness measured by OCT (Parisi et al., 2001, 2003). No significant difference was found in the latency of the pattern visually evoked potential (PVEP) P100 of AD patients and control subjects (Iseri et al., 2006). The normal PVEP responses revealed no evidence for any abnormality of primary visual cortex or of optic nerve function despite considerable RNFL loss (Iseri et al., 2006). However, some earlier studies did find abnormalities of the flash VEP (Wright et al., 1986; Norman et al., 1995) but probably not useful clinically (Coburn et al., 2003). However using PERG and PVEP, another study revealed a reduction in amplitude of N95 and increased latency of P100 wave in most AD eyes (Krasodomska et al., 2010).

#### **2.4 Optic disc morphology in AD eyes**

A large cup-to-disc ratio, thin rim area and volume are identified in AD eyes compared to age-matched normal eyes (Tsai et al., 1991; Danesh-Meyer et al., 2006). In one of these studies, the patients had a MMSE result of  $21 \pm 4$  taking an upper limit of the vertical cup-to-disc ratio as 0.42 gives a sensitivity of 0.45 and specificity of 0.84 (Danesh-Meyer et al., 2006). Pallor area to disc area ratio did not significantly differ between AD patients and normal subjects in one study (Tsai et al., 1991). However patients with a higher ratio had a higher Alzheimer disease assessment scale and longer duration of illness (Tsai et al., 1991). The changes are not in a uniform pattern for all AD patients (Berisha et al., 2007).

#### **2.5 Information from Down syndrome**

It has been shown that all adults with Down syndrome (DS) over 35-40 years old who had autopsies performed have AD pathology in their brains i.e., beta amyloid plaques and neurofibrillary tangles (Malamud, 1972). Amyloid precursor protein gene on the locus of the proximal part of the long arm of chromosome 21 is over-expressed in DS patients (Goldgaber et al., 1987), leading to AD development (Prasher et al., 1998). The DS brain pathology is comparable to AD brain and may be useful in further AD studies (Hof et al., 1995). Regarding visual functions, DS patients have impaired colour discrimination, stereoacuity, and contrast sensitivity, similarly to AD patients (Rocco et al., 1997). Moreover abnormal spatial vision in DS children has been detected without other ophthalmologic abnormalities (Suttle & Turner, 2004). A literature review of children with Down syndrome age 0-16 years revealed that refractive error, strabismus, poor acuity, nystagmus, and blepharitis were common ophthalmologic findings whereas cataract and glaucoma were less common (Creavin & Brown, 2009). A pattern reversal VEP study demonstrated significantly longer P100 latency and smaller amplitude in DS patients (16/36 cases) as compared to age-matched controls (Kakigi et al., 1993). By employing achromatic transient VEP, children with DS had small or undetectable N75 but normal latency as compared to normal developing children (Suttle & Turner, 2004). Patients with DS also responded abnormally to chromatic transient VEP (Suttle & Lloyd, 2005). As far as we are aware, there has been no current report about RNFL measurement in DS eyes.

### **3. Hypotheses to explain RNFL thinning in AD**

Three hypotheses to explain retinal ganglion cell fibre damage in AD have been proposed.

### 3.1 Is the retina affected by AD pathology directly?

AD pathology might develop not only in the cortex but also in the retina, perhaps in the ganglion cell layer (Lu et al., 2010). Beta amyloid, amyloid associated proteins, tau and amyloid precursor protein are expressed in the human retina at the level of ganglion cells and fibres in older eyes and in the retinal pigment epithelium in retinitis pigmentosa and age-related macular degeneration (Löffler et al., 1995). However neurofibrillary tangles, senile plaques, and amyloid angiopathy have not been identified in the retina even in association with extensive neuronal loss (Leuba & Kraftsik, 1994; Blanks et al., 1989, 1996b). A further study identified neither neurofibrillary degeneration nor amyloid angiopathy in AD patients' retinas (Hinton et al., 1986). Glial fibrillary acidic protein (GFAP) localized to Muller cells and astrocytes in the GCL is increased in AD eyes; as is found in retinal injuries and in the AD brain (Blanks et al., 1996b). It indicates that the retinal degeneration is accompanied by a glial response as GFAP is a major cytoskeletal component of astrocytes (Blanks et al., 1996b). Amyloid beta or Abeta deposition was found mainly in the outer and inner plexiform layer in the retina of the APP<sup>swe</sup>/PS1<sup>DeltaE9</sup> transgenic (tg) mouse model of Alzheimer disease (Perez et al., 2009). Likewise, Abeta plaques with increased retinal microvascular deposition of Abeta and neuroinflammation in Tg2576 mouse retinas were detected chiefly from the GCL to the inner plexiform layer and some plaques were also identified in the outer nuclear layer, the photoreceptor layer, and the optic nerve (Liu et al., 2009). Abeta deposits reduced with abeta vaccinations (Liu et al., 2009). Hyperphosphorylated tau was demonstrated in areas adjacent to the plaques (Liu et al., 2009). Furthermore, abeta deposition was observed in the cytosol of lens fibre cells along with equatorial supranuclear cataracts in AD patients as compared to age-matched controls (Goldstein et al., 2003). No supranuclear cataracts were identified in any normal individual in this study (Goldstein et al., 2003). Like AD, an evaluation of lens in patients with Down syndrome revealed supranuclear opacification with accelerated supranuclear abeta accumulation (Moncaster et al., 2010).

### 3.2 AD and glaucoma

Wostyn has proposed a link between glaucoma and AD suggesting that an abnormal high trans-lamina cribrosa pressure difference in AD eyes has led to glaucomatous optic neuropathy (Wostyn et al., 2009). Glaucoma is characterized by a progressive loss of RNFL and a resulting visual field defect. Elevated IOP is a strong risk factor but not all patients with glaucoma have high IOP (Johanson et al., 2008; Berdahl et al., 2008b). The subgroup is classified as normal tension glaucoma (NTG) (Johanson et al., 2008). The retinal ganglion cell fibres in NTG eyes might be vulnerable to normal IOP as it is relatively high in the NTG eyes. The cause of NTG is still unknown. Recent studies have revealed that AD patients may have a higher risk of developing glaucoma than normal subjects (Bayer et al., 2002a; Tamura, 2006) and that glaucoma in AD patients tends to be more progressive than glaucoma in non-AD cases (Bayer & Ferrari, 2002b). A case control study (Chandra et al., 1986), investigating all death certificates (1,930,627) for the United States in 1978, compared 7195 cases who had senile and presenile dementia as the cause of death with other patients who died from other conditions. Glaucoma was associated with these demented patients with odd ratio of 2.6. Early RNFL loss in glaucoma occurs in the temporal inferior and temporal superior regions (Hoyt et al., 1973; Pederson & Anderson, 1980; Tuulonen &

Airaksinen, 1991; Jonas et al., 1993) as found in some of the AD studies described above. Trans-lamina cribrosa pressure differences may have resulted in the glaucomatous like RNFL changes. A study (Jonas et al., 2003) revealed that lamina cribrosa forms a barrier between the intraocular space and retrobulbar space. The lamina cribrosa has been found to be thinner in glaucomatous eyes than in control eyes (Fig.2). The outer part of the cribrosa that is directly in contact with pia mater or indirectly with cerebrospinal fluid (CSF) was significantly thinner in the glaucomatous eyes as compared to the controls, and the shortest distance between the intraocular space and the CSF space was significantly less in the glaucoma patients. The optic disc is situated close to this area. Trans-lamina cribrosa pressure (the pressure gradient across the lamina cribrosa) is derived from the intraocular pressure minus the retrobulbar CSF pressure (Jonas et al., 2003). Normally the intraocular pressure is higher than that in the CSF. Abnormal pressure from either side of the lamina cribrosa may be involved in the pathogenesis of several ocular and neurological conditions. In vivo, high IOP glaucoma can damage the optic nerve head and very low IOP can cause swollen discs.

Reduced ICP in patients with normal tension glaucoma (NTG) could cause abnormal trans-lamina cribrosa pressure (Berdahl et al., 2008a). Trans-lamina cribrosa pressure was significantly greater in patients with primary open angle glaucoma (POAG) and NTG than in normal individuals (Ren et al., 2010). CSF pressure in severe AD patients tends to be disproportionately low (Silverberg et al., 2006) and therefore may create a situation where there is relatively high IOP in their eyes (still within a normal reference range). Glaucomatous-like RNFL changes may then be expected to occur. There is evidence of choroid plexus (CP) degeneration in AD brains and their CSF production is affected (Serot et al., 2003). The choroid plexus consists of villi covered by a single layer of ciliated cuboidal epithelium and extends through the lateral, 3<sup>rd</sup>, and 4<sup>th</sup> ventricles, acting as a blood-CSF barrier (Serot et al., 2003). It is contiguous with ependyma; produces CSF; synthesizes several molecules; and carries nutrients from blood to the CSF (Serot et al., 2003; Silverberg, et al., 2001). Two-thirds of the CSF secretion is derived from the CPs, the remainder coming from brain interstitial fluid drainage, which is produced by the capillary-astrocyte complex found in the blood brain barrier (Johanson et al., 2008). The production rate of the blood-CSF barrier is substantially greater than that of the blood brain barrier (Johanson et al., 2008). Another source of CSF production is likely to be ependyma lining the ventricles (Pollay & Curl, 1967). CSF reabsorption (Johanson et al., 2008) occurs along sleeves of subarachnoid spaces surrounding cranial nerves that enter the nose and eyes; through the cribriform plate, nasal mucosa, and cervical lymphatic system eventually. CSF is also drained along spinal nerve arachnoid pathways. Arachnoid villi in the dural sinuses absorb the CSF when ICP is elevated. CSF pressure (Johanson et al., 2008) is normally higher than venous pressure in the dural sinuses. It is steady when CSF formation and reabsorption are balanced. CSF pressure measured by lumbar puncture in a lateral recumbent position is directly proportional to CSF production rate and outflow resistance. CSF pressure is determined by hydrodynamic and haemodynamic parameters. Regarding hydrodynamic factors, reduced CSF production or increased outflow resistance will decrease CSF pressure. In ageing the CP epithelium becomes atrophic; its basement membrane thickens; and CSF secretion decreases by 50% (Serot et al., 2003). These changes in AD choroid plexuses appear more pronounced than in



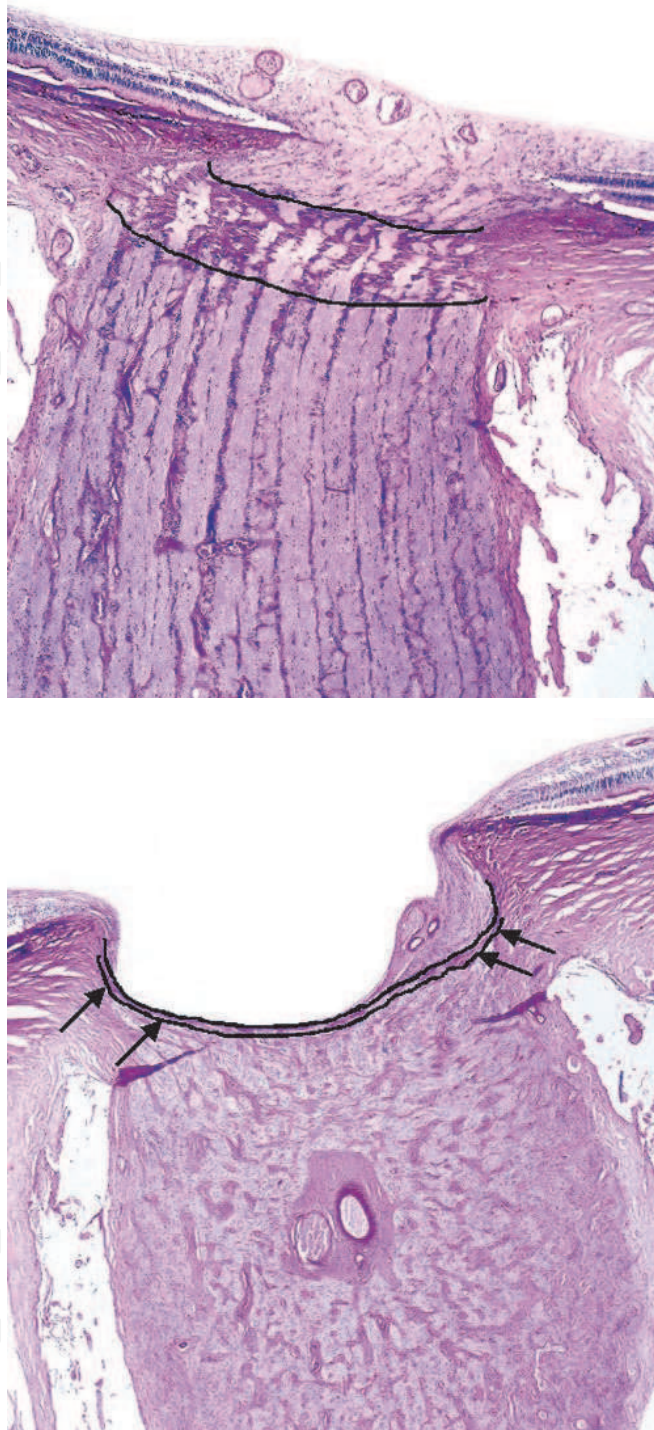


Fig. 2. Top: histological section of the optic disc in a non-glaucomatous eye; bottom: histological section of the optic disc in a glaucomatous eye (periodic acid Schiff staining). Arrows: regions in the posterior lamina cribrosa in direct contact with pia mater and indirectly exposed to the CSF space. The lamina cribrosa is outlined in black lines and was thinner with greater posterior bowing in the glaucoma than the controls (Jonas, Berenshtein, & Holbach, Anatomic Relationship between Lamina Cribrosa, Intraocular Space, and Cerebrospinal Fluid Space, 2003). Permission to reproduce the figures has been granted by Investigative Ophthalmology and Visual Science.

normal ageing and additionally stroma fibrosis has also been demonstrated in AD (Serot et al., 2003). Abeta proteins have been detected in the choroid plexus in AD brain (Kalaria et al., 1996). Ig and C1q depositions are frequently found along the basement membrane of the plexus in AD brains, suggestive of immunological processes in this location (Serot et al., 2003). As a consequence the choroid plexus cannot function normally (Serot et al., 2003). In young adults, the CSF production rate is 0.4 ml/min or 500 – 600 ml per day, the CSF volume is 150 ml, and the CSF turnover rate is 4 volumes per day (Johanson et al., 2008). In AD patients, on the contrary, the CSF production rate is 0.2 ml/min, the CSF volume is 250 ml due to brain atrophy, and the CSF turnover rate is 1.2 volumes per day (Johanson et al., 2008). In addition to the affected CSF production, the resistance of CSF outflow in AD is becoming greater for there is evidence of abeta depositions in the meninges (Silverberg et al., 2003; Hamano et al., 1997; Kalaria et al., 1996). Further studies are needed to confirm low CSF pressure in AD patients; to establish a relationship between the severity of cognitive impairment, brain atrophy, ventricular volume, CP morphology with CSF pressure; and to establish whether the trans-laminar cribrosa pressure difference plays an important role in the pathogenesis of RNFL thinning in AD.

### **3.3 Retrograde trans-synaptic degeneration secondary to cortical pathology**

Lastly, we hypothesize that the RGC loss in AD could be partly due to retrograde trans-synaptic degeneration. RGC loss following an occipital injury, which is a consequence of retrograde trans-synaptic degeneration of geniculate-cortical towards retino-geniculate pathways; and anterograde degeneration of cortico-geniculate pathway, has been identified in the visual pathway (Cowey, 1974; Mehta & Plant, 2005b; Jindahra et al., 2009; Bridge et al., 2011). Neuronal loss, neurofibrillary tangles (NFT) and senile plaques have been identified in several neocortex areas including primary visual cortex (Pearson et al., 1985; Leuba & Kraftsik, 1994). Senile plaques were also identified in the LGN (Leuba & Kraftsik, 1994; Leuba & Saini, 1995) along with NFTs and degenerating axons or threads in the white matter underlying area 17 (Leuba & Saini, 1993; Leuba & Saini, 1995), reflecting a spread of the degeneration along the cortico-geniculate axons (Leuba & Kraftsik, 1994; Leuba & Saini, 1995). In a study (Leuba & Saini, 1995), senile plaques were found more in the parvocellular layer of the dLGN than the magnocellular layer, the interlaminar zones, and the optic radiation. No neuritic degeneration (NFT, neuritic plaque, and thread) was demonstrated in the LGN in this study, suggesting mainly amyloid deposition in this area. The finding was in good agreement with another that showed mild tau pathology in the LGN of AD patients (Dugger et al., 2011). In addition, senile plaques and NFTs were detected in the pyramidal and non-pyramidal cells in layer 5 and 6 of the primary visual cortex (Leuba & Saini, 1995). The degeneration in the visual cortex varied greatly among individuals possibly due to different AD subtypes as presented below. Neuronal loss, glial cell proliferation, NFT, and neuritic plaque (NP) deposition have been demonstrated in visual cortex, area 17 in particular, in AD patients with mean age of 76.1 +/- 8.1 years when compared with age-matched controls (Leuba & Kraftsik, 1994). The tangles in layer 5 are twice in number as in layer 3 in the occipital lobe except area 18 and the neuritic plaques are found in all layers in one study (Pearson et al., 1985). In a study (Hof et al., 1989), AD patients with Balint syndrome which is characterized by optic apraxia (impairment of target pointing under visual guidance), ocular apraxia (inability to shift gaze to a new visual target), and

simultagnosia (perception and recognition in a small part of visual field) had greater NFT density and NP area in all cortical layers of area 17 and 18 as compared to AD patients without Balint syndrome. The NFT density in the superior frontal cortex of AD with Balint syndrome appeared much less than that in AD without Balint syndrome. Patients with Balint syndrome from stroke did not show NFT or high NP numbers in the visual cortex. The mean number of Meynert cells in layer 5 and 6 of area 17 in AD with Balint syndrome was significantly lower than that in AD without Balint syndrome. This study suggested a disruption of occipito-parietal connections or dorsal stream in these AD with Balint syndrome cases. Another study used SMI32-immunoreactive staining technique which represented pyramidal neurons in a small subset of total neuronal population (Hof & Morrison, 1990). It had been shown that the Meynert cell (the largest SMI32-ir neurons) counts in area 17 and 18 were significantly lower in AD patients than in age-matched controls only in a small magnitude. The loss appeared more pronounced in temporal and prefrontal cortices. The neuronal loss was confined to area 4b in area 17 and layer 3, 6 in area 18. The findings might have indicated the degeneration of projections of Meynert cells in these regions to area V5 that is responsible for visuospatial skills. NFT in area 17 and 18 were less numerous than area 9 and 20 in AD patients (Hof & Morrison, 1990). NFT were dominant in layer 2-3 in the visual cortices whereas in layer 5 in area 9 and 20. NP were numerous in layer 2-4 with the greatest density in layer 4 of area 17 in layer 2-3 in area 18. A study (Arnold et al., 1991) revealed the distribution of NFT and NP among 39 cortical regions in 11 AD patients, having mean age 80.2 years (range 63-88 years) and mean duration of disease 7.5 years (range 3-15 years). It had been shown that NFT in the limbic and temporal lobes were substantially higher than the frontal, parietal, and occipital lobes. NPs were evenly distributed throughout the cortex with the highest density in the temporal and occipital lobes. When comparing NFT among visual cortices namely area 17, 18, and 20 (inferior temporal gyrus) in 8 AD patients aged 48-82 years, the number of NFT was low in area 17 but progressively increased in area 18 and 20 respectively, which paralleled to the hierarchical visual organization (Lewis et al., 1987). NFTs were found predominantly in layer 3 and 5, which contained cortico-cortical and cortico-fugal projecting fibres (Lewis et al., 1987). A substantial number of NPs was identified equally in all three regions. They were present across all cortical layers (Lewis et al., 1987). A study (Kiyosawa et al., 1989) of AD patients with and without impaired visual functions i.e., figure copying, colour vision tested by isochromatic plates, and stereopsis showed no change in their primary visual cortices in 18F-fluoro-2-deoxyglucose positron emission tomography (PET) as compared to the results in age-matched controls. Additionally AD cases with impaired visual functions showed significantly decreased glucose metabolism in visual association and inferior parietal areas compared with the controls. AD patients with good vision showed no significant change in these areas. No neuronal loss in area 17 of AD brains was demonstrated in another study (Mountjoy et al., 1983).

#### 4. Conclusion

There is increasing evidence of RNFL thinning or RGC loss in patients with AD but the relationship between the degree of cognitive impairment and the degree of RNFL loss has not been established yet. There are a few possibilities that could explain the findings. These

include AD change in the retina, abnormal trans-lamina cribrosa pressure, and retrograde trans-synaptic degeneration. The degenerative changes in the brain and retina vary among AD patients because of different AD subtype, severity, and duration. It seems that the RNFL measurement has a good potential to be a monitoring tool in AD patients in the near future. Further investigations are required to understand more about AD pathology in these areas.

## 5. References

- Arnold, S.E., Hyman, B.T., Flory, J., Damasio, A.R., & Van Hoesen, G.W. (1991). The Topographical and Neuroanatomical Distribution of Neurofibrillary Tangles and Neuritic Plaques in the Cerebral Cortex of Patients with Alzheimer's Disease. *Cereb Cortex*, 1, 103-116.
- Bayer, A.U., Ferrari, F., & Erb, C. (2002a). High occurrence rate of glaucoma among patients with Alzheimer's disease. *Eur Neuro*, 47, 165-168.
- Bayer, A.U., & Ferrari, F. (2002b). Severe progression of glaucomatous optic neuropathy in patients with Alzheimer's disease. *Eye*, 16, 209-212.
- Berdahl, J.P., Fautsch, M.P., Stinnett, S.S., & Allingham, R.R. (2008a). Intracranial pressure in open angle glaucoma, normal tension glaucoma, and ocular hypertension: a case control study. *Invest Ophthalmol Vis Sci*, 49, 5412-5418.
- Berdahl, J.P., Allingham, R.R., & Johnson, D.H. (2008b). Cerebrospinal fluid pressure is in primary open-angle glaucoma. *Ophthalmology*, 115, 763-768.
- Berisha, F., Feke, G.T., Trempe, C.L., McMeel, J.W., & Schepens, C.L. (2007). Retinal abnormalities in early Alzheimer's disease. *Invest Ophthalmol Vis Sci*, 48, 2285-2289.
- Blanks, J.C., Hinton, D.R., Sadun, A.A., & Miller, C.A. (1989). Retinal ganglion cell degeneration in Alzheimer's disease. *Brain Res*, 501, 364-372.
- Blanks, J.C., Torigoe, Y., Hinton, D.R., & Blanks, R.H. (1996a). Retinal pathology in Alzheimer's disease. I. Ganglion cell loss in foveal/parafoveal retina. *Neurobiol Aging*, 17, 377-384.
- Blanks, J.C., Schmidt, S.Y., Torigoe, Y., Porrello, K.V., Hinton, D.R., & Blanks, R.H. (1996b). Retinal pathology in Alzheimer's disease. II. Regional neuron loss and glial changes in GCL. *Neurobiol Aging*, 17, 385-395.
- Bridge, H., Jindahra, P., Barbur, J., & Plant, G.T. (2011). Imaging reveals optic tract degeneration in hemianopia. *Invest Ophthalmol Vis Sci*, 52, 382-388.
- Chandra, V., Bharucha, N.E., Schoenberg, B.S. (1986). Conditions associated with Alzheimer's disease at death: Case-control study. *Neurology*, 36, 209-211.
- Coburn, K.L., Arruda, J.E., Estes, K.M., & Amoss, R.T. (2003). Diagnostic utility of visual evoked potential changes in Alzheimer's disease. *J Neuropsychiatry Clin Neurosci*, 15, 175-179.
- Cowey, A. (1974). Atrophy of retinal ganglion cells after removal of striate cortex in a rhesus monkey. *Perception*, 3, 257-260.
- Creavin, A.L., Brown, R.D. (2009). Ophthalmic abnormalities in children with Down syndrome. *J Pediatr Ophthalmol Strabismus*, 46, 76-82
- Crow, R.W., Levin, L.B., LaBree, L., Rubin, R., & Feldon, S.E. (2003). Sweep Visual Evoked Potential Evaluation of Contrast Sensitivity in Alzheimer's Dementia. *Invest Ophthalmol Vis Sci*, 44, 875-878.

- Curcio, C.A., & Drucker, D.N. (1993). Retinal ganglion cells in Alzheimer's disease and aging. *Ann Neurol*, 33, 248-257.
- Danesh-Meyer, H.V., Birch, H., Ku, J.Y., Carroll, S., Gamble, G. (2006). Reduction of optic nerve fibers in patients with Alzheimer disease identified by laser imaging. *Neurology*, 28, 1852-1854.
- Davies, D.C., McCoubrie, P., McDonald, B., & Jobst, K.A. (1995). Myelinated axon number in the optic nerve is unaffected by Alzheimer's disease. *Br J Ophthalmol*, 79, 596-600.
- Dugger, B.N., Tu, M., Murray, M.E., & Dickson, D.W. (2011). Disease specificity and pathologic progression of tau pathology in brainstem nuclei of Alzheimer's disease and progressive supranuclear palsy. *Neurosci Lett*, 491, 122-126.
- Goldgaber, D., Lerman, M.I., McBride, W.O., Saffiotti, U., Gajdusek, D.C (1987). Isolation, characterization, and chromosomal localization of human brain cDNA clones coding for the precursor of the amyloid of brain in Alzheimer's disease. Down's syndrome and aging. *J Neural Transm*, Suppl 24, 23-28.
- Goldstein, L., Muffat, J., Cherny, R., Moir, R., Ericsson, M., Huang, X., Mavros, C; Coccia, J.A., Faget, K.Y., Fitch, K.A., Masters, C.L., Tanzi, R.E, Chylack, L.T., Bush, A.I. (2003). Cytosolic  $\beta$ -amyloid deposition and supranuclear cataracts in lenses from people with Alzheimer's disease. *Lancet*, 361, 1258-1265.
- Hamano, T., Yoshimura, M., Yamazaki, T., Shinkai Y, Yanagisawa K, Kuriyama M, Ihara Y. (1997). Amyloid beta protein (A beta) accumulation in the leptomeninges during aging and in Alzheimer's Disease. *Neuropathol Exp Neurol*, 56, 922-932.
- Hedges, T.R. 3rd, Perez Galves, R., Speigelman, D., Barbas, N.R., Peli, E., & Yardley, C.J. (1996). Retinal nerve fiber layer abnormalities in Alzheimer's disease. *Acta Ophthalmol Scand*, 74, 271-275.
- Hinton, D. R., Sadun, A. A., Blanks, J. C., & Miller, C. A. (1986). Optic nerve degeneration in Alzheimer's disease. *N Engl J Med*, 315, 485-487.
- Hof, P.R., Bouras, C., Perl, D.P., Sparks, D.L., Mehta, N., Morrison, J.H (1995). Age-related distribution of neuropathologic changes in the cerebral cortex of patients with Down's syndrome: quantitative regional analysis and comparison with Alzheimer's disease. *Arch Neurol*, 52, 379-391.
- Hof, P.R., & Morrison, J.H. (1990). Quantitative analysis of a vulnerable subset of pyramidal neurons in Alzheimer's disease: II. Primary and secondary visual cortex. *J Comp Neuro*, 301, 55-64.
- Hof, P.R., Bouras, C., Constantinidis, J., & Morrison, J.H. (1989). Balint's syndrome in Alzheimer's disease: specific disruption of the occipito-parietal visual pathway. *Brain Res*, 493, 368-375.
- Hoyt, W.F., Frisen, L., & Newman, N.M. (1973). Fundoscopy of nerve fiber layer defects in glaucoma. *Invest Ophthalmol Vis Sci*, 12, 814-829.
- Iseri, P., Altinas, O., Tokay, T., & Yuksel, N. (2006). Relationship between cognitive impairment and retinal morphological and visual functional abnormalities in Alzheimer disease. *J Neuroophthalmol*, 26, 18-24.
- Jindahra, P., Petrie, A., & Plant, G. T. (2009). Retrograde trans-synaptic retinal ganglion cell loss identified by optical coherence tomography. *Brain*, 312, 628-634.

- Johanson, C.E., Duncan, J. A., Klinge, P.M., Brinker, T., Stopa, E.G., & Silverberg, G.D. (2008). Multiplicity of cerebrospinal fluid functions: new challenges in health and disease. *Cerebro Spinal Fluid Research*, 5, 10.
- Jonas, J.B., Berenshtein, E., & Holbach, L. (2003). Anatomic relationship between lamina cribrosa, intraocular Space, and cerebrospinal fluid space. *Invest Ophthalmol Vis Sci*, 44, 5189-5195.
- Jonas, J.B, Fernandez, M.C., & Stürmer, J. (1993). Pattern of glaucomatous neuroretinal rim loss. *Ophthalmology*, 100, 63-68.
- Justino, L., Kergoat, M., Bergman, H., Chertkow, H., Robillard, A., & Kergoat, H. (2001). Neuroretinal function is normal in early dementia of the Alzheimer type. *Neurobiology Aging*, 22, 691-695.
- Kakigi, R. Oono S, Matsuda Y, Kuroda Y. (1993). Pattern-reversal visual evoked potential in Down's syndrome. *Acta Neurol Scand*, 87, 410-415.
- Kalaria, R.N., Premkumar, D.R., Pax, A.B., Cohen, D.L., & Lieberburg, I. (1996). Production and increased detection of amyloid beta protein and amyloidogenic fragments in brain microvessels meningeal vessels and choroid plexus in Alzheimer's disease. *Res Mol Brain Res*, 35, 58-68.
- Kergoat, H., Kergoat, M., Justino, L., Chertkow, H., Robinllard, A., & Bergman, H. (2002). Visual retinocortical function in dementia of the Alzheimer type. *Gerontology*, 48, 197-203.
- Kergoat, H., Kergoat, M., Justino, L., Chertkow, H., Robillard, A., & Bergman, H. (2001). An evaluation of the retinal nerve fiber layer thickness by scanning laser polarimetry in individuals with dementia of the Alzheimer type. *Acta Ophthal Scand*, 79, 187-191.
- Kiyosawa, M., Bosley, T., Chawluk, J., Jamieson, D., Schatz, N., Savino, P.J., Sergott, R.C., Reivich, M., Alavi, A. (1989). Alzheimer's disease with prominent visual symptoms. Clinical and metabolic evaluation. *Ophthalmology*, 96, 1077-1085.
- Krasodomska, K., Lubiński, W., Potemkowski, A., & Honczarenko, K. (2010). Pattern electroretinogram (PERG) and pattern visual evoked potential (PVEP) in the early stages of Alzheimer's disease. *Doc Ophthalmol*, 121, 111-21.
- Leuba, G., & Kraftsik, R. (1994). Visual cortex in Alzheimer's disease: Occurrence of neuronal death and glial proliferation, and correlation with pathological hallmarks. *Neurobiol Aging*, 15, 29-43.
- Leuba, G., & Saini, K. (1993). Involvement of the visual thalamus in Alzheimer's disease. In: *Alzheimer's disease: Advances in clinical and basic research*, Corain, B., Iqbal, K., Nicolini, M., Winbtad, B., Wisniewski, H., & Zatta, P., 139-149, Wiley, England.
- Leuba, G., & Saini, K. (1995). Pathology of subcortical visual centres in relation to cortical degeneration in Alzheimer's disease. *Neuropathol Appl Neurobiol*, 21, 410-422.
- Lewis, D.W., Campbell, M.J., Terry, R.D., & Morrison, J.H. (1987). Laminar and Regional Distributions of Neurofibrillary Tangles and Neuritic Plaques in Alzheimer's Disease: A Quantitative Study of Visual and Auditory Cortices. *J Neurosci*, 7, 1799-1808.
- Liu, B., Rasool, S., Yang, Z., Glabe, C.G., Schreiber, S.S., Ge, J., & Tan, Z. (2009). Amyloid-peptide vaccinations reduce {beta}-amyloid plaques but exacerbate vascular

- deposition and inflammation in the retina of Alzheimer's transgenic mice. *Am J Pathol*, 175, 2099-2110.
- Löffler, K.U., Edward, D.P., & Tso, M.O. (1995). Immunoreactivity against tau, amyloid precursor protein, and beta-amyloid in the human retina. *Invest Ophthalmol Vis Sci*, 36, 24-31.
- Lu, Y., Li, Z., Zhang, X., Ming, B., Jia, J., Wang, R., Ma, D (2010). Retinal nerve fiber layer structure abnormalities in early Alzheimer's disease: evidence in optical coherence tomography. *Neurosci Lett*, 480, 69-72.
- Mashima, Y., Oshitari, K., Imamura, Y., Momoshima, S., Shiga, H., & Oguchi, Y. (1996). High-resolution magnetic resonance imaging of the intraorbital optic nerve and subarachnoid space in patients with papilledema and optic atrophy. *Arch Ophthalmol*, 114, 1197-1203.
- Mehta, J.S, & Plant, G.T. (2005b). Optical coherence tomography findings in congenital/longstanding homonymous hemianopia. *Am J Ophthalmol*, 140, 727-729.
- Miller, N.R. (1990). Alzheimer's disease, optic neuropathy, and selective ganglion cell damage. *Ophthalmology*, 97, 7-8.
- Malamud, N. (1972). Neuropathology of organic brain syndromes associated with aging. In: *Aging Brain*, Gaitz, C.M., 63-87, Plenum, New York.
- Moncaster, J.A., Pineda, R., Moir, R.D., Lu, S., Burton, M.A., Ghosh, J.G., Ericsson, M., Soscia, S.J., Mocofanescu, A., Folkert, R.D., Robb, R.M., Kuszak, J.R., Clark, J.I., Tanzi, R.E., Hunter, D.G., Goldstein, L.E. (2010). Alzheimer's disease amyloid-beta links lens and brain pathology in Down syndrome. *PLoS One*, 5, e10659, 1-13.
- Moore, N.C., Tucker, K.A., Jann, M.W., Hostetler, R.M., & Coburn, K.L. (1995). Flash P2 delay in primary degenerative dementia of the Alzheimer type. *Prog Neuropsychopharmacol Biol Psychiatry*, 19, 403-410
- Mountjoy, C.Q., Roth, M., Evans, N.J., & Evans, H.M. (1983). Cortical neuronal counts in normal elderly controls and demented patients. *Neurobiol Aging*, 4, 1-11.
- Paquet, C., Boissonnot, M., Roger, F., Dighiero, P., Gil, R., & Hugon, J. (2007). Abnormal retinal thickness in patients with mild cognitive impairment and Alzheimer's disease. *Neurosci Lett*, 420, 97-99.
- Parisi, V. (2003). Correlation between morphological and functional retinal impairment in patients affected by ocular hypertension, glaucoma, demyelinating optic neuritis and Alzheimer's disease. *Seminars in Ophthalmol*, 18, 50-57.
- Parisi, V., Restuccia, R., Fattapposta, F., Mina, C., Bucci, M.G., & Pierelli, F. (2001). Morphological and functional retinal impairment in Alzheimer's disease patients. *Clin Neurophysiol*, 112, 1860-1867.
- Pasquale, L.R. (2008). Low intracranial pressure: A tipping point in our understanding of primary open-angle glaucoma? *Ophthalmology*, 115, 761-762.
- Pearson, R.C., Esiri, M.M., Hiorns, R.W., Wilcock, G.K., & Powell, T.P. (1985). Anatomical correlates of the distribution of the pathological changes in the neocortex in Alzheimer disease. *Proc Natl Acad Sci USA*, 82, 4531-4534.
- Pederson, J.E., & Anderson, D.R. (1980). The mode of progressive disc cupping in ocular hypertension and glaucoma. *Arch Ophthalmol*, 98, 490-495.


- Perez, S.E., Lumayag, S., Kovacs, B., Mufson, E.J., & Xu, S. (2009). Beta-amyloid deposition and functional impairment in the retina of the APP<sup>swe</sup>/PS1<sup>DeltaE9</sup> transgenic mouse model of Alzheimer's disease. *Invest Ophthalmol Vis Sci*, 50, 793-800.
- Pollay, M., & Curl, F. (1967). Secretion of cerebrospinal fluid by the ventricular ependyma of the rabbit. *Am J Physiol*, 213, 1031-1038.
- Prasher, V.P., Farrer, M.J., Kessling, A.M., Fisher EM, West RJ, Barber PC, Butler AC. (1998). Molecular mapping of Alzheimer-type dementia in Down's syndrome. *Ann Neurol*, 43, 380-383.
- Ren, R., Jonas, J.B., Tian, G., Zhen, Y., Ma, K., Li, S., Wang, H., Li, B., Zhang, X., & Wang, N. (2010). Cerebrospinal fluid pressure in glaucoma: a prospective study. *Ophthalmology*, 117, 259-266.
- Rocco, F.J., Cronin-Golomb, A., Lai, F. (1997). Alzheimer-like visual deficits in Down syndrome. *Alzheimer Dis Assoc Disord*, 11, 88-98.
- Sadun, A.A., & Bassi, C.J. (1990). Optic nerve damage in Alzheimer's disease. *Ophthalmology*, 97, 9-17.
- Serot, J.M., Béné, M.C., & Faure, G.C. (2003). Choroid plexus, aging of the brain, and Alzheimer's disease. *Front Biosci*, 1, 515-521.
- Silverberg, G., Mayo, M., Saul, T., Fellmann, J., & McGuire, D. (2006). Elevated cerebrospinal fluid pressure in patients with Alzheimer's disease. *Cerebrospinal fluid research*, 3, 7.
- Silverberg, G.D., Heit, G., Huhn, S., Jaffe, R.A., Chang, S.D., Bronte-Stewart, H., Rubenstein, E., Possin, K., & Saul, T.A. (2001). The cerebrospinal fluid production rate is reduced in dementia of the Alzheimer's type. *Neurology*, 57, 1763-1766.
- Silverberg, G.D., Mayo, M., Saul, T., Rubenstein, E., & McGuire, D. (2003). Alzheimer's disease, normal-pressure hydrocephalus, and senescent changes in CSF circulatory physiology: a hypothesis. *Lancet Neurol*, 2, 506-511.
- Suttle, C.M., Turner, A.M. (2004). Transient visual evoked potentials in children with Down's syndrome. *Ophthal Physiol Opt*, 24, 91-99
- Suttle, C.M., Lloyd, R. (2005). Chromatic and achromatic transient VEPs in adults with Down syndrome. *Ophthal Physiol Opt*, 25, 501-513
- Tamura, H., Kawakami, H., Kanamoto, T., Kato, T., Yokoyama, T., Sasaki, K., Izumi, Y., Matsumoto, M., Mishima, H.K. (2006). High frequency of open-angle glaucoma in Japanese patients with Alzheimer's disease. *J Neurol Sci*, 246, 79-83.
- Trick, G.L., Barris, M.C., & Bickler-Bluth, M. (1989). Abnormal pattern electroretinograms in patients with senile dementia of the Alzheimer type. *Ann neurol*, 26, 226-231.
- Tsai, C.S., Ritch, R., Schwartz, B., Lee, S.S., Miller, N.R., Chi, T., & Hsieh, F.Y. (1991). Optic nerve head and nerve fiber layer in Alzheimer's disease. *Arch Ophthalmol*, 109, 199-204.
- Tuulonen, A., & Airaksinen, P.J. (1991). Initial glaucomatous optic disk and retinal nerve fiber layer abnormalities and their progression. *Am J Ophthalmol*, 111, 485-490.
- Valenti, D.A. (2007). Neuroimaging of retinal nerve fibre layer in AD using optical coherence tomography. *Neurology*, 69, 1060.
- Wostyn, P., Audenaert, K., & De Deyn, P.P. (2009). Alzheimer's disease and glaucoma: Is there a causal relationship? *Br J Ophthalmol*, 93, 1557-1559.



Wright, C.E., Harding, G.F., & Orwin, A. (1986). The flash and pattern VEP as a diagnostic indicator of dementia. *Doc Ophthalmol*, 62, 89-96.

IntechOpen

IntechOpen



## **The Clinical Spectrum of Alzheimer's Disease -The Charge Toward Comprehensive Diagnostic and Therapeutic Strategies**

Edited by Dr. Suzanne De La Monte

ISBN 978-953-307-993-6

Hard cover, 362 pages

**Publisher** InTech

**Published online** 06, September, 2011

**Published in print edition** September, 2011

The Clinical Spectrum of Alzheimer's Disease: The Charge Toward Comprehensive Diagnostic and Therapeutic Strategies is highly informative and current. Acknowledged experts in the field critically review both standard and under-appreciated clinical, behavioral, epidemiological, genetic, and neuroimaging attributes of Alzheimer's disease. The collection covers diverse topics of interest to clinicians and researchers alike. Experienced professionals and newcomers to the field will benefit from the read. The strengths and weaknesses of current clinical, non-invasive, neuro-imaging, and biomarker diagnostic approaches are explained. The perspectives give fresh insights into the process of neurodegeneration. Readers will be enlightened by the evidence that the neural circuits damaged by neurodegeneration are much broader than conventionally taught, suggesting that Alzheimer's could be detected at earlier stages of disease by utilizing multi-pronged diagnostic approaches. This book inspires renewed hope that more effective treatments could be developed based upon the expanding list of potential therapeutic targets.

### **How to reference**

In order to correctly reference this scholarly work, feel free to copy and paste the following:

Panitha Jindahra and Gordon T Plant (2011). Retinal Nerve Fibre Layer Thinning in Alzheimer Disease, The Clinical Spectrum of Alzheimer's Disease -The Charge Toward Comprehensive Diagnostic and Therapeutic Strategies, Dr. Suzanne De La Monte (Ed.), ISBN: 978-953-307-993-6, InTech, Available from: <http://www.intechopen.com/books/the-clinical-spectrum-of-alzheimer-s-disease-the-charge-toward-comprehensive-diagnostic-and-therapeutic-strategies/retinal-nerve-fibre-layer-thinning-in-alzheimer-disease>

**INTECH**  
open science | open minds

### **InTech Europe**

University Campus STeP Ri  
Slavka Krautzeka 83/A  
51000 Rijeka, Croatia  
Phone: +385 (51) 770 447  
Fax: +385 (51) 686 166  
[www.intechopen.com](http://www.intechopen.com)

### **InTech China**

Unit 405, Office Block, Hotel Equatorial Shanghai  
No.65, Yan An Road (West), Shanghai, 200040, China  
中国上海市延安西路65号上海国际贵都大饭店办公楼405单元  
Phone: +86-21-62489820  
Fax: +86-21-62489821

© 2011 The Author(s). Licensee IntechOpen. This chapter is distributed under the terms of the [Creative Commons Attribution-NonCommercial-ShareAlike-3.0 License](#), which permits use, distribution and reproduction for non-commercial purposes, provided the original is properly cited and derivative works building on this content are distributed under the same license.

IntechOpen

IntechOpen