

We are IntechOpen, the world's leading publisher of Open Access books Built by scientists, for scientists

4,800

Open access books available

122,000

International authors and editors

135M

Downloads

Our authors are among the

154

Countries delivered to

TOP 1%

most cited scientists

12.2%

Contributors from top 500 universities



WEB OF SCIENCE™

Selection of our books indexed in the Book Citation Index
in Web of Science™ Core Collection (BKCI)

Interested in publishing with us?
Contact book.department@intechopen.com

Numbers displayed above are based on latest data collected.

For more information visit www.intechopen.com



The Clinical Use of SPECT and PET Molecular Imaging in Alzheimer's Disease

Varvara Valotassiou¹, Nikolaos Sifakis², John Papatriantafyllou³,
George Angelidis¹ and Panagiotis Georgoulas¹

¹Department of Nuclear Medicine, University Hospital of Larissa

²Department of Nuclear Medicine, "Alexandra" University Hospital

³Department of Neurology, General Hospital "G. Gennimatas"

Greece

1. Introduction

Single photon emission computed tomography (SPECT) and positron emission tomography (PET) are functional nuclear medicine techniques which allow for accurate non-invasive in vivo measurements of a wide range of regional tissue functions in man. Brain functional imaging with SPECT and PET is based on the recording of the distribution of administered radionuclides in three dimensions, thus producing maps of brain biochemical and physiological processes. SPECT and PET techniques are able to image brain perfusion and metabolism, as well as various neurotransmission or other cellular processes using specific radioligands which mark in vivo receptors, transporters or enzymes.

Brain SPECT and PET imaging - or molecular imaging -, has been applied to the study of Alzheimer's disease (AD) for over two decades. These functional neuroimaging approaches have the capability of identifying subtle pathophysiologic changes in the brain before structural changes are present (Xu et al., 2000). Therefore they possess greater potential for accurate and early diagnosis, monitoring disease progression, and better treatment follow-up. Furthermore, the application of SPECT and PET techniques to the study of AD has led to increased understanding of the underlying pathology and the disease processes and improved the differential diagnosis from other neurodegenerative causes of dementia.

2. Clinical applications of SPECT and PET molecular imaging in AD

2.1 Radiopharmaceuticals for SPECT and PET brain imaging

Brain SPECT and PET imaging is performed using radiopharmaceuticals which utilize the highly selective properties of Blood Brain Barrier (BBB). The intact BBB has been a significant limitation whenever a nuclear imaging technique is employed to study the function of the living human brain since it may impede brain uptake of radiotracers (Jolliet Riant & Tillement, 1999). The main factors which regulate passage across the BBB are ionic selectivity and lipid solubility of substances (Costa, 2004). Osmotic pressure and specific and non-specific binding to plasma proteins, cell membranes and other components present in the bloodstream, may also affect the permeability of BBB and brain uptake of the administered radiopharmaceuticals (Tanaka & Mizojiri, 1999). In the absence of radiotracer

binding to these metabolic (biological) barriers, free diffusion of lipophilic small neutral compounds occurs directly through the endothelial cells of BBB (Waterhouse, 2003).

2.1.1 Properties and mechanisms of brain uptake

Radiopharmaceuticals used for brain perfusion SPECT imaging are lipophilic and neutral compounds with limited protein binding, which penetrate freely the intact BBB by simple diffusion (Costa, 2004). They distribute in proportion to regional cerebral blood flow (rCBF) and remain trapped in neuronal tissue without redistribution for a suitable amount of time to permit SPECT imaging.

Brain perfusion SPECT radiopharmaceuticals are labeled with ^{99m}Tc which has excellent physical characteristics for imaging purposes and dosimetry and it is always available at a low cost.

^{99m}Tc -bicisate (ECD) and ^{99m}Tc -exametazime (HMPAO) are the most common radiopharmaceuticals used in routine clinical practice (Kung et al., 2003). They are both lipophilic and neutral tracer agents with suitable characteristics to pass the BBB by passive diffusion. ^{99m}Tc -bicisate (ECD) is retained in brain tissue after being hydrolysed to ionized non-diffusible metabolites by interaction with esterases in brain cells (Walovitch et al., 1994), while ^{99m}Tc -HMPAO is converted to one or more polar species by an assumed interaction with glutathione (Jacquier-Sarlin et al., 1996).

The PET radiopharmaceuticals are labeled with isotopes of elements that naturally occur in the various substrates (Newberg & Alavi, 2003). The most common radioisotopes used for labeling are ^{18}F and ^{11}C . ^{18}F labeled compounds have the advantage over ^{11}C labeled compounds of the longer half life of ^{18}F (110 min versus 20 min) which allows longer imaging protocols. The advantage of ^{11}C labeling is that, theoretically, any organic molecule could be labeled by isotopic substitution of ^{11}C for natural carbon, retaining the full properties of the parent molecule (Pimlott, 2005).

The most common application of PET in AD is the study of regional cerebral glucose metabolism (rCGM) and to a lesser extent the measurements of regional cerebral blood flow (rCBF) and oxygen metabolism, with the use of radiotracer concentrations in the picomolar range which rarely exerts any pharmacological or toxicological effect (Gee, 2003).

The radiofluorinated analogue ^{18}F -2-fluoro-2-deoxy-D-glucose (^{18}F -FDG) is used for brain glucose metabolism studies. ^{18}F -FDG is transported into the brain cells by facilitated diffusion, then phosphorylated to FDG-6- PO_4 and trapped intracellularly where it can be measured, without further metabolism (Newberg & Alavi, 2003). ^{15}O H_2O and $^{15}\text{O}_2$ are used for the measurement of rCBF and oxygen metabolism, respectively.

SPECT and PET receptor imaging radioligands are neutral and lipophilic compounds with high plasma clearance and low plasma protein binding, and the ability to pass the intact BBB by simple diffusion, while regional cerebral distribution reflect receptor density (Pimlott, 2005). Furthermore they perform high affinity and specificity and/or selectivity for the specific receptor of interest over other receptors, limited or measurable metabolism, low toxicity and good in-vitro stability (Wong & Pomper, 2003).

Although ^{99m}Tc has so far been incorporated in most SPECT imaging studies, a general problem with ^{99m}Tc complexes is the low brain uptake due to the large molecular weight of linking moieties required to radiolabel compounds with ^{99m}Tc (Johannsen & Pietzsch, 2002). The incorporation of the much smaller radioiodine into a radiotracer can increase brain uptake and currently most of the research studies on SPECT neuroreceptor brain imaging are performed using agents labeled with ^{123}I (Pimlott, 2005).

2.2 Imaging of brain perfusion and glucose metabolism in AD

A substantial number of rCBF and rCGM studies with SPECT and PET have been performed in AD patients as well as in other neurodegenerative disorders. These studies have demonstrated characteristic patterns of perfusion and metabolism abnormalities which distinguish AD from other types of dementia and supported the use of SPECT and PET imaging as biomarkers of AD for the detection of the underlying changes of perfusion and metabolism and monitoring disease progression and response to treatment. In general, there is a concordance between brain perfusion and metabolism deficits, exhibited on SPECT and PET studies, respectively.

Brain perfusion SPECT imaging in AD patients typically shows bilateral hypoperfusion of the parietal and posterior temporal lobes (Ichimya, 1998; Ishii et al., 1996; Lojkowska et al., 2002). The perfusion deficits are frequently symmetric but not necessarily of the same magnitude and severity. Motor and sensory cortices are usually spared. Hypoperfusion of the posterior association cortices is a finding that some authors consider specific for AD and positive evidence for its diagnosis, although other conditions may display a similar pattern (Hirao et al., 2006). Prospective studies with histological confirmation in demented patients and control cases have shown that the sensitivity and specificity of rCBF SPECT imaging for the differentiation of patients with AD from control subjects is 89% and 80%, respectively (Jobst et al., 1998). With progression of the disease, hypoperfusion spreads from the posterior to the anterior temporal and frontal lobes (Fig. 1) (Brown et al., 1996).

The pattern and degree of hypoperfusion have been correlated in many studies with the onset, the severity, the clinical features and the prognosis of the disease, although with contradictable results in several cases. Temporoparietal hypoperfusion has been shown to be more severe in early-onset than in late-onset AD (Weinstein et al., 1991). Late onset patients tend to present with the characteristic involvement of the medial temporal lobes producing marked memory loss whereas early onset patients present with predominant posterior cortical association area involvement (Kemp et al., 2003). The Mini Mental Examination scores in AD patients correlate with the rCBF in temporal and parietal regions (Rodriguez et al., 1999). Moreover, specific clinical symptoms that AD patients may present are associated with perfusion abnormalities in discrete cortical areas. The right middle medial temporal region emerged as an important neural correlate of aggression (Lanctôt et al., 2004); depressive symptoms were associated with relative hypoperfusion in the prefrontal cortex (Levy-Cooperman et al., 2008); a significant association was also found between anosognosia and decreased perfusion in the orbitofrontal cortex (Shibata et al., 2008); hypoperfusion in the inferior, medial and orbital frontal lobes as well as the anterior cingulate gyri were found to be associated with the lack of awareness in patients with early AD (Hanyu et al., 2008); apathetic AD patients performed hypoperfusion in the left anterior cingulate and right orbitofrontal cortex (Lanctôt et al., 2007); hypoperfusion in prefrontal cortex, anterior cingulate gyri, inferior to middle temporal cortices, and parietal cortex of the right hemisphere has been observed in AD patients with delusions (Nakano et al., 2006); finally, hypoperfusion in the left anterior cingulate and left orbitofrontal cortices, and relative sparing of perfusion in the right anterior cingulate, right orbitofrontal and left middle mesial temporal cortices emerged as predictors of appetite loss in AD patients (Ismail et al., 2008). Decreased blood flow in the frontal lobe of AD patients is correlated not only with reduced cognitive function at the time of the evaluation but with rapid progression in the subsequent clinical course, as well (Nishimura et al., 2007). Hypoperfusion in the left temporal region has been associated with lowering of the median

survival and higher death rates (Claus et al., 1999), though perfusion in the right parietal lobe has also found to be a significant predictor of survival in patients with AD (Jagust et al., 1998).

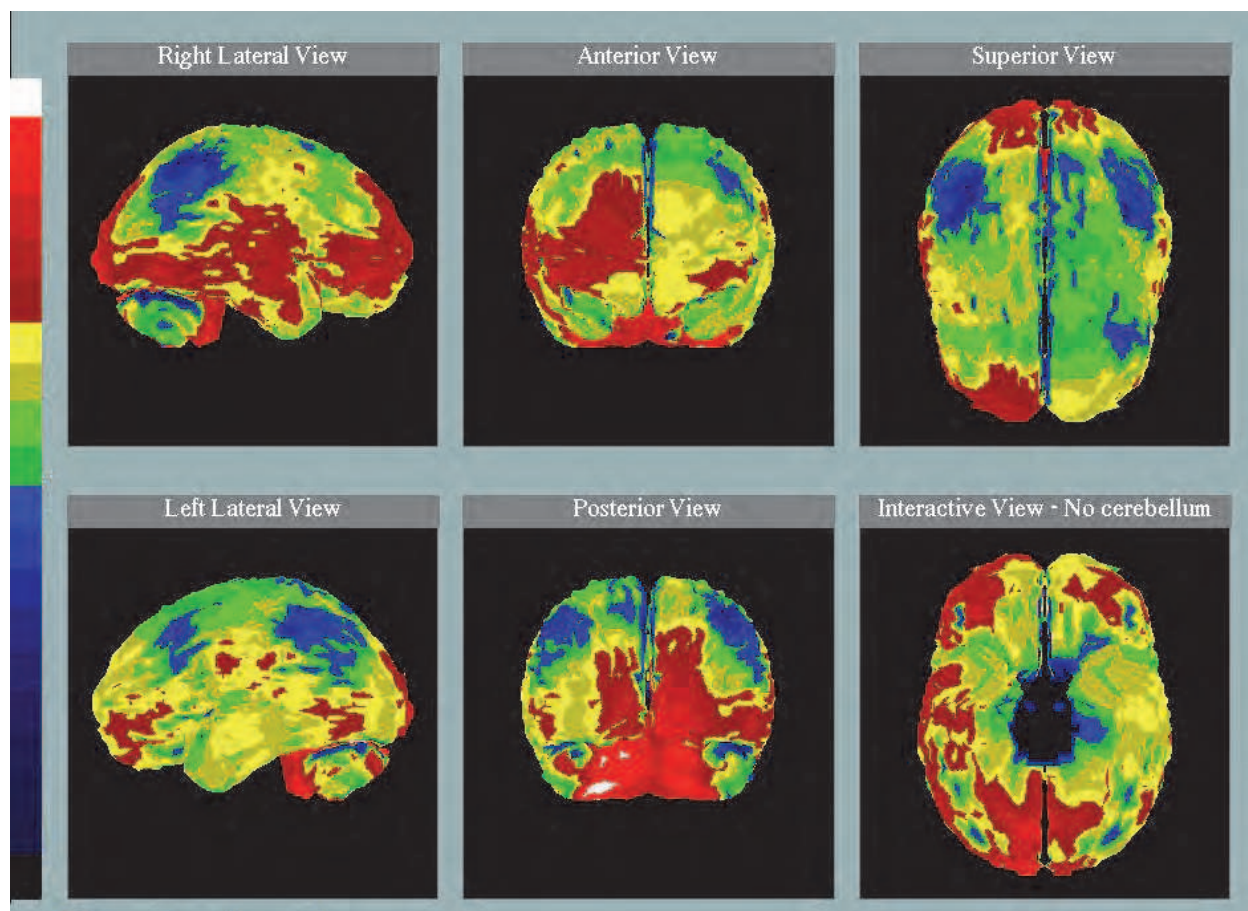


Fig. 1. Brain perfusion SPECT study in a patient with Alzheimer's disease. Reduced ^{99m}Tc -HMPAO uptake in parietal, temporal and frontal lobes. Hypoperfusion is more severe on the left hemisphere.

FDG PET studies in AD patients have demonstrated a typical pattern of reduced temporoparietal FDG uptake with sparing of the basal ganglia, thalamus and cerebellum (Coleman, 2005). Hypometabolism begins typically in the superior parietal cortex, then spreads inferiorly and anteriorly to involve the inferior parietal, superior temporal, and prefrontal cortices. The extent of hypometabolism correlates with the severity of cognitive impairment and often shows right/left hemispheric asymmetry (Haxby et al., 1990). More recent studies using higher resolution PET scanning have reported marked hypometabolism of the hippocampal head and amygdala in AD (Stein et al., 1998).

FDG PET demonstrated high sensitivity and specificity (94% and 73%, respectively) for detecting the presence of AD in histopathologically confirmed demented patients. In contrast, clinical evaluation without FDG PET showed lower sensitivity and specificity (83%-85% and 50%-55%, respectively), as determined by an entire series of evaluations repeated over a period of years (Silverman et al., 2002). Even early in the disease process, before the appearance of volume loss, FDG PET has been helpful in diagnosing AD, with a sensitivity and specificity of about 90%, irrespective of the degree of cognitive impairment

(Hoffman et al., 2000). It is the neuroimaging technique that has been shown to yield the highest prognostic value for providing a diagnosis of presymptomatic AD 2 years or more before the full dementia picture is manifested (Silverman et al. 2001). Thus, PET is able to measure cognitive decline at some of the earliest possible stages, providing evidence of its usefulness for early AD detection.

SPECT and FDG PET studies have also been applied in patients with mild cognitive impairment (MCI) in order to predict progression from MCI to AD. Reduced glucose metabolism in the inferior parietal cortex and hypoperfusion in the parahippocampus, lateral parietal and posterior cingulate in converters as compared with non-converters have been reported (Ishiwata et al., 2006; Mosconi et al., 2004). Longitudinal FDG PET and perfusion SPECT studies have shown that hypometabolism in the parietal association areas and hypoperfusion in the bilateral inferior parietal areas, angular gyrus and the precuneus had a high predictive value and discriminative ability of converters and non-converters, while hypometabolism in the posterior cingulate gyrus had a lower predictive value (Chetelat et al., 2003; Hirao et al., 2005). Combined baseline memory deficits and rCBF SPECT images identified pre-clinical AD with a sensitivity and specificity of 77.8% (Borroni et al., 2006). These SPECT and PET findings suggest that initial functional neuroimaging studies of individuals with MCI may be useful in predicting who will convert to AD in the near future.

2.3 Beta amyloid imaging

In the last years, the detection of senile plaques (SPs) and neurofibrillary tangles (NFTs) has been a target for nuclear molecular imaging in the field of AD. The development of radiotracers able to localize SPs and NFTs could be useful not only in the diagnosis of AD but also in the investigation of the temporal relationship between amyloid deposition, neuronal loss, and cognitive decline and assessment of the effects of drugs in disease progression. Also, these radiotracers could provide treatment for AD patients early in the course of the disease when response to treatment is usually better.

The development of plaque-binding compounds started with monoclonal antibodies against beta-amyloid ($A\beta$) and self-associating $A\beta$ fragments, and was followed by analogues of histopathological dyes such as Congo Red, Chrysamine G, and Thioflavin T, which are used to stain SPs and NFTs in postmortem AD brain sections (Valotassiou et al., 2010; Villemagne et al., 2005). Recently, malononitrile analogues, which share the same binding site on $A\beta$ peptides with the nonsteroidal anti-inflammatory drugs (NSAIDs), have been developed as potential tracers for $A\beta$ imaging (Agdeppa et al., 2001, 2003a; Shoghi-Jadid et al., 2002).

2.3.1 Radiolabeled antibodies

Several radiolabeled anti- $A\beta$ antibodies and self-associating $A\beta$ amyloid fragments have been developed for potential in vivo SPECT amyloid imaging in AD. ^{99m}Tc -10H3, ^{111}In (^{111}In) AMY33 and 10D5 (Bickel et al., 1994; L.C. Walker et al., 1994) although gave promising results in vitro, however, they didn't meet success for in vivo studies mainly due to poor BBB penetration. Despite the efforts that have been made to modify the structure of antibodies and to develop different drug delivery methods suitable for brain studies in vivo, significant problems still constrain the potential application of these probes in human subjects.

2.3.2 Radiolabeled derivatives of histopathological dyes

The first chemically modified neutral thioflavin derivatives were labelled with I-123 in an effort to develop radioiodinated tracers for SPECT imaging of A β plaques. Radioiodinated TZDM, TZPI, IBOX and IMPY showed good A β plaque binding in vitro but low brain uptake in vivo since they lack sufficient hydrophobicity for diffusion through the BBB, except IMPY which exhibited more promising binding properties (Ono et al., 2002; Zhuang et al., 2001). [¹¹C]-SB-13, a radiolabeled Congo Red derivative, (Verhoeff et al., 2004) has been recently evaluated in AD patients and healthy control subjects. [¹¹C]-SB-13 showed increased retention in the frontal and posterior temporal-inferior parietal association cortices in the AD patients, but not in the comparison subjects.

Another radiolabeled benzothiazole aniline (BTA) analogue [N-methyl-¹¹C]-2-(4'-methylaminophenyl)-6-hydroxybenzothiazole ([¹¹C]6-OH-BTA-1), which is a neutral derivative of thioflavin T, has been studied extensively, in both preclinical and clinical studies (Klunk et al., 2001; Mathis et al., 2002). It was named "Pittsburgh Compound-B" or PIB and exhibited high affinity for aggregated amyloid but not for NFTs (Ye et al., 2005), and reasonable lipophilicities for crossing the BBB. In AD patients, the distribution pattern of ¹¹C-PIB is characterized by significantly great uptake in the frontal, temporal, parietal, and occipital cortices and the striatum but low entry into the cerebellum and subcortical white matter (Nordberg, 2008). The retention of PIB in cortical AD brain regions was found to be inversely related to the rCGM as measured by FDG PET in the same brain regions. ¹¹C-PIB uptake did not show significant correlation with the degree of cognitive impairment. Similar PIB retention was observed in both AD patients and controls in areas with low A β amyloid deposition (Klunk et al., 2004). Elevated ¹¹C-PIB uptake was also observed in dementia with lewy bodies and about 50% of mild cognitive impairment subjects, compared to healthy controls (Morris & Price, 2001). Interestingly, about 25% of the healthy controls demonstrated cortical binding of ¹¹C-PIB, predominantly in the prefrontal cortex, a finding which supports the in vitro observations that A β aggregation predominantly occurs before onset of dementia. ¹⁸F-flutemetamol (or ¹⁸F-GE067), a fluorolabeled structural thioflavin analogue of PIB, was developed recently. The spatial distribution of ¹⁸F-flutemetamol uptake in AD resembles closely the distribution typically seen with ¹¹C-PIB binding (Nelissen et al., 2009). High ¹⁸F-flutemetamol uptake was observed in striatum while the uptake in medial temporal cortex, one of the areas of predilection for neurofibrillary tangles in AD, was relatively low. Furthermore, the retention of the radioligand was similar in AD patients and healthy controls in brain regions known to be relatively unaffected by amyloid deposition.

2.3.3 Radiolabeled malononitrile analogues

Newer radioligands such as the radiofluorinated [¹⁸F]FDDNP and [¹⁸F]FENE, which are analogues of the 2-[1-[6-(dimethylamino)-2-naphthyl]ethylidene] malononitrile (DDNP), have been used to label not only SPs but also NFTs for the first time in the living brain of AD patients with PET (Agdeppa et al., 2003b). FDDNP and NSAIDs share a previously unrecognized common binding site on A β (1-40) fibrils and senile plaques and also exhibit anti-aggregation effects on A β peptides.

The PET imaging data showed increased retention of [¹⁸F]FDDNP in the hippocampus, amygdale, entorhinal and temporal lobe regions of the brain, which are consistent with areas known to develop SPs and NFTs. The findings were associated with hypometabolism, as measured with FDG PET, and atrophy, as observed with MRI, in the same brain areas

and correlated with lower memory performance scores (Agdeppa et al., 2001; Shoghi-Jadid et al., 2002). [¹⁸F]FDDNP provides a disease-specific, in vivo imaging tool for localization and loading of AD-related lesions, which in turn, could aid in early diagnosis of AD in combination with other diagnostic tests (Agdeppa et al., 2003a). Indeed, [¹⁸F]FDDNP has greater sensitivity at early stages of AD, before clinical evidence of cognitive decline. Moreover, [¹⁸F]FDDNP-PET may contribute in the elucidation of the relation between possible neuroprotective NSAIDs and A β aggregates. The shared binding site on A β fibrils and plaques may be a site of anti-aggregation drug action (e.g., naproxen and ibuprofen). Naproxen, ibuprofen and even FDDNP significantly inhibit aggregation of the A β (1-40) peptide in the micromolar range (Agdeppa et al., 2003b). Therefore, [¹⁸F]FDDNP-PET could be used in determining the occupancy rate of NSAIDs and experimental drugs in plaques in the living brain of AD patients, thus offering new opportunities for early diagnosis, prevention and treatment of AD.

2.3.4 Flavonoids

Flavonoids and their derivatives (chalcones and aurones) have been proved to have anti-oxidant effect due to matrix metalloproteinases (MMP) inhibitory activity (Calliste et al., 2001), as well as anti-inflammatory and neuroprotective properties by modulating microglia-related immune responses in the brain (Rezai-Zadeh et al., 2008). Radioiodinated flavones have also been used in experimental studies as possible amyloid imaging probes. They displayed high brain penetration, high brain uptake, fast washout from the brain and good binding affinity not only on A β ¹⁻⁴⁰ aggregates but on A β ¹⁻⁴² aggregates as well. Moreover, they showed high binding affinity for NFTs, too (Ono et al., 2005, 2007).

2.4 Imaging of the acetylcholine system

PET and SPECT can evaluate noninvasively the acetylcholine system in the human brain with the use of appropriate radiotracers, in order to detect impairments even at the presymptomatic stage of AD as well as monitoring treatment outcomes of the drugs that enhance acetylcholine activity in AD.

The available radiotracers target various elements and processes involved with cholinergic neurotransmission and function. These include the study of acetylcholine receptors and acetylcholine neuronal integrity.

Radioligands have been developed to measure both nicotinic and muscarinic receptors. ¹¹C-labeled nicotine (Nordberg et al., 1991) as well as epibatidine and azetidide derivatives labeled with ¹¹C or ¹⁸F were used to visualize and quantify nicotinic receptors in the brain. Although epibatidine demonstrated high affinity and specificity for nicotinic receptors, unfortunately is very toxic, which may preclude its use in humans (Villemagne et al., 1997). Nevertheless, epibatidine and azetidide analogs didn't meet clinical application (Sihver et al., 1999). Early in the course of AD, PET studies revealed a reduced ¹¹C-nicotine uptake to nicotinic receptors in frontal and temporal cortex and in the hippocampus in comparison with that of age-matched healthy control subjects (Volkow et al., 2001).

Several radiotracers have been developed for mapping muscarinic receptors. For the most part these radiotracers are limited by the lack of selectivity for the muscarinic receptor subtypes (M1-M4), except for [¹⁸F]FP-TZTP, which appears to bind predominantly to M2 receptors (Carson et al., 1998).

For the study of acetylcholine neuronal integrity, radioigands have been developed to measure both the activity of acetylcholinesterase and the acetylcholine vesicular transporter.

The activity of acetylcholinesterase can be measured with PET either using radiolabeled acetylcholine analogues that serve as substrates for acetylcholinesterase and hydrolyze to a hydrophilic product that is trapped in the cell or using radioligands that directly bind to acetylcholinesterase (Kuhl et al., 1999; Pappata et al., 1996). Radiolabeled acetylcholine analogues N-methyl-3-piperidyl-acetate [MP3A], N-methylpiperidin-4-yl-acetate [MP4A], and N-methylpiperidin-4-yl-propionate [PMP] have been used for this purpose. PET studies in patients with AD demonstrated a widespread reduction of acetylcholinesterase activity in the cerebral cortex. In normal aging no changes were observed. Additionally, the early loss of cholinergic transmission in the cortex could be shown with these tracers, which precedes the loss of cholinergic neurons in the nucleus basalis of Meynert (Herholz et al., 2004). Several radioligands that target the acetylcholine vesicular transporter have been labelled but only (2)-5 [¹²³I]iodobenzovesamicol (¹²³I-IBVM) has been used in SPECT studies to image the living human brain (Kuhl et al., 1994). ¹²³I-IBVM is an analogue of vesamicol that binds to the acetylcholine vesicular transporter. Cortical binding of ¹²³I-IBVM in normal subjects was found to decline only mildly with age (3.7% per decade), but it was markedly reduced in AD patients. The reductions predicted dementia severity while the binding levels were also determined by the age of disease onset (Kuhl et al., 1996). Patients with an early onset demonstrated reductions throughout the cortex and hippocampus, whereas patients with late onset had reductions only in the temporal cortex and hippocampus. This finding may reflect the greater cholinergic loss in early- rather than in late-onset AD (Rossor et al., 1984).

2.5 Imaging of neuroinflammation

The process of neurodegeneration in AD is associated with activation of resting microglial cells and local glial responses. Peripheral benzodiazepine receptors are the mediators of central nervous system inflammation. Radiolabelled isoquinoline ([¹¹C]R-PK11195) has been used in PET studies as an indicator of microglia activation in AD. [¹¹C](R)-PK11195 is a ligand for the peripheral benzodiazepine receptors which binds to the outer mitochondrial membrane of activated, but not resting, microglia (Banati, 2002). PET studies in AD patients demonstrated increased [¹¹C](R)-PK11195 uptake in the temporal cortex (particularly the fusiform, the parahippocampal and the inferior temporal gyri), the inferior parietal cortex, the posterior cingulate and the amygdala (Cagnin et al., 2002). These areas with high [¹¹C](R)-PK11195 uptake subsequently underwent the most marked atrophic changes within the following year as shown by a longitudinal serial volumetric MRI scan. This suggests that an *in vivo* measure of activated microglia provides an indirect index of disease activity. ¹²³I-PK11195, a SPECT ligand for the peripheral benzodiazepine receptors, has been recently studied in AD patients. Significantly increased uptake was found in the frontal and right mesotemporal regions which correlated with cognitive deficits (Versijpt et al., 2003).

2.6 Imaging of the serotonergic system

Several SPECT and PET studies have investigated the implication of serotonin (5HT) in the modulation of cognitive and behavioral/neuropsychiatric disturbances of neurodegenerative dementias (Meltzer et al., 1998). Post-synaptic 5HT_{2A} receptors and pre- and post-synaptic 5HT_{1A} receptors have been studied *in vivo* in AD.

PET studies with ¹⁸F-setoperone, a 5HT_{2A} receptor antagonist, demonstrated reduced parietal, temporal, frontal and occipital cortical binding in untreated moderate-severe AD patients (Blin et al., 1993), while reduced ¹⁸F-altanserin binding were also observed in mild-moderate AD in the anterior cingulate, prefrontal, temporal, and sensorimotor cortices

(Meltzer et al., 1999). No correlation was found between cortical ^{18}F -altanserin binding and MMSE scores. Pre- and post-synaptic 5HT_{1A} receptors studies with ^{18}F -MPPF have shown decreased binding in the hippocampus and the raphe nucleus of AD patients (Kepe et al., 2006).

2.7 Differential diagnosis

2.7.1 Differential diagnosis of AD from dementia with lewy bodies

The discrimination of AD from dementia with lewy bodies (DLB) is difficult since these disorders share common scintigraphic findings. Temporoparietal hypoperfusion and hypometabolism on SPECT and FDG PET studies is common to both AD and DLB (Minoshima et al., 2001; Pasquier et al., 2002), although subtle differences in perfusion and metabolism patterns have been reported (Colloby et al., 2002), with a relative preservation of medial temporal lobe structures and rCBF in DLB and more extended biparietal hypoperfusion in DLB compared to AD patients.

The differential diagnosis of AD from DLB is based on the greater degree of occipital hypoperfusion or hypometabolism in DLB than in AD. The reported sensitivity and specificity for the accuracy of discriminating AD from DLB on the basis of the finding of hypoperfusion and hypometabolism in the occipital cortex ranged between 65-90% and 80-87%, respectively (Lobotesis et al., 2001; Minoshima et al., 2001).

Post mortem brain studies have shown that the presynaptic dopaminergic terminals in the putamen of DLB patients show a 57% reduction compared to controls. This reduction in dopaminergic terminals leads to loss of the presynaptic dopamine transporter system (DAT) (Piggott et al., 1999). If one considers the DAT a surrogate marker of dopaminergic nigrostriatal neurons, imaging of the DAT sites with a specific marker, will be able to identify nigrostriatal dopaminergic degeneration in DLB patients during life. [^{123}I]-ioflupane is a cocaine analogue that binds specifically to the DAT in the membrane of the presynaptic dopaminergic neurones. SPECT studies with [^{123}I]-ioflupane in DLB patients demonstrated reduction of the presynaptic tracer uptake in the striata of both hemispheres, which was clearly more marked in the putamen than caudate nucleus and linked to significant loss of DAT (Z. Walker et al., 2002). This finding enabled the clear differentiation from AD that showed the striatal uptake to be within the normal range. Separation between DLB and AD based on [^{123}I]-ioflupane SPECT imaging is achieved with sensitivity, specificity, and positive predictive value of 78%, 94%, and 90%, respectively (O'Brien et al., 2004).

Recently, an alternative scintigraphic method - cardiac uptake of ^{123}I -metaiodobenzylguanidine (MIBG) - for differentiating AD from DLB was reported. Markedly decreased cardiac uptake was observed in DLB because of cardiac sympathetic denervation (Tateno et al., 2008). Thereafter, the combination of perfusion and [^{123}I]-ioflupane SPECT and MIBG scintigraphy could increase the accuracy of clinical diagnosis of DLB.

2.7.2 Differential diagnosis of AD from vascular dementia

The pattern of hypoperfusion and hypometabolism on brain perfusion SPECT and FDG PET studies in vascular dementia (VaD) varies greatly and depends on the location of the ischemic lesions (Mori et al., 1999). In the multi-infarct type of VaD, the pattern of perfusion and metabolism is characterized by small or large, single or multiple cortical defects randomly distributed. Motor and sensory cortices may also be involved (DeReuck et al.,

1998). In demented patients with white matter lesions, hypoperfusion and hypometabolism are seen mainly in frontal, posterior frontal and anterior temporoparietal cortical regions due to disruption of cortico-cortical connections. In VaD patients with subcortical lesions alone, without cortical lesions on CT, remote cortical metabolism and perfusion defects on intact cortical and subcortical structures are seen, due to disconnection or diaschisis of cortico-subcortical pathways (Kwan et al., 1999).

The great overlapping of hypoperfusion and hypometabolism patterns between AD and VaD, which some times reflect the presence of mixed dementia too, may complicate the interpretation of SPECT and PET images, making the differential diagnosis of AD and VaD difficult. In such cases the administration of acetazolamide has been proved to be a useful tool in the evaluation of vascular reserve capacity (Tikofsky & Hellman, 1991) and can contribute significantly in the differential diagnosis. Acetazolamide is a carbonic anhydrase inhibitor which increases the local pCO₂ in the brain tissue leading to arteriolar dilatation and local increase of rCBF. In AD, vascular reserve capacity is preserved and the administration of acetazolamide results in increased rCBF in the hypoperfused areas seen on SPECT perfusion study. In VaD, acetazolamide fails to increase rCBF in areas with vascular lesions where the vascular reserve capacity is impaired (Pavics et al., 1999).

2.7.3 Differential diagnosis of AD from frontotemporal lobar degeneration

In patients with frontotemporal lobar degeneration (FTLD), PET and SPECT studies revealed the preferential involvement of the frontotemporal regions (Jeong et al., 2005; McNeill et al., 2007). More specifically, these studies demonstrated an extensive decrease of glucose metabolism and perfusion in the frontal and temporal areas, cingulate gyri, uncus, and insula, and subcortical areas, including the basal ganglia and medial thalamic regions (Fig. 2).

The widespread abnormalities observed in FTLD patients may reflect the cumulative findings of the specific variants of FTLD i.e. the frontal or behavioural variant (bvFTD) and the temporal variants of semantic dementia (SD) and progressive non fluent aphasia (PNFA). FDG PET and perfusion SPECT studies in patients with PNFA and SD showed hypometabolism and hypoperfusion in the left hemisphere including the temporal, parietal and middle frontal lobe, whereas in bvFTD patients prominent frontal lobes deficits have been demonstrated (Pernecky et al., 2007; Sinnatamby et al., 1996).

PIB PET studies could potentially aid in differentiating between FTLD and AD patients. FTLD patients showed significantly lower PIB retention compared to AD in frontal, parietal, temporal, and occipital cortices as well as in putamen. The PIB uptake in these FTLD patients did not differ significantly from the healthy controls in any region (Engler et al., 2008).

2.7.4 Differential diagnosis of AD from other dementias

In Creutzfeldt-Jakob encephalopathy, brain perfusion and metabolism studies have revealed various degrees of focal or diffuse hypoperfusion and hypometabolism, which correlated with the severity of the disease, while the use of [¹¹C]-L deuterodeprenyl (DED) -a tracer to assess astrocytosis- showed parallel increases in DED uptake indicating astrocytosis (Engler et al., 2003). Use of iomazemil SPECT to bind with benzodiazepine receptors in a case of Creutzfeldt-Jakob disease has been described with reduced uptake in later stages suggesting neuronal degeneration (Itoh et al., 1998).

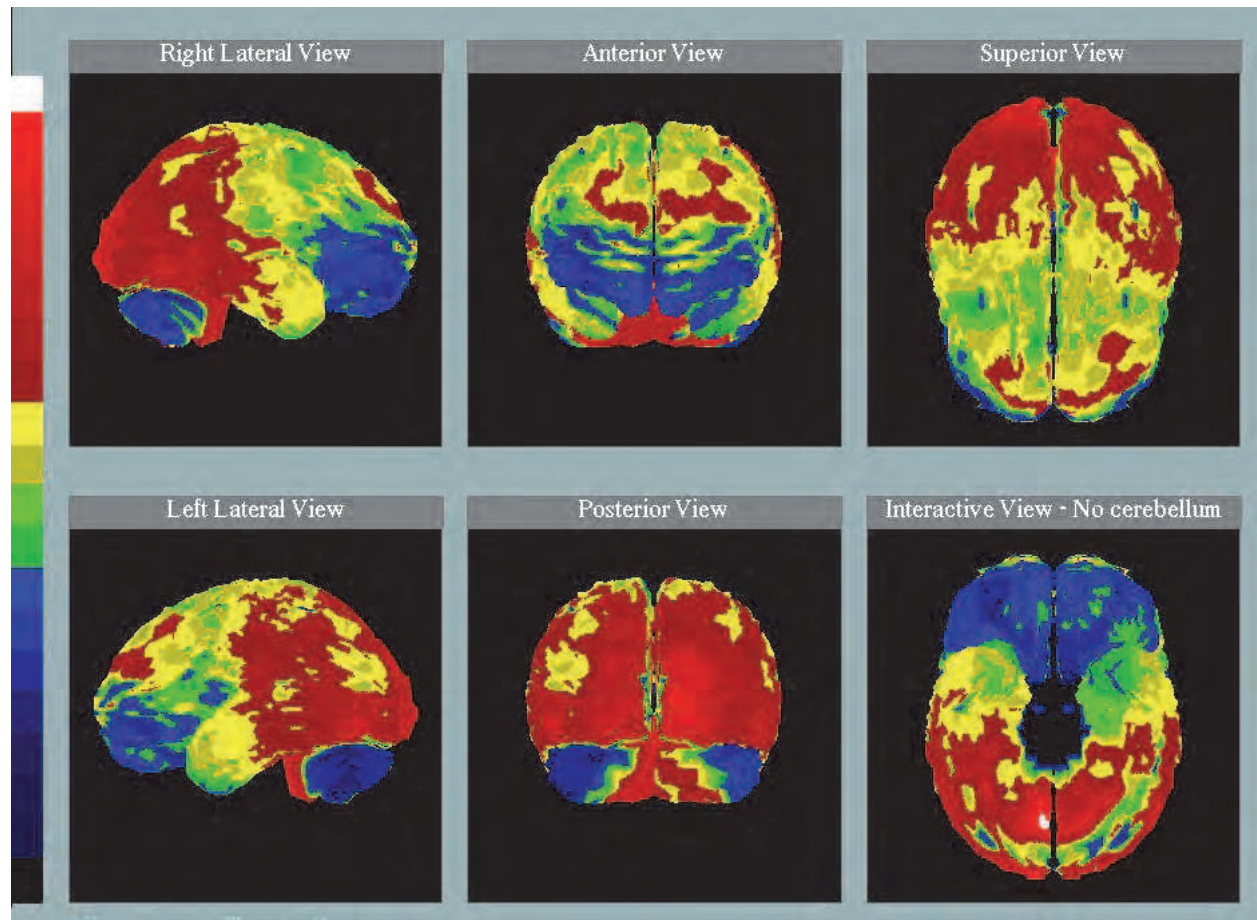


Fig. 2. Brain perfusion SPECT study in a patient with Frontotemporal lobar degeneration. Reduced ^{99m}Tc -HMPAO uptake is observed in frontotemporal cortical areas, more marked in the frontal lobes.

In acute immunodeficiency syndrome (AIDS) dementia, brain perfusion SPECT and FDG PET images demonstrated randomly distributed multiple focal cortical and subcortical deficits of perfusion and metabolism with a predilection for the basal ganglia. These perfusion and metabolism abnormalities may be present even when patients are asymptomatic and correlate better with cognitive improvement after therapy than do structural images (Kim et al., 1996; Tatsch et al., 1990).

Demented patients with Parkinson's disease or other parkinsonian syndromes such as corticobasal degeneration (CBD), progressive supranuclear palsy (PSP) and multiple system atrophy (MSA) may present overlapping perfusion and metabolism templates with AD patients. Demented patients with Parkinson's disease and AD share a common pattern of marked posterior hypoperfusion involving the parietal, temporal, and occipital lobes, as well as hypoperfusion in the dorsolateral prefrontal cortex (Eckert et al., 2005; Spampinato et al., 1991). In PSP, glucose metabolism and perfusion was decreased in the midbrain and medial frontal cortex (Eckert et al., 2005; Okuda et al., 2000). Relative hypometabolism and hypoperfusion in the basal ganglia and fronto-parietal cortex contralateral to the most affected side was a characteristic finding in CBD (Eckert et al., 2005; Hossain et al., 2003). MSA patients exhibited a pattern characterized by marked bilateral reductions of perfusion and metabolism in the lentiform nuclei, the pons and the cerebellum (Cilia et al., 2005;

Eckert et al., 2005). Recent neuroreceptor studies have found that decreased striatum uptake on the presynaptic DAT SPECT imaging in demented patients with Parkinson's disease or other parkinsonian syndromes, may be a useful marker for the discrimination from AD (Hilker et al., 2005; Pirker et al., 2000).

In symptomatic patients with Huntington's disease (HD) brain perfusion SPECT imaging shows decreased or absent tracer uptake in the caudate nucleus or basal ganglia (Nagel et al., 1991). The impairment of basal ganglia may not be permanent and tracer uptake may return to normal after therapy with olanzapine (Etchebehere et al. 1999).

2.8 Assessment of treatment

Acetylcholinesterase inhibitors have been the most widely used drugs to treat AD. Perfusion, metabolism and nicotinic receptors SPECT and PET imaging can be used to assess the efficacy of these drugs in inhibiting acetylcholinesterase, to determine the doses required to achieve optimal inhibition and identify patients in whom the concentration of acetylcholinesterase may be too low for acetylcholinesterase inhibitors to be effective (Kuhl et al., 2000).

Perfusion SPECT studies have shown that treatment with donepezil appeared to reduce the decline in rCBF, suggesting a preservation of functional brain activity (Nakano et al., 2001; Staff et al., 2000). Increases in rCBF in anterior cingulate, lateral orbitofrontal, dorsolateral prefrontal, and temporoparietal areas after short term acetylcholinesterase inhibitor therapy was significantly related to behaviors of irritability, disinhibition, and euphoria (Ceravolo et al., 2004; Nakano et al., 2001). These data suggest that cognitive or behavioral benefits after cholinesterase inhibitor therapy are related to clear increases in rCBF in crucial areas specifically involved in the attention and limbic networks.

Increases in rCBF in AD patients have also been reported after acute and fairly short periods of treatment with other cholinesterase inhibitors such as tacrine and velnacrine, and with the acetylcholine releaser linopirdine (van Dyck et al., 1997). Tacrine treatment increased cerebral blood flow, cerebral glucose metabolism, and uptake of ^{11}C -nicotine to the brain paralleled by improvement in neuropsychological performance. Though the effects of tacrine on nicotine receptors occurred early in the course of treatment (3 weeks), those in metabolism were observed only after months of treatment (Nordberg et al., 1998). Tacrine increased binding of ^{11}C -nicotine in the temporal cortex of AD patients was interpreted as reflecting a restoration of nicotinic receptors (Nordberg et al., 1997). These results are in agreement with preclinical data showing that cholinergic stimulation leads to upregulation of nicotinic receptors (Svensson & Nordberg, 1996).

Acetylcholinesterase inhibitors can be labeled with positron emitters without changing their pharmacologic properties. This would allow for the investigation of their regional distribution and pharmacokinetics in the human brain. Studies that have assess the effects of these drugs at their molecular target show the relationship between doses of a drug and percent occupancy of receptors or transporters, or percent of enzyme inhibition. This can be achieved either by using the radiolabeled drug itself, if it has a good specific-to-nonspecific binding ratio, or by using a radioligand that binds to the same site as the drug (Traykov et al., 1999). This same strategy can be applied to measure the receptor occupancies achieved by nicotinic or muscarinic drugs at doses that improve cognitive or behavioral function (Ding et al., 2000). Equivalent studies can also be done to assess the efficacy of cholinesterase inhibitors in inhibiting acetylcholinesterase (Pappata et al., 1996). Acetylcholine-enhancing

drugs that have been labelled with positron emitters include nicotine, tacrine, and physostigmine.

2.9 Genetic risk for AD and PET

Subtle changes in brain function may occur prior to overt manifestations of the disease in genetically at-risk individuals. The combination of functional brain imaging with genetic risk factors may enhance the ability to detect differences predictive of disease development prior to onset and assist in the potential for increasing the efficacy of therapeutic treatments (Reiman et al., 2001). FDG PET studies in asymptomatic apolipoprotein $\epsilon 4$ allele (APOE $\epsilon 4$) carriers demonstrated a decline of metabolism in the left posterior cingulate, inferior parietal, and lateral temporal regions (Kennedy et al., 1995; Small et al., 2000). Likewise, perfusion SPECT studies in asymptomatic presenilin-1 mutation subjects demonstrated reduced perfusion in the hippocampal complex, anterior and posterior cingulate, posterior parietal lobe, and anterior frontal lobe (Johnson et al., 2001).

3. Conclusion

The application of SPECT and PET techniques to the study of AD patients has elucidated the *in vivo* understanding of the underlying pathology of the disease. The variety of the available radiotracers has rendered SPECT and PET objective biomarkers for monitoring of biochemical processes altered by neuronal loss. Nuclear molecular imaging of changes in brain A β deposition, perfusion, metabolism and neurotransmitter turnover, as well as alterations in receptor, transporter or enzyme concentrations can provide unique information not attainable by other methods. The noninvasive PET and SPECT imaging provided novel ways to improve early and differential diagnosis of AD and monitor the disease progression and the effects of symptomatic or disease modifying therapies.

4. References

- Agdeppa, E.D., Kepe, V., Liu, J., Flores-Torres, S., Satyamurthy, N., Petric, A., Cole, G.M., Small, G.W., Huang, S.C., & Barrio, J.R. (2001). Binding characteristics of radiofluorinated 6-dialkylamino-2-naphthylethylidene derivatives as positron emission tomography imaging probes for beta-amyloid plaques in Alzheimer's disease. *Journal of Neuroscience*, Vol. 21, No. 24, (December 2001), pp. 189-193, ISSN 0270-6474
- Agdeppa, E.D., Kepe, V., Liu, J., Small, G.W., Huang, S.C., Petric, A., Satyamurthy, N., & Barrio, J.R. (2003a). 2-Dialkylamino-6-acylmalononitrile substituted naphthalenes (DDNP Analogs): novel diagnostic and therapeutic tools in Alzheimer's disease. *Molecular Imaging & Biology*, Vol. 5, No. 6, (November - December 2003), pp. 404-417, ISSN 1536-1632
- Agdeppa, E.D., Kepe, V., Petri, A., Satyamurthy, N., Liu, J., Huang, S.C., Small, G.W., Cole, G.M., & Barrio, J.R. (2003b). In vitro detection of (S)-naproxen and ibuprofen binding to plaques in the Alzheimer's brain using the positron emission tomography molecular imaging probe 2-(1-[6-[(2-[(18)F] fluoroethyl) (methyl) amino]-2-naphthyl] ethylidene) malononitrile. *Neuroscience*, Vol. 117, No. 3, (March 2003), pp. 723-730, ISSN 0306-4522

- Banati, R.B. (2002). Visualising microglial activation in vivo. *Glia*, Vol. 40, No. 2, (November 2002), pp. 206-217, ISSN 1098-1136
- Bickel, U., Lee, V.M., Trojanowski, J.Q., & Pardridge, W.M. (1994). Development and in vitro characterization of a cationized monoclonal antibody against beta A4 protein: A potential probe for Alzheimer's disease. *Bioconjugate Chemistry*, Vol. 5, No. 2, (March 1994), pp. 119-125, ISSN 1043-1802
- Blin, J., Baron, J.C., Dubois, B., Crouzel, C., Fiorelli, M., Attar-Levy, D., Pillon, B., Fournier, D., Vidailhet, M. & Agid, Y. (1993). Loss of brain 5-HT₂ receptors in Alzheimer's disease. In vivo assessment with positron emission tomography and [18F]setoperone. *Brain*, Vol. 116, No. 3, (June 1993) pp. 497-510, ISSN 0006-8950
- Borroni, B., Anchisi, D., Paghera, B., Vicini, B., Kerrouche, N, Garibotto, V., Terzi, A., Vignolo, L.A., Di Luca, M., Giubbini, R., Padovani, A. & Perani, D. (2006). Combined 99mTc-ECD SPECT and neuropsychological studies in MCI for the assessment of conversion to AD. *Neurobiology of Aging*, Vol. 27, No. 1, (January 2006), pp. 24-31, ISSN 0197-4580
- Brown, D.R., Hunter, R., Wyper, D.J., Patterson, J., Kelly, R.C., Montaldi, D., & McCullough, J. (1996). Longitudinal changes in cognitive function and regional cerebral function in Alzheimer's disease: a SPECT blood flow study. *Journal of Psychiatric Research*, Vol. 30, No. 2, (March - April 1996), pp. 109 -126, ISSN 0022-3956
- Cagnin, A., Gerhard, A., & Banati, R.B. (2002). In vivo imaging of neuroinflammation. *European Neuropsychopharmacology*, Vol. 12, No. 6, (December 2002), pp. 581-586, ISSN 0924-977X
- Calliste, C.A., Le Bail, J.C., Trouillas, P., Pouget, C., Habrioux, G., Chulia, A.J., & Duroux J.L. (2001). Chalcones: structural requirements for antioxidant, estrogenic and antiproliferative activities. *Anticancer Research*, Vol. 21, No. 6A, (November - December 2001), pp. 3949-3956, ISSN 0250-7005
- Carson, R.E., Kiesewetter, D.O., Jagoda, E., Der, M.G., Herscovitch, P., & Eckelman, W.C. (1998). Muscarinic cholinergic receptor measurements with [18F]FP-TZTP: control and competition studies. *Journal of Cerebral Blood Flow & Metabolism*, Vol. 18, No. 10, (October 1998), pp. 1130 -1142, ISSN 0271-678X
- Ceravolo, R., Volterrani, D., Tognoni, G., Dell'Agnello, G., Manca, G., Kiferle, L., Rossi, C., Logi, C., Strauss, H.W., Mariani, G., & Murri, L. (2004). Cerebral perfusional effects of cholinesterase inhibitors in Alzheimer disease. *Clinical Neuropharmacology*, Vol. 27, No. 4, (July - August 2004), pp. 166-170, ISSN 0362-5664
- Chetelat, G., Desgranges, B., De La Sayette, V., Viader, F., Eustache, F., & Baron, J.C. (2003). Mild cognitive impairment: can FDG-PET predict who is to rapidly convert to Alzheimer's disease? *Neurology*, Vol. 60, No. 8, (April 2003), pp. 1374-1377, ISSN 0028-3878
- Cilia, R., Marotta, G., Benti, R., Pezzoli, G., & Antonini, A. (2005). Brain SPECT imaging in multiple system atrophy. *Journal of Neural Transmission*, Vol. 112, No. 12, (December 2005), pp. 1635-1645, ISSN 0300-9564
- Claus, J.J., Walstra, G.J., Hijdra, A., van Royen, E.A., Verbeeten, B. Jr, & van Gool, W.A. (1999). Measurement of temporal regional cerebral perfusion with single-photon emission tomography predicts rate of decline in language function and survival in early Alzheimer's disease. *European Journal of Nuclear Medicine*, Vol. 26, No. 3, (March 1999), pp. 265-271, ISSN 0340-6997

- Coleman, R.E. (2005). Positron emission tomography diagnosis of Alzheimer's disease. *Neuroimaging Clinics of North America*, Vol. 15, No. 4, (November 2005), pp. 837-846, ISSN 1052-5149
- Colloby, S.J., Fenwick, J.D., Williams, E.D., Paling, S.M., Lobotesis, K., Ballard, C., McKeith, I., & O'Brien, J.T. (2002). A comparison of (99m)Tc-HMPAO SPET changes in dementia with Lewy bodies and Alzheimer's disease using statistical parametric mapping. *European Journal of Nuclear Medicine & Molecular Imaging*, Vol. 29, No. 5, (May 2002), pp. 615-622, ISSN 1619-7070
- Costa, D.C., Walker, Z., Walker, R.W., & Fontes, F.R. (2003). Dementia with Lewy bodies versus Alzheimer's disease: role of dopamine transporter imaging. *Movement Disorders*, Vol. 18, Suppl. 7, (October 2003), pp. 34-38, ISSN 1531-8257
- Costa, D.C. (2004). The blood-brain barrier, In: *Nuclear Medicine in clinical diagnosis and treatment*, P.J. Ell, S.S. Gambhir, (Eds.), 1235-1246, Churchill Livingstone, ISBN 0-443-07312-0, New York, USA
- DeReuck, J., Decoo, D., Marchau, M., Santens, P., Lemahieu, I., & Strijckmans, K. (1998). Positron emission tomography in vascular dementia. *Journal of the Neurological Sciences*, Vol. 154, No. 1, (January 1998), pp. 55-61, ISSN 0022-510X
- Ding, Y.S., Volkow, N.D., Logan, J., Garza, V., Pappas, N., King, P., & Fowler, J.S. (2000). Occupancy of brain nicotinic acetylcholine receptors by nicotine doses equivalent to those obtained when smoking a cigarette. *Synapse*, Vol. 35, No. 3, (March 2000), pp. 234-237, ISSN 0887-4476
- Eckert, T., Barnes, A., Dhawan, V., Frucht, S., Gordon, M.F., Feigin, A.S., & Eidelberg, D. (2005). FDG PET in the differential diagnosis of parkinsonian disorders. *Neuroimage*, Vol. 26, No. 3, (July 2005), pp. 912-921, ISSN 1053-8119
- Engler, H., Lundberg, P.O., Ekblom, K., Nennesmo, I., Nilsson, A., Bergström, M., Tsukada, H., Hartvig, P., & Långström, B. (2003). Multitracer study with positron emission tomography in Creutzfeldt-Jakob disease. *European Journal of Nuclear Medicine & Molecular Imaging*, Vol. 30, No. 1, (January 2003), pp. 85-95, ISSN 1619-7070
- Engler, H., Santillo, A.F., Wang, S.X., Lindau, M., Savitcheva, I., Nordberg, A., Lannfelt, L., Långström, B., & Kilander, L. (2008). In vivo amyloid imaging with PET in frontotemporal dementia. *European Journal of Nuclear Medicine & Molecular Imaging*, Vol. 35, No. 1, (January 2008), pp. 100-106, ISSN 1619-7070
- Etchebehere, E.C., Lima, M.C., Passos, W., Maciel Júnior, J.A., Santos A.O., Ramos, C.D., & Camargo, E.E. (1999). Brain SPECT imaging in Huntington's disease before and after therapy with olanzapine. *Arquivos de Neuro-psiquiatria*, Vol. 57, No. 3B, (September 1999), pp. 863-866, ISSN 0004-282X
- Gee, A.D. (2003). Neuropharmacology and drug development. *British Medical Bulletin*, Vol. 65, No. 1, (March 2003), pp. 169-177, ISSN 0007-1420
- Hanyu, H., Sato, T., Akai, T., Shimizu, S., Hirao, K., Kanetaka, H., Iwamoto, T., & Koizumi, K. (2008). Neuroanatomical correlates of unawareness of memory deficits in early Alzheimer's disease. *Dementia and Geriatric Cognitive Disorders*, Vol. 25, No. 4, (April 2008), pp. 347-353, ISSN 1420-8008
- Haxby, J.V., Grady, C.L., Koss, E., Horwitz, B., Heston, L., Schapiro, M., Friedland, R.P., & Rapoport, S.I. (1990). Longitudinal study of cerebral metabolic asymmetries and associated neuropsychological patterns in early dementia of the Alzheimer type. *Archives of Neurology*, Vol. 47, No. 7, (July 1990), pp. 753-760, ISSN 0003-9942
- Herholz, K., Weisenbach, S., Zündorf, G., Lenz, O., Schröder, H., Bauer, B., Kalbe, E., & Heiss, W.D. (2004). In vivo study of acetylcholine esterase in basal forebrain,

- amygdala, and cortex in mild to moderate Alzheimer disease. *Neuroimage*, Vol. 21, No. 1, (January 2004), pp. 136–143, ISSN 1053-8119
- Hilker, R., Thomas, A.V., Klein, J.C., Weisenbach, S., Kalbe, E., Burghaus, L., Jacobs, A.H., Herholz, K., & Heiss, W.D. (2005). Dementia in Parkinson disease: functional imaging of cholinergic and dopaminergic pathways. *Neurology*, Vol. 65, No. 11, (December 2005), pp. 1716-1722, ISSN 0028-3878
- Hirao, K., Ohnishi, T., Hirata, Y., Yamashita, F., Mori, T., Moriguchi, Y., Matsuda, H., Nemoto, K., Imabayashi, E., Yamada, M., Iwamoto, T., Arima, K. & Asada, T. (2005). The prediction of rapid conversion to Alzheimer's disease in mild cognitive impairment using regional cerebral blood flow SPECT. *Neuroimage*, Vol. 28, No. 4, (December 2005), pp. 1014–1021, ISSN 1053-8119
- Hirao, K., Ohnishi, T., Matsuda, H., Nemoto, K., Hirata, Y., Yamashita, F., Asada, T., & Iwamoto, T. (2006). Functional interactions between entorhinal cortex and posterior cingulate cortex at the very early stage of Alzheimer's disease using brain perfusion single-photon emission computed tomography. *Nuclear Medicine Communications*, Vol. 27, No. 2, (February 2006), pp. 151-156, ISSN 0143-3636
- Hoffman, J.M., Welsh-Bohmer, K.A., Hanson, M., Crain, B., Hulette, C., Earl, N., & Coleman, R.E. (2000). FDG PET imaging in patients with pathologically verified dementia. *Journal of Nuclear Medicine*, Vol. 41, No. 11, (November 2000), pp. 1920–1928, ISSN 0161-5505
- Hossain, A.K., Murata, Y., Zhang, L., Taura, S., Saitoh, Y., Mizusawa, H., Oda, K., Matsushima, E., Okubo, Y., & Shibuya, H. (2003). Brain perfusion SPECT in patients with corticobasal degeneration: analysis using statistical parametric mapping. *Movement Disorders*, Vol. 18, No. 6, (June 2003), pp. 697–703, ISSN 1531-8257
- Ichimya, A. (1998). Functional and structural brain imagings in dementia. *Psychiatry and Clinical Neurosciences*, Vol. 52, Suppl, (December 1998), pp. 223–225, ISSN 1440-1819
- Ishii, K., Mori, E., Kitagaki, H., Sakamoto, S., Yamaji, S., Imamura, T., Ikejiri, Y., & Kono, M. (1996). The clinical utility of visual evaluation of scintigraphic perfusion patterns for Alzheimer's disease using I-123 IMP SPECT. *Clinical Nuclear Medicine*, Vol. 21, No. 2, (February 1996), pp. 106-110, ISSN 0363-9762
- Ishiwata, A., Sakayori, O., Minoshima, S., Mizumura, S., Kitamura, S., & Katayama, Y. (2006). Preclinical evidence of Alzheimer changes in progressive mild cognitive impairment: a qualitative and quantitative SPECT study. *Acta Neurologica Scandinavica*, Vol. 114, No. 2, (August 2006), pp. 91-96, ISSN 0001-6314
- Ismail, Z., Herrmann, N., Rothenburg, L.S., Cotter, A., Leibovitch, F.S., Rafi-Tari, S., Black, S.E., & Lanctôt, K.L. (2008). A functional neuroimaging study of appetite loss in Alzheimer's disease. *Journal of the Neurological Sciences*, Vol. 271, No. 1-2, (August 2008), pp. 97-103, ISSN 0022-510X
- Itoh, Y., Amano, T., Shimizu, T., Hashimoto, J., Kubo, A., & Fukuuchi, Y. (1998). Single photon emission computed tomography image of benzodiazepine receptors in a patient with Creutzfeldt-Jakob disease. *Internal Medicine*, Vol. 37, No. 10, (October 1998), pp. 896–900, ISSN 1349-7235
- Jacquier-Sarlin, M.R., Polla, B.S., & Slosman, D.O. (1996). Oxido-reductive state: the major determinant for cellular retention of technetium-99m-HMPAO. *Journal of Nuclear Medicine*, 37: Vol., No. 8, (August 1996), pp. 1413-1416, ISSN 0161-5505
- Jagust, W.J., Haan, M.N., Reed, B.R., & Eberling, J.L. (1998). Brain perfusion imaging predicts survival in Alzheimer's disease. *Neurology*, Vol. 51, No. 4, (October 1998), pp. 1009-1013, ISSN 0028-3878

- Jeong, Y., Cho, S.S., Park, J.M., Kang, S.J., Lee, J.S., Kang, E., Na, D.L., & Kim, S.E. (2005). 18F-FDG PET findings in frontotemporal dementia: an SPM analysis of 29 patients. *Journal of Nuclear Medicine*, Vol. 46, No. 2, (February 2005), pp. 233-239, ISSN 0161-5505
- Jobst, K.A., Barnetson, L.P., & Shepstone, B.J. (1998). Accurate prediction of histologically confirmed Alzheimer's disease and the differential diagnosis of dementia: the use of NINCDS-ADRDA and DSM-III-R. criteria, SPECT, x-ray CT, and Apo E4 in medial temporal lobe dementias: Oxford Project to Investigate Memory and Aging. *International. Psychogeriatrics*, Vol. 10, No. 3, (September 1998), pp. 271-302, ISSN 1041-6102
- Johannsen, B. & Pietzsch, H.J. (2002). Development of technetium 99m-based CNS receptor ligands: have there been any advances? *European Journal of Nuclear Medicine and Molecular Imaging*, Vol. 29, No. 2, (February 2002), pp. 263-275, ISSN 1619-7070
- Johnson, K.A., Lopera, F., Jones, K., Becker, A., Sperling, R., Hilson, J., Londono, J., Siegert, I., Arcos, M., Moreno, S., Madrigal, L., Ossa, J., Pineda, N., Ardila, A., Roselli, M., Albert, M.S., Kosik, K.S., & Rios, A. (2001). Presenilin-1-associated abnormalities in regional cerebral perfusion. *Neurology*, Vol. 56, No. 11, (June 2001), pp. 1545-1551, ISSN 0028-3878
- Joliet-Riant, P. & Tillement, J.P. (1999). Mechanisms of nutrient and drug transfer through the blood-brain barrier and their pharmacological changes. *L'Encéphale*, Vol. 25, No. 2, (March - April 1999), pp. 135-145, ISSN 0013-7006
- Kemp, P.M., Holmes, C., Hoffmann, S.M., Bolt, L., Holmes, R., Rowden, J., & Fleming, J.S. (2003). Alzheimer's disease: differences in technetium-99m HMPAO SPECT scan findings between early onset and late onset dementia. *Journal of Neurology, Neurosurgery and Psychiatry*, Vol. 74, No. 6, (June 2003), pp. 715-719, ISSN 0022-3050
- Kennedy, A.M., Frackowiak, R.S., Newman, S.K., Bloomfield, P.M., Seaward, J., Roques, P., Lewington, G., Cunningham, V.J., & Rossor, M.N. (1995). Deficits in cerebral glucose metabolism demonstrated by positron emission tomography in individuals at risk of familial Alzheimer's disease. *Neuroscience Letters*, Vol. 186, No. 1, (February 1995), pp. 17-20, ISSN 0304-3940
- Kepe, V., Barrio, J.R., Huang, S.C., Ercoli, L., Siddarth, P., Shoghi-Jadid, K., Cole, G.M., Satyamurthy, N., Cummings, J.L., Small, G.W., & Phelps, M.E. (2006). Serotonin 1A receptors in the living brain of Alzheimer's disease patients. *Proceedings of the National Academy of Sciences of the United States of America*, Vol. 103, No. 3, (January 2006), pp.702-707, ISSN 0027-8424
- Kim, D.M., Tien, R., Byrum, C., & Krishnan, K.R. (1996) Imaging in acquired immune deficiency syndrome dementia complex (AIDS dementia complex): a review. *Progress in Neuro-psychopharmacology & Biological Psychiatry*, Vol. 20, No. 3, (April 1996), pp. 349-370, ISSN 0278-5846
- Klunk, W.E., Wang, Y., Huang, G.F., Debnath, M.L., Holt, D.P., & Mathis, C.A. (2001). Uncharged thioflavin-T derivatives bind to amyloid-beta protein with high affinity and readily enter the brain. *Life Sciences*, Vol. 69, No. 13, (August 2001), pp. 1471-1484, ISSN 0024-3205
- Klunk, W.E., Engler, H., Nordberg, A., Wang, Y., Blomqvist, G., Holt, D.P., Bergström, M., Savitcheva, I., Huang, G.F., Estrada, S., Ausén, B., Debnath, M.L., Barletta, J., Price, J.C., Sandell, J., Lopresti, B.J., Wall, A., Koivisto, P., Antoni, G., Mathis, C.A., &

- Långström, B. (2004). Imaging brain amyloid in Alzheimer's disease with Pittsburgh compound-B. *Annals of Neurology*, Vol. 55, No. 3, (March 2004), pp. 306-319, ISSN 0364-5134
- Kuhl, D.E., Koeppe, R.A., Fessler, J.A., Minoshima, S., Ackermann, R.J., Carey, J.E., Gildersleeve, D.L., Frey, K.A., & Wieland, D.M. (1994). In vivo mapping of cholinergic neurons in the human brain using SPECT and IBVM. *Journal of Nuclear Medicine*, Vol. 35, No. 3, (March 1994), pp. 405-410, ISSN 0161-5505
- Kuhl, D.E., Minoshima, S., Fessler, J.A., Frey, K.A., Foster, N.L., Ficarò, E.P., Wieland, D.M., & Koeppe, R.A. (1996). In vivo mapping of cholinergic terminals in normal aging, Alzheimer's disease, and Parkinson's disease. *Annals of Neurology*, Vol. 40, No. 3, (September 1996), pp. 399-410, ISSN 0364-5134
- Kuhl, D.E., Koeppe, R.A., Minoshima, S., Snyder, S.E., Ficarò, E.P., Foster, N.L., Frey, K.A., & Kilbourn, M.R. (1999). In vivo mapping of cerebral acetylcholinesterase activity in aging and Alzheimer's disease. *Neurology*, Vol. 52, No. 4, (March 1999), pp. 691-699, ISSN 0028-3878
- Kuhl, D.E., Minoshima, S., Frey, K.A., Foster, N.L., Kilbourn, M.R., & Koeppe, R.A. (2000). Limited donepezil inhibition of acetylcholinesterase measured with positron emission tomography in living Alzheimer cerebral cortex. *Annals of Neurology*, Vol. 48, No. 3, (September 2000), pp. 391-395, ISSN 0364-5134
- Kung, H.F., Kung, M.P., & Choi, S.R. (2003). Radiopharmaceuticals for single-photon emission computed tomography brain imaging. *Seminars in Nuclear Medicine*, Vol. 33, No. 1, (January 2003), pp. 2-13, ISSN 0001-2998
- Kwan, L.T., Reed, B.R., Eberling, J.L., Schuff, N., Tanabe, J., Norman, D., Weiner, M.W., & Jagust, W.J. (1999). Effects of subcortical cerebral infarction on cortical glucose metabolism and cognitive function. *Archives of Neurology*, Vol. 56, No. 7, (July 1999), pp. 809-814, ISSN 0003-9942
- Lancôt, K.L., Herrmann, N., Nadkarni, N.K., Leibovitch, F.S., Caldwell, C.B., & Black, S.E. (2004). Medial temporal hypoperfusion and aggression in Alzheimer disease. *Archives of Neurology*, Vol. 61, No. 11, (November 2004), pp. 1731-1737, ISSN 0003-9942
- Lancôt, K.L., Moosa, S., Herrmann, N., Leibovitch, F.S., Rothenburg, L., Cotter, A., & Black, S.E. (2007). A SPECT study of apathy in Alzheimer's disease. *Dementia and Geriatric Cognitive Disorders*, Vol. 24, No. 1, (June 2007), pp. 65-72, ISSN 1420-8008
- Levy-Cooperman, N., Burhan, A.M., Rafi-Tari, S., Kusano, M., Ramirez, J., Caldwell, C., & Black, S.E. (2008). Frontal lobe hypoperfusion and depressive symptoms in Alzheimer disease. *Journal of Psychiatry & Neuroscience*, Vol. 33, No. 3, (May 2008), pp. 218-226, ISSN 1180-4882
- Lobotesis, K., Fenwick, J.D., Phipps, A., Ryman, A., Swann, A., Ballard, C., McKeith, I.G., & O'Brien, J.T. (2001). Occipital hypoperfusion on SPECT in dementia with Lewy bodies but not AD. *Neurology*, Vol. 56, No. 5, (March 2001), pp. 643-649, ISSN 0028-3878
- Lojkowska, W., Ryglewicz, D., Jedrzejczak, T., Sienkiewicz-Jarosz, H., Minc, S., Jakubowska, T., & Kozłowicz-Gudzinska, I. (2002). SPECT as a diagnostic test in the investigation of dementia. *Journal of the Neurological Sciences*, Vol. 203-204, (November 2002), pp. 215-219, ISSN 0022-510X
- Mathis, C.A., Bacskai B.J., Kajdasz, S.T., McLellan, M.E., Frosch, M.P., Hyman, B.T., Holt, D.P., Wang, Y., Huang, G.F., Debnath, M.L., & Klunk, W.E. (2002). A lipophilic

- thioflavin-T derivative for positron emission tomography (PET) imaging of amyloid in brain. *Bioorganic & Medicinal Chemistry Letters*, Vol. 12, No. 3, (February 2002), pp. 295–298, ISSN 0960-894X
- McNeill, R., Sare, G.M., Manoharan, M., Testa, H.J., Mann, D.M., Neary, D., Snowden, J.S., & Varma, A.R. (2007). Accuracy of single-photon emission computed tomography in differentiating frontotemporal dementia from Alzheimer's disease. *Journal of Neurology, Neurosurgery and Psychiatry*, Vol. 78, No. 4, (April 2007), pp. 350–355, ISSN 0022-3050
- Meltzer, C.C., Smith, G., DeKosky, S.T., Pollock, B.G., Mathis, C.A., Moore, R.Y., Kupfer, D.J., & Reynolds, C.F. 3rd. (1998). Serotonin in aging, late-life depression, and Alzheimer's disease: the emerging role of functional imaging. *Neuropsychopharmacology*, Vol. 18, No. 6, (June 1998), pp. 407–430, ISSN 0893-133X
- Meltzer, C.C., Price, J.C., Mathis, C.A., Greer, P.J., Cantwell, M.N., Houck, P.R., Mulsant, B.H., Ben-Eliezer, D., Lopresti, B., DeKosky, S.T. & Reynolds, C.F. 3rd. (1999). PET imaging of serotonin type 2A receptors in late-life neuropsychiatric disorders. *The American Journal of Psychiatry*, Vol. 156, No. 12, (December 1999), pp. 1871–1878, ISSN 0002-953X
- Minoshima, S., Foster, N.L., Sima, A.A., Frey, K.A., Albin, R.L., & Kuhl, D.E. (2001). Alzheimer's disease versus dementia with Lewy bodies: cerebral metabolic distinction with autopsy confirmation. *Annals of Neurology*, Vol. 50, No. 3, (September 2001), pp. 358–365, ISSN 0364-5134
- Mori, E., Ishii, K., Hashimoto, M., Imamura, T., Hirono, N., & Kitagaki, H. (1999). Role of functional brain imaging in the evaluation of vascular dementia. *Alzheimer Disease and Associated Disorders*, Vol. 13, Suppl. 3, (October – December 1999), pp. 91–101, ISSN 0893-0341
- Morris, J.C. & Price, A.L. (2001). Pathologic correlates of nondemented aging, mild cognitive impairment, and early-stage Alzheimer's disease. *Journal of Molecular Neuroscience*, Vol. 17, No. 2, (October 2001), pp. 101–118, ISSN 0895-8696
- Mosconi, L., Perani, D., Sorbi, S., Herholz, K., Nacmias, B., Holthoff, V., Salmon, E., Baron, J.C., De Cristofaro, M.T., Padovani, A., Borroni, B., Franceschi, M., Bracco, L. & Pupi, A. (2004). MCI conversion to dementia and the APOE genotype: a prediction study with FDG-PET. *Neurology*, Vol. 63, No. 12, (December 2004), pp. 2332–2340, ISSN 0028-3878
- Nagel, J.S., Ichise, M., & Holman, B.L. (1991). The scintigraphic evaluation of Huntington's disease and other movement disorders using single photon emission computed tomography perfusion brain scans. *Seminars in Nuclear Medicine*, Vol. 21, No. 1, (January 1991), pp. 11–23, ISSN 0001-2998
- Nakano, S., Asada, T., Matsuda, H., Uno, M., & Takasaki, M. (2001). Donepezil hydrochloride preserves regional cerebral blood flow in patients with Alzheimer's disease. *Journal of Nuclear Medicine*, Vol. 42, No. 10, (October 2001), pp. 1441–1445, ISSN 0161-5505
- Nakano, S., Yamashita, F., Matsuda, H., Kodama, C., & Yamada T. (2006). Relationship between delusions and regional cerebral blood flow in Alzheimer's disease. *Dementia and Geriatric Cognitive Disorders*, Vol. 21, No. 1, (December 2006), pp. 16–21, ISSN 1420-8008


- Nelissen, N., Van Laere, K., Thurfjell, L., Owenius, R., Vandenbulcke, M., Koole, M., Bormans, G., Brooks, D.J., & Vandenberghe, R. (2009). Phase 1 study of the Pittsburgh Compound B derivative 18F-Flutemetamol in healthy volunteers and patients with probable Alzheimer Disease. *Journal of Nuclear Medicine*, Vol. 50, No. 8, (August 2009), pp. 1251-1259, ISSN 0161-5505
- Newberg, A.B. & Alavi, A. (2003). Normal patterns and variants in single-photon emission computed tomography and positron emission tomography brain imaging. *Seminars in Nuclear Medicine*, Vol. 33, No. 1, (January 2003), pp. 42-55, ISSN 0001-2998
- Nishimura, T., Hashikawa, K., Fukuyama, H., Kubota, T., Kitamura, S., Matsuda, H., Hanyu, H., Nabatame, H., Oku, N., Tanabe, H., Kuwabara, Y., Jinnouchi, S., & Kubol, A. (2007). Decreased cerebral blood flow and prognosis of Alzheimer's disease: a multicenter HMPAO-SPECT study. *Annals of Nuclear Medicine*, Vol. 21, No. 1, (January 2007), pp. 15-23, ISSN 0914-7187
- Nordberg, A., Hartvig, P., Lilja, A., Viitanen, M., Amberla, K., Lundqvist, H., Andersson, J., Nybäck, H., Ulin, J., & Anderson, Y. (1991). Nicotine receptors in the brain of patients with Alzheimer's disease. Studies with 11C-nicotine and positron emission tomography. *Acta Radiologica Supplementum*, Vol. 376, (1991), pp. 165-166, ISSN 0365-5954
- Nordberg, A., Lundqvist, H., Hartvig, P., Andersson, J., Johansson, M., Hellström-Lindahi, E., & Långström, B. (1997). Imaging of nicotinic and muscarinic receptors in Alzheimer's disease: effect of tacrine treatment. *Dementia and Geriatric Cognitive Disorders*, Vol. 8, No. 2, (March - April 1997), pp. 78-84, ISSN 1420-8008
- Nordberg, A., Amberla, K., Shigeta, M., Lundqvist, H., Viitanen, M., Hellström-Lindahl, E., Johansson, M., Andersson, J., Hartvig, P., Lilja, A., Långström, B., & Winblad, B. (1998). Long-term tacrine treatment in three mild Alzheimer patients: effects on nicotinic receptors, cerebral blood flow, glucose metabolism, EEG, and cognitive abilities. *Alzheimer Disease and Associated Disorders*, Vol. 12, No. 3, (September 1998), pp. 228-237, ISSN 0893-0341
- Nordberg, A. (2008). Amyloid plaque imaging in vivo: current achievement and future prospects. *European Journal of Nuclear Medicine and Molecular Imaging*, Vol. 35, Suppl. 1, (March 2008), pp. 46-50, ISSN 1619-7070
- O'Brien, J.T., Colloby, S., Fenwick, J., Williams, E.D., Firbank, M., Burn, D., Aarsland, D., & McKeith, I.G. (2004). Dopamine transporter loss visualized with FP-CIT SPECT in the differential diagnosis of dementia with Lewy bodies. *Archives of Neurology*, Vol. 61, No. 6, (June 2004), pp. 919-925, ISSN 0003-9942
- Okuda, B., Tachibana, H., Kawabata, K., Takeda, M., & Sugita, M. (2000). Cerebral blood flow in corticobasal degeneration and progressive supranuclear palsy. *Alzheimer Disease and Associated Disorders*, Vol. 14, No. 1, (January - March 2000), pp. 46-52, ISSN 0893-0341
- Ono, M., Kung, M.P., Hou, C., & Kung, H.F. (2002). Benzofuran derivatives as Aβ-aggregate-specific imaging agents for Alzheimer's disease. *Nuclear Medicine and Biology*, Vol. 29, No. 6, (August 2002), pp. 633-642, ISSN 0969-8051
- Ono, M., Yoshida, N., Ishibashi, K., Haratake, M., Arano, Y., Mori, H., & Nakayama, M. (2005). Radioiodinated flavones for in vivo imaging of beta-amyloid plaques in the brain. *Journal of Medicinal Chemistry*, Vol. 48, No. 23, (November 2005), pp. 7253-7260, ISSN 0022-2623

- Ono, M., Maya, Y., Haratake, M., Ito, K., Mori, H., & Nakayama, M. (2007). Aurones serve as probes of b-amyloid plaques in Alzheimer's disease. *Biochemical and Biophysical Research Communications*, Vol. 361, No. 1, (September 2007), pp. 116-121, ISSN 0006-291X
- Pappata, S., Tavitian, B., Traykov, L., Jobert, A., Dalger, A., Mangin, J.F., Crouzel, C., & DiGiambardino, L. (1996). In vivo imaging of human cerebral acetylcholinesterase. *Journal of Neurochemistry*, Vol. 67, No. 2, (August 1996), pp. 876-879, ISSN 0022-3042
- Pasquier, J., Michel, B.F., Brenot-Rossi, I., Hassan-Sebbag, N., Sauvan, R., & Gastaut, J.L. (2002). Value of (99m)Tc-ECD SPET for the diagnosis of dementia with Lewy bodies. *European Journal of Nuclear Medicine and Molecular Imaging*, Vol. 29, No. 10, (October 2002), pp. 1342-1348, ISSN 1619-7070
- Pávics, L., Grünwald, F., Reichmann, K., Horn, R., Kitschenberg, A., Hartmann, A., Menzel, C., Schomburg, A.G., Overbeck, B., Csernay, L., & Biersack, H.J. (1999). Regional cerebral blood flow single-photon emission tomography with 99mTc-HMPAO and the acetazolamide test in the evaluation of vascular and Alzheimer's dementia. *European Journal of Nuclear Medicine*, Vol. 26, No. 3, (March 1999), pp. 239-245, ISSN 0340-6997
- Perneczky, R., Diehl-Schmid, J., Pohl, C., Drzezga, A., & Kurz, A. (2007). Non-fluent progressive aphasia: cerebral metabolic patterns and brain reserve. *Brain Research*, Vol. 1133, No. 1, (February 2007), pp. 178-185, ISSN 0006-8993
- Piggott, M.A., Marshall, E.F., Thomas, N., Lloyd, S., Court, J.A., Jaros, E., Burn, D., Johnson, M., Perry, R.H., McKeith, I.G., Ballard, C., & Perry, E.K. (1999). Striatal dopaminergic markers in dementia with Lewy bodies, Alzheimer's and Parkinson's disease; rostro-caudal distribution. *Brain*, Vol. 122, No. Pt 8, (August 1999), pp. 1449-1468, ISSN 0006-8950
- Pimlott, S.L. (2005). Radiotracer development in psychiatry. *Nuclear Medicine Communications*, Vol. 26, No. 3, (March 2005), pp. 183-188, ISSN 0143-3636
- Pirker, W., Asenbaum, S., Bencsits, G., Prayer, D., Gerschlager, W., Deecke, L., & Brücke, T. (2000). [123I]beta-CIT SPECT in multiple system atrophy, progressive supranuclear palsy, and corticobasal degeneration. *Movement Disorders*, Vol. 15, No. 6, (November 2000), pp. 1158-1167, ISSN 1531-8257
- Reiman, E.M., Caselli, R. J., Chen, K., Alexander, G.E., Bandy, D., & Frost, J. (2001). Declining brain activity in cognitively normal apolipoprotein E epsilon 4 heterozygotes: A foundation for using positron emission tomography to efficiently test treatments to prevent Alzheimer's disease. *Proceedings of the National Academy of Sciences of the United States of America*, Vol. 98, No. 6, (March 2001), pp. 3334-3339, ISSN 0027-8424
- Rezai-Zadeh, K., Ehrhart, J., Bai, Y., Sanberg, P.R., Bickford, P., Tan, J., & Shytle, R.D. (2008). Apigenin and luteolin modulate microglial activation via inhibition of STAT1-induced CD40 expression. *Journal of Neuroinflammation*, Vol. 5, (September 2008), pp. 41, ISSN 1742-2094
- Rodriguez, G., Nobili, F., Copello, F., Vitali, P., Gianelli, M.V., Taddei, G., Catsafados, E., & Mariani, G. (1999). 99mTc-HMPOA regional cerebral blood flow and quantitative electroencephalography in Alzheimer's disease: a correlative study. *Journal of Nuclear Medicine*, Vol. 40, No. 4, (April 1999), pp. 522-529, ISSN 0161-5505

- Rossor, M.N., Iversen, L.L., Reynolds, G.P., Mountjoy, C.Q., & Roth, M. (1984). Neurochemical characteristics of early and late onset types of Alzheimer's disease. *British Medical Journal (Clinical Research Ed.)*, Vol. 288, No. 6422, (March 1984), pp. 961-964, ISSN 0267-0623
- Shibata, K., Narumoto, J., Kitabayashi, Y., Ushijima, Y., & Fukui, K. (2008). Correlation between anosognosia and regional cerebral blood flow in Alzheimer's disease. *Neuroscience Letters*, Vol. 435, No. 1, (April 2008), pp. 7-10, ISSN 0304-3940
- Shoghi-Jadid, K., Small, G.W., Agdeppa, E.D., Kepe, V., Ercoli, L.M., Siddarth, P., Read, S., Satyamurthy, N., Petric, A., Huang, S.C., & Barrio, J.R. (2002). Localization of neurofibrillary tangles and beta-amyloid plaques in the brains of living patients with Alzheimer disease. *The American Journal of Geriatric Psychiatry*, Vol. 10, No. 1, (January - February 2002), pp. 24-35, ISSN 1064-7481
- Sihver, W., Fath, K.J., Ogren, M., Lundqvist, H., Bergström, M., Watanabe, Y., Långström, B., & Nordberg, A. (1999). In vivo positron emission tomography studies on the novel nicotinic receptor agonist [11C]MPA compared with [11C]ABT-418 and (S)-[11C]nicotine in rhesus monkeys. *Nuclear Medicine and Biology*, Vol. 26, No. 6, (August 1999), pp. 633-640, ISSN 0969-8051
- Silverman, D.H., Small, G.W., Chang, C.Y., Lu, C.S., Kung, D.E., Aburto, M.A., Chen, W., Czernin, J., Rapoport, S.I., Pietrini, P., Alexander, G.E., Schapiro, M.B., Jagust, W.J., Hoffman, J.M., Welsh-Bohmer, K.A., Alavi, A., Clark, C.M., Salmon, E., de Leon, M.J., Mielke, R., Cummings, J.L., Kowell, A.P., Gambhir, S.S., Hoh, C.K., & Phelps, M.E. (2001). Positron emission tomography in evaluation of dementia: Regional brain metabolism and long-term outcome. *The Journal of the American Medical Association*, Vol. 286, No. 17, (November 2001), pp. 2120-2127, ISSN 0002-9955
- Silverman, D.H., Gambhir, S.S., Huang, H.W., Schwimmer, J., Kim, S., Small, G.W., Chodosh, J., Czernin, J., & Phelps, M.E. (2002). Evaluating early dementia with and without assessment of regional cerebral metabolism by PET: a comparison of predicted costs and benefits. *Journal of Nuclear Medicine*, Vol. 43, No. 2, (February 2002), pp. 253-266, ISSN 0161-5505
- Sinnatamby, R., Antoun, N.A., Freer, C.E., Miles, K.A., & Hodges, J.R. (1996). Neuroradiological findings in primary progressive aphasia: CT MRI and cerebral perfusion SPECT. *Neuroradiology*, Vol. 38, No. 3, (April 1996), pp. 232-238, ISSN 0028-3940
- Small, G.W., Ercoli, L.M., Silverman, D.H., Huang, S.C., Komo, S., Bookheimer, S.Y., Lavretsky, H., Miller, K., Siddarth, P., Rasgon, N.L., Mazziotta, J.C., Saxena, S., Wu, H.M., Mega, M.S., Cummings, J.L., Saunders, A.M., Pericak-Vance, M.A., Roses, A.D., Barrio, J.R., & Phelps, M.E. (2000). Cerebral metabolic and cognitive decline in persons at genetic risk for Alzheimer's disease. *Proceedings of the National Academy of Sciences of the United States of America*, Vol. 97, No. 11, (May 2000), pp. 6037-6042, ISSN 0027-8424
- Spampinato, U., Habert, M.O., Mas, J.L., Bourdel, M.C., Ziegler, M., de Recondo, J., Askienazy, S., & Rondot, P. (1991). (99mTc)-HM-PAO SPECT and cognitive impairment in Parkinson's disease: a comparison with dementia of the Alzheimer type. *Journal of Neurology, Neurosurgery and Psychiatry*, Vol. 54, No. 9, (September 1991), pp. 787-792, ISSN 0022-3050

- Staff, R.T., Gemmell, H.G., Shanks, M.F., Murray, A.D., & Venneri, A. (2000). Changes in the rCBF images of patients with Alzheimer's disease receiving Donepezil therapy. *Nuclear Medicine Communications*, Vol. 21, No. 1, (January 2000), pp. 37-41, ISSN 0143-3636
- Stein, D.J., Buchsbaum, M.S., Hof, P.R., Siegel, B.V. Jr, & Shihabuddin, L. (1998). Greater metabolic rate decreases in hippocampal formation and proisocortex than in neocortex in Alzheimer's disease. *Neuropsychobiology*, Vol. 37, No. 1, (December 1998), pp. 10-19, ISSN 0302-282X
- Svensson, A.L. & Nordberg, A. (1996). Tacrine interacts with an allosteric activator site on alpha 4 beta 2 nAChRs in M10 cells. *Neuroreport*, Vol. 7, No. 13, (September 1996), pp. 2201-2205, ISSN 0959-4965
- Tanaka, H. & Mizojiri, K. (1999). Drug-protein binding and blood-brain barrier permeability. *The Journal of Pharmacology and Experimental Therapeutics*, Vol. 288, No. 3, (March 1999), pp. 912-918, ISSN 0022-3565
- Tateno, M., Kobayashi, S., Shirasaka, T., Furukawa, Y., Fujii, K., Morii, H., Yasumura, S., Utsumi, K., & Saito, T. (2008). Comparison of the usefulness of brain perfusion SPECT and MIBG myocardial scintigraphy for the diagnosis of dementia with Lewy bodies. *Dementia and Geriatric Cognitive Disorders*, Vol. 26, No. 5, (November 2008), pp. 453-457, ISSN 1420-8008
- Tatsch, K., Schielke, E., Bauer, W.M., Markl, A., Einhäupl, K.M., & Kirsch, C.M. (1990). Functional and morphological findings in early and advanced stages of HIV infection: a comparison of ^{99m}Tc-HMPAO SPECT with CT and MRI studies. *Nuklearmedizin*, Vol. 29, No. 6, (December 1990), pp. 252-258, ISSN 0029-5566
- Tikofsky, R.S. & Hellman, R.S. (1991). Brain single photon emission computed tomography: new activation and intervention studies. *Seminars in Nuclear Medicine*, Vol. 21, No. 1, (January 1991), pp. 40-57, ISSN 0001-2998
- Traykov, L., Tavitian, B., Jobert, A., Boller, F., Forette, F., Crouzel, C., Di Giamberardino, L., & Pappata, S. (1999). In vivo PET study of cerebral [¹¹C] methyl-tetrahydroaminoacridine distribution and kinetics in healthy human subjects. *European Journal of Neurology*, Vol. 6, No. 3, (May 1999), pp. 273-278, ISSN 1471-0552
- van Dyck, C.H., Lin, C.H., Robinson, R., Cellar, J., Smith, E.O., Nelson, J.C., Arnsten, A.F., & Hoffer, P.B. (1997). The acetylcholine releaser linopirdine increases parietal regional cerebral blood flow in Alzheimer's disease. *Psychopharmacology*, Vol. 132, No. 3, (August 1997), pp. 217-226, ISSN 0033-3158
- Valotassiou, V., Archimandritis, S., Sifakis, N., Papatriantafyllou, J., & Georgoulas, P. (2010). Alzheimer's disease: SPECT and PET tracers for beta-amyloid imaging. *Current Alzheimer Research*, Vol. 7, No. 6, (September 2010), pp. 477-486, ISSN 1567-2050
- Verhoeff, N.P., Wilson, A.A., Takeshita, S., Trop, L., Hussey, D., Singh, K., Kung, H.F., Kung, M.P., & Houle, S. (2004). In-vivo imaging of Alzheimer disease beta-amyloid with [¹¹C]SB-13 PET. *The American Journal of Geriatric Psychiatry*, Vol. 12, No. 6, (November - December 2004), pp. 584-595, ISSN 1064-7481
- Versijpt, J.J., Dumont, F., Van Laere, K.J., Decoo, D., Santens, P., Audenaert, K., Achten, E., Slegers, G., Dierckx, R.A., & Korf, J. (2003). Assessment of neuroinflammation and microglial activation in Alzheimer's disease with radiolabelled PK11195 and single photon emission computed tomography. A pilot study. *European Neurology*, Vol. 50, No. 1, (June 2003), pp. 39-47, ISSN 0014-3022

- Villemagne, V.L., Horti, A., Scheffel, U., Ravert, H.T., Finley, P., Clough, D.J., London, E.D., Wagner, H.N. Jr, & Dannals, R.F. (1997). Imaging nicotinic acetylcholine receptors with fluorine-18-FPH, an epibatidine analog. *Journal of Nuclear Medicine*, Vol. 38, No. 11, (November 1997), pp. 1737-1741, ISSN 0161-5505
- Villemagne, V.L., Rowe, C.C., Macfarlane, S., Novakovic, K.E., & Masters, C.L. (2005). Imaginem oblivionis: the prospects of neuroimaging for early detection of Alzheimer's disease. *Journal of Clinical Neuroscience*, Vol. 12, No. 3, (April 2005), pp. 221-230, ISSN 0967-5868
- Volkow, N.D., Ding, Y.S., Fowler, J.S., & Gatley, S. (2001). Imaging brain cholinergic activity with positron emission tomography: its role in the evaluation of cholinergic treatments in Alzheimer's dementia. *Biological Psychiatry*, Vol. 49, No. 3, (February 2001), pp. 211-220, ISSN 0006-3223
- Walker, L.C., Price, D.L., Voytko, M.L., & Schenk, D.B. (1994). Labeling of cerebral amyloid in vivo with a monoclonal antibody. *Journal of Neuropathology and Experimental Neurology*, Vol. 53, No. 4, (July 1994), pp. 377-383, ISSN 0022-3069
- Walker, Z., Costa, D.C., Walker, R.C., Shaw, K., Gacinovic, S., Stevens, T., Livingston, G., Ince, P., McKeith, I.G., & Katona, C.L. (2002). Differentiation of dementia with Lewy bodies from Alzheimer's disease using a dopaminergic presynaptic ligand. *Journal of Neurology, Neurosurgery and Psychiatry*, Vol. 73, No. 2, (August 2002), pp. 134-140, ISSN 0022-3050
- Walovitch, R.C., Cheesman, E.H., Maheu, L.J., & Hall, K.M. (1994). Studies of the retention mechanism of the brain perfusion imaging agent ^{99m}Tc-bicisate (^{99m}Tc-ECD). *Journal of Cerebral Blood Flow and Metabolism*, Vol. 14, Suppl. 1, (January 1994), pp. 4-11, ISSN 0271-678X
- Waterhouse, R.N. (2003). Determination of lipophilicity and its use as a predictor of blood-brain barrier penetration of molecular imaging agents. *Molecular Imaging and Biology*, Vol. 5, No. 6, (November - December 2003), pp. 376-389, ISSN 1536-1632
- Weinstein, H.C., Hijdra, A., Van Royen, E.A., Derix, M.M., Walstra, G., & Jonker, C. (1991). SPECT in early- and late-onset Alzheimer's disease. *Annals of the New York Academy of Sciences*, Vol. 640, (1991), pp. 72-73, ISSN 0077-8923
- Wong, D.F. & Pomper, M.G. (2003). Predicting the success of a radiopharmaceutical for in vivo imaging of central nervous system neuroreceptor systems. *Molecular Imaging and Biology*, Vol. 5, No. 6, (November - December 2003), pp. 350-362, ISSN 1536-1632
- Xu, Y., Jack, C.R. Jr, O'Brien, P.C., Kokmen, E., Smith, G.E., Ivnik, R.J., Boeve, B.F., Tangalos, R. G., & Petersen, R.C. (2000). Usefulness of MRI measures of entorhinal cortex versus hippocampus in AD. *Neurology*, Vol. 54, No. 9, (May 2000), pp. 1760-1767, ISSN 0028-3878
- Ye, L., Morgenstern, J.L., Gee, A.D., Hong, G., Brown, J., & Lockhart, A. (2005). Delineation of positron emission tomography imaging agent binding sites on beta-amyloid peptide fibrils. *The Journal of Biological Chemistry*, Vol. 280, No. 25, (June 2005), pp. 23599-23604, ISSN 0021-9258
- Zhuang, Z.P., Kung, M.P., Hou, C., Skovronsky, D.M., Gur, T.L., Plössl, K., Trojanowski, J.Q., Lee, V.M., & Kung, H.F. (2001). Radioiodinated styrylbenzenes and thioflavins as probes for amyloid aggregates. *Journal of Medicinal Chemistry*, Vol. 44, No. 12, (June 2001), pp. 1905-1914, ISSN 0022-2623



The Clinical Spectrum of Alzheimer's Disease -The Charge Toward Comprehensive Diagnostic and Therapeutic Strategies

Edited by Dr. Suzanne De La Monte

ISBN 978-953-307-993-6

Hard cover, 362 pages

Publisher InTech

Published online 06, September, 2011

Published in print edition September, 2011

The Clinical Spectrum of Alzheimer's Disease: The Charge Toward Comprehensive Diagnostic and Therapeutic Strategies is highly informative and current. Acknowledged experts in the field critically review both standard and under-appreciated clinical, behavioral, epidemiological, genetic, and neuroimaging attributes of Alzheimer's disease. The collection covers diverse topics of interest to clinicians and researchers alike. Experienced professionals and newcomers to the field will benefit from the read. The strengths and weaknesses of current clinical, non-invasive, neuro-imaging, and biomarker diagnostic approaches are explained. The perspectives give fresh insights into the process of neurodegeneration. Readers will be enlightened by the evidence that the neural circuits damaged by neurodegeneration are much broader than conventionally taught, suggesting that Alzheimer's could be detected at earlier stages of disease by utilizing multi-pronged diagnostic approaches. This book inspires renewed hope that more effective treatments could be developed based upon the expanding list of potential therapeutic targets.

How to reference

In order to correctly reference this scholarly work, feel free to copy and paste the following:

Varvara Valotassiou, Nikolaos Sifakis, John Papatriantafyllou, George Angelidis and Panagiotis Georgoulas (2011). The Clinical Use of SPECT and PET Molecular Imaging in Alzheimer's Disease, The Clinical Spectrum of Alzheimer's Disease -The Charge Toward Comprehensive Diagnostic and Therapeutic Strategies, Dr. Suzanne De La Monte (Ed.), ISBN: 978-953-307-993-6, InTech, Available from: <http://www.intechopen.com/books/the-clinical-spectrum-of-alzheimer-s-disease-the-charge-toward-comprehensive-diagnostic-and-therapeutic-strategies/the-clinical-use-of-spect-and-pet-molecular-imaging-in-alzheimer-s-disease>

INTECH
open science | open minds

InTech Europe

University Campus STeP Ri
Slavka Krautzeka 83/A
51000 Rijeka, Croatia
Phone: +385 (51) 770 447
Fax: +385 (51) 686 166
www.intechopen.com

InTech China

Unit 405, Office Block, Hotel Equatorial Shanghai
No.65, Yan An Road (West), Shanghai, 200040, China
中国上海市延安西路65号上海国际贵都大饭店办公楼405单元
Phone: +86-21-62489820
Fax: +86-21-62489821

© 2011 The Author(s). Licensee IntechOpen. This chapter is distributed under the terms of the [Creative Commons Attribution-NonCommercial-ShareAlike-3.0 License](#), which permits use, distribution and reproduction for non-commercial purposes, provided the original is properly cited and derivative works building on this content are distributed under the same license.

IntechOpen

IntechOpen