

We are IntechOpen, the world's leading publisher of Open Access books Built by scientists, for scientists

4,800

Open access books available

122,000

International authors and editors

135M

Downloads

Our authors are among the

154

Countries delivered to

TOP 1%

most cited scientists

12.2%

Contributors from top 500 universities



WEB OF SCIENCE™

Selection of our books indexed in the Book Citation Index
in Web of Science™ Core Collection (BKCI)

Interested in publishing with us?
Contact book.department@intechopen.com

Numbers displayed above are based on latest data collected.

For more information visit www.intechopen.com



Lipoplasty of the Back

Francisco Agullo, Sadri O. Sozer and Humberto Palladino
*Texas Tech University Health Sciences Center El Paso,
Paul L. Foster School of Medicine, and El Paso Cosmetic Surgery
United States*

1. Introduction

Suction lipectomy is among the most common invasive surgical procedures performed. The most common target area is the abdomen although other body parts such as flanks, thighs, arms and breast are also subject to lipoplasty in the hands of the most experienced practitioners.

In recent years and with the increase in body contouring demand as a result of the popularity of the bariatric procedures the back has presented as a challenging area to treat. Although there are few publications available addressing this important anatomic area, a broad spectrum of techniques has been utilized to address this problem, and following the usual trend a most conservative approach is preferred.

Geometrically speaking, the waist and back area form an “hourglass figure”. [1, 2] This ideal shape provides much insight into how any lipodystrophy should be treated.

2. Indications

Ideal candidates for lipoplasty of the back present with excess subcutaneous fat in the flank and back which often create “rolls”. There are many techniques available to treat excess skin and fat in the trunk area. Liposuction is an excellent treatment method for the back and flanks in most circumstances. Excess skin with laxity, stretch marks, or a lack of excess subcutaneous fat are clear contraindications.

As with any surgical procedure, a strict preoperative workup is essential to determine risk factors and optimize postoperative results.

3. Technique

Suction assisted lipectomy (SAL) and most recently, ultrasound assisted lipectomy (UAL) and laser assisted lipaectomy (LAL), play an essential role in the management of this problem. While direct excision is the method of choice for those cases where a significant amount of excess tissue is present, liposuction is the alternative for patients in the obese and overweight group with mild to moderate excess tissue. This technique has the benefit of being significantly less invasive and morbid than direct excision avoiding incisional complications and the presence of scars across the back.

The back should be addressed as a three dimensional structure and different considerations apply to male and females. Female’s back has a lateral contour with widening at the level of

the ribs and hips. The center portion is narrow and this creates a more appealing lateral contour. From the lateral view, the midline shows a superior kyphosis and lumbar lordosis accentuating the shape of the buttocks. In males this is different, with narrower hips translating into a V shape type due to the difference in the fat deposits and more muscular structure. [3]

There are many fibrous connections between the superficial fat of the back and the underlying fascia that often form into rolls. There is a lack of medical literature on treatment through liposuction of fat rolls. Some authors have described a direction for suctioning that is parallel to the fat roll axis. Other authors have described the release of folds in a transverse manner. Some have even advocated a cranio-caudal axis of liposuction.

We individualize the treatment per patient. Different cannulas and type of liposuction are selected for different patients. Body habitus, quality of skin, sex, age, race and amount and distribution of subcutaneous tissue are taken in consideration when making the decision. In our practice we utilize tumescent technique with SAL and UAL. We have not personally used the LAL and although we are aware of its advantages, there has not been consistent scientific proof that LAL is better than SAL or the combination of SAL and UAL. The cannulas are usually of large diameter and multiple access points are utilized using a crisscross technique to cover the large back surface including paraspinal, bra line, infrascapular, flanks, and lumbar regions.

In males we always combined the UAL with SAL since the tissues are denser with greater amount of fibrous connections between the superficial fat and underlying fascia. Some females with lax tissues have been treated with SAL alone although the tissues of the flanks and back often times are denser and require UAL to obtain an optimal result. [4]

Most of the time, four incisions are utilized to perform adequate liposuction of the back. One incision is placed at the midline of the bra strap area, one incision above the buttock cleft at the level of the sacrum, and two incisions at the waistline, one for each side. In certain cases, two to three incisions per side are required to be able to perform the multiplane liposuction appropriately.

In our series of patients treated with this modality we routinely achieve a significant improvement in the contour of the back, flanks, lumbar and gluteal area. By combining liposuction with fat grafting techniques we broaden the possibilities of improvement addressing not only the back but also the surrounding areas thus, providing an optimal result for the patient. Fat grafting of the buttocks along with suction lipectomy of the lumbar, flanks and upper back significantly impact the overall result by emphasizing the projection of the buttocks and reshaping the lumbar contour at the same time. The suction lipectomy of the upper back and flanks allows for the harvest of the adipose tissue to be transplanted removing the usual creases on the lateral upper back and flank regions.

As a side note, besides the aesthetic improvement of the back and lumbosacral area there could be an added benefit in cases of back pain, with improvement and strengthening of the paraspinal muscles. [5]

4. Complications

In our experience, complications of lipoplasty in the back are rare when performed by experienced surgeons. The back and flanks are very “forgiving” areas for lipoplasty, making deformities due to superfluous liposuction extremely rare. The most common complication is under-correction of the deformities and need for a secondary “revision” procedure.

Hyperpigmentation of the liposuction port scars is common, specially in Hispanic and black patients. This pigmentation is often post-inflammatory hyperpigmentation and resolves over a period of four to six months.

Although other complications are rare, they are still possible and thus described at length in the “Complications of Liposuction” chapter.

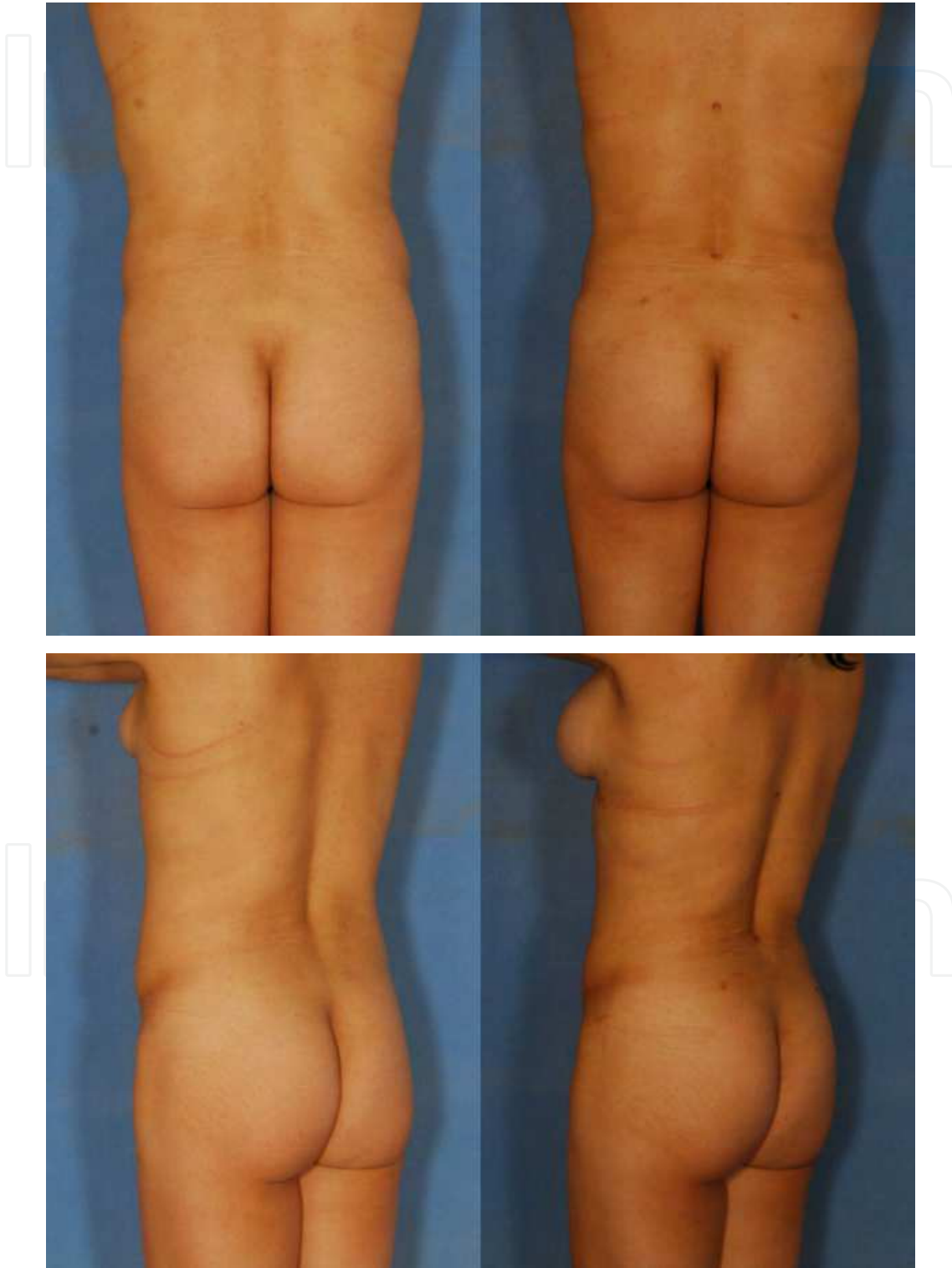


Fig. 1. Liposuction of the back and fat injections to the buttocks.

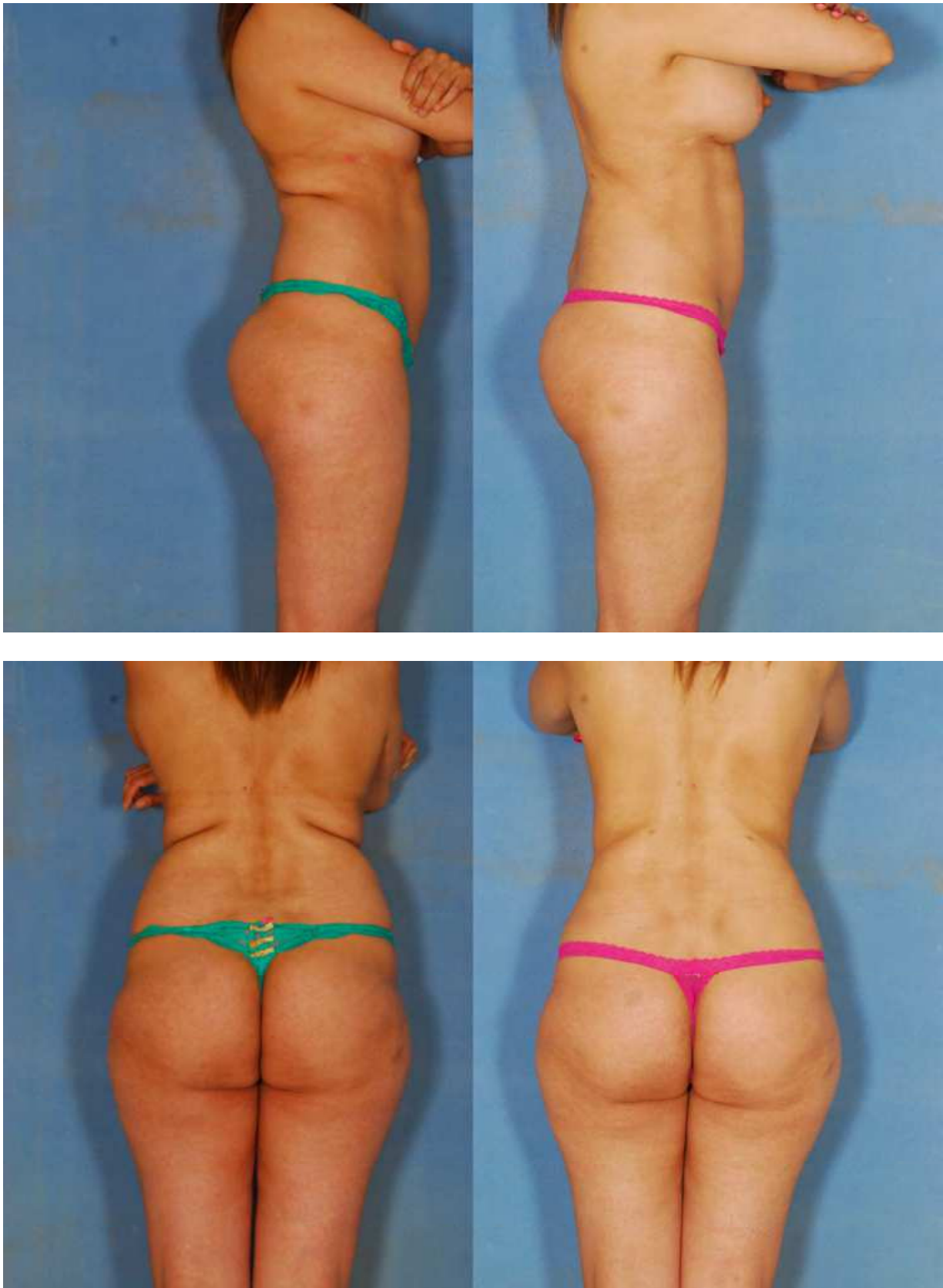


Fig. 2. Ultrasound assisted liposuction of the back.

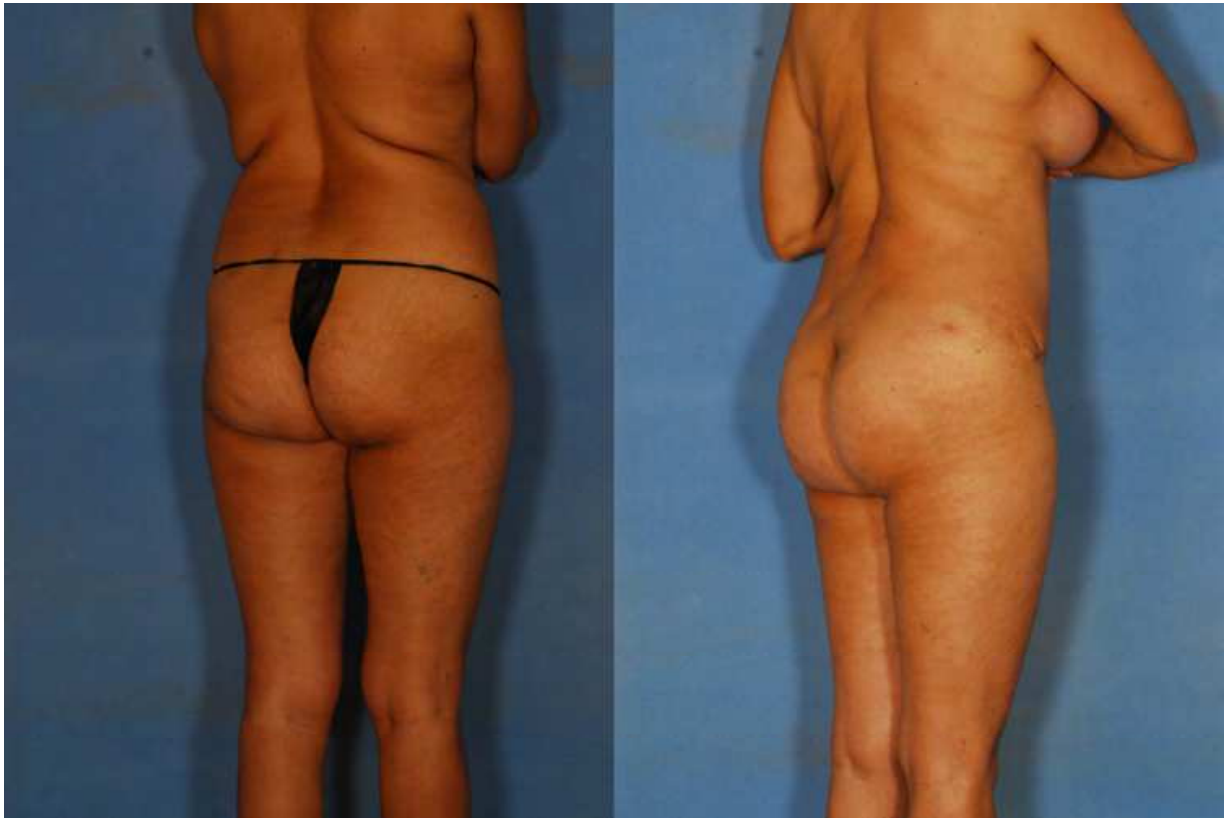

Fig. 3. Suction assisted liposuction of the back and fat injections to the buttocks.

5. Conclusion

Suction lipectomy of the back has become an essential tool in body contouring. The combination of these techniques with fat grafting allows simultaneous improvement of many areas in the back resulting in a significant overall enhancement of the body contour.


6. References

- [1] Pawlowski B, Grabarczyk M: Center of body mass and the evolution of female body shape. *Am J Hum Biol* 2003, 15(2):144-150.
- [2] Apfelberg DB: The vast "waistland": a rediscovered area in liposuction. *Ann Plast Surg* 1994, 33(3):237-240.
- [3] Matarasso SL: Liposuction of the chest and back. *Dermatol Clin* 1999, 17(4):799-804, vi.
- [4] Zocchi ML: Ultrasonic assisted lipoplasty. Technical refinements and clinical evaluations. *Clin Plast Surg* 1996, 23(4):575-598.

- [5] Theron J, Guimaraens L, Casasco A, Coellar H, Sola T: Lumbosacral liposuction. A new tool for the treatment of low back pain. *Interv Neuroradiol* 2007, 13(2):153-160.

IntechOpen

IntechOpen



Advanced Techniques in Liposuction and Fat Transfer

Edited by Prof. Nikolay Serdev

ISBN 978-953-307-668-3

Hard cover, 230 pages

Publisher InTech

Published online 12, September, 2011

Published in print edition September, 2011

Liposuction is the first cosmetic procedure to change beautification surgery from open extensive excision surgery into a more atraumatic closed one. It gave rise to the modern understanding of minimally scarring and minimally invasive surgery and changed the understanding and preferences of both patients and doctors. It also became the most common procedure in cosmetic surgery world-wide, practiced by an increased number of physicians from various specialties. The techniques of fat grafting, closely bound with liposuction, have found widespread application and fat stem cells seem to be changing the future of many areas in medicine. Turning the pages, the reader will find a lot of information about advances, tips and tricks, as well as important milestones in the development of the different methods available, such as classic, power, ultrasound, laser and radio-frequency assisted liposuction etc. Most useful anesthesia techniques are described and discussed, and guidelines have been established for medical indications. Special attention is paid to good patient selection, complications and risks.

How to reference

In order to correctly reference this scholarly work, feel free to copy and paste the following:

Francisco Agullo, Sadri O. Sozer and Humberto Palladino (2011). Lipoplasty of the Back, *Advanced Techniques in Liposuction and Fat Transfer*, Prof. Nikolay Serdev (Ed.), ISBN: 978-953-307-668-3, InTech, Available from: <http://www.intechopen.com/books/advanced-techniques-in-liposuction-and-fat-transfer/lipoplasty-of-the-back>

INTECH
open science | open minds

InTech Europe

University Campus STeP Ri
Slavka Krautzeka 83/A
51000 Rijeka, Croatia
Phone: +385 (51) 770 447
Fax: +385 (51) 686 166
www.intechopen.com

InTech China

Unit 405, Office Block, Hotel Equatorial Shanghai
No.65, Yan An Road (West), Shanghai, 200040, China
中国上海市延安西路65号上海国际贵都大饭店办公楼405单元
Phone: +86-21-62489820
Fax: +86-21-62489821

© 2011 The Author(s). Licensee IntechOpen. This chapter is distributed under the terms of the [Creative Commons Attribution-NonCommercial-ShareAlike-3.0 License](#), which permits use, distribution and reproduction for non-commercial purposes, provided the original is properly cited and derivative works building on this content are distributed under the same license.

IntechOpen

IntechOpen