

We are IntechOpen, the world's leading publisher of Open Access books Built by scientists, for scientists

4,800

Open access books available

122,000

International authors and editors

135M

Downloads

Our authors are among the

154

Countries delivered to

TOP 1%

most cited scientists

12.2%

Contributors from top 500 universities



WEB OF SCIENCE™

Selection of our books indexed in the Book Citation Index
in Web of Science™ Core Collection (BKCI)

Interested in publishing with us?
Contact book.department@intechopen.com

Numbers displayed above are based on latest data collected.

For more information visit www.intechopen.com



The Transplantation Operation and Its Surgical Complications

Junjie Zhao, Zhenli Gao and Ke Wang
*Yantai YuHuangDing Hospital
China*

1. Introduction

Over the past decades, the outcomes of kidney transplantation have improved markedly due to advancements in prevention and treatment of acute rejection episodes, management of posttransplant complications and better knowledge of immunosuppressive drugs. As a result, transplantation has become the mainstay and preferred treatment for patients of all ages with end-stage renal disease. However, the surgical technique for renal transplantation has changed little from the original pelvic operation described in 1951 by Küss et al. It seems the operation has been standardized and there is little need for further discussions over the topic. In fact, the argumentation on surgical technique has never ceased since its birth, for optimization of the surgical outcomes, many aspects of operative techniques have been modified and novel techniques have been invented. In modern immunosuppressive era, the pattern of surgical complications has evolved and gains some fresh features. In this chapter, we will review the standard operative procedures performed today and introduce the updated surgical techniques as well. Meanwhile, the characteristics of major surgical complications and the evolvement of their diagnosis and treatment will be expatiated on. After all, the surgical operation is invariably the key of a successful transplantation; surgical techniques are constantly related to the morbidity and mortality of the patients.

2. Standard surgical technique on kidney transplantation

The standard kidney transplant procedure is the pelvic operation originally used by French surgeons Küss, Dubost, and Servelle and their associates in 1951 and refined subsequently by Murray and Harrison for the first successful kidney transplantation in human history. The heterotopic pelvic approach has been widely accepted for its multiple advantages and considered a standard access. The classical surgical techniques of revascularization and urinary tract reconstruction have also been broadly used to this day. Each renal transplantation operation is a review of original historic work both in urological and vascular discipline.

2.1 Site

The operative site for standard kidney transplantation is pelvic fossa, however, there is always a disagreement on the criteria to select the appropriate side to accommodate the transplant. Initially, it is recommended that placing the donor kidney in the recipient's

contralateral side to ensure the renal pelvis and ureter are anterior in case those future surgeries are required (John, 2002). Afterward, it is stated that the more important consideration is to avoid sites of previous transplants, other operations, or peritoneal dialysis catheters though the dissection on the right is slightly easier (James, 2004). Subsequently, suggestion from scholars is presented that each side of the recipient's pelvis is acceptable, however the right external iliac vessels are longer and more horizontal compared to the left side, which facilitates the vascular anastomoses (Stuart, 2008). With progresses of surgical technique and accumulation of clinical experience the concept of selecting the right pelvic fossa as the preferred site for the first transplantation has been universally accepted. However, the ipsilateral severe atherosclerotic vascular disease, venous disorders such as previous deep venous thromboses and femoral dialysis catheters should be routinely excluded. The peritoneal dialysis catheters and previous minor abdominal operation such as appendectomy, conventional herniorrhaphy are not absolute contraindications according to our experiences. It also elicits one issue for nephrologists that the initial peritoneal dialysis catheter or femoral dialysis catheter is properly intubated on the left side for the potential renal recipients. The standard Gibson incision can avoid most stoma of peritoneal dialysis catheters. On the other hand, the minor transperitoneal surgeries or small operations on abdominal wall usually yield limited adhesion at the place to accomplish the transplantation. But, the transplantation is strongly not recommended at the side where has a history of herniorrhaphy with propylene mesh or ipsilateral open operation of ureter and bladder. Because the propylene mesh results in inflammatory response and connective tissue proliferation conducting to fibrosis formation and a thick scar plate on the inner surface of lower abdominal wall, which make the dissection of bladder a formidable task. Previous ipsilateral pelvic surgeries generally preclude the sequent transplantation due to local inordinate anatomical features and severe perivesical tissue conglutination. Massively enlarged polycystic kidneys are challenges for urologists; one would choose the side of the smaller kidney. However, bilateral extremely enlarged polycystic kidneys would make the transplant surgery very difficult or impossible. In that occasion, right or bilateral native nephrectomy might be considered. Sequential and simultaneous laparoscopic bilateral native nephrectomies have all been testified safe and effective. For the second transplantation patients the kidney is implanted on the contralateral side, usually left side.

2.2 Incision and exposure

The kidney transplant operation can be performed via many different routes, however two important issues must be considered when deciding the incision for a renal transplant: a good access to the iliac fossa and bladder and a minimal rate of wound related morbidity. Historically, three classic incisions have been recommended for kidney transplant surgery: pelvic Gibson incision, the hockey stick incision and oblique incision. Curvilinear incision made in lower quadrant of the abdomen, known as the "pelvic Gibson incision", which affords relatively atraumatic and convenient access to the iliac fossa and bladder is mainly used for renal transplantation. Oblique incision and inverted J-shaped incision, known as the "hockey stick incision" are the other two frequently used incisions in some centers. Nanni and colleagues compared the two incisions with regard to the incidence of long-term complications, they concludes that the oblique surgical incision was better than the hockey-stick incision for lower incidence of hernia and abdominal wall relaxation and the more favorable cosmetic results (Nanni et al. 2005). Paramedian, midline incision and even

transverse incision are lately introduced to the practice of living kidney transplantation for better cosmetic appearance, but these incisions are of same inherent drawback of difficult exposure of operative bed, which can be possible alternatives for special candidates. (Filocamo et al., 2007; Park et al., 2008).

When a Gibson incision is made, the external oblique muscle and fascia are divided in the line of the incision and split to the lateral extent of the wound. The internal oblique and transverse muscles are divided with cautery in the line of the incision, or in a more beneficial way to divide the two layers of muscles on the confluence of the oblique muscles and the rectus sheath, which avoids division of the internal oblique and transversus muscles. The latter method, most frequently used in our institute, has two major advantages both for patients and surgeons. Firstly it markedly reduces the blood loss resulting from capillary hemorrhage of muscle wound surface during the transplantation, which is usually underestimated by surgeons. Uraemic patients often have a bleeding diathesis at the time of surgery due to malfunctioned platelet, especially when being heparinized during pretransplant hemodialysis. In addition, the muscle fibers could disrupt during closure because of high tension of the wound covering the graft, particularly, if there is a large kidney for a small recipient. The pararectus division of muscles and aponeurosis facilitates the process of wound closure and diminishes the incidence of muscles collapse and wound complications.

The inferior epigastric vessels are ligated and divided, but if there are multiple renal arteries, the inferior epigastric vessels should be preserved in the beginning in case the inferior epigastric artery is required for anastomosis to a lower polar renal artery. Division of the spermatic cord has not been advocated during past decades for its drawback of inducing secondary testicular complications, but freed laterally and retracted medially. The round ligament can be divided for adequate exposure.

The exposure of iliac vessels seems to be an effortless process, but bearish expansion of the extraperitoneal space might cause the peritoneum injury and subsequent enterocele, a rare but potentially fatal surgical complication, described as "renal paratransplant hernia" in recent year. We have encountered three cases of the rare surgical complication in early years. In our opinion, in most, if not all cases, paratransplant hernia is an iatrogenic surgical complication as a result of an unnoticed defect of the peritoneum due to improper maneuvers during the transplantation. Meticulous dissection may help avoid this complication. And if a peritoneal defect is found, it should be closed immediately, regardless of its size to avoid the occurrence of a postoperative paratransplant hernia.

A self-retaining retractor is usually inserted to obtain optimal exposure, which allows the assistant to free both hands to assist the anastomoses. However, the position of the retractor should be checked carefully before fixing it because the inadvertent retractor injury was one of the causes to femoral neuropathy, an unusual complication after kidney transplantation, with major clinical features of reversible muscle weakness or paralysis of hip flexion. The lymphatics that course along and over the vessels must be ligated with a nonabsorbable suture and divided, rather than cauterized, to prevent the later occurrence of a lymphocele. The surgeon must be cautious not to mistake the genitofemoral nerve for a lymph vessel. The former lies on the medial edge of the psoas muscle, and a branch may cross the distal external iliac artery.

2.3 Vascular reconstruction

In general, it is preferable to do the end-to-side venous anastomosis first, and then the end-to-side arterial anastomosis. Some scholars argued that the arterial anastomosis should be

done first if the renal artery is to be anastomosed to the internal iliac artery. Although end-to-side anastomosis to the external iliac vein and end-to-end anastomosis to the internal iliac artery is once the classical vascular anastomosis pattern, and also practiced in some centers now, many facts have revealed that the internal iliac artery is not a preferred option for the arterial anastomosis compared with external iliac artery. Firstly, dissection of the internal iliac artery is not as straightforward as that of the external iliac artery. Meanwhile, a mobilization of a length of the external and common iliac arteries is also needed when the internal iliac artery is considered as the candidate of arterial anastomosis because of the application of vascular clamps and prevention of kinking of artery when being rotated laterally for anastomosis, which increases the operative time and risk of surgical complications. Furthermore, it is an intractable problem to handle if the concomitant internal iliac vein is inadvertently damaged during the dissection. Moreover, the risk of anastomosis site stenosis and erectile dysfunction is much higher than that of external iliac artery following the transplantation. Lastly, the short internal iliac artery and variation are common. Therefore, the routine end-to-end anastomosis to the internal iliac artery is not recommended.

Since Carrel described a 3-point anastomosis technique for an end-to-end allograft arterial anastomosis in 1902, transplant surgeons have invented different techniques for arterial and venous anastomoses. Most efforts have been made to decrease ischemic time and promote the quality of anastomosis. The classical and universally used technique is the 2-point anastomosis, with initial sutures placed at either end of the venotomy or arteriotomy. Sometimes, an anchor suture is placed at the midpoint of the lateral wall to prevent posterior or anterior wall being caught up in the suture line. Another running anastomoses fashion, so called "1-suture, 1-knot technique", which does not need to turn the kidney medial and lateral, has showed some advantages especially in obese patients and recipients with deep iliac fossa. Mital and associates, in 1996, performed arterial and venous anastomoses using 4-stay sutures and several vascular clips for each anastomosis, without a continuous vascular suture. (Mital et al, 1996). Afterwards, sutureless vascular anastomosis technique using vascular clips or titanium ring pin staplers have been described and suggested safe and time-saving in small series (Jones, 1998; Ye, 2006). However, these sutureless techniques seem not to be popularized, and their long-time outcomes need further observation.

2.3.1 Venous anastomosis

The renal vein is anastomosed end-to-side, usually to the external iliac vein using a continuous 5-0 monofilament vascular suture following an appropriate venotomy performed in the external iliac vein. In rare conditions such as thrombosis or hypoplasia of both iliac veins, the renal vein has to be anastomosed to other site. Anastomosis to the inferior vena cava is the most common alternative, usually associated with a native nephrectomy. The usage of infra-renal inferior vena cava or infra-hepatic inferior vena cava has been described in the literature. Otherwise, portal venous drainage system, inferior mesenteric vein, superior mesenteric vein, even venous collaterals with large caliber secondary to thrombosis of the inferior vena cava and iliac veins such as a presacral collateral vein and the left ovarian vein have been utilized for renal transplantation with satisfactory results (Wong et al, 2008).

Short right renal vein, particularly from living donors, represent a technical challenge to the transplant surgeon. Usually, the satisfactory anastomosis can be achieved by thorough

mobilization of the recipient common and external iliac veins. Sometimes, the techniques of donor vein elongation are needed especially in obese recipients. Right renal vein extension using the inferior vena cava is an excellent option and frequently used in deceased kidney transplantation, but is not suitable to living donors. A variety of techniques have been developed to elongate the short live donor vein, and extension techniques using saphenous, gonadal vein or superficial femoral vein grafts or a polytetrafluoroethylene graft have demonstrated nice results. Extensively elongation of renal vein should be avoided either in live or deceased transplantation for prophylaxis of occurrence of renal vein thrombosis.

2.3.2 Arterial anastomosis

The end-to-side arterial anastomosis is generally placed more proximally than the vein, usually performed using an appropriately trimmed cuff of aorta attached to the renal artery with a continuous 5-0 or 6-0 monofilament vascular suture after a suitable arteriotomy placed in the external iliac artery. The arterial clamps should be applied with great care to avoid the disruption of vascular calcified plaque. Endarterectomy is usually unnecessary. An opening of proper caliber created with artery puncher in the external iliac artery may facilitate the anastomosis of renal arteries from live donors in the absence of "Carrel patch". Careful suture performance is absolutely crucial for the allograft to maintain normal arterial blood flow and function. Appropriate full-thickness suture of arterial wall must be achieved in each stitch, particularly in patients with arteriosclerosis.

Kidney with multiple arteries is a challenge before artery anastomosis. There are various anastomosis patterns for this situation. How best to manage multiple arteries depending on the characteristics of multiple arteries and individual transplant surgeon's preference. Anastomosis of two arteries close together on an aortic patch of a left-sided deceased donor kidney is comparatively straightforward. If they are more than 2 cm apart, consideration could be given to perform two separate anastomoses. Dual arteries to a right-sided kidney often make positioning of the kidney difficult without kinking one or the other artery, sometimes the arteries have to be shortened to fulfill two separate anastomoses. Most complicated cases are encountered in live transplant setting, cuff of aorta is impossible, multiple and short arteries are common with the increasing popularity of laparoscopic living donor nephrectomy. For double arteries, two separate anastomoses are recommended in most occasions. Double parallel anastomoses to the external iliac artery are most common pattern. Sometimes the lower hilar artery or lower polar artery can anastomose to internal iliac artery or inferior epigastric artery in an end-to-end manner. Very small accessory renal arteries, particularly at the upper pole, can be ligated without problems. Arteries reconstruction on the back table operation before revascularization is an effective way suggested by many authors. The advantages of ex vivo reconstruction techniques are that they preserve the small accessory renal arteries by an end-to-side or conjoined anastomosis to renal artery stem and reduce the operative time by simplifying the anastomosis. Multiple short arteries or arteries with other vascular anomalies can also be salvaged. Theoretically, the incidence of vascular complications may be higher using complicated reconstruction techniques on back table. It is necessary to consult the vascular surgeons to achieve the difficult reconstruction under magnification.

2.4 Urinary tract reconstruction

Reconstruction of urinary tract begins following a successful revascularization. The type of urinary tract reconstruction is various. The standard and usual form of urinary tract reconstruction is ureteroneocystostomy. But the classical status of ureteroneocystostomy has

been challenged recently. Pyeloureterostomy and ureteroureterostomy conventionally is considered salvage procedures when the transplant ureter's blood supply seems to be compromised or the urinary bladder is difficult to identify. Nie and associates recently compared the overall incidence of urological complications between ureteroureterostomy and ureteroneocystostomy in kidney transplantation, no difference was found, moreover, ureteroureterostomy decreased the incidence of urine leakage and therefore was advocated a good first option for urinary tract reconstruction with a greater possibility of resolving a ureteral stenosis with endourology and no risk of reflux (Nie et al, 2010). Timsit and collages compared results in 151 consecutive kidney transplantations with routine pyeloureterostomy and that in 129 procedures with extravesical anti-reflux ureteroneocystostomy, the outcomes from routine pyeloureterostomy group were even better and also had the similar advantages as the ureteroureterostomy's (Timsit et al, 2010). However, ureteroneocystostomy is still the preferred selection of urinary tract reconstruction for most surgeons because of its various advantages. ureteroneocystostomy is a familiar technique we often applied in general urological surgeries. Deep dissection of native ureter and native nephrectomy are unnecessary. It can be performed regardless of the quality or presence of the native ureter and retains the possibility of conversion to an ureteroureterostomy or pyeloureterostomy if the implant fails. The location of ureteroneocystostomy is usually several centimeters away from the vascular anastomoses, which facilitate the examination and correction of a possible urinary complication during the reinterventions.

2.4.1 Ureteroneocystostomy

There are a variety of techniques for ureteroneocystostomy, which in general can be categorized into transvesical or extravesical and antireflux or non-antireflux. The Leadbetter-Politano (LP) technique is the classic transvesical ureteroneocystostomy described by Murray et al in 1954 for the first successful renal transplant. This technique utilizes one cystostomy to access the interior of the bladder and another cystostomy to recreate a new ureteric orifice in a normal anatomic position. The ureter is tunneled in the submucosal space to prevent reflux. The extravesical ureteroneocystostomy was first described by Witzel in 1896, then again by Gregoir in April 1961, and soon thereafter by Lich et al, who published the technique in November 1961. The Lich-Gregoir (LG) technique was designed to avoid a second cystostomy, yet retain an antireflux mechanism. It creates a 2-3 cm submucosal tunnel with muscle backing of the ureter to provide a valve effect. In addition to the avoidance of a separate cystostomy, other comparative advantages were less bladder dissection, a shorter ureteral length, and no interference with native ureteral function. Additionally, the LG was noted to be rapid and technically easier to perform than the LP technique. Several variations of the LG implantation have been described, such as the use of running instead of interrupted sutures to create the ureteral mucosal anastomosis, performance of a tunnel by submucosal blunt dissection instead of muscular imbrication, placement of a single horizontal Halsted stitch at the proximal apex of the bladder incision to the ureter to prevent tension at the acute angle of the anastomosis, placement of an anchor stitch on the distal ureteral tip to the full thickness of the bladder, folding back the tip of the ureter to make a terminal cuff, incorporation of the muscular layer with the mucosal layer of the bladder in the anastomosis and the parallel-incision technique with a submucosal tunnel created between the two parallel incisions in the lateral bladder. All of

these so-called modified Lich ureteroneocystostomies include extravascular access, the formation of an antireflux tunnel, and an urothelial anastomosis (Kayler et al, 2010).

Another extravascular approach to ureteroneocystostomy that also includes an antireflux tunnel but lacks an urothelial anastomosis, called the U-stitch technique. By elimination of the urothelial anastomosis, this technique was demonstrated to shorten operative times even further than that of the LG technique. But this technique is associated with an increased risk of a urinary complication and abandoned at our center, and being against by many other institutions.

The techniques without an antireflux mechanism are least often described. Although early comparative analyses have failed to show significant differences between reflux and antireflux techniques, but most non-antireflux techniques have been marginalized and abandoned.

The management of double ureters is something like management of dual arteries to some extent. If there is a common part, a straightforward ureteroneocystostomy can be done as a single ureter. Two separate ureteroneocystostomy using L-G technique is preferred in our center when two ureters are not in one common sheath. The dual ureters can also be reconstructed on back table conjoining them into one common stem to anastomose with bladder or native ureter

2.4.2 Other alternatives

There are some unusual forms of urinary tract reconstruction technique using in special conditions, such as pyelopyelostomy in orthotopic renal transplantation, ureteroenterostomy into an intestinal conduit or an intestinal pouch and pyelovesicostomy when the native ureter and the renal transplant ureter are unsuitable for urinary tract reconstruction. No matter what method is used, a tension-free and watertight anastomosis is most important.

2.5 Closure

There are three aspects should be taken into consideration before closing the wound: Haemostasis, reexamination and placement of drains. Careful haemostasis is necessary for every surgery especially for a uremic patient. The special attention should be paid to the vascular anastomosis site and renal pedicle area in case there is active bleeding from an unrecognized leak or an unligated vessel, which is a cause of emergent reoperation during the very early postoperative period even before leaving the operating room. The significance of reexamination is to find if there are some grave technique faults and correct them before the closure. Vessels are always the emphasis for checking, besides the bleeding the strength of renal artery pulsation and the vascular tension of renal vein should be sensed gently using fingers, adjusting the position of graft if there is a kinking or compression of long vessels. In the mean time, the ureter should be tension free and burden free from adjacent structures after the graft is properly placed. No urine leak is permitted. Drain placement is a very important step that can not be ignored, the related issues we will discuss soon.

The value of obtaining a baseline biopsy specimen before closure remains controversial, but it is the fact that it incurs some unnecessary biopsy-induced vascular complications for some grafts with perfect function. A capsulotomy of the transplanted kidney before closure basically has been abandoned in adult transplantation because it is of no use on the whole.

The process of closure is not as easy as incision making. Muscular tension often higher either from an additional graft or descending effect of muscle relaxant. A running #1 polydioxanone

suture (PDS) provide a convenient choice for closure, some centers routinely close muscles and aponeurosis with single-layer PDS suture (Nanni et al. 2005), which reduce the closing time but is also a risk factor of wound complications. Our experience is to close the wound with two-layer PDS suture plus five to six interrupted anchor stitches in muscle layers with nonabsorbable sutures, which has been proved an appropriate method. Otherwise, attention should also be paid to avoid injuring the peritoneum when closing the incision, for one careless stitch can tear the peritoneum leading to a defect and the paratransplant hernia especially in patients with obesity and ascites. The vaulted transplanted ureter under the muscle layer should not be involved by suture when closing. Furthermore, excessive tension on the suture may lead to compression of the kidney or lead to defects resulting in wound complications, a mesh could be used to achieve a tension free closure.

2.6 Stent, catheter and drains

The debate about the three types of tube has never stopped. The viewpoints varies too much, some of disputes are swordplay. Double J stent is an object full of controversy since its introduction to urology. Its function in renal transplants to significantly reduce ureteric complications is broadly accepted. One meta-analysis has addressed the prophylactic routine stenting in renal transplants is cost-effective (Mangus et al, 2004). The minor flaw such as an increased risk of urinary tract infection, an additional cystoscopy and patient discomfort from bladder spasm is relatively unimportant and controllable, can not counteract its contribution to a markedly lowered incidence of ureteric complications, which sometimes can be a cause of graft loss. The optimal duration of prophylactic stenting has also not been determined. Based on local center preference, it is usually 2 to 6 weeks. In our center, stent is removed during an office visit 4 weeks after transplantation, accompanying with a routine general checkup.

A dwelling catheter is necessary for every kidney transplantation patients, it is important to maintain the catheter in an unobstructed condition during the early postoperative period. The reported duration time usually is 5 to 7 days, our experience is 7 days. Seven-day is a proper compromise to prevent urine leak in the absence of an increasing incidence of urinary tract infection. What's more, acute vascular rejection usually occurs one week after transplantation, a dwelling catheter is helpful for the patients to detect the early sharp reduction of urine output, a usual signal of acute rejection.

There always remains considerable controversy over the necessity and duration of perigraft drains. Some authors suggested non-drains closure if the hemostasis is satisfactory because drain tubes increase the infection risk in immunosuppressive patients. But most others support placing a closed suction retroperitoneal drain at the time of transplant and a considerable majority of them suggest removal of drains in 48 hours in case of infection. However some authors argue the rationality of prolonged drainage, as reported, the median day of drain removal was 18 days in individual center. (Tiong et al, 2009). Based on our preference, we suggest a "two-drain policy" routinely for every transplant patients. The incidence of postoperative hematomas and lymphoceles in renal transplantation is dramatically higher than general urological surgeries' for various reasons. So the principle of drain placing can not simply mimic the pattern of general surgery. In the early posttransplant period, bleeding is commonly from the operative bed, it is usual to record 100 to 200 mL of heavily blood-stained drainage in the first few hours of transplantation. After that, even a week later, the spontaneous bleeding of graft can also develop a problematic hematoma. Moreover, most lymphoceles formations and urine leak occur

approximately one week after transplantation, too early removal of drains increase the risk. The reason of two drains is based on the fact that there are two isolated dead space created by the allograft, over the upper pole and under the lower pole of the transplant kidney; one lower drain often can not drain the bleeding from the upper pole. We place one additional drain onto the upper pole of graft and the other one down to prevesical space, centimeters away from the renal vessels and ureter. The upper drain usually is removed 4 to 5 days posttransplant or until drainage is less than 20 mL daily, the lower drain is routinely removed one day after the catheter removal if there is no evidence of urine leak or lymphorrhea, which significantly diminishes the incidence of postoperative hematomas, lymphoceles and urinomas compared with our early experiences with one-drain policy, but no increase of wound related infection.

3. Surgical considerations in pediatric recipient

In children, the standard surgical approach in adult carries two disadvantages. First, there is a size mismatch between the available extraperitoneal space and the adult sized donor kidney. Secondly, the recipient artery may be small compared with the artery of the graft that make the vascular anastomosis more difficult and may jeopardize the blood pressure and blood flow which is required for the donor kidney to survive. The conventional view is that the transplant procedure is same as for adults if their weight is more than 20 kg. If weight less than 20 kg, the right Gibson incision can be carried up to the costal margin to increase exposure of the right extraperitoneal space or using a transperitoneal approach. Some centers usually perform transperitoneal kidney transplantation in children below 5 years. However some advocated extraperitoneal renal transplantation technique in children who weigh less than 15 kg, which limits potential gastrointestinal complications and allows the confinement of potential surgical complications, such as bleeding and urinary leakage (Furness et al, 2001). When a transperitoneal approach used, it is generally done through a midline incision from the xyphoid to the pubis, the posterior peritoneum is incised lateral to the ascending colon. Ligating and dividing two to three lumbar veins posteriorly is often necessary to facilitate the application of vascular occluding clamp. The terminal aorta is dissected free at its junction with the right or left common iliac artery. The donor artery is either anastomosed to the distal aorta to obtain the best arterial inflow, or with one of the common iliac arteries in an end-to-side fashion using 5-0 or 6-0 monofilament vascular suture. The selection of common iliac artery avoids a complete occlusion of the aorta which is associated with temporary acidosis of both lower extremities (van Heurn et al, 2009). The donor vessels are often amputated and may be spatulated to ensure a wide anastomosis and to avoid kinking which may lead to impaired blood flow. An aortic punch is basically used to prevent renal artery occlusion if significant hypotension occurs. The ureter of an adult size kidney is usually long and wide enough to obtain a tension free ureteroneocystostomy. The problem is the too long ureter is easy to be kinked and twisted, even causing internal hernia (Sánchez et al, 2005); therefore, sometimes the long ureter should be shortened to obtain best result. Temporary ureteral stenting is beneficial to prevent urological complications, but special care should be taken for the removing technique because standard cystoscopy in adults is not suitable for a very young child. It is a smart way to attach the stent with the indwelling bladder or reservoir catheter and removing it as the catheter is withdrawn. An antireflux procedure is imperative for pediatric patients. Because a large number of recipients are a result of obstructive uropathy due to outflow obstruction,

small capacity or poor function of the bladder, which all predisposes to vesicoureteral reflux of the transplanted kidney.

4. Dual kidney transplantation

As a result of the shortage of kidneys for transplantation and the increasing demand for transplantable grafts, the option for using organs from expanded criteria donors has become widely accepted. One option for using organs from donors with a suboptimal nephron mass is dual kidney transplantation (DKT). Dual kidney transplantation is the deceased renal transplantation using two marginal kidneys simultaneously either from the donors older than 60 years old, or from solitary pediatric donors age younger than 5 years or small (< 21 kg). The paired kidneys from solitary pediatric donors are recovered and transplanted as en bloc, known as "en bloc kidney (EBK)". The double kidneys from old donors can be also used as en bloc, but mostly in a split individual implantation technique, bilaterally or ipsilateral. Clinical kidney transplants using solitary paired deceased donor kidneys were reported in the early 1960s, followed by increasing interest in the use of paired pediatric deceased donor kidneys as en bloc with the first case to a pediatric recipient and thereafter, to adult recipients showing possible advantage of more renal reserve and technical feasibility. One recent report shows EBK pediatric donor transplants had the best long-term outcomes among deceased donor transplants (Bhayana et al, 2010). Various strategies have improved the outcome of EBK pediatric donor transplants, including changes in techniques. For an adult recipient, the paired kidneys usually also placed extraperitoneally in the iliac fossa via a Gibson incision. Commonly, the aorta and the inferior vena cava of EBK are anastomosed to the external iliac artery and vein with 5-0 or 6-0 monofilament vascular suture in an end-to-side technique. Sometimes, the end-to-side anastomosis is applied to the aorta and inferior vena cava to prevent kinking of renal vessels and ureters. For the same purpose, the upper pole of the grafts sometimes fixes to the iliopsoas muscle. Double ureteroneocystostomies of the native contracted bladder are performed separately, or the ends of the two ureters are reconstructed into a conjoined ureter and then one ureteroneocystostomy is performed. Sometimes ureteroureterostomies are performed. Kato and collages, in 2008, developed the urinary tract reconstruction technique with a vascularized "bladder patch" including the vesical trigone from the same donor, which precludes the challenging ureteral reconstruction and ureteroneocystostomy, and excludes the risk of anastomotic strictures and postoperative reflux, significantly reduces the incidence of urine leak. In the mean time, the donor bladder wall served a purpose of bladder augmentation as well. (Kato et al, 2008).

Since first report of DKT from an adult deceased donor in the United States was revealed in 1996, many centers now perform DKT using various organ selection criteria and surgical techniques, including the extra- or intraperitoneal bilateral placement of the two kidneys through two separate Gibson incisions or one midline incision. In 1998, Masson et al. were the first to transplant both adult donor kidneys unilaterally into the same iliac fossa. Their reasoning was that this would reduce the surgical trauma and thus facilitate the immediate postoperative recovery of the patient, and also leave the contralateral iliac fossa intact for a further transplantation procedure in the event of graft loss. However, extraperitoneal unilateral placement through a single Gibson incision presents several technical hurdles, such as more extensive vessel dissection and a higher risk of renal vein thrombosis due to compression by the two kidneys. A comparison between 29 unilateral and 29 bilateral DKT

procedures in an initial series has showed both techniques are safe, with no differences in surgical complication rates. In brief, the procedure begins with the classic Gibson incision, preferably on the right side. After creating an adequate extraperitoneal space, the right donor kidney is preferably placed superiorly because its renal vein can be lengthened by a segment of inferior vena cava. Another reason to position the right kidney superolaterally in the right flank is because the right kidney has a longer artery. If necessary, the internal iliac vein is dissected to mobilize the external iliac vein and thus facilitate renal vein anastomoses to the external iliac vein of the recipient. The extended renal vein and renal artery of the right kidney are anastomosed end-to-side to the iliac vessels of the recipient; these anastomoses are often to the external iliac vessels. After revascularization of the right kidney, vascular clamps are placed immediately below the venous and arterial anastomoses. The left donor kidney is transplanted distally, allowing the transplanted right kidney to continue to be perfused. The left kidney is positioned inferomedially to the right kidney. The renal artery and vein of the left kidney are anastomosed end-to-side to the external iliac vessels. Extravesical ureteroneocystostomies are performed separately, with a double J stent for each ureter, leaving the ureter of the upper transplanted kidney lateral to the lower one.

5. Orthotopic kidney transplantation

Orthotopic kidney transplantation (OKT) is seldom performed due to its complicated procedure and high related morbidity. However an increasing percentage of patients with end-stage renal disease currently are not candidates for a heterotopic kidney transplant because of associated severe vascular pathology, obesity, or retained iliac fossae from a former graft. In such situations, where heterotopic transplant is not appropriate, an orthotopic kidney transplant is an alternative.

The surgical technique consists of a retroperitoneal approach to the splenic hilus via lumbotomy. To preserve its entire length, the vein is ligated close to the renal parenchyma including its bifurcation. The renal artery is often narrow and cannot be used in most cases. The recipient's urinary tract is always carefully dissected and preserved. In most of the reported cases, renal graft revascularization was performed using the recipient's splenic artery and left renal vein. Types of artery revascularization include end-to-end anastomoses between graft renal artery and native splenic artery, renal artery or inferior mesenteric artery or end-to-side anastomoses between graft renal artery and Aorta. Types of vein revascularization include end-to-end anastomoses between graft renal vein and native renal vein or splenic vein or end-to-side anastomoses between graft renal vein and inferior vena cava. The excretory system is reconstructed using pyelo-pyelic anastomoses in most cases, and uretero-ureteral anastomoses, uretero-pyelic anastomoses, ureterocalicostomy in the others.

The reported overall vascular complication rate is about 5.4%, and total urological complication rate is about 8.1%. Musquera et al. in their recent report demonstrated that no statistically significant differences are observed between orthotopic and heterotopic transplant series when comparing overall patients and graft survival. OKT is a feasible alternative for selected patients who are considered unsuitable for heterotopic kidney transplant.

6. Minimally invasive kidney transplantation

During the past decade, the use of minimally invasive surgical procedures has increased in popularity among surgeons and patients. The introduction of minimally invasive techniques

in the transplant field is expanding the number of living-related donor nephrectomies. The minimally invasive approach allows a significant reduction of postoperative pain, decreased length of hospital stay, shorter recovery time, and enhanced cosmesis, representing a significant advantage for the patient. However, the renal transplant surgery is always the forbidden zone of minimally invasive techniques because of the formidable technical barriers. The pioneers initially attempted the laparoscopic techniques in the renal autotransplantation of experimental animals, establishing the basis for clinical performance of autotransplantation and other complex urologic vascular procedures laparoscopically. Then the laparoscopic autotransplantation for patients with ureteral lesions or renovascular hypertension have been reported in few cases. In 2002, Hoznek and associates presented their initial experience on robotic assisted kidney transplantation, Operative time was 178 minutes. Robotic assistance made anastomosis possible by its unique ability of stereoscopic magnification and ultra-precise suturing techniques due to the flexibility of the robotic wristed instruments. Renal perfusion was excellent with immediate diuresis. The study demonstrates that robotic assisted kidney transplantation is feasible. However, technical and cost hindrances limit the routine use of robots. Until 2010, another robotic transabdominal kidney transplantation has been reported in a morbidly obese patient (BMI 41Kg/m²) with 4 trocars and a 7 cm midline incision. The operative time was 223 min, and the blood loss was less than 50 ml. The kidney had immediate graft function. No perioperative complications were observed, and the patient was discharged on postoperative day 5 with normal kidney function. In 2011 the first European case of robotic renal transplantation was accomplished using 3 trocars and a 7 cm suprapubic incision. The suprapubic incision used for introduction of the kidney and also the uretero-vesical anastomosis. Besides the robotic renal transplantation, Rosales et al presented the first laparoscopic renal transplantation, without robotic assistance, using 4 trocars, a hand-access device and a 7 cm Pfannenstiel incision. In this case the ureterovesical reimplantation was done laparoscopically using a modified Taguchi technique. In view of the rapid progresses in laparoscopic vascular and urological reconstruction technique, we have reason to believe that minimally invasive kidney transplantation would have a bright future.

7. Surgical complications of kidney transplantation

Surgical complications of kidney transplantations have always been received considerable attention in the literature, because they can lead to morbidity, graft loss and mortality. As with other surgical cases, postoperative hemorrhage, wound complication may be seen in kidney transplant operation. However, there are some transplant-related surgical complications are special issues unique to kidney transplantation recipients, which can be categorized as vascular, urologic or lymphatic.

7.1 Wound complications

As with other types of surgery, wound complications are probably the most common surgical complication after a kidney transplant, with an approximate incidence of 5%. The general risk factors of wound complications is similar to other sorts of surgery, including systemic factors (e.g. increased age, obesity, diabetes and malnutrition), wound features (e.g. hematoma and dead space) and operative characteristics (e.g. poor surgical technique, lengthy operation (>2 h) and intraoperative contamination). In the transplant setting, the graft creates two natural dead spaces at the either pole of the kidney, and the formation of hematoma and lymphoceles is more frequent than general urological procedure.

Furthermore, the inevitable immunocompromising medications have significant adverse effect on wound healing and resistance to infection. Besides the well-known impairment of steroids on wound healing, the commonly used immunosuppressant, mycophenolate mofetil (MMF), has been defined as a significant risk factor of wound complications. Recently, the mammalian target of rapamycin (mTOR) inhibitors, sirolimus and everolimus, believed not to be nephrotoxic, have showed the strong association with problematic lymphocele and impaired wound healing attributed to their powerful antiproliferative, anti-inflammatory, antiangiogenesis and antilymphangiogenic activity, which are essential for the healing and repair of wounds. Interestingly, although patients undergoing transplantation are at an elevated risk for poor wound healing and infection, the incidence of wound complications are not significantly higher in kidney recipients compared with that in nontransplant patients undergoing similar types of surgery. But wound complication often incurs patient dissatisfaction and increasing cost, moreover, in certain situations, wound complications may also be associated with graft loss and mortality. In general, wound complications can be broadly categorized into infectious and noninfectious complications.

7.1.1 Wound Infections

Wound infections can be divided into superficial wound infections and deep wound infections.

Superficial wound infections: Diagnosed within 30 d of operation, limited to skin or subcutaneous tissue, and at least one of the following should be present:

- a. purulent drainage from the superficial incision;
- b. a sign or symptom of infection, such as pain, tenderness, heat, or swelling, and the incision is deliberately left open by a surgeon, unless culture becomes negative;
- c. the diagnosis of superficial wound infection is confirmed by the surgeon.

Deep wound infections: Diagnosed within 30 d of operation, involvement of the fascial or muscular layers, and at least one of the following should be present:

- a. purulent drainage from the deep incision;
- b. spontaneous dehiscence while the patient has fever ($>38^{\circ}\text{C}$), localized pain, or tenderness;
- c. An abscess is found on direct examination, on reoperation, or by radiologic examination; the content contains pus, and the culture yielded one or more microorganisms;
- d. the diagnosis of deep incisional infection is confirmed by the surgeon.

The treatment of wound infections should follow the universal principals of general surgery including application of broad-spectrum antibiotic and surgical care, such as opening the wound, evacuating pus, cleansing the wound and dressing changes. But for kidney transplant patients, the aggressively higher doses of immunosuppressors in recipients should be lowered; the sirolimus-based immunosuppressive regimen might be converted to tacrolimus or cyclosporine-based scheme according to conditions of surgical site. On the other hand, the timing and dosage of broad-spectrum antibiotic should be investigated systematically for prolonged duration of antibiotic administration in immunocompromised patients usually incurs opportunistic infection.

7.1.2 Noninfectious wound complications

Noninfectious wound complications generally refer to all of the wound problems except infections including wound dehiscence, perigraft sterile fluid collection and incisional

hernias. Although noninfectious, each of them is important risk factor of wound infections. Perigraft sterile fluid collections mainly involve the seroma and lymphocele, which we will expatiate on later. Herein, we chiefly discuss the clinical characteristics of wound dehiscence and incisional hernias.

Wound dehiscence is defined as an incision prematurely bursting open or splitting along surgical suture lines in the absence of documented infection. Similarly, it can be categorized into superficial and deep wound dehiscence. Incisional hernias refer to a protrusion of a portion of an organ or tissue through the incision, which is a result of deep wound dehiscence. The majority of incisional hernias developed in the first three months after kidney transplantation.

Generally, superficial wound dehiscences are treated as superficial wound infection excluding antibiotic therapy. For an anergic wound the healing process can be electively stimulated with the vacuum sealing method, which has shown promising results. Conversely, deep wound dehiscence, as well as symptomatic incisional hernias, requires operative repair. The open surgical procedure varies according to the surgeon's preference. Routinely, small defects undergo primary fascial repair, and large or recurrent defects are repaired with mesh.

7.2 Vascular complications

Vascular complications during and after kidney transplantation are usually uncommon with an incidence of less 10%. But they are important causes of graft dysfunction. According to the location of affected vessels, vascular complications can be grouped into graft vessels complications and recipient vessels complications. Actually, the lesion often affected the both.

7.2.1 Graft vessels complications

7.2.1.1 Renal Artery Thrombosis

Occlusion of renal artery by thrombus is a rare event occurring in 0.2-3.5% of renal transplantations. Though uncommon, it is a transplant emergency that often results in graft loss. The exact cause of renal artery thrombosis has remained obscure. The aetiology is multifactorial. Technical factors are the important causes, but not always. Other possible contributory factors may be concluded as thrombophilic state, history of previous thrombosis, lupus anticoagulants, atherosclerosis, poor cardiac output, ATN or acute rejection. Vessel kinking, torsion, intimal injuries are the frequently reported technique errors resulting in renal artery thrombosis, which should be avoided. Adequate training on techniques of vascular anastomosis and graft recovery is essential, to reduce the occurrence of repeated reanastomosis and iatrogenic vascular injury. Renal artery thrombosis can occur at any time, but commonly occurs in the early postoperative period. The typical clinical presentation is a sudden onset of oliguria or anuria with deterioration of graft function, usually painless, which demands a differential diagnosis with acute rejection and urologic complications. Helical computerized tomography (CT) may be more diagnostic than ultrasound for that it can directly depict renal artery thrombosis when ultrasound studies are inconclusive. Angiography is warranted in confusing cases. Prompt reoperation is crucial to salvage such a graft when diagnosis is suspected, because irreversible cortical necrosis can occur within minutes. That is why it could be responsible for more than one-

third of early graft losses. Actually, transplant nephrectomy is usually the rule. Since the extremely bad prognosis of graft survival, prevention is of utmost importance especially in high-risk patients.

7.2.1.2 Renal Vein Thrombosis

Renal vein thrombosis (RVT) is an unusual but disastrous complication, reported to occur with an incidence of 0.3-3%, more frequent than renal artery thrombosis. Pathogenesis of RVT is still controversial, the multiple factors conducing to renal artery thrombosis discussed earlier also contribute here, moreover, technique reasons seem to play an invariable role. A long renal vein is considered a contributory thrombogenic factor by some studies, some center even routinely shorten the left renal vein at the time of surgery to prevent thrombosis. So an immoderately prolonged right renal vein using the inferior vena cuff should be avoided during the back table preparation. Small vein and multiple veins may also predispose to thrombosis. Unlike artery, wall of vein is subtle and fragile, more inclined to be damaged, compressed and twisted, meticulous surgical techniques on renal retrieval, renal vein repair and anastomosis and positioning of kidney may prevent most avoidable occurrence of RVT. In contrast to the renal artery thrombosis, the clinical presentation of RVT is more evident and perilous, sometimes, life-threatening. Majority of RVT occurs during the early period after transplantation, particularly due to technique problems. Rare late RVT even occurring years after operation mainly results from thrombophilic states, secondary thrombosis from ipsilateral DVT or de novo nephropathy. For most early acute cases, besides the typical sudden onset of oliguria or anuria with deterioration of graft function, severe pain and swelling over the graft is definite, an unstable haemodynamics status and decreasing concentration of haemoglobin is present if incurring rupture of graft. Clinical presentation of late RVT may be gentle, especially for the kidneys with partial occlusion of the renal vein, sometimes, only present a deteriorating dysfunctional graft. On Ultrasound images, the allograft may appear swollen and hypoechoic. At Doppler ultrasound examination, venous flow is absent, and the arterial waveform shows reversed, plateauing diastolic flow. A perinephric fluid collection or huge hematoma can be seen if graft rupture occurs.

After an early diagnosis is made by clinical presentation and ultrasound examination, patient should be underwent emergent exploration as soon as possible, which is the sole chance to salvage the graft. There are two ways to save the allograft, thrombectomy or retransplantation. Firstly, patient needs to be heparinized before any procedure, if no obvious evidence of technique error, a thrombectomy of renal vein may be attempted, fresh clot should be removed and flushed out completely, and the transplant renal artery might be clamped to control the bleeding if the graft is ruptured, accompanying with a repair of rupture. A routine vein tissue biopsy is essential to identify the cause. Removal of the kidney and reperfusion with preservation solution may be the last option especially if encountering the short right renal vein from live donor. The iliac vein has to be mobilized to a maximal extent to facilitate the reanastomosis. Besides the open surgical technique, percutaneous chemical and mechanical thrombolysis has been showed a feasible method but with a risk of leading to pulmonary embolism. It may be possible to treat a partial RVT with heparin. We have been associated with three cases of late partial RVT, revascularization of renal vein in all three cases has been achieved by subcutaneous low molecular weight heparin injection combing with intravenous infusion of thrombolytics for 2-3 weeks, no graft loss occurs.

7.2.1.3 Transplant Renal Artery Pseudoaneurysm and Transplant Renal Artery Rupture

Transplant renal artery pseudoaneurysm and transplant renal artery rupture are two extremely rare but potentially devastating vascular complications after kidney transplantations, with an incidence rate of less than 1%. Transplant renal artery pseudoaneurysm is a major risk factor of transplant renal artery rupture. Related data are limited in isolated case reports, but some essentials can be concluded from them. Transplant renal artery pseudoaneurysm can be extra-renal or intra-renal. Extra-renal pseudoaneurysms are usually located at the anastomotic site, and are commonly caused by poor surgical technique, vessel wall ischemia or arterial dehiscence caused by perivascular infection, especially fungi infection. Patients with pseudoaneurysm after their renal transplant are usually asymptomatic and diagnosed incidentally. Few are reported to present with fever, anemia, hypertension, functional impairment, graft loss and life-threatening hemorrhage due to acute rupture. From the review of literature, there are no specific physical findings to predict the risk of rupture. Ultrasound doppler and scanning can readily recognize them. CT angiography, Magnetic resonance (MR) angiography or catheter directed conventional angiography can be used to confirm the diagnosis. The indications for repair of pseudoaneurysm and management options remain controversial. Life-threatening hemorrhage due to acute rupture needs an urgent intervention, the allograft is definitely jeopardized and transplant nephrectomy might inevitably be needed. Recent reports advocate that symptomatic false aneurysms, large size (larger than 2.5 cm), presence of infection, progressive enlargement and impending rupture are indications for repair. Some authors suggest positive surgical repair so long as the pseudoaneurysm is found regardless of if it is symptomatic. Asymptomatic small pseudoaneurysms can be managed conservatively with regular monitoring, but with a risk of acute transplant renal artery rupture. Open surgical repair, endovascular repair and ultrasound-guided percutaneous thrombin injection are the current reported treatment options for managing extra-renal pseudoaneurysm complicating renal transplantation.

7.2.1.4 Transplant Renal Artery Stenosis

Transplant renal artery stenosis (TRAS) is the most common vascular complication following renal transplantation. Depending upon the criteria used for diagnosis its incidence varies from 1 to 23%. It accounts for approximately 1 to 5% of cases of posttransplant hypertension and at least 75% of all posttransplant vascular complications. TRAS is a potentially curable cause of refractory posttransplant hypertension and graft dysfunction. There are three main types of renal transplant artery stenosis: (1) stenosis at the anastomosis; (2) localized stenosis, and (3) multiple or diffuse stenoses. It can occur at any times, usually becomes apparent between 3 mo and 2 yr after renal transplantation. Different locations and timings of disease onset may reflect different etiologies. The most common causes of stenosis are technical reasons. The stenosis due to defective surgical technique, usually located at the anastomosis and especially at the end-to-end anastomosis. The other technical causes reported were vessel lesions during preservation or intimal trauma due to vascular clamps and torsion, kinking or angulation of the artery. Stenosis can be also a result of donor or recipient atherosclerosis. Immunological injury is also proposed as the possible cause, especially in diffuse and multiple stenoses. TRAS resulting from technical reasons usually arises early after transplantation. Stenoses occurring later, sometimes several years posttransplant, usually reflect atherosclerotic disease either of the transplant renal artery or of the adjacent proximal iliac artery. In subtle TRAS

postglomerular resistances are usually increased to sustain intracapillary pressure despite the low renal perfusion pressure. Thus, the glomerular filtration rate may be normal or only slightly depressed. When hemodynamically significant stenoses occur, hypertension and progressive kidney dysfunction are common, without treatment, irreversible graft loss is the rule. TRAS is usually manifested as intractable hypertension, with deterioration of renal function. A vascular murmur in the iliac fossa can often be present but significant stenosis can also occur in the absence of the audible bruit. The gold standard for diagnosing TRAS still remains renal angiography, but it is only electively indicated when a stenosis is suspected on the basis of non-invasive tests. Doppler ultrasound, with many advantages has become the imaging modality to enable the diagnosis and follow-up of TRAS.

A TRAS could be treated conservatively or by revascularization. Stenosis can be treated successfully pharmacologically provided that allograft perfusion is not jeopardized. Revascularization can be by percutaneous transluminal angioplasty (PTA) or by surgical correction. PTA is the preferred initial mode of therapy. Technical success has been reported at greater than 80% with clinical success, the restenosis rates are reported to be 10% to 60%. Surgical techniques include resection and revision of the anastomosis, saphenous vein bypass graft of the stenotic segment, patch graft, or localized endarterectomy. The success rate ranges from 63 to 92%, and the recurrence rate is close to 12%. A prompt intervention is mandatory in stenosis exceeding 70%.

7.2.2 The recipient vessels complications

7.2.2.1 Iliac Artery Stenosis

Iliac artery stenosis is a rare complication after renal transplantation, though unusual it can be the cause of hypertension and renal dysfunction. The stenosis can occur at proximal or distal to the anastomosis site or both, also can be bilateral or multilevel occlusive disease. Usually the lesion is located proximal to the transplant anastomosis site, known as "stenosis of the iliac segment proximal to the transplant renal artery (Prox-TRAS)". The incidence for Prox-TRAS was reported to be 2.4%. The causes inducing TRAS are also predisposing factors of iliac artery stenosis, such as technical errors and atherosclerosis. The iliac artery stenosis is usually suspected by the clinical manifestations including bruits, lower extremity claudication, hypertension and renal allograft dysfunction. But it may be asymptomatic and discovered incidently. Surgeons have paid much more attention to Prox-TRAS not only because of the higher incidence but it can cause ischemia of allograft and ipsilateral lower extremity at the same time compared with the distal stenosis. The diagnosis is established based on direct and indirect evidences, because visualization of the stenosis proximal to the transplant artery could not be achieved with the duplex sonography method in all the patients due to the depth of the common iliac artery or an unfavorable angle of the Doppler beam. The criteria for diagnosing isolated Prox-TRAS are summarized as follows (Voiculescu et al, 2003):

1. Decrease in low pulsatility index when compared with data obtained before
 2. Low low pulsatility index (<1.0)
 3. Pulsus parvus et tardus
 4. No TRAS
 5. V max within the iliac artery proximal to the graft greater than 200 cm/sec
 6. Monophasic flow profile within the iliac artery distal from the transplant artery
- PTA with stents for short iliac artery occlusions or stenosis has showed profitable short- and long-term outcomes in most patients. In patients with multilevel occlusive or bilateral

lesions, particularly with atherosclerotic disease, endarterectomy or bypass surgery could be taken into consideration.

7.2.2.2 External iliac Artery Pseudoaneurysms

External iliac artery pseudoaneurysms following renal transplantation are very uncommon, with an incidence rate of <1%. Its etiology is similar with that of the transplant renal artery pseudoaneurysm, usually a result of vascular injury due to defective surgical technique or perivascular infection. On ultrasound the diagnosis is straightforward. However, the surgical management is somewhere different. Besides the transplant nephrectomy and pseudoaneurysm excision, arterial reconstruction is recommended to prevent lower limb ischemia. During the past decade, endovascular repair has become the first-choice treatment of posttransplant iliac pseudoaneurysms even in emergent setting in some centers. As the end-to-side arterial anastomosis has been becoming the standard fashion, the incidence of internal iliac artery pseudoaneurysms is exceedingly rare regardless of the biopsy-induced complications.

7.2.2.3 Deep Venous Thrombosis

Deep venous thrombosis (DVT) is a well-recognized complication in patients undergoing any type of surgery. Its occurrence after general surgical procedures is well characterized. However, the real incidence of DVT after kidney transplantation is uncertain, varying from 0.8% to 25%. In our center the incidence of symptomatic posttransplant DVT is less than 1%. Some authors feel it occurs with greater frequency, comparing with patients underwent other types of major surgery. Possible reasons include a pelvic dissection, venous anastomosis with clamping of the vein, decreased venous emptying secondary to the position of the kidney, mechanical compression by hematoma or lymphoceles, and the higher proportion of diabetic patients. The opponents advocate the reasons of a decreased risk of DVT, including bleeding tendency of uremic patients and lower hematocrit levels. Theoretically, the position of the graft adjacent to the iliac vein could affect venous outflow from the lower limb. But in previous studies, no statistically significant difference of posttransplant DVT was found on the side of the graft versus the contralateral side. One study suggested the recipients with severe early renal insufficiency should be regarded as high risk patients for late DVT after renal transplantation. Other well defined risk factors of DVT, such as age >40 years, obesity, history of venous thromboembolism, bed rest >5 days also contribute to DVT after kidney transplantation. Purely clinical signs and symptoms of pain, swelling and calf tenderness cannot be used to diagnose DVT, but they alert one to obtain further testing to exclude or confirm the diagnosis. Actually, majority of the DVT patients are asymptomatic and some present as acute pulmonary embolism alone, a potentially fatal complication. In rare occasion, DVT can be a cause of renal allograft loss due to proximal extension of iliofemoral deep venous thrombosis. Duplex ultrasonography has now replaced venography as the most widely used diagnostic test for an acute DVT with excellent sensitivity and specificity of 97% and 94% respectively, CT pulmonary angiography can be performed when excluding pulmonary embolism.

Therapeutic anticoagulation is imperative for a symptomatic posttransplant DVT patient to prevent clot extension, fatal and non-fatal pulmonary embolism and to reduce the risk of recurrent thrombosis. The current options include unfractionated heparin, warfarin and low molecular weight heparin. Graduated compression stockings should be used immediately to reduce pain and swelling and decreases the incidence of the post-thrombotic syndrome. The

role and timing of venous thrombectomy for ilio-femoral vein thrombosis is pending, especially for kidney transplant patients. Early clot removal is achieved by either mechanical thrombectomy using an open or endovascular approach, or catheter-directed thrombolysis. Permanent or retrievable inferior vena caval filters could be placed for the patients at highest risk of pulmonary embolism. The usual principles and measures of DVT prophylaxis, such as early ambulation, calf exercises or fitting of graduated compression stockings, are also important for kidney transplant patients, in particular, the high risk patients. Subcutaneous injection of low molecular weight heparin can be added for higher risk patients, such as an obese patient with a history of DVT. Of course, the corresponding bleeding risk should be taken into account as well.

7.3 Urological complications

Urological complications are quite common following renal transplant procedure associated with significant morbidity and sometimes a compromising graft function. In general, the urological complications involve any postoperative morbidity related to urinary system and male genital system, whereas the surgical complications are undoubtedly the most important, to some extent, may be prevented. Other urologic complications discussed in the literatures such as hematuria and urinary tract infection, are often a portion of symptoms or results of surgical complications; and some overlaps the surgical aspects but not the whole, for instance, urinary calculi and erectile dysfunction. Four major surgical urological complications discussed here are urine leak, ureteral obstruction, vesicoureteral reflux, and renal allograft rupture.

7.3.1 Urine leak

Urine leaks can be pyelic, vesical or ureteral in origin with a reported incidence of 1% to 4.3%. Pyelic leak is often a result of unrecognized surgical laceration of the renal pelvis during the back table preparation or transplantation. The occurrence of vesical leak is dramatically low after L-G technique fundamentally replaced the conventional transvesical ureteroneocystostomy due to escape from an additional cystic incision. But ureteral leak is constantly considered for its high incidence because the transplant ureter is by nature prone to ischemia, which is one of the two key contributing factors to ureteral leak. The blood supply of the transplant ureter only derives from the small branches of renal artery of allograft in the subtle periureteral fat and sometimes from the end arterial branches of a lower pole renal artery; thereby the more distal ureter is the more tendencies to be ischemic, which partially interprets the fact that most ureteral leak originate from the ureterovesical junction. The ischemia can be aggravated by immune injury during the course of acute rejection. The other key causative factor of leakage is surgical technical problems, most of which are technical errors that should be avoided. The leading technical error is the failure to achieve a watertight and tension-free anastomosis. Dehiscence of anastomotic site due to a full bladder from blocked Foley catheter or undetected electrocautery injury to ureter is occasionally encountered. Ureter ischemia and perforation caused by a malposed double J ureteral stent is the rare cause. The clinical presentation of ureteral leaks can be apparent or mild. Timetable of obvious symptoms have a few diagnostic significance. Leaks due to technical errors like misplacement of ureteral sutures often occur within the first 4 days, whereas leaks from necrosis usually occur within the first 14 days. The symptoms are various typically with a significant reduction of urine output but volume of perigraft drain increases dramatically, however it is not always the case. Sometimes the urine leak can not

be drained due to displacement of drains or drain tubes have been removed, the urine would flow into retroperitoneal cavity or out of the wound, or even be reabsorbed into the peritoneal cavity under high pressure or from an unrecognized hole made in the transplant procedure, developing into urine ascites. Evident manifestations include lower abdominal bulge, a swollen, tender scrotum or edema of labia, abdominal and/or back pain. Fever is a frequent sign even no evidence of infection. Graft function is compromised when large volume urine leak compress the collecting system or vessels. The diagnosis can be established if the urine output recovers and collections decrease immediately after the reinsertion of catheter into the bladder. However, generally a creatinine value mensuration of collections is needed to differentiate urine from the lymphorrhea or seroma. Creatinine in lymph and serum are almost identical, whereas that in urine is prominently high. Various imaging modalities may be used to assist the diagnosis. Ultrasonography often may be applied first for its advantages of convenient and atraumatic, urinary extravasation can be found but usually impossible to identify the origin. Intravenous pyelography might have a positive finding if the graft function is normal and a cystogram may show the leak especially when it is situated at the anastomotic site. Radionuclide imaging can be diagnostic if a confusing case is presented.

Most ureteral leak may be cured simply by prolonged catheterization for at least 2 weeks if there is an indwelling ureteral stent. If there is no ureteral stent conservative treatment is still recommended as the initial management and quite a few leakages can be resolved. If conservative method fails, surgery is indicated. Endoscopic technique is fascinating but technically challenging, the ectopic ureteral orifice and unfixed irregular position of the ureter usually make the retrograde placement of ureteral stent a mission impossible. Percutaneous nephrostomy tube placement might be more practical if there is a hydronephrosis as a result of the secondary ureteral obstruction. Therefore open surgery is recommended by many authors as a preferred management. Difficulty in locating the leak is often beyond our imagination due to the presence of extensive tissue edema. Filling and emptying the bladder intermittently, sometimes using the methylthioninium chloride, a dye, can help to identify the leak. Based on our experience, we do not recommend simple repair of the leak even if it is clear at the ureterovesical junction because ureteral stent can not be placed, more important, most leaks are a result of necrosis. Reimplantation of the ureter over a stent is a good option. If the visible necrosis is found, the transplant ureter should be cut back to where it is clearly healthy. After the removal of the necrotic part of ureter, if a tension-free anastomosis can be achieved reimplantation of the transplant ureter is usually sufficient, if not there are multiple options available to solve the problem. Above all native urinary tract should be considered, and ureteroureterostomy with the ipsilateral native ureter may be the best choice with many advantages. Boari bladder flaps are also useful if native ureter is unavailable. Boari bladder flaps have been used to bridge a loss of total ischemic ureter with a satisfactory result. But this technique reduces the bladder volume and should be selected cautiously for the "small bladder" patient from any reason. Sometimes, the bladder can be anastomosed directly to the kidney capsule with a nephrostomy tube for several weeks, but pyelovesicostomy often fail to perform due to an inability to mobilize the transplant kidney or bladder sufficiently. If the native urothelium can not be reached ileal substitution is a feasible alternative and has been reported successfully to salvage difficult and recurrent transplant urinary fistulae when native urinary tract could not be used. Appendix has been reported to replace complete necrotic ureter of pediatric recipient successfully. Recently a new minimally invasive technique of

total ureteral replacement, initially described for the palliative treatment of ureteral obstructions has been introduced as an alternative to an open procedure to treat ureteral necrosis after renal transplantation. This technique is based on the use of a silicone-polytetrafluoroethylene -bonded tube tunnelled underneath the skin to bypass the graft and bladder.

7.3.2 Ureteral obstruction

The obstruction of the transplant ureter is another most common urological complication; the incidence would be probably 3% to 7%. Causes of the obstruction are miscellaneous, which can be broadly divided into extraureteral, ureteral and intraureteral. Extraureteral factors include compression from lymphocele, hematoma, urinoma, spermatic cord or adhesive band. Ureteral cause means a ureteral twist, ureteral narrowing from ischemia, infarction or fibrosis due to rejection or infection, an anastomotic site stenosis, congenital ureteropelvic junction obstruction in the donor ureter, or in exceptional condition, a ureteral inguinal hernia. Intraureteral factors involve stone, clot, sloughed renal papilla, fungal ball or foreign body. The clinical presentation of ureteral obstruction can occur in early postoperative period or years after the transplant depending on different causes, the symptoms commonly subtle, whereas the obstruction symptoms associated with a technical error usually occur early and obvious with a symptom of acute or subacute upper urinary tract obstruction and a climbing creatinine level. Hydronephrosis on ultrasound may be seen or not according to the extent of obstruction and timing of detection.

The emergent exploration should be considered if the symptoms are apparent and advancing. The original incision can be reopened, and some possible technique faults should be taken into consideration. One rare but serious fault is that the anterior transplant ureter is angulated by a careless stitch during closing the wound, in that situation, the suture should be removed and injured ureter should be repaired carefully. A redundant and twisted ureter usually needs correction by another ureteroneocystostomy. More frequently, the problem arises from the ureterovesical junction due to overtight muscular tunnel by an aggressive anti-reflux anastomosis. We prefer reimplantation of the transplant ureter instead of simple loosen the suture over the seromuscular layer because the local edema and inflammation may proceed. Spermatic cord should be divided if it is suspected a cause of obstruction. Late ureteral stenosis is usually asymptomatic but gradual; the reason is complicated, and some of them have little relation to the surgery but most of the obstruction usually need surgical intervention for better long-term graft survival. Endoscopic technique is above all considered, unlike the urine leak, late ureteral stenosis basically accompany a hydronephrotic transplant kidney, the stricture can be diagnosed and managed in an antegrade fashion and approximately half of the patients can be cured. Balloon dilation, incision with a holmium:YAG laser or knife have been reported effective in treating transplant ureter stricture. Recurrent stricture is the main barrier for the technique as other percutaneous dilation surgery. A long-term stent is a compromise between redilation and open surgery. Open surgery is the standard way to manage the recurrent strictures, but painstaking and dangerous course is inevitable. A sufficient preparation is essential to identify the location of the stenosis, a preoperative temporary percutaneous ureteral stent is very beneficial for the assistance of locating the ureter. After finding and removing the unhealthy part of transplant ureter, the various reconstruction techniques discussed earlier can be used.

7.3.3 Vesicoureteral reflux

The exact incidence of posttransplant vesicoureteral reflux (VUR) is not known since most patients with VUR are asymptomatic and the gold standard for diagnosis, voiding cystourethrograms (VCUG), is not a routine item. When routinely checked in transplant patients in some series, the frequency of VUR varies from 1% to 86%; such a large variation can be attributed to different surgical techniques, time when VUR was tested, methods used to detect VUR, underlying urological condition, and selection criteria of the study groups. Surgical techniques are vital and controllable factors to reduce the occurrence of posttransplant VUR, therefore the non-antireflux techniques have been nearly abandoned in most of institutions. The association between VUR and urinary tract infection and reflux nephropathy has been well established in pediatric patients with native kidneys. However, the clinical significance of posttransplant VUR in the kidney transplant patients and the impact of postoperative VUR on short-term and long-term graft survival still remain controversial. Early, it was argued that VUR might be a cause of late deterioration in function, mimicking chronic rejection. Shortly after that, however, researchers suggested VUR is not a frequent cause of late renal allograft failure. A recent report has showed posttransplant VUR did not negatively affect graft function during short-term period after kidney transplantation. More recently, other authors described the presence of low-grade VUR did not affect long-term graft function in patients with late urinary tract infections. Therefore it is not necessary to screen the posttransplant VUR routinely. Positive management is only taken into account for a symptomatic posttransplant VUR. A VCUG is indicated if recurrent pyelonephritis or urinary tract infections are present, which show a symptomatic posttransplant VUR incidence of approximately 1%.

Administration of appropriate antibiotics is the primary and crucial treatment. Long-term continuous prophylaxis was sufficient in most cases. Surgical intervention is only considered for intractable cases because randomized trials of antibiotic prophylaxis versus surgical therapy plus antibiotic prophylaxis have not shown a difference in development of nonfebrile urinary tract infection in primary VUR studies. The surgery indications are recurrent febrile graft pyelonephritis or urinary tract infections refractory to antibiotic therapy and severe reflux (grade IV ~V) resulting in renal scarring or a compromising graft function. Open surgery is the standard approach to solve the problem. Reimplantation of the transplant ureter using the L-G technique has been proved to be effective and provides excellent long-term results for patients with VUR in combination with recurrent urinary tract infections after kidney transplantation. Endoscopic treatment has developed rapidly over the past decade along with the advancement of minimally invasive technique in the treatment of primary VUR. Endoscopic techniques mainly involve injection of a bulking substance into the muscular posterior wall of the ureterovesical junction. The resulting bulking effect compresses the ureteral lumen and provides a substitute for the normal muscular backing of the transmural ureter. However the overall success rates are lower than those reported for primary reflux or for open reconstruction.

7.3.4 Renal allograft rupture

Renal allograft rupture (RAR) was first described by Murray et al. in 1968. The reported incidence varies from 0.3 and 9.6%, although uncommon, it is an emergent and dangerous urological complication, potentially threatens graft and patient survival. The acute rejection is the most frequent cause of graft rupture. Acute tubular necrosis has been revealed another important risk factor comparable to severe acute rejection. Uncommon causes of RAR

include renal vein thrombosis, ureteric obstruction, renal biopsy, heparin therapy, complete lymphatic ligation, trauma, nephrostomy tubes and renal cell cancer development. RAR usually develops within 2-3 weeks after transplantation, however, the longest reported interval between clinical renal transplantation and renal allograft rupture was 4 years. Timing of the onset often indicated etiologies; rupture emerging in very early posttransplant period usually a result of renal vein thrombosis due to technique errors, for instance, twisting and kinking of the vein or intima tear; whereas rupture occurs later when caused by rejection. Clinical manifestations are commonly similar, presenting a sudden pain and swelling over the graft area, oliguria or anuria with hypotension and a drop in haematoglobin. Sometimes bleeding from the incision or haematuria can be found, fever is not uncommon. Clinical diagnosis may be confirmed by ultrasound or CT scan. On ultrasound a perinephric fluid collection or crescent of clot along the convex margin of the kidney usually can be revealed, sometimes, associated with extensive renal vein thrombosis. At the emergent exploration, a huge hematoma surrounding the convexity of the graft can usually be found, the rupture can occur along the convex border or at either renal pole. Do not hesitate to perform a prompt graft nephrectomy if there is an unsteady hemodynamic status. In other situations, the immediate decision of transplant nephrectomy is mainly depending on the condition of graft and experience of surgeon. Nephrectomy is almost the definite treatment for RAR in early age; however, surgical conservative treatment has been advocated by more authors over the past two decades, with a amazing reported salvage rate varying from 40~100%. Mattress suture of parenchyma over haemostyptic material as well as electrocautery haemostasis are the most commonly used and efficacious salvage techniques. The additional application of a mesh (Polyglactin absorbable mesh, lyophilized dura, fascia) wrapping the graft can improve the haemostasis and prevents the expansion and fragmentation of the parenchyma. In our opinion, transplant-preserving management could be attempted but not recommended when there is irreversible concomitant rejection, or a second RAR.

7.4 Lymphorrhoea and lymphocele

Lymphorrhoea, also known as lymphorrhagia, is the large volume collection of lymph that drains from perigraft drainage tubes, which may develop into a lymphocele when the collection accumulates in the postoperative dead space. The clinical incidence of lymphorrhoea and lymphocele is uncertain in large series varying from 0.6% to 18.1%, however, the actual rate of occurrence is unexpected high up to approximately 50% owing to the advent of ultrasound for routine graft surveillance, for that the majority of lymphatic collections are asymptomatic or subclinical. The major origin of the lymphorrhoea has been identified by lymphangiography and radionuclide imaging as extravasation of the lymph from the lymphatics adjacent to the iliac vessels of the recipient due to an excessive dissection of lymphatic vessels and a failure to occlude all of the lymphatic vessels divided during the preparation of the operative bed. It still remains unexplained why unligated lymphatic vessels from the renal hilum and capsule of the graft contribute so little to the formation of a lymphocele. Despite of unavoidable dissection of lymphatics overlying the iliac vessels and potential dead space the allograft create the high occurrence of lymphocele after kidney transplantation is also closely related to the immunosuppressive regimen. Steroids adversely affected macrophage function, and more important, the mTOR inhibitors such as sirolimus and everolimus have a direct antilymphangiogenic effect and powerful antifibroblastic activity, which could prevent the healing of dissected lymph channels around the host iliac

vessels. Another important contributing factor is acute cellular rejection. Obesity has been reported an independent risk factor for lymphocele formation. Low molecular weight heparin and excessive use of diuretics also have been implicated as contributing factors to lymphocele formation. Most lymphorrhea and lymphoceles are clinically silent and resolve spontaneously over time, but the clinical presentation can also be clinically evident, even presenting as 'acute abdomen'. Symptoms usually emerge at 2 weeks to 6 months after transplantation with the peak incidence at 6th week posttransplant. Symptoms may be primary or secondary, primary symptoms result from mechanical compression of lymphoceles to the adjacent structures such as abdominal bulging or mass, painless leg edema due to compression of ipsilateral iliofemoral vein, hydronephrosis as a result of compression of the ureter, urinary frequency or retention due to compression of the bladder neck. Secondary symptoms may be local or systematic, frequently misleading, such as ipsilateral DVT, deterioration of renal function, weight gain, hypertension and fever, even compartment syndrome. Ultrasonography is crucial to diagnosis, simple and effective. On ultrasound, lymphoceles appear as mostly anechoic or hypoechoic, rounded, perigraft fluid collections, they can have septations and multiple in number, Most noninfectious lymphoceles can be distinguished from hematomas and abscesses in term of distinctive homogeneity. Urinomas, usually around the ureter, have the similar appearance to a lymphocele, and may be distinguished by the irregular and indistinct margins owing to the lack of true wall. The accurate differential method is to measure the creatinine concentration of the liquid accommodating in the cysts by ultrasound-guided aspiration, also a way of treatment. This measure can also be used to differentiate lymphorrhea and urine leak when large volume of clear, weak yellow liquid collections appearing in perigraft drainage bag. Other adjunctive procedures such as CT, MR and intravenous pyelography are not routine diagnostic modality unless complicated cases happens or in preparation for a surgery.

It is unnecessary to deal with the small and asymptomatic collections for that most of them may resolve spontaneously; on the contrary, if large or symptomatic, an intervention may be necessary. The modality of treatment may be simple aspiration, percutaneous drainage placement, sclerotherapy and surgery. Percutaneous aspiration or drainage alone is sometimes curative, however, frequently the therapeutic effect is counteracted by the high recurrence rates and infection incurred. Because of the trait prone to recurrence, percutaneous aspiration or drainage combining the injection of sclerosants have been advocated by more authors as a simple, safe and efficacious minimally invasive method to manage the majority of lymphoceles due to a significantly fall of recurrence rates. Povidone-iodine is the classic and effective sclerosant, with which many novel sclerosants compare the therapeutic efficacy. Other potent sclerosants suggested in the literatures include the ethanol, diatrizoate and octreotide. Surgery is only indicated for refractory cases, the main purpose of surgery is to drain the lymph collections into the peritoneal cavity, known as "unroofing" or "fenestration". The procedure can be performed using either open or laparoscopic surgical techniques depending on its relationship with the allograft. If the cysts locate adjacent to peritoneal cavity, laparoscopic unroofing is an agreeable option. Surgeons can reach the lymphocele via transperitoneal approach; during the surgery the lymphocele wall is excised a 5cm disc and sutured to the peritoneum to keep the window open, a simultaneous omentoplasty has been recommended for a better resolvable effect. Laparoscopic procedures are least invasive but should be done meticulously to prevent the inadvertent lesions of the urinary tract to promote the advantages of laparoscopy. Open surgery is considered when the lymphoceles situates an improper position especially deep in pelvic beside vessels of graft, usually via a lower midline

abdominal incision and a transperitoneal approach. In some conditions, previous transplant incision may be reopened for better access. It is important to ensure the lymphocele cavity is full and the bladder is empty before the operation. Intraoperative ultrasound is beneficial for localization when the operative finding is dubious.

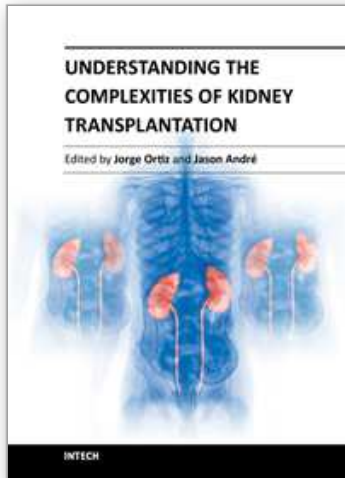
8. Conclusion

Surgical operation is the first, critical step of a successful kidney transplant. A good few graft loss result from severe surgical complications, which are frequently associated with technique errors. Meticulous surgical technique during transplantation may help avoid majority of preventable surgical complications and related morbidity and mortality.

9. References

- Bhayana, S.; Kuo, YF.; Madan, P.; Mandaym, S.; Thomas, PG.; Lappin, JA.; Rice, JC. & Ishihara, K. (2010). Pediatric en bloc kidney transplantation to adult recipients: more than suboptimal? *Transplantation*, Vol.90, No.3 (August 2010), pp. (248-254), ISSN 0041-1337
- Boggi, U.; Vistoli, F.; Signori, S.; D'Imporzano, S; Amorese, G.; Consani, G.; Guarracino, F.; Melfi, F.; Mussi, A. & Mosca, F. (2011). Robotic renal transplantation: first European case. *Transplant International*, Vol.24, No.2 (February 2011), pp. (213-218), ISSN 0934-0874
- Filocamo, MT.; Zanazzi, M.; Li Marzi, V.; Marzocco, M.; Guidoni, L.; Dattolo, E. & Nicita G. (2007). The approach by midline incision for extraperitoneal kidney transplantation. *Transplantation Proceedings*, Vol. 39, No. 10, (December 2007), pp. (3077-3080), ISSN 0041-1345
- Furness, PD 3rd.; Houston, JB.; Grampsas, SA.; Karrer, FM; Firlit, CF. & Koyle, MA. (2001). Extraperitoneal placement of renal allografts in children weighing less than 15 kg. *Journal of Urology*, Vol.166, No.3 (September 2001), pp. (1042-1045), ISSN 0022-5347
- Giulianotti, P.; Gorodner, V.; Sbrana, F.; Tzvetanov, I.; Jeon, H.; Bianco, F.; Kinzer, K.; Oberholzer, J. & Benedetti, E. (2010). Robotic transabdominal kidney transplantation in a morbidly obese patient. *American Journal of Transplantation*, Vol.10, No.6 (June 2010), pp. (1478-1482), ISSN 1600-6135
- Hoznek, A.; Zaki, SK.; Samadi, DB.; Salomon, L.; Lobontiu, A.; Lang, P. & Abbou, CC. (2002). Robotic assisted kidney transplantation: an initial experience. *Journal of Urology*, Vol.167, No.4 (April 2002), pp. (1604-1606), ISSN 0022-5347
- James, F. (2004). Transplantation of Abdominal Organs, In: *Sabiston Textbook of Surgery*, Seventeenth Edition, pp. (708-709), Elsevier, ISBN 0-7216-0409-9, Philadelphia, Pennsylvania, USA
- John, M. (2002). Renal Transplantation, In: *Campbell's Urology*, Eighth Edition, pp. (358-359), Elsevier Science, ISBN 0-7216-9058-0, Philadelphia, Pennsylvania, USA
- Jones JW. (1998). A new anastomotic technique in renal transplants reduces warm ischemia time. *Clinical Transplantation*, Vol. 12, No. 1, (February 1998), pp. (70-72), ISSN 0902-0063
- Kato, T.; Selvaggi, G.; Burke, G.; Ciancio, G.; Zilleruelo, G.; Hattori, M.; Gosalbez, R. & Tzakis, A. (2008). Partial bladder transplantation with en bloc kidney transplant--the first case report of a 'bladder patch technique' in a human. *American Journal of Transplantation*, Vol.8, No.5 (May 2008), pp. (1060-1063), ISSN 1600-6135

- Kayler, L.; Kang, D.; Molmenti, E. & Howard, R. (2010). Kidney transplant ureteroneocystostomy techniques and complications: review of the literature. *Transplantation Proceedings*, Vol.42, No. 5 (June 2010), pp. (1413-1420), ISSN 0041-1345
- Mangus, RS.; Haag, BW. & Carter, CB. (2004). Stented Lich-Gregoir ureteroneocystostomy: case series report and cost-effectiveness analysis. *Transplantation Proceedings*, Vol.36, No.10 (May 2004), pp. (2959-2961), ISSN 0041-1345
- Mital, D.; Foster, PF.; Jensik, SC.; del Rio, JV.; Sankary, HN.; McChesney, LP. & Williams, JW. (1996). Renal transplantation without sutures using the vascular clipping system for renal artery and vein anastomosis--a new technique. *Transplantation*, Vol. 62, No. 8, (October 1996), pp. (1171-1173), ISSN 0041-1337
- Nanni, G.; Tondolo, V.; Citterio, F.; Romagnoli, J.; Borgetti, M.; Boldrini, G. & Castagneto, M. (2005). Comparison of oblique versus hockey-stick surgical incision for kidney transplantation. *Transplantation Proceedings*, Vol. 37, No. 6, (August 2005), pp. (2479-2481), ISSN 0041-1345
- Nie, Z.; Zhang, K.; Huo, W.; Li, Q.; Zhu, F. & Jin, F. (2010). Comparison of urological complications with primary ureteroureterostomy versus conventional ureteroneocystostomy. *Clinical Transplantation*, Vol.24, No. 5 (October 2010), pp. (615-619), ISSN 0902-0063
- Park, SC.; Kim, SD.; Kim, JI. & Moon IS. (2008). Minimal skin incision in living kidney transplantation. *Transplantation Proceedings*, Vol. 40, No. 7, (September 2008), pp. (2347-2348), ISSN 0041-1345
- Sánchez, AS.; Tebar, JC.; Martín, MS.; Bachs, JM.; Moreno, MJ.; Navarro, HP. & Rodríguez, JA. (2005). Obstructive uropathy secondary to ureteral herniation in a pediatric en bloc renal graft. *American Journal of Transplantation*, Vol.5, No.8 (August 2005), pp. (2074-2077), ISSN 1600-6135
- Stuart, M. (2008). Renal Transplantation, In: *Smith's general Urology*, Seventeenth Edition, pp. (547-548), Lange Medical Publication, ISBN 0-07-145737-2, New York, USA
- Timsit, MO.; Lalloué, F.; Bayramov, A.; Taylor, M.; Billaut, C.; Legendre, C.; Kreis, H.; Badet, L. & Méjean, A. (2010). Should routine pyeloureterostomy be advocated in adult kidney transplantation? A prospective study of 283 recipients. *Journal of Urology*, Vol.184, No. 5 (September 2010), pp. (2043-2048), ISSN 0022-5347
- Tiong, HY.; Flechner, SM.; Zhou, L.; Wee, A.; Mastroianni, B.; Savas, K.; Goldfarb, D.; Derweesh, I. & Modlin, C. (2009). A systematic approach to minimizing wound problems for de novo sirolimus-treated kidney transplant recipients. *Transplantation*, Vol.87, No.2 (January 2009), pp. (296-302), ISSN 0041-1337
- Voiculescu, A.; Hollenbeck, M.; Plum, J.; Hetzel, GR.; Mödder, U.; Pfeiffer, T.; Sandmann, W. & Grabensee, B. (2003). Iliac artery stenosis proximal to a kidney transplant: clinical findings, duplex-sonographic criteria, treatment, and outcome. *Transplantation*, Vol.76, No.2 (July 2003), pp. (332-339), ISSN 0041-1337
- van Heurn, E & de Vries, EE. (2009). Kidney transplantation and donation in children. *Pediatric Surgery International*, Vol.25, No.5 (May 2009), pp. (385-393), ISSN 0179-0358
- Wong, VK.; Baker, R.; Patel, J.; Menon, K. & Ahmad N. (2008). Renal transplantation to the ovarian vein: a case report. *American Journal of Transplantation*, Vol. 8, No. 5 (May 2008), pp. (1064-1066), ISSN 1600-6135
- Ye, G.; Mo, HG.; Wang, ZH.; Yi, SH.; Wang, XW. & Zhang YF. (2006). Arterial anastomosis without sutures using ring pin stapler for clinical renal transplantation: comparison with suture anastomosis. *Journal of Urology*, Vol. 175, No. 2, (February 2006), pp. (636-640), ISSN 0022-5347



Understanding the Complexities of Kidney Transplantation

Edited by Prof. Jorge Ortiz

ISBN 978-953-307-819-9

Hard cover, 564 pages

Publisher InTech

Published online 06, September, 2011

Published in print edition September, 2011

Kidney transplantation is a complex field that incorporates several different specialties to manage the transplant patient. This book was created because of the importance of kidney transplantation. This volume focuses on the complexities of the transplant patient. In particular, there is a focus on the comorbidities and special considerations for a transplant patient and how they affect kidney transplant outcomes. Contributors to this book are from all over the world and are experts in their individual fields. They were all individually approached to add a chapter to this book and with their efforts this book was formed. Understanding the Complexities of Kidney Transplantation gives the reader an excellent foundation to build upon to truly understand kidney transplantation.

How to reference

In order to correctly reference this scholarly work, feel free to copy and paste the following:

Junjie Zhao, Zhenli Gao and Ke Wang (2011). The Transplantation Operation and Its Surgical Complications, Understanding the Complexities of Kidney Transplantation, Prof. Jorge Ortiz (Ed.), ISBN: 978-953-307-819-9, InTech, Available from: <http://www.intechopen.com/books/understanding-the-complexities-of-kidney-transplantation/the-transplantation-operation-and-its-surgical-complications>

INTECH
open science | open minds

InTech Europe

University Campus STeP Ri
Slavka Krautzeka 83/A
51000 Rijeka, Croatia
Phone: +385 (51) 770 447
Fax: +385 (51) 686 166
www.intechopen.com

InTech China

Unit 405, Office Block, Hotel Equatorial Shanghai
No.65, Yan An Road (West), Shanghai, 200040, China
中国上海市延安西路65号上海国际贵都大饭店办公楼405单元
Phone: +86-21-62489820
Fax: +86-21-62489821

© 2011 The Author(s). Licensee IntechOpen. This chapter is distributed under the terms of the [Creative Commons Attribution-NonCommercial-ShareAlike-3.0 License](https://creativecommons.org/licenses/by-nc-sa/3.0/), which permits use, distribution and reproduction for non-commercial purposes, provided the original is properly cited and derivative works building on this content are distributed under the same license.

IntechOpen

IntechOpen