

We are IntechOpen, the world's leading publisher of Open Access books Built by scientists, for scientists

4,800

Open access books available

122,000

International authors and editors

135M

Downloads

Our authors are among the

154

Countries delivered to

TOP 1%

most cited scientists

12.2%

Contributors from top 500 universities



WEB OF SCIENCE™

Selection of our books indexed in the Book Citation Index
in Web of Science™ Core Collection (BKCI)

Interested in publishing with us?
Contact book.department@intechopen.com

Numbers displayed above are based on latest data collected.
For more information visit www.intechopen.com



Transplantation for the Complex Patient with Hepatitis C and End Stage Renal Disease: A Review

Jorge Ortiz, Jason Andre and Kamran Khanmoradi Victor Araya
*Albert Einstein Medical Center, Philadelphia PA
USA*

1. Introduction

Hepatitis C (HCV) and End Stage Renal Disease (ESRD) are two major health issues affecting millions worldwide. The diagnosis of HCV in the dialysis patient has significant prognostic indications and specific interventions are necessary in order to evaluate the extent of liver disease and the feasibility of medical treatment or the need for organ replacement therapy. For the transplant candidate, unique issues with respect to immunosuppressive agents and the appropriate use of HCV positive donors may be particularly vexing. Prior reviews have focused on issues classically limited to nephrology or hepatology, this update will address transplantation issues as well.

2. Epidemiology

The Hepatitis C virus (HCV) is a member of the Flaviviridae family. Approximately 150 million people are infected by this single stranded RNA virus, 5 million of whom live in the United States. It is estimated that 85% of patients will develop chronic infection, which is defined as the presence of HCV RNA for six months after presumed onset. Subsequent spontaneous clearing of the virus is rare. Approximately 10-30% will develop cirrhosis. In the renal dialysis population, the incidence of de novo infection is 3-7% per year. The prevalence ranges from 10-20% and may be underestimated due to cases of low viral load.^{1,2,3}

Factors associated with virus acquisition in this patient population include the number of blood units transfused (which has decreased with the advent of erythropoietin alpha and blood bank screening), the length of dialysis therapy and the type of renal replacement therapy. Patients on hemodialysis are at higher risk compared to those on peritoneal dialysis.⁴ There are at least six genotypes and many subtypes. HCV accounts for 30-50% of liver transplantation procedures performed and is also associated with many extra hepatic manifestations,⁵ (Table 1) most importantly diabetes. The mechanisms underlying the diabetogenicity of HCV likely involve insulin resistance, diminished hepatic glucose uptake and the directly injurious effect of the virus on beta cells of the pancreas.⁶ In the kidney, HCV is strongly associated with membranoproliferative glomerulonephritis (MPGN), membranous glomerulonephritis, focal segmental glomerulosclerosis, mesangial proliferative glomerulonephritis⁷ and albuminuria.⁸ Clinically silent immune complex

glomerulonephritis was commonly seen in biopsies of patients with end stage HCV liver disease undergoing liver transplantation.⁹

Antiphospholipid syndrome
Aplastic Anemia
Autoimmune hemolytic anemia
Autoimmune thyroiditis
Chronic fatigue syndrome
Behcet's Syndrome
Carotid atherosclerosis
CRST syndrome
Dermatomyositis
Diabetes
Fibromyalgia
Guillain-Barré syndrome
Hypertrophic cardiomyopathy
Hypocholesterolemia
Idiopathic pulmonary fibrosis
Idiopathic thrombocytopenic purpura
IgA deficiency
Lichen planus
MALToma
Mooren corneal ulcers
Multiple myeloma
Non-Hodgkins lymphoma
Neurocognitive impairment
Pancreatitis Polyarteritis nodosa
Polymyositis Porphyria cutanea tarda
Rheumatoid arthritis
Sialadenitis
Sjogren's syndrome
Systemic lupus erythematosus
Uveitis
Waldenstrom's macroglobulinemia

Table 1. Extrahepatic disease manifestations with HCV infection

3. Evaluation for treatment and kidney transplantation

Evaluation of the potential kidney transplant recipient with HCV involves a careful history and physical examination. Patients with encephalopathy, variceal bleeding, ascites and muscle wasting have significant risk of continued deterioration and should be considered for liver (and kidney) transplantation. The presence of hepatocellular carcinoma within the Milan or UCSF criteria¹⁰ should also be considered an indication for combined liver and kidney transplantation.

False positives (and negatives (0.23%)) are not uncommonly seen with the current generation of ELISA blood tests and therefore a confirmatory PCR should be ordered¹¹. The

mean time from detection of HCV RNA to the appearance of antibody may be as long as six months¹². Nevertheless, screening with PCR is not recommended. A negative PCR in a previously positive patient should be repeated because frequent variations in the viral load can be seen. The genotype of the virus may determine its susceptibility to interferon treatment. However, early studies in patients with renal replacement therapy failed to demonstrate that HCV genotype is a factor in interferon responsiveness¹³. Additionally, HCV genotype does not seem to influence survival in renal transplant recipients¹⁴.

4. Biopsy

Liver function tests are not sensitive enough to determine whether there is significant inflammation or even cirrhosis¹⁵. Liver biopsies are therefore indicated in all HCV positive candidates being considered for kidney transplantation and possible treatment. Studies indicate that advanced fibrosis is a common finding despite normal aminotransferase levels¹⁶. Histologic features of chronic hepatitis will be seen in 100% of ESRD patients with HCV. 60-80% of patients will have significant fibrosis and 10-12% will have cirrhosis¹⁷. Established cirrhosis was found to be the most important predictor of death after renal transplantation and is considered a relative contraindication to isolated renal transplantation¹⁸. If the liver biopsy shows cirrhosis mandatory screening for hepatocellular carcinoma must be instituted¹⁹.

Regarding the biopsy technique, obtaining tissue via the transjugular route may be safer than the percutaneous method especially if the patient has ascites, disorders of the coagulation system or undergoes peritoneal dialysis. An additional advantage of the transjugular approach is the determination of portal pressure gradients which may help to diagnose sub clinical portal hypertension. Radiologic imaging or upper endoscopy (another important screening tool) may demonstrate obvious cirrhosis and varices perhaps obviating the need for this particular intervention. In the absence of cirrhosis, biopsies should be performed at five year intervals. Surrogate serum markers for fibrosis and cirrhosis have been investigated but are not yet the standard of care²⁰.

5. Hepatocellular carcinoma

The incidence of hepatocellular carcinoma (HCC) is increasing in the general population²¹ and is higher in patients with ESRD. The prognosis is also worse for patients with ESRD²². Screening is crucial as prognosis after the onset of symptoms is dismal while patients with small expeditiously treated lesions reap a significant survival advantage. The yearly risk of HCC in patients with HCV is highest in those with established cirrhosis (about 2-8% per year). HCV infected patients who do not have cirrhosis have a lower risk of developing HCC. Based on current knowledge all patients with HCV and cirrhosis should undergo surveillance. This should entail a radiologic exam (CT scan, MRI or ultrasound) and alpha fetoprotein monitoring. These screens should be performed (in cirrhotics) at 6-12 month intervals. If HCC is found, metastatic workup includes bone scans and chest CT scans. Surgical resection can be safely performed for patients with ESRD and preserved liver function²³. For patients with decompensated cirrhosis and small solitary HCC or early multifocal disease (up to three lesions, total tumor burden less than 6.5cm) the best option is liver (and kidney) transplantation²⁴. Other modalities used to treat HCC include chemoembolization, alcohol infusion, radiofrequency ablation, Y-90, and acetic acid infusion.

Systemic chemotherapy is not associated with improvements in patient survival. Sorafenib (Nexavar) may be associated with survival improvements in untransplantable patients.

6. Anti viral therapy

Antiviral therapy before transplantation with the objective of eradicating the virus is the current standard of care. Secondary benefits may include the prevention of hepatic decompensation and hepatocellular carcinoma. In dialysis patients, the only recommended treatment is Alpha Interferon monotherapy. The average virological response is 40% and is independent of genotype. Interferon therapy interruption, seen in up to 60% of patients, is due to side effects. The most common of which are flu like symptoms, neurologic symptoms and gastrointestinal symptoms. Sustained viral response (SVR) may be durable (22 months average) post transplantation in those patients successfully treated before surgery. Of the sixteen patients studied in one report, HCV viral counts remained negative in all.²⁵ Immunosuppressive issues remain troublesome in this complex patient population. Others have also indicated that successfully treated dialysis patients may have an improved graft survival and lower incidence of HCV related kidney disease²⁶ and new onset post transplant diabetes.

The higher rate of SVR after interferon therapy may result from higher levels of interferon in patients with renal failure. The dose of interferon is 3 million units one to three times a week. Pegylated interferons, although commonly used, are not yet recommended. From a pharmacokinetic standpoint dose adjustments would probably be unnecessary in patients with renal impairment²⁷. Absorption may vary with a patient on dialysis²⁸. One study reported 87.5% viral clearance in 8 patients after 12 weeks of therapy. All of the 6 patients who completed 48 weeks of therapy achieved a biochemical response²⁸. In another report, two of six genotype 1 patients completed a 24 week course of Pegylated Interferon and achieved a SVR³⁰. The appropriate dose of Pegylated Interferon Alpha-2 is probably 135 micrograms a week, this gives similar serum levels as 180 micrograms per week in patients with preserved renal function. Pegylated Interferon Alpha-2 should probably be dosed between 0.5-1.0 micrograms/kg (as opposed to 1.0-1.5 ug/kg)³¹.

Ribavirin is contraindicated, alone and with interferon, because of the hemolytic anemia associated with it. However, some groups have shown that it can be used in combination with interferon at reduced dosages with plasma monitoring and erythropoietin and iron supplementation³². These studies did not prove that ribavirin in low doses, in this population, improved response rates. It is very important to note that if hemolysis results in anemia that necessitates blood transfusion, the patient may be rendered untransplantable because of increased immune reactivity. Amantadine has not proven beneficial.

In kidney transplant recipients, interferon treatment is contraindicated because of the increased risk of acute cellular and antibody mediated rejection³³. An exception is the patient with fibrosing cholestatic hepatitis (FCH). FCH is characterized by cholestasis with only mild to moderate elevation of transaminases and a rapid deterioration in liver function³⁴. Some investigators believe that after combined liver and kidney transplantation, the liver protects the kidney from rejection and interferon can therefore safely be administered.

Ribavirin monotherapy may improve serum aminotransferases and proteinuria, but its effect on liver histology is controversial. Chronic hemolysis may prevent its safe use. Some

have recommended that ribavirin be dose adjusted for those renal transplant recipients with HCV who have developed significant proteinuria³⁵.

7. Prognosis

HCV infection in renal failure patients is usually asymptomatic. The virus seems to have a lower impact on the liver histology of dialysis patients than on the histology of the HCV-positive immunocompetent patients with normal renal function³⁶. It would appear that histological progression of liver injury after transplantation is minimal in HCV positive kidney recipients. In fact, fibrosis might regress in some patients³⁷. Nevertheless, it is a negative prognostic indicator for survival on dialysis and after kidney transplantation. HCV may intensify oxidative stress in patients with uremia, leading to cardiovascular compromise³⁸. Diabetes and cardiovascular disease were statistically significantly associated with patient death (while on dialysis) in one study³⁹. Those patients with cirrhosis have a 35% higher death rate than noncirrhotic counterparts.^{40,41} In another report, HCC was a statistically significantly more common cause of death in HCV positive dialysis patients⁴². Overall survival in these patients is improved after kidney transplantation compared to remaining on dialysis, despite the theoretical risk of accelerating virus replication with immunosuppression⁴³, but worse than HCV negative counterparts. This might be related to an increased risk of cardiovascular disease, posttransplant diabetes mellitus, sepsis^{44,45,46}, and rejection⁴⁷. Thrombotic microangiopathy, MPGN and proteinuria are also associated with HCV infection and may result in lower rates of patient and graft survival⁴⁸. The most common cause of proteinuria post transplant is still chronic allograft nephropathy, and a biopsy is crucial for the diagnosis⁴⁹. All cause hospitalizations are significantly higher in HCV positive kidney recipients compared to HCV negative ones. HCV positive kidney transplant recipients are more likely to be African American, male, older, and have a higher rate of alcohol abuse, experience extended time on dialysis, malnutrition (as measured by serum albumin) and prior transplantation. Those patients with concomitant hepatitis B infection do particularly poorly in terms of patient and graft survival⁵⁰. As do patients with HIV co-infection⁵¹.

8. HCV and Tacrolimus

As stated, HCV infection is associated with pre transplant and de novo post transplant diabetes. This is seen more commonly with Tacrolimus compared to Cyclosporine. Nevertheless, the U.S. FK506 multicenter trial demonstrated higher patient survival in those HCV positive patients who received Tacrolimus compared to Cyclosporine. According to a recent query of the UNOS database (Tables 2-3), 1,3,5 year graft survival for HCV positive recipients of HCV negative organs was 89.7%, 76.7% and 61.6% for those patients treated with cyclosporine. 1,3,5 year graft survival with Tacrolimus immunosuppression was 92.2%, 80.6% and 63.3%. If the donor were HCV positive, 1,3,5 year graft survival for HCV positive recipients was 92.7%, 76% and 56.3% for cyclosporine treated recipients and 89.6%, 74.6% and 52.5% for Tacrolimus treated patients. Patient survival at 1,3, and 5 years for HCV negative donor organs was 94.8%, 88.8% and 80.5% with cyclosporine 95.6%, 89.4% and 79.7% with Tacrolimus. If the donor were HCV positive, patient survival at 1,3 and 5 years was 98%, 91.1% and 82% for cyclosporine and 93.9%, 87% and 75.8% for Tacrolimus.⁵² The mechanisms behind diminished graft and patient survival with HCV positive donors and Tacrolimus immunosuppression are not entirely clear.

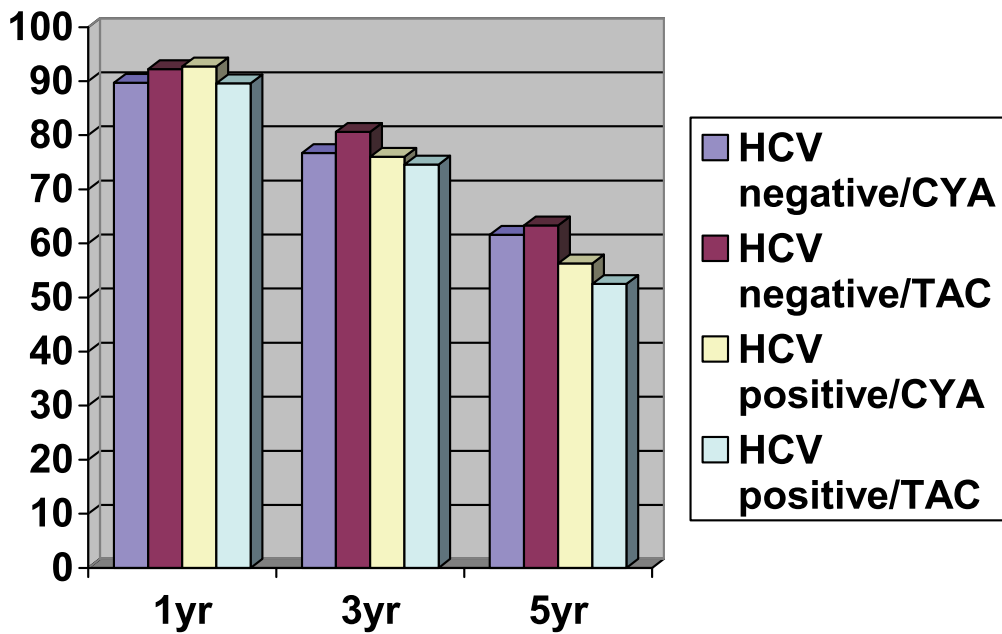


Table 2. Graft Survival by Donor HCV status and Main Maintenance Immunosuppression Agent

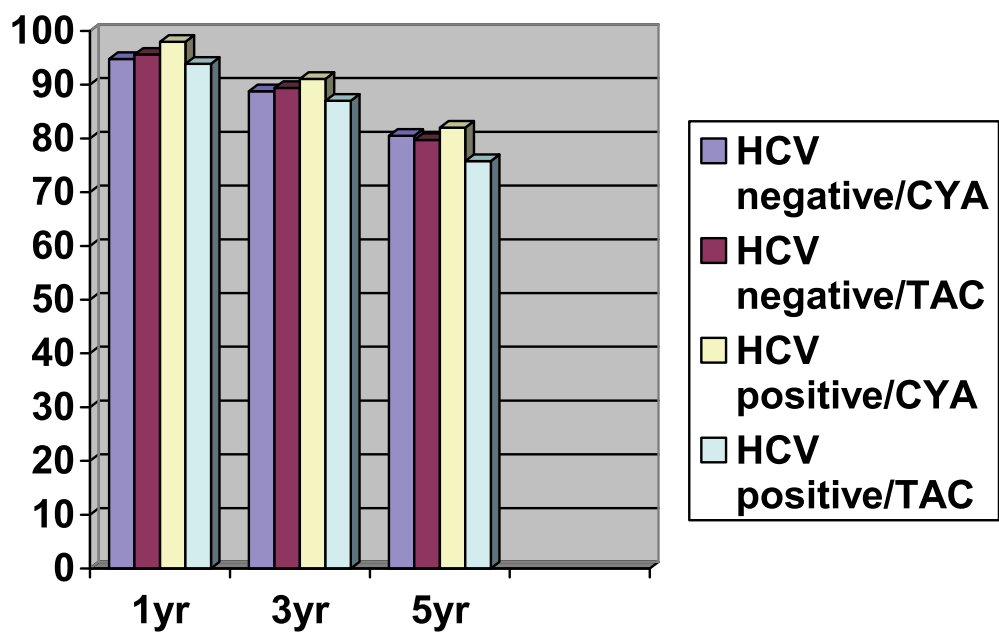


Table 3. Patient Survival By Donor HCV Status and Main Maintenance Immunosuppression Agent

9. Mycophenolate, steroids and induction agents

Another risk factor for diabetes, and a multitude of other complications, is prolonged steroid usage. Early rapid withdrawal has been reported to be safe (at least in the short term) compared with a historic control group⁵³. The use of mycophenolate mofetil is associated with improved survival (at least with HCV positive donors) due to fewer infectious deaths⁵⁴. Patients induced with OKT3 or anti-lymphocyte globulin have experienced inferior survivals⁵⁴. The UNOS database was queried for 1,3 and 5 year patient and graft survival for HCV recipients of donor positive and donor negative organs stratified by induction agent (see Table 4). Definitive conclusions pertaining to the best induction agent for the ESRD patient with HCV can not be made until randomized prospective trials are performed.

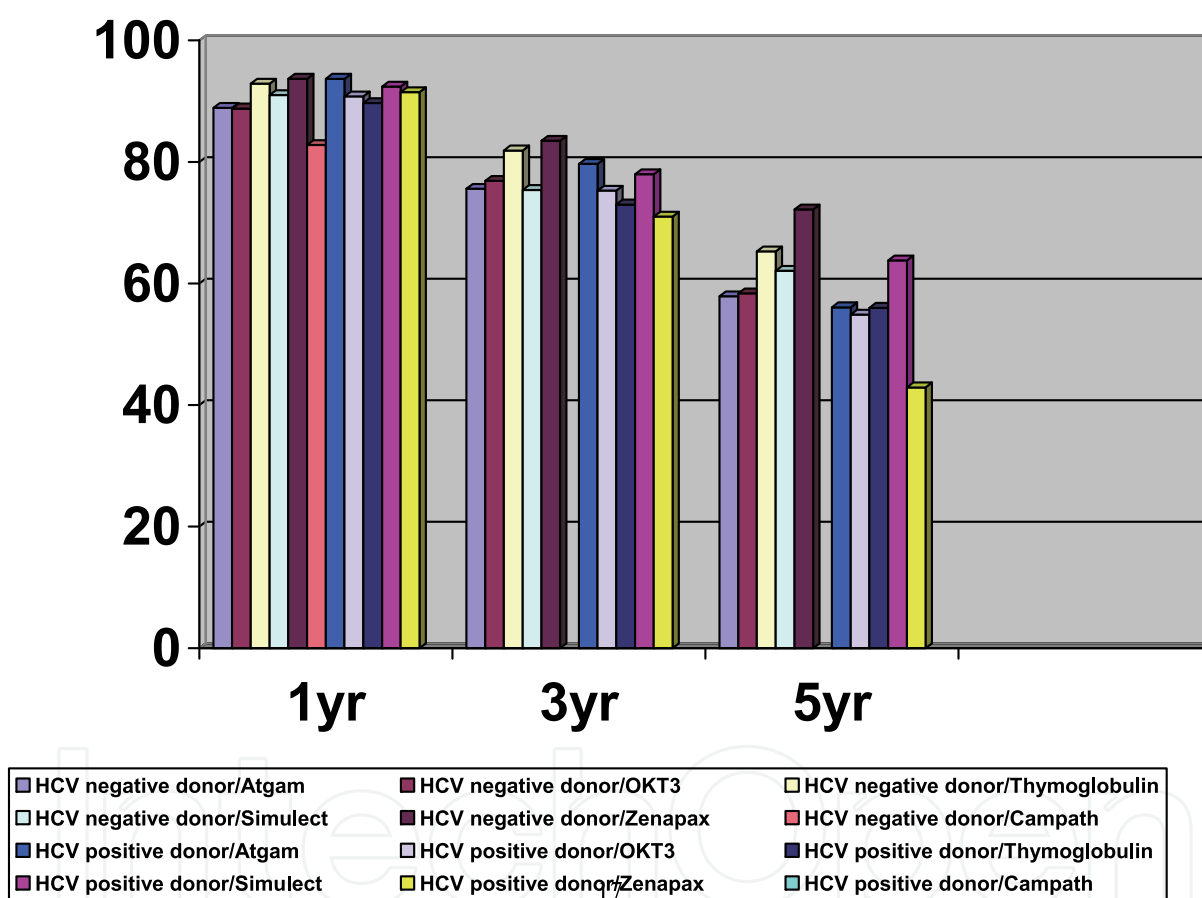


Table 4. Graft Survival by Donor HCV Status and Induction Agent

10. HCV positive donors

The organ donor shortage has compelled centers to transplant kidneys from donors who test positive for HCV. The prevalence and utilization of HCV positive organ donor referrals has increased in the United States. The prevalence of HCV is several fold higher in deceased donors compared to healthy living blood donors. Almost 20% of anti HCV positive donors will be RNA negative⁵⁶. The utilization of HCV positive kidneys for HCV negative recipients is contraindicated^{57, 58}.

Surprisingly, Bucci et al demonstrated that 34.1% of HCV positive donor kidneys were allocated to HCV negative recipients in the United States in 2000⁵⁹. The use of donor positive kidneys for HCV positive recipients is associated with greater long term mortality compared to virus negative kidneys. Although HCV positive recipients more frequently develop new onset diabetes mellitus (NODM) compared to negative controls, the risk is heightened with HCV positive donors⁶⁰. Nevertheless, in comparison to staying on the waitlist, transplantation with donor virus positive kidneys is associated with increased survival in HCV positive recipients⁶¹. There is no definitive proof that conversion of genotype after transplantation portends a bad prognosis. Nevertheless, one case reported did implicate a genotypic mismatched kidney transplant in the exacerbation of hepatic dysfunction⁶². Any possible adverse effect of super infection with a different genotype is believed to be outweighed by the beneficial effect of decreased time on dialysis⁶³.

11. Summary

The patient with HCV and ESRD is very complex. All positive antibody screens should be confirmed with PCR. The standard workup should include a search for clinical signs of hepatic decompensation and a liver biopsy. The biopsy, if it does not show cirrhosis, should be repeated at 5 year intervals. Patients should be treated with interferon if at all possible in order to minimize long term hepatologic complications and to improve outcomes after kidney transplantation. The formulation of interferon and the exact dosing remain a matter of debate. Ribavirin should probably be used only with close follow up and in a setting of a trial. After transplantation, interferon is contraindicated.

Although HCV is a negative prognostic indicator, those patients with HCV are better served transplanted compared to remaining on the waitlist. HCV positive organ donors are also a negative prognostic indicator but nonetheless may confer a significant survival advantage due to the associated decrease in the wait time for a deceased organ. Decompensated cirrhosis is an indication for combined liver and kidney transplantation. At this time well compensated cirrhotics are not considered candidates for single or dual organ transplants, although many centers perform both. Mycophenolate mofetil and steroid freedom have been shown to be safe in this patient population. The results with various calcineurin inhibitors and induction agents have been reviewed. Until randomized perspective trials are performed, the choice of which medication to employ is center specific and experience driven.

12. Conclusion

HCV will remain a major health issue for decades to come. Appropriate communication between disciplines is mandatory in order to ensure excellent patient outcomes. Randomized trials and multi-disciplinary meetings are indicated.

13. References

- [1] Hanuka N, Sikueler E, Tovbin D, et al: Hepatitis C virus infection in renal failure patients in the absence of anti-hepatitis C virus antibodies. *Journal of Viral hepatitis* 2002, 9:141
- [2] Lauer GM, Walder BD. Hepatitis C virus infection. *N Engl J Med* 2001, 345:41

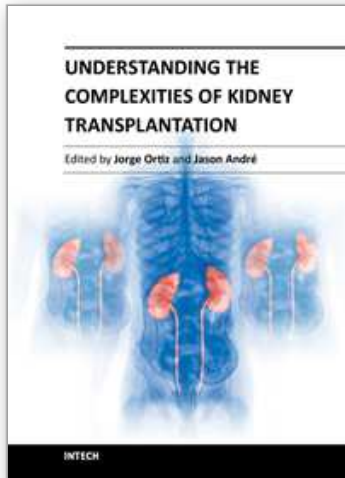
- [3] Batty DS Jr, Swanson SJ, Kirk AD, et al. Hepatitis C virus seropositivity at the time of renal transplantation in the United States: associated factors and patient survival. *Am J Transplant* 2001, 1:179
- [4] Pereira BJG. Hepatitis C in organ transplantation: Its significance and influence on transplantation policies. *Curr Opin Nephrol Hypertens* 1993, 2:912
- [5] Agnello V, De Rosa FG. Extrahepatic disease manifestations of HCV infection: some current issues. *Journal of Hepatology* 2004, 40:341
- [6] Masini M, Campani D, Boggi U et al. Hepatitis C virus infection and human pancreatic beta-cell dysfunction. *Diabetes care* 2005, 28:940
- [7] Gopalani A, Ahuja TS. Prevalence of glomerulopathies in autopsies of patients infected with the hepatitis C virus. *Am J Med Sci* 2001, 322:57
- [8] Tsui JL, Vittinghoff E., Shlipak MG, et al., Relationship between Hepatitis C and Chronic Kidney Disease: Results from the Third National Health and Nutrition Examination Survey. *J Am Soc Nephrol* 2006, 17:1168
- [9] McGuire BM, Julian BA, Synon S, et al. Brief Communication: Glomerulonephritis in Patients with Hepatitis C Cirrhosis Undergoing Liver Transplantation. *Ann Intern Med* 2006, 144:735
- [10] Mazzaferro V; Regalia E; Doci R, et al. Liver transplantation for the treatment of small hepatocellular carcinomas in patients with cirrhosis. *N Engl J Med* 1996, 334(11):693-9
- [11] Schneeberger PM, Keur I, Van der Vliet W, et al. Hepatitis C virus infection in dialysis centers in the Netherlands: a national survey by serological and molecular methods. *J Clin Microbiol* 1998, 36:1711
- [12] Furusyo N, Hayashi J, Kakuda K, et al. Acute Hepatitis C among Japanese hemodialysis patients: a prospective 9-year study. *Am J Gastroenterol* 2001, 96:1593
- [13] Izopet J, Rostaing L, Mousson F, et al. High rate of hepatitis C virus clearance in hemodialysis patients after interferon-alpha therapy. *J Infect Dis* 1997; 17:1614
- [14] Natov SN, Lau JY, Ruthazer R, et al. Hepatitis C virus genotype does not affect patient survival among renal transplant candidates. The New England Organ Bank Hepatitis C Study Group. *Kidney Int* 1999, 56:700
- [15] Fabrizi F, Martin P, Dixit V, et al. Acquisition of hepatitis C virus in hemodialysis patients: a prospective study by branched DNA signal amplification assay. *Am J Kidney Dis* 1998; 31:647
- [16] Sterling RK, Sanyal AJ, Luketic VA, et al. Chronic hepatitis C infection in patients with end stage renal disease: characterization of liver histology and viral load in patients awaiting renal transplantation. *Am J Gastroenterol* 1999, 94:3576
- [17] Martin P, Carter D, Fabrizi F, et al. Histopathologic features of hepatitis C in renal transplant candidates. *Transplantation* 2000, 69:1479
- [18] Mathurin P, Mouquet C, Poynard T, et al. Impact of HBV and HCV on kidney transplantation outcome. *Hepatology* 1999, 29: 257
- [19] Llovet JM, Burroughs A, Bruix J. Hepatocellular carcinoma. *Lancet* 2003; 362:1907-1917
- [20] Varaut A, Fontaine H, Serpaggi Je, et al. Diagnostic Accuracy of the Fibrotest in Hemodialysis and Renal Transplant Patients with Chronic Hepatitis C Virus. *Transplantation* 2005, 80:1550
- [21] El-Serag HB, Mason AC: Rising incidence of hepatocellular carcinoma in the United States. *N Engl J Med* 1999; 340:745-750

- [22] Hayashi H, Ohtake Y, Kashima T, et al: Hepatocellular carcinoma among hemodialysis patients infected with hepatitis C virus-early evolution and rapid prognosis. *Clin Nephrol* 1999;51:321-323
- [23] Cheng S, Wu C Shu K, Ho W et al. Liver Resection for Hepatocellular Carcinoma in Patients With End-Stage Renal Failure. *Journal of Surgical Oncology* 2001; 78:241-247
- [24] Bruix J and Sherman M. Management of Hepatocellular Carcinoma. *Hepatology*, vol 42, No 5, 2005
- [25] Kamar N, Toupance O., Buchler M. Evidence that clearance of hepatitis C virus RNA after alpha-interferon therapy in dialysis patients is sustained after renal transplantation. *J Am Soc Nephrol* 2003, 14:2092
- [26] Cruzado J.M., Casanovas-Taltavull T., Torras J. Pretransplant interferon prevents hepatitis C virus-associated glomerulonephritis in renal allografts by HCV -RNA clearance. *Am J Transplant* 2003, 3:357
- [27] Martin P., Mitra S., Farrington K. Pegylated (40kDa)interferon alfa=2a (Pegasys) is unaffected by renal impairment. *Hepatology* 2000, 32:370
- [28] Barril G., Quiroga J.A. Sanz P. Pegylated interferon alfa 2a kinetics during experimental hemodialysis: impact of permeability and pore size of dialyzers. *Aliment Pharmacol Ther* 2004, 20:37
- [29] Sporea I., Sirli R., Golea O., Peg interferon alfa 2a (40kDA) in patients on chronic hemodialysis with chronic C hepatitis: preliminary results. *Rom J Gastroenterol* 2004, 20:99
- [30] Annichiarico A.E., Siciliano M., Pegylated interferon-alpha 2 monotherapy for hemodialysis patients with chronic hepatitis C. *Aliment Pharmacol Ther* 2004, 20:123
- [31] Fried MW, Shiffman ML, Reddy KR, et al. Peginterferon alfa-2a plus ribavirin for chronic hepatitis C virus infection-a pilot study. *N Engl J Med* 2002, 347:975
- [32] Bruchfeld A, Stahle L, Andersson J, et al. Ribavirin treatment in dialysis patients with chronic hepatitis C virus infection-a pilot study. *J Viral Hepat* 2001, 8:287
- [33] Baid S, Tolckoff-Rubin N, Saidman S, et al. Acute Humoral rejection in hepatitis C-infected renal transplant recipients receiving antiviral therapy. *Am J Transplant* 2003, 3:74
- [34] Toth CM, Pascual M, Chung RT, et al. Hepatitis C virus-associated fibrosing cholestatic hepatitis after renal transplantation. *Transplantation* 1988, 66:1254
- [35] Kamar, N, Ribes D, Izopet J, et al. Treatment of hepatitis C Virus Infection (HCV) After renal Transplantation: Implication for HCV-Positive Dialysis Patients Awaiting a Kidney Transplant. *Transplantation* 2006, 82:853
- [36] Alric L, Di-Martino V, Selves J. et al. Long term impact or renal transplantation on liver fibrosis during hepatitis C virus infection. *Gastroenterology* 2002; 123(5):1494
- [37] Kamar N, Rostaing L, Selves J et al. Natural history of hepatitis C virus-related liver fibrosis after renal transplantation. *Am J Transplant* 2005, 5:1704
- [38] Pawlak K, Pawlak D, Mysliwiec M. Hepatitis intensified oxidative stress, MIP-1 beta and RANTES plasma levels in uraemic patients. *Cytoine* 2004, 28:197
- [39] Bloom RD, Sayer G., Kosuntarty F et al. Outcome of Hepatitis C virus Infected Kidney Transplant Candidates Who Remain on the Waiting List. *Am J Transplant* 2005, 5:139

- [40] Fabrizi F, Poordad FF, et al. Hepatitis C Infection and the Patient with End-Stage renal Disease. *Hepatology* 2002, 36:3
- [41] Marcelli D, Stanhard D, Conte F, et al. ESRD patient mortality with adjustment for comorbid conditions in Lombardy (Italy) versus the United States. *Kidney Int* 1996; 50:1013
- [42] Maisonneuve P., Agodoa L., Geller R. Cancer in patients on dialysis for end-stage renal disease: an international collaborative study. *Lancet* 1999, 354:93
- [43] Knoll GA, Tankersley MR, Lee JY, et al. The impact of renal transplantation on survival in hepatitis C-positive end stage renal patients. *Am J Kidney Dis* 1997; 29:608
- [44] Yunossi Zzm, Braun WE, Protiva DA et al. Chronic viral hepatitis in renal transplant recipients with allografts functioning for more than 20 years. *Transplantation* 1999, 67:272
- [45] Fabrizi F, Martin P, Dixit V, et al. Post-transplant diabetes mellitus and HCV seropositive status after renal transplantation: Meta analysis of clinical studies. *Am J Transplant* 2005, 5:2433
- [46] Pereira BJ, Wright TL, SchmidCH, Levey AS. The impact of pretransplantation hepatitis C infection on the outcome of renal transplantation. *Transplantation* 1995, 60:799
- [47] Sotsky T, Polyak MR, Riggio R et al. Hepatitis C infection confers increased risk of immunologic failure following renal transplantation. *Transplantation* 1999; 67 Suppl 1):S577
- [48] Baid S, Pascual M, Williams WW, et al. Renal thrombotic microangiopathy associated with anticardiolipin antibodies in hepatitis C-positive renal allograft recipients. *J Am Soc Nephrol* 1999, 10:146
- [49] Nampoory MR, Johnny KV, Costandi JN, et al. High incidence of proteinuria in hepatitis C virus infected renal transplant recipients is associated with poor patient and graft outcome. *Transplant Proc* 2001, 33:3639
- [50] Breitenfeldt MK, Rasenack J, Berthold H, et al. Impact of hepatitis B and C on graft loss and mortality of patients after kidney transplantation. *Clin Transplant* 2002, 16:130
- [51] Rostaing L, Izopet J, Cisterne JM, et al: Impact of hepatitis C virus duration and hepatitis C virus genotypes on renal transplant patients: Correlation with clinicopathological features. *Transplantation* 1998, 65:930
- [52] www.UNOS.org OPTN data accessed 12/08/06
- [53] Akalin E, Murphy B, Sehgal V, et al. Rapid steroid withdrawal in hepatitis C virus-positive kidney transplant recipients *Clin Transplant* 2004, 18:384
- [54] Abbott KC, Bucci JR, Matsumoto CS, et al. Hepatitis C and renal Transplantation in the Era of Modern Immunosuppression. *J Am Soc Nephrol* 2003, 14:2908
- [55] Gentil MA, Rocha JL, Rodriguez-Algarra G et al. Impaired kidney transplant survival in patients with antibodies to hepatitis C virus. *Nephrol Dial Transplant* 1999, 14:2908
- [56] Pereira B, Milford E, Kirkman R, et al. Prevalence of HCV RNA in organ donors positive for HCV antibody and in the recipients of their organs. *N Engl J Med* 1992, 327:910
- [57] <http://www.hdcn.com/symp/03asn/09/per/per.htm>
- [58] Natov SN, Pereira BJ. Transmission of viral hepatitis by kidney transplantation: donor evaluation and transplant policies (Part 2:hepatitis C virus). *Transpl Infect Dis* 2002, 4:124

- [59] Bucci JR, Matsumoto CS, Swanson SJ, et al. Donor hepatitis C seropositivity: clinical correlates and effect on early graft and patient survival in adult cadaveric kidney transplantation. *J Am Soc Nephrol* 2002, 13:2974
- [60] Abbott KC, Lentine KL, Bucci JR, et al. Impact of diabetes and hepatitis after kidney transplantation on patients who are affected by hepatitis C virus. *J Am Soc Nephrol* 2004, 15:3166
- [61] Abbot KC, Lentine KL, Bucci JR, et al. The Impact of Transplantation with Deceased Donor hepatitis C-Positive Kidneys on Survival in Wait-Listed Long Term Dialysis Patients. *Am J. Transplant* 2004, 4:2032
- [62] Schussler T, Staffield-Coit C., Eason J, et al. Severe Hepatitis C Infection in a Renal Transplant Recipient Following Hepatitis C genotype Mismatch Transplant. *Am J Transplant* 2004, 4:1375
- [63] Gane E, Pilmore H. Management of chronic viral hepatitis before and after renal transplantation. *Transplantation* 2002, 74:427

IntechOpen



Understanding the Complexities of Kidney Transplantation

Edited by Prof. Jorge Ortiz

ISBN 978-953-307-819-9

Hard cover, 564 pages

Publisher InTech

Published online 06, September, 2011

Published in print edition September, 2011

Kidney transplantation is a complex field that incorporates several different specialties to manage the transplant patient. This book was created because of the importance of kidney transplantation. This volume focuses on the complexities of the transplant patient. In particular, there is a focus on the comorbidities and special considerations for a transplant patient and how they affect kidney transplant outcomes. Contributors to this book are from all over the world and are experts in their individual fields. They were all individually approached to add a chapter to this book and with their efforts this book was formed. Understanding the Complexities of Kidney Transplantation gives the reader an excellent foundation to build upon to truly understand kidney transplantation.

How to reference

In order to correctly reference this scholarly work, feel free to copy and paste the following:

Jorge Ortiz, Jason Andre, Kamran Khanmoradi and Victor Araya (2011). Transplantation for the Complex Patient with Hepatitis C and End Stage Renal Disease: A Review, Understanding the Complexities of Kidney Transplantation, Prof. Jorge Ortiz (Ed.), ISBN: 978-953-307-819-9, InTech, Available from: <http://www.intechopen.com/books/understanding-the-complexities-of-kidney-transplantation/transplantation-for-the-complex-patient-with-hepatitis-c-and-end-stage-renal-disease-a-review>

INTECH
open science | open minds

InTech Europe

University Campus STeP Ri
Slavka Krautzeka 83/A
51000 Rijeka, Croatia
Phone: +385 (51) 770 447
Fax: +385 (51) 686 166
www.intechopen.com

InTech China

Unit 405, Office Block, Hotel Equatorial Shanghai
No.65, Yan An Road (West), Shanghai, 200040, China
中国上海市延安西路65号上海国际贵都大饭店办公楼405单元
Phone: +86-21-62489820
Fax: +86-21-62489821

© 2011 The Author(s). Licensee IntechOpen. This chapter is distributed under the terms of the [Creative Commons Attribution-NonCommercial-ShareAlike-3.0 License](#), which permits use, distribution and reproduction for non-commercial purposes, provided the original is properly cited and derivative works building on this content are distributed under the same license.

IntechOpen

IntechOpen