

# We are IntechOpen, the world's leading publisher of Open Access books Built by scientists, for scientists

**4,800**

Open access books available

**122,000**

International authors and editors

**135M**

Downloads

Our authors are among the

**154**

Countries delivered to

**TOP 1%**

most cited scientists

**12.2%**

Contributors from top 500 universities



**WEB OF SCIENCE™**

Selection of our books indexed in the Book Citation Index  
in Web of Science™ Core Collection (BKCI)

Interested in publishing with us?  
Contact [book.department@intechopen.com](mailto:book.department@intechopen.com)

Numbers displayed above are based on latest data collected.

For more information visit [www.intechopen.com](http://www.intechopen.com)



# Efficacy of Autogenous Dermis Graft for Wound Coverage

Seung-Kyu Han

*Department of Plastic Surgery  
Korea University College of Medicine Seoul,  
Korea*

## 1. Introduction

Skin grafting is the easiest and the most reliable way to obtain proper wound coverage. However, the two major concerns of skin grafting are the poor color match in the recipient sites and donor site morbidity including pain, discomfort, and hypertrophic scarring. Major pigment mismatches are common in split-thickness grafts particularly in darker skinned patients including Asians (Fig. 1). Several factors may play a role in the color mismatch of a regular skin graft. These include the amount of melanin, the degree of transfer of melanosomes to keratinocytes, and the number of melanocytes (Carlson et al., 2002; Velangi & Rees, 2001). Because the melanocytes are localized to the basal cell layer of the epidermis, the origin of the color mismatch has been assumed to be in the epidermal melanin (Tyack et al., 1997; Swope et al., 2002). Because regular skin grafts transferred to new locations maintain their epidermal specificity, a pigmentation difference with the surrounding skin is unavoidable.

To minimize the limitations of the classic skin graft, the author has developed a dermis graft, which is a deepithelialized split thickness skin graft, and have reported promising results of the method for coverage of small to medium sized wounds on the body (Han et al., 2007). The important aspects of this method involve the immediate return of the epidermis to the donor site in order to overcome the donor site morbidity and minimize the pigment mismatch between graft and surrounding skin by restoring the epidermal portion of the recipient site through inducing epithelization from the adjacent skin.

The purpose of this chapter is to present usefulness of the dermis graft in a wound coverage.

## 2. Surgical technique

After sharp debridement of the recipient site, skin and underlying subcutaneous tissue of the wound margin is undermined approximately 5mm in length along the periphery and meticulous hemostasis is obtained. The defect size of the recipient site measures. A thin epidermal flap is elevated on the gluteal area or the lateral thigh using a Zimmer dermatome, in which the thickness is set to 0.010 inches. The blade is then reset to 0.012 to 0.020 inches and the dermis to be grafted is cut from the same area. The previously elevated epidermal flap is replaced on the donor site and sutured with prolene. The harvested dermis is tailored to the size and shape of the defect including the undermined area and transferred

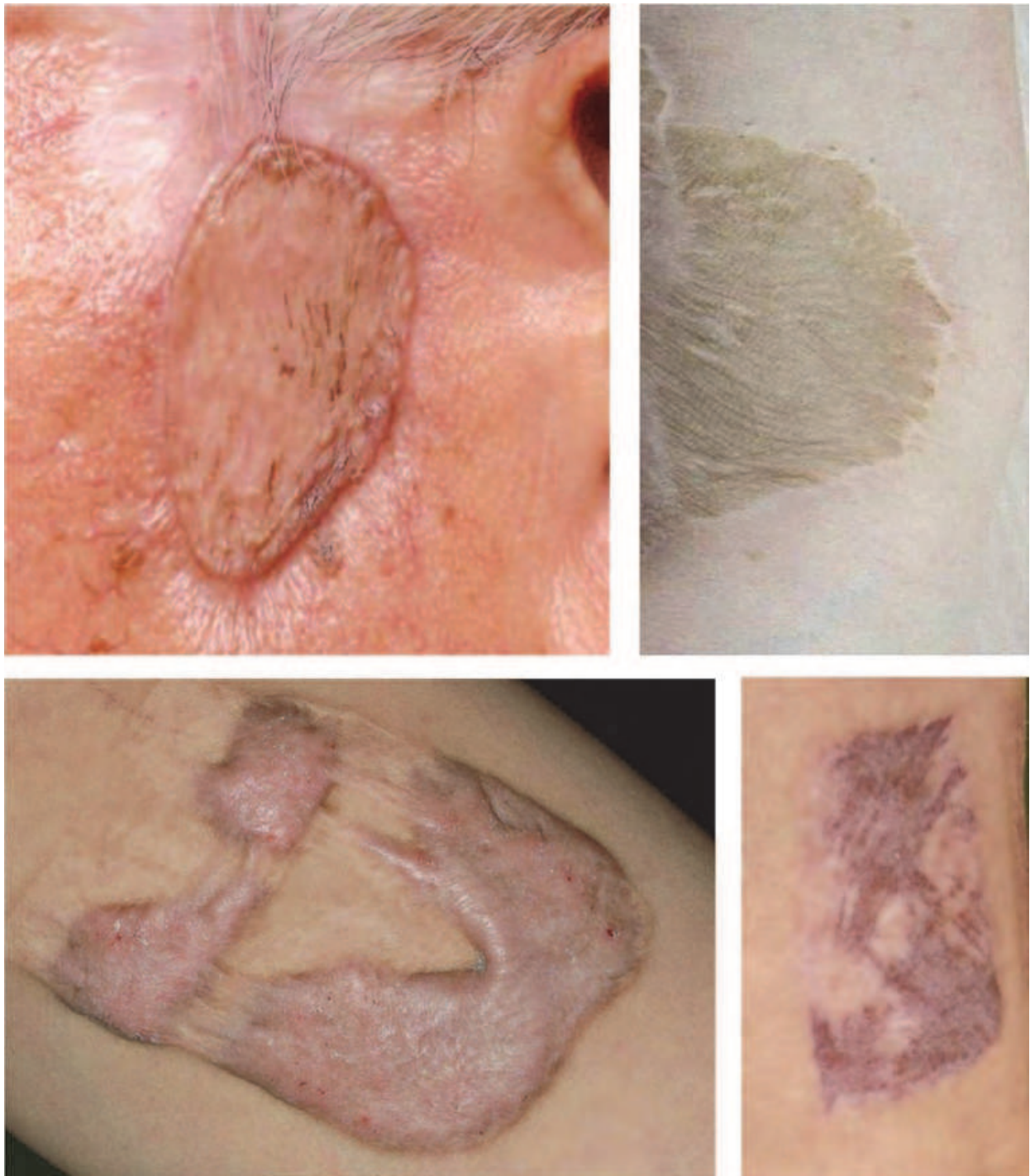

Fig. 1. Two major concerns of skin grafting. (*Above*) Poor color match in the recipient sites. (*Below*) Hypertrophic scar formation on the donor sites.

to the recipient site. The edge of the dermis graft is inserted into the undermined wound margin and fixed to the wound bed along the circumference of the defect using PDS sutures. The undermined marginal skin over the grafted dermis is then fixed to the underlying dermis using prolene sutures (Fig. 2). The skin sutures are removed after approximately 5 - 7 days in order to reduce the stitch marks. Sunshine is avoided for the first three to six months using sun-blocking agents.

### 3. Indication

The dermis graft is indicated in any cases with small to medium sized skin defect (smaller than 42.0 cm<sup>2</sup> based on the author's experience). Especially, a dermis graft is likely to have its greatest reconstructive role on the exposed areas such as the face, neck, forearms, and hands. In fairly large wounds (larger than 42.0 cm<sup>2</sup> based on the author's experience), the return of the patients to their normal daily activities is likely to be delayed because the epithelization of the graft takes a longer time. There is no data on the critical size or thickness of the dermis that can produce scar-free wound healing. Therefore, further study will be needed.

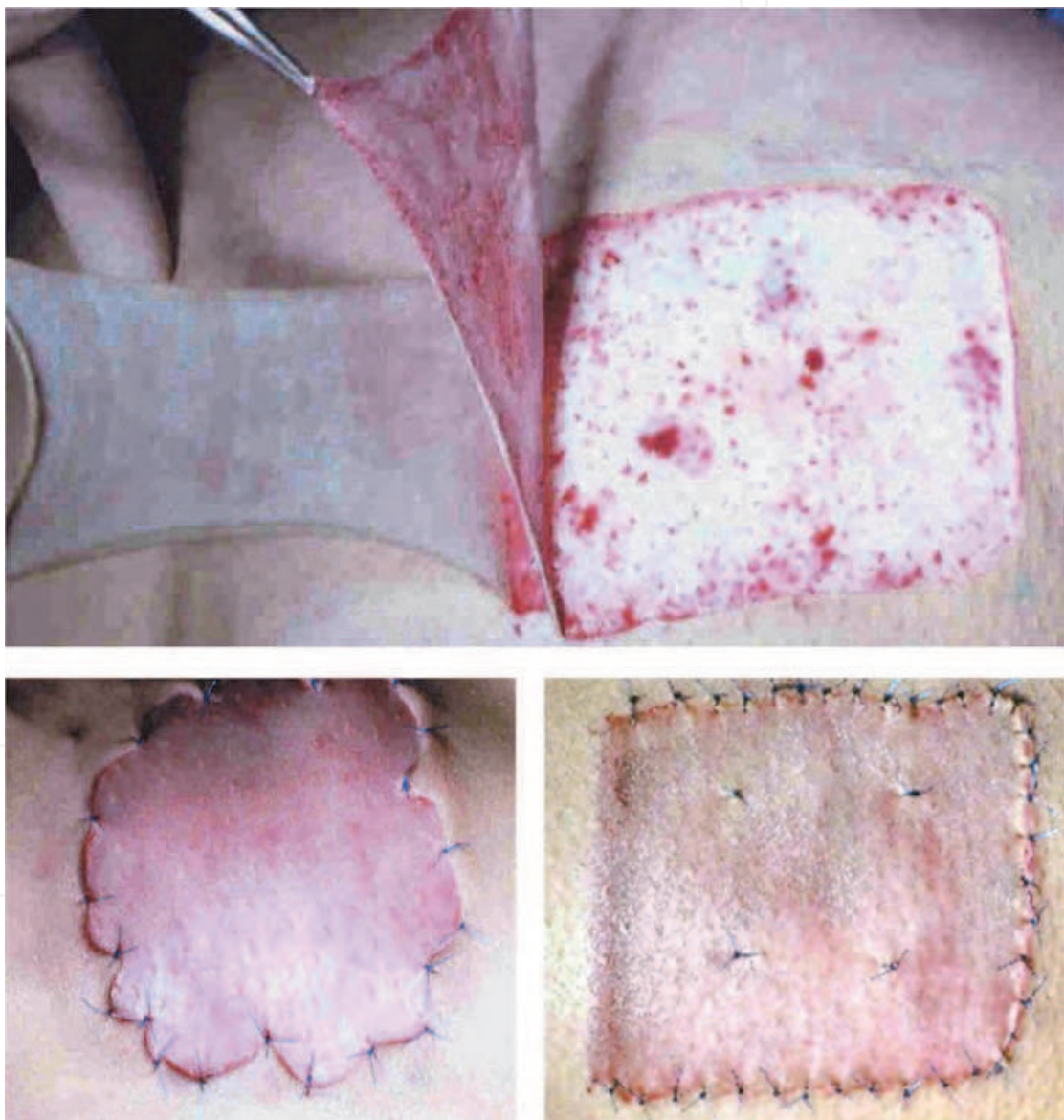


Fig. 2. (*Above*) The thin epidermal flap is elevated on the gluteal area, the dermis to be grafted is then cut on the same area. (*Below, left*) The edge of the dermis graft is inserted into the undermined wound margin and fixed to the wound bed along the circumference of the defect. (*Below, right*) The previously elevated epidermal flap is replaced on the donor site.

It was found that a full thickness small sized wound, which was left to heal by secondary intention, sometimes resulted in acceptable scarring in a concave area of the skin. In some wounds, however, a period of several weeks or months is required for complete healing, particularly in actinically damaged, fragile skin. Wounds on convex areas of the skin heal rather poorly (depressed scar) via secondary intention. The resultant wound contraction, which is an important clinical component, is not an uncommon problem (Fig. 3). Skin or dermal substitutes, which are currently produced by advanced technology, may replace the regular skin graft (Kuroyanagi et al., 2001; Terino et al., 2001). However, these procedures usually heal with a significantly conspicuous and unfavorable scar (Figs. 4 and 5). Further improvements are required in such technology to obtain a favorably aesthetic result as obtained with the dermis graft method.

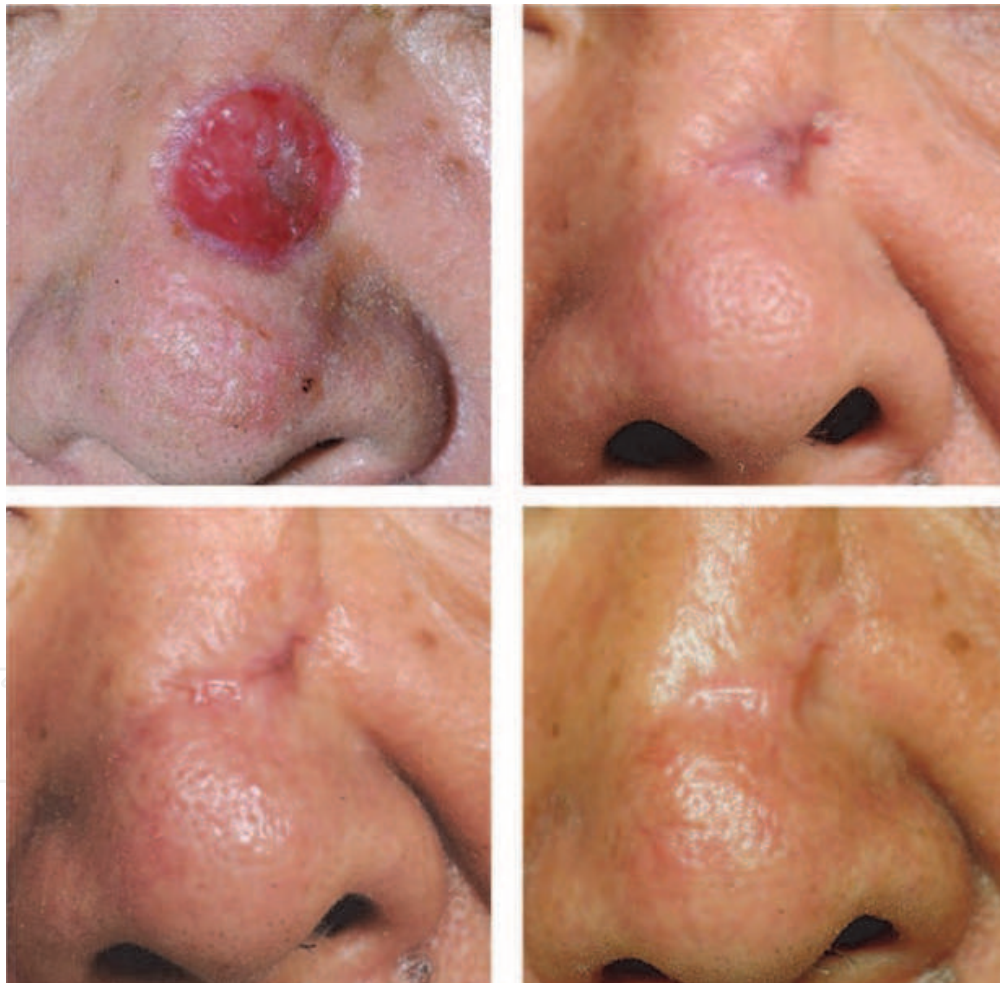


Fig. 3. An open wound on nasal dorsum, which was left to heal by secondary intention, resulted in a conspicuous wound contraction.

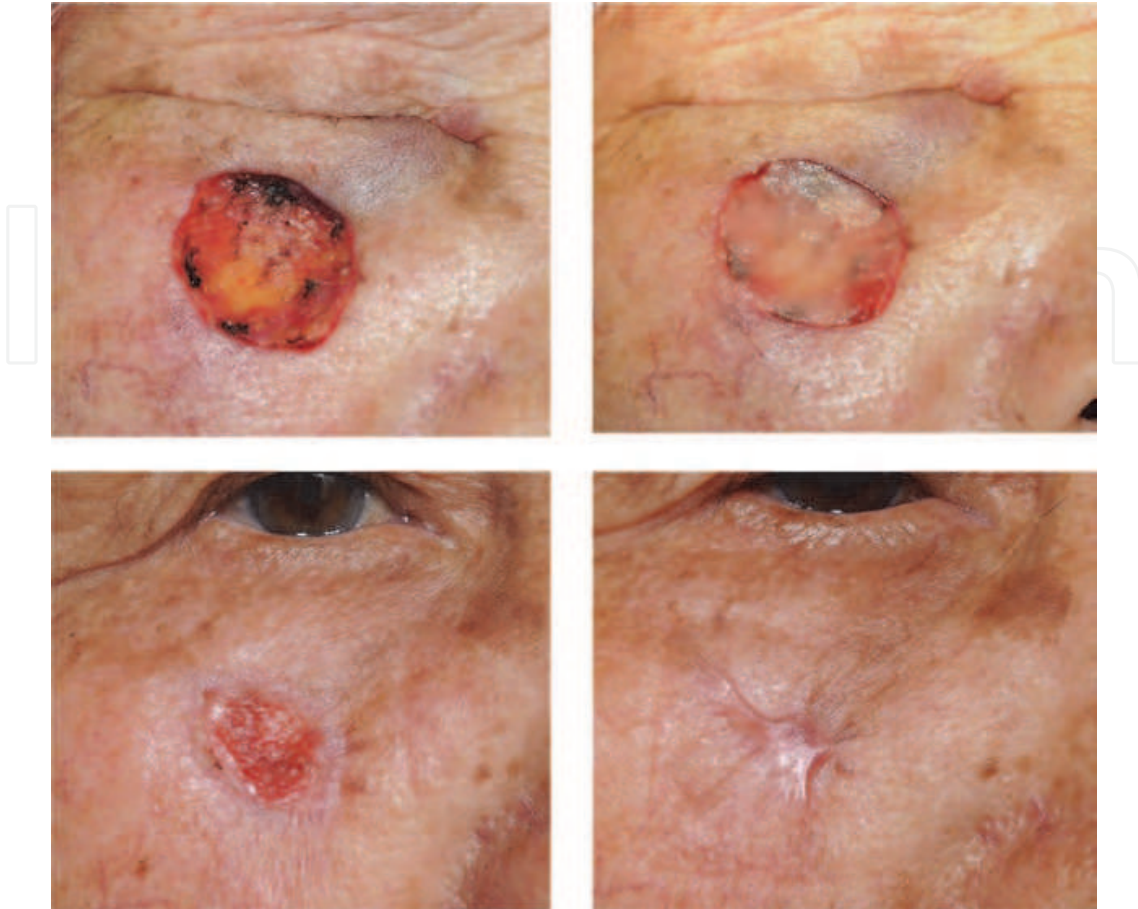


Fig. 4. A full thickness skin defect on a lower eyelid healed by grafting of an artificial dermis. The resultant scar was prominent with contraction.

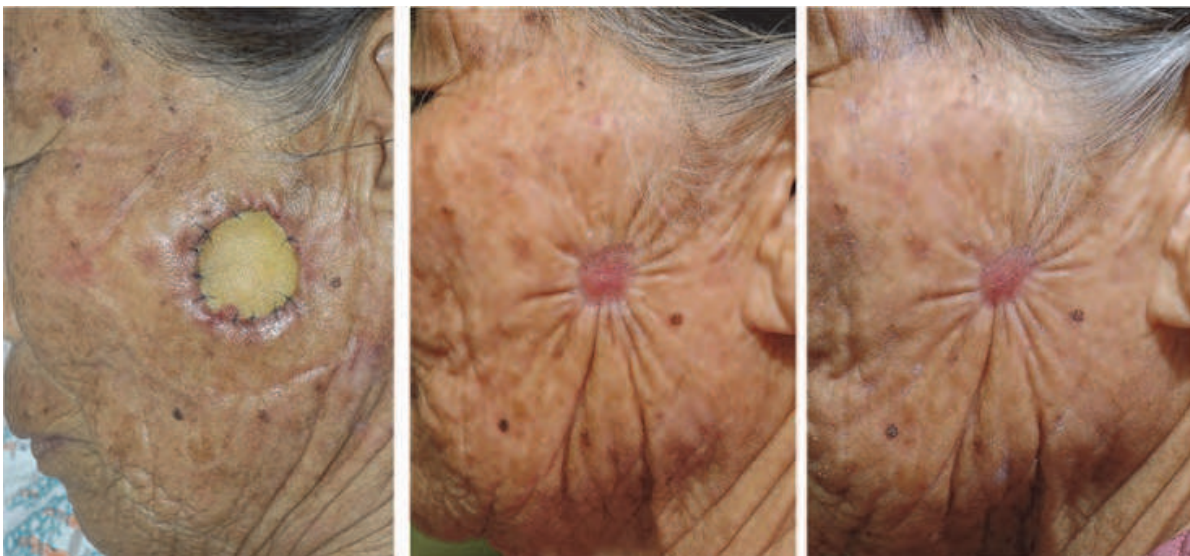


Fig. 5. A wound on cheek healed by grafting of an allogenic dermis. The resultant scar was unfavorable.

## 4. Author's experience

### 4.1 Clinical research

The author has evaluated the efficacy of the dermis graft used for wound coverage by comparing it with that of a regular skin graft (Han et al., 2007). The patients included in the study provided informed written consent for the study, but has not been registered in an official database of the institutional review board.

#### 4.1.1 Patients and methods

From April of 2001 to March of 2004, the dermis graft was applied to 53 patients (17 male, 36 female), ranging in age from 6 to 61 years (average, 36.5 years). The size of the wound ranged from 2.7 to 42.0 cm<sup>2</sup>, with a mean and a median size of 12.0 and 10.5 cm<sup>2</sup>, respectively. The recipient sites were located as follows: 8 on the face, 6 on the forearm, 34 on the hand, 4 on the lower extremities, and 1 on the back. Simultaneously, a regular split thickness skin graft procedure was performed on the wounds of approximately the same size and location as the dermis graft in 33 patients. The size of the regular skin graft wound ranged from 2.3 to 42.0 cm<sup>2</sup>, with a mean and a median size of 14.0 and 12.0 cm<sup>2</sup>, respectively. The locations of the wound were as follows: 3 on the face, 6 on the forearm, 21 on the hand, and 3 on the lower extremities. This provided an opportunity to compare the results of the dermis graft with those of the regular skin graft. Prior to classifying the patients into the two treatment groups, detailed information of the new procedure (dermis graft), which included the surgical techniques, advantages, and disadvantages, was provided to each patient. The patients were classified according to their compliance. Compliant patients who fully understood and agreed to the new procedure underwent a dermis graft and noncompliant patients who did not want the new procedure underwent a regular skin graft.

The healing time for both groups was compared. The mean follow-up time was 12.4 months ranging from 3 months to 2 years. Twenty-six dermis graft patients and 20 regular skin graft patients had more than a 12-month follow-up period. The scar condition was evaluated in these long-term follow-up patients by two blind observers (plastic surgery residents in training at the author's institution) after a 12 to 24 month follow-up (average, 15.7 months for the dermis graft group and 15.0 months for the regular skin graft group) according to the Vancouver Scar Scale (VSS), which included pigmentation, scar height, pliability, and vascularity (Vloemans et al., 2003; Sullival et al., 1990). The averaged scores of the two observers were used as data for the analysis.

The patients' satisfaction for the donor and recipient site was also surveyed in the long-term follow-up patients. The patients' satisfaction was compared using a Visual Analogue Scale (VAS) with a score of 0 being the worst and 5 being the best. Statistical comparisons for the data of the VSS and the VAS were performed using a Mann-Whitney U-test. *P* values < 0.05 were considered significant.

#### 4.1.2 Results

The graft take was complete in all patients in both groups. Refilling of the blood vessels and multiple pin point bleeding was observed on the grafted dermis within the first 2 to 3 days. Reepithelization occurred progressively from the periphery to the center of the grafted dermis.

The whole wound of the dermis graft had reepithelialized after grafting within 11 to 20 days (average  $15.5 \pm 1.9$  days). The skin grafted wounds had healed by 7 to 16 days (average  $11.8 \pm 1.6$  days). In the long-term follow-up, good quality skin characteristics were achieved in the dermis graft.

A comparison of the scars at the recipient site, as assessed by the VSS, showed that the dermis graft was superior to the regular skin graft in terms of pigmentation, height, and vascularity ( $p < 0.05$ ). No significant difference in pliability was detected. The overall average VSS scores of the dermis and skin graft were  $1.0 \pm 1.1$  and  $1.6 \pm 1.1$ , respectively ( $p < 0.05$ ). The patients' satisfaction in the dermis graft group, as assessed by the VAS, was also better than that in skin graft group ( $4.2 \pm 0.9$  and  $3.4 \pm 1.1$  each).

Regarding the donor sites, the results of the dermis graft were also satisfactory. All the donor sites of dermis graft healed within 9 days (average  $7.5 \pm 0.8$  days). In contrast, those of the regular skin graft required 11 to 16 days to heal (average  $12.8 \pm 1.1$  days). The donor sites of the dermis graft were also superior to those of the skin graft in terms of scar quality and patient satisfaction. The average of overall VSS scores for the donor sites of the dermis graft and regular skin graft were  $0.7 \pm 0.9$  and  $1.3 \pm 0.7$  each ( $p < 0.05$ ). The average VAS scores for the dermis and skin graft donors were  $4.1 \pm 1.3$  and  $2.8 \pm 0.8$  each ( $p < 0.05$ ). There were no significant complications and no functionally relevant scar in either group (Fig. 6).

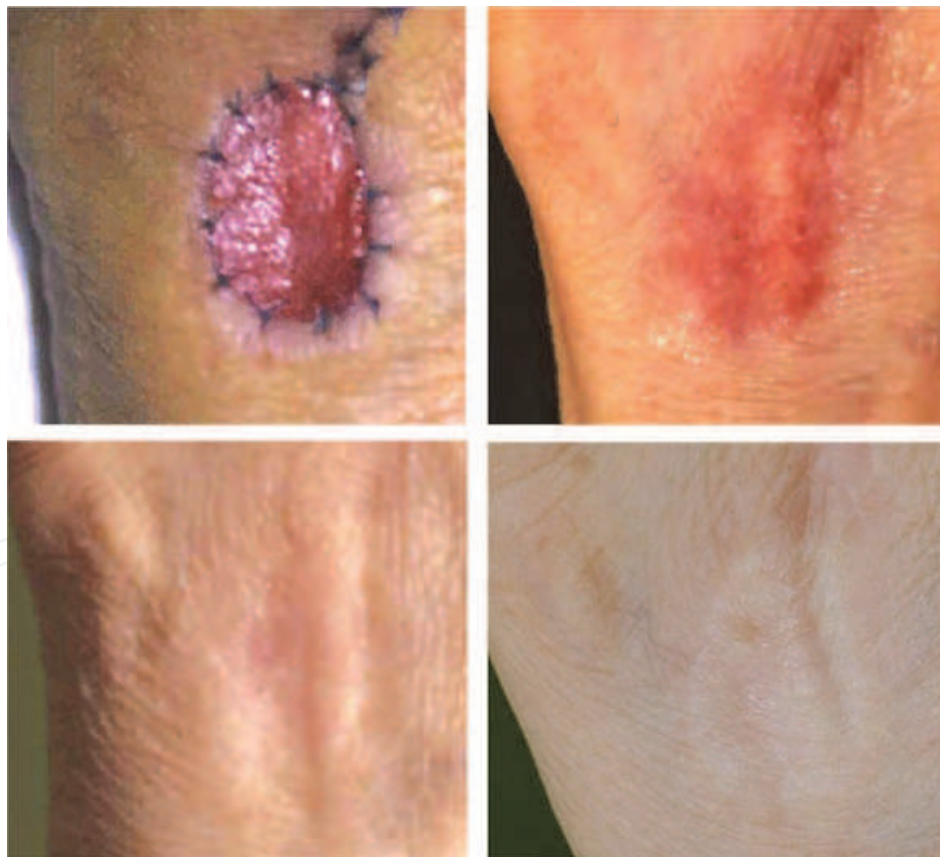


Fig. 6. A woman received a venous island flap coverage to reconstruct an amputated finger tip. (Above, left) The donor site was covered by a dermis graft harvested from her buttock. (Above, right) Two-month postoperative view. (Below, left) Eight-month postoperative view. (Below, right) Fourteen-month postoperative view, which demonstrated excellent color match with the adjacent skin.



## 4.2 Dermis graft on face after removal of skin cancer

The author has evaluated the reliability of the dermis graft for covering defects after removal of non-melanoma skin cancer on the face. Surgical excision of skin cancer leaves a soft tissue defect which requires reconstruction. Proper selection of reconstruction method is the key point to get a successful result on the face. In planning reconstruction for facial defects, reconstructive efforts should start from the safest and least invasive methods while achieving optimal functional and cosmetic outcomes. A variety of methods can be used to cover the defects; healing by secondary intention, a primary closure, a skin graft, and a local flap. Healing by secondary intention usually leaves a significantly conspicuous and unfavorable scar. Darker skin is more prone to hypertrophic scarring or keloids. The role of primary closure for reconstruction after complete eradication of skin cancer on the face is very limited because of defect size and shape. Only small defects with elliptical shapes yield satisfactory results after primary closure. A local flap may provide several advantages, including decreased scar contracture and satisfactory contour, color, and texture match. In some cases, however, a local flap is not feasible, mainly due to the limitation of size and arc of rotation, particularly in young patients. Poor flap design and inappropriate incisions may contribute to unacceptable scars, violation of aesthetic subunits, and resultant disfigurement on difficult-to-treat areas. In addition, compromise of flap vascularity and inadequate wound closure created by insufficient undermining, lack of deep closure, excessive tension, or inadequate approximation of wound edges predispose to unfavorable results.

### 4.2.1 Patients and methods

Thirty-eight patients (20 male, 18 female) were treated for the facial defects created by the resection of the non-melanoma skin cancer on the face from January 2006 and December 2008. The patients had more than 12-months of follow-up and the clinical records of all patients were reviewed. The patients' age ranged from 57 to 83 years (average,  $68.7 \pm 6.3$  years). The defect size ranged from 3.3 to 6.5 cm<sup>2</sup> with a mean of  $5.1 \pm 0.9$  cm<sup>2</sup>. The location of the defect was as follows: 17 cases on the nose, 14 in the orbital area, 4 on the cheek, 2 on the temple area, and 1 on the forehead.

Functional and cosmetic outcomes, focusing on scar contracture, pain, itching, scar height, color, texture, and postoperative complications were assessed. The patients' satisfaction was also evaluated by using a VAS with a score of 0 being the worst and 10 being the best. The patients were followed up for 12 to 36 months (mean,  $20.5 \pm 6.2$  months).

### 4.2.2 Results

The graft was well taken by all patients. Reepithelization occurred progressively from the periphery to the center of the grafted dermis. The entire dermis graft reepithelialized after grafting within 17 to 27 days (mean,  $25.1 \pm 2.4$  days).

All patients had satisfactory results in both functional and cosmetic matters with high quality skin characteristics. No significant scar contracture was observed and none of the patients complained of pain or itching. In the scar height, 20 scars were flat and 18 scars were slightly depressed. Neither hypertrophic nor keloid scar was observed. In the color parameter, most of the scars (30 scars) showed favorable color match to the surrounding skin (Figs. 7 and 8) and 8 scars were hypopigmented (Fig. 9). Hyperpigmentation or redness was not observed. In terms of the skin texture, favorable smooth texture was obtained in 25 cases and shiny texture in 13 cases. Obviously conspicuous scar was not identified in all

cases and no revision procedure was needed to improve scar quality. There were no significant complications and no recurrences were observed during the follow-up. The patients' satisfaction with the dermis graft was also excellent (mean score  $8.3 \pm 1.3$ ).

Regarding the donor sites, the results of the dermis graft were also satisfactory. All the donor sites of dermis graft healed within 9 days (average  $7.2 \pm 1.1$  days). There were no significant complications and no functionally relevant scar (Fig. 10).

### 5. Advantages and disadvantages

The primary advantage of this method is to provide a graft that is similar to the surrounding skin, leaving minimal scars and color mismatch. Since the epidermal portion can be restored by epithelization, induced by the migration and proliferation of adjacent epidermal cells including melanocytes, the density and activity of the melanocytes as well as the precursor melanocytes of the epidermis of the graft become similar to those observed in the adjacent skin.

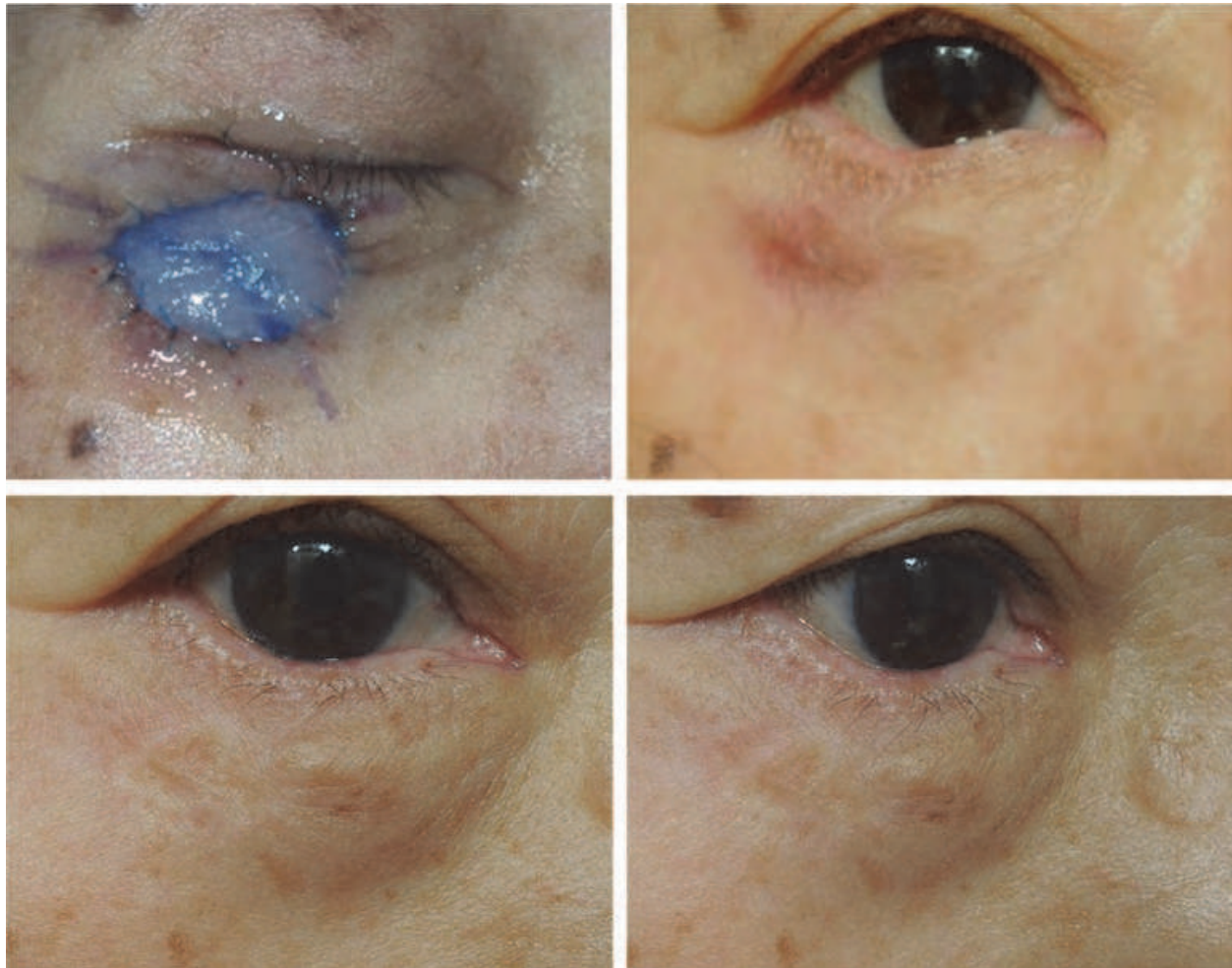


Fig. 7. A skin defect created by removal of basal cell carcinoma treated with the dermis graft. (Above, left) Immediate postoperative view. (Above, right) One-month postoperative view. (Below) Two-year postoperative view, which showed excellent results with minimal scar contraction.

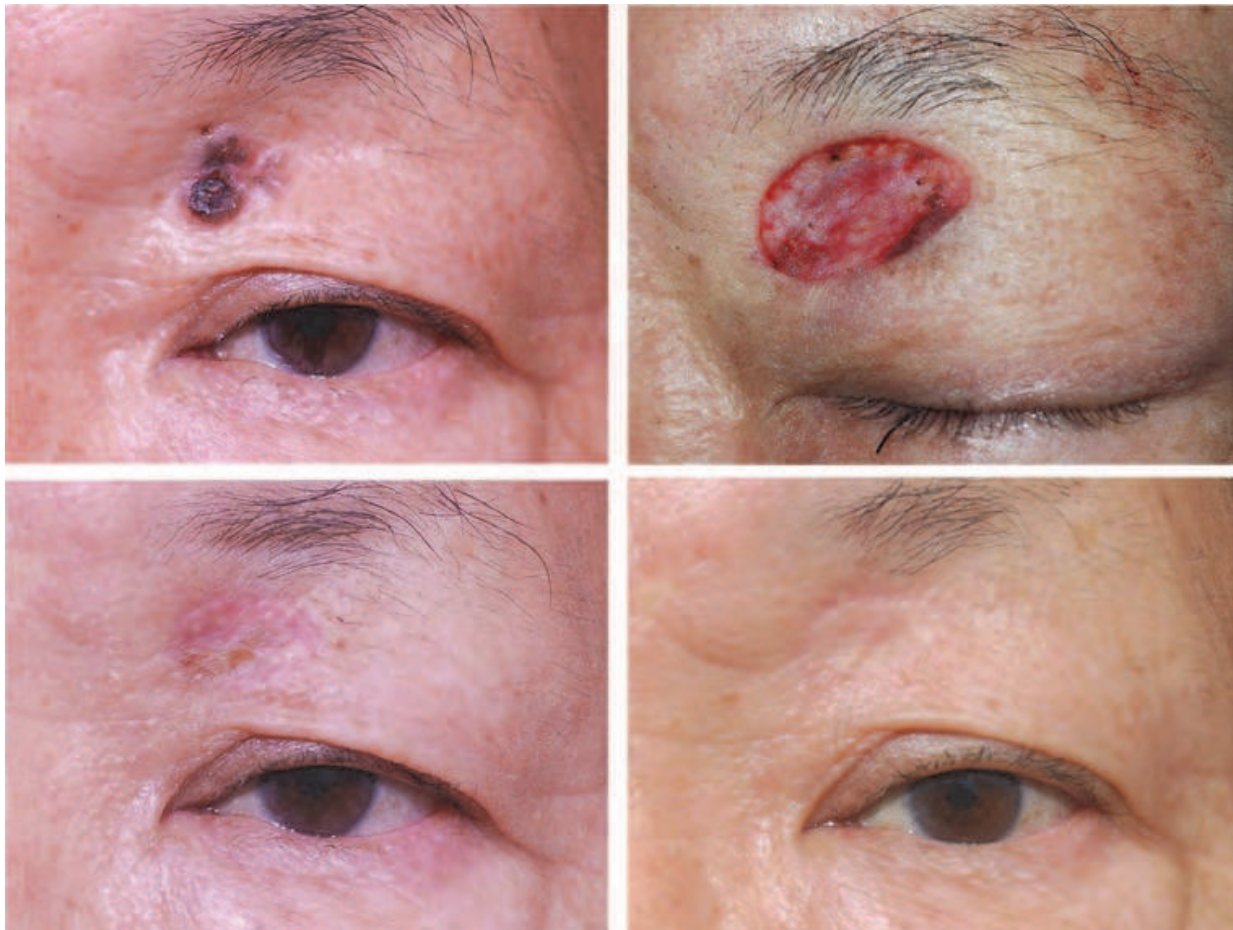


Fig. 8. A skin defect seen on a lower eyelid created by removal of basal cell carcinoma treated with the dermis graft. (Above, left) Preoperative view. (Above, right) After removal of the lesion. (Below, left) One-month postoperative view. (Below, right) One-year postoperative view. The resultant scar was acceptable.

Regarding wound contraction of the recipient site after dermis grafting, the contraction of myofibroblasts can be inhibited by grafting with a more dermal portion than a regular skin graft. In previous studies, the inhibition of scar contraction was attributed to the amount of dermal collagen rather than to the amount of epidermis (Chou et al., 2001; Rudolph, 1979; Brown et al., 1990). Another advantage of the dermis graft is the quick healing of the donor site without an obvious scar appearance because the epidermis can be replaced immediately to ensure the closure of the donor bed. Hypertrophic scarring is rare, and the level of pigmentation is less than that of the donor site in a regular skin graft. The patient has less donor site pain and discomfort, which is a very important component from the patient's point of view. Care of the donor site is also very simple. Dermis grafts are feasible for all wounds that are candidates for regular skin grafts including acute facial burns or post facial cancer excisions.

The only possible demerit with dermis grafting is the delay in complete healing of the recipient site. As previously described, there was a 3.7 day delay in graft healing of the recipient site (15.5 and 11.8 days in the dermis graft and the regular skin graft groups, respectively). However, it is believed that the 3.7 day delay would not cause significant trouble, and what ever problems there are can be overcome by selecting suitable sized wounds.

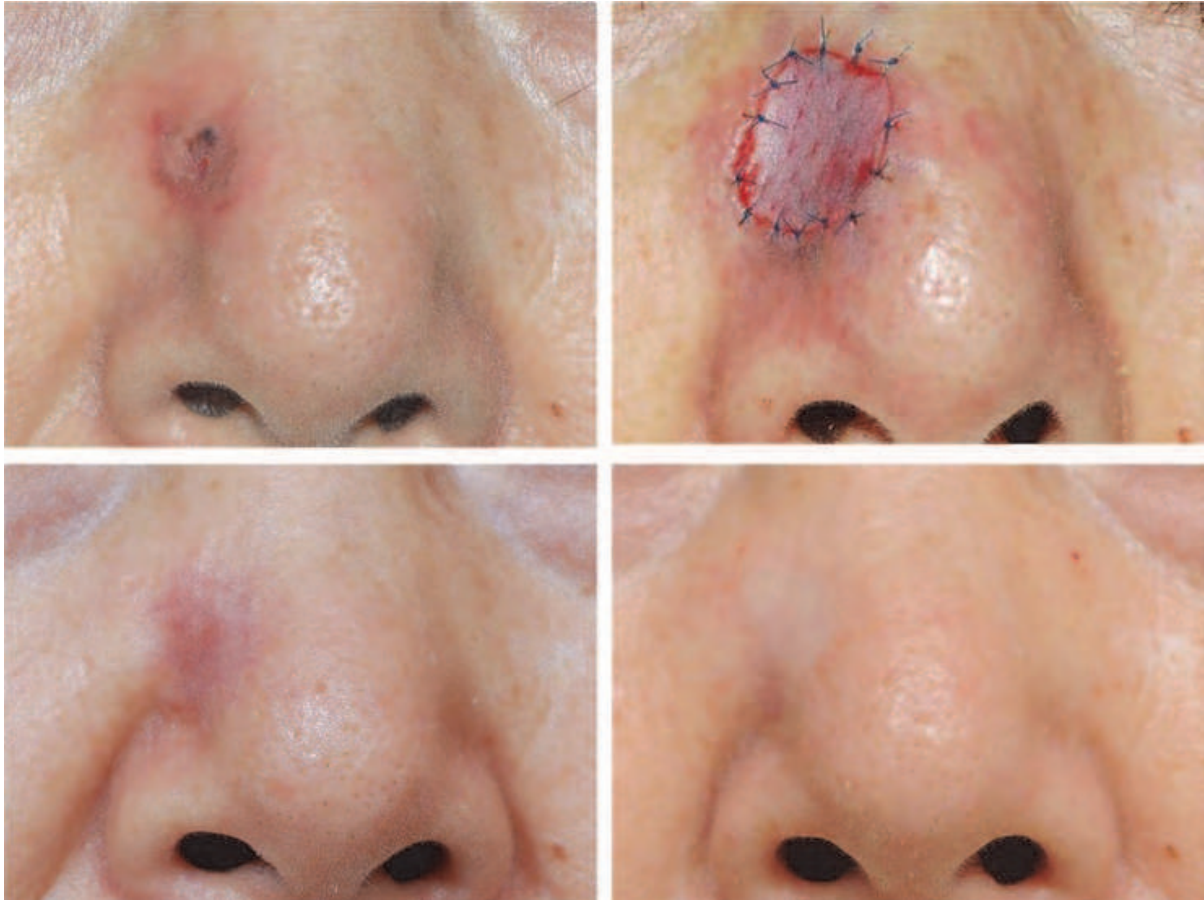


Fig. 9. A skin defect on a nose created by removal of basal cell carcinoma treated with the dermis graft. (*Above, left*) Preoperative view. (*Above, right*) Immediate postoperative view. (*Below, left*) One-month postoperative view. (*Below, right*) One-year postoperative view. Hypopigmentation of the grafted site was noted in this case.

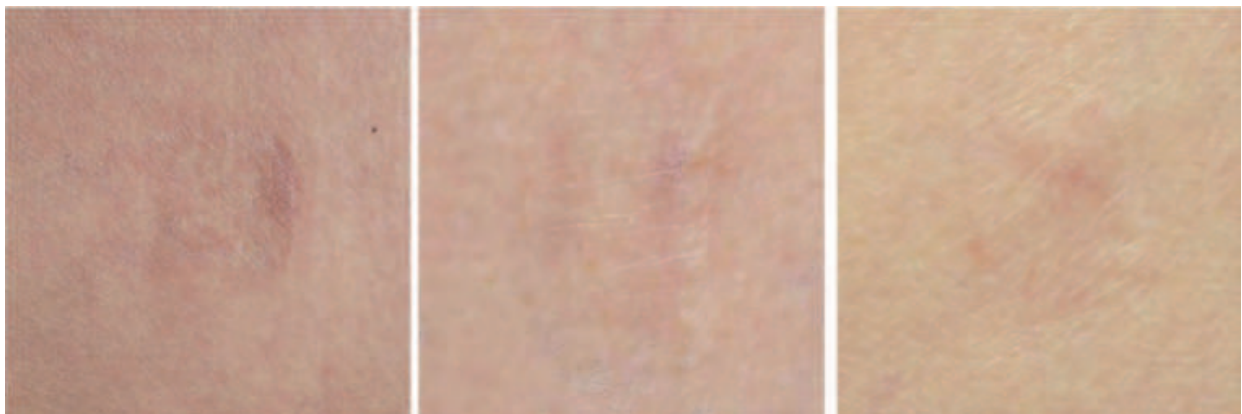

Fig. 10. Healed donor sites of the dermis grafts demonstrate acceptable cosmetic results.

## 6. Conclusion

The dermis graft technique for wound coverage is superior to a regular skin graft technique in terms of the aesthetic results of both the recipient and donor sites. The donor site healing

process is faster, and the patient's pain and discomfort can also be reduced significantly. The dermis graft can be used reliably for covering small to medium sized wounds on exposed areas and may be considered as the first choice.

## 7. References

- Brown D, Garner W, Young L. Skin grafting: Dermal components in inhibition of wound contraction. *South Med J*. 1990;83:789-793.
- Carlson JA., Grabowski R., Mu XC., Del Rosario A. Possible mechanisms of hypopigmentation in lichen sclerosus. *Am J Dermatopathol*. 2002;24:97-101
- Chou TD., Chen SL., Lee TW., Chen SG. Reconstruction of burn scar of the upper extremities with artificial skin. *Plast Reconstr Surg*. 2001;108:378-384.
- Han SK, Yoon TH, Kim JB, Kim WK. Dermis graft for wound coverage. *Plast Reconstr Surg*. 2007 ;120:166-172.
- Kuroyanagi Y, Yamada N, Yamashita R, Uchinuma E. Tissue-engineered product: allogenic cultured dermal substitute composed of spongy collagen with fibroblasts. *Artificial Organs*. 2001;25:180-186.
- Rudolph R. Inhibition of myofibroblasts by skin grafts. *Plast Reconstr Surg*. 1979;63:473-478.
- Sullival, T., Smith, J., Kermod, J., McIver, E., and Courtermanche, D. J. Rating the burn scar. *J Burn Care Rehabil*. 1990;11:256-261.
- Swope VB., Supp AP., Boyce ST. Regulation of cutaneous pigmentation by titration of human melanocytes in cultured skin substitutes grafted to athymic mice. *Wound Repair Regen*. 2002;10:378-385.
- Terino EO. AlloDerm acellular dermal graft: applications in aesthetic soft tissue augmentation. *Clin Plast Surg*. 2001;28:83-90.
- Tyack ZF., Pegg S., Ziviani J. Postburn dyspigmentation : Its assessment, management, and relationship to scarring. *J Burn Care Rehabil*. 1997;18:435-440.
- Velangi SS., Rees JL. Why are scars pale? An immunohistochemical study indicating preservation of melanocyte number and function in surgical scars. *Acta Derm Venereol*. 2001;81:326-332.
- Vloemans AF., Soesman AM., Suijker M., Kreis RW. Arandomised clinical trial comparing a hydrocolloid-derived dressing and glycerol preserved allograft skin in the management of partial thickness burns. *Burns*. 2003;29-34.



## **Skin Grafts - Indications, Applications and Current Research**

Edited by Dr. Marcia Spear

ISBN 978-953-307-509-9

Hard cover, 368 pages

**Publisher** InTech

**Published online** 29, August, 2011

**Published in print edition** August, 2011

The procedure of skin grafting has been performed since 3000BC and with the aid of modern technology has evolved through the years. While the development of new techniques and devices has significantly improved the functional as well as the aesthetic results from skin grafting, the fundamentals of skin grafting have remained the same, a healthy vascular granulating wound bed free of infection. Adherence to the recipient bed is the most important factor in skin graft survival and research continues introducing new techniques that promote this process. Biological and synthetic skin substitutes have also provided better treatment options as well as HLA tissue typing and the use of growth factors. Even today, skin grafts remain the most common and least invasive procedure for the closure of soft tissue defects but the quest for perfection continues.

### **How to reference**

In order to correctly reference this scholarly work, feel free to copy and paste the following:

Seung-Kyu Han (2011). Efficacy of Autogenous Dermis Graft for Wound Coverage, Skin Grafts - Indications, Applications and Current Research, Dr. Marcia Spear (Ed.), ISBN: 978-953-307-509-9, InTech, Available from: <http://www.intechopen.com/books/skin-grafts-indications-applications-and-current-research/efficacy-of-autogenous-dermis-graft-for-wound-coverage>

**INTECH**  
open science | open minds

### **InTech Europe**

University Campus STeP Ri  
Slavka Krautzeka 83/A  
51000 Rijeka, Croatia  
Phone: +385 (51) 770 447  
Fax: +385 (51) 686 166  
[www.intechopen.com](http://www.intechopen.com)

### **InTech China**

Unit 405, Office Block, Hotel Equatorial Shanghai  
No.65, Yan An Road (West), Shanghai, 200040, China  
中国上海市延安西路65号上海国际贵都大饭店办公楼405单元  
Phone: +86-21-62489820  
Fax: +86-21-62489821

© 2011 The Author(s). Licensee IntechOpen. This chapter is distributed under the terms of the [Creative Commons Attribution-NonCommercial-ShareAlike-3.0 License](#), which permits use, distribution and reproduction for non-commercial purposes, provided the original is properly cited and derivative works building on this content are distributed under the same license.

IntechOpen

IntechOpen