

# We are IntechOpen, the world's leading publisher of Open Access books Built by scientists, for scientists

**4,800**

Open access books available

**122,000**

International authors and editors

**135M**

Downloads

Our authors are among the

**154**

Countries delivered to

**TOP 1%**

most cited scientists

**12.2%**

Contributors from top 500 universities



**WEB OF SCIENCE™**

Selection of our books indexed in the Book Citation Index  
in Web of Science™ Core Collection (BKCI)

Interested in publishing with us?  
Contact [book.department@intechopen.com](mailto:book.department@intechopen.com)

Numbers displayed above are based on latest data collected.

For more information visit [www.intechopen.com](http://www.intechopen.com)



## Clinical Evaluation of Glyaderm, a Dermal Substitute Based on Glycerinized Donor Skin

Pirayesh A., Richters CD, Hoeksema H,  
Verbelen J, Heyneman A and Monstrey S.

*Burn centre, University Hospital, Gent  
Euro Skin Bank, Beverwijk*

*Belgium  
The Netherlands*

### 1. Introduction

The main goal in burn management has always been increasing the survival of severely burned patients by rapid debridement and early closure of burn wounds, consequently reducing the risk of infection, sepsis and multi-organ failure. However, in the last decennia, surgical emphasis has shifted from survival to 'quality of survival', especially by improving the residual scars and preventing secondary contractures. Research and development of dermal skin substitutes has been directed towards improvement of scar quality by a bi-layered reconstruction of dermis and epidermis.

Allogeneic skin recovered from deceased donors is often used in the management of burns and other full thickness skin defects as a temporary coverage before definitive closure with autologous skin. Donor skin is used to improve the quality of the wound bed before grafting with autologous skin, as a biological dressing for partial thickness wounds (Hermans, 1989), or as overlay on widely expanded autograft (sandwich technique, Kreis et al., 1989). Excised full thickness defects treated with thin and widely expanded split thickness autografts often heal with an un-aesthetic, hypertrophic scar as final result as shown in figure 1.

In patients with extensive burns it is not possible to use thicker autografts with limited expansion because of increased donor site morbidity. These results may improve if a dermal substitute is placed underneath the split thickness skin graft. This substitute can replace the dermal tissue that is lost and provide a scaffold to the cells infiltrating in the wound bed during the healing process. The scaffold must be designed in such a way the cells will produce the new collagen fibers in a random organized structure, replacing slowly the scaffold material instead of making the typical parallel oriented fibers of scars (Van der Veen et al., 2010). In the past decades, several dermal substitutes products have become available but the clinical evidence on the effectiveness is limited until now (Brusselaers et al., 2010). These commercially available products are based on animal derived collagen or human skin and associated with high costs (Jones et al., 2002).

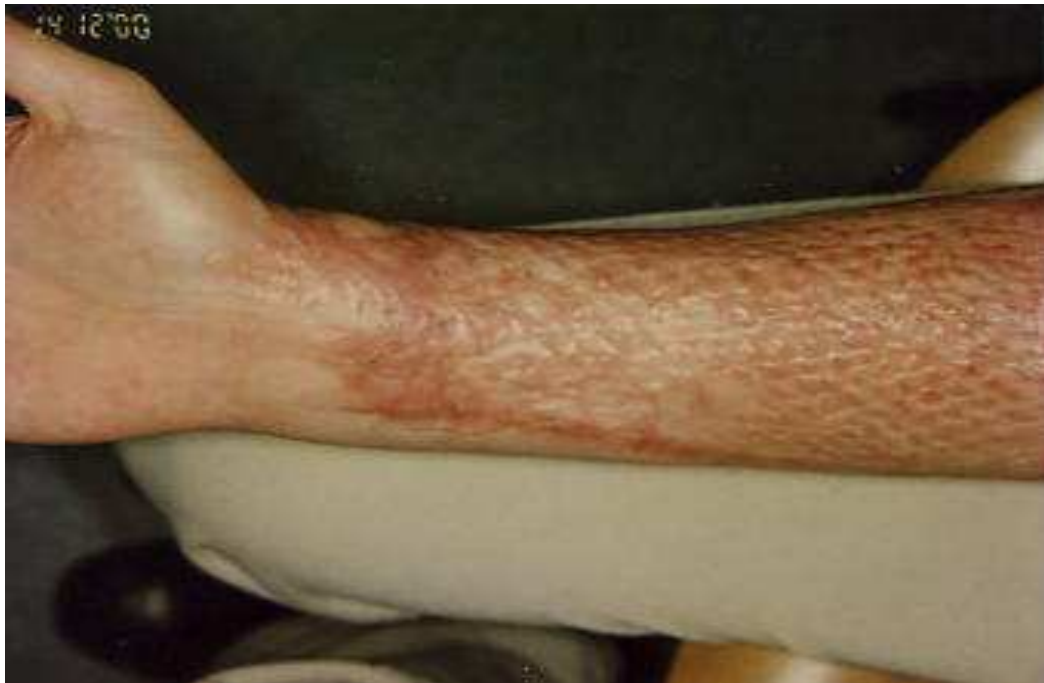

Fig. 1. Typical scar formation results after sandwich grafting, the mesh of the autologous skin graft pattern is still visible.

## 2. Development of dermal substitute

Dermal substitutes can be obtained from animal or human tissue as well as synthetic materials. The advantage of human skin is the presence of the natural collagen- elastin fibre network, providing the optimal three dimensional fibre structure for ingrowing fibroblast and blood vessels. Antigenic structures must be absent from the dermal substitute to avoid the induction of inflammatory processes that can worsen final scar quality. Human allogeneic skin has been applied to the wound as dermal substitute in the past as described by Cuono et al., 1987. In this method, the more immunogenic epidermis was removed several days after grafting the human donor skin and replaced by autogous cultured epithelial sheets. Technically, this method is difficult and in the allogeneic dermis cells of the donor remain present that can induce inflammation after wound closure. Therefore, several methods have been developed to remove the donor cells and hairs from the donor skin. This resulted in products known as Alloderm, Surederm, Graft jacket using enzymes and freeze drying techniques.

We have developed a cost-effective method to eliminate the antigenic structures by using low concentrations of sodium hydroxide (Richters et al. 2008). De-cellularization of glycerol 85% preserved skin starts by rinsing out the glycerol, thereafter the skin is incubated in 0.06M NaOH for 6 weeks. The NaOH solution is refreshed every week and finally neutralized. The acellular dermis is again preserved in glycerol 85%. This method avoids freezing which may damage the collagen and elastin fibers and, at the same time, it is very effective in washing out the donor cells and hairs. The prototypes, consisting of an intact, native collagen-elastin matrix obtained using the NaOH method were tested in a porcine model. Full thickness wounds of 4x4 cm were transplanted with the prototype and an autologous split skin graft meshed 1:3. Contraction of the wounds treated with this

prototype was significantly lower compared to the control wounds, transplanted with only autologous skin (Richters et al., 2008, Pirayesh et al., 2007 and 2008). The six weeks treatment with NaOH showed the best results. Further experiments showed a two stage procedure was more optimal with the take rate of the autologous skin > 90% if the interval between application of the prototype and the autologous skin was 7 days. Final result with respect to contraction was comparable to Integra in this porcine model but the scar was more smooth (Pirayesh et al., 2011, manuscript in preparation). This encouraging results let to the first pilot of clinical experiments on burn patients.

### 3. Clinical application of Glyaderm

This novel dermal substitute is called Glyaderm, which is an abbreviation for Glycerol-preserved Acellular Dermis. Before application of Glyaderm, the wound bed must show viable granulation tissue. In most cases, woundbed preparation with allogeneic donor skin is needed; in burns this takes about 7 days after debridement. Glyaderm is preserved in

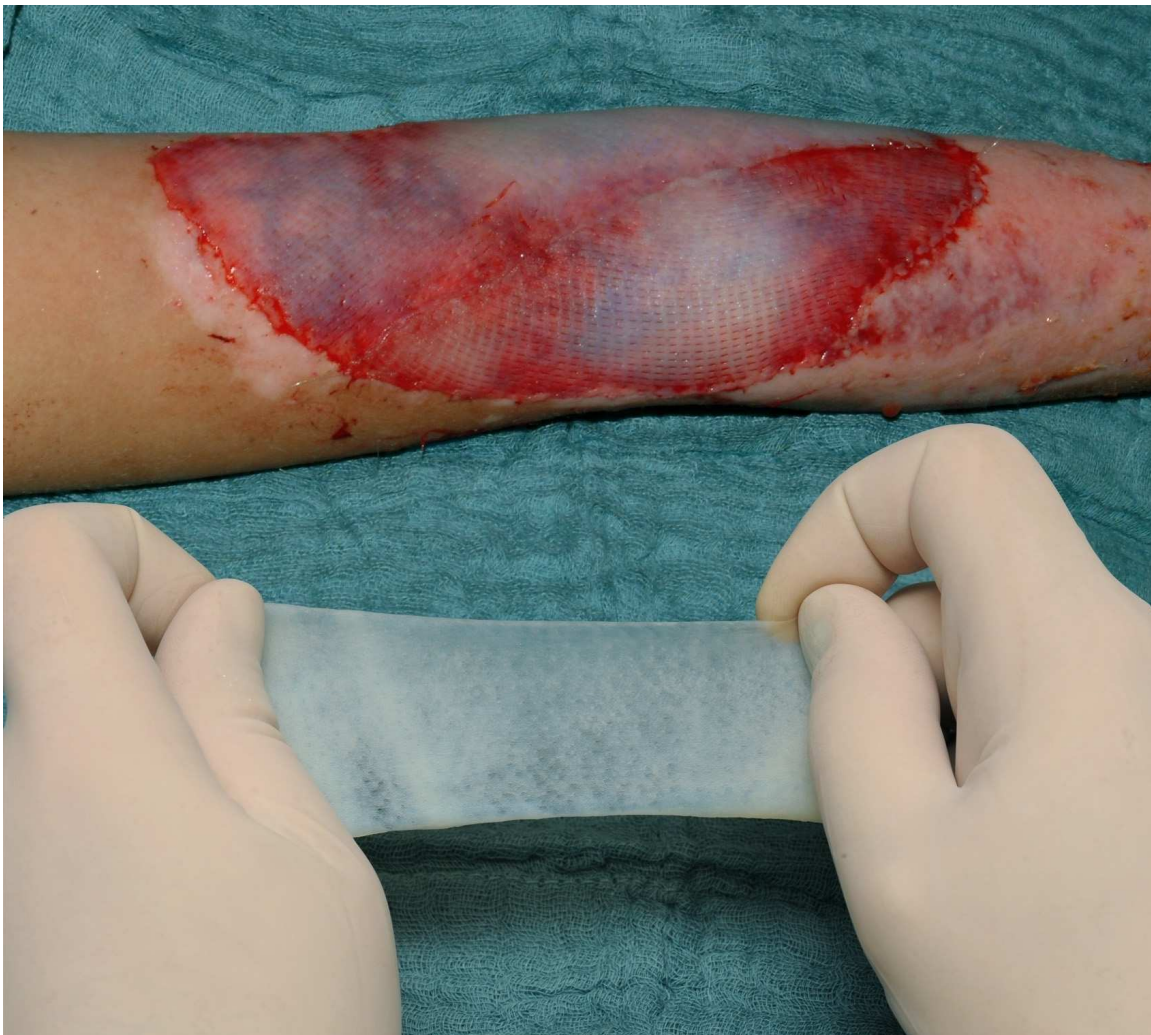

Fig. 2. Example of Glyaderm

85% glycerol and must be rinsed in sterile 0.9% NaCl before use on the patient. The Glyaderm is meshed 1:1 to allow drainage of wound fluid. Glyaderm was used on the patients also in a two stage procedure in clinical studies, approved by the local ethics committee of the University of Ghent, Belgium. A pilot study and a comparative study were performed sofar.

#### **4. Pilot study**

In the first non-randomized pilot experiments 15 patients with full thickness burns (TBSA < 40%) were selected to study the optimal wound dressing, to avoid dehydration and bacterial contamination of the Glyaderm during the first days before the autologous skin was applied. Then a group of 10 patients with full thickness wounds was selected (5 with burns and 5 with reconstructive wounds) and was treated to define the optimal time between the two operations using Laser Doppler Imaging. The depth of the burn wounds was first assessed using laser Doppler imaging (Monstrey et al., 2007) to assure the wounds were deep dermal. The patients were recruited and treated with Glyaderm and split thickness skin graft after wound bed preparation with glycerol preserved allografts. Patient demographics were recorded and Laser Doppler imaging was used to monitor the vascularization of glyaderm. We also discovered that Laser Doppler Imaging allows us to measure wound tissue perfusion and monitor daily ingrowth of blood vessels into the dermal substitute. This allows us to know the exact timeframe in which the dermal bed is vascularised enough and skin grafting can be carried out. This is typically after 5-7 days, much shorter than the period necessary for ingrowth of the currently most widely used commercial dermal substitute Integra (Dantzer et al., 2001)

##### **4.1 Randomised, controlled, paired, intra-individual Comparative study in 30 patients**

After completing the pilot studies, a comparative study was performed. Patients with full thickness burns or full thickness lower arm defects after free flap harvesting were recruited. Part of the wounds were treated with Glyaderm and split thickness skin and the other part with split thickness skin only. This was done in anatomically related areas to allow paired, intra-individual comparison of the wound healing. Preferably, a left/right comparison was made and the experimental treatment was randomized. Patient demographics were recorded and at regular follow up time points of 1, 3, 6 and 12 months after wound closure biopsies were taken and objective and subjective scar assessment was performed. The dermatospectrometer was used to measure scar colour, Dermalab cutometer for pliability and the modified Vancouver scar scale as well as a contour scale (Brusselaers et al 2010) were used. All data were recorded in a purpose designed database and subjected to statistical analysis with SPSS software package.

#### **5. Results of the pilot study**

All recruited patients responded well to a dressing regimen of surfasoft, a semipermeable membrane, with betadine gel and paraffin gauze in terms of bacterial control and prevention from desiccation of Glyaderm with capital. Laser Doppler Imaging proved to show enhanced vascularization from day 1 to day 5 allowing to exactly delineate the optimal engraftment interval. This was found to be 6 days with a 1 day standard deviation.

The increase in blood vessel growth can be observed clearly in Figure 3, the areas with a red color represent blood vessel flow and these are larger on day 7 in this patient. The take of the Glyaderm was > 90% and the take of the autologous skin > 95%. The results with respect to scar formation in this pilot study were encouraging. Figure 4 shows pictures of the wound and final scar of the same patient as in Figure 3. The color of the scar is not red and the patient is able to move the head normally, indicating good elasticity.

IntechOpen

### Laser Doppler Imaging of GlyaDerm vascularisation

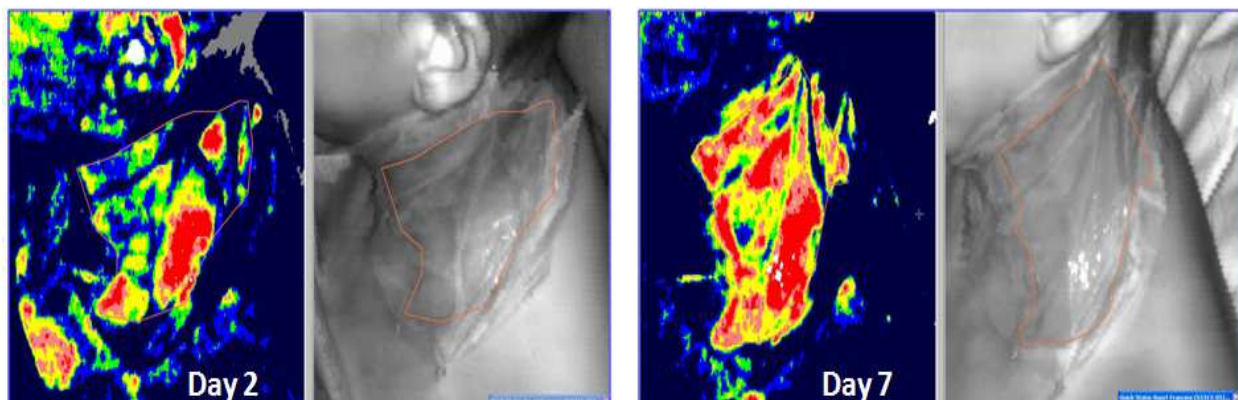
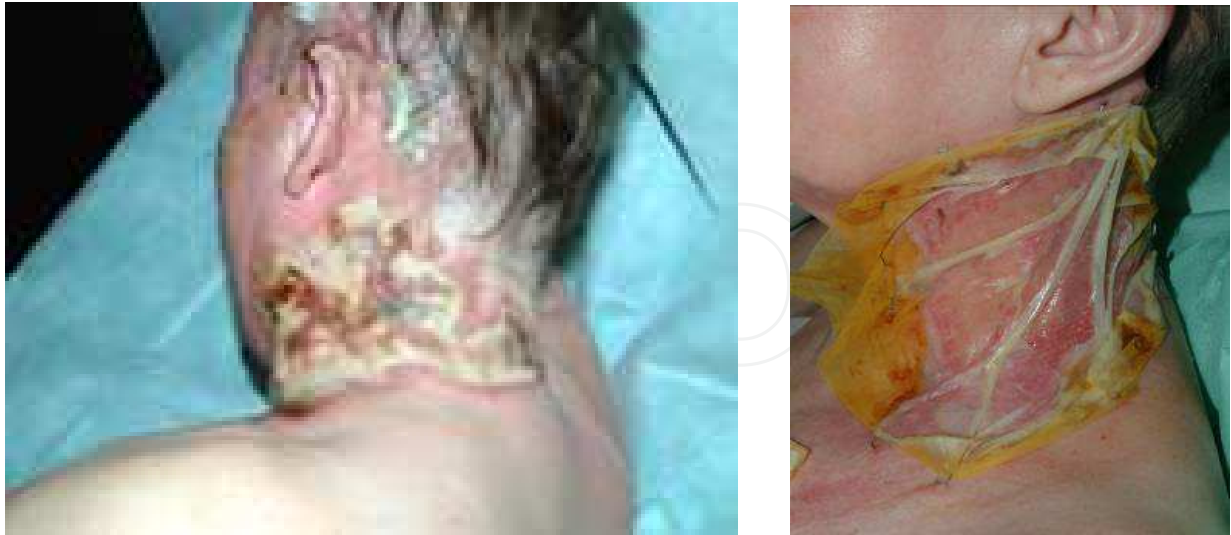

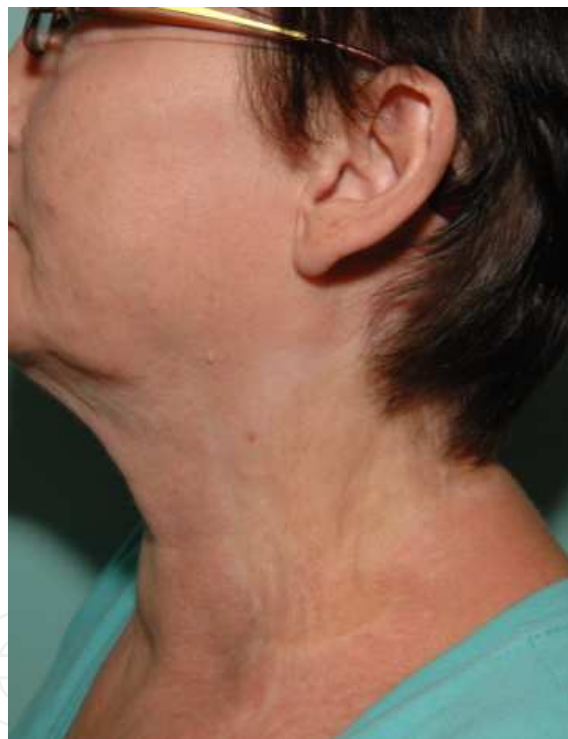
Fig. 3. Shows the growth of blood vessels in a deep burn wound treated with Glyaderm

## 6. Results of the comparative study

The take rates in the STSG on Glyaderm were comparable to the take rates in the wounds with a STSG alone (Wilcoxon Signed Ranks Test  $Z = -0.823$ ,  $p = .41$ ). Pliability and Visual Scores and contour scale assessment indicate a trend of improvement with Glyaderm treatments; however, follow-up times are currently too short with small numbers to be able to draw conclusions, we expect a necessary follow-up interval of two years. Comparing the Dermalab measurements for elasticity “Glyaderm + STSG” versus “STSG alone” statistics indicate that: “Glyaderm + STSG” has significantly more elasticity when compared to “STSG alone” 1 month and 12 months after wound closure.



A: Burn wound before treatment



B: Two years follow-up

Fig. 4. Final results of this wound with respect to scar formation show a cosmetic good quality of the scar.

## 7. Conclusion

The results of the comparative, controlled, intra-individual clinical study show beneficial effects of a dermal substitute on the elasticity of the scar. The natural structure of the collagen and elastin fibers in glyaderm may have contributed to this effect. Glyaderm is the first non-commercial dermal substitute that can compete with all currently available dermal

equivalents. Laser Doppler imaging allows monitoring of vascular ingrowth in dermal substitutes such as Glyaderm. Although most burn experts advocate the use of dermal substitutes, the challenge remains to objectively show the perceived benefit over split thickness skin grafting alone. The evolving evaluation with objective scar assessment tools within these studies may help to demonstrate this benefit in the near future.

Our next study with Glyaderm has started recently; a multi-centre clinical study in major European Burn centers. To allow also quality of life and cost-effectiveness studies, 60 patients will be treated with glyaderm + STSG and 60 patients with STSG alone.

Researchers continue their quest for the ideal skin substitute, and in the future it should be possible to create such an advanced skin substitute, containing melanocytes, hair follicles and sebaceous glands. The available products remain rather expensive, due to commercial incentives, high manufacturing costs, special shipment and storage conditions. Nevertheless, accelerated healing and closure of the wound will reduce the labour intensive dressing changes, hospital stay and the need for reconstructive surgery. Until the optimal off the shelf skin substitute becomes available, the burn surgeon can improve aesthetic and functional outcome by choosing from the gamut of currently available scaffolds for bilayered skin restoration. Glyaderm may well be an optimal cost-effective solution to bridge this gap in the near future.

## 8. References

- Brusselaers N, Pirayesh A, Hoeksema H, Richters CD, Verbelen J, Beele H, Blot SI, Monstrey S. *J Trauma* 2010; 68: 490-501.
- Brusselaers N, Pirayesh A, Hoeksema H, Verbelen J, Blot S, Monstrey S. Burn scar assessment: a systematic review of objective scar assessment tools. *Burns* 2010, 36:1157-1164.
- Cuono CB, Langdon R, Birchall N, Barttelbart S, McGuire J. Composite autologous-allogeneic skin replacement: development and clinical application. *Plast Recon Surg* 1987, 80: 626-637.
- Dantzer E, Braye FM. Reconstructive surgery using an artificial dermis (Integra): results with 39 grafts. *Br J Plast Surg*. 2001, 54: 659-664.
- Hermans MHE. Clinical experience with glycerol preserved donor skin treatment in partial thickness burns. *Burns* 1989; 15: 57-60.
- Jones I., Currie L., Martin P. A guide to biological skin substitutes. *Br J Plast Surg* 2002, 55: 185-193.
- Kreis RW, Vloemans AFPM., Hoekstra MJ, Mackie DP, Hermans RP. The use of non-viable glycerol-preserved cadaver skin combined with widely expanded autografts in the treatment of extensive third-degree burns. *J Trauma* 1989; 29:51-55
- Monstrey S, Hoeksema H, Verbelen J, Pirayesh A, Blondeel P. Assessment of burn depth and burn wound healing potential. *Burns* 2008; 34:761-769.
- Pirayesh A, Monstrey S, Blondeel P, Hoekstra H, Vanoorbeek J, Hoeksema H, Richters CD. Development of a novel dermal substitute based on glycerinized allograft: Clinical (Phase I) and experimental evaluation. *Burns* 2007; 33:S13



- Pirayesh A., Dur A.F.M., Paauw N.J., Monstrey S., Kreis R.W., Hoekstra M.J., Richters C.D. Evaluation of acellular dermis for closure of abdominal wall defects in a rat model. *Eur Surg res* 2008; 41 :345-352.
- Pirayesh A., Hoeksema H, Richters CD, Monstrey S. Determination of the optimal time interval between application of a dermal substitute and grafting with autologous skin using Laser Doppler Imaging. Manuscript in preparation.
- Richters C.D., Pirayesh A., Hoeksema H., Kamperdijk E.W.A., Kreis R.W., Dutrieux R.P., Monstrey S., Hoekstra M.J. Development of a dermal matrix from glycerol preserved allogeneic skin. *Cell and Tissue Banking* 2008; 9 : 309-315.
- Van der Veen V, Van der Wal MB, Van Leeuwen MC, Ulrich MM, Middelkoop E. Biological background of dermal substitutes. *Burns* 2010; 36: 305-321.

IntechOpen



## **Skin Grafts - Indications, Applications and Current Research**

Edited by Dr. Marcia Spear

ISBN 978-953-307-509-9

Hard cover, 368 pages

**Publisher** InTech

**Published online** 29, August, 2011

**Published in print edition** August, 2011

The procedure of skin grafting has been performed since 3000BC and with the aid of modern technology has evolved through the years. While the development of new techniques and devices has significantly improved the functional as well as the aesthetic results from skin grafting, the fundamentals of skin grafting have remained the same, a healthy vascular granulating wound bed free of infection. Adherence to the recipient bed is the most important factor in skin graft survival and research continues introducing new techniques that promote this process. Biological and synthetic skin substitutes have also provided better treatment options as well as HLA tissue typing and the use of growth factors. Even today, skin grafts remain the most common and least invasive procedure for the closure of soft tissue defects but the quest for perfection continues.

### **How to reference**

In order to correctly reference this scholarly work, feel free to copy and paste the following:

Pirayesh A., Richters CD, Hoeksema H, Verbelen J, Heyneman A and Monstrey S. (2011). Clinical Evaluation of Glyaderm, a Dermal Substitute Based on Glycerinized Donor Skin, *Skin Grafts - Indications, Applications and Current Research*, Dr. Marcia Spear (Ed.), ISBN: 978-953-307-509-9, InTech, Available from: <http://www.intechopen.com/books/skin-grafts-indications-applications-and-current-research/clinical-evaluation-of-glyaderm-a-dermal-substitute-based-on-glycerinized-donor-skin>

**INTECH**  
open science | open minds

### **InTech Europe**

University Campus STeP Ri  
Slavka Krautzeka 83/A  
51000 Rijeka, Croatia  
Phone: +385 (51) 770 447  
Fax: +385 (51) 686 166  
[www.intechopen.com](http://www.intechopen.com)

### **InTech China**

Unit 405, Office Block, Hotel Equatorial Shanghai  
No.65, Yan An Road (West), Shanghai, 200040, China  
中国上海市延安西路65号上海国际贵都大饭店办公楼405单元  
Phone: +86-21-62489820  
Fax: +86-21-62489821

© 2011 The Author(s). Licensee IntechOpen. This chapter is distributed under the terms of the [Creative Commons Attribution-NonCommercial-ShareAlike-3.0 License](#), which permits use, distribution and reproduction for non-commercial purposes, provided the original is properly cited and derivative works building on this content are distributed under the same license.

IntechOpen

IntechOpen