

# We are IntechOpen, the world's leading publisher of Open Access books Built by scientists, for scientists

**4,800**

Open access books available

**122,000**

International authors and editors

**135M**

Downloads

Our authors are among the

**154**

Countries delivered to

**TOP 1%**

most cited scientists

**12.2%**

Contributors from top 500 universities



**WEB OF SCIENCE™**

Selection of our books indexed in the Book Citation Index  
in Web of Science™ Core Collection (BKCI)

Interested in publishing with us?  
Contact [book.department@intechopen.com](mailto:book.department@intechopen.com)

Numbers displayed above are based on latest data collected.

For more information visit [www.intechopen.com](http://www.intechopen.com)



# Penis-Sparing Surgery with Neo-Glans Reconstruction for Benign, Premalignant or Malignant Penile Lesions

Enzo Palminteri<sup>1</sup>, Fernando Fusco<sup>2</sup>,  
Elisa Berdondini<sup>1</sup> and Andrea Salonia<sup>3</sup>

<sup>1</sup>Center for Urethral and Genitalia  
Reconstructive Surgery, Arezzo

<sup>2</sup>Department of Urology, University  
Federico II, Naples

<sup>3</sup>Department of Urology, University  
Vita-Salute San Raffaele, Milan  
Italy

## 1. Introduction

Penile neoplasm is an uncommon malignancy affecting less than 1 out of 100000 males in Europe and in the United States. Seventy-eight percent of all tumours appear on the glans and/or prepuce [1,2]. Many of these lesions are red, moist patches which can be misdiagnosed as either a benign skin condition (i.e. Zoon's balanitis or lichen planus) or a premalignant lesion such as the lichen sclerosus (LS) that, if left untreated, has the risk of progression to invasive squamous cell carcinoma in 5 to 33% of the cases [3]. Beyond all, both benign, premalignant and malignant lesions may cause pruritus, pain, bleeding, crusting and difficulties in retracting the foreskin, and overall psychosexual disability.

The treatment of benign, premalignant and malignant penile lesions has changed over time [4,5]. Traditional penile surgery is associated with a mutilating approach, eventually characterized by a high incidence of aesthetic, dysfunctional and psychological post-operative disorders [6-8]. In this context, the use of either medical or topical surgical treatments has been supported with the specific aim to maintain a good functional and aesthetic penile shaft; topical chemotherapy, laser ablation, cryotherapy, and local excisions have been thus reported in the scientific literature [3, 4]. However, these techniques are associated with high failures rates and unsightly scarring that impacts on penile appearance and sexual activity.

Recently in patients with either premalignant or malignant superficial lesions, alternative forms of surgical therapy have aimed at preserving the phallus without jeopardizing local cancer control have been extensively suggested. These organ-sparing techniques, providing the reconstruction of an aesthetic neo-glans without any impairment of patient's survival have also been suggested for more advanced tumours [1 - 3, 9].

## 2. Surgical techniques

Penis-preserving surgery with cosmetic reconstruction of a neo-glans is performed via 4 different surgical techniques using a free split-thickness skin graft (STSG) harvested from the thigh.

### 2.1 Glans skinning and glans resurfacing

The penis is circumcised and the penile skin is degloved. The glandular epithelium is fully removed up to the coronal sulcus. After preliminary marking, skin level incisions are made distally, skirting the edges of the meatus and proximally below the coronal margin. Vertical midline incisions are made dorsally and ventrally and join these distal and proximal incisions so that the glans covering can be dissected away as separate right and left halves. The STSG is harvested from the thigh using manual dermatome, and I subsequently transplanted like an umbrella over the bed of the stripped glans. The graft is then tailored and quilted over the glans with multiple 6-zero polyglactin interrupted stitches. The penile skin is sutured to the graft at the coronal sulcus (fig. 1 and 2).

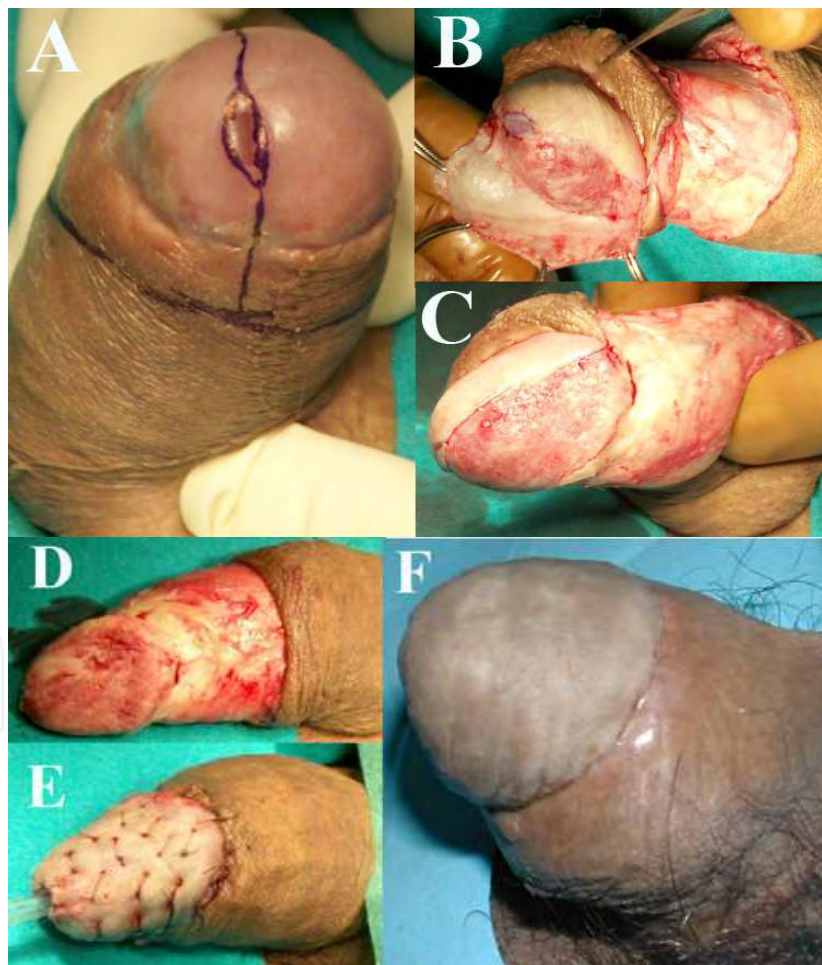


Fig. 1. Glans skinning and glans resurfacing: Squamous cell carcinoma involving glans and coronal sulcus (A). The glans epithelium is removed together with the distal foreskin (B - C - D). The skin graft is sutured and quilted over the stripped glans (E). Penile appearance 6 months after surgery (F).

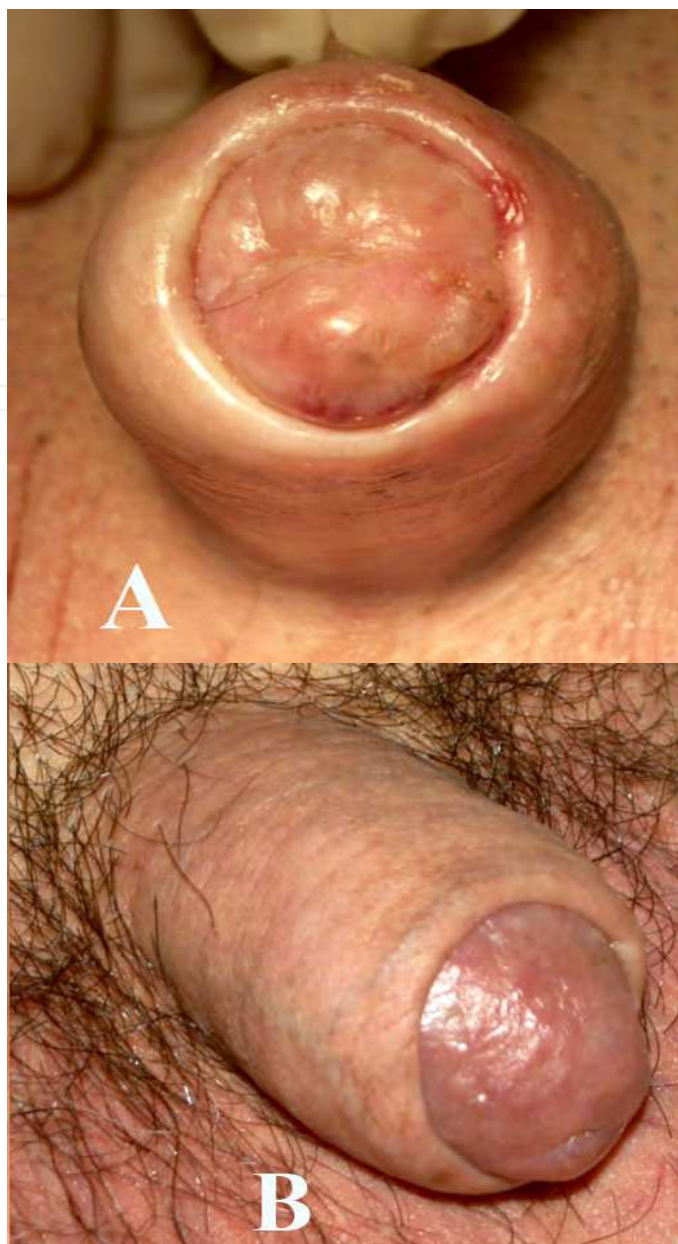


Fig. 2. Glans skinning and glans resurfacing: Lichen Sclerosus and Carcinoma in situ involving glans penis (A). Penile appearance 6 months after surgery (B).

This procedure is suitable for crippling benign and premalignant lesions, as well as malignant lesions, limited to the glandular epithelium.

## 2.2 Glansectomy and neo-glans reconstruction

The penis is circumcised and the penile skin is degloved. The glans is carefully segregated from the corpora cavernosa and the urethra is then distally sectioned. After removing the glans, the urethra is ventrally opened and the external urethral meatus is fixed to the tip of the corpora cavernosa. The STSG is then transplanted like an umbrella over the tips of the corpora cavernosa. The graft is tailored and quilted using interrupted stitches over the top of the corpora. Finally, the graft is fixed to the penile skin in order to recreate a neo-sulcus (fig. 3).

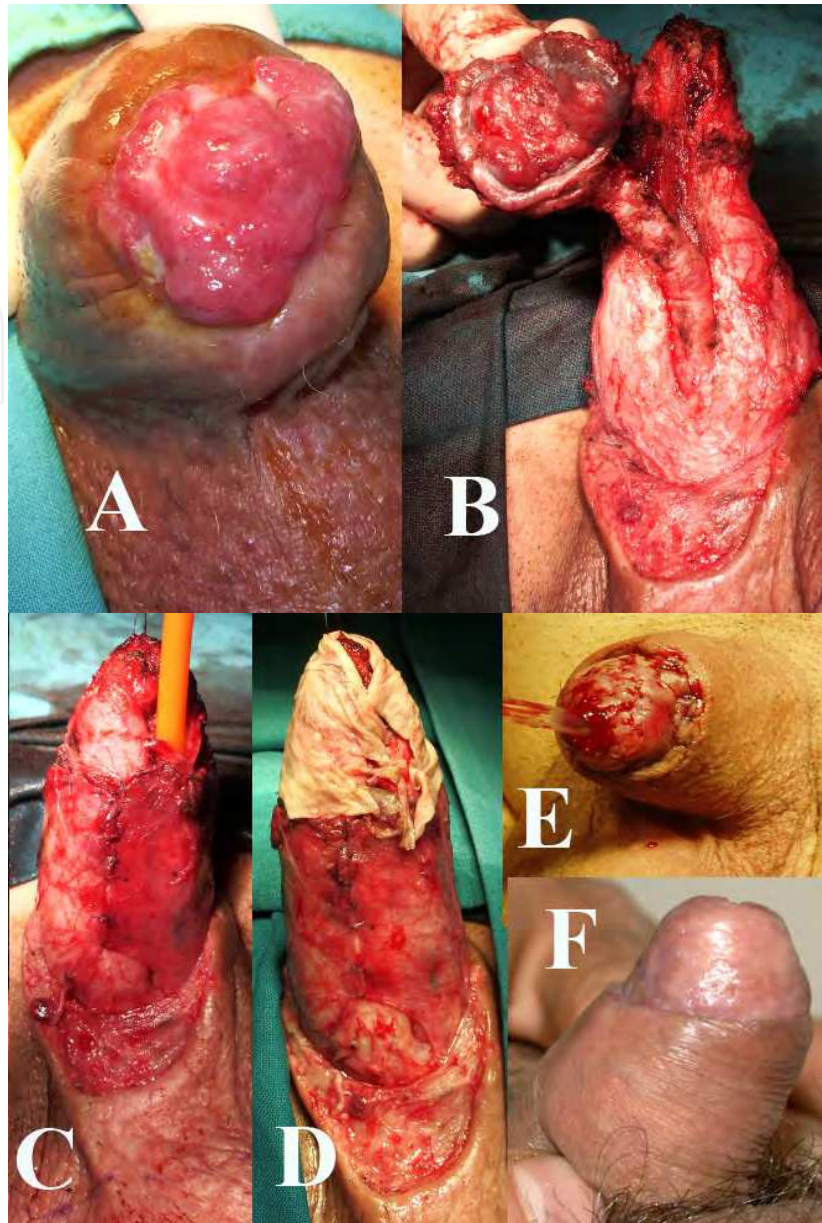


Fig. 3. Glansectomy and neo-glans reconstruction :Squamous cell carcinoma involving glans penis (A). The glans is dissected from the corpora cavernosa and the urethra is distally sectioned (B). The urethral meatus is fixed to the summit of the corpora cavernosa (C). The STSG is transplanted like an umbrella over the summit of the corpora cavernosa (D). The graft is tailored and quilted using interrupted stitches over the top of the corpora. The graft is fixed to the penile skin in order to recreate a neo-sulcus (E). Penile appearance 6 months after surgery (F).

This procedure is usually suitable for malignant lesions infiltrating the glans.

### 2.3 Partial penectomy and neo-glans reconstruction

The partial penectomy is performed with resection margins of only few millimetres, according to the current techniques [10].

The lateral edges of the residual corpora cavernosa are sutured together to create a hemispheric dome-shaped stump. The urethra is then spatulated and the meatus is fixed on

the new tip of the corpora cavernosa. The STSG is transplanted like an umbrella over the summit of the hemispheric stump where it is quilted. The graft is eventually fixed to the penile skin with the aim to recreate a glandular neo-sulcus (fig. 4).

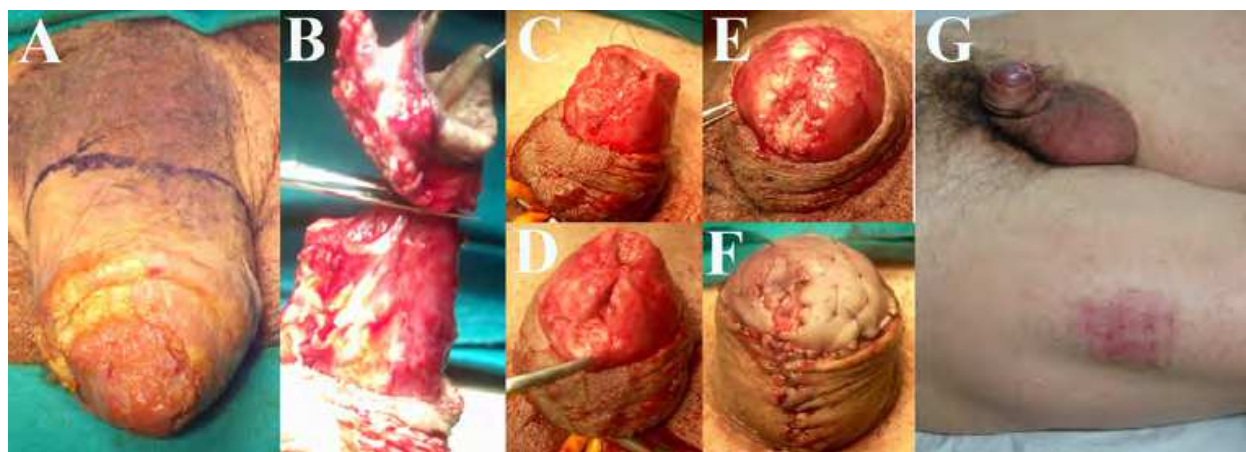


Fig. 4. Partial penectomy and neo-glans reconstruction : Squamous cell carcinoma involving glans and penile shaft (A). Foreskin degloving and partial penectomy (B).The lateral edges of the residual corpora cavernosa are sutured together to create a hemispheric dome-shaped stump (C - D). The urethra is spatulated and the meatus is fixed on the new tip of the corpora cavernosa (E). The STSG is transplanted over the summit of the hemispheric stump (F). Penile appearance 6 months after surgery (G).

This procedure is suitable for malignant lesions involving the penile shaft.

#### 2.4 Neo-glans reconstruction following previous traditional partial penectomy

The top of the penile stump is skinned and the tip of the residual corpora cavernosa is reconverted to a hemispheric shape. The urethra is spatulated and the meatus is fixed on the new tip of the corpora cavernosa. The STSG is transplanted like an umbrella over the summit of the hemispheric stump where it is quilted. The graft is fixed to the penile skin thus recreating a glandular neo-sulcus (fig. 5).

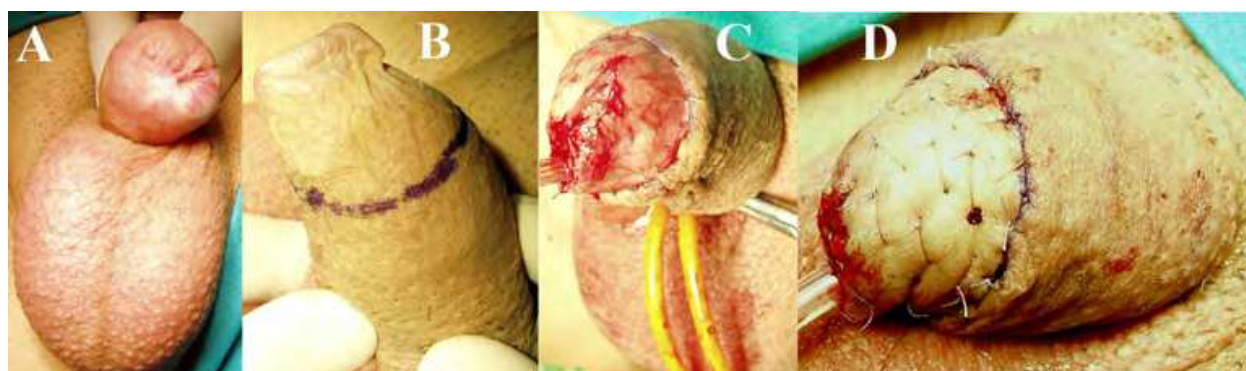


Fig. 5. Neo-glans reconstruction following previous traditional partial penectomy : Penile stump following partial penectomy (A). The top of the penile stump is skinned and the tip of the residual corpora is reconverted to a hemispheric shape (B -C). The STSG is transplanted like an umbrella over the summit of the hemispheric stump and fixed to the penile skin thus re-creating a neo-sulcus (D).

This procedure is suitable for unaesthetic residual penile stumps following previous traditional partial penectomy.

In all cases a 12-Fr silicone Foley catheter is inserted and a soft and humid dressing is applied covering the penis. The dressing is left in place for three days and the patient is requested to remain in bed. If the graft is observed to be without hematoma, seroma or infection after four days, the patient is mobilised and discharged from the hospital.

From 2002 through 2010, 21 patients (mean age 61 years; range 41-78) suffering from either benign, pre-malignant or malignant penile lesions underwent organ-sparing surgery with neo-glans reconstruction: 3 cases were treated by glans-skinning and glans-resurfacing, 10 by glanssectomy and neo-glans reconstruction, 4 by partial penectomy and a neo-glans reconstruction, and 4 by neo-glans reconstruction after a traditional partial penectomy. No significant immediate post-operative complications were observed. Five (23.8%) patients showed partial graft loss and wound separation that were resolved after conservative management. No immediate or later complications were observed at the harvesting site. With a mean follow-up of 45 months, all patients were free of primary local disease. All patients were satisfied with the phallic post-operative appearance and recovered their sexual ability, although sensitivity was reduced as a consequence of glans/penile amputation.

### 3. Discussion

Laser ablation or other conservative therapies for penile lesions aim to remove the diseased tissue, but recurrence of the disease may eventually occur in unrecognised pre-malignant foci arising within the unstable epithelium following a partial procedure. Moreover, precancerous lesions often show recalcitrance after conservative treatments, with final evolution to a SCC in 5 to 33% of the cases [4,9,15-17]. Recently, plastic and reconstructive surgical techniques have been developed to reduce the functional and psychological morbidity in patients who have undergone mutilating penile surgery [1-3,9,11-14]. In selected patients, the use of these relatively-new plastic and reconstructive approaches provided a satisfactory aesthetic and functional outcome, without sacrificing a rigorous cancer control [1-3].

In this context, when performing a glans skinning and resurfacing, the epithelium is completely removed, thus reducing the risk of either disease recurrence or progression in different sites as compared with the primary lesion. Moreover, for lichen sclerosus which involves the male genitalia, an evolution toward a grossly scarring disease has been frequently described, with the subsequent phimosis which may promote poor local hygiene and chronic inflammatory conditions potentially being the etiological factors promoting penile malignancy. In this case, LS is frequently associated with dysplasia; therefore some authors have suggested that LS should be considered as a formal pre-cancerous lesion [15-18]. In these patients, total excision of the dysplastic glandular epithelium reduces the risk of cancer developing. Likewise, this approach may solve the problem of discomfort during sexual intercourse, which is frequently a consequence of the scarred glans.

In our series, even one patient with persistent extensive Zoon' balanitis was able to resume sexual activity after glans skinning and glans resurfacing. In patients who underwent glanssectomy or partial penectomy, sensitivity was reduced as a predictable consequence of glans/penile amputation, but the cosmetic appearance of the neo-glans was similar to that of a native glans. The patients were then able to fully regain sexual functioning, with a

favourable psychological impact. In these patients, the aesthetic appearance of the penis was subjectively superior when compared with patients who underwent others traditional techniques, thus promoting a positive psychological impact. This last aspect is of paramount importance since many patients with penile cancer are significantly reluctant to undergo partial or total penectomy due to the self-feeling of compromised masculinity [3]. It has been previously reported that roughly 80% of penile malignancies are probably amenable to these penis-preserving techniques, since most of the lesions occur distally and involve only the superficial epithelium of the glans [2]. In this context, it is important to highlight that in patients with superficial penile cancer associated to pre-cancerous lesions due to LS, any conservative treatment does not actually remove these lesions, thus potentially allowing cancer recurrence over time which may arise from an *unstable* epithelium bordering the primary lesion. Therefore, a rigorous patient selection is compulsory in order to technically provide an aesthetic solution with an effective long-term cancer control.

#### 4. Conclusions

The penis-sparing surgery coupled with neo-glans reconstruction is an adequate treatment approach in rigorously selected patients with either benign, pre-malignant or malignant penile lesions. While preserving a good aesthetic appearance of the penile shaft, the goal of all these techniques is to maintain a functional penis in terms of both urination and sexual function, without jeopardizing cancer control.

#### 5. Acknowledgement

The surgical techniques described in this article were developed and suggested to us by Dr. Aivar Bracka, without whose teaching and guidance it would not have been possible to obtain these positive results.

#### 6. References

- [1] C.T. Brown, S. Minhas and D.J. Ralph, "Conservative surgery for penile cancer: subtotal glans excision without grafting," *British Journal of Urology International*, vol. 96, pp. 911-912, 2005.
- [2] P. Pietrzak, C.M. Corbishley and N. Watkin, "Organ-sparing surgery for invasive penile cancer: early follow-up data," *British Journal of Urology International*, vol. 94, pp. 1253-1257, 2004.
- [3] P. Hadway, C.M. Corbishley and N.A. Watkin, "Total glans resurfacing for premalignant lesions of the penis: initial outcome data," *British Journal of Urology International*, vol. 98, pp.532-536, 2006.
- [4] P.K. Hegarty, R.W. Rees, N.C. Borley, et Al. "Contemporary management of penile cancer," *British Journal of Urology International*, vol. 102, pp.928-932, 2008.
- [5] A. Bracka, "Glans resection and plastic repair," *British Journal of Urology International*, vol. 105, pp. 136-144, 2009.
- [6] S. Opjordsmoen and S.D. Fossa, "Quality of life in patients treated for penile cancer. A follow-up study," *British Journal of Urology*, vol. 74, pp. 652-657.
- [7] C.A. D'Ancona, N.J. Botega, C. De Moraes, et Al.. "Quality of life after partial penectomy for penile carcinoma," *Urology*, vol. 50, pp. 593-596, 1997.



- [8] F.R. Romero, K.R. Pereira Dos Santos Romero, M.A. Elias De Mattos, et Al. "Sexual function after partial penectomy for penile cancer," *Urology*, vol. 66, pp. 1292-1295, 2005.
- [9] E. Palminteri E, E. Berdondini, M. Lazzeri, et Al. "Resurfacing and reconstruction of the glans penis," *European Urology*, vol. 52, pp. 893-900, 2007.
- [10] S. Minhas, O. Kayes, P. Hegarty, et Al. "What surgical resection margins are required to achieve oncological control in men with primary penile cancer ?" *British Journal of Urology*, vol. 96, pp. 1040-1043, 2005.
- [11] A.G. Fonseca, G.N. Rabelo, K.S. Vidal et Al. "Glandectomy with preservation of corpora cavernosa in the treatment of penile carcinoma," *International Brazilian Journal Urology*, vol. 29, pp. 437-440, 2003.
- [12] N. Bissada, "Organ-sparing surgery for invasive penile carcinoma," *British Journal of Urology*, vol. 95, pp. 1118-1119, 2005.
- [13] M.L. Greenberger and B.A. Lowe BA, "Penile stump advancement as an alternative to perineal urethrostomy after penile amputation," *Journal of Urology*, vol. 161, pp. 893-894, 1999.
- [14] S. Parkash, N. Ananthakrishnan and P. Roy, "Refashioning of phallus stumps and phalloplasty in the treatment of carcinoma of the penis," *British Journal of Surgery*, vol. 73, pp. 902-905, 1986.
- [15] A.L. Cubilla, E.F. Velazquez and R.H. Young, "Epithelial lesions associated with invasive penile squamous cell carcinoma: a pathologic study of 288 cases," *International Journal of Surgical Pathology*, vol. 12, pp. 351-364, 2004.
- [16] M.R. Nasca, D. Innocenzi and G. Micali, "Penile cancer among patients with genital lichen sclerosus," *Journal American Academy Dermatology*, vol. 41, pp. 911-914, 1999.
- [17] J. Powell, A. Robson A, D. Cranston, et Al, "High incidence of lichen sclerosus in patients with squamous cell carcinoma," *British Journal of Dermatology*, vol. 145, pp. 85-89, 2001.
- [18] G. Barbagli, E. Palminteri, F. Mirri, et Ali, "Penile carcinoma in patients with genital lichen sclerosus: a multicentric survey," *Journal of Urology*, vol. 175, pp. 1359-1363, 2006.

IntechOpen



## **Skin Grafts - Indications, Applications and Current Research**

Edited by Dr. Marcia Spear

ISBN 978-953-307-509-9

Hard cover, 368 pages

**Publisher** InTech

**Published online** 29, August, 2011

**Published in print edition** August, 2011

The procedure of skin grafting has been performed since 3000BC and with the aid of modern technology has evolved through the years. While the development of new techniques and devices has significantly improved the functional as well as the aesthetic results from skin grafting, the fundamentals of skin grafting have remained the same, a healthy vascular granulating wound bed free of infection. Adherence to the recipient bed is the most important factor in skin graft survival and research continues introducing new techniques that promote this process. Biological and synthetic skin substitutes have also provided better treatment options as well as HLA tissue typing and the use of growth factors. Even today, skin grafts remain the most common and least invasive procedure for the closure of soft tissue defects but the quest for perfection continues.

### **How to reference**

In order to correctly reference this scholarly work, feel free to copy and paste the following:

Enzo Palminteri, Fernando Fusco, Elisa Berdondini and Andrea Salonia (2011). Penis-Sparing Surgery with Neo-Glans Reconstruction for Benign, Premalignant or Malignant Penile Lesions, Skin Grafts - Indications, Applications and Current Research, Dr. Marcia Spear (Ed.), ISBN: 978-953-307-509-9, InTech, Available from: <http://www.intechopen.com/books/skin-grafts-indications-applications-and-current-research/penis-sparing-surgery-with-neo-glans-reconstruction-for-benign-premalignant-or-malignant-penile-lesi>

**INTECH**  
open science | open minds

### **InTech Europe**

University Campus STeP Ri  
Slavka Krautzeka 83/A  
51000 Rijeka, Croatia  
Phone: +385 (51) 770 447  
Fax: +385 (51) 686 166  
[www.intechopen.com](http://www.intechopen.com)

### **InTech China**

Unit 405, Office Block, Hotel Equatorial Shanghai  
No.65, Yan An Road (West), Shanghai, 200040, China  
中国上海市延安西路65号上海国际贵都大饭店办公楼405单元  
Phone: +86-21-62489820  
Fax: +86-21-62489821

© 2011 The Author(s). Licensee IntechOpen. This chapter is distributed under the terms of the [Creative Commons Attribution-NonCommercial-ShareAlike-3.0 License](#), which permits use, distribution and reproduction for non-commercial purposes, provided the original is properly cited and derivative works building on this content are distributed under the same license.

IntechOpen

IntechOpen