

We are IntechOpen, the world's leading publisher of Open Access books Built by scientists, for scientists

4,800

Open access books available

122,000

International authors and editors

135M

Downloads

Our authors are among the

154

Countries delivered to

TOP 1%

most cited scientists

12.2%

Contributors from top 500 universities



WEB OF SCIENCE™

Selection of our books indexed in the Book Citation Index
in Web of Science™ Core Collection (BKCI)

Interested in publishing with us?
Contact book.department@intechopen.com

Numbers displayed above are based on latest data collected.

For more information visit www.intechopen.com



Acupuncture for Disorders of Consciousness - A Case Series and Review

Wen-Long Hu^{1,2,3}, Yu-Chiang Hung^{1,2} and Chih-Hao Chang^{2,3,4}

¹*Department of Chinese Medicine, Kaohsiung Chang Gung Memorial Hospital and Chang Gung University College of Medicine, Kaohsiung,*

²*Kaohsiung Medical University College of Medicine, Kaohsiung,*

³*Fooyin University College of Nursing, Kaohsiung,*

⁴*Division of Chinese Medicine, Kaohsiung Municipal Chinese Medical Hospital, Kaohsiung, Taiwan*

1. Introduction

The lives of numerous patients in critical condition have been saved since the development of neuro-intensive care medicine in the 1960s. However, an unfortunate outcome of this development is the existence of a pool of surviving patients with unresponsiveness. This previously rare condition has been a new challenge for the medical community. After decades of medical development, a general framework of diagnosis and treatment of unresponsiveness has gradually been established, although the current knowledge is mainly derived from personal experience, and consensus is lacking for well-defined and effective diagnostic and treatment procedures (Liang, 2008). Disorders of consciousness mainly include coma, vegetative states (VSs), and minimally-conscious states (MCSs) (Bernat, 2006). The causes of consciousness disorders are mainly traumatic brain injury and cerebrovascular diseases, but they may also include hypoxia resulting from cardiac arrest and resuscitation, shock, and carbon monoxide (CO) poisoning. The lesions are predominantly found in the cerebral cortex, hypothalamus, and midbrain (Povlishock & Christman, 1995; Kampel et al., 1998). Consciousness emerges from interactions of the reticular activating system between the two cerebral hemispheres and the brain stem. Any factor interfering with these delicate processes may decrease alertness. The cerebral cortex lacks any intrinsic mechanism to promote responsiveness, which instead requires subcortical structures to generate and maintain consciousness. External stimuli are transmitted to the brain stem through the sensory organs, subsequently relayed to the thalamus, and eventually delivered to the cerebral cortex. The hypothalamus also plays a crucial role during this process, especially in controlling periodic rhythms. Different etiological factors of consciousness disorders result in differences in neuropathology. This is exemplified by studies of nerve electrophysiology showing that short-term brain hypoxia mainly affects the cerebral cortex; however, as the duration of hypoxia extends, deeper structures are also compromised (Hoesch et al., 2008). The pathology of VS is divided into three categories: large-scale damage to the cerebral cortex, injury to links (e.g., thalamus)

between the cerebral cortex and the brain stem, and injury to connections (e.g., corpus callosum) within the cerebral cortex. The latter type of injury is also known as severe diffuse axonal injury (DAI). However, thalamus lesions or DAI are rarely found among MCS patients (Jennett et al., 2001).

Over the last decade, we have been applying acupuncture to various unresponsive patients who were receiving traditional Western medical treatment, and we have observed significant results. Similar advanced care protocols using multi-modal therapy have also been applied in some research fields (DeFina et al., 2010). Here, we report our findings using auxiliary acupuncture in addition to Western medicine, which enabled patients to regain consciousness in 6 weeks. Specifically, each of our patients from suffered consciousness disorders ranging from stroke, traumatic brain injury, hypoxic-ischemic encephalopathy, hypoxic encephalopathy, and post-partum eclampsia. Each patient had a Glasgow Coma Scale (GCS) score of 8 or lower.

2. Acupuncture therapy - restoring consciousness

We applied a consistent acupuncture procedure using the acupuncture positions of Eding zone, Dingnie zone, Shuigou (GV26), and Twelve Well on several patients with various consciousness disorders.

2.1 Scalp acupuncture: Eding zone and dingnie zone (Fig. 1)

Eding zone is located from the midline to the top of the forehead. Specifically, it extends from the front hairline to the Baihui (GV20) at the top of the head and has a width of approximately 1 cun. This zone belongs to the Governor Vessel and the Bladder Meridian of Zutaiyang and is divided into four parts, each of which can be used to treat diseases of the head, throat, upper energizer (or chest cavity, including the chest and diaphragm), the middle energizer (upper abdomen, umbilical abdomen), and the lower energizer (lower abdomen) (Zhu et al., 1993). Three stainless steel filiform needles with a diameter of 0.26 mm and length of 40 mm were sequentially inserted at 30 degree into Eding zone using the promotion needling technique in which the needles are twisted, slightly lifted, re-inserted to obtain Qi (de qi, causing the acupuncture needle to elicit the patient's feeling of soreness, numbness, distension, heaviness, or even sensation like an electric shock around the point

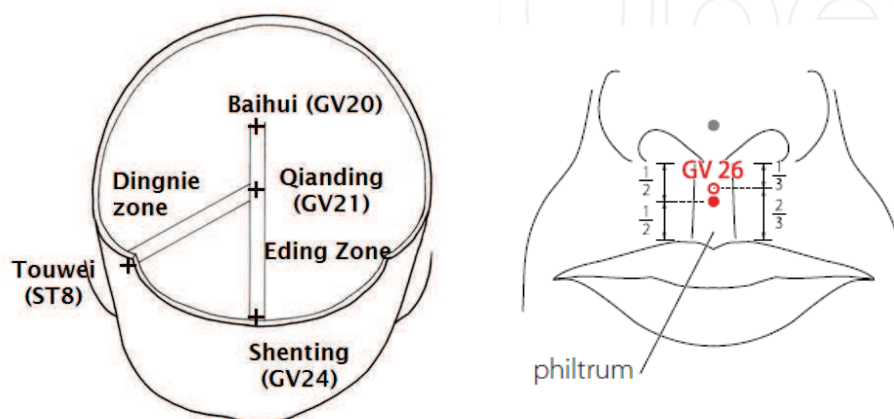


Fig. 1. Eding zone, Dingnie zone & GV26 (WPRO, 2009)

together with the practitioner's feeling of tenseness around the needle) (WPRO, 2007), and kept in place for 1 h. The procedure was applied three times every week. Twenty sessions of this procedure comprised a therapeutic course.

Dingnie zone is a strip between Qianding (GV21) and Touwei (ST8) and has a width of approximately 1 cun. It belongs to the Governor Vessel, the Bladder Meridian of Zutaiyang, and the Gallbladder Meridian of Zushaoyang. This strip is mainly used for treating movement disorders and sensory disturbances, and it has an especially significant effect on central and sensory movement disorders (Zhu et al., 1993). Four stainless steel filiform needles with a diameter of 0.26 mm and length of 40 mm were sequentially inserted at 30 degree into the two sides (two needles/side) using the promotion needling technique in which the needles are twisted, slightly lifted, re-inserted to obtain Qi, and kept in place for 1 h.

2.2 Body acupuncture: GV26 (Fig. 1) and Twelve Well points (Fig. 2)

Shuigou is also known as Renzhong. The Twelve Well points belong to the twelve Meridians. A stainless steel filiform needle with a diameter of 0.26 mm and length of 25 mm is sequentially inserted into individual points with half needling (no retention).

GV26: Shuigou. At the junction of the upper one third and lower two thirds of the philtrum midline. (WPRO, 2009)

LU11: Shaoshang. On the thumb, radial to the distal phalanx, 0.1 F-cun proximal-lateral to the radial corner of the thumb nail, at the intersection of the vertical line of the radial border and the horizontal line of the base of the thumb nail. (WPRO, 2009)

LI1: Shangyang. On the index finger, radial to the distal phalanx, 0.1 F-cun proximal-lateral to the radial corner of the index fingernail, at the intersection of the vertical line of the radial border of the fingernail and the horizontal line of the base of the index fingernail. (WPRO, 2009)

ST45: Lidui. On the second toe, lateral to the distal phalanx, 0.1 F-cun proximal-lateral to the lateral corner of the second toenail, at the intersection of the vertical line of the lateral border and the horizontal line of the base of the second toenail. (WPRO, 2009)

SP1: Yinbai. On the great toe, medial to the distal phalanx, 0.1 F-cun proximal-medial to the medial corner of the toenail, at the intersection of the vertical line of the medial border and horizontal line of the base of the toenail. (WPRO, 2009)

HT9: Shaochong. On the little finger, radial to the distal phalanx, 0.1 F-cun proximal-lateral to the radial corner of the little fingernail, at the intersection of the vertical line of the radial border of the nail and horizontal line of the base of the little fingernail. (WPRO, 2009)

SI1: Shaoze. On the little finger, ulnar to the distal phalanx, 0.1 F-cun proximal-medial to the ulnar corner of the little fingernail, at the intersection of the vertical line of ulnar border of the nail and horizontal line of the base of the little fingernail. (WPRO, 2009)

BL67: Zhiyin. On the little toe, lateral to the distal phalanx, 0.1 F-cun proximal to the lateral corner of the toenail; at the intersection of the vertical line of the lateral side of the nail and the horizontal line of the base of the toenail. (WPRO, 2009)

KI1: Yongquan. On the sole of the foot, in the deepest depression of the sole when the toes are flexed. (WPRO, 2009)

PC9: Zhongchong. On the middle finger, 0.1 F-cun proximal to the radial corner of the middle fingernail, at the intersection of the vertical line of the radial side of the nail and the horizontal line of the base of the fingernail. (WPRO, 2009)

TE1: Guanchong. On the ring finger, ulnar to the distal phalanx, 0.1 F-cun proximal to the ulnar corner of the fingernail, at the intersection of the vertical line of the ulnar side of the nail and the horizontal line of the base of the fingernail. (WPRO, 2009)

GB44: Zuqiaoyin. On the fourth toe, lateral to the distal phalanx, 0.1 F-cun proximal to the lateral corner of the toenail, at the intersection of the vertical line of the lateral side of the nail and the horizontal line of the base of the fourth toenail. (WPRO, 2009)

LR1: Dadun. On the great toe, lateral to the distal phalanx, 0.1 F-cun proximal to the lateral corner of the toenail, at the intersection of the vertical line of the lateral side of the nail and the horizontal line of the base of the toenail. (WPRO, 2009)

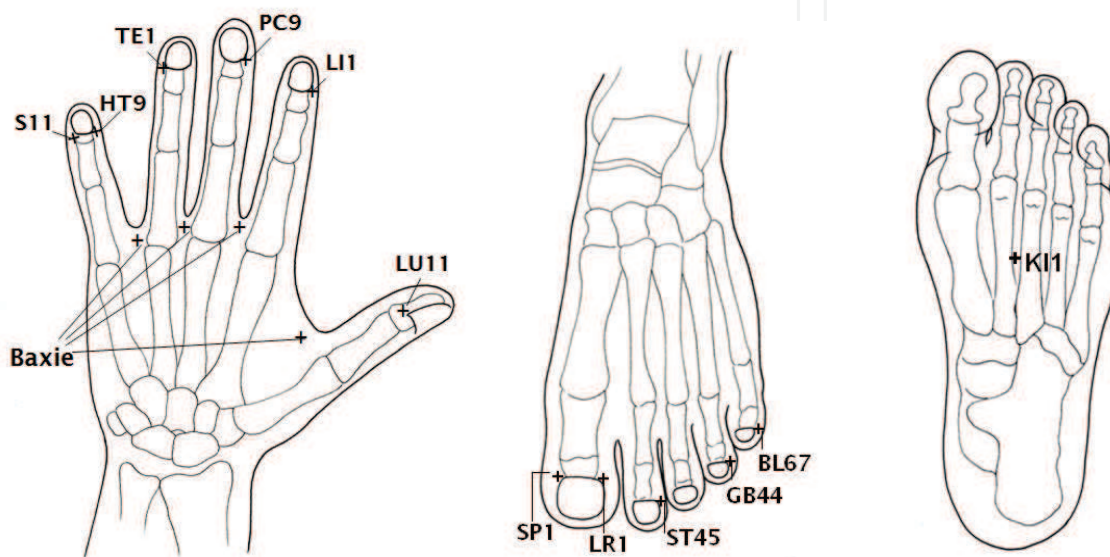


Fig. 2. Twelve Well points & Baxie

3. Case reports

3.1 Stroke

3.1.1 History and examination

An 84-year-old male who had suffered from diabetes and hypertension for more than 10 years had been treated with Western medicine regularly to control his symptoms. On January 21, 2008, he suddenly suffered a general weakness when going up stairs. He subsequently lost consciousness and was sent to the emergency ward of our hospital. Due to respiratory failure, he was placed on support with a ventilator. After admission, neither a brain computerized tomography (CT) scan nor magnetic resonance imaging (MRI) detected any hemorrhage or newly developed infarction. However, it was discovered that the patient had a high level of myocardial enzymes, corroborated by electrocardiography, which showed ST-T elevation in V4-V5. Thus, the patient was assumed to have suffered from acute myocardial infarction and cardiogenic shock and was subsequently transferred to a cardiac intensive care ward. On January 27, the patient was weaned from the ventilator, but still had a GCS score of 8 (E1V2M5). On January 29, because of a persistent consciousness disorder, he again underwent brain MRI, which revealed a partial infarction in the right and middle cerebral arteries. The next day, he was transferred to an intensive care ward in the Department of Neurology for further evaluation and treatment. On the same day, he

suffered gastrointestinal hemorrhage. On February 1, the patient developed intermittent atrial fibrillation associated with a rapid ventricular rate, and he therefore received a consultation and treatment from cardiovascular physicians. On February 5, he repeatedly exhibited ventricular tachycardia, from which he recovered after treatment with an automated external defibrillator (AED). On February 12, brain MRI indicated that infarction and hemorrhagic transformation appeared in both parts of the thalamus, the right cerebral peduncle, the right occipital lobe, and the right temporal-parietal area. On February 18, the patient suffered a urinary tract infection combined with pneumonia and sepsis, but remission was achieved after antibiotic treatment. Afterwards, he showed no apparent improvement in consciousness and exhibited signs of left hemiplegia, which was considered to be caused by hypoxic encephalopathy. On February 27, with a GCS of 8, he underwent a consultation and began acupuncture treatment.

3.1.2 Treatment (Table 1)

After three acupuncture treatments, the patient gradually regained responsiveness such that he could follow simple action commands. He was subsequently transferred to an ordinary ward in the Department of Neurology with a GCS of 11 and left side weakness. After 14 treatments, the patient could answer questions correctly and was therefore transferred to a rehabilitation ward. During this period, he developed angina pectoris and hyponatremia, which were improved after application of sublingual nitroglycerin as well as a diet adjustment to increase his salt intake (facilitated by dietitians). After 17 treatments, he completely regained consciousness and had a GCS of 15. After 20 treatments, the patient showed further improvement and was discharged from the hospital.

Date (sessions)	GCS	Muscle power*	Events
2008.02.27 (1)	E1V2M5	3/ 3/ 2/ 2	Intensive care ward, Dept. of Neurology
0303 (3)	E3V2M6	4/ 4/ 2/ 2	Ordinary ward, Dept. of Neurology
0313 (8)	E3V2M6	4/ 4/ 2/ 2	Hyponatremia
0325 (14)	E3V5M6	4/ 4/ 2/ 2	Rehabilitation ward, angina pectoris and hyponatremia
0403 (17)	E4V5M6	4/ 4/ 3/ 3	
0409 (20)	E4V5M6	4/ 4/ 3/ 3	Discharged from hospital

Table 1. Acupuncture therapeutic sessions for a patient with stroke (GCS: Glasgow coma scales; *: right upper extremity/right lower extremity/left upper extremity/left lower extremity)

3.2 Traumatic brain injury

3.2.1 History and examination

A 19-year-old female was involved in an automobile accident and was transferred to the emergency ward of our hospital from another medical institution on May 24, 2008. After admission, the patient lost consciousness and had a GCS of 8 (E1V2M5) as well as a dilated right pupil. Examination of the brain CT scan revealed multiple sites of contusion and bleeding in the subarachnoid space, left brain ventricle, and left temporal lobe, along with fracture of the right facial bone. After emergency intubation, the patient was transferred to

an intensive care ward in the Department of Neurosurgery. On May 26, she was extubated, but she remained unconscious and was additionally found to suffer from right hemiplegia. In addition, brain MRI detected a contusion and edema in the left cerebral peduncle and edema in the left optic chiasm. On May 30, with a GCS of 8, she underwent a consultation and began acupuncture treatment.

3.2.2 Treatment (Table 2)

After two acupuncture treatments, the patient could open her eyes. Due to a contusion and bruising, her right eye drooped, but the pupillary light reflex was still present. Overall, her GCS score had improved to 11; therefore, she was transferred to an ordinary ward the same day. After four treatments, she was observed to be making vulgar verbalizations (unconscious), which was indicative of progress. After six treatments, she had a GCS score of 14 and continuous improvement of her overall symptoms; thus, she was transferred to a rehabilitation ward. After nine treatments, she completely regained consciousness and had a GCS score of 15. After 15 treatments, her condition was greatly improved, and she was discharged from the hospital and underwent follow-up therapy as an outpatient. After recovery of responsiveness, she switched to the treatment associated with freeing meridians (Eding zone, Dingnie zone, Fengchi, Taijian, Jianyu, Quchi, Hegu, Baxie, Zusanli, Yanglingquan, and Sanyinjiao) to address her deficit of nerve function. After 45 treatments, the patient completely regained her muscle power and could live independently (Barthel Index score of 100). Eight months after the treatments, she restarted her first year of college study.

Date (sessions)	GCS	Muscle power	Events
2008.05.30 (1)	E1V2M5	1/ 2/ 3 /3	Intensive care ward, Dept. of Neurosurgery
0602 (2)	E4V2M5	1/ 2/ 3/ 3	Ordinary ward, Dept. of Neurosurgery
0611 (6)	E4V4M6	2/ 3/ 4/ 4	Rehabilitation ward
0618 (9)	E4V5M6	2/ 3/ 4/ 4	
0620 (10)	E4V5M6	4/ 3/ 4/ 4	
0705 (15)	E4V5M6	4/ 3-4/ 4-5/ 4-5	Discharged from hospital
1222 (45)	E4V5M6	5/ 5/ 5/ 5	Outpatient; Barthel Index: 100

Table 2. Acupuncture therapeutic sessions for a patient with traumatic brain injury

3.2.3 Acupuncture therapy - freeing meridians

We used the same acupuncture treatment for all patients who recovered from consciousness disorders but still displayed neurologic impairments, regardless of the individual etiology of the disorder. The following acupuncture points were used: Eding zone, Dingnie zone, Fengchi, Taijian, Jianyu, Quchi, Hegu, Baxie, Zusanli, Yanglingquan, and Sanyinjiao. The application of needles to Eding and Dingnie zones was the same as described previously except that the retention time was 30 min. Stainless steel filiform needles with a diameter of 0.26 mm and length of 40 mm were inserted into Quchi, Zusanli, Yanglingquan, and Sanyinjiao; stainless steel filiform needles with a diameter of 0.26 mm and length of 25 mm

were inserted into Fengchi points on two sides, as well as Taijian, Jianyu, and Hegu; stainless steel filiform needles with a diameter of 0.26 mm and length of 13 mm were inserted into Baxie. The needles were twisted, slightly lifted, and re-inserted to obtain Qi. In Jianyu, Quchi, Hegu, Yanglingquan, and Zusanli, this needling technique was followed by being connected to an electrical stimulator (Model-05B; Ching-Ming Medical Device Co., Taipei, Taiwan). Electricity was generated as an output of programmed pulse voltage at 1.2 Hz with a regular wave, 390-ms square pulse at a maximal tolerable intensity of 500 Ω (12–18 V; a strong but not painful sensation for the patient). The electroacupuncture was applied for 30 minutes to maintain the therapeutic effect.

GB20: Fengchi. In the anterior region of the neck, inferior to the occipital bone, in the depression between the origins of sternocleidomastoid and the trapezius muscles. (Fig. 3) (WPRO, 2009)

Taijian (Ex-UE23). 1 ½ cun below the tip of the acromion. (Fig. 3) (GMRLWB, 1970)

LI15: Jianyu. On the shoulder girdle, in the depression between the anterior end of lateral border of the acromion and the greater tubercle of the humerus. (Fig. 4) (WPRO, 2009)

LI11: Quchi. On the lateral aspect of the elbow, at the midpoint of the line connecting LU5 with the lateral epicondyle of the humerus. (Fig. 4) (WPRO, 2009)

LI4: Hegu. On the dorsum of the hand, radial to the midpoint of the second metacarpal bone. (Fig. 4) (WPRO, 2009)

Baxie (EX-UE 9). When a loose fist is made, the points are on the dorsum of the hand, proximal to the margins of the webs between all five fingers, at the junction of the red and white skin. Both hands altogether have a total of eight points. (Fig. 2) (Yang, 2000)

ST36: Zusanli. On the anterior aspect of the leg, on the line connecting ST35 with ST41, 3 B-cun inferior to ST35. (Fig. 5) (WPRO, 2009)

GB34: Yanglingquan. On the fibular aspect of the leg, in the depression anterior and distal to the head of the fibula. (Fig. 5) (WPRO, 2009)

SP6: Sanyinjiao. On the tibial aspect of the leg, posterior to the medial border of the tibia, 3 B-cun superior to the prominence of the medial malleolus. (Fig. 5) (WPRO, 2009)

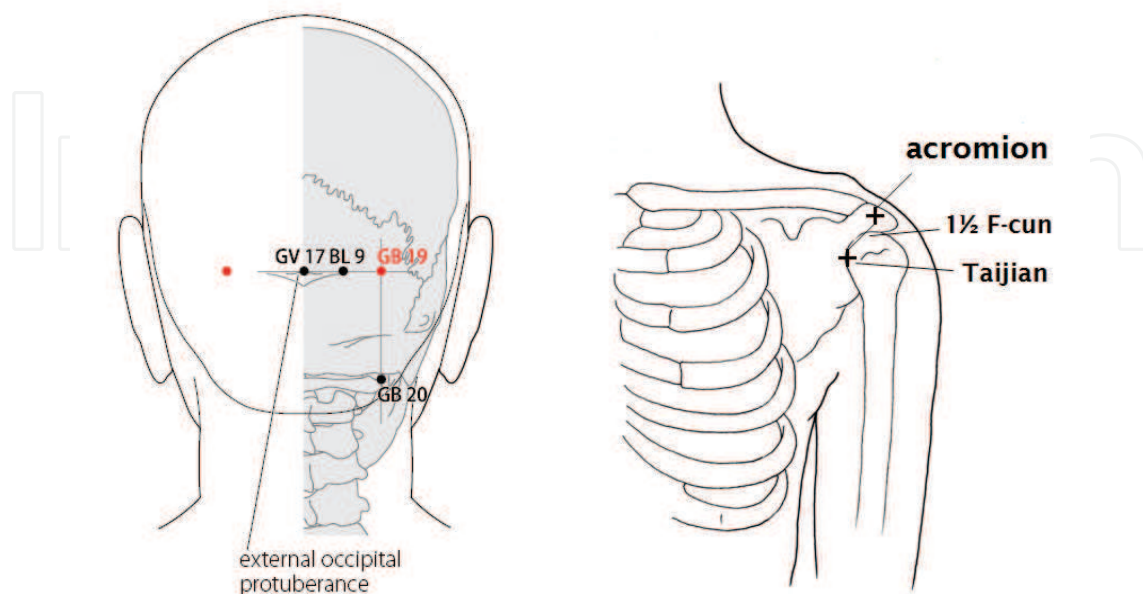


Fig. 3. GV17, GB19, GB20 (WPRO, 2009) & Taijian

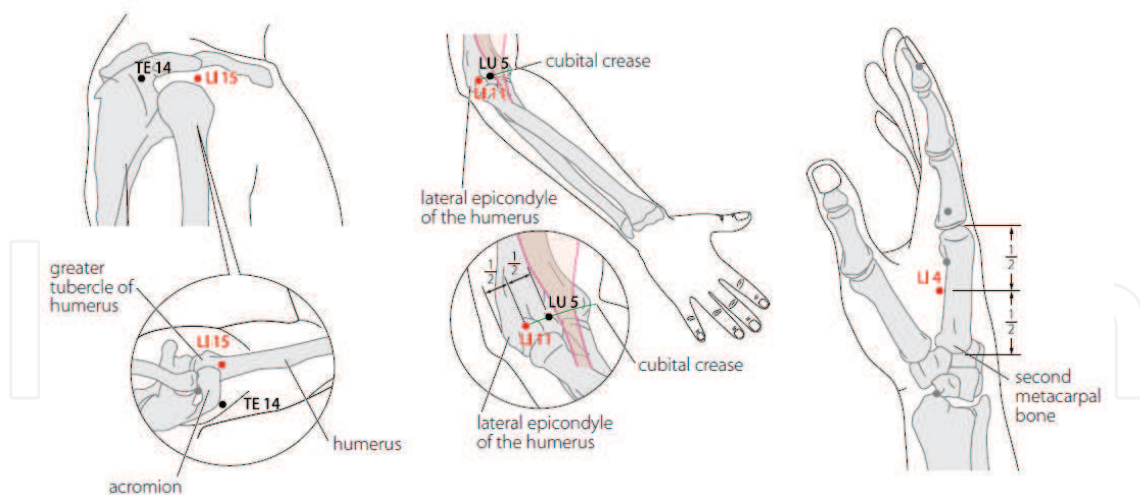


Fig. 4. LI15, LI11 & LI4 (WPRO, 2009)

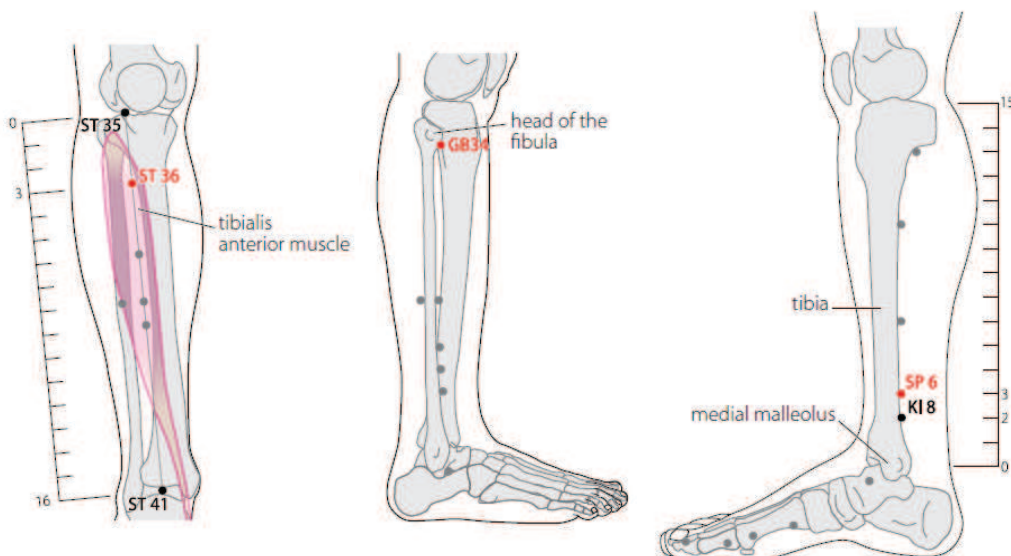


Fig. 5. ST36, GB34 & SP6 (WPRO, 2009)

3.3 Hypoxic-ischemic encephalopathy

3.3.1 History and examination

A 39-year-old female with a history of hyperthyroidism had been regularly undergoing Western medicine treatments to control the symptoms. She had an obstetric history of G5P2A2. On June 16, 2005, after a full-term pregnancy, she gave birth to a baby boy (natural birth). Subsequently, she suffered postpartum hemorrhage (ca. 2500 cc) due to atonic uterus and underwent hysterectomy. During the operation, she developed shock caused by dropped blood pressure and was subjected to cardiopulmonary resuscitation along with transfusion and intubation. After the initial first-aid procedures, the patient was transferred to the emergency ward of our hospital for further treatment. She was then transferred to an intensive care ward in the Department of Neurosurgery. The next day, it was discovered that she had developed pulmonary edema and hemopneumothorax; thus, she was subjected to chest intubation and drainage. During this period, the patient received a large number of

transfusions and tapered the administration of the vasopressor, but she remained in a coma and was dependent on a ventilator. Afterwards, the patient developed pneumonia, empyema, and infections in the vagina, urinary tract, and central venous catheter. For these infections, she was treated with antibiotics. Although neither brain CT scan nor brain MRI detected any apparent damage, she remained unconscious. On June 27, the patient was transferred to an intensive care ward in the Department of Internal Medicine. On the next day, she was weaned from the ventilator and extubated. On June 29, with a GCS score of 8, she underwent a consultation and began acupuncture treatment.

3.3.2 Treatment (Table 3)

On June 30, the patient was transferred to a ward in the Department of Gynaecology and Obstetrics. After five acupuncture treatments, she gradually regained consciousness and had a GCS score of 12 but occasionally complained of blindness. The Nao-Sanzhen (Naohu and Naokong; Figure 3, "Jin-Sanzhen" technique) (Yuan et al., 2005) was used for her blindness. After eight treatments, she completely recovered consciousness, and her overall condition was greatly improved. Thus, she was discharged from the hospital and underwent follow-up therapy as an outpatient. After recovery, she switched to the treatment of freeing meridians to resolve her impaired nerve function. After 21 treatments, the patient recovered her visual perception. After 40 treatments, she completely regained her muscle power, could live independently, and had a Barthel Index score of 100.

GV17: Naohu. On the head, in the depression superior to the external occipital protuberance. (Fig. 3) (WPRO, 2009)

GB19: Naokong. On the head, at the same level as the superior border of the external occipital protuberance, directly superior to GB20. (Fig. 3) (WPRO, 2009)

Date (sessions)	GCS	Muscle power	Events
2005.06.29 (1)	E4V2M2	0/ 0/ 0/ 0	Intensive care ward, Dept. of Internal Medicine
0630	E4V2M2	0/ 0/ 0/ 0	Ward in Dept. of Gynaecology and Obstetrics
0708 (5)	E4V2M6	0/ 2/ 0/ 2	Blindness
0718 (8)	E4V5M6	2/ 3/ 2/ 3	Discharged from hospital
0808 (15)	E4V5M6	3/ 3/ 3/ 3	Outpatient treatment
0826 (21)	E4V5M6	4/ 4/ 4/ 4	Regained eyesight
2006.01.20 (40)	E4V5M6	5/ 5/ 5/ 5	Barthel Index: 100

Table 3. Acupuncture therapeutic sessions for a patient with hypoxic-ischemic encephalopathy

3.4 Hypoxic encephalopathy

3.4.1 History and examination

We treated a 68-year-old female with a history of various diseases including diabetes, hypertension, chronic renal failure, congestive heart failure, atherosclerosis, and osteoporosis. On April 13, 2006, the patient suffered general weakness, pain in the right

limbs, and dyspnea and was therefore admitted into our hospital. Subsequently, she developed chest pain, which radiated into her back and was suspected to be caused by dissection of an aortic aneurysm. However, no obvious lesion was detected by chest CT scan. The patient also clearly displayed worsening renal function (BUN: 161.6 mg/dl; Cr: 10.24 mg/dl); thus, she was subjected to emergency hemodialysis. During the dialysis, the patient occasionally exhibited delirium, which improved after a short period. Afterwards, she was transferred to a ward in the Department of Nephrology. Around May 5, the patient showed poor glycemic control. Given her leukocytosis symptoms, infection was suspected, and she was given prophylactic antibiotic treatment. Correspondingly, her arteriovenous fistulization operation was postponed. On May 10, she suffered gouty arthritis on the first right toe and was treated with colchicine. On the same day, she underwent the arteriovenous fistulization procedure. The next day, she experienced choking when having her lunch, which developed into acute respiratory failure; she then received emergency intubation and was subsequently placed on a ventilator. A high level of food residue was found in her endotracheal tubes. After a 5-min treatment of cardiopulmonary resuscitation, the patient's heart rate was recovered, but she remained unconscious. Subsequently, she was transferred to an intensive care ward in the Department of Internal Medicine and received antibiotic treatment. At the same time, she received bronchoscopy, which identified rice grains and minor bleeding in her left lung. The brain CT scan did not reveal any apparent lesion. On May 18, ventilator weaning was attempted but was unsuccessful due to respiratory failure. On May 23, with a GCS score of 3, she underwent a consultation and began acupuncture treatment.

3.4.2 Treatment (Table 4)

On June 1, the patient remained in respiratory failure and was transferred to a respiratory intensive care ward. On June 2, she received a tracheotomy and had a GCS score of 3. On June 10, she was weaned from the ventilator and had a GCS score of 7. Three days later (the 10th acupuncture treatment), she regained consciousness (GCS of 11) and was transferred to a ward in the Department of Nephrology. On June 18, the patient developed a sudden dyspnea after hemodialysis, which was identified as respiratory failure resulting from sepsis. She was then re-connected to a ventilator and had a GCS score of 6. On June 22, she was weaned from the ventilator and had a GCS score of 6. On June 29 (the 17th treatment), the patient recovered consciousness (GCS of 11), and she had not developed any symptoms of fever or chill over the previous two weeks. However, she still had leukocytosis and emergence of hypotension during hemodialysis, both of which were indicative of sepsis. Thus, the antibiotic treatment was continued. On July 3, with a GCS score of 11, the patient exhibited upper gastrointestinal bleeding and was transfused with concentrated red blood cells during hemodialysis. On July 6, with a GCS score of 11, she displayed paroxysmal supra-ventricular tachycardia during hemodialysis, after which she occasionally exhibited atrial fibrillation with a rapid ventricular response. On July 8, with a GCS score of 11, the patient again developed a fever, and the blood culture revealed an infection of *Candida albicans*. On July 15, she exhibited dyspnea and tachycardia; the electrocardiography revealed ST elevation and T-wave changes in V2-V6. In addition, she was also found to harbor high levels of myocardial enzymes and develop hypotension and was assumed to have developed an acute myocardial infarction. Thus, she was transferred to a cardiac intensive care ward. Concurrently, she also suffered bronchopneumonia and had a GCS

score of 5. On July 22 (the 27th treatment), with a GCS score of 9-11, she was successfully weaned from the ventilator. Three days later, she was transferred to a ward in the Department of Cardiology. Afterwards, the patient received hemodialysis on Monday, Wednesday, and Friday every week, during which she occasionally exhibited hypotension. In addition, she had poor wound healing in her left leg, which was accompanied by fever. On August 18, with a GCS score of 9-11, she received debridement and antibiotic treatment. On September 2 (the 45th treatment), the patient regained consciousness and her condition was improved. She was therefore discharged from the hospital and transferred to an elderly center for recuperation.

Date (sessions)	GCS	Muscle power	Events
2006.05.23 (1)	E1VeM1	0/ 0/ 0/ 0	Intensive care ward, Dept. of Internal Medicine; on a ventilator
0601 (5)	E1VtM1	0/ 0/ 0/ 0	Respiratory Intensive Care ward, tracheotomy
0608 (8)	E3VtM1	0/ 0/ 0/ 0	
0610 (9)	E3VtM1	0/ 0/ 0/ 0	Ventilator weaning
0613 (10)	E4VtM6	0/ 0/ 3/ 0	Ward in Dept. of Nephrology
0618 (12)	E3VtM2	0/ 0/ 2/ 0	Sepsis, respiratory failure, on a ventilator
0622 (14)	E3VtM2	0/ 0/ 2/ 0	Ventilator weaning
0629 (17)	E4VtM6	2/ 0/ 3/ 0	
0715 (24)	E3VtM1	0/ 0/ 0/ 0	Cardiac Intensive Care ward, acute myocardial infarction, on a ventilator
0722 (27)	E3-4VtM5-6	2/ 0/ 3/ 0	Ventilator weaning, ward in Dept. of Cardiology
0902 (45)	E4VtM6	2/ 0/ 3/ 0	Discharged from hospital

Table 4. Acupuncture therapeutic sessions for a patient with hypoxic encephalopathy

3.5 Post-partum eclampsia

3.5.1 History and examination

We treated a 30-year-old female who had been healthy and had an obstetric history number of G2P0A1. On July 2, 2009, at 39⁺⁵ weeks of pregnancy, her amniotic sac broke, and she was sent to another hospital via ambulance for delivery. Due to the prolonged labor, a caesarean section was suggested and performed by her gynecologist the next day. During the surgery, spinal anesthesia was performed and a 2600-g baby girl was born. Subsequently, a chocolate cyst on her left side was removed, and the wound was sutured after a drainage tube was placed. Her condition was stable and she was conscious, so she was sent to a ward to rest. However, the patient experienced chest discomfort and palpitations the next morning. At that time, the nurses first gave her oxygen and notified the doctors for treatment. Her blood pressure was 150/100 mmHg, her pulse was 120/min, and her respiration rate was 17/min. When the attending physician arrived, 5% glucose water and magnesium sulfate drips were administered. Afterwards, the doctor suggested to the patient's family members that she should be transferred to our hospital for further treatment. Laboratory examination showed 15400 leukocytes, protein in the urine (+), occult blood (+), and IgE of 129 IU/ml. Before the ambulance arrived, the patient had already exhibited clasped hands, trismus, and mild

convulsions. Doctors from that hospital then gave 1 Amp of valium and 20 ml of 20% G/W by intravenous injection. After the administration, the patient could not speak but was able to nod when questioned. In addition, after an infusion of 500 ml D5W + 2 Amp drips of MgSO₄, the patient was subsequently transferred to our hospital for treatment. Upon arrival, the patient showed changes in consciousness, a body temperature of 38.3°C, blood pressure of 158/71 mmHg, a heart rate of 110 bpm, and a GCS score of E2V2M2. Therefore, emergency physicians first had her intubated to establish an airway, followed by a series of imaging examinations, including a brain CT scan and chest X-ray, but nothing notable was detected. ECG showed sinus tachycardia, while EEG indicated widespread cortical dysfunction. Antiepileptic drugs were administered but were ineffective. Instead, the patient suffered from consistent convulsions. Under status epilepticus along with eclampsia, she was assumed to suffer malignant hyperthermia and was transferred to an intensive care ward for further treatments. On July 6, the patient developed rhabdomyolysis, acute renal failure, systemic edema, and pulmonary edema, and she underwent emergency hemodialysis. Brain MRI showed extensive vasculitis, and she had a GCS score of 3. Two days later, she was found to have hypotension and disseminated intravascular coagulation. Thus, antibiotic treatment was given. Meanwhile, the patient exhibited a drug-related rash, and alternative antiepileptic drugs were provided. On July 13, with a GCS score of 3, she underwent a consultation and began acupuncture treatment.

3.5.2 Treatment (Table 5)

After three acupuncture treatments, the patient could open her eyes naturally. After eight treatments, she was weaned from a ventilator and extubated, and she had a GCS score of 9.

Date (sessions)	GCS	Muscle power	Events
2009.07.13 (1)	E1VeM1	1/ 1/ 1/ 1	Intensive care ward, status epilepticus, acute respiratory failure, acute renal failure, sepsis, on a ventilator
0714	E2VeM1	1/ 1/ 1/ 1	
0718 (3)	E3VeM1	1/ 1/ 1/ 1	
0719	E4VeM2	1/ 1/ 1/ 1	
0720 (4)	E4VeM3	1/ 1/ 1/ 1	
0729 (8)	E4V1M4	1/ 1/ 1/ 1	Ventilator weaning and extubation
0802 (10)	E4V2M5	2-/ 2-/ 2/ 2-	Ward in Dept. of Neurology, pneumonia and urinary tract infection detected the next day
0817 (16)	E4V2M6	2-/ 2-/ 2/ 2-	
0924 (31)	E4V2M6	2-/ 2-/ 2/ 2-	Rehabilitation ward, urinary tract infection detected after a week
1022 (43)	E4V2M6	3/ 3/ 3/ 3	Discharged from hospital

Table 5. Acupuncture therapeutic sessions for a patient with postpartum eclampsia

On August 2, with conditions continuing to improve and a GCS score of 11, she was sent to a ward in the Department of Neurology. The next day, the patient developed pneumonia and a urinary tract infection, and she had a GCS score of 11; antibiotic treatment was given. Afterwards, her condition continued to improve, except that her limbs were still weak, and her consciousness remained unstable. Her husband claimed that she could recognize acquaintances. Subsequently, because of anemia, transfusion therapy was administered. Afterwards, she suffered an allergic reaction and hematuria, and hemodialysis was immediately arranged. After hemodialysis, the patient stabilized and her renal function returned to normal. On August 17 (the 16th treatment), the patient regained consciousness, but she could not speak fluently due to vocal cord paralysis and had a GCS score of 12. On September 24, the patient was moved into a rehabilitation ward and had a GCS of score 12. After 1 week, she developed a urinary tract infection; thus, antibiotics were given (a GCS score of 12). On October 22 (the 43rd treatment), her condition had improved and she was therefore discharged.

4. Discussion and conclusion

Brain damage can result in the production of inhibitors, including γ -aminobutyric acid (GABA), which generates a response resembling automatic shutdown. The purpose of this response is probably to conserve energy and promote cell survival. However, this also causes a comatose state (Clauss & Nel, 2006). Therefore, any treatment affecting the reticular activating system may be worth trying, and among the possible treatments, acupuncture has the most potential.

Traditional Chinese medical science suggests that consciousness disorders are caused by a disruption of Yin and Yang, which results in blocking of blood and Qi and causes brain dystrophy. Unconsciousness usually involves syndrome of block or syndrome of collapse. Syndrome of block is characterized by unconsciousness, trismus, clasped hands, red face, rough breathing, and other features. In general, the syndrome of block, such as heat-toxin, phlegm, internal wind, and stasis, leads to an imbalance of Yin and Yang and unconsciousness. Syndrome of collapse has the characteristics of unconsciousness, cold limbs, sweating, closed eyes, opened mouth, snoring, opened hands, and urinary incontinence. Syndrome of collapse includes blood and Qi depletion, Yin and Yang failure, incompatible maintainability, and orifice dystrophies (Wang & Dong, 2007; He et al., 2005). The consciousness strategies in this article use Twelve Well points connecting the meridian Qi of three yins and three yangs. The Governor Vessel is the head of all yang meridians. Eding zone and Renzhong can be used to regulate the Governor Vessel and release the Qi of yang hyperactivity. Liver meridian intersects at the parietal. Eding and Dingnie zones can be used to regulate the meridian Qi of the liver and gall bladder and to extinguish wind and subdue yang. Thus, this strategy can pacify the liver to extinguish wind, regulate Yin and Yang, and promote consciousness (Yang, 1601). In the procedure of freeing meridians, Eding zone, Dingnie zone, and Fengchi pacify the liver and subdue Yang. Quchi and Hegu are the He point and Yuan point of the large intestine meridian, Quchi is not restricted to one place, and Hegu can rise and spread. These two points work together to regulate the meridian Qi and promote blood flow and are therefore able to cure paralyzed upper limb. Zusanli raises Yang and stimulates the stomach to increase Yang. Sanyinjiao strengthens the spleen and Yin blood. Yanglingquan, the point of conjunction of the sinews, relaxes sinews and benefits joints. The combination of three points tonifies Qi and replenishes blood, dispels wind, and

dredges collaterals, thus curing paralyzed lower limb (Dai, 1978). The Nao-sanzhen can provide pulp and stimulate the brain to resolve blindness (Yuan & Luo, 2004).

In studies that have examined the use of acupuncture for the treatment of stroke, body acupuncture accounts for 38.54%, scalp acupuncture accounts for 10.42%, the combination of acupuncture and medical treatment accounts for 12.5%, electroacupuncture accounts for 13.54%, general treatment accounts for 19.79%, moxibustion treatment accounts for 2.08%, and tongue acupuncture accounts for 3.13% (Jin, 2008). Currently, diagnosis and treatment options for cerebral hemorrhage continue to expand, and new treatment strategies continue to emerge, such as minimally invasive treatments for hematoma. However, the recent uses of minimally invasive hematoma treatment or intracerebral hematoma drainage in neurosurgery have not significantly reduced the death or disability rates associated with these diseases. Therefore, the goal is not only to promote the treatment of hematoma, but also to disrupt the process of progressive pathophysiology. Thus, the discussion of treatments for minimizing the death and disability rates of cerebral hemorrhage patients is still one of the most significant topics in neurology (Bai et al., 2010).

4.1 Twelve Well points

The Twelve Well points together comprise one of the Five-Shu points, next to nails. These points are also the origin of Yin and Yang for twelve meridians. The Qi of the meridians intersect at the ends of the extremities, metaphorically like an initial source. The 12 Well points serve the purposes of clearing heat, allaying excitement, prompting Qi, activating blood, and dredging the meridian (Yan & Zang, 2007). Acupuncture on the 12 Well points and exsanguinations can clear the stagnant Qi and blood within the meridians, adjust organs, promote harmony within organs, un-impede meridians, balance blood and Qi, and promote harmony of Yin and Yang, thus serving the purpose of curing the disease. Moreover, this can also greatly regulate the blood system as it promotes human metabolism and increases heart rate, systolic blood pressure, and blood supply to the brain. Through the nerve-body fluid regulation, it improves microcirculation and vascular function, which helps to remove harmful free radicals from the blood. Therefore, for acute cerebral infarction, early intervention of acupuncture on the 12 Well points can significantly ameliorate cerebral ischemia (Teng et al., 2009).

Acupuncture on the 12 Well points in mice with focal cerebral ischemia can reduce the release of tumor necrosis factor- α (TNF- α) and alleviate cerebral ischemic injury caused by TNF- α , and intervention within six hours is the most effective. The mechanism in mice is probably similar to that of early intervention through acupuncture of the 12 Well points in ischemic cerebrovascular disease (Ma et al., 2006). For experimental cerebral ischemic mice, acupuncture on the 12 Well points and exsanguination has been shown to increase blood flow in the ischemic region of the brain. This effectively delays hypoxia in the brain tissues (Ma et al., 2000). When three-edged needles were used on Renzhong, the 12 Well points and Shixuan in mice with experimental cerebral ischemia, an increase of HSP₇₀ (heat shock protein in the brain) messenger ribonuclear acid (mRNA) expression in the cortex and hippocampus was observed in the acupuncture group compared to the control group. This indicates that acupuncture can boost HSP₇₀ mRNA expression in the brain through regulation of calcium channels by HSP₇₀ to achieve nerve protection (Huang, 2008).

Acupuncture on the six Well points of the hands and exsanguination are classical first aid measures in traditional Chinese medicine, and this approach has been used in clinical applications for thousands of years. It has the effects of reducing heat and stasis, increasing blood flow, protecting the brain, and promoting consciousness. Its medical theory is based on Chinese meridian-collateral theory and the qi-blood doctrine. After acupuncture on the six Well points of the hands and exsanguination, the consciousness of stroke patients improves. This is probably due to the effect of acupuncture on the six Well points of the hands and the effect of exsanguination on hemodynamic regulation and biochemical changes in regional cerebral areas. Analysis of GCS changes in patients with cerebral infarction and cerebral hemorrhage who were treated with acupuncture provides clinical evidence for the effectiveness of acupuncture at an early time point following cerebral hemorrhage (Ding & Guo, 2004) (Table 6). Acupuncture on the six Well points of the hands and exsanguination can improve the consciousness of patients with infarct damage of small size and can increase systolic blood pressure, causing the heart rate to accelerate (Guo et al., 2005).

Acupuncture on the six Well points of the hands and exsanguination has shown excellent effects on hemodynamics in rabbits with experimental cerebral ischemia and cerebral hemorrhage. Somatic nerves and autonomic vessel walls are pathways for Well point acupuncture and exsanguination to the center. Receptors of the central adrenaline and choline play important roles (Guo et al., 1997). Acupuncture on the six Well points of the hands and exsanguination can cause an increase in partial O₂ pressure and a decrease in H⁺ concentration in regions of cerebral ischemia in mice. It further eases hypoxia and acidosis due to acute cerebral ischemia (He et al., 2002), adjusts homeostasis of K⁺ and Na⁺ in extracellular fluid, and reduces the development of cytotoxic brain edema (Ma et al., 1997). Acupuncture on the six Well points of the hands and exsanguination provide protection to the brains of patients when applied soon after a stroke. Pricking to draw blood can reduce nitric oxide (NO) concentration, improve nitric oxide synthase (NOS) activity, and reduce damage caused by free radicals on brain tissue (Huang et al., 2006) following cerebral ischemia in mice. Moreover, it can decrease the malondialdehyde (MDA) concentration, increase super oxide dismutase (SOD) activity, clear free radicals, and reduce lipid peroxidation (Huang et al., 2005). It can significantly increase HSP₇₀ expression in an ischemic brain cortex, further enhance the protection of brain tissue against anti-ischemic injury, prohibit additional development of ischemic brain damage, and strengthen the ability of brain repair (Wang et al., 2005). In addition, it can improve the responsive ability of nerve cells by elevating c-fos (cellular proto-oncogene fos) protein concentration in the ischemic region, thus improving the brain's ability to repair itself, reducing neuronal apoptosis, and protecting the brain from further ischemic damage (Wang et al., 2004). Finally, it inhibits the entry of extracellular Ca²⁺ into cells, decreases raised excitatory amino acid (EAA) and NO concentrations after cerebral ischemia, reduces neurotoxicity, and improves the prognosis (Ren et al., 2001a; 2001b).

4.2 Scalp acupuncture combined with body acupuncture

Because the four limbs have wide distributions within the cerebral cortex, the Well points can strongly stimulate brain function. If diseases occur in the head, Baihui, or Sishencong, which are closer to the precentral gyrus, acupuncture can directly stimulate the functions of the central motor and sensory nervous systems (Chen et al., 2009). Because Shuigou is the

point of intersection for Shouyangming, Zuyangming, and the Governor Vessel, it is an essential point for first aid. Acupuncture on Shuigou can promote consciousness and restore resuscitation. Mechanical stimulation caused by acupuncture leads to the expedition of systemic blood circulation, affects blood supply to the brain, increases collateral circulation, strengthens oxygen supply capacities in various brain tissues, eliminates edema around the necrotic tissue, saves endangered dysfunctional neurons, promotes proliferation of astrocytes, and increases repair to promote the patient's consciousness and reduce the incidence of complications and mortality (Shan et al., 2002). When the patient's condition stabilizes, acupuncture can improve lesions caused by ischemic hypoxia by the regulation of excitement levels in the brain stem and cerebral cortex through nerve conduction, which gradually returns the excitation and inhibition processes to normal, thus promoting consciousness (Bi, 2004; Wu et al., 2003).

A previous report showed that nine days after an operation for hypertensive intracerebral hemorrhage, the patients in the acupuncture groups were provided with both acupuncture and Western medical treatment. The use of Xingnao Kaiqiao acupuncture at the base and scalp supplemented traditional body acupuncture; the result was significantly better than that of the control group (Li et al., 2006). The application of this combination of acupuncture promotes NO formation in the blood and brain tissues, increases NO concentration, ameliorates microvascular self-improvement movement, improves circulation, elevates SOD activity, and decreases lipid peroxide (LPO) concentration, thereby reducing the oxidative damage to the brain tissue, decreasing the cellular influx of calcium, improving calcium overload in brain tissue, benignly regulating the abnormal metabolism of neurotransmitters in the central nervous system, and reducing necrosis and apoptosis of brain cells (Ding & Shi, 2004). Scalp acupuncture therapy is based on functional areas of the cerebral cortex; it directly stimulates the intersections of all Yangs, "places where meridian passed, treatments thereby can be reached." The anterior oblique line of the parieto-temporal is equivalent to the cerebral cortex on the precentral gyrus's projection of the scalp; therefore, directly stimulating this area can improve cerebral blood circulation and increase oxygen saturation so that the corresponding area of the cerebral blood flow in ischemic disorders can be improved. Brain cells that are hibernating or in shock as a result of hemorrhagic focal constriction or inhibition of excitation can quickly restore their excitability (Zhu, 2000). Scalp acupuncture by Guirong Dong (Dong et al., 1990) first challenged the notion that scalp acupuncture cannot be used for acute hemorrhagic stroke. No matter which types of acupuncture are used, all acupuncture increases the expression of HSP₇₀ mRNA to promote the expression of HSP₇₀ protein, thus stimulating the protection and repair of neurons (Zhao et al., 2004).

4.3 Xingnao Kaiqiao acupuncture

After many years of study, Xuemin Shi established Xingnao Kaiqiao, or XNKQ (resuscitating), acupuncture using Neiguan as the main point to regulate the spirit of the whole body (Shi, 1998). Neiguan is a luo point on the Jueyin Pericardium meridian. It connects to the Yinwei vessel and is one of the eight intersection points of the vessels. Acupuncture on Neiguan can promote calmness and regulate blood circulation. Shuigou, one of the Governor Vessels, is an important point for consciousness, and it is a combined point of Shouyangming and Zuyangming. The Governor Vessel, the sea of the Yang meridians, begins in the cells and flows upward to the brain, and it has a close relationship

with the brain and other organs. Therefore, Shuigou serves as a gateway. Sanyinjiao is the point of intersection for the three yin meridians. Acupuncture on this point regulates the kidney, liver, and spleen (Ma et al., 2006).

Neiguan and Quze are both critical points on the Jueyin Pericardium meridian of the hands. Electroacupuncture on these points, combined with Western treatments, can help patients to regain consciousness earlier, and it reduces complications for some patients (Fu et al., 2009). Continuous electroacupuncture on Neiguan can indirectly excite the median nerve; cause excitements in the brain stem, reticular formation, hypothalamus, and other structures; lift non-specific inhibition of the ascending activation system; and improve the patient's consciousness. Electrical stimulation can also affect autonomic nerves through spinal nerve traffic signals. It increases the oxygen supply by adjusting the cardiac function and respiratory activities. The distal projection is the largest in the cerebral cortex, and it therefore has a greater afferent effect and a greater impact on the cerebral cortex, which may help patients to regain consciousness and neurological functions (Wei et al., 2007). Furthermore, acupuncture on Shuigou and Yintang can also increase the oxygen supply to the brain, improve the nutritional status, and increase the excitability of neurons (Teng, 2000). Electroacupuncture can increase the activity of Na^+ , K^+ , Mg^{2+} , and Ca^{2+} -ATP enzymes in brain injury patients, reduce calcium overload, prevent secondary damage to nerve cells, improve abnormal blood vessel contraction, reduce spasm and abnormal platelet aggregation, increase the concentrations of dopamine, epinephrine, and norepinephrine, elevate adrenergic nerve activity, and enhance the metabolism of central norepinephrine to promote metabolism in the cerebral cortex. Furthermore, it can inhibit the production of endothelin, reduce MDA content, reduce free radical reactions, reduce reperfusion injury in brain tissue, and it can protect the blood-brain barrier, delay and reduce the formation and development of cerebral edema, and promote functional recovery of the penumbra and brain functions (Zhao et al., 2003; Zhou et al., 1991; Luo et al., 1987; Liu & Zhao, 2003). Neiguan contains cutaneous nerves in the forearms. Beneath it is a palmar cutaneous branch of median nerves. The deepest layer distributes forearm volar interosseous nerves, and Quzhe is passed by the median nerve stem (WPRO, 2009). Electroacupuncture median nerve stimulation (MNS) is currently an internationally recognized strategy to treat traumatic coma. The introduction of a low-frequency current in the median nerve distribution area can increase blood circulation in the brain, reduce cerebral edema in the necrotic area, and promote the secretion of neurotrophic substances. Moreover, by restricting the release of β -endorphin in coma patients, it inhibits the increase of intracranial pressure, saves the dying neurons, and promotes consciousness (DeFina et al., 2010; Xu, et al., 2004; Xu & Wang, 2006). The mechanisms of consciousness promotion with electroacupuncture of Neiguan are probably related to MNS. The effects of electroacupuncture are more precise in patients with diffuse axonal injury (Peng et al., 2010). This is probably due to the regulation of Bcl-2 (inhibits apoptosis) and Bax (promotes apoptosis) gene expression (Li et al., 2003), which stimulate the occurrence of new collateral axons and establish new axon contacts (Wu et al., 1998).

XNKQ acupuncture can effectively improve the flexibility of the red blood cells during reperfusion. This plays a significant role in maintaining the normal operation of microcirculation, maintaining the levels of material and energy metabolism, and promoting the functional recovery of nerve cells (Hu et al., 1995). Furthermore, it also can regulate glycoside fat concentrations in the ganglion of the brain for protection and promotion of

nerve reconstruction, which facilitates the improvement of consciousness disorders (Wang et al., 2004). XNKQ acupuncture can be used on Baihui, Shuigou, Yongquan, Laogong, and Fengchi, which are traditional treatment points for consciousness. Through acupuncture at the previously mentioned points, light insertion and heavy extraction are the main strategies for strong stimulation. Applying G6805 electrical therapeutic equipment to give a dense wave of electrical stimulation can help improve the metabolism of brain cells, initiate the consciousness-related functions of the reticular formation, significantly reduce the duration of consciousness disorders, and promote consciousness in coma patients (Liu et al., 2010). Acupuncture on the Shuigou point can efficiently reduce the infarction area of MCAO mice after cerebral ischemia, and it has a point-specific advantage. An appropriate acupuncture frequency (180 times/minute) and duration (5 seconds) can significantly reduce the infarction area (Wei et al., 2010).

Acupuncture can mitigate cerebral vasospasm, improve blood flow in damaged areas, promote the establishment of effective collateral circulation to reduce cerebral edema and high intracranial pressure, and promote the creation of brain cell metabolism. Meanwhile, it activates the function of the brain stem reticular system and increases the excitability of nerve cells so that the inhibited brain cells can re-emerge. Acupuncture on Shuigou can improve the oxygen supply to brain tissues and adjust the catecholamine concentration so that the sympathetic nerve can reach a relatively stable state (Zhang & Liu, 2010). Based on the effects of acupuncture on SOD activities in ischemic stroke patients, it appears that acupuncture can improve the activity of SOD, allow the body to eliminate free radicals effectively, strengthen the body against excessive reactive oxygen species attacks, reduce damage to brain tissue, and promote the metabolism of brain tissue to facilitate body recovery (Zhou et al., 1993). Acupuncture on Neiguan can increase cerebral perfusion and improve cerebral circulation (Shi et al., 1998). Through the observation of a transcranial Doppler, it has been shown that acupuncture on Baihui expedites the flow velocity of the middle cerebral artery, decreases vascular resistance, and increases cerebral blood volume (Liu et al., 1996).

XNKQ acupuncture can bidirectionally regulate hemodynamic parameters of acute stroke patients to assist cerebral blood flow, increase SOD activity, reduce LPO concentration, mitigate brain tissue damage, elevate the PGI₂/TXA₂ (prostacyclin/ thromboxane A₂) ratio, and reduce the chance of thrombosis to advance brain tissue recovery (Shi, 2005). XNKQ acupuncture can ameliorate brain cell metabolism in cerebral infarction patients, stimulate the regeneration of brain cells after damage, and enhance the recovery of cerebral function (Shen & Shi, 2010). Acupuncture can notably reduce the difference in oxygen saturation between the arteries and the internal jugular bulb in acute cerebral ischemia patients, decrease the rate of cerebral oxygen uptake, and strengthen the tolerance of brain to ischemia and hypoxia, thus maintaining the balance of oxygen supply and demand and protect the brain in severe brain injury patients (Shen & Shi, 2009). XNKQ acupuncture has had positive regulation on neuropeptide Y and calcitonin gene related protein in patients' plasma. Moreover, it can also be used for treating acute cerebral infarction, and early intervention can yield a better clinical outcome. Proteomics studies have shown that XNKQ acupuncture uses multiple mechanisms, targets, and levels to fully treat cerebral ischemic stroke (Shi, 2006). When XNKQ acupuncture was first developed, it was mainly used to treat strokes involving limb paralysis, urination disorders, stress ulcers, arrhythmia, diabetes, and other complications and comorbidities. Whether XNKQ acupuncture has more

advantages compared to other types of acupuncture with respect to reducing the occurrence of complications will require further studies (Wu et al., 2008).

4.4 Conclusion

An experienced doctor can use acupuncture to augment consciousness disorder treatment. For patients with consciousness disorders from different causes, restoring consciousness acupuncture is used for treatment, and it provides satisfactory results. Our experience shows that several factors affect the recovery of people with consciousness disorders due to brain damage: 1. level of brain tissue damage – acupuncture is not an efficient treatment for patients with severe damage; 2. infections such as pneumonia, urinary tract infections, bedsores, and sepsis lead to poor results; 3. completeness of treatment – the effects are not significant enough for patients with interrupted treatment, regardless of regular Western treatment, therapy, or traditional Chinese treatment; 4. disease duration – patients who have certain diseases for more than three months have poor results or need longer treatments; 5. age – younger patients yield better results; and 6. psychological factors – patients who are optimistic improve faster than patients with who are depressed. Treating consciousness disorders requires care from various people, including neurologists, neurosurgeons, Chinese medicine practitioners, psychologists, dietitians, psychiatrists, family members, and friends. Patients benefit from a comprehensive treatment plan that further prevents the occurrence of complications. If Western and Chinese treatments are combined, the best potential outcomes can be achieved, expediting and boosting the efficacy of treatment, which decreases medical costs.

Condition/study	No.	Design	Test group	Control group	Results
Infarction, intracerebral hemorrhage (Ding & Guo, 2004)	99:76	Random control	Add acupuncture on Twelve Well points and exsanguinate	Regular Western treatment	GCS score changes after 80 minutes: test group 0.31 ± 0.07 ; control group -0.14 ± 0.05
Ma et al., 2006	46:45	Case control	Add main points: Neiguan, Renzhong, Sanyingjiao; auxiliary points: Jiquan, Weizhong, Chize	Regular Western treatment	Consciousness rate after 10 days of treatments: test group 54.35%; control group 33.33% Consciousness rate after 20 days of treatments: test group 73.91%; control group 53.33%

Condition/study	No.	Design	Test group	Control group	Results
Shi, 2005	9005	Case series	Main Points: Neiguan, Renzhong, Sanyingjiao; auxiliary points: Jiquan, Weizhong, Chize		Recovery: 59.27%; valid: 23.15%; Improved: 16.14%; invalid: 0.44%; death: 1.0%
Intracerebral hemorrhage Wang, 2008	30:30	Random control	Add consciousness point, Yongquan, Shuiquou, Taichong, Quchi	Regular Western treatment	Consciousness time and rate after 30 days: test group 33.00± 5.00 days, 80%; control group 80.00± 4.00 days, 60%
Intracerebral hemorrhage postoperative Li et al., 2006	50:50	Random control	Add XNKQ acupuncture (Neiguan, Shuigou, Sanyingjiao, Baihui, Fengchi, etc.); Scalp acupuncture (parieto-temporal anterior and posterior oblique line); Body Acupuncture (Chengjiang, Jiansanzhen, Shousanli, Zusanli, etc.)	Regular Western treatment	Improvement of neurological deficit: test group 86.0%; control group 14.0%
Traumatic brain injury Peng et al., 2010	29:27	Random control	Add Shuigou, Yintang, Electroacupuncture on Neiguan	Regular Western treatment	Consciousness time and rate after 1 month: test group 18.57± 7.14 days, 72.4%; control group 24.60± 5.00 days, 37.0% After 3 months: test group 25.04± 16.68 days, 86.2%; control group 37.90± 16.94 days, 77.8%

Condition/study	No.	Design	Test group	Control group	Results
Fu et al., 2009	16:16	Random control	Add electroacupuncture on Neiguan and Quze	Regular Western treatment	promoting consciousness rate: test group 25.0% (7 times), 81.3% (30 times); control group 0 (7 times), 43.8% (30 times)
Liu et al., 2010	15:14	Case control	Add electroacupuncture on Baihui, Shuigou, Yongquan, Laogong, and Fengchi	Regular Western treatment	Consciousness time and rate: test group 40.1 days, 73.3%; control group 51.8 days, 28.6%
Bi, 2004	38:22	Case control	Acupunctures: Baihui, Neigun, Qihai, Guanyuan, Zusanli, Siguan, Shuigou, Zhongchong, Sanyinjiao, Laogong, and Yongquan Moxibustion: Baihui, Shenque, Qihai, Guanyuan, Zusanli, Yongquan	Regular Western treatment	Test group: 31 cases restore consciousness, 5 cases with increasing GCS, 2 cases are invalid; control group data are 13, 5, 4, respectively
Consciousness disorders in brain surgery Chen et al., 2009	46:46	Random control	Add acupuncture on Twelve Well points, Shuigou, Baihui, Sishencong, and electroacupuncture on Zhisanzhen	Regular Western treatment	Test group regular recovery rate 80.4%, efficiency 100%, reduces consciousness time; Control group has 32.6%, 91.3%, respectively

Table 6. Summary of acupuncture therapy for consciousness disorders.

5. Acknowledgment

The authors thank Mr Jui-Hsin Chen for help in manuscript preparation.

6. References

Bai, WJ.; Zheng, LQ. & Zhang, ZQ. (2010). Clinical Study on Integrated Tradition Chinese and Western Medicine Stroke Unit on Consciousness Patients with Cerebral


- Haemorrhage. *Journal of Emergency in Traditional Chinese Medicine*, Vol.19, No.10, (October 2010), pp. 1663-1664, ISSN 1004-745X
- Bernat, JL. (2006). Chronic disorders of consciousness. *Lancet*, Vol.367, No.9517, (April 2006), pp. 1181-1192, ISSN 1474-547X
- Bi, JH. (2004). The wake-promoting effects of adjuvant acupuncture on comatose patients post brain injury. *Chinese Journal of Clinical Rehabilitation*, (December 2004), Vol.8, No.34, pp. 7725, ISSN 1671-5926
- Chen, XY.; Zhu, Y. & Huang, XS. (2009). Effect of strong stimulation of acupuncture at twelve Jing-well points as main for neurosurgery patients with disorder of consciousness. *Zhongguo Zhen Jiu*. Vol.29, No.8, (August 2009), pp. 619-622, ISSN 0255-2930
- Clauss, R. & Nel, W. (2006). Drug induced arousal from the permanent vegetative state. *NeuroRehabilitation*, Vol.21, No.1, (May 2006), pp. 23-28. ISSN 1878-6448
- Dai, XM. (1978). *Zhenjiu bingli yanfang 23000*, Qiye Shuju Press, pp. 59-62, Taipei, Taiwan
- DeFina, PA.; Fellus, J.; Thompson, JW.; Eller, M.; Moser, RS.; Frisina, PG.; Schatz, P.; Deluca, J.; Zigarelli-McNish, M. & Prestigiacomo, CJ. (2010). Improving outcomes of severe disorders of consciousness. *Restorative Neurology and Neuroscience*, Vol.28, No.6, (January 2010), pp. 769-780. ISSN 0922-6028
- Ding, J. & Guo, Y. (2004). Effects of pricking blood at twelve Jing points of hand on state of consciousness in the patient of early stroke. *Zhongguo Zhen Jiu*, Vol.24, No.10, (October 2004), pp. 673-676, ISSN 0255-2930
- Ding, J. & Shi, XM. (2004). "Xingnao Kaiqiao" Acupuncture for the treatment of stroke in experimental study. *Chinese Journal of the Practical Chinese with Modern Medicine*, Vol.17, No.4, (February 2004), pp. 1424-1425, ISSN 1607-2286
- Dong, GR.; Guan, LB., Liu, MN.; et al. (1990). Observation on scalp acupuncture for the treatment of 48 cases with acute cerebral hemorrhage. *Zhongguo Zhen Jiu*, Vol.10, No.1, (February 1990), pp. 19, ISSN 0255-2930
- Fu, YY.; Cao, SQ.; Zhuang, JX.; Hu, L.; Chen, DK. & Gu, FJ. (2009). Observation on electroacupuncture combined with routine western medicine therapy for promoting consciousness of the patient with coma caused by craniocerebral trauma. *Zhongguo Zhen Jiu*, Vol.129, No.12, (February 2009), pp. 107-110, ISSN 0255-2930
- Guangzhou Military Region Logistics Weisheng Bu (GMRLWB). (1970). *Changyoung Xinyi Liaofa Shouce*, People's Medical Publishing House, pp. 121, Beijing, China
- Guo, Y.; Hu, LM.; Zhang, YJ.; Wang, XY.; Miao, WF. & Xu, TP. (1999). The dynamic observation of extracellular Ca²⁺ concentration with hand twelve well points bloodletting on experimental cerebral ischemia in rats. *Journal of Clinical Acupuncture and Moxibustion*, Vol.15, No.6, (June 1999), pp. 48, ISSN 1005-0779
- Guo, Y.; Wang, XY.; Xu, TP.; Dai, ZH. & Li, YC. (2005). Effect of blood-letting puncture at twelve well-points of hand on consciousness and heart rate in patients with apoplexy. *Journal of Traditional Chinese Medicine*, Vol.25, No.2, (June 2005), pp. 85-89, ISSN 0254-6272
- Guo, Y.; Zhou, ZL.; Zhou, GP.; Ma, Y.; Wang, XY.; Hu, LM.; Xu, TP. & Zhang, YJ. (1997). First aid of early stroke - Hand twelve Jing points bloodletting on clinical and experimental research. *Shanghai Journal of Acupuncture and Moxibustion*, Vol.16, No.2, (February 1997), pp. 11, ISSN 1005-0957
- He, J.; Wu, B. & Liu, Yi. (2005). Acupuncture treatment for a comatose patient due to severe craniocerebral injury: an evidence-based therapy. *Chinese Journal of Clinical Rehabilitation*, Vol.9, No.13, (April 2005), pp. 110-112, ISSN 1673-8225

- He, SQ.; Guo, YW.; Ma, YF.; Miao F. & Wang XY. (2002). Effects of the Bloodletting of the 12 Hand Jing-Points on the Level of H⁺ in the Brain of the Rats with Cerebral Ischemia. *Journal of Clinical Acupuncture and Moxibustion*, Vol.18, No.2, (February 2002), pp. 43-44, ISSN 1005-0779
- Hoesch, RE.; Koenig, MA. & Geocadin, RG. (2008). Coma after global ischemic brain injury: pathophysiology and emerging therapies. *Critical Care Clinics*, Vol.24, No.1, (January 2008), pp. 25-44. ISSN 1557-8232
- Hu, GQ.; Tian, F.; Li P. & Zhao, LR. (1995). "Xingnao Kaiqiao" acupuncture on cerebral ischemia and reperfusion affecting red blood cell deformability in rabbits. *Tianjin Journal of Traditional Chinese Medicine*, Vol.12, No.4, (August 1995), pp. 31-33, ISSN 1672-1519
- Huang, BL.; Yu LZ. & Cheng J. (2006). Intervention of blood-letting puncture on 12-well points of hand on activity of nitric oxide synthase after focal cerebral ischemia in rats. *Chinese Journal of Clinical Rehabilitation*, Vol.10, No.7, (February 2006), pp. 174-176, ISSN 1671-5926
- Huang, BL.; Yu, LZ.; Liu, SX. & Wang, BH. (2005). The Effects of Blood-letting Puncture in Twelve-well Points of the Hand on Content of MDA and Activity of SOD after Focal Cerebral Ischemia in Rats. *Journal of Xianning College (Medical Sciences)*, Vol.19, No.1, (June 2005), pp. 4-6, ISSN 1008-0635
- Huang, JB. (2008). The Affection of HSP70mRNA in Cerebral Cortex and Hippocampus Part of Experimental Ischemia Rat with Pricking Blood Therapy on Emergency Points. *Journal of Emergency in Traditional Chinese Medicine*, Vol.17, No.6, (June 2008), pp. 811-812, ISSN 1004-745X
- Jennett, B.; Adams, JH.; Murray, LS. & Graham, DI. (2001). Neuropathology in vegetative and severely disabled patients after head injury. *Neurology*, Vol.56, No.4, (February 2001), pp. 486-490. ISSN 1526-632X
- Jin, X. (2008). Literature Research on Acupuncture and Moxibustion Treatment for Stroke. *Chinese Archives of Traditional Chinese Medicine*, Vol.26, No.9, (September 2008), pp. 2016-2019, ISSN 1673-7717
- Kampel, A.; Franz, G.; Aichner, F.; Pfausler, B.; Haring, HP.; Felber, S.; Luz, G.; Schocke, M. & Schmutzhard, E. (1998). The persistent vegetative state after closed head injury: clinical and magnetic resonance imaging findings in 42 patients. *Journal of Neurosurgery*, Vol.88, No.5, (May 1998), pp. 809-816, ISSN 1933-0693
- Li, T.; Zhao, JG.; Tian, GJ.; Zhang, L. & Liu, SJ. (2006). Clinical observation on effect of acupuncture on nervous functions of the patient after operation of hypertensive cerebral hemorrhage. *Zhongguo Zhen Jiu*. Vol.26, No.4, (April 2006), pp. 247-249, ISSN 0255-2930
- Li, ZZ.; Sun, XD.; Zhang, XJ; et al. (2003). Observation on therapeutic effect of integrated treatment of traditional Chinese medicine and western medicine in promoting revival of coma for the patient of severe craniocerebral trauma. *Zhongguo Zhen Jiu*, Vol.23, No.7, (July 2003), pp. 380-382, ISSN 0255-2930
- Liang, QY. (2008). To awake from coma: Progress in disorders of consciousness. *Taiwan Medical Journal*, (October 2008), Vol.51, No.10, pp. 425-429, ISSN 1726-3603
- Liu, C.; Yang, ZQ. & Cui, YM. (1996). The observation of acupuncture on blood flow velocity of middle cerebral artery by digital transcranial Doppler. *Henan Traditional Chinese Medicine*, Vol.16, No.4, (April 1996), pp. 24, ISSN 1003-5028
- Liu, JP.; Yang, ZL.; Wang, MS.; Shi, R. & Zhu, BP. (2010). Observation on therapeutic effect of electroacupuncture therapy for promoting consciousness of patients with coma. *Zhongguo Zhen Jiu*. Vol.130, No.13, (March 2010), pp. 206-208, ISSN 0255-2930

- Liu, Q. & Zhao, YL. (2003). The effects of acupuncture on nitric oxide and endothelin in brain injured rats. *Chinese Archives of Traditional Chinese Medicine*, Vol.21, No.7, (July 1996), pp. 11-14, ISSN 1673-7717
- Luo, HC.; Zhou, DF.; Jia, YK.; et al. (1987). Clinical and Experimental Research of Electroacupuncture Treatment for Depression. *Journal of Peking University(Health Sciences)*, Vol.19, No.1, (February 1987), pp. 45-47, ISSN 1671-167X
- Ma, HF.; Tu Y.; Ma, WZ.; Guo, CQ.; Hao, JD. & Wu, JH. (2006). Effect of Acupuncture of Twelve Jing (Well)-points on Cerebral and Serum TNF- α Contents in Rats with Regional Cerebral Ischemia. *Acupuncture Research*, Vol.31, No.1, (January 2006), pp. 35-37, ISSN 1000-0607
- Ma, Q.; Zhao, JG.; Zheng, W.; Tian, GJ. & Wei, GW. (2006). Acupuncture for restoring consciousness and inducing resuscitation in treating disturbance of consciousness due to acute stroke. *Chinese Journal of Clinical Rehabilitation*, Vol.10, No.11, (March 2006), pp. 142-143, ISSN 1671-5926
- Ma, YF.; Guo Y.; Zhang YJ.; Xu, TP. & Pao, JZ. (1997). Quantitative Pathomorphologic Study on Inhibitory Effects of Acupuncture on Experimental Hyperplasia of Mammary Glands in Mice. *Zhongguo Zhen Jiu*, Vol.17, No.9, (September 1997), pp. 562, ISSN 0255-2930
- Ma, YF.; Guo Y.; Zhang YJ.; Xu, TP. & Pao, JZ. (2000). Dynamic observation of the influence of blood-letting puncture of hand twelve well points on partial pressure of oxygen in ischemic brain tissue in rats with experimental cerebral ischemia. *Shanghai Journal of Acupuncture and Moxibustion*, Vol.19, No.1, (January 2000), pp. 40-42, ISSN 1005-0957
- Peng, F.; Chen, ZQ. & Luo, JK. (2010) Clinical observation on continuous electroacupuncture at Neiguan (PC 6) for arousing consciousness of comatose patients with severe craniocerebral trauma. *Zhongguo Zhen Jiu*, Vol.30, No.6, (June 2010), pp. 465-468, ISSN 0255-2930
- Povlishock, JT. & Christman, CW. (1995). The pathobiology of traumatically induced axonal injury in animals and humans: a review of current thoughts. *Journal of Neurotrauma*, Vol.12, No.4, (August 1995), pp. 555-564, ISSN 1557-9042
- Ren, XJ.; Tu, Y.; Guo, Y.; et al. (2001a). Dynamic Observation of the Effects of Bloodletting of the 12 Hand Jing-Points on the Level of Excitatory Amino Acid in the Brain of the Rat with Cerebral Ischemia. *Journal of Beijing University of Traditional Chinese Medicine*, Vol.24, No.6, (June 2001), pp. 48-50, ISSN 1006-2157
- Ren, XJ.; Tu, Y.; Guo, Y.; et al. (2001b). Effects of the Bloodletting of the 12 Hand Jing-Points on the Level of Nitric Oxide in the Brain of the Rats with Cerebral Ischemia. *Journal of Beijing University of Traditional Chinese Medicine*, Vol.24, No.4, (April 2001), pp. 51-53, ISSN 1006-2157
- Shan, AJ.; Yin W.; Jia, SW.; et al. (2002). Quantitative study of acupuncture in treating unconscious patients with severe brain injuries. *Guangdong Medical Journal*, (February 2002), Vol.23, No.3, pp. 248-250, ISSN 1001-9448
- Shen, PF. & Shi, XM. (2009). The Clinical Research on Improvement of Acupuncture on Ultra-early Period of Cerebral Oxygen Metabolism of Acute Cerebral Ischemia. *Chinese Archives of Traditional Chinese Medicine*, Vol. 29, No.6, (June 2010), pp. 1192-1193, ISSN 1673-7717
- Shen, PF. & Shi, XM. (2010). Clinical Research on the Resuscitating Acupuncture Method Cure Stroke Patient Observe the Glucose Metabolism. *Chinese Archives of Traditional Chinese Medicine*, Vol. 28, No.2, (February 2010), pp. 258-260, ISSN 1673-7717

- Shi, XM. (1998). *Apoplexy and Xingnao Kaiqiao Acupuncture (Chin)*. Tianjin Science and Technology Publishing House, pp. 339, ISBN 7530823051, Tianjin, China
- Shi, XM. (2005). Clinical Research on the Treatment of 9005 Cases of Apoplexy with the Acupuncture Method of Sharpening Mind and Inducing Consciousness. *Hunan Guiding Journal of Traditional Chinese Medicine and Pharmacology*, Vol.11, No.1, (January 2005), pp. 3-5, ISSN 1007-547X
- Shi, XM.; Fu LX.; Zhai, N.; et al. (1998). Protective Action of "Xing Nao Kai Qiao" Acupuncture Method on Injuries of Myocardial Ultrastructure in the Rat of Experimental Cerebral Ischemia. *Zhongguo Zhen Jiu*, Vol.18, No.7, (July 1998), pp. 405, ISSN 0255-2930
- Shi, XM.; Zhao, XF.; Xiong J.; Wen, JR. & Wang S. (2006). Evaluation and Proteomics of Xingnao Kaiqiao Acupuncture in Acute Cerebral Infarction Therapy. *Tianjin Journal of Traditional Chinese Medicine*, VOL.23, No.5, (October 2006), pp. 440, ISSN 1672-1519
- Teng, AQ.; Chen, NG. & He, ZW. (2009). The observation of twelve Well points pricking blood therapy for acute cerebral infarction. *Modern Journal of Integrated Traditional Chinese and Western Medicine*, Vol.18, No.29, (October 2009), pp. 3555-3556, ISSN 1008-8849
- Teng, LZ. (2000). *Manual of Diagnosis and Treatment of Traumatic brain injury*. Shandong Science and Technology Press, pp. 410, ISBN 9787533126445 / 7533126440, Tsinan, Shandong, China
- Wang, SJ.; Kang, SB. & Li, AY. (2004). Effect of Acupuncture on Free Radical System and Cholinergic System in the Brain of Alzheimer's Disease Rats. *Acupuncture Research*, Vol.29, No.2, (June 2004), pp. 47-49, ISSN 1000-0607
- Wang, XY.; Li, JS.; Guo Y.; Liu, GW.; Pan, RQ.; Li, GL.; Han Y.; Wang, Q. & Zhang GZ. (2004). The Influence of Blood-letting Puncture of Twelve Jing-Well Points on Corticocerebral C-fos Protein Expression in Rat MCAO Model. *Shanghai Journal of Acupuncture and Moxibustion*, Vol.23, No.12, (December 2004), pp. 39-41, ISSN 1005-0957
- Wang, XY.; Li, JS.; Liu, GW.; et al. (2005). Effect of Collateral Puncture-bloodletting at JING Point on Expression of HSP70 Protein of Cerebral Cortex in Rats with Middle Cerebral Artery Occlusion. *Tianjin Journal of Traditional Chinese Medicine*, Vol.22, No.6, (December 2005), pp. 477-478, ISSN 1672-1519
- Wang, Y. & Dong, QQ. (2007). Diagnostic for Conscious Disturbance and Treatment with Combination of Traditional Chinese Medicine with Western Medicine. *Chinese Archives of Traditional Chinese Medicine*, Vol.25, No.5, (May 2007), pp. 973-975, ISSN 1673-7717
- Wei, PX.; Sun L.; Liu SX.; et al. (2007). Primary study on pericardium meridian of Hand-Jueyin Stimulation therapy in improving the level of consciousness of patients in brain coma. *Nervous Diseases and Mental Health*, Vol.7, No.3, (June 2007), pp. 169-171, ISSN 1009-6574
- Wei, YY.; Fan, XN.; Wang, Shu.; Yang, S. & Shi XM. (2010). Specificity effect of acupuncture at Shuigou (GV 26) on brain infarction area in MCAO rats and the influence of acupuncture parameter. *Zhongguo Zhen Jiu*, Vol.30, No.3, (March, 2010), pp. 221-225, ISSN 0255-2930
- World Health Organization Regional Office for the Western Pacific (WPRO). (2009). *WHO Standard Acupuncture Point Locations in the Western Pacific Region*. WPRO, pp. 31, 34, 35, 39, 41, 64, 68, 70, 72, 86, 88, 133, 136, 156, 158, 181, 188, 193, 196, 216, ISBN 978-92-9061-248-7, Manila, Philippines
- World Health Organization Regional Office for the Western Pacific (WPRO). (2007). *WHO International Standard Terminologies on Traditional Medicine in the Western Pacific Region*. WPRO, pp. 241, ISBN 978-92-9061-248-7, Manila, Philippines

- Wu, HQ.; Fan, XN.; Wang, S. & Shi, XM. (2008). Important points of "Xingnao Kaiqiao" in the application to non-stroke diseases. *Journal of Tianjin University of Traditional Chinese Medicine*, Vol.27, No.1, (March 2008), pp. 51-53, ISSN 1673-9043
- Wu, W.; Wang, W. & Yu, GJ. (1998). Hyperbaric oxygenation combining therapy for 80 children with viral encephalitic coma. *Chinese Journal of Physical Therapy*, Vol.21, No.2, (April 1998), pp. 75-77, ISSN 0254-1408
- Wu, WP.; Liang W.; Cao, YS.; et al. (2003). Jin Sanzhen for the treatment of 18 cases with persistent vegetative state post brain injury. *Chinese Journal of Clinical Rehabilitation*, Vol.7, No.31, (December 2003), pp. 4212, ISSN 1673-8225
- Xu, BB. & Wang, Z. (2006). Clinical study on median nerve stimulation therapy in improving the level of consciousness of patients in coma caused by head traumas. *Chinese Journal of School Doctor*, Vol.20, No.1, (January 2006), pp. 14-17, ISSN 1001-7062
- Xu, P.; Wang, Z.; Wu, YW.; et al. (2004). Primary study on median nerve stimulation therapy in improving the level of consciousness of patients in coma caused by head traumas. *Acta Academiae Medicine Suzhou*, Vol.24, No.2, (April 2004), pp. 199-202, ISSN 1000-5749
- Yan, GP. & Zang DW. (2007). A clinical and experimental review on the point of Shi-er Jing. *Chinese Journal of the Practical Chinese With Modern Medicine*, (November 2007), Vol.20, No.11, pp. 1014-1015, ISSN 1607-2286
- Yang, JS. (2000). *The Science of Acupuncture and Moxibustion*. Zhi-Yin Press, pp. 436, ISBN 957-9101-08-6, Taipei, Taiwan
- Yang, JZ. (1601). Zhenjiu Dacheng, In: *Encyclopedia of Traditional Chinese Medicine*, 4th Edition, Qiu, PR. (Ed.) (2006). Hunan Electronic and Audio-Visual Publishing House, ISBN 7-900377-49-2
- Yuan, Q.; Chai, TQ. & Yi, W. (2005). *Zhongfeng Houyizheng Jin-Sanzhen Textiao Zhiliao*, People's Military Medical Press, pp. 84, ISBN 7-80194-689-8, Beijing, China
- Yuan, Q.; Luo, GM. (2004). *Jin-Sanzhen Liaofa Jieshuo*. Shanghai Scientific and Technological Literature Publishing House, pp. 51, ISBN 7543923548, Shanghai, China
- Zhang, Y. & Liu, F. (2010). The progress of acupuncture improving the disorder of consciousness post traumatic brain injury research. *Chinese Journal of Ethnomedicine and Ethnopharmacy*, No.9, (May 2010), pp. 128-129, ISSN 1007-8517
- Zhao, YL.; Liu Q. & Shi, HX. (2003). Effects of acupuncture on ATP enzyme in injured brain tissues. *Chinese Archives of Traditional Chinese Medicine*, Vol.21, No.4, (April 2003), pp. 546-548, ISSN 1673-7717
- Zhao, YT.; An, YR. & Xue, YG. (2004). Recent progress of acupuncture treatment of acute cerebral hemorrhage. *Journal of Gansu College of Traditional Chinese Medicine*, Vol.21, No.4, (August 2004), pp. 57-59, ISSN 1003-8450
- Zhou, CS.; Wu, XL. & Kong, DQ. (1993). Clinical observation on acupuncture on superoxide dismutase activity in patients with ischemic stroke. *Zhongguo Zhen Jiu*, Vol.13, No.6, (December 1993), pp. 20, ISSN 0255-2930
- Zhou, DF.; Ruan, Y.; Fan, XD.; et al. (1991). Comparison of four psychiatric treatment on B, 5-HT2 receptors of rat brain cortex. *Chinese Journal of Neuropsychiatry*, Vol.24, No.4, (August 1991), pp. 207-209, ISSN 0412-4057
- Zhu, HY. (2000). Observations on the treatment of apoplection hemiplegia by alternate resuscitating and scalp acuuncures. *Shanghai Journal of Acuuncure and Moxibustion*, Vol.19, No.1, (January 2000), pp. 16-17, ISSN 1005-0957
- Zhu, MQ.; Kong, YQ.; Peng, ZY; Zhou, MH. & Lu, SK. (1993). *Zhong gou Tou pi zhen*, Guangdong Science & Technology Press, pp. 16-17, ISBN 7-5359-1012-2, Guangdong, China



Acupuncture - Clinical Practice, Particular Techniques and Special Issues

Edited by Prof. Marcelo Saad

ISBN 978-953-307-630-0

Hard cover, 138 pages

Publisher InTech

Published online 06, September, 2011

Published in print edition September, 2011

Acupuncture is growing in popularity world-wide. Acupuncture and related techniques are useful tools for treating a spectrum of diseases. However, there are still many areas of controversy connected to it due to the fact that mechanisms of action of acupuncture are not entirely clear. Another debilitating element is the absence of a convincing model of sham acupuncture for a control group in clinical trials. Therefore, there are still inappropriate prejudice and unfamiliarity regarding acupuncture. I hope this book can contribute to guide the advance of this ancient medical art. The reader will here find texts wrote by authors from different parts of the world. The chapters cover strategic areas to collaborate with the consolidation of the knowledge in acupuncture. The main objective is to share elements to make acupuncture more and better offered at health systems worldwide.

How to reference

In order to correctly reference this scholarly work, feel free to copy and paste the following:

Wen-Long Hu, Yu-Chiang Hung and Chih-Hao Chang (2011). Acupuncture for Disorders of Consciousness - A Case Series and Review, Acupuncture - Clinical Practice, Particular Techniques and Special Issues, Prof. Marcelo Saad (Ed.), ISBN: 978-953-307-630-0, InTech, Available from:

<http://www.intechopen.com/books/acupuncture-clinical-practice-particular-techniques-and-special-issues/acupuncture-for-disorders-of-consciousness-a-case-series-and-review>

INTECH
open science | open minds

InTech Europe

University Campus STeP Ri
Slavka Krautzeka 83/A
51000 Rijeka, Croatia
Phone: +385 (51) 770 447
Fax: +385 (51) 686 166
www.intechopen.com

InTech China

Unit 405, Office Block, Hotel Equatorial Shanghai
No.65, Yan An Road (West), Shanghai, 200040, China
中国上海市延安西路65号上海国际贵都大饭店办公楼405单元
Phone: +86-21-62489820
Fax: +86-21-62489821

© 2011 The Author(s). Licensee IntechOpen. This chapter is distributed under the terms of the [Creative Commons Attribution-NonCommercial-ShareAlike-3.0 License](#), which permits use, distribution and reproduction for non-commercial purposes, provided the original is properly cited and derivative works building on this content are distributed under the same license.

IntechOpen

IntechOpen