

# We are IntechOpen, the world's leading publisher of Open Access books Built by scientists, for scientists

**4,800**

Open access books available

**122,000**

International authors and editors

**135M**

Downloads

Our authors are among the

**154**

Countries delivered to

**TOP 1%**

most cited scientists

**12.2%**

Contributors from top 500 universities



**WEB OF SCIENCE™**

Selection of our books indexed in the Book Citation Index  
in Web of Science™ Core Collection (BKCI)

Interested in publishing with us?  
Contact [book.department@intechopen.com](mailto:book.department@intechopen.com)

Numbers displayed above are based on latest data collected.

For more information visit [www.intechopen.com](http://www.intechopen.com)



# Proposed Protocol for Histopathological Examination of Liver Specimen in Diagnosing Chronic Hepatitis

Andrzej Gabriel and Michał Kukla  
*Medical University of Silesia in Katowice*  
*Poland*

## 1. Introduction

The most common histopathological classification of chronic hepatitis was determined by descriptive terms, which included a subjective factor of histopathological description. It might have caused a lot of interpretative discrepancies among diagnosticians dealing with chronic liver inflammation. These difficulties led sometimes to inappropriate treatment protocol, such as the use of interferon, or caused discrepancies in the morphological rating of treatment efficiency. The first attempt of rating liver specimens in an objective way was Histological Activity Index (HAI), reported in 1981 by Knodell et al. Subsequently, many locally used modifications have been created (Lindh, Scheuer, Batts&Ludwig, Ishak, Gabriel, METAVIR). It made chronic hepatitis classification much more objective and helped in statistical analysis of research results. New diagnostic criteria of chronic liver diseases prepared in 1984 by the World Congress of Gastroenterology and International Association for the Study of the Liver (IASL) prompted authors to update previously used classifications (International Working Party, 1994). The purpose of this study is to optimize the clinical data necessary in proper diagnosis, taking into account the new criteria of inflammatory activity, process of fibrosis and steatosis.

### 2.1 Clinical part of the protocol

The points of the protocol relating to the anamnesis are to determine the nature of the disease – acute or chronic – in accordance with definition based on time criterion proposed by Leevy in 1976 (Leevy et al., 1976). Additionally, anamnesis should lead to the detection of two or more coexisting etiologic factors, for example infection with two hepatitis viruses. The protocol also considers the source of infection, as this factor may be important in determining prognostic significance, such as perinatal HBV/HCV infection, which leads to chronic state and increases the probability of developing primary liver cancer in adulthood.

The authors propose to include five hepatotropic viruses into the protocol. Knowledge and description of the viruses will help in development of serological and immunological tests. Viral factors can be detected using:

- Indication of viral markers by immunoassay and radioimmunoassay methods (EIA and RIA),

- Polymerase Chain Reaction (PCR) in the serum,
- Fluorescence in situ hybridisation (FISH) or chromogenic in situ hybridization (CISH)
- Measurement of viral genetic material (RNA, DNA) in the serum (RT-PCR).

A large number of liver lesions are caused by toxic agents such as alcohol and long-term drug use. This aspect requires special attention in anamnesis. Less common etiologic factors in adults, but more common in children are congenital metabolic disorders such as:  $\alpha$ 1-antiprotease ( $\alpha$ 1-antitrypsin) deficiency, storage diseases, galactose intolerance or abnormal metabolism of copper and iron.

Laboratory tests are divided into three groups:

- non-specific tests of liver parenchymal necrosis,
- tests to assess liver viability,
- general tests of the inflammatory process.

Radiological procedures, such as abdominal ultrasonography, bile ducts X-ray (cholecystography, cholangiography), magnetic resonance imaging (MRI) and computed tomography (CT) are the main sources of knowledge relating to the size of the liver, presence of focal lesions and some of the extrahepatic bile ducts malfunctions. If liver biopsy is performed earlier, its results should be attached. This knowledge simplifies proper diagnosis and enables assessment of the dynamics of the inflammatory and fibrotic process. The summary of the clinical part of the protocol is to establish preliminary diagnosis causing liver dysfunction. If the diagnostician is unable to establish the etiology of the disease it is possible to conduct research with additional selective histopathological techniques, such as immunohistochemical analysis of liver tissue performed using sera containing monoclonal antibodies to detect viral antigens. It is possible to use other specific techniques, PCR or hybridization *in situ*, to detect viral nucleic acids. If the clinical data is not complete and morphological picture is not characteristic, descriptive morphological diagnosis should be used. When there is the suspicion of morphological abnormalities the test for the presence of iron or copper can be performed.

## 2.2 Morphological part of the protocol

Morphological protocol describes necro-inflammatory activity, fibrosis and degenerative alteration of hepatocytes.

*Grading* for necro-inflammatory activity is based on a 4-point scale assessing the intensity of inflammatory and necrotic process - piecemeal necrosis including bridging necrosis, focal lobular necrosis and portal inflammation. The primary grading scoring system for necro-inflammatory activity proposed by Batts (Table 1) was modified by a group of Polish hepatologists and introduced to the protocol (Batts&Ludwig 1995, Gabriel et al., 1999). Piecemeal necrosis is a specific morphological change produced by a cytotoxic reaction of lymphocytes to hepatocytes. It is the death of hepatocytes at the margin of the lobule which is associated with the destruction of the limiting plate. The process extends piecemeal towards the centre of the lobule. Lymphocytes are seen adjacent to the damaged hepatocytes. The severity of lobular necrosis may encompass changes from a single foci of lymphocytic or lymphocytic-granulocytic infiltration (without hepatocyte death), through inflammatory-cell infiltration with single hepatocyte destruction to advanced confluent bridging necrosis involving a considerable portion of lobular surface with the associated collapse of the lobular stroma or perivenular confluent necrosis. The assessment of the intensity of inflammatory infiltration in portal spaces was not taken into consideration due

to less prognostic significance and difficulties in objective assessment. This category of portal inflammation, according to Theise, is inappropriate for clinical evaluation as it is a defining lesion for chronic hepatitis. Furthermore, prominent lymphoid aggregates or follicles of hepatitis C might falsely inflate the severity of necroinflammatory activity compared to conditions where such lymphoid follicles are much less typical (chronic hepatitis B, autoimmune cholangitis, primary biliary cirrhosis) (Theise 2007). The presence of degenerative and regenerative changes in hepatocytes is an additional element accompanying inflammatory infiltrations and/or necrosis. It seems that these changes are of minor importance in determining the inflammatory activity and are secondary to necrosis and inflammation.

Grading Terminology		Criteria	
Semiquantitative	Descriptive	Lymphocytic piecemeal necrosis	Lobular inflammation and necrosis
0	Portal inflammatory only, no activity	None	None
1	Minimal	Minimal, patchy	Minimal; occasional spotty necrosis
2	Mild	Mild; involving some or all portal tracts	Mild; little hepatocellular damage
3	Moderate	Moderate; involving all portal tracts	Moderate; noticeable hepatocellular damage
4	Severe	Severe; may here bridging necrosis	Severe; prominent diffuse hepatocellular damage

Table 1. Grading of disease activity in chronic hepatitis (Batts&Ludwig)

Another part of the protocol is the assessment of the intensity of fibrotic process - *staging*. The evaluation of fibrosis staging is based on a 4-point scale proposed by Batts&Ludwig. There are also other semi-quantitative scoring systems by METAVIR, Knodel, Desmet or Scheuer used to assess hepatitis activity but of local significance and usage. The comparison of scoring systems used by different authors for staging of chronic hepatitis is presented in Table 2. This parameter can be accurately assessed in histopathological sections after additional histochemical staining techniques for the detection of collagen fibers, such as Azan and Masson's trichrome. When pathological fibrosis is present in the liver tissue, both the number of actively formed collagen fibres and their location should be determined to assess its severity. The term 'portal fibrosis' refers to the involvement in the process of collagen fibroplasia of portal tracts alone. Periportal fibrosis means the presence of collagen fibres in portal tracts and their extension into the lobules or formation of single fibrous bridges which connect the adjacent portal tracts (portal-portal fibrosis). Bridging fibrosis is the presence of fibrous bridges which connect the adjacent portal tracts or portal tracts and the central venule, which leads to architectural distortion. Bridging fibrosis and nodular

regeneration correspond to stage 4 of histopathological severity. Proposed protocol does not include the scoring system proposed by Desmet, which differentiated the occurrence of porto-portal and porto-central septa as separate stages. The latter was attributed as playing a greater importance in the development of cirrhosis (Desmet 1994). The authors have added the description of advanced vascular changes to this point after consideration of the submitted proposals. It is of great importance in describing specimens of transplanted liver, especially during chronic graft rejection process. It is also useful in the evaluation of portal hypertension.

Score	Description	Knodell et al. (1981)	Desmet et al. (1994)	Scheuer (1991)
0	No fibrosis	No fibrosis	None	None
1	Mild fibrosis	Fibrosis portal expansion	Periportal fibrous expansion	Enlarged, fibrotic portal tracts
2	Moderate fibrosis		Porto-portal septa ( $\geq 1$ septum)	Periportal or portal-portal septa, but intact architecture
3	Severe fibrosis	Bridging fibrosis (portal-portal or portal-central linkage)	Porto-central septa ( $\geq 1$ septum)	Fibrosis with architectural distortion, but no obvious cirrhosis
4	Cirrhosis	Cirrhosis	Cirrhosis	Probable or definite cirrhosis

Table 2. Scoring systems for staging of chronic hepatitis.

Additional morphological features of lesser importance are ballooning degeneration, steatosis, cholestasis, bilirubinostasis, state of bile in ducts and ductules. The presence of ballooning degeneration and steatosis may indicate toxic damage or metabolic disorders such as non-alcoholic fatty liver disease/non-alcoholic steatohepatitis (NAFLD/NASH). Determining the degree of steatosis is important in liver transplant eligibility. 70% of cases of infections with HCV (mostly genotype 3a HCV) is associated with the presence of steatosis. Hepatic steatosis in the course of chronic hepatitis C is one of the risk factors for

fibrosis progression. Moreover, steatosis decreases the rate of sustained response for antiviral therapy.

Estimation of steatosis extent with numerical semi-quantitative assessment is commonly used in NAFLD. Many scoring scales were proposed. Currently the most widely used are the scales proposed by Brunt, Kleiner, Mendler and Dixon. The scoring system proposed by Kleiner et al. estimating NAFLD activity score (NAS) seems to be most suitable due to its simple and clear grading of steatosis and ballooning degeneration. The scoring scale proposed by Kleiner et al. is presented in Table 3.

<b>NAFLD Activity Score (NAS) (0-8)</b>		
Sum of scores for steatosis, lobular inflammation and hepatocellular ballooning.		
<b>Steatosis (0-3)</b>	<b>Hepatocyte ballooning (0-2)</b>	<b>Lobular inflammation (0-3)</b>
0 - 5% hepatocytes involved	0 - none	0 - none
1 - 5-33% of hepatocytes involved	1 - few ballooned cells	1 - <2 foci per x 200 field
2 - 33-66% hepatocytes involved	2 - many cells / prominent ballooning	2 - 2-4 foci per x 200 field
3 - >66% hepatocytes involved		3 - >4 foci per x 200 field
<b>Correlation between total NAFLD activity scores and an overall histological diagnosis of steatohepatitis</b>		
NAFLD activity score	Histological diagnosis of steatohepatitis	
≥5	Probable or define NASH	
3-4	Uncertain NASH	
≤2	Not NASH	

Table 3. Scoring system according to Kleiner et al.

Cholestasis is usually observed in chronic biliary diseases such as primary liver cirrhosis, primary sclerosing cholangitis and autoimmune cholangitis. Cholestasis in acute phase of infection is typical for viral infections, but it occurs rarely during chronic and autoimmune hepatitis. Accurate assessment of biliary tracts within portal spaces is important for determining the stage of primary biliary cirrhosis, primary sclerosing cholangitis and autoimmune processes of destruction of the bile ducts during chronic graft rejection. Regenerative proliferation of bile ductules is accompanied by advanced changes in organ architecture in cases of chronic inflammations with high activity and in the course of cirrhosis. The last point of the morphological protocol is biopsy-point rating, which seems to be useful for statistical evaluation of process activity. A justified criticism of the approach proposed by Knodell et al. is that it incorporates necro-inflammatory activity and fibrosis into an overall grade (Knodell et al., 1981). This implies that these two histological features increase in parallel to each other. The morphological component of the protocol involves a detailed description of the specimen, which helps for proper interpretation by the clinician. The last point of the protocol is to establish a final diagnosis with the use of descriptive terminology



(hepatitis with minimal, mild, moderate, severe inflammatory activity [grade], portal, periportal, septal fibrosis, cirrhosis [stage]).

There are several possibilities as to how to compose the final conclusion:

- a. The unequivocal histopathological picture is indictive for...
- b. The histopathological picture, aside from the clinical data, can lead to diagnosis.
- c. The unequivocal diagnosis is not possible due to i.e. disintegrated material, improper fixing of material, non-representative material.

If the etiology is unknown, the pathologist may propose additional tests. When the clinical data is not complete, the morphological picture is not characteristic or specimen is insufficient for certain diagnosis – the biopsy specimen is shorter than 25 mm or includes less than 11 portal tracts – delineation of morphological features and alterations should be carried out. *Staging* and *grading* is allowed only for the assessment of biopsy specimens which fulfill all of the above mentioned criteria.

Additional tests can be performed in the case of morphological abnormalities - the Prussian blue reaction in Perl's test for iron presence, rhodamine according to Lindqvist for copper deposits, PAS following digestion with diastase for  $\alpha$ 1-antiprotease.

Results of prior biopsy should be attached. This allows for the assessment of the dynamics of the inflammatory or fibrotic process.

The summary of the clinical part of the protocol is to establish preliminary diagnosis of liver dysfunction.

If the diagnostician is unable to establish the etiology of the disease, it is possible to conduct research with additional selective histopathological techniques, such as immunohistochemical analysis of liver tissue performed using sera containing monoclonal antibodies to detect viral antigens. It is possible to use other specific techniques, PCR or hybridization *in situ*, FISH and CISH to detect viral nucleic acids.

### 2.3 Difficulties in the differential diagnosis of chronic hepatitis

So far, pathologists have generally determined the degree and extent of hepatitis activity or progression of disease. Lobular inflammatory cell infiltration tends to predominate in acute phases of hepatitis, while portal and periportal inflammation is characteristic of chronic state. Portal hepatitis is a frequent form of chronic inflammation, consisting of infiltrations which comprise lymphocytes, plasma cells and macrophages. Plasma cells are predominant in autoimmune hepatitis alongside destruction of bile ducts with lymphocytic infiltration. Aggregates of lymphocytes or lymph follicles are observed in approximately 50% of chronic hepatitis C patients. When portal hepatitis is not accompanied by periportal or lobular infiltrations, the process is described as non-active. When periportal hepatitis is associated with focal hepatocyte destruction, the process is termed piecemeal necrosis. Mild inflammation, involving portal tracts is known as portal hepatitis. It is difficult to differentiate between true chronic hepatitis and non-specific hepatitis, or reactive chronic hepatitis, which accompanies a number of systemic diseases. When piecemeal necrosis or marked lobular necrosis coexists with inflammatory cells infiltrations, chronic hepatitis should be suspected. Marked fibrosis (septal fibrosis/cirrhosis) suggests chronic hepatitis or chronic biliary disease. If mild inflammatory infiltration in portal tracts exists as separate alteration, the condition is described as chronic reactive hepatitis. The diagnosis of chronic liver disease cannot be stated only on the basis of histopathological assessment and must be supported by clinical data (disease duration at least 6 months).

**2.4 Proposed protocol for histopathological examination of liver biopsy specimen**

ID History			
<b>First Name</b>		<b>Address:</b>	
<b>Last name</b>			
<b>Date of birth</b>			
<b>(Preliminary) Clinical diagnosis</b>			
<b>Since when has he/she been ill?</b> <i>(month, year)</i>			
<b>Has he/she ever suffered from hepatitis?</b> <i>(year)</i>			
<b>What type?</b> <i>(if documented)</i>			
<b>The way of infection</b>			
<b>Completed hepatitis vaccination</b>			
<b>Other diseases</b>	<i>metabolic diseases</i>		
	<i>other</i>		
<b>BMI</b>	<i>kg/m<sup>2</sup></i>	<b>Height</b>	<i>cm</i>
<b>Body weight</b>	<i>kg</i>	<b>Waist circumference</b>	<i>cm</i>
		<b>Hip circumference</b>	<i>cm</i>
<b>Drugs used:</b>	<i>Actually</i>		
	<i>Formerly</i>		
<b>Alcohol</b> <i>(average amount per week)</i>			



**Etiological factors examined***(serological methods and molecular biology)*

<b>HBV</b>	<b>HCV</b>	<b>HDV</b>	<b>Others</b>
HBsAG ...			HAV ...
Anty HBs...			HGV ...
HBeAg ...	Anty HCV ...	Anty HDV ...	
Anty HBe...	RNA HCV (PCR) ...		HIV ...
Anty HBc...	Viral genotype ...	RNA-HDV (pg/ml) ...	CMV ...
DNA-HBV (PCR) ...	Viral load (IU/ml) ...		HSV ...
HBV-DNA (pg/ml) ...			

**Radiology** *(USG, CT, MRI, bile ducts X-ray)*

**Laboratory tests**

pANCA	
ANA .....	Total protein .....
SMA .....	Albumin: .....
LKM-1 .....	Globulin: .....
AMA .....	<i>a1</i> .....
IgG .....	<i>a2</i> .....
α1 AT level .....	<i>β</i> .....
	<i>γ</i> .....

**a) parenchymal necrosis tests:**

ALT .....	AST .....
-----------	-----------

**b)**

alkaline phosphatase .....	GGTP .....	bilirubin .....
TIBC .....	Fe .....	ferritin .....
cholesterol .....	HDL .....	LDL .....
triglycerides .....	ceruloplasmin .....	glucose .....

**c) blood morphology**

RBC .....	WBC .....	Neutrophils .....
HGB .....		Lymphocytes .....
HCT .....		Monocytes .....
MCV .....	PLT .....	Eosynophils .....

**d) inflammatory process test**

CRP .....	Erythrocyte sedimentation rate .....
-----------	--------------------------------------

**e) coagulation**

INR .....	prothrombin index .....	fibrinogen .....
-----------	-------------------------	------------------

**Short course of the disease: results of the former liver biopsy (Nr... Date...)**

date and signature of physician

## Histopathology

### Immunohistochemical and in situ hybridisation tissue tests:

Etiologic factors.....

HBsAg..... HCVAg..... HBV DNA (PCR/CISH or FISH)

HBcAg..... HDVAg..... HCV RNA (PCR/CISH or FISH)

HBeAg.....

Staining for the presence of: Fe..... Cu.....  $\alpha$ 1- antiprotease.....

Inflammatory activity grade <i>Criteria</i>		
Score *	piecemeal necrosis-range	lobular inflammation and necrosis
0	none	none
1 minimal	single	minimal grade inflammation, single focal necrosis
2 mild	occupying single portal areas	low grade inflammation, slight destruction of hepatocytes
3 moderate	occupying all portal areas	moderate grade inflammation, noticeable destruction of hepatocytes
4 severe	occupying all portal areas	high grade inflammation, prominent diffuse hepatocellular damage, the presence of bridging or perivenular necrosis

Regressive changes in hepatocytes	
Ballooning degeneration grade..... Score**	Steatosis grade..... Score**
0 - none	0 - <5% hepatocytes involved
1 - few ballooned cells	1 - 5-33% hepatocytes involved
2 - many cells or prominent ballooning	2 - 33-66% hepatocytes involved
	3 - >66% hepatocytes involved

Regenerative changes in hepatocytes (dysplasia).....

Stage of fibrosis		
Score *	Fibrosis	Criteria
0	no fibrosis	normal amount of connective tissue
1	fibrosis of portal area	occupation of portal areas by fibrosis
2	periportal fibrosis	periportal fibrosis or single bridges portal-portal
3	bridging fibrosis	many fibrous bridges with distortion of hepatic architecture
4	cirrhosis	cirrhosis

**Cholestasis and bilirubinostasis**.....  
 Changes in vessels.....

**Scoring**

inflammation ... steatosis ... ballooning ... fibrosis ...

Histopathological description:

Additional studies proposed .....

**Final diagnosis** .....

**In descriptive terminology** .....

**Proposed differentiation** .....

date and signature of physician

\*According to modified Batts & Ludwig scoring system

\*\* According to Kleiner scoring system

**3. Conclusion**

A standardized universal protocol of liver biopsy such as the proposed scheme will facilitate the diagnosis of patients with suspected chronic liver disease. Obtaining complete and accurate clinical data by pathologists will allow more precise interpretation of observed

histological findings and will point to the necessity of additional tests. The histopathological picture should be assessed independently by two experienced pathologists in the case of research. In normal practice assessment by one experienced hepato-pathologist is accurate. In the future, in the final version of the protocol, histopathological data should be stored in a database especially prepared for pathologists.

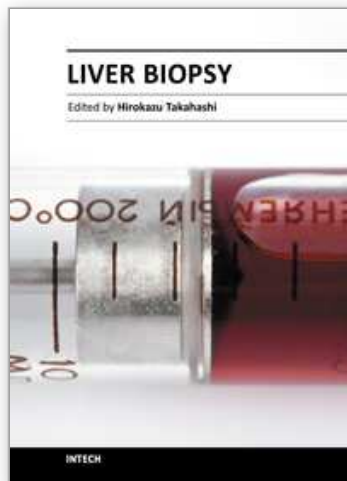
The prevalence of this protocol will unify the terminology used so far and will reduce differences in interpretation between the various centers. Modern treatment of chronic liver diseases is very expensive, especially in the case of viral infections. It requires a strict eligibility of patients for therapy. We hope that application of this protocol will assist in the proper use of financial resources thus leading to an increase in the number of complete recoveries.

#### 4. Acknowledgment

The authors would like to thank professors Adam Nowosławski and Julian Stolarczyk for their helpful suggestions and remarks. The authors would also like to thank the group of Polish hepato-pathology experts (Adam Ziółkowski, Wojciech Szczepański, Bożena Walewska-Zielecka, Janusz Miętkiewski) who prepared the recommendations for morphological assessment of liver biopsy specimens. Also many thanks to Dr. Krzysztof Tomaszek for helping prepare the final manuscript.

#### 5. References

- Batts, T. & Ludwig, J. (1995). *Chronic hepatitis. An update on terminology and reporting*. Am J Surg Pathol, Vol.19, pp. 1409-1419
- Desmet, V.J. et al. (1994). *Classification of chronic hepatitis: diagnosis, grading and staging*. Hepatology, Vol.19, pp.1513-1520.
- Gabriel, A. et al., (1999). *Podsumowanie wstępne dotyczące wypracowania standardu oceny histopatologicznej biopsji wątroby w przebiegu przewlekłych zapaleń wątroby - Katowice 15.04.1999* Pol J Pathol, Vol.50, No 4, supp.1, pp.31-32 (in Polish).
- International Working Party (1994). *Terminology of chronic hepatitis*. Am J Gastroenterol, Vol.90 pp.181
- Kleiner, D.E. et al. (2005) *Design and validation of histological scoring system for non-alcoholic fatty liver disease*. Hepatology, Vol. 41, pp.1313-1321.
- Knodell, R.G. et al. (1981). *Formulation and application of a numerical scoring system for assessing histological activity in asymptomatic chronic active hepatitis*. Hepatology, Vol.1, pp.431-43
- Theise, N.D.(2007). *Liver biopsy assesment in chronic viral hepatitis: a personal, practical approach*. Modern Pathology, Vol.20, pp.3-14



## **Liver Biopsy**

Edited by Dr Hirokazu Takahashi

ISBN 978-953-307-644-7

Hard cover, 404 pages

**Publisher** InTech

**Published online** 06, September, 2011

**Published in print edition** September, 2011

Liver biopsy is recommended as the gold standard method to determine diagnosis, fibrosis staging, prognosis and therapeutic indications in patients with chronic liver disease. However, liver biopsy is an invasive procedure with a risk of complications which can be serious. This book provides the management of the complications in liver biopsy. Additionally, this book provides also the references for the new technology of liver biopsy including the non-invasive elastography, imaging methods and blood panels which could be the alternatives to liver biopsy. The non-invasive methods, especially the elastography, which is the new procedure in hot topics, which were frequently reported in these years. In this book, the professionals of elastography show the mechanism, availability and how to use this technology in a clinical field of elastography. The comprehension of elastography could be a great help for better dealing and for understanding of liver biopsy.

### **How to reference**

In order to correctly reference this scholarly work, feel free to copy and paste the following:

Andrzej Gabriel and Michał Kukla (2011). Proposed Protocol for Histopathological Examination of Liver Specimen in Diagnosing Chronic Hepatitis, Liver Biopsy, Dr Hirokazu Takahashi (Ed.), ISBN: 978-953-307-644-7, InTech, Available from: <http://www.intechopen.com/books/liver-biopsy/proposed-protocol-for-histopathological-examination-of-liver-specimen-in-diagnosing-chronic-hepatiti>

**INTECH**  
open science | open minds

### **InTech Europe**

University Campus STeP Ri  
Slavka Krautzeka 83/A  
51000 Rijeka, Croatia  
Phone: +385 (51) 770 447  
Fax: +385 (51) 686 166  
[www.intechopen.com](http://www.intechopen.com)

### **InTech China**

Unit 405, Office Block, Hotel Equatorial Shanghai  
No.65, Yan An Road (West), Shanghai, 200040, China  
中国上海市延安西路65号上海国际贵都大饭店办公楼405单元  
Phone: +86-21-62489820  
Fax: +86-21-62489821



© 2011 The Author(s). Licensee IntechOpen. This chapter is distributed under the terms of the [Creative Commons Attribution-NonCommercial-ShareAlike-3.0 License](#), which permits use, distribution and reproduction for non-commercial purposes, provided the original is properly cited and derivative works building on this content are distributed under the same license.

IntechOpen

IntechOpen