

# We are IntechOpen, the world's leading publisher of Open Access books Built by scientists, for scientists

## 4,800

Open access books available

## 122,000

International authors and editors

## 135M

Downloads

Our authors are among the

## 154

Countries delivered to

## TOP 1%

most cited scientists

## 12.2%

Contributors from top 500 universities

**WEB OF SCIENCE™**Selection of our books indexed in the Book Citation Index  
in Web of Science™ Core Collection (BKCI)

Interested in publishing with us?  
Contact [book.department@intechopen.com](mailto:book.department@intechopen.com)

Numbers displayed above are based on latest data collected.

For more information visit [www.intechopen.com](http://www.intechopen.com)

## Autofluorescence Imaging for Diagnosing Intestinal Disorders

Mikihiro Fujiya<sup>1</sup>, Kentaro Moriichi<sup>1</sup>, Nobuhiro Ueno<sup>1</sup>,  
Yusuke Saitoh<sup>2</sup> and Yutaka Kohgo<sup>1</sup>

<sup>1</sup>*Division of Gastroenterology and Hematology/Oncology, Department of Medicine,  
Asahikawa Medical University, Asahikawa,*

<sup>2</sup>*Digestive Disease Center, Asahikawa City Hospital, Asahikawa  
Japan*

### 1. Introduction

Image enhanced endoscopies, such as narrow band imaging (NBI) and autofluorescence imaging (AFI), were recently developed and clinically applied for the diagnosis of gastrointestinal diseases. From the results of recent clinical studies, these novel technologies appear to be useful for detecting, as well as evaluating, gastrointestinal disorders. While NBI can emboss the vessel structure, AFI can capture fluorescence emitted from intestinal tissues and also describe the area in which the fluorescence intensity is reduced as a magenta color on the monitor. This device produces an excitation light source of 390-470 nm and delivers it to the tissue surface through an endoscope. The low light level autofluorescence emitted from the tissue and white light reflection are detected and amplified by two high sensitivity CCDs. The fluorescence image is then transformed into a green hue, while the reflection image is transformed into red and blue hues. Thereafter, the images are displayed on a monitor as color images in real-time (**Figure 1**) (Nakashima A, et al. 2001).

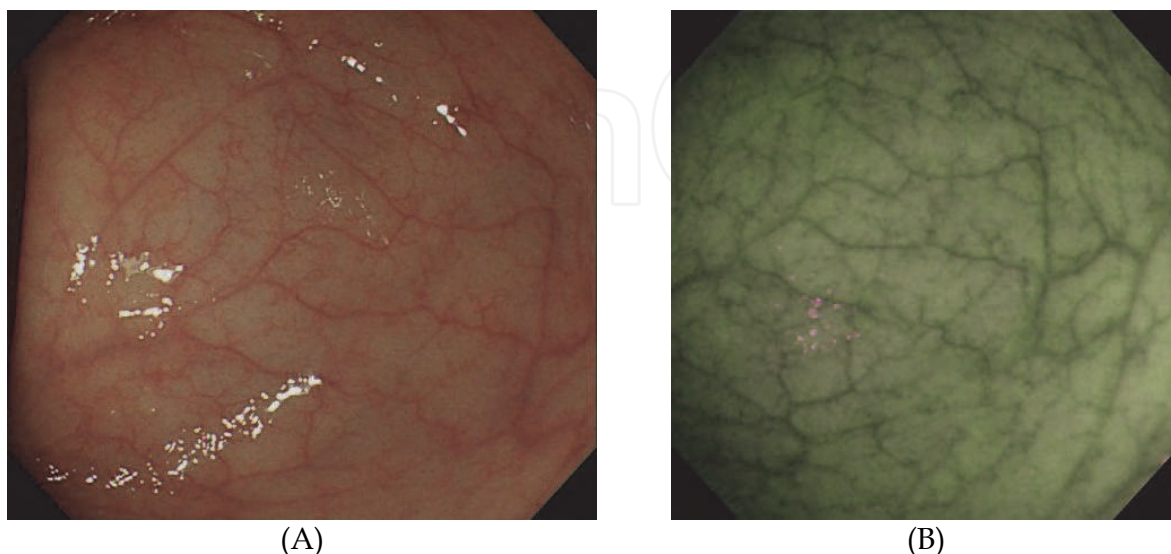


Fig. 1. High resolution endoscopy (HRE) (A) and AFI (B) in the normal colon.

AFI is characterized as a tool for simply describing the abnormal findings as color changes, whereas the diagnosis of conventional endoscopy, NBI and other technologies are based on the empirical judgment of morphological features. Moreover, the characteristics that AFI provides are based on the strength of fluorescence, so the quantification of the fluorescence intensity (proposed as the "F index") using an analytical image software program can provide an objective diagnosis for intestinal disorders (**Figure 2**).

This chapter focuses on the efficacy of AFI for the detection and differentiation of colon neoplasms, as well as the evaluation and surveillance of ulcerative colitis, and reviews the likely future progression of this technology in the diagnosis of intestinal disorders.

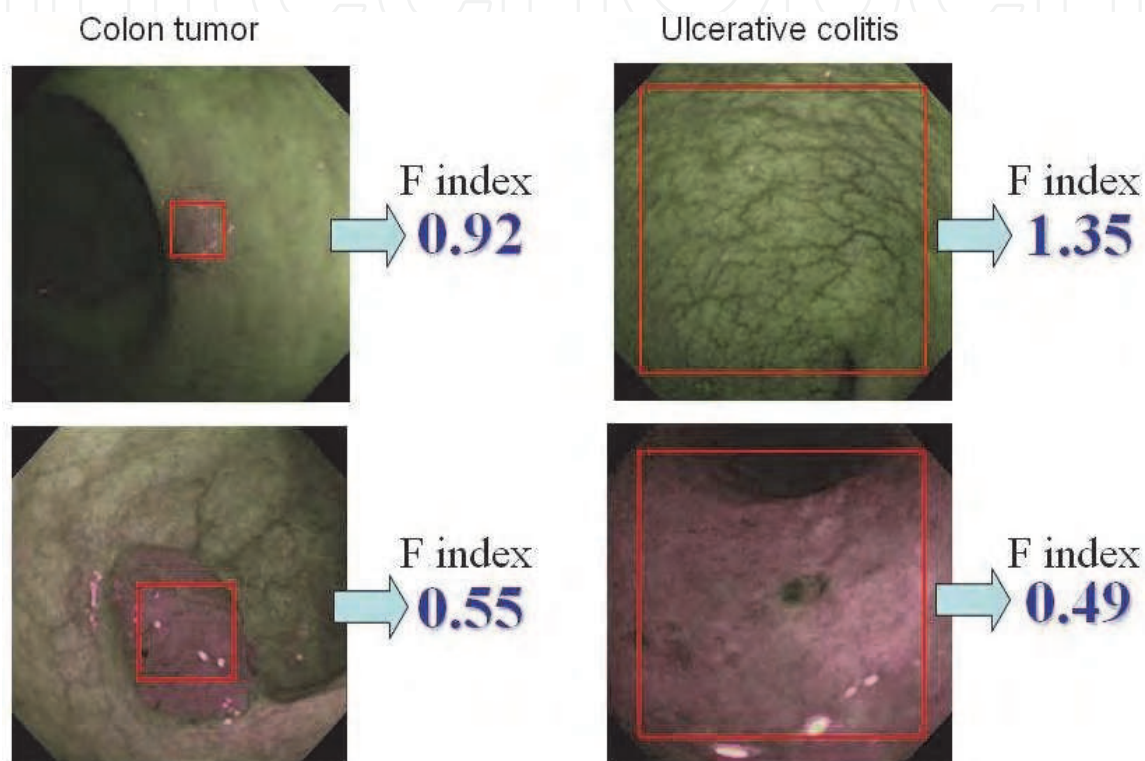


Fig. 2. Lesions are traced and measured to determine the strength of the red and green areas. The ratio of the reverse gamma value of green (fluorescence) divided by that of red (reflex) is defined as the fluorescence index (F index).

## 2. Endoscopic features of colonic lesions obtained by AFI

The typical images of intestinal disorders including neoplasms, inflammatory bowel disease, other types of colitis, Behcet disease, amyloidosis and other diseases are described in this section.

### 2.1 Colon cancer and adenoma

Almost all colon cancers and adenomas are described as magenta in AFI (**Figure 3**). The invasion depth of the cancer does not appear to influence the intensity of the fluorescence captured by AFI (**Figure 4**). The margin of the tumor is clear in AFI, even for flat and depressed types of tumors (**Figure 5**). Interestingly, AFI can detect only the tumor area, but not the reactive changes surrounding the tumor (**Figure 6**). This suggests that AFI detects some histological component of the tumor. The intensity of the fluorescence captured by AFI appears to be inversely proportional to the dysplastic grade of adenoma (Moriichi, et al. in submission).

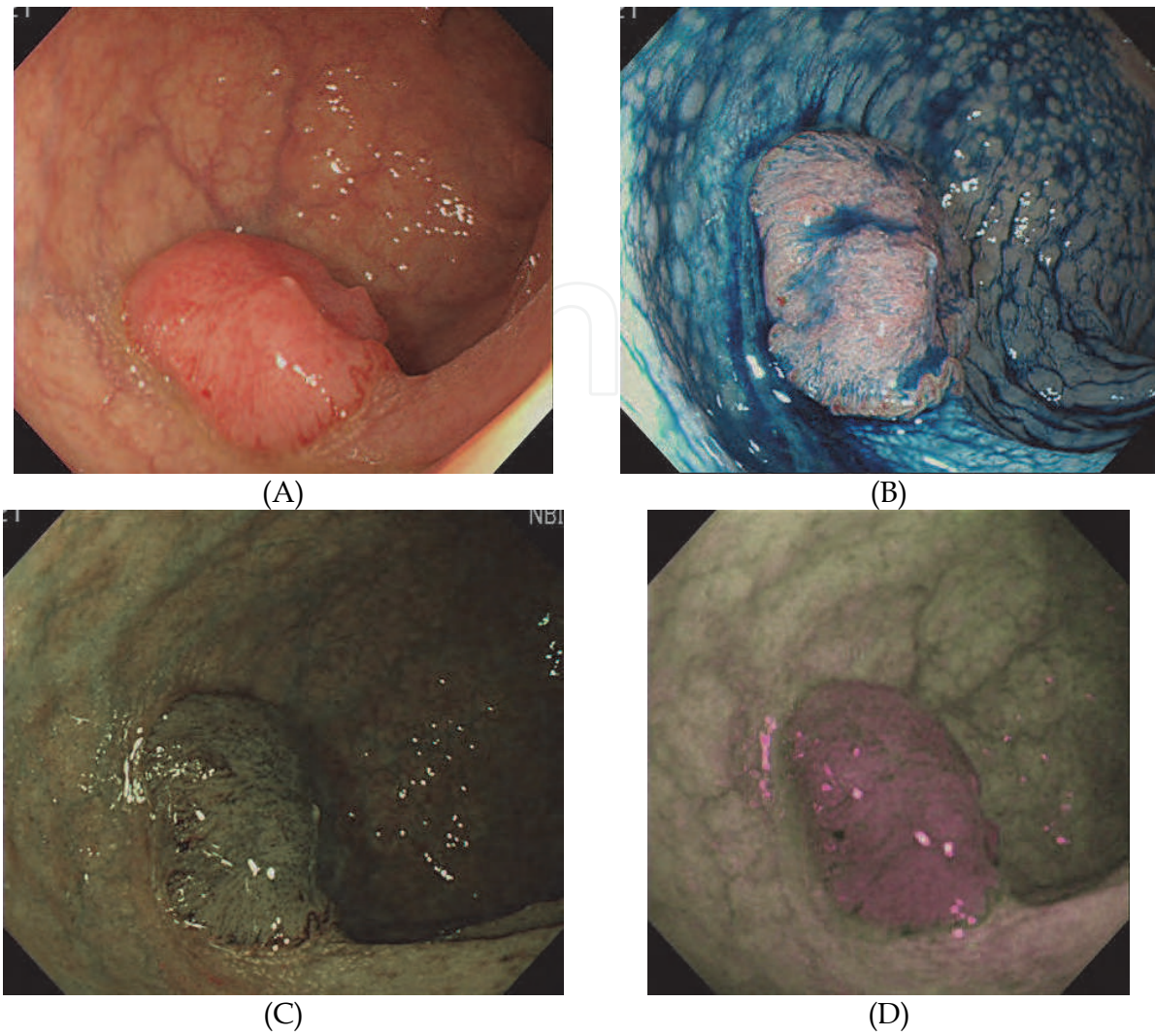


Fig. 3. HRE (A), indigocarmine-spraying image (B), narrow band imaging (C) and AFI (B) of the colon cancer with submucosal invasion.

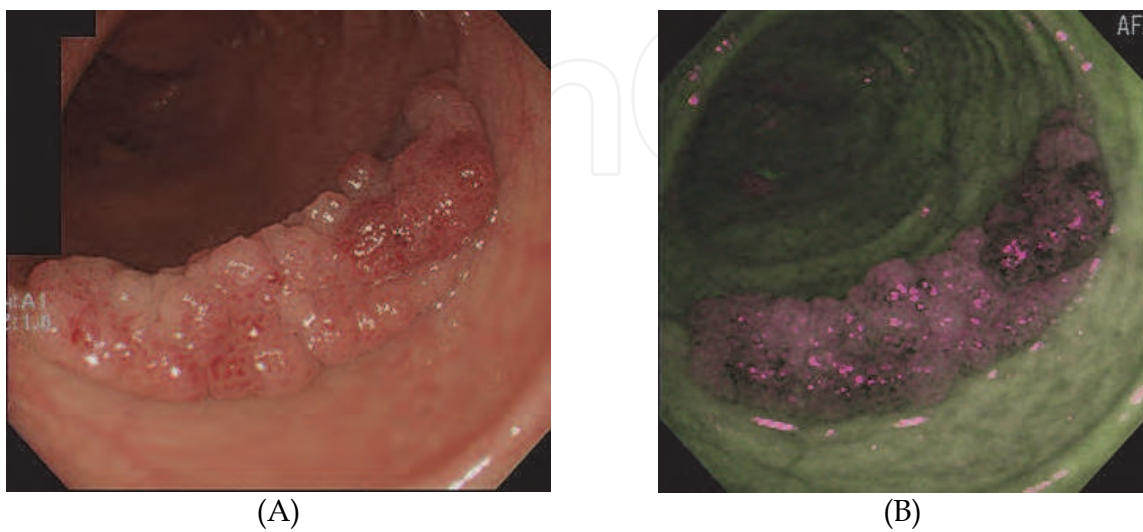


Fig. 4. HRE (A) and AFI (B) of colon cancer limited to the mucosal layer.

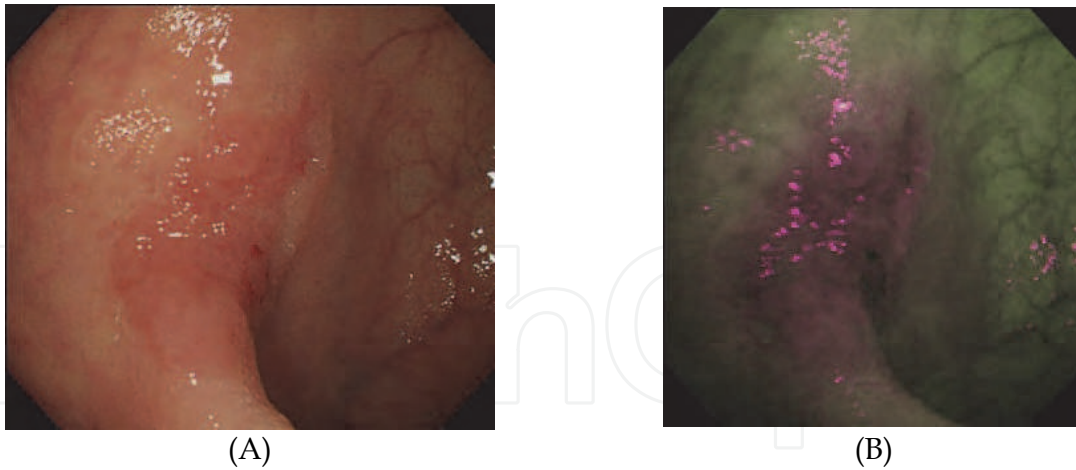


Fig. 5. HRE (A) and AFI (B) of a flat and depressed type of colon cancer with submucosal invasion.

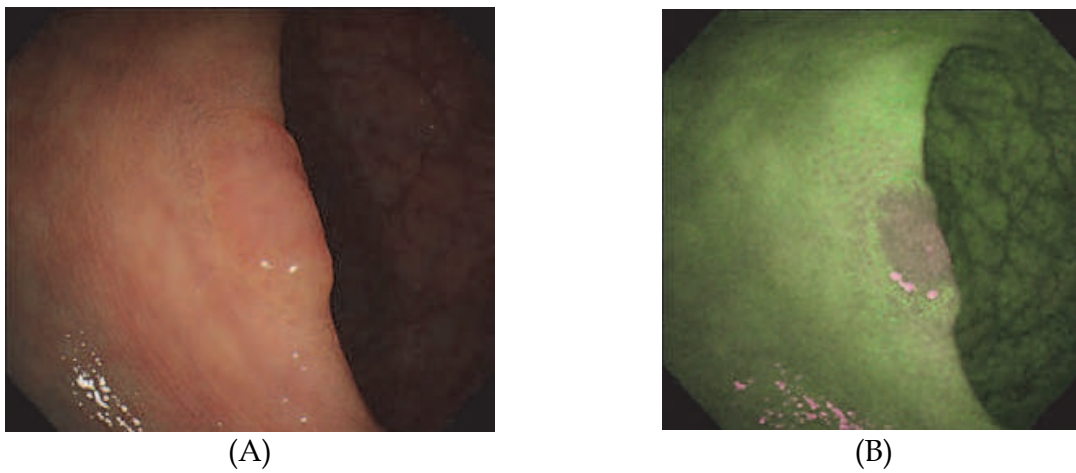


Fig. 6. HRE revealed a flat and depressed type of tumor (A). AFI detected only the depressed area as magenta (B), thus suggesting that the tumor cells are limited to the depression area.

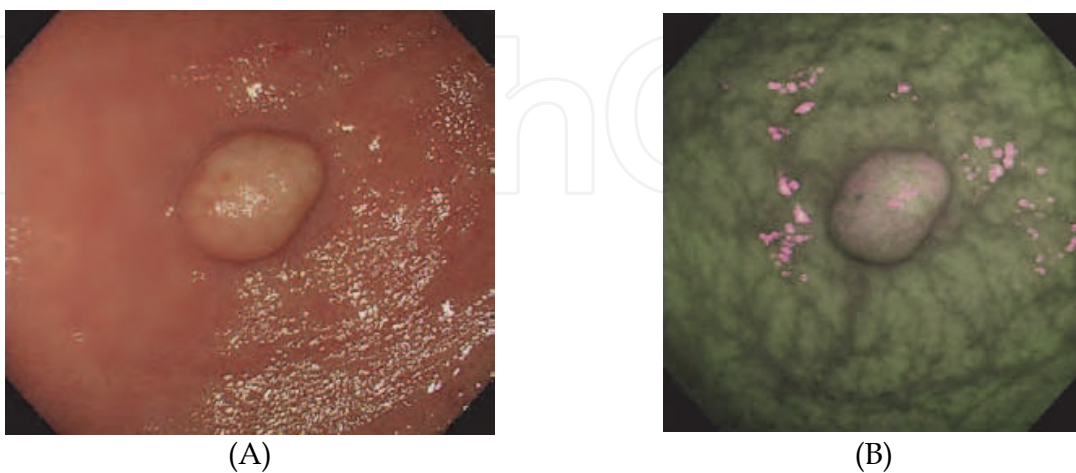


Fig. 7. HRE reveals a smooth yellowish elevation (A). AFI describes the tumor as a slight magenta area. Sometimes, the surface of a carcinoid shows heterogenous magenta and green (B).

## 2.2 Carcinoid tumors

Carcinoid tumors form in the neuroendocrine system. This type of tumor is thought to initiate from the deep portion of the intestinal epithelia (Modlin IM, et al. 2003). The tumor is therefore likely to be a submucosal tumor in the early stage. A typical finding of carcinoid tumors by white light endoscopy is a yellowish elevation with a smooth surface. AFI detects the tumor as a slight magenta area, but not strong magenta as is seen for typical colon cancer (Figure 7).

## 2.3 Lymphoma

The intestinal tract is a major organ presenting with extranodal lymphoma lesions (Groves FD, et al. 2000)(Gurney KA, et al. 2002)(Morton LM, et al. 2006). The most frequently observed types of lymphoma are non-Hodgkin's, B cell lymphomas including diffuse large B cell lymphoma, follicular lymphoma and mucosa-associated lymphoid tissue (MALT) lymphoma. Diffuse large B cell lymphoma frequently forms a submucosal tumor which is detected as a magenta area by AFI (Figure 8). Conversely, Follicular, MALT and T cell lymphomas are sometimes detected as diffusely spread magenta spots or areas by AFI (Figures 9, 10 and 11).

## 2.4 Ulcerative colitis

Ulcerative colitis is a chronic refractory colitis. While clinical symptoms are essential to assess the activity of ulcerative colitis, endoscopic assessment helps to predict the relapse or evaluate the grade of mucosal healing (Fujiya M, et al. 2002). Typical endoscopic features of ulcerative colitis are an absence of vessel permeation, multiple erosions and ulcers, and hemorrhage which diffusely appears from the rectum to the oral side of colon. We previously reported that the activity of ulcerative colitis is inversely proportional to the intensity of fluorescence captured by AFI (Figures 12 and 13) (Fujiya M, et al., 2007).

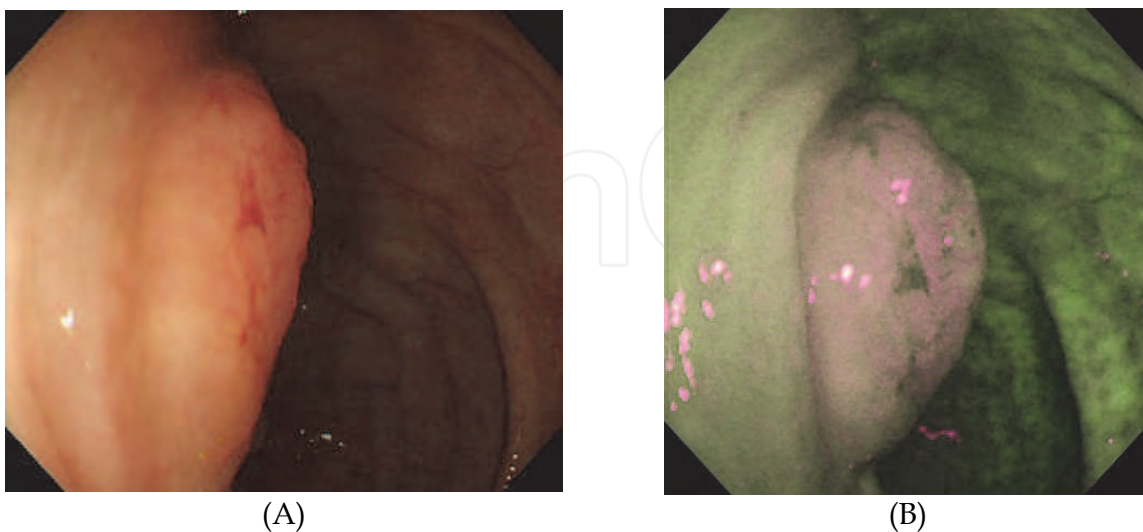


Fig. 8. HRE (A) and an AFI image (B) of a diffuse large B cell lymphoma at the ileocecal valve.

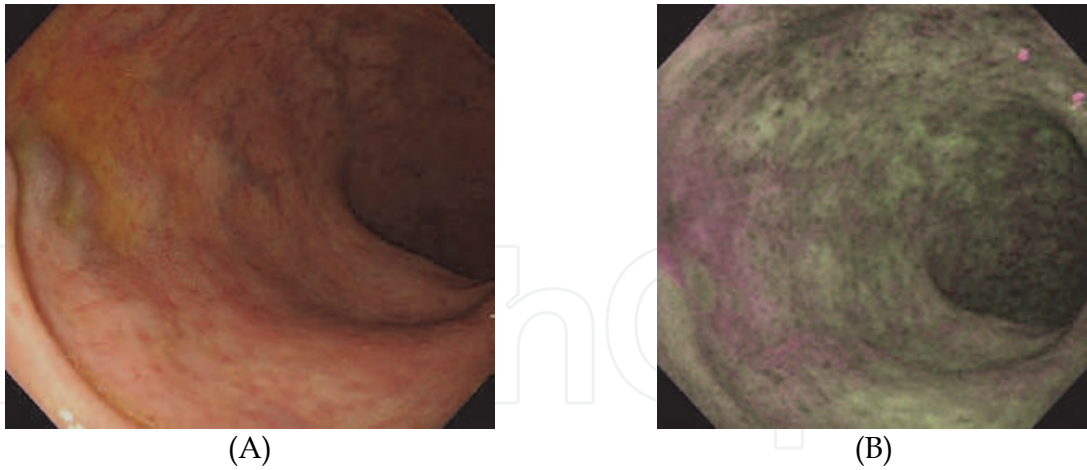


Fig. 9. HRE describes many abnormal vessels in the rectum (A). AFI can detect mosaic magenta spots which correspond to the invasion of follicular lymphoma (B).

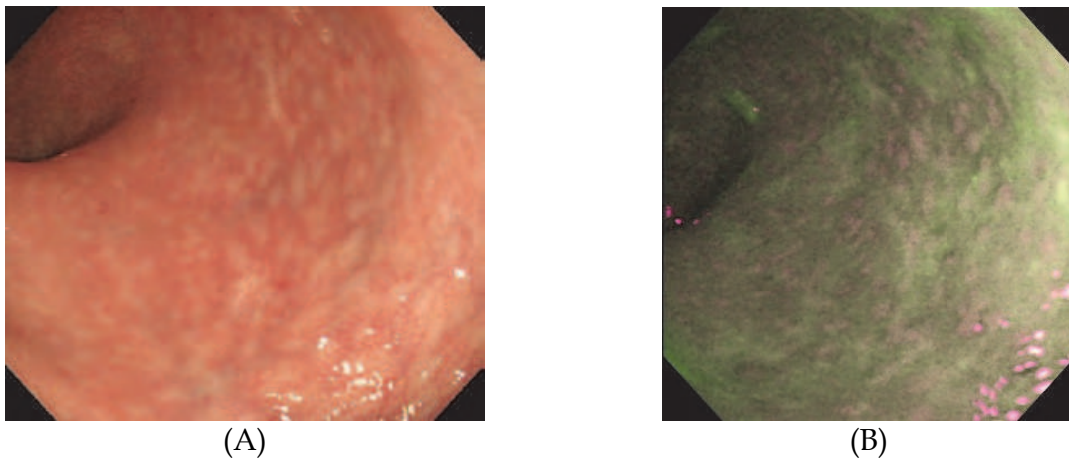


Fig. 10. HRE describes a mosaic of red and white mucosa in the rectum (A). AFI detects diffusely spread magenta spots which correspond to the invasion of MALT lymphoma (B).

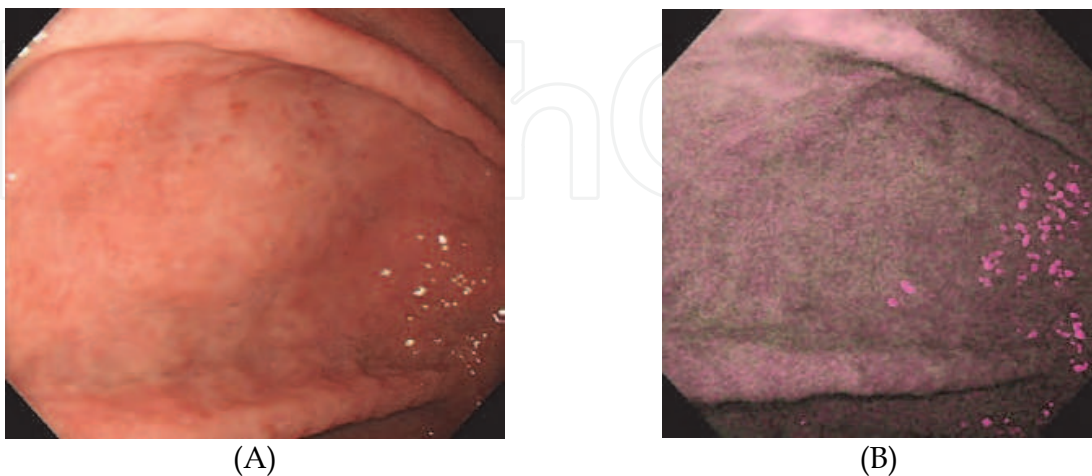


Fig. 11. HRE describes an edematous mucosa with no vessel permeation (A). AFI detects a diffuse and strong magenta area which corresponds to the invasion of T cell lymphoma originating from the tonsil (B).

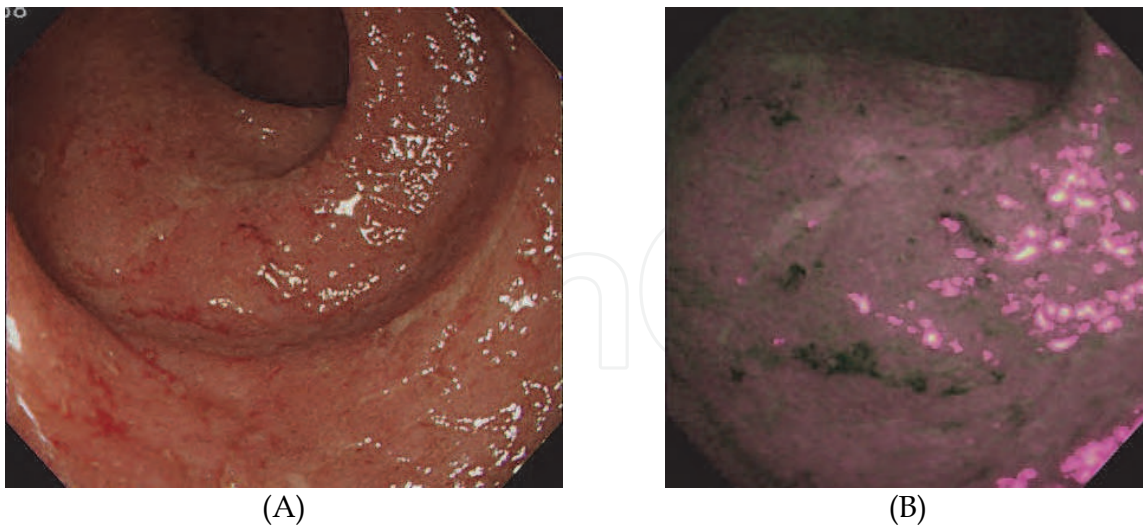


Fig. 12. HRE indicates the presence of an edematous mucosa with small ulcers and bleeding in a patient with active ulcerative colitis (A). AFI demonstrated diffuse strong magenta areas with some deep green spots, which reflect the presence of histologically active inflammation (B).

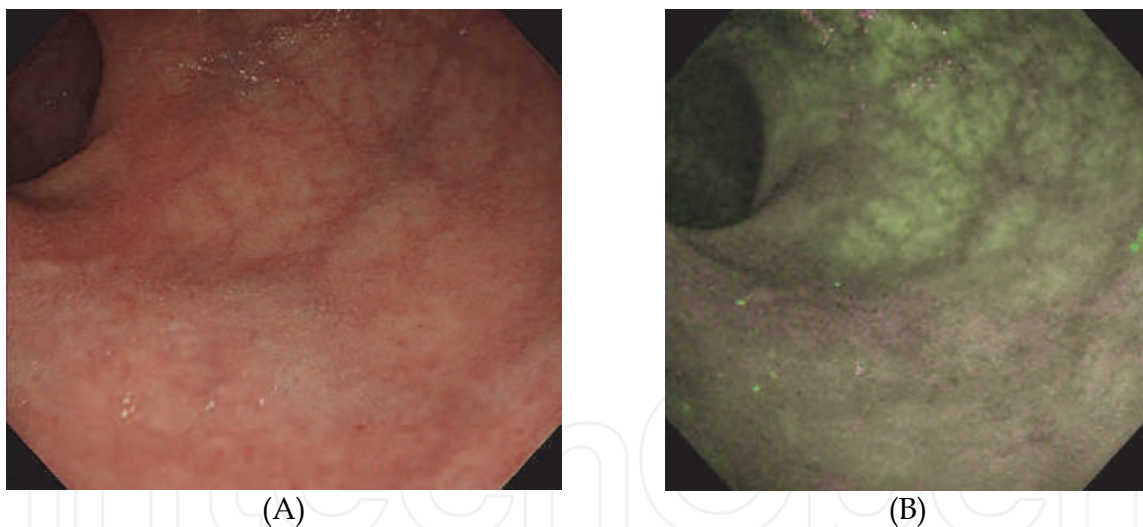


Fig. 13. HRE describes the edematous mucosa and an area with vessel permeation (A). AFI demonstrated a slight magenta area and a green area with vessel permeation, which corresponds to an active lesion and a quiescent area, respectively (B).

### 2.5 Enterocolitis

Enterocolitis is an inflammatory disease of the digestive tract caused by various microbes, parasites and chemicals. While most cases can be diagnosed without the need for endoscopy, some enteritis that persists in spite of antibiotic treatments require endoscopic evaluation. The presence of edematous mucosa with multiple erosions, ulcers and bleeding are typically observed. These findings are enhanced as magenta areas by AFI (**Figure 14**).



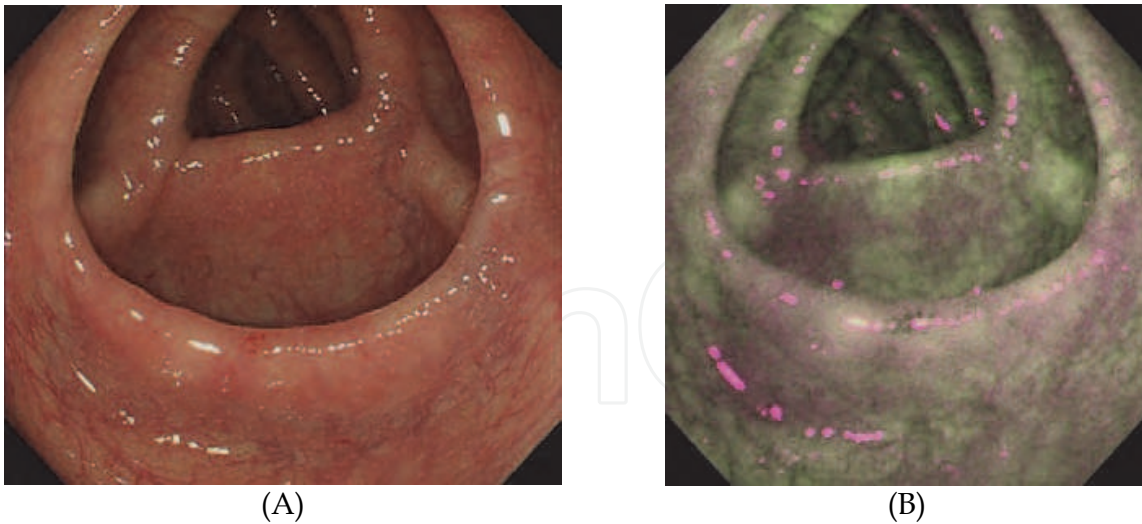


Fig. 14. HRE shows the edematous mucosa with minute erosions (A). AFI enhanced the lesions as magenta areas (B).

### 2.6 Aphthoid colitis

Aphthoid colitis is a form of intestinal inflammation which cannot be categorized into any other category of intestinal diseases. Sometimes, aphthoid colitis is an early step in the process of developing Crohn's disease, Behcet disease or other inflammatory disorders. In AFI, aphthoid ulcers exhibit a clear magenta area surrounded by a blurred magenta area that reflects edema and the infiltration of immune cells (**Figure 15**).

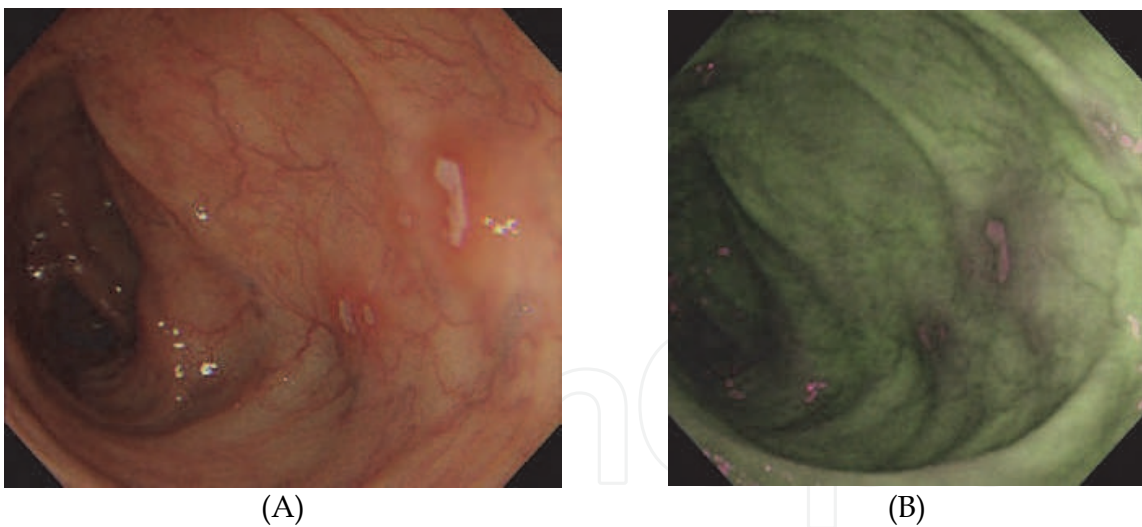


Fig. 15. Aphthoid ulcers surrounded by edematous mucosa are observed by HRE (A). AFI reveals the ulcer bed as a strong magenta area with surrounding edema presented as a faint magenta area (B).

### 2.7 Behcet disease

Behcet disease is a systemic vasculitis that frequently presents with mucosal injury and ocular involvement (**International Study Group for Behçet's Disease, 1990**). The small intestine, particularly the ileocecal valve, is a frequently involved site. Punched-out ulcers and aphtha are typical lesions in the intestinal tract (**Figure 16**).

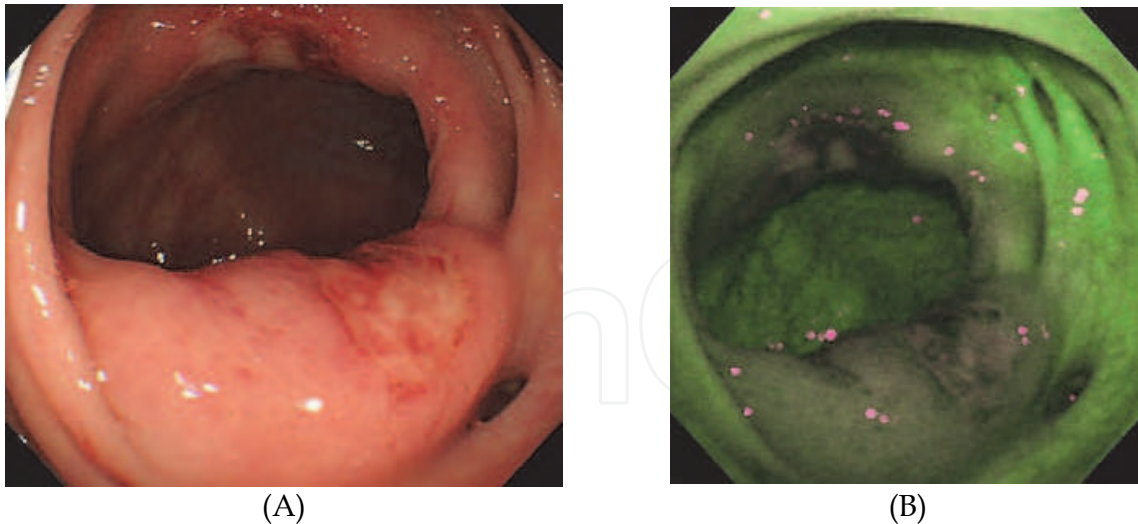


Fig. 16. HRE reveals a large ulcer on the ileocecal valve with an edematous mucosa and another large ulcer on the opposite site (A). AFI describes both ulcers as slight magenta areas, and the edematous mucosa surrounding the ulcers as faint magenta areas (B).

### 2.8 Amyloidosis

Amyloidosis is defined as an extracellular deposit of fibril proteins, P-components, or other glycoproteins in organs and tissues, causing mild to severe pathophysiological changes (Westermarck P. 2005). The intestinal tract is a frequently involved site of amyloid deposition (Koppelman RN, et al. 2000). The endoscopic features of intestinal amyloidosis include elevated lesions, ulcerations, nodules, petechial mucosal hemorrhage. AFI enhances these changes as magenta areas (Figure 17).

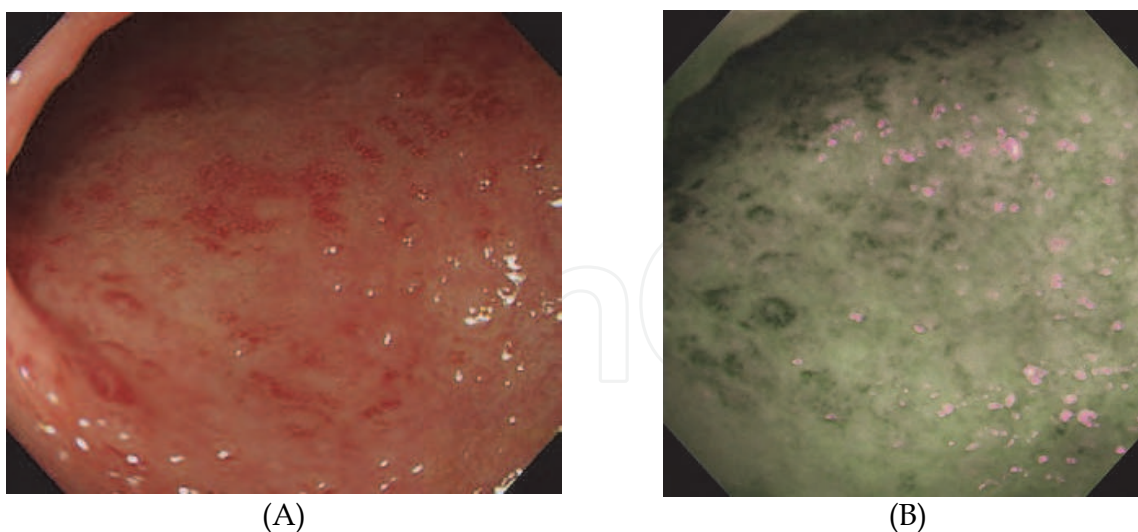


Fig. 17. HRE reveals a diffuse edematous mucosa with dilated vessels (A). AFI describes the edematous mucosa as a magenta area and the dilated vessels as deep green (B).

### 2.9 Phlebosclerotic colitis

Phlebosclerotic colitis is characterized as the presence of sclerosis with calcification in the tributaries of the superior mesenteric vein (Arimura Y, et al. 1998). This leads to chronic

venous insufficiency and congestion, causing abdominal pain, diarrhea and intestinal obstruction. The endoscopic feature of phlebosclerotic colitis is a dark purple mucosa with a marked thickness and absence of the haustra at the right side colon. AFI typically reveals a strong green area with magenta spots at the corresponding site (**Figure 18**).

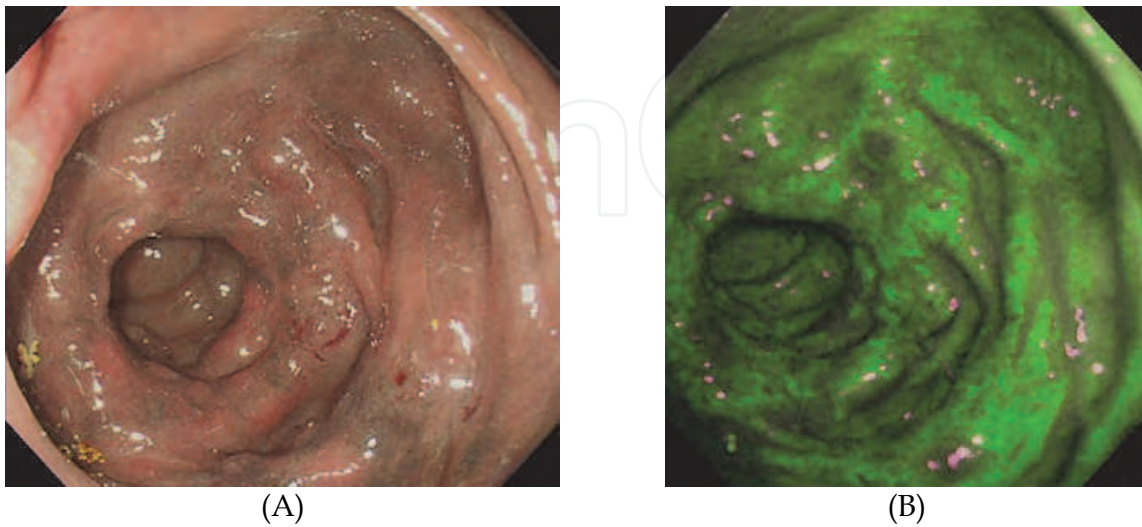


Fig. 18. HRE reveals a dark purple mucosa with edematous changes and an absence of the haustra. (A). AFI exhibits a strong green area with magenta spots (B).

### 2.10 Disuse atrophy

When the intestinal tract does not function for a long time due to a bowel rest or an intestinal operation with a stoma, disuse atrophy of the intestine develops. The typical endoscopic features are an edematous mucosa with easy bleeding. AFI detects magenta areas in the corresponding site (**Figure 19**).

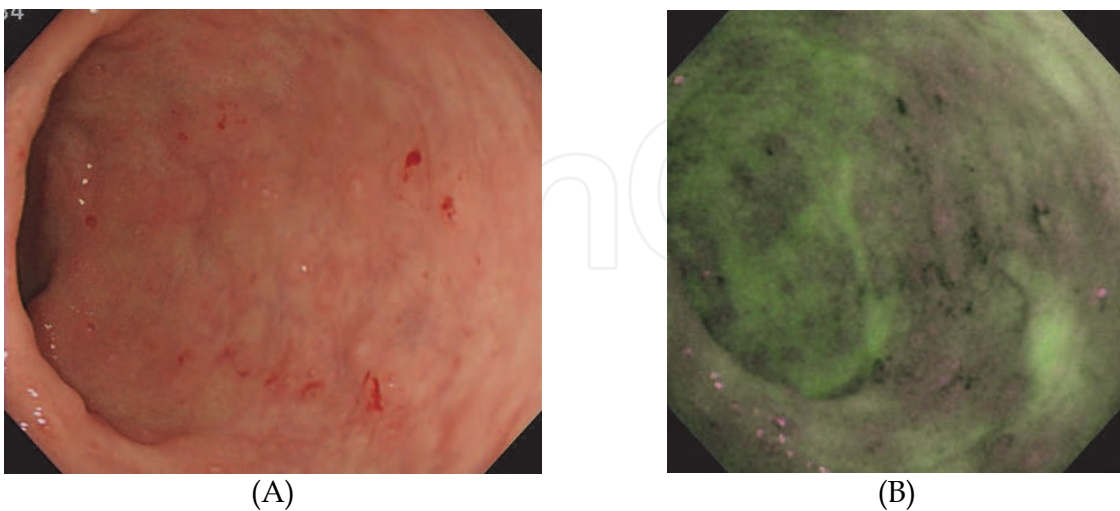


Fig. 19. HRE reveals the presence of an edematous mucosa with small erosions and spotty bleeding (A). AFI enhances the erosions as magenta and the bleeding as deep green areas (B).

### 3. The diagnostic efficacy of AFI for colon disorders

The significance of AFI for diagnosing intestinal disorders, including colon cancer, lymphoma and ulcerative colitis are reviewed in this section.

#### 3.1 Adenoma and cancer

During the process of colon carcinogenesis, normal epithelia are thought to initially turn into benign adenomas, accumulate gene alterations, and then transform into advanced adenocarcinomas (Fearon ER, et al. 1990) (Lengauer C, et al. 1998). All adenomas are thus considered to be premalignant lesions. Indeed, several trials on endoscopic resection for colon adenoma successfully decreased the mortality of colon cancer (Winawer SJ, et al. 1993). However, some patients under close colonoscopic surveillance still develop colorectal cancer (Robertson DJ, et al. 2005.). This discrepancy may be caused by the rapid progression of adenomas, as well as the overlooking of colorectal adenoma by endoscopists with different levels of experience. Indeed, systematic reviews of back-to-back colonoscopies showed that 15% to 32% of colorectal adenomas were possibly missed by colonoscopy (van Rijn JC, et al. 2006), particularly flat and depressed adenomas (Rembacken BJ, et al. 2000)(Saitoh Y, et al. 2001).

Several studies have been conducted to assess the efficacy of AFI for detecting colon adenoma. Matsuda et al. investigated the detection rate of colon polyps at the proximal colon by AFI using a modified back-to-back method. They showed a higher detection rate of colon neoplasms by AFI than that by white light endoscopy (Matsuda T, et al. 2008). In contrast, van den Broek et al. compared the detection rate of AFI with that of HRE using a procedure to inspect the entire colon twice during withdrawal: once with AFI and once with HRE by the same endoscopist. They concluded that AFI showed no significant effect on reducing the adenoma miss-rate in comparison to HRE (van den Broek FJ, et al. 2009). We previously investigated the efficacy of AFI for the detection of colon adenoma by either less-experienced physicians or endoscopic experts, and found that AFI improved the detection rate of colon adenoma, particularly by less-experienced physicians. The effectiveness of AFI for detecting colon adenoma thus appears to depend on the endoscopist and his/her level of experience.

Of interest, AFI does not detect hyperplastic polyps as a clear magenta area (Figure 20). Based on this property, AFI is expected to be used for discriminating colon neoplasms from non-neoplasms. However, the practical usefulness of AFI in the differential diagnosis of colon adenoma remains controversial (van den Broek FJ, et al. 2009)(Boparai KS, et al. 2009)(van den Broek FJ, et al. 2009). We recently investigated the effectiveness of HRE, NBI, AFI and chromoendoscopy for differentiating colon adenoma from hyperplastic polyps. From the numerical analysis of the intensity of fluorescence captured by AFI, the strength of the fluorescence was significantly lower for colon adenoma than that in hyperplastic polyp. Furthermore, our prospective study indicated that AFI improved the diagnostic accuracy to distinguish colon adenoma from hyperplastic polyps, particularly in the resident group (Sato R, et al. in press). Therefore, it is suggested that AFI captures a lower intensity of fluorescence from colon adenoma in comparison to that from hyperplastic polyps, and AFI can therefore contribute to the differential diagnosis of colon polyps if endoscopists accurately assess the intensity of fluorescence.

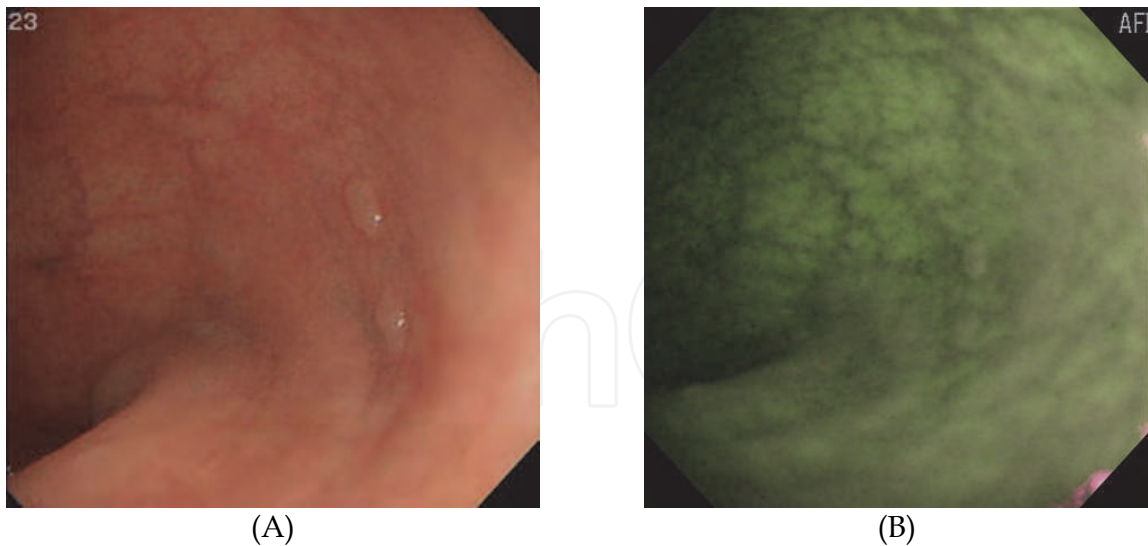


Fig. 20. HRE reveals two whitish polyps (A). AFI does not enhance the polyps (B).

### 3.2 Lymphoma

While the intestinal involvement of lymphoma cells is enhanced as magenta by AFI as mentioned above, the efficacy of AFI for diagnosing lymphoma has not been thoroughly investigated. Our study concerning the capacity of AFI (Ueno et al. 2010) for diagnosing intestinal lymphoma demonstrated the usefulness of AFI (Figure 21). A numerical analysis of the fluorescence intensity showed that AFI captured a stronger fluorescence from lymphoma than lymphoid hyperplasia (LH) (Figure 22). A histological analysis of intestinal lymphoma and LH revealed that the cell density, but not the histological type, is a significant factor that is inversely proportional to the intensity. Consequently, AFI is a useful tool to diagnose intestinal lymphoma, but cannot be used for the differentiation of histological types.

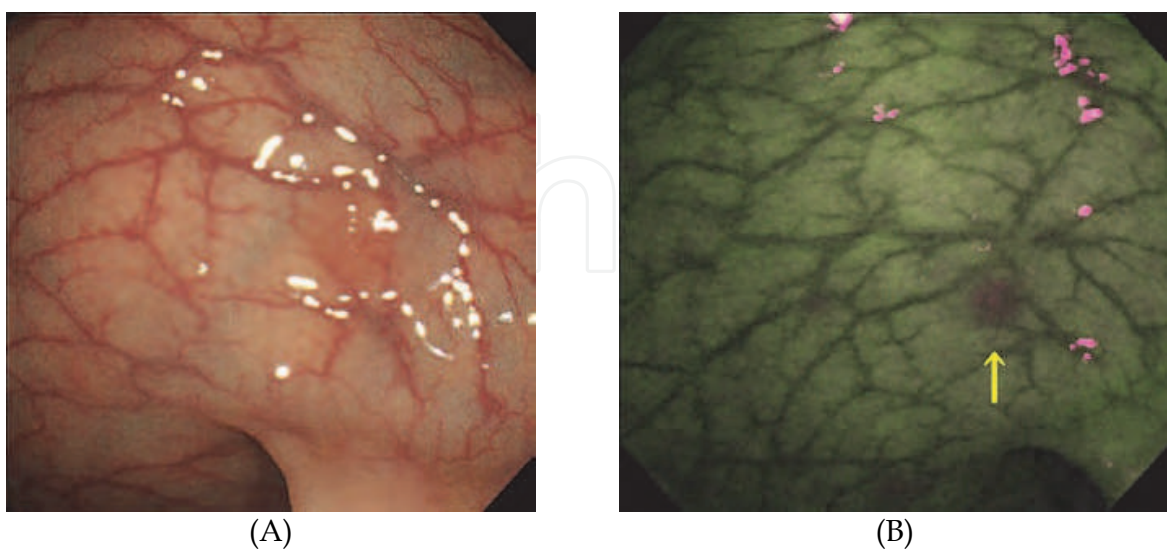


Fig. 21. HRE reveals a very faint change in the way the light is caught (A). AFI clearly detects a small lesion (arrow) of an intestinal lymphoma as a magenta spot (B) (These pictures are cited from Ueno et al. Endoscopy (in press)).

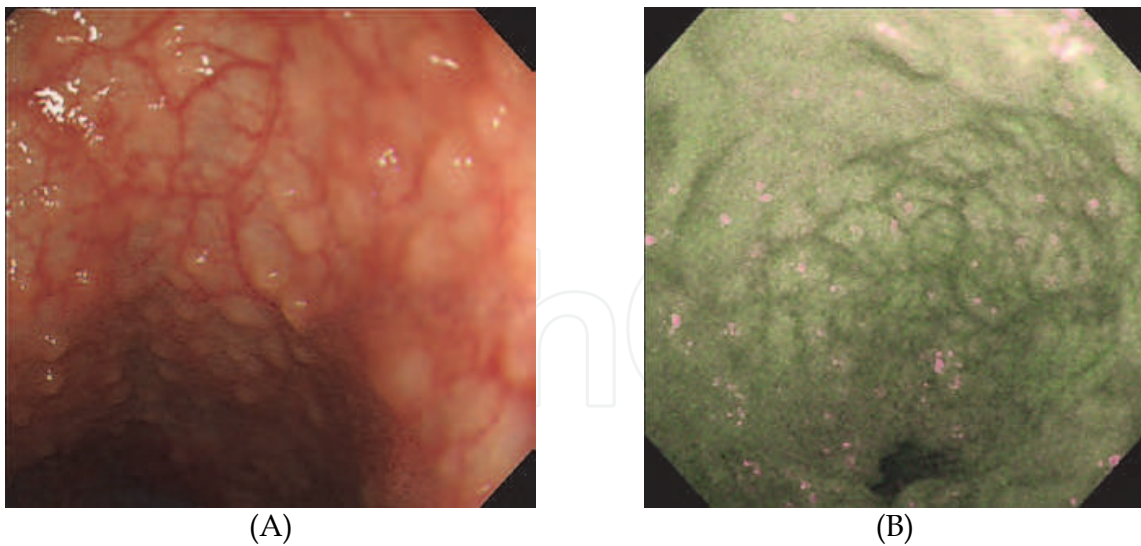


Fig. 22. HRE reveals multiple polyps in the ileum (A). AFI does not enhance the polyps (B) (This picture is cited from Ueno et al. Endoscopy (in press)).

### 3.3 Ulcerative colitis

Ulcerative colitis is a chronic refractory colitis whose etiology is still unknown. Various therapeutic strategies for ulcerative colitis are performed according to the type and activity of the disease, thus, the evaluation of the activity is important to choose an appropriate treatment. While clinical symptoms are essential to assess the activity of ulcerative colitis, endoscopic assessment helps to predict the relapse or evaluate the grade of mucosal healing (Fujiya M, et al. 2002).

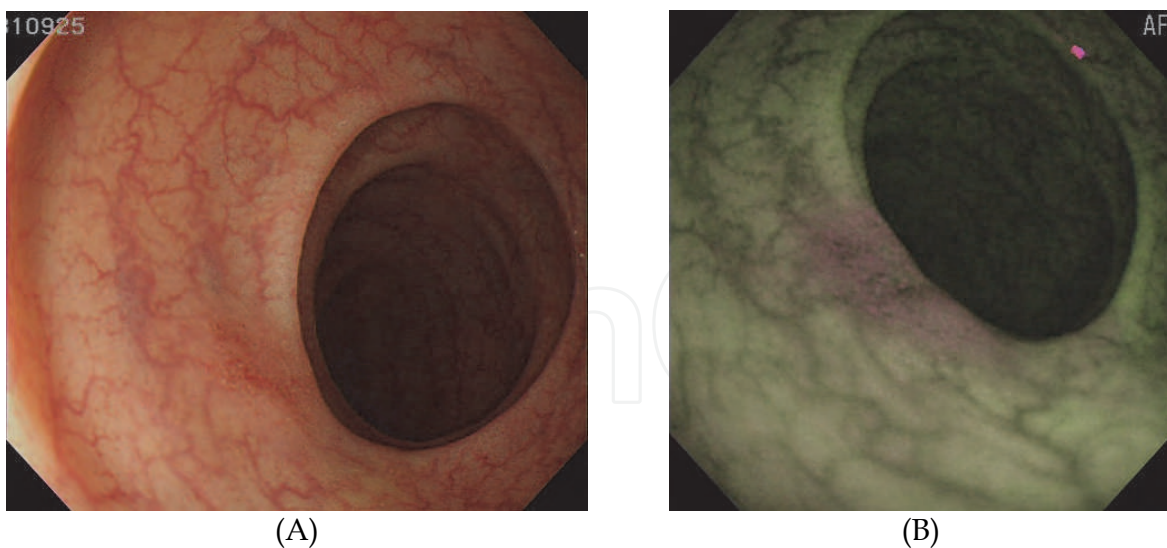


Fig. 23. HRE reveals a small amount of redness with minute erosions (A). AFI clearly describes the lesion as a magenta area, suggesting the limited active inflammation in the area (B).

Our previous investigation proposed that the intensity of fluorescence captured by AFI was inversely proportional to the histological activity in ulcerative colitis (Fujiya M, et al. 2007). Even a small lesion with slightly active inflammation can be clearly detected by AFI

(Figures 23 and 24). This suggests that when a numerical analysis of the fluorescence intensity is performed, AFI can evaluate the activity of ulcerative colitis with quite a high reproducibility and inter-observer consistency. Furthermore, it has been reported that AFI may be used to detect dysplasia in the inflamed mucosa of ulcerative colitis (Matsumoto T, et al. 2007). The future analysis of the efficacy of AFI to assess the disease activity and detect dysplasia is therefore expected to confirm the significance of AFI in the diagnosis of ulcerative colitis.

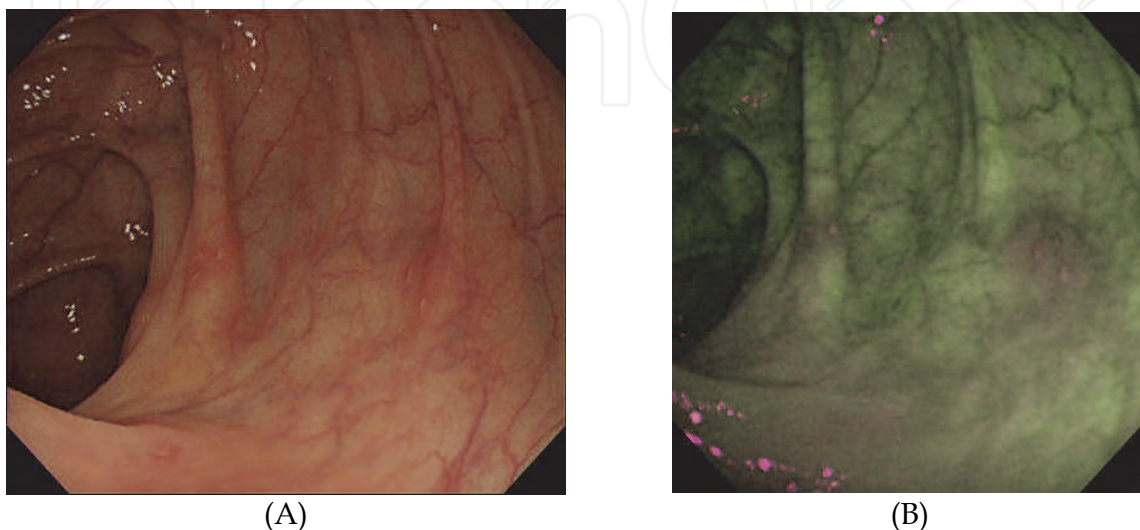


Fig. 24. HRE reveals several minute erosions (A). AFI detects the erosions with the surrounding inflammation as a magenta area (B)

#### 4. Conclusion

This review describes the typical findings of AFI and the significance of AFI in the diagnosis of intestinal disorders including colon cancer and adenoma, lymphoma, inflammatory bowel diseases, intestinal autoimmune diseases and other conditions. While the efficacy of AFI is still being explored, AFI can definitely be used as an efficient tool for objectively assessing intestinal diseases, particularly by less-experienced physicians. In the near future, a numerical analysis of the fluorescence intensity will provide a new diagnostic strategy for intestinal disorders with both high reproducibility and inter-observer consistency.


#### 5. References

- Arimura, Y., Kondoh, Y., Kurokawa, S., Azuma, N., Sekiya, M., Nakagawa, N., Endo, T., Satoh, M., & Imai, K. (1998). Chronic ischemic colonic lesion caused by phlebosclerosis with calcification. *Am J Gastroenterol*, Vol.93, No.11, 2290-2, ISSN: 0002-9270
- Boparai, K. S., van den Broek, F. J., van Eeden, S., Fockens, P., & Dekker, E. (2009). Hyperplastic polyposis syndrome: a pilot study for the differentiation of polyps by using high-resolution endoscopy, autofluorescence imaging, and narrow-band imaging. *Gastrointest Endosc*, Vol.70, No.5, 947-55, ISSN: 0016-5107
- van den Broek, F. J., Fockens, P., Van Eeden, S., Kara, M. A., Hardwick, J. C., Reitsma, J. B., & Dekker, E. (2009). Clinical evaluation of endoscopic trimodal imaging for the

- detection and differentiation of colonic polyps. *Clin Gastroenterol Hepatol*, Vol.7, No.3, 288-95, ISSN: 1542-3565
- van den Broek, F. J., van Soest, E. J., Naber, A. H., van Oijen, A. H., Mallant-Hent, R. Ch., Böhmer, C. J., Scholten, P., Stokkers, P. C., Marsman, W. A., Mathus-Vliegen, E. M., Curvers, W. L., Bergman, J. J., van Eeden, S., Hardwick, J. C., Fockens, P., Reitsma, J. B., & Dekker, E. (2009). Combining autofluorescence imaging and narrow-band imaging for the differentiation of adenomas from non-neoplastic colonic polyps among experienced and non-experienced endoscopists. *Am J Gastroenterol*, Vol.104, No.6, 1498-507, ISSN: 0002-9270
- Fearon, E. R., & Vogelstein, B. (1990). A genetic model for colorectal tumorigenesis. *Cell*, Vol.61, No.5, 759-767, ISSN: 0092-8674
- Frank, D. Groves., Martha, S. Linet., Lois, B. Travis., & Susan, S. Devesa. (2000). Cancer surveillance series: non-Hodgkin's lymphoma incidence by histologic subtype in the United States from 1978 through 1995. *J Natl Cancer Inst*, Vol.92 No.15, 1240-51, ISSN: 1460-2105
- Fujiya, M., Saitoh, Y., Nomura, M., Maemoto, A., Fujiya, K., Watari, J., Ashida, T., Ayabe, T., Obara, T., & Kohgo, Y. (2002). Minute findings by magnifying colonoscopy are useful for the evaluation of ulcerative colitis. *Gastrointest Endosc*, Vol.56, No.4, 535-542, ISSN: 0016-5107
- Fujiya, M., Saitoh, Y., Watari, J., Moriichi, K., & Kohgo, Y. (2007). Auto-Fluorescence Imaging is useful to assess the activity of ulcerative colitis. *Digestive Endoscopy*, Vol.19, No. ,145-149, ISSN: 0915-5635
- Gurney, K. A., & Cartwright, R. A. (2002). Increasing incidence and descriptive epidemiology of extranodal non-Hodgkin lymphoma in parts of England and Wales. *Hematol J*, Vol.3, No.2, 95-104, ISSN: 0390-6078
- International Study Group for Behçet's Disease. (1990). Criteria for diagnosis of Behçet's disease. *Lancet* Vol.335, No.8697, 1078-80, ISSN: 0140-6736
- Koppelman, R. N., Stollman, N. H., Baigorri, F., & Rogers, A. I. (2000). Acute small bowel pseudo-obstruction due to amyloidosis: a case report and literature review. *Am J Gastroenterol*, Vol.95, No.1, 294-296, ISSN: 0002-9270
- Lengauer, C., Kinzler, K., & Vogelstein, B. (1998). Genetic instabilities in human cancers. *Nature*, Vol.396, No.6712, 643-649, ISSN: 0028-0836
- Lindsay, M. Morton., Sophia, S. Wang., Susan, S. Devesa., Patricia, Hartge., Dennis, D. Weisenburger, & Martha, S. Linet. (2006). Lymphoma incidence patterns by WHO subtype in the United States, 1992-2001. *Blood*, Vol.107, No.1, 265-276, ISSN: 0006-4971
- Matsuda, T., Saito, Y., Fu, K. I., Uraoka, T., Kobayashi, N., Nakajima, T., Ikehara, H., Mashimo, Y., Shimoda, T., Murakami, Y., Parra-Blanco, A., Fujimori, T., & Saito, D. (2008). Does autofluorescence imaging videoendoscopy system improve the colonoscopic polyp detection rate? – a pilot study. *Am J Gastroenterol*, Vol.103, No.8 , 1926-32, ISSN: 0002-9270
- Matsumoto, T., Moriyama, T., Yao, T., Mibu, R., & Iida, M. (2007). Autofluorescence imaging colonoscopy for the diagnosis of dysplasia in ulcerative colitis. *Inflamm Bowel Dis*, Vol.13, No.5, 640-641, ISSN: 1078-0998
- Modlin, I.M., Lye, K.D., & Kidd, M. (2003). A 5-decade analysis of 13,715 carcinoid tumors. *Cancer*, Vol.97, No.4, 934-59, ISSN: 0008-543X



- Nakashima, A., Miwa, H., Watanabe, H., Kobayashi, O., Ogihara, T., & Sato, N. (2001). A new technique: light-induced fluorescence endoscopy in combination with pharmacoendoscopy. *Gastrointest Endosc*, Vol.53, No. 3, 343-8, ISSN: 0016-5107
- Rembacken, B. J., Fujii, T., Cairns, A., Dixon, M. F., Yoshida, S., Chalmers, D. M., & Axon, A. T. (2000). Flat and depressed colonic neoplasms: a prospective study of 1000 colonoscopies in the UK. *Lancet*, Vol.355, No.9211, 1211-1214, ISSN: 0140-6736
- van Rijn, J. C., Reitsma, J. B., Stoker, J., Bossuyt, P. M., van Deventer, S. J., & Dekker, E. (2006). Polyp miss rate determined by tandem colonoscopy: a systematic review. *Am J Gastroenterol*, Vol.101, No.2, 343-350, ISSN: 0002-9270
- Robertson, D. J., Greenberg, E. R., Beach, M., Sandler, R.S., Ahnen, D., Haile, R. W., Burke, C. A., Snover, D. C., Bresalier, R. S., McKeown-Eyssen, G., Mandel, J. S., Bond, J. H., Van Stolk, R. U., Summers, R. W., Rothstein, R., Church, T. R., Cole, B. F., Byers, T., Mott, L., & Baron, J. A. (2005). Colorectal cancer in patients under close colonoscopic surveillance. *Gastroenterology*, Vol.129, No.1, 34-41, ISSN: 0016-5085
- Saitoh, Y., Waxman, I., West, A. B., Popnikolov, N. K., Gatalica, Z., Watari, J., Obara, T., Kohgo, Y., & Pasricha, P. J. (2001). Prevalence and distinctive biologic features of flat colorectal adenomas in a North American population. *Gastroenterology*, Vol.120, No.7, 1657-1665, ISSN: 0016-5085
- Sato, R., Fujiya, M., Watari, J., Ueno, N., Moriichi, K., Kashima, S., Maeda, S., Ando, K., Kawabata, H., Sugiyama, R., Nomura, Y., Nata, T., Itabashi, K., Inaba, Y., Okamoto, K., Mizukami, Y., Saitoh, Y., & Kohgo, Y. (in press) The diagnostic accuracy of high-resolution endoscopy, autofluorescence imaging and narrow-band imaging for differentially diagnosing colon adenoma. *Endoscopy*, ISSN: 0013-726X
- Winawer, S. J., Zauber, A. G., Ho, M. N., O'Brien, M. J., Gottlieb, L. S., Sternberg, S. S., Waye, J. D., Schapiro, M., Bond, J. H., Panish, J. F., Ackroyd, F., Shike, M., Kurtz, R. C., Hornsby-Lewis, L., Gerdes, H., Stewart, E. T., & The National Polyp Study Workgroup. (1993). Prevention of Colorectal Cancer by Colonoscopic Polypectomy. *N Eng J Med* Vol.329, No.27, 1977-1981, ISSN: 0028-4793
- Ueno, N., Fujiya, M., Moriichi, K., Ikuta, K., Nata, T., Konno, Y., Ishikawa, C., Inaba, Y., Ito, T., Sato, R., Okamoto, K., Tanabe, H., Maemoto, A., Sato, K., Watari, J., Ashida, T., Saitoh, Y., & Kohgo, Y. (in press). Endoscopic auto-fluorescence imaging is useful for the differential diagnosis of intestinal lymphomas resembling lymphoid hyperplasia. *J Clin Gastroenterol*, ISSN: 0192-0790
- Westermarck, P. Aspects on human amyloid forms and their fibril polypeptides. (2005). *FEBS J*, Vol.272, No.23, 5942-9, ISSN: 1742-464X



## **Colonoscopy**

Edited by Prof. Paul Miskovitz

ISBN 978-953-307-568-6

Hard cover, 326 pages

**Publisher** InTech

**Published online** 29, August, 2011

**Published in print edition** August, 2011

To publish a book on colonoscopy suitable for an international medical audience, drawing upon the expertise and talents of many outstanding world-wide clinicians, is a daunting task. New developments in videocolonoscopy instruments, procedural technique, patient selection and preparation, and moderate sedation and monitoring are being made and reported daily in both the medical and the lay press. Just as over the last several decades colonoscopy has largely supplanted the use of barium enema x-ray study of the colon, new developments in gastrointestinal imaging such as computerized tomographic colonography and video transmitted capsule study of the colonic lumen and new discoveries in cellular and molecular biology that may facilitate the early detection of colon cancer, colon polyps and other gastrointestinal pathology threaten to relegate the role of screening colonoscopy to the side lines of medical practice. This book draws on the talents of renowned physicians who convey a sense of the history, the present state-of-the art and ongoing confronting issues, and the predicted future of this discipline.

### **How to reference**

In order to correctly reference this scholarly work, feel free to copy and paste the following:

Mikihiro Fujiya, Kentaro Moriichi, Nobuhiro Ueno, Yusuke Saitoh and Yutaka Kohgo (2011). Autofluorescence Imaging for Diagnosing Intestinal Disorders, *Colonoscopy*, Prof. Paul Miskovitz (Ed.), ISBN: 978-953-307-568-6, InTech, Available from: <http://www.intechopen.com/books/colonoscopy/autofluorescence-imaging-for-diagnosing-intestinal-disorders>

**INTECH**  
open science | open minds

### **InTech Europe**

University Campus STeP Ri  
Slavka Krautzeka 83/A  
51000 Rijeka, Croatia  
Phone: +385 (51) 770 447  
Fax: +385 (51) 686 166  
[www.intechopen.com](http://www.intechopen.com)

### **InTech China**

Unit 405, Office Block, Hotel Equatorial Shanghai  
No.65, Yan An Road (West), Shanghai, 200040, China  
中国上海市延安西路65号上海国际贵都大饭店办公楼405单元  
Phone: +86-21-62489820  
Fax: +86-21-62489821

© 2011 The Author(s). Licensee IntechOpen. This chapter is distributed under the terms of the [Creative Commons Attribution-NonCommercial-ShareAlike-3.0 License](#), which permits use, distribution and reproduction for non-commercial purposes, provided the original is properly cited and derivative works building on this content are distributed under the same license.

IntechOpen

IntechOpen