

We are IntechOpen, the world's leading publisher of Open Access books Built by scientists, for scientists

4,800

Open access books available

122,000

International authors and editors

135M

Downloads

Our authors are among the

154

Countries delivered to

TOP 1%

most cited scientists

12.2%

Contributors from top 500 universities



WEB OF SCIENCE™

Selection of our books indexed in the Book Citation Index
in Web of Science™ Core Collection (BKCI)

Interested in publishing with us?
Contact book.department@intechopen.com

Numbers displayed above are based on latest data collected.
For more information visit www.intechopen.com



Bisphosphonate-Related Osteonecrosis of the Jaw Around Dental Implants

Tatsuo Shirota¹, Atsushi Nakamura², Yoshiro Matsui³,
Masashi Hatori¹, Masanori Nakamura¹ and Satoru Shintani¹

¹*Showa University,*

²*Yamato Tokushukai Hospital,*

³*Kagawa University,*

Japan

1. Introduction

Bisphosphonate is the collective name for compounds in which the backbone of pyrophosphoric acid, a P-O-P structure, is converted to chemically stable P-C-P, and this structure shows the affinity of bisphosphonate for bone hydroxyapatite in the body (Fleisch et al. 2002). Administered bisphosphonate preparations (BPs) transfer to and deposit in bone, exhibiting a bone resorption-inhibitory effect. The chemical structure of the side chain bound to the carbon atom of P-C-P markedly influences bisphosphonate activity, and, particularly, side chains containing nitrogen molecules not only markedly increase the affinity for HA but also bone resorption-inhibitory activity (Migliorati et al. 2005). Because of this potent bone resorption-inhibitory effect, BPs are the first-choice treatment for osteoporosis worldwide (Russell et al. 2007), and their efficacy for malignant tumor-associated hypercalcemia (Body et al. 1999), ostealgia complicating bone metastasis of solid tumors (Hortobagyi et al. 1998), and multiple myeloma accompanied by bone destruction (Berenson et al. 1996) has been shown. Adverse effects of BPs were previously considered to be relatively mild, such as digestive symptoms induced by oral preparations and fever induced by injections (Berenson et al. 1996), but the association of BPs with osteonecrosis of the jaw has been frequently described since Marx (2003) initially reported it (Ruggiero et al. 2004; Marx et al. 2005; Khosla et al. 2007)

Bisphosphonate-related osteonecrosis of the jaw (BRONJ) is clinically diagnosed when the following 3 conditions are met: 1) current or previous treatment with BPs, 2) persistent exposure of necrotized bone in the maxillofacial region for 8 weeks or longer, 3) no past medical history of radiotherapy for the jaw bone (AAOMS 2007; Ruggiero et al. 2009). BPs inducing BRONJ mostly contain nitrogen (NBPs). BRONJ frequently develops in patients under NBP treatment upon dental treatment, such as tooth extraction, implant placement, and surgical periodontal treatment accompanied by bone invasion, and inflammatory diseases, such as periodontal disease and abscess (Ruggieri et al. 2009; Vahtsevanos et al. 2009; Yoneda et al. 2010). BRONJ shows poor responses to the standard treatment for common osteomyelitis of the jaw, such as curettage/resection of necrotized tissue and antimicrobial drugs, and its intractability is the most serious problem.

Stack & Epker (1995) initially reported the influence of BPs on dental implant treatment. They introduced a case in which all 5 favorably functioning implants in the lower anterior tooth region were lost after the 5-month administration of a BP containing no nitrogen, etidronatedisodium (Didronel; Procter and Gamble, Cincinnati, OH), for osteoporosis. The details of the bone wound healing process after implant loss or whether BRONJ developed were not described, but the author concluded that Didronel administration is a risk factor for implant treatment. However, several recent studies reported that implant treatment in the presence of NBPs was possible when the NBPs were oral drugs. Fugazzotto et al (2007) evaluated that a retrospective analysis of case records of patients with a history of oral BPs therapy treated as part of routine periodontal and implant treatment. They reported that no osteonecrosis was noted immediately postoperatively or during follow-up period 61 patients, and all implants were functioning successfully 12 to 24 months post-insertion. Grant et al. (2008) evaluated the clinical results of 115 patients who received oral BPs during implant treatment. They showed that there was no significant difference in treatment results between patients with and without oral BPs during implant treatment. It was also reported that no patients developed ONJ after implant treatment. Bell & Bell (2008) reported that bone grafting for implant treatment in 42 patients who received oral BPs for osteoporosis treatment was conducted safely. Therefore, no conclusion has been reached regarding whether oral BPs are contraindicated for implant treatment. On the other hand, it has been clarified that the risk of developing BRONJ upon open dental treatment rises in patients treated with NBP intravenous injection showing a potent bone adsorption-inhibitory action, and implant treatment is considered contraindicated for such cases (Khan et al. 2008; Ruggiero et al. 2009). However, there have been fewer reports on the influence of intravenous BPs on implants which have already acquired osseointegration and are favorably functioning, and the actual state is unclear.

We experienced the case of a patient who developed ONJ around implants in the maxilla, considered to be caused by intravenous BP administration for osteometastasis treatment of breast cancer, and underwent partial maxillectomy to relieve inflammation (Shirota et al. 2009). This chapter introduces clinical findings, the treatment and its outcome, and peri-implant histopathological findings in the patient, and the developmental mechanism of peri-implant BRONJ is discussed with a literature review.

2. Patient and methods

2.1 Outline of the patient

The patient was a 54-year-old female who visited our hospital for chief complaints of peri-implant pain in the upper left molar region and bone exposure. The patient developed breast cancer about 6 years ago and underwent left mastectomy followed by irradiation and chemotherapy. However, multiple cancer metastases occurred about 2 years ago, and the patient underwent cancer chemotherapy and intravenous BPs injection.

The patient underwent implant treatment for the upper left molar region at a dental clinic immediately before the development of breast cancer, in which 2 implants were placed. These implants functioned without a problem for about 6 years, but peri-implant gingival recession, bone exposure, and pain appeared about one month ago, and the patient received antimicrobial drug administration, irrigation, and disinfection at a clinic, but the symptoms did not improve. Thus, the patient visited our department. On the first examination, brown-colored necrotized bone was exposed in the upper left first molar region on the buccal side.

The peri-implant gingiva was painful and swollen with slight flare, but no implant mobility was observed (Fig.1). On panoramic radiography, mild bone resorption was noted in alveolar bone in the implant neck. Computed tomography (CT) revealed sequestration with an irregular trabecular bone structure around the implant (Fig.2). Biopsy was performed in consideration of metastasis of breast cancer to the oral cavity, but only inflammatory cell infiltration was observed without tumor cells.

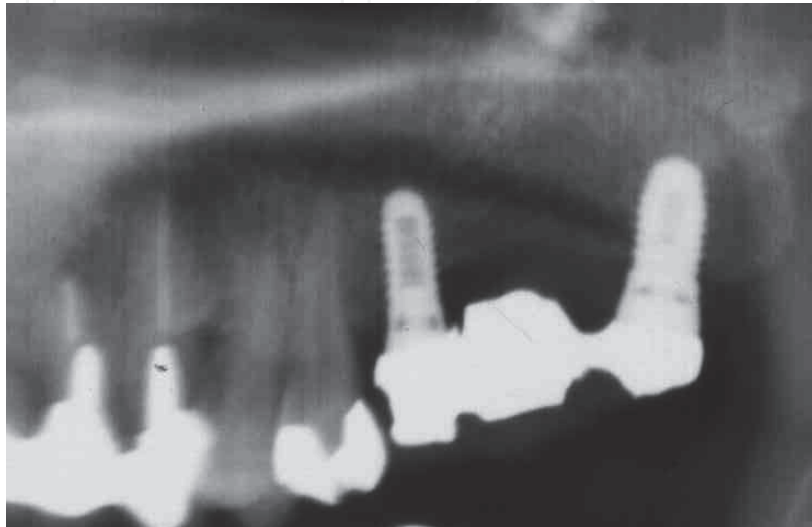


Fig. 1. Radiograph showing slight bone resorption around the implants.

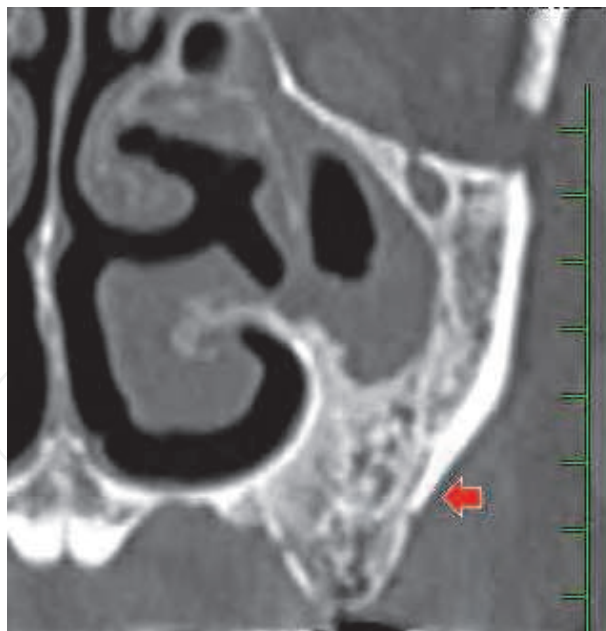


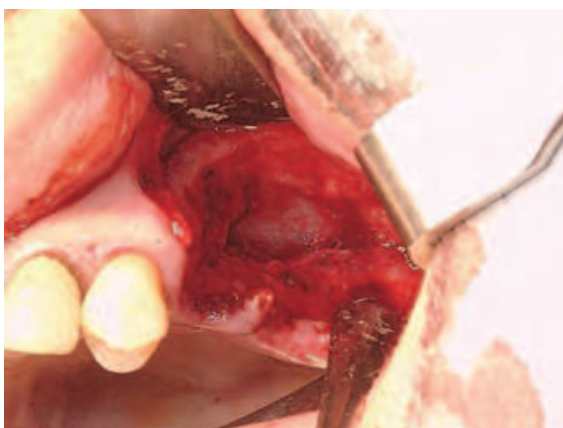
Fig. 2. Computed tomography (CT) image around the implants (arrow).

2.2 Diagnosis and treatment

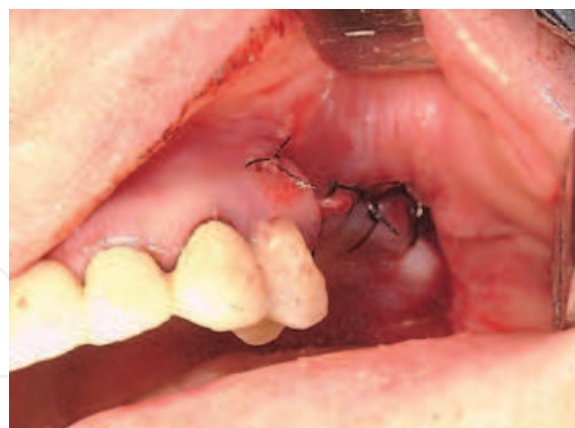It is well-known that curative chemotherapy or long-term adrenocortical steroid administration for lymphoblastic leukemia and Hodgkin and non-Hodgkin lymphomas induces osteonecrosis of the femoral head (Kubo et al. 2001; Bojko et al 2003; Karimova et al.

2008). Many anticancer drugs were administered for breast cancer metastasis in this patient, but no osteonecrosis of the jaw caused by these drugs has been reported. In addition, the clinical symptoms of this patient met all diagnostic criteria of BRONJ proposed by AAOMS (AAOMS 2007; Ruggiero et al. 2009). Based on these findings, BP-induced osteonecrosis was diagnosed.

In the treatment, morbid bone tissue including implants was resected in consideration of the following 3 conditions: 1) early chemotherapy for metastatic cancer was necessary, for which removal of the infected lesion was necessary, 2) there was a possibility that continuation of the withdrawal of BPs would aggravate metastatic cancer-associated bone destruction and hypercalcemia, and 3) it was difficult to remit inflammation by employing conservative treatment proposed by the American Association of Oral and Maxillofacial Surgeons (AAOMS 2007; Ruggiero et al. 2009). After considering these points, sequestrectomy of the left maxilla was selected. The gingival margin was incised between the upper left first premolar and implant towards the maxillary tuberosity, and the lesion area was exposed by forming a buccal and palatal mucoperiosteal flap. The bone cortex of the lesion was brownish black, and necrotic bone was confirmed between the distal surface of the second premolar and mesial surface of the implant placed in the second molar area, but particularly around the implant placed in the first molar area (Fig.3a). The area for resection around the living bone in the lesion was determined after the extraction of the second premolar, and the pathological bone tissue including the implant was removed with a Lindeman bar and bone chisel, followed by the grinding of the bone surface of the resection stump until bleeding was confirmed. As a result, the instrument partially perforated the maxillary sinus floor, and the thickened maxillary sinus mucosa was exposed. This sinus mucosa was spared, and the surgical wound was completely closed by suturing the mucoperiosteal flaps (Fig.3b)



(a) Pathological bone including the implants was removed, and maxillary sinus mucosa was exposed.



(b) The surgical wound was completely closed by suturing the mucoperiosteal flap.

Fig. 3. Intraoperative view of the sequestrectomy of the left maxilla.

After surgery, antibiotic was intravenously administered for 3 days and oral antibiotic was administered for 3 days. In addition, hyperbaric oxygen therapy was performed. The efficacy of hyperbaric oxygen therapy for BRONJ is controversial (Ruggiero et al. 2004; Freiberger et al 2009), but, at least, it may be effective to promote mucoepithelial wound healing in the

sequestration-resected region. The wound was completely covered with healthy mucosa 2 weeks after surgery (Fig.4.). Since the remission of inflammation could be confirmed, anticancer drug and BP administration was initiated for metastatic cancer and bone metastasis-associated bone destruction. The patient died of multiorgan failure associated with multiple cancer metastasis 8 months after surgery, but BRONJ did not recur before death.

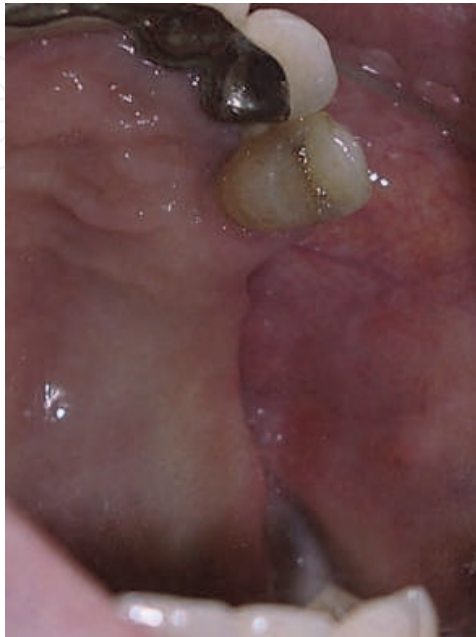

Fig. 4. Intraoral view at 4 weeks after surgery.

2.3 Macroscopic and μ CT findings of the resected specimen

Implants were strongly fixed to the bone, and areas of brown sequestration were observed around them (Fig.5.). On μ CT, no apparent abnormality, such as trabecular destruction, was observed, and the implant surface was in direct contact with the trabecula at various sites (Fig.6.).

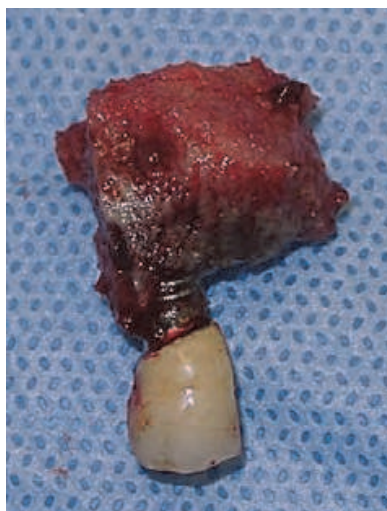

Fig. 5. The resected specimen shows a portion of the left maxilla including two implants.

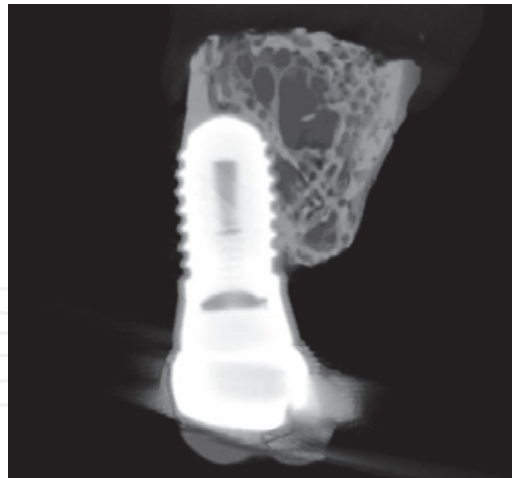


Fig. 6. μ CT findings of the resected specimen.

2.4 Histopathological analysis

2.4.1 Histologic preparation

The resected specimen was divided into the lesion including the implants and peri-lesion, i.e., healthy tissue in the resected stump. The bone tissue around the implants was fixed, dehydrated, and embedded in polyester resin (Ligorac®, Wako Pure Chemical Industries, Ltd., Tokyo, Japan). Undecalcified ground sections 15 μ m in thickness were cut along the long axis of the implant using the EXAKT Cutting-Grinding System (EXAKT, Norderstedt, Germany) and stained with 1% toluidine blue (pH 7.2), then the bone tissue around the implant was observed under light microscopy. Meanwhile, the bone tissue around the lesion was dehydrated and embedded in paraffin according to the conventional procedure. Some of the sections were stained with hematoxylin-eosin (HE) and AZAAN. Other sections were processed for immunohistochemical analysis by immunostaining with anti-human CD3, CD20, CD45 and CD68 (Daco, Carpinteria, CA).

2.4.2 Peri-implant histopathological findings in undecalcified ground sections

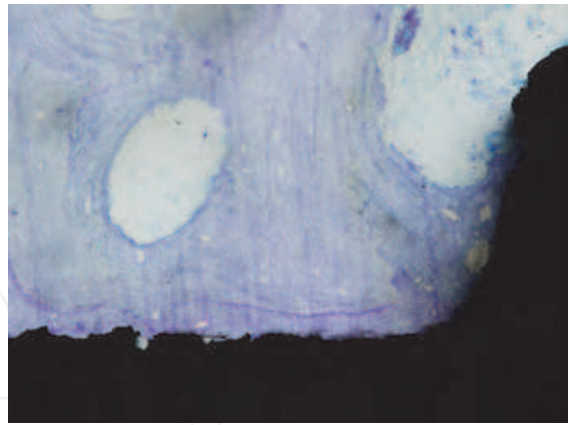
The implant surface was mostly in direct contact with bone tissue, suggesting that osseointegration was maintained until BRONJ development (Fig.7a). No osteocyte was present in the cavity of bone contacting implants or the surrounding trabeculae, nor were there cellular components on the bone surface, and bone tissue mostly showed sequestration (Fig.7b). The marrow cavity was filled with aggregates of actinomycete-like microorganisms, neutrophils, and other necrotized soft tissue (Fig.8a). In addition, adsorption cavities with a worm-eaten appearance were widely present. Normally, bone tissue necrotized in the body is absorbed by osteoclasts, shows sequestration, and is naturally excreted. However, no osteoclasts were present in the resorption cavity, suggesting that active resorption of the bone occurred in the BRONJ developmental process, rather than the resorption of necrotized bone by osteoclasts (Fig.8b).

2.4.3 Histopathological findings around lesions in decalcified sections

Osteocytes were present in the bone cavity (Fig.9a,b). The trabecular surface was smooth, and osteoid formation and osteoblast arrangement were observed. Reactive bone formation was also observed at various trabecular sites. Granulation tissue rich in capillary blood




(a) Most of the implant surfaces are in direct contact with the bone ($\times 40$).

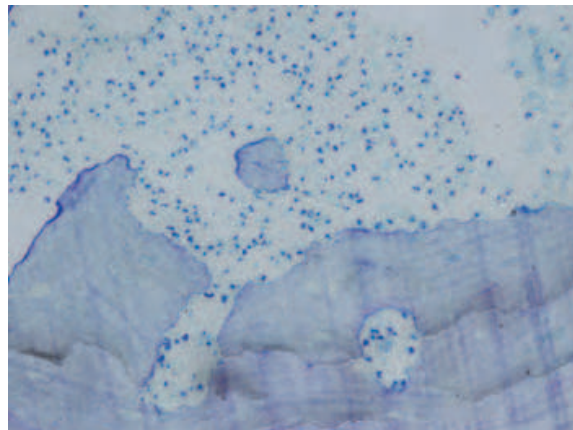


(b) The bone in contact with the implant surface is necrotic ($\times 200$).

Fig. 7. Histological findings of the tissue from the implants in an undecalcified sections stained with toluidine blue.



(a) Growth of a bacterial colony into the marrow cavity is observed ($\times 200$).



(b) Marked bone destruction with a moth eaten appearance is observed on the necrotic trabecular bone surface ($\times 200$).

Fig. 8. Histological findings of the tissue from the implants in an undecalcified sections stained with toluidine blue.

vessels invaded the bone marrow region (Fig.10a,b). On immunohistological staining, lymphocytes infiltrating the bone marrow were mostly CD3-positive, showing that the cells were derived from T cells. In contrast, only a few lymphocytes were positive for CD20 and CD45 (Fig.11a,b), but they were considered not to be significant. Multinucleated giant cells strongly positive for CD68, assumed to be osteoclasts, were present at various sites on the trabecular surface (Fig.12a,b).

3. Discussion on the peri-implant BRONJ developmental mechanism

No viewpoint regarding the pathogenesis of BRONJ has been established. Based on clinical experience, mucosal injuries caused by poorly fitting dentures and oral surgical treatment, such as that for periodontal disease and tooth extraction, have been reported as local risk factors, but this patient received no surgical dental treatment during the BP administration

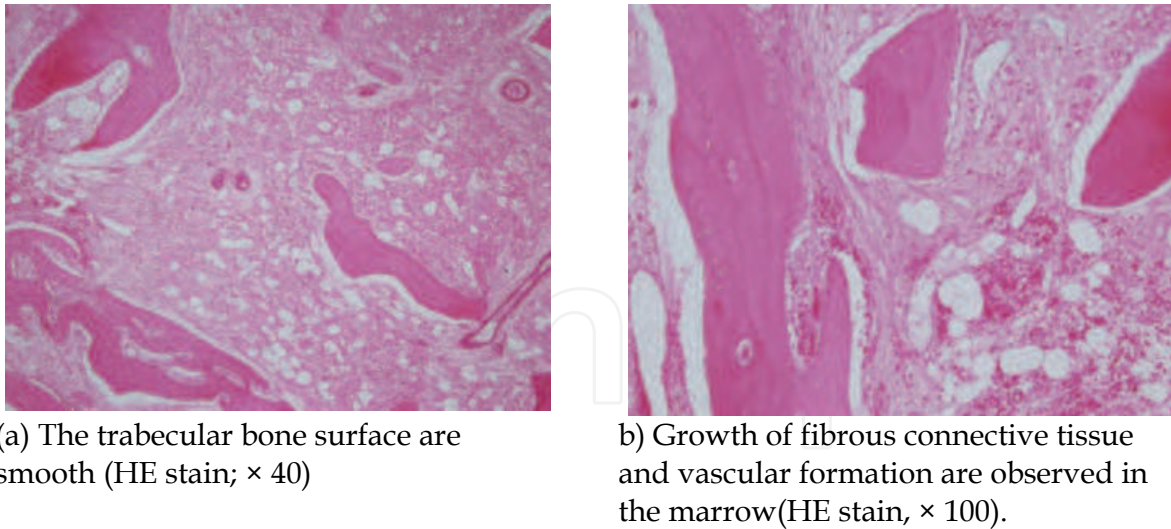


Fig. 9. Histological findings of the tissue around the lesion in a decalcified thin section.

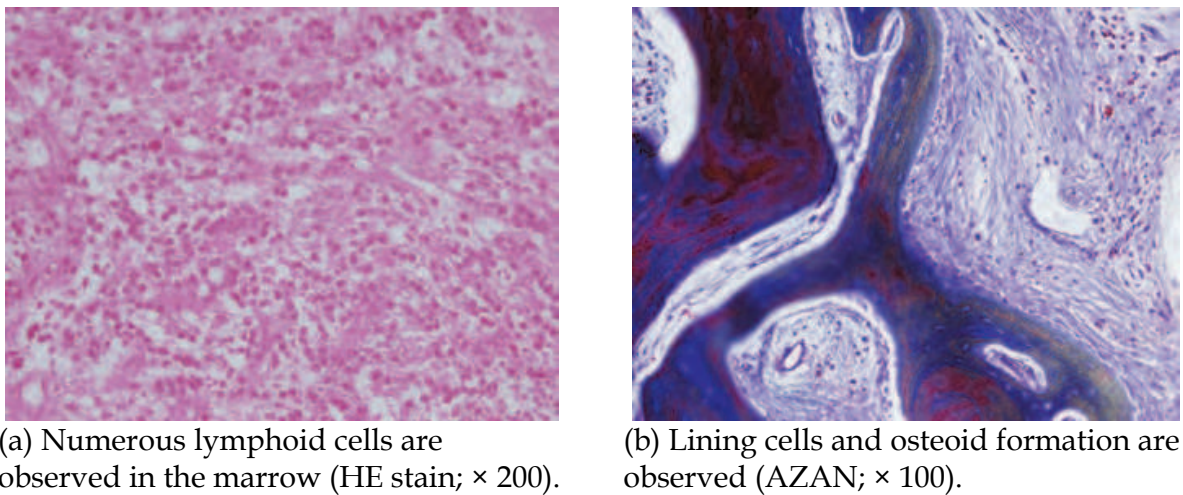


Fig. 10. Histological findings of the tissue around the lesion in a decalcified thin section.

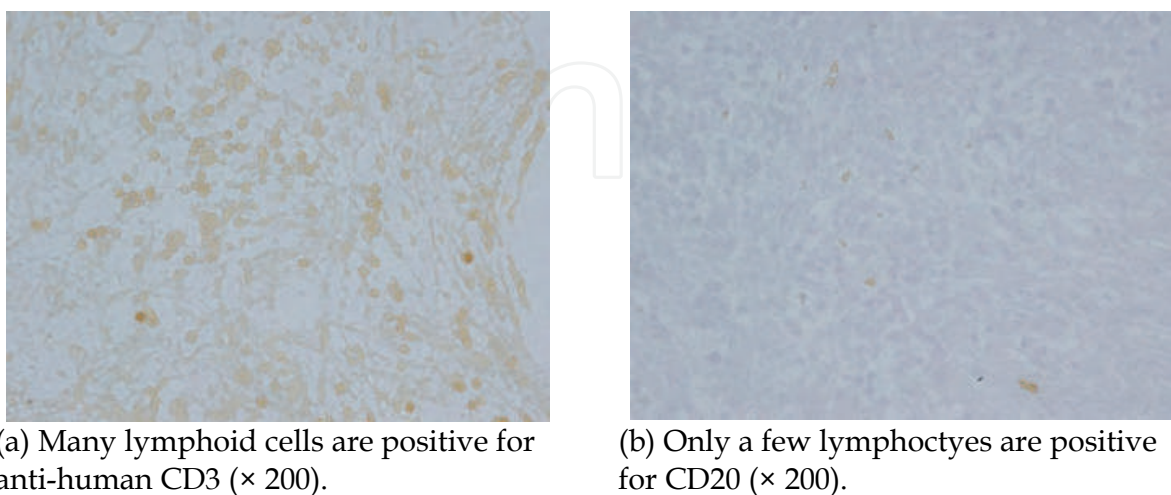


Fig. 11. Immunohistological staining of the tissue around the lesion in a decalcified thin section.

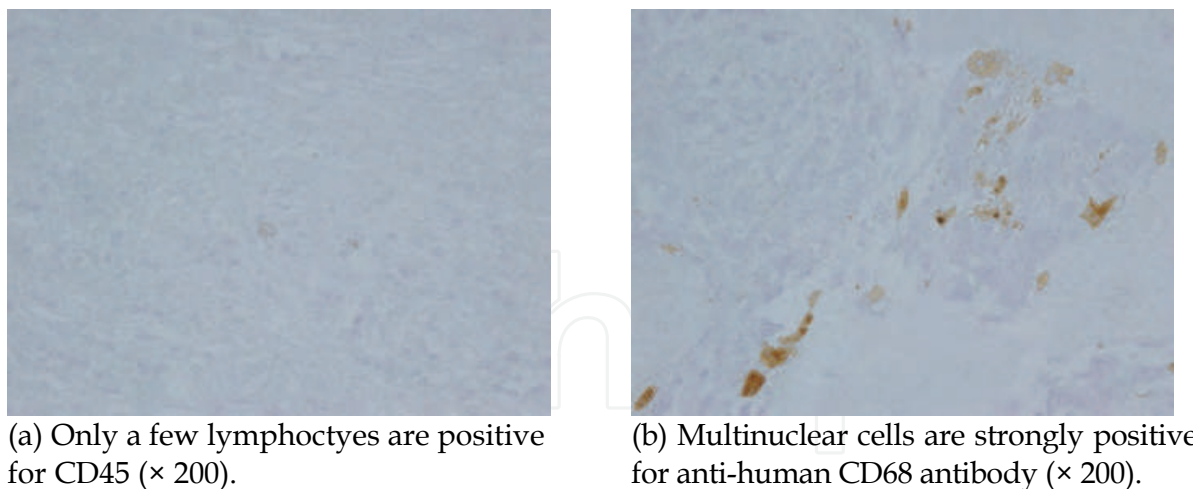


Fig. 12. Immunohistological staining of the tissue around the lesion in a decalcified thin section.

period, and no implant mobility was observed in the BRONJ site. Histologically, osseointegration was widely maintained on the implant surface, and no deep overgrowth of gingival epithelium was noted, suggesting that BRONJ in this patient suddenly occurred around favorably functioning implants, and was not induced by peri-implant inflammation. Necrosis of the femoral head (Kerachian et al. 2006) and irradiation-induced osteonecrosis of the jaw (Marx 1983) are widely known as osteonecrotic lesions, and the cause is insufficiency of vascular formation in both diseases. Reportedly, zoledronate exhibits a potent vascularization-inhibitory effect (Giraud et al. 2004), and the BP-induced obstruction of blood vessels in bone and necrosis of osteocytes around them have been reported (Hansen et al. 2007). Based on these findings, it is hypothesized that insufficiency of the blood supply is also involved in BRONJ, but, histologically, the absence of vascularization inhibition in BRONJ has been reported (Bedogni et al. 2008). Another important hypothesis suggests an influence of reduced bone remodeling due to the BP-induced inhibition of bone resorption by osteoclasts. It has been reported that osteocyte mortality increases when bone remodeling declines, i.e., BPs reduce bone remodeling, increasing osteocyte death, which is involved in BRONJ (Allen et al. 2009). However, many resorption cavities were present on the peri-implant-sequestered bone surface, and the growth of granulation tissue containing abundant capillary blood vessels and reactive bone formation in the resected stump were confirmed in this patient. Thus, it is difficult to explain the cause of BRONJ with insufficient blood supply and the bone remodeling-inhibitory effect of BPs alone.

Pamidronate and zoledronate administered intravenously to this patient are BPs that incorporate nitrogen. BPs containing nitrogen (NBPs) induce an inflammatory reaction by stimulating cells (Hewit et al. 2005; Endo et al. 1993; Nakamura et al. 1996). NBPs also exist on the surface of gram-negative cell walls, and increase inflammatory reactions to lipopolysaccharide (LPS), which has a strong inflammatory effect (Yamaguchi et al. 2000). Therefore, BRONJ may be caused by interactions among several factors differing among cases, not by a single cause. For example, in this patient, the following conditions may have influenced each other and caused BRONJ: 1) the excessive inhibition of bone turnover due to the NBP-related inhibition of bone resorption; 2) the occlusal force loaded on implants was directly transmitted to the bone, which activated local bone metabolism in the surrounding

region, releasing BP accumulated in the bone at a high level; 3) free NBP-induced inflammatory reactions, induction of osteoclast apoptosis (Roelofs et al. 2006), and inhibition of epithelial activity (Landesberg et al. 2009); 4) increased risk of bacterial infection due to suppression of the immune system; 5) enhanced inflammatory reactions due to interactions between gram-negative bacterial lipopolysaccharides and NBPs and 6) reduced local blood flow by vascularization inhibition and vascular obstruction (Fig.13).

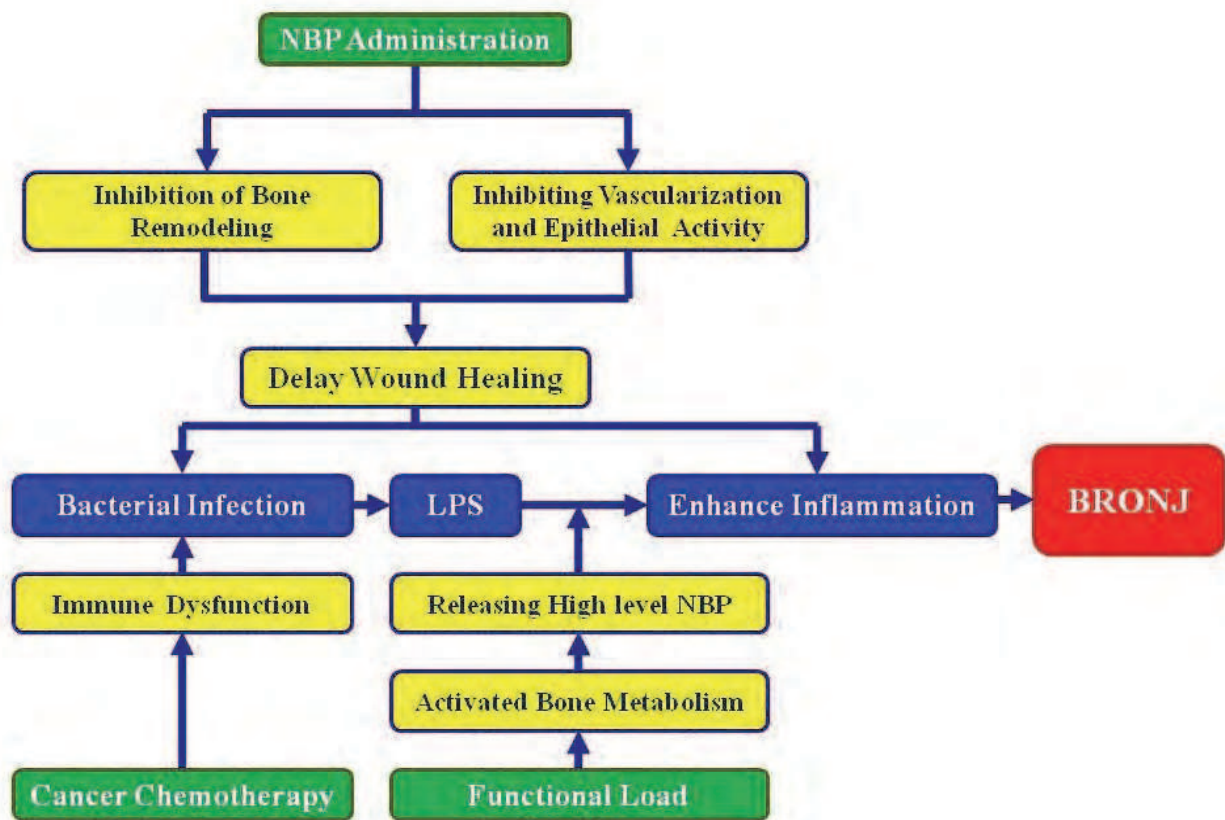


Fig. 13. Hypothetical mechanism of BRONJ around the implants.

4. Conclusion

BRONJ is intractable, and no treatment method has been established. Only guidelines mainly concerning prevention and conservative treatment have been proposed. When peri-implant BRONJ occurs, firstly, conservative treatment should be selected following the AAOMS treatment guidelines, placing great importance on the prevention of exacerbation of BRONJ, but when NBPs are administered to control bone metastasis, it should be a priority to re-start BP administration and prevent any delay in cancer chemotherapy. Accordingly, although the appropriateness and timing of sequestration site resection should be carefully investigated, active surgical treatment may be one choice for some patients. Implant treatment is no longer special treatment. It is widely introduced into routine dental practice as a method to recover the occlusal function of defective teeth. Therefore, NBP intravenous injections will be increasingly administered to patients with a past medical history of implant treatment, for which the establishment of a practical clinical policy for the prevention and treatment of BRONJ is strongly desired.

5. References


- AAOMS. (2007) American association of oral and maxillofacial surgeons position paper on bisphosphonate-related osteonecrosis of the jaws. *The Journal of Oral and Maxillofacial Surgery*, Vol. 67, No.3, (March 2007), pp. 943-950, ISSN 0278-2391
- Allen, M.R. & Burr, D.B. (2009). The pathogenesis of bisphosphonate-related osteonecrosis of the jaw: so many hypotheses, so few data. *The Journal of Oral and Maxillofacial Surgery*, Vol.67 No.5 Supplement 1, (May 2009), pp. 61-70, ISSN 0278-2391
- Bedogni, A., Blandamura, S., Lokmic, Z., Palumbo, C., Ragazzo, M., Ferrari, F., Tregnaghi, A., Pietrogrande, F., Procopio, O., Saia, G., Ferretti, M., Bedogni, G., Chiarini, L., Ferronato, G., Ninfo, V., Lo Russo, L., Lo Muzio, L. & Nocini P.F. (2008). Bisphosphonate-associated jawbone osteonecrosis: a correlation between imaging techniques and histopathology. *Oral Surgery, Oral Medicine, Oral Pathology, Oral Radiology and Endodontology*, Vol. 105, No. 3, (March 2009), pp.358-364, ISSN 1079-2104
- Bell, B.M., & Bell, R.E. (2008). Oral bisphosphonates and dental implants: a retrospective study. *The Journal of Oral and Maxillofacial Surgery*, Vol. 66, No.5, (May 2008), pp.1022-1024, ISSN 1079-2104
- Berenson, J. R., Lichtenstein, A., Porter, L., Dimopoulos, M.A., Bordoni, R., George, S., Lipton, A., Keller, A., Ballester, O., Kovacs, M. J., Blacklock H.A., Bell, R., Simeone, J., Reitsma, D. J., Hefferman, M., Seaman, J. & Knight, R. D. (1996). Efficacy of pamidronate in reducing skeletal event in patients with advanced multiple myeloma. Myeloma Aredia Study Group. *The New England Journal of Medicine*, Vol. 334, No. 8, (February 1996), pp.488-493, ISSN 0028-4793
- Body, J. J., Lortholary, A., Romieu, G., Vigneron, A. M. & Ford, J. (1999). A dose-finding study of zoledronate in hypercalcemic cancer patients. *Journal of Bone and Mineral Research*, Vol.14, No.19, (September 1999), pp.1557-61, ISSN 1523-4681
- Bojko, P., Hilger, R.A., Ruehm, S.G., Dirsch, O., Seeber, S. & Scheulen, M.E. (2003). Femoral head necrosis in three patients with relapsed ovarian cancer receiving high-dose chemotherapy followed by autologous peripheral blood stem cell transplantation. *Bone Marrow Transplantation*, Vol. 31, No.6, (March 2003), pp.487-491, ISSN 0268-3369
- Endo, Y., Nakamura, M., Kikuchi, T., Shinoda, H., Takeda, Y., Nitta, Y. & Kumagai, K. (1993) Aminoalkylbisphosphonates, potent inhibitors of bone resorption, induce a prolonged stimulation of histamine synthesis and increase macrophages, granulocytes, and osteoclasts in vivo. *Calcified Tissue International* Vol.52, No.3, (March 1993), pp.248-254, ISSN 0171-967X
- Fleisch, H., Reszka, A., Rodan, G. & Rogers, M. (2002). Bisphosphonates: Mechanisms of action, *Principles of Bone Biology*, Bilezikian, J. P., Raisz, L. G. & Rodan, G.A., pp. 13161-1385, Academic Press, ISBN 012-0986-523, San Diego
- Freiberger, J.J. (2009). Utility of hyperbaric oxygen in treatment of bisphosphonate-related osteonecrosis of the jaws. *The Journal of Oral Maxillofacial Surgery*. Vol.67, No.5 Supplement 1, (March 2009), pp.96-106, ISSN 1079-2104
- Fugazzotto, P.A., Lightfoot, W.S., Jaffin, R. & Kumar, A. (2007). Implant placement with or without simultaneous tooth extraction in patients taking oral bisphosphonates: postoperative healing, early follow-up, and the incidence of complications in two

- private practices. *Journal of Periodontology*, Vol.78, No.9, (September 2007), pp.1664-1669 ISSN 0022-3492
- Giraud, E., Inoue, M. & Hanahan, D. (2004). An amino-bisphosphonate targets MMP-9-expressing macrophages and angiogenesis to impair cervical carcinogenesis. *The Journal of Clinical Investigation*, Vol.114, No.5, (September 1 2004), pp.623-633, ISSN, 0021-9738
- Grant, B.T., Amenedo, C., Freeman, K. & Kraut RA. (2008). Outcomes of placing dental implants in patients taking oral bisphosphonates: a review of 115 cases. *The Journal of Oral and Maxillofacial Surgery*, Vol. 66, No.2, (February 2008), pp.223-230, ISSN 0278-2391
- Hansen, T., Kunkel, M., Springer, E., Walter, C., Weber, A., Siegel, E. & Kirkpatrick, C.J. (2007). Actinomycosis of the jaws--histopathological study of 45 patients shows significant involvement in bisphosphonate-associated osteonecrosis and infected osteoradionecrosis *Virchows Archiv* Vol.451, No.6, (December 2007), pp.1009-1017, ISSN 0945-6317
- Hewit, R.E., Lissina, A., Green, A.E., Slay, E.S., Price, D.A. & Sewell, D.A. (2005) The bisphosphonate acute phase response: rapid and copious production of proinflammatory cytokines by peripheral blood gd T cells in response to aminobisphosphonates is inhibited by statins. *Clinical Experimental Immunology*, Vol.139, No.1, (January 2005), pp.101-111, ISSN 0009-9104
- Hortobagyi, G. N., Theriault, R. L., Lipton, A., Porter, L., Blayney, D., Sinoff, C., Wheeler, H., Simeone, J. F., Seaman, J. J., Knight, R. D., Heffernan, M., Mellars, K. & Reitsma, D. J. (1998). Long-term prevention of skeletal complications of metastatic breast cancer with pamidronate. Protocol 19 Aredia Brest Cancer Study Group. *Journal of Clinical Oncology*, Vol.16, No.6, (June 1998), pp.2038-2044, ISSN 0732-183X
- Karimova, E.J., Rai, S.N., Wu, J., Britton, L., Kaste, S.C. & Neel, M.D. (2008). Femoral resurfacing in young patients with hematologic cancer and osteonecrosis. *Clinical Orthopaedics Related Research*, Vol. 466, No. 12, (December 2008), pp.3044-3050, ISSN 1528-1132
- Kerachian, M.A., Harvey, E. J., Cournoyer, D., Chow, T.Y. & Séguin C. (2006). A vascular necrosis of the femoral head: vascular hypotheses. *Journal of Endothelial Cell Research*, Vol.23, No. 4, (July-August 2006), pp.237-244, ISSN 1062-3329
- Khan, A.A., Sándor, G.K., Dore, E., Morrison, A.D., Alsahli, M., Amin, F., Peters, E., Hanley, D.A., Chaudry, S.R., Dempster, D.W., Glorieux, F.H., Neville, A.J., Talwar, R.M., Clokie, C.M., Al Mardini, M., Paul, T., Khosla, S., Josse, R. G., Sutherland, S., Lam, D.K., Carmichael, R.P., Blanas, N., Kendler, D., Petak, S., St-Marie, L.G., Brown, J., Evans, A.W., Rios L. & Compston, J.E.; Canadian Association of Oral and Maxillofacial Surgeons. (2008). Canadian consensus practice guidelines for bisphosphonate associated osteonecrosis of the jaw. *The Journal of Rheumatology*, Vol.35, No.7, (July 2008), pp.1391-1397, ISSN 0315-162X
- Khosla, S., Burr, D., Cauley, J., Dempster, D.W., Ebeling, P.R., Felsenberg, D., Gagel, R.F., Gilsanz, V., Guise, T., Koka, S., McCauley, L.K., McGowan, J., McKee, M.D., Mohla, S., Pendrys, D.G., Raisz, L.G., Ruggiero, S.L., Shafer, D.M., Shum, L., Silverman, S.L., Van Poznak, C.H., Watts, N., Woo, S.B. & Shane, E.; American Society for Bone and Mineral Research. (2007). Bisphosphonate-associated osteonecrosis of the jaw: Report of a task force of the American Society for Bone

- and Mineral Research. *Journal of Bone and Mineral Research*, Vol.22, No. 10, (October 2007), pp.1479-1491, ISSN 1523-4681
- Kubo, T., Kojima, A., Yamazoe, S., Ueshima, K., Yamamoto, T. & Hirasawa, Y. (2001). Osteonecrosis of the femoral head that developed after long-term topical application. *Journal of Orthopaedic Science*, Vol.6, No.1, (January 2001), pp.92-94, ISSN 0949-2658
- Landesberg, R., Eisig, S., Fennoy, I. & Siris, E. (2009). Alternative indications for bisphosphonate therapy. *The Journal of Oral and Maxillofacial Surgery*, Vol.67, No.5 Supplement 1, (May 2009), pp.27-34, ISSN 1079-2104
- Marx, R. E. (1983). Osteonecrosis: a new concept of its pathophysiology. *The Journal of Oral and Maxillofacial Surgery*, Vol.41, No.5, (May 1983), pp. 283-288, ISSN 1079-2104
- Marx, R. E. (2003). Pamidronate (Aredia) and Zoledronate (Zometa) Induced Avascular Necrosis of the Jaws: A growing epidemic. *Journal of Oral and Maxillofacial Surgery*, Vol.61, No.9, (September 2003), pp.1115-1117, ISSN 1079-2104
- Marx, R. E., Sawatari, Y., Fortin, M. & Broumand, N. (2005). Bisphosphonate-induced exposed bone (osteonecrosis/osteopetrosis) of the jaws. *Journal of Oral and Maxillofacial Surgery*, Vol.63, No.11, (November 2005), pp.1567-1575, ISSN 1079-2104
- Migliorati, C.A., Casiglia, J., Epstein, J., Jacobsen, P.L., Siegel, M.A. & Woo, S.B. (2005). Managing the care of patients with bisphosphonate-associated osteonecrosis: an American Academy of Oral Medicine position paper. *Journal of the American Dental Association*, Vol.136, No.12, (December 2005), pp.1658-68, ISSN 0002-8177
- Nakamura, M., Ando, T., Abe, M., Kumagai, K & Endo, Y. (1996) Contrast between effects of aminobisphosphonates and non-aminobisphosphonates on collagen-induced arthritis in mice. *British Journal of Pharmacology*, Vol.119, No.2, (September 1996), pp.205-212, ISSN 1476-5381
- Roelofs, A.J., Thompson, K., Gordon, S. & Rogers, M.J. (2006). Molecular mechanisms of action of bisphosphonates: current status. *Clinical Cancer Research*, Vol.12, No.20 Pt 2, (October 2006), pp.6222s-6230s, ISSN1557-3265
- Ruggiero, S. L., Mehrotra, B., Rosenberg, T.J. & Engroff, S. L. (2004). Osteonecrosis of the Jaws associated with the use of bisphosphonates: a review of 63 cases. *The Journal of Oral and Maxillofacial Surgery*, Vol.62, No.5, pp.527-534, ISSN 1079-2104
- Ruggiero, S.L., Dodson, T.B., Assael, L.A., Landesberg, R., Marx, R.E. & Mehrotra, B.; American Association of Oral and Maxillofacial Surgeons. (2009). American Association of Oral and Maxillofacial Surgeons Position Paper on Bisphosphonate-Related Osteonecrosis of the Jaws - 2009 update. *The Journal of Oral and Maxillofacial Surgery*, Vol.67, No.5 Supplement, pp.2-12, ISSN 1079-2104
- Russell, R.G., Xia, Z., Dunford, J.E., Oppermann, U., Kwaasi, A., Hulley, P.A., Kavanagh, K.L., Triffitt, J.T., Lundy, M.W., Phipps, R.J., Barnet, B.L., Coxon, F.P., Rogers, M.J., Wattss, N.B. & Ebetino, F.H. (2007). Bisphosphonates an update on mechanisms of action and how these relate to clinical efficacy. *Annals of the New York Academy of Sciences* Vol.1117, (November 2007), pp.209-257, ISSN 1749-6632
- Shirota, T., Nakamura, A., Matsui, Y., Hatori, M., Nakamura, M. & Shintani, S. (2009) Bisphosphonate-related osteonecrosis of the jaw around dental implants in the maxilla: report of a case. *Clinical Oral Implants Research*, Vol.20, No.12, (December 2009), pp. 1402-1408, ISSN 0905-7161

- Starck, W.J. & Epker, B.N. (1995). Failure of osseointegrated dental implants after diphosphonate therapy for osteoporosis: a case report. *The International Journal of Oral & Maxillofacial Implants*, Vol. 10, No.1, (January-February 1995), pp.74-78, 0882-2786
- Vahtsevanos, K., Kyrgidis, A., Verrou, E., Katodritou, E., Triaridis, S., Andreadis, C.G., Boukovinas, I., Koloutsos, G.E., Teleioudis, Z., Kitikidou, K., Paraskevopoulos, P., Zervas, K. & Antoniadis, K. (2009). Longitudinal cohort study of risk factors in cancer patients of bisphosphonate-related osteonecrosis of the jaw. *Journal of Clinical Oncology*, Vol.27, No.32, (November 2009), pp.5356-5362, ISSN 0732-183X
- Yamaguchi, K., Motegi, K., Iwakura, Y. & Endo, Y. (2000). Involvement of interleukin-1 in the inflammatory actions of aminobisphosphonates in mice. *British Journal of Pharmacology*, Vol.130, No.7, (August 2000), pp.1646-1654, ISSN 1476-5381
- Yoneda, T., Hagino, H., Sugimoto, T., Ohta, H, Takahashi, S., Soen, S., Taguchi, A., Toyosawa, S., Nagata, T. & Urade, M. (2010). Bisphosphonate-related osteonecrosis of the jaw: position paper from the Allied Task Force Committee of Japanese Society for Bone and Mineral Research, Japan Osteoporosis Society, Japanese Society of Periodontology, Japanese Society for Oral and Maxillofacial Radiology, and Japanese Society of Oral and Maxillofacial Surgeons. *Journal of Bone and Mineral Metabolism*, Vol.28, No.4, pp.365-383, ISSN 1435-5604

IntechOpen



Implant Dentistry - A Rapidly Evolving Practice

Edited by Prof. Işer Turkyilmaz

ISBN 978-953-307-658-4

Hard cover, 544 pages

Publisher InTech

Published online 29, August, 2011

Published in print edition August, 2011

Implant dentistry has come a long way since Dr. Branemark introduced the osseointegration concept with endosseous implants. The use of dental implants has increased exponentially in the last three decades. As implant treatment became more predictable, the benefits of therapy became evident. The demand for dental implants has fueled a rapid expansion of the market. Presently, general dentists and a variety of specialists offer implants as a solution to partial and complete edentulism. Implant dentistry continues to evolve and expand with the development of new surgical and prosthodontic techniques. The aim of *Implant Dentistry - A Rapidly Evolving Practice*, is to provide a contemporary clinic resource for dentists who want to replace missing teeth with dental implants. It is a text that relates one chapter to every other chapter and integrates common threads among science, clinical experience and future concepts. This book consists of 23 chapters divided into five sections. We believe that, *Implant Dentistry: A Rapidly Evolving Practice*, will be a valuable source for dental students, post-graduate residents, general dentists and specialists who want to know more about dental implants.

How to reference

In order to correctly reference this scholarly work, feel free to copy and paste the following:

Tatsuo Shirota, Atsushi Nakamura, Yoshiro Matsui, Masashi Hatori, Masanori Nakamura and Satoru Shintani (2011). Bisphosphonate-Related Osteonecrosis of the Jaw Around Dental Implants, *Implant Dentistry - A Rapidly Evolving Practice*, Prof. Işer Turkyilmaz (Ed.), ISBN: 978-953-307-658-4, InTech, Available from: <http://www.intechopen.com/books/implant-dentistry-a-rapidly-evolving-practice/bisphosphonate-related-osteonecrosis-of-the-jaw-around-dental-implants>

INTECH
open science | open minds

InTech Europe

University Campus STeP Ri
Slavka Krautzeka 83/A
51000 Rijeka, Croatia
Phone: +385 (51) 770 447
Fax: +385 (51) 686 166
www.intechopen.com

InTech China

Unit 405, Office Block, Hotel Equatorial Shanghai
No.65, Yan An Road (West), Shanghai, 200040, China
中国上海市延安西路65号上海国际贵都大饭店办公楼405单元
Phone: +86-21-62489820
Fax: +86-21-62489821

© 2011 The Author(s). Licensee IntechOpen. This chapter is distributed under the terms of the [Creative Commons Attribution-NonCommercial-ShareAlike-3.0 License](#), which permits use, distribution and reproduction for non-commercial purposes, provided the original is properly cited and derivative works building on this content are distributed under the same license.

IntechOpen

IntechOpen