

We are IntechOpen, the world's leading publisher of Open Access books Built by scientists, for scientists

4,800

Open access books available

122,000

International authors and editors

135M

Downloads

Our authors are among the

154

Countries delivered to

TOP 1%

most cited scientists

12.2%

Contributors from top 500 universities



WEB OF SCIENCE™

Selection of our books indexed in the Book Citation Index
in Web of Science™ Core Collection (BKCI)

Interested in publishing with us?
Contact book.department@intechopen.com

Numbers displayed above are based on latest data collected.

For more information visit www.intechopen.com



Crestal Bone Level Alterations in Implant Therapy

Theofilos Koutouzis

*University of Florida, College of Dentistry, Department of Periodontology
United States*

1. Introduction

Tooth restorations using implant-supported prostheses for functional and esthetic rehabilitation of patients has become an established and widely used treatment modality in modern dentistry. Preservation of peri-implant bone is one important factor for success. The quantity and quality of the bone surrounding an implant not only affect implant osseointegration, but also influence the shape and contour of the overlying soft tissues, which are important for the esthetic outcome of treatment. Therefore, assessment of peri-implant marginal bone levels has become an integral part of the evaluation of the implant patient. Different evaluation protocols and success criteria based on marginal bone level changes have been described in the literature. Radiographic techniques including panoramic tomography and intra-oral radiography using long cone paralleling techniques have been widely used to monitor marginal bone levels at implants and diagnose interproximal bone loss (Kullman et al. 2007). Here the distance from a fixed reference point (e.g. implant shoulder or implant-abutment junction) to the inter-proximal bone level is recorded at baseline and monitored longitudinally. In numerous studies baseline radiographs are taken at the time of prosthesis installation, where any marginal bone level changes which occurred at the period between implant installation and prosthesis installation are not taken into account. While a panoramic tomograph allows the entire implant to be visualized limitations including image resolution and distortion are well known (Åkesson et al. 1993, De Smet et al. 2002). Further limitations of conventional radiography include the inability to monitor facial and lingual/palatal bone levels, low sensitivity in the detection of early bone changes and the underestimation of bone loss (Brägger et al. 1988, De Smet et al. 2002). Recently, multi-slice computer tomography (CT) and cone beam volume imaging have been used in implant dentistry offering the advantage that osseous structures can be represented in three planes, true to scale and without overlay or distortion (Mengel et al. 2006).

2. The effect of surgical protocols on crestal bone level alteration

The evolution of implant dentistry has lead to treatment protocols and approaches that differ substantially to the ones that utilized at the initial stages of implantology. Treatment modifications on stages of implant surgery, load timing and implant placement in grafted sockets have been introduced and utilized extensively the two last decades. In addition factors related to treatment planning such as inter-implant, tooth-implant distances and

supra-crestal, crestal and subcrestal placement of the implant-abutment interface can have effects on crestal bone level alterations around implants.

2.1 One versus two-stage implant surgery

One stage implant surgery refers to placement of a healing abutment following implant installation that remains transmucosally and exposed to the oral cavity following replacement of the mucoperiosteal flaps (Figure 1). In contrast, during two-stage implant surgery a cover screw is placed following implant installation and the implant is completely submerged following suturing of the flaps. Three to six months later the implant is uncovered with a second surgical procedure and a healing abutment is placed allowing the peri-implant mucosa to heal.

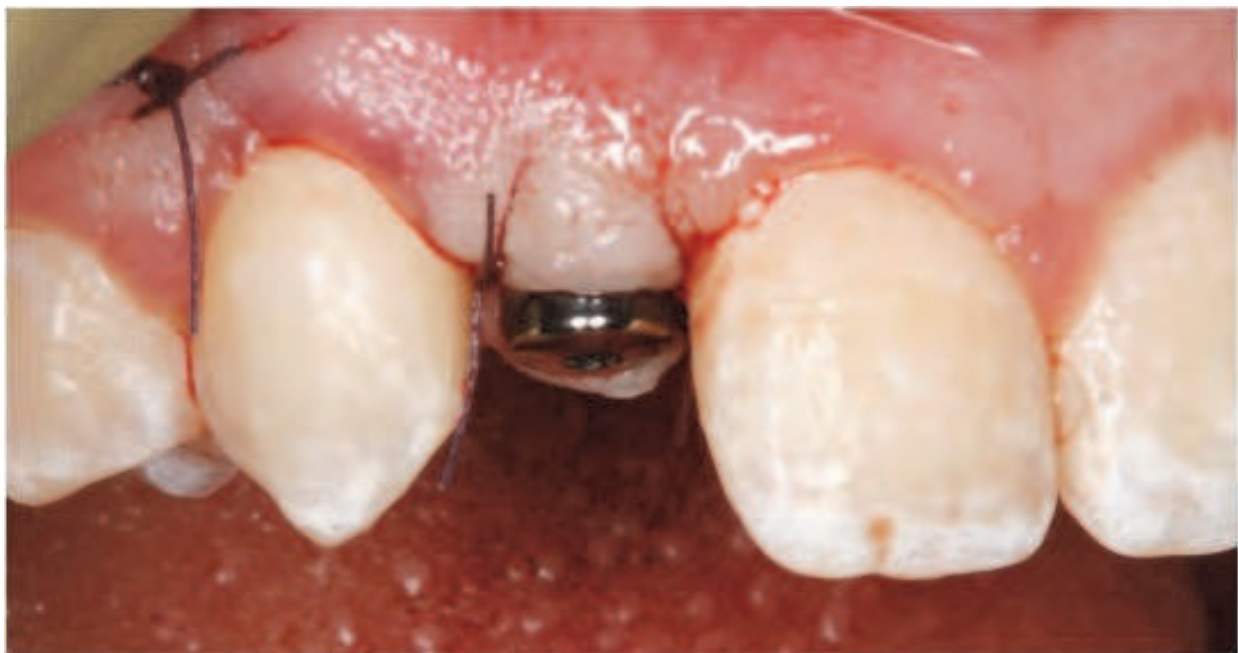

Fig. 1. Healing abutment remains transmucosal at the one-stage implant surgery

The effect of one-stage and two-stage implant surgery on peri-implant mucosa and crestal bone level changes have been evaluated in both experimental and clinical studies. Abrahamsson et al. 1996 in an animal study compared the morphology and the composition of the transmucosal tissue for 3 different implant systems (Astra Tech, Brånemark, Straumann), using either a two-stage (Astra Tech, Brånemark) or one-stage technique (Straumann) over a six-month period. The epithelial and connective tissue components had similar dimensions and composition. All 3 groups exhibited bone loss of around 0.5 mm, the epithelium height was around 2 mm (slight variation among groups, 1.6-2.3 mm) and the connective tissue was roughly 1 mm. The connective tissue consisted of 86% collagen and 8% fibroblasts, where the collagen fibers were parallel to the surface of the implant. These histological observations suggested that the soft tissue seal has the same characteristics using these implants systems. Similarly, in a following study (Abrahamsson et al. 1999) no histological and radiographical differences were found between implants of one system (Astra Tech) placed with different installation techniques (one-stage vs two-stage).

Although there is a large number of clinical studies and reports for implants placed with one-stage or two-stage surgical techniques, there are few studies which directly compare

these two techniques. Åstrand et al. 2004 in a split-mouth clinical study compared implants placed with one-stage (ITI, TPS solid screws) and two-stage (Brånemark) surgical technique supporting maxillary screw-retained fixed partial dentures for 3 years. No statistically significant differences were found between the implants studied (regarding bone level changes and survival rates), except for the frequency of periimplantitis, which was higher for the ITI implants. Similar findings were reported in another clinical study comparing implants placed with one-stage (ITI, TPS hollow screws) and two-stage surgical technique (Brånemark) supporting mandibular fixed partial dentures over a 3 year time period (Momberg et al. 2001). After 3 years, the cumulative success rates were 97.9% and 96.8% for the Brånemark and ITI systems, respectively. Kemppainen et al. 1997 with a parallel group design study compared Astra Tech implants placed with a two-stage surgical technique versus ITI hollow cylinders placed with a one-stage surgical technique for single tooth replacement for 1 year. Again, there were no statistically significant differences in failures and marginal bone level changes between the implant systems and surgical protocols after 1 year of function (mean marginal bone loss was 0.13 mm for Astra Tech implants and 0.11 mm for ITI implants).

It appears that using one-or two-stage surgical techniques have no clinically significant effect on success, survival rates and marginal bone levels. However, one has to consider that the one-stage technique has less morbidity for the patients since it involves a single surgical procedure, but the two-stage surgery might offers greater potential for soft tissue management.

2.2 Load timing and marginal bone level changes

Healing associated with oral endosseous titanium implants is based on osseointegration or 'functional ankylosis' (Brånemark et al. 1969). It has been advocated that after implant placement, surgical sites should be undisturbed for at least 3-6 months to allow uneventful wound healing, thereby enhancing osseointegration between the implant and the bone (Adell et al. 1981). The rationale behind this approach is that implant micro-movements caused by functional forces during wound healing may induce fibrous tissue formation rather than bone contact, leading to clinical failure (Adell et al. 1981). Micromovements of more than 100µm were reported to be sufficient to jeopardize healing with direct bone to implant contact (Brunski 1993).

Interestingly, several experimental studies have shown that immediate loading of endosseous titanium implants will not necessarily lead to fibrous tissue healing (Henry et al. 1997, Piattelli et al. 1997, 1998, Romanos et al. 2001, Nkenke et al. 2001, 2003). In fact some data have demonstrated that early loading increased bone to implant contact when compared to unloaded controls (Piattelli et al. 1998, Romanos et al. 2001). In addition several clinical studies investigating the efficacy of immediate loading protocols (Esposito et al. 2009, Nkenke et al. 2006, Weber et al. 2009) suggested that immediate loading of endosseous implants might be a realistic protocol in various jawbone regions. However, from the available clinical studies it is not possible to draw definitive conclusions regarding exclusion and inclusion criteria for immediate loading, threshold values for implant stability that permit immediate loading, nor bone quality needed for immediate loading. Moreover, evaluations of implants subjected to immediate loading have been reported mainly on the basis of implant survival without mentioning marginal bone level changes. Evaluation of marginal bone level changes around implants subjected to immediate loading is more

frequently reported for single tooth replacements rather for fixed and complete partial dentures.

The definition of immediate functional loading which was suggested in Consensus Conference Meetings (Aparicio et al. 2003, Cochran et al. 2004) relate to an implant-supported restoration, which is placed in occlusion with the opposing dentition within 48 h from implant placement. In this context, a critical evaluation of publications in the field of single-tooth replacement is required. Thus, despite the use of an immediate or early-cemented crown restoration on an implant, functional loading was applied after an additional period of healing in several studies (Ericsson et al. 2000, Chaushu et al. 2001, Andersen et al. 2002, Malo et al. 2003, Norton 2004, Ottoni et al. 2005). There are a few studies on immediate functional loading of implants used for single-tooth replacement (Calandriello et al. 2003a, 2003b, Cannizzaro & Leone 2003, Glauser et al. 2003, Lindeboom et al. 2006). The majority of these studies were prospective cohort studies and included between 20 and 50 subjects/implants. Cannizzaro & Leone 2003 compared 23 single-tooth implants that were subjected to immediate loading along with 24 implants whose loading was delayed. No implants were lost in the test and control groups at the 2 year follow-up. The radiographic examination revealed that 91.3% of the test implants and 87.5% of the controls showed a marginal bone loss of 1 mm, while 8.7% of the test group and 12.5% of the controls demonstrated marginal bone loss that varied between 1 and 2 mm. Thus, the percentage of implants that had 1 mm of marginal bone loss was higher in the control group than in the test groups. Calandriello et al. 2003a evaluated 20 implants used for single-tooth rehabilitation which were exposed to immediate loading. At the 12-month re-examination, no implants were lost and the mean marginal bone loss was 1.22 mm. In a subsequent prospective multicenter trial, Calandriello et al. 2003b evaluated immediate functional loading of implants used in single-tooth replacement in the molar segments of the mandible. The survival rate recorded at 6 months was 100%, and the overall marginal bone loss was 1.0 mm. Glauser et al. 2003 analyzed 20 implants used for single-tooth replacement with immediate functional loading. No implant loss was recorded at the 12-month evaluation and the mean marginal bone loss was 1.2 mm.

Koutouzis et al. 2011 evaluated the outcome of immediately loaded implants placed with the osteotome technique for single tooth replacements over a 12-month period. Twenty patients in need of oral prosthetic rehabilitation that included single implant placement in the anterior-premolar position participated in this prospective trial. A modified implant installation procedure with an under preparation of the implant bed using the osteotome technique and immediate loading of the implant was performed (Figure 2). Out of the 22 implants placed in 20 patients one implant failed to integrate (4.5%) and was therefore removed 3 months following implant installation. The mean marginal bone loss from the time of implant placement to the 6-month examination was 0.08 mm, while 0.19 mm loss was observed from the time of implant placement to the 12-month examination. The amount of marginal bone loss reported in this study was smaller compared to immediate loaded single implants placed with a conventional site preparation (Calandriello et al. 2003a, 2003b, Glauser et al. 2003).

In conclusion the current literature suggests that immediate loading does not promote marginal bone loss for implants replacing single teeth. Importantly the majority of marginal bone level changes occur during the first 3-6 months of loading with no significant alterations thereafter.

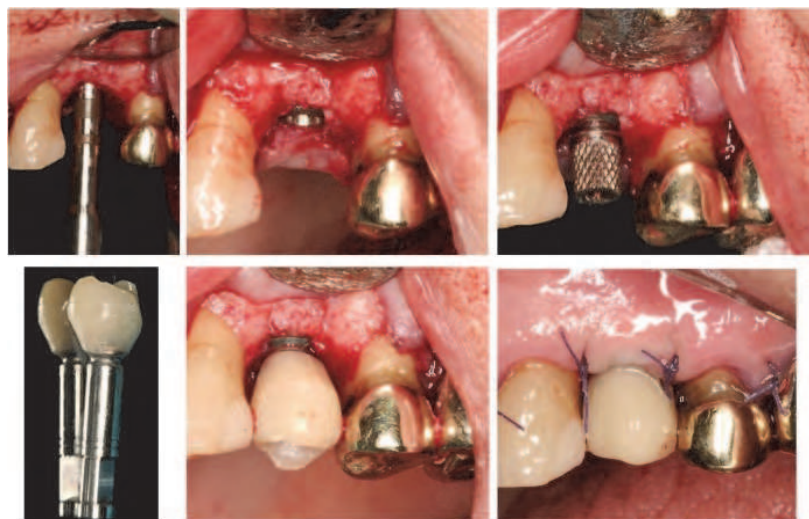


Fig. 2. Implant placement with the osteotome technique and immediately loaded

2.3 Marginal bone level changes around implants placed in grafted sockets.

Following tooth extraction, bone modeling and remodeling characterize the healing of the extraction socket (Carlsson et al. 1967, Araujo & Lindhe 2005) where a reduction in both the height and the width of the alveolar ridge can occur (Pietrokovski & Massler 1967, Johnson 1969, Schropp et al 2003). In an attempt to preserve alveolar bone and to optimize implant installation, several materials have been used to augment the residual extraction socket.

In experimental animal studies, it was demonstrated that several of the biomaterials used were incorporated in newly formed bone, maintained as inactive fillers and slowly resorbed during host tissue remodeling (Araujo et al. 2001, Carmagnola et al. 2002, Cardaropoli et al. 2005). Multiple human histological studies evaluating socket preservation procedures have also described the presence of residual biomaterials for various healing periods (Becker et al. 1998, Artzi et al. 2000, 2001, Iasella et al. 2003, Carmagnola et al. 2003). It was reported that the implanted particles were entrapped in dense connective tissue and thus, potentially interfere with normal extraction healing. This was further exemplified in two human clinical and histologic studies (Becker et al. 1996, 1998) where it was reported that extraction sockets filled with demineralized freeze-dried bone allograft (DFDBA) or freeze-dried bone allograft (FDBA) resulted in retention of graft particles in the fibrous connective tissue and interfered with the healing of the extraction socket. Similar findings were observed by Carmagnola et al. 2003 where extraction sockets were filled with deproteinized bone xenograft (DBX). The authors of this study reported that healing was comprised by increased amount of connective tissue and small amounts of newly formed bone surrounding the graft particles. Conversely, other studies have reported more favorable histologic outcomes for extraction sockets filled with DFDBA, bioactive glass and DBX (Iasella et al. 2003, Froum et al. 2002, Barone et al. 2008).

Several clinical studies (Artzi et al. 2000, 2001, Iasella et al. 2003, Lekovic et al. 1997, 1998, Nevins et al. 2006) utilizing biomaterials to augment socket healing have reported smaller changes in ridge dimensions compared to non-grafted controls thus enhancing the possibility of implant installation in adequate bone volume and in desired positions. However, these studies do not describe implant survival nor implant success rates following the socket preservation procedures. In a systematic review (Fiorellini & Nevins 2003) evaluating dental implant survival rates, the authors concluded that implant survival was

similar between implants placed in native bone and implants placed in sites previously treated with ridge augmentation and preservation techniques. Notably, none of the 13 studies included in the analysis reported on survival rates of implants placed following socket preservation techniques.

There is limited information regarding crestal bone level alterations for implants placed in sockets preserved with various biomaterials. A recent study (Koutouzis et al. 2010) retrospectively compared bone level changes around implants placed in post extraction sockets augmented with DFDBA to implants placed in native bone (Figure 3). The overall survival rate from baseline to the last follow-up visit was 100% for both groups. The mean marginal bone loss was a mean of 0.15 mm for both groups at the 12 month follow-up. There were no significant differences regarding the percentage of implants and implant surfaces demonstrating marginal bone loss.

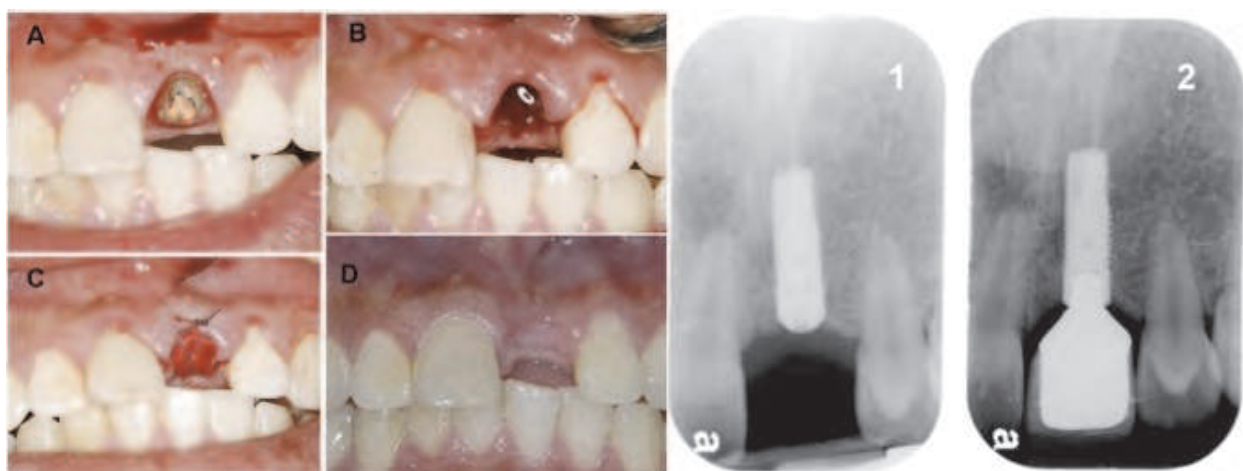

Fig. 3. Clinical photos of tooth #9 A) prior to extraction, B) immediately following extraction, C) following DFDBA and collagen membrane placement, D) 4 months following extraction. Radiographs of implant at the same site 1) at implant installation and 2) one year following implant installation.

In conclusion grafting extraction sockets with various types of biomaterials has a beneficial effect on preserving the dimensions of the edentulous ridge. Although there is variation in histologic findings from animal and human studies regarding the composition of the sites that healed following grafting procedures. This variation may reflect differences in the potential of different grafted materials to regenerate extraction sockets, differences in surgical techniques, the use of barrier membranes and/or differences in healing time. Although there are reports showing that implant survival is similar between implants placed in native bone and implants placed in sites previously treated with ridge augmentation and preservation techniques there is very limited information regarding marginal bone level changes around those implants. From the results of one study it can be concluded that implants placed in post extraction sockets augmented with DFDBA exhibited minimal amount of marginal bone loss, similar to implants placed in native bone.

2.4 The effect of tooth-implant and inter-implant distances on marginal bone level changes

Studies on Brånemark implants placed adjacent to teeth revealed that the inter-unit distance is a risk factor to consider with respect to marginal bone loss at the adjacent tooth (Esposito

et al. 1993, Andersson et al. 1998, Thilander et al. 2001). In these studies there was a large variation in bone loss between subjects and that the recorded bone loss differed significantly between anterior and posterior tooth regions. Furthermore, from radiographic examinations of young individuals who received their single implant therapy during adolescent, Thilander et al. 2001 reported 1.4-2.2 mm bone loss between crown cementation and 10-year follow-up at adjacent teeth to single implants placed in incisors position. On the other hand, Esposito et al. 1993 found that the increased bone loss at adjacent teeth was confined to the time period before loading and that no increase in bone loss was detected following the period of functional loading. The latter finding is supported by data from Cardaropoli et al. 2003 and Chang et al. 2010 showing a lack of a relationship between the inter-unit distance and longitudinal marginal bone loss at the proximal tooth surface next to an implant. The later study evaluated implants with a micro-threaded conical portion (Astra Tech).

The horizontal distance between two implants may have an influence on the maintenance of the proximal bone crest level (Figure 4). It was shown in experimental and clinical studies that the inter-implant bone crest level shifted apically when the inter-implant distance decreased. Based on observations made in a cross-sectional study, Tarnow et al. 2000 accredited the more apically located position of the bone crest between implants with less than 3mm of inter-implant distance to the lateral component of the vertical bone loss to the first thread that is common at implants with an external hex design. The proposed explanation, however, was not supported by a 3-year longitudinal study of the same type of implants (Cardaropoli et al. 2003), in which multivariate analysis failed to identify lateral bone loss as a significant factor for longitudinal reduction of the inter-implant bone crest level. Furthermore, animal studies revealed no significant difference in mid-proximal bone crest resorption in relation to the horizontal distance between implants designed with a Morse cone connection and platform switching (Novaes et al. 2006 a & b, de Oliveira et al. 2006). It has been claimed, based on observations of implants placed in the tibia of rabbits, that closely placed implants may favor bone growth between implants (Hatley et al. 2001). However, whether maintenance of the mid-proximal bone crest level may be related to the design of the implant-abutment interface needs to be documented in longitudinal studies.

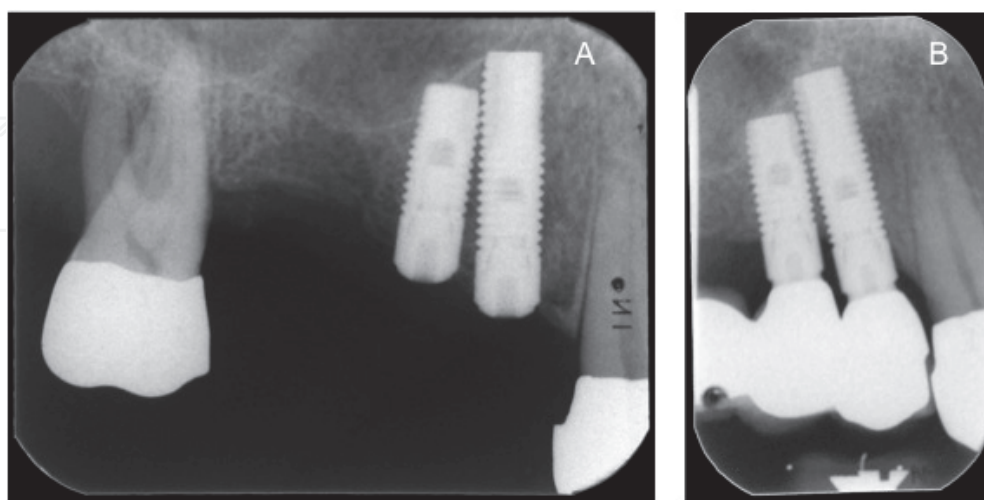


Fig. 4. Radiographs of implants at #4 and #5 position placed with an inter-implant distance less than 3mm. Note the marginal bone loss between implant installation (A) and prosthesis delivery (B).

Taken together one can conclude that the marginal bone level at teeth adjacent to single implants with a micro-threaded conical portion is not influenced by the horizontal and vertical tooth-implant distances. However, this statement cannot be supported for implants with an external-hex design. Loss in height of the mid-proximal bone crest in the inter-implant areas is influenced by the bone loss at the two bordering implants and the horizontal inter-unit distance, although no such relationship is evident for the proximal area between an implant and the adjacent tooth.

2.4 Position of the fixture/abutment interface in relation to the alveolar crest and marginal bone level changes

The location of the fixture/abutment interface (FAI) can be placed in various positions in relation to the alveolar crest (crestal, supracrestal, subcrestal) (Figure 5). The location of the FAI can be of major importance when the goal is to construct aesthetic restorations. Placement of the FAI in a more apical position can create an ideal emergence profile for the prosthetic construction (Buser & von Arx 2000).

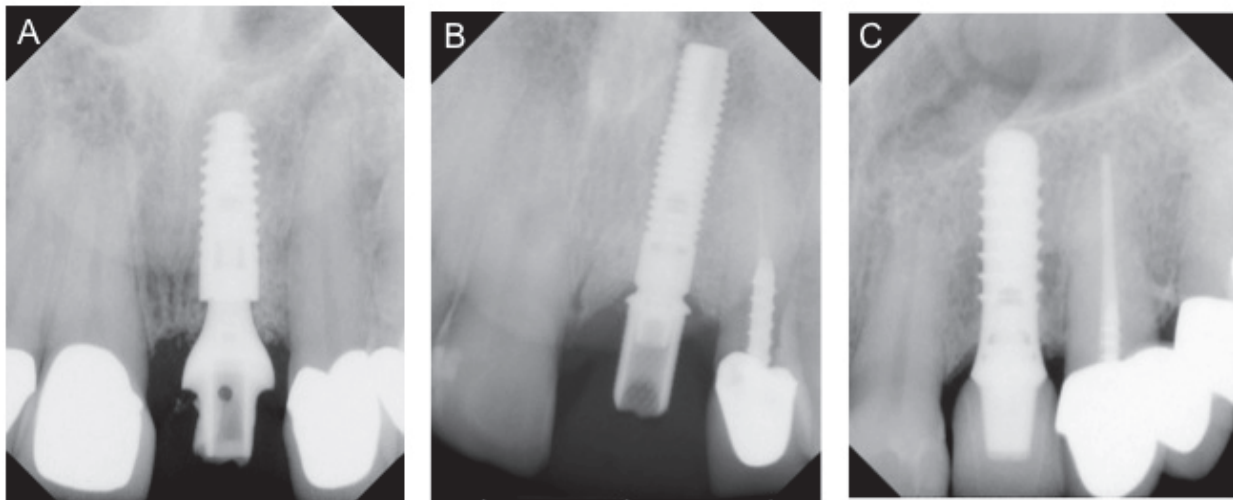


Fig. 5. Radiographs of implants placed with the FAI at A)subcrestal, B)crestal, C)supracrestal in relation to the alveolar crest

Subcrestal position of the FAI has been reported to have a negative influence on marginal bone level changes in a few animal studies (Jung et al. 2008, Hermann et al. 2000, Todescan et al. 2002, Pontes et al. 2008). In an experimental study in dogs Hermann et al. 2000 reported that placement of two-part implants with the FAI 1 mm below the crestal bone resulted in pronounced crestal bone loss following 6 months of healing. In this study the authors used custom-made implants with a FAI micro-gap of 50 μm . Similarly, Jung et al. 2008 reported that the greatest amount of bone loss occurred in implants placed with the FAI 1mm below the bone crest compared to implants placed with FAI 1mm above or at the level of the bone crest. In this study, implants with non-matching implant abutment diameters were utilized. However, the amount of crestal bone loss was smaller compared to that found in the study by Hermann et al. 2000. In a similar animal experiment, Todescan et al. 2002 evaluated the healing around implants (Brånemark System) that were placed either 1 mm above, level with or 1 mm below the crestal bone. Here it was reported that the first marginal bone to implant contact was located between 1.6 mm and 2.5 mm apical to the FAI

with the shortest implant contact distance associated with implants that were placed in the subcrestal position. Similar findings have been reported by Pontes et al. 2008 where they placed implants with the FAI at the bone crest, 1 mm and 2 mm apical to this position. Following 4 months of healing all implant groups had the first bone to implant contact apical to the FAI. None of these animal studies reported bone formation above the FAI when implants are placed in a subcrestal position. In contrast to the previously described studies, few animal experiments (Welander et al. 2009, Weng et al. 2008) have reported a more favorable outcomes for implants in a subcrestal position with bone formation close to or even above the FAI. Welander et al 2009 observed osseointegration coronal to the FAI when placing implants with the FAI 2 mm subcrestally. The test implants in this study had a surface modification extending to the implant margin that included the shoulder part of the implant and a conical interface between the abutment and the implant. Similar findings were reported by Weng et al. 2008, showing that implants with subcrestal position presented bone growth onto the implant shoulder in nearly all histological sections. Implants utilized in this study contained a reduced abutment diameter in relation to the fixture diameter, a Morse taper implant-abutment connection, and a microstructured surface treatment which included the cervical collar and extended onto the implant shoulder.

The effects of altered vertical implant positioning in patients were reported by Hämmerle et al. 1996. Here one-stage transmucosal implants were placed with the border between the rough/smooth surface 1 mm subcrestally. This group of implants was compared to implants placed according to the manufacturer's recommendation with the rough/smooth border positioned precisely at the alveolar crest. The implants in the subcrestal group lost a mean of 2.26 mm of clinical bone height during the first 12 months, and the control implants lost 1.02 mm during the same time period. The authors concluded that subcrestal placement of implants with smooth/polished collars should not be recommended.

There is limited information from clinical studies for subcrestal placement of two-part implants. In a recent case series Donovan et al. 2010 reported that subcrestal placement of dental implants with microstructured surface treatment extending onto the implant shoulder and with reduced abutment diameter resulted in minimal marginal loss of hard tissues (0.11 mm). In addition, mineralized hard tissue on the implant shoulder was demonstrated in 69% of the implants after a mean follow-up time of 14 months. However, in this study grafting of the remaining osseous wound defect between the bone crest and the coronal aspect of the fixture was performed subsequent to implant placement. A subsequent study (Koutouzis et al. 2011) reported on the same patient population and evaluated the effect of bone grafting of the defect between the bone crest and the coronal aspect of the implant for implants with reduced abutment diameters placed non-submerged and in subcrestal positions (Figure 6).

Records of 50 consecutive patients treated with subcrestally placed dental implants grafted with a xenograft (Group A) and 50 consecutive patients with subcrestally placed dental implants without any grafting material (Group B) were reviewed. The mean marginal loss of hard tissues was 0.11 ± 0.30 mm for Group A and 0.08 ± 0.22 mm for Group B. Sixty nine percent of the implants in Group A and 77% of the implants in Group B demonstrated hard tissue on the implant platform. There were no statistical significant differences between the groups regarding marginal peri-implant hard tissue loss. Thus grafting of the remaining osseous wound defect between the bone crest and the coronal aspect of the implant has no effect on marginal peri-implant hard tissue changes (Figure 7).

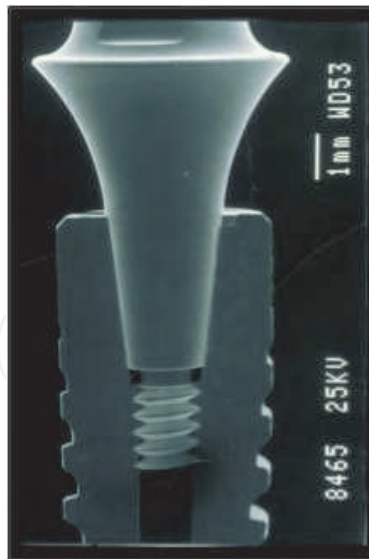

Fig. 6. Implant with a Morse taper implant-abutment connection and a microstructured surface treatment including the cervical collar and extending onto the implant shoulder.

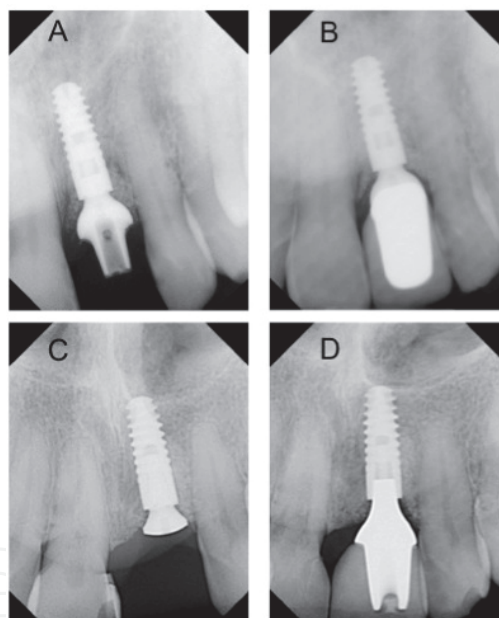


Fig. 7. Radiographs of an implant at #9 site of a patient in Group A: A) at implant installation and B) 12 months following implant installation and of a patient in Group B: C) at implant installation and C) 16 months following implant installation.

Taken together it seems that the location of the FAI can have an effect on marginal bone level changes depending on the type of implant system used. Even though one-stage transmucosal implants exhibit stable peri-implant bone levels when the FAI is located supracrestal and the border between rough and smooth surface is located at the alveolar crest it seems that placement of the border between the rough and smooth surface below the bone crest can lead to marginal bone loss and it is not recommended. Placement of the FAI in subcrestal position has been documented to have positive effect on marginal bone levels for implants with reduced abutment diameter in relation to the fixture diameter, a Morse

taper implant-abutment connection and a microstructured surface treatment which includes the cervical collar and extends onto the implant shoulder.

3. The effect of fixture-abutment interface (FAI) design on marginal bone level changes

Early bacterial colonization of implant surfaces and peri-implant tissues can occur within minutes after implant installation (Fürst et al. 2007). When a prosthetic abutment is connected to a fixture, a microgap is created between the components. Microorganisms may grow into this fixture-abutment interface microgap (Quirynen et al. 1993, 2006, Callan et al. 2005) and establish a bacterial reservoir resulting in an area of inflamed soft tissue facing the fixture-abutment junction (Ericsson et al. 1995). The presence of an FAI microgap in close relation to bone may thus have a role in the development of peri-implant inflammation and bone loss (Persson et al. 1996, Herman et al. 1997, 2001, King et al. 2002, Piatelli et al. 2003). Prevention of microbial leakage at the fixture-abutment interface is a major challenge in the construction of two-piece implant systems in order to minimize inflammatory reactions and to maximize peri-implant bone stability.

Microbial penetrations along the internal part of dental implants have been reported in some in vitro studies utilizing implants with different fixture-abutment interface geometries devoid of mechanical loading (Quirynen et al. 1994, Jansen et al. 1997, Tesmer et al. 2009, Aloise et al. 2010). For instance, Quirynen et al. 1994 demonstrated that when fixtures with an external hex design and abutments were assembled and installed in a liquid blood medium inoculated with oral microorganisms, bacterial invasion of the fixture-abutment interface microgap was detected. Similarly, Jansen et al. 1997 reported microbial leakage of thirteen different implant-abutment combinations using *E.coli* as indicator bacteria. Among the different implant-abutment combinations an implant with an internal connection and a silicon washer demonstrated the fewest cases of leakage. Tesmer et al. 2009 evaluated the potential risk for invasion of *A. actinomycetemcomitans* and *P. gingivalis* at the fixture-abutment interface of implants with Morse-taper internal connection. Fixtures and abutments were assembled and allowed to incubate in a bacterial solution of *A. actinomycetemcomitans* and *P. gingivalis* for five days. They reported that three of the ten implants evaluated developed one colony-forming unit (CFU) for *A. actinomycetemcomitans*, whereas zero of ten samples developed CFUs for *P. gingivalis*. Similar results have been reported from Aloise et al. for implants with Morse-taper internal connection. In this experiment they utilize a different evaluation method where the internal part of the implants were inoculated with *S.Sanguinis* and then implants connected to the respective abutments. Following total immersion of 10 implants with Morse-taper internal connection in a sterile solution for 14 days, only two implants showed evidence of bacterial leakage.

There is limited information from in vitro studies evaluating microbial contamination of the fixture-abutment interface microgap under loading conditions. Steinebrunner et al. 2005 used a 2-axis chewing simulator to apply a 120N force for a total of 1200000 cycles. They reported statistically significant differences between five implant systems with respect to number of chewing cycles and bacterial leakage. Specifically, implants with a tri-channel internal connection showed bacterial leakage at significantly higher numbers of chewing cycles compared to implants with external hex, implants with internal connection and a silicon washer, and implants with internal hex with friction fit connection. Koutouzis et al. 2010 utilized an in vitro dynamic loading model to assess the potential risk for invasion of

oral micro-organisms into the fixture-abutment interface microgap of dental implants with different fixture-abutment connection characteristics. In this experiment twenty-eight implants were divided into two groups (n=14/group) based on their microgap dynamics. Group 1 was comprised of fixtures with internal Morse-taper connection that connected to standard abutments. Group 2 was comprised of implants with a four-groove conical internal connection that connected to multi-base abutments (Figure 8). The specimens were immersed in a bacterial solution of *Escherichia coli* and loaded with 500,000 cycles of 15 N in a wear simulator. Following disconnection of fixtures and abutments, microbial samples were taken from the threaded portion of the abutment, plated and cultured under appropriate conditions. The difference between loosening and tightening torque value was also measured. One of the 14 samples in Group 1 and 12/14 of samples in Group 2 developed multiple colony forming units (CFU) for *E.coli*. Implants in Group 1 exhibited an increase in torque value in contrast to implants in Group 2 that exhibited a decrease. This study indicated that differences in implant design may affect the potential risk for invasion of oral micro-organisms into the FAI microgap under dynamic loading conditions.

The effects of FAI design on marginal bone level changes have been analyzed in several animal studies that have been also reported results on the effect of the position of the FAI. Those studies have been discussed extensively in a previous section of this chapter. In

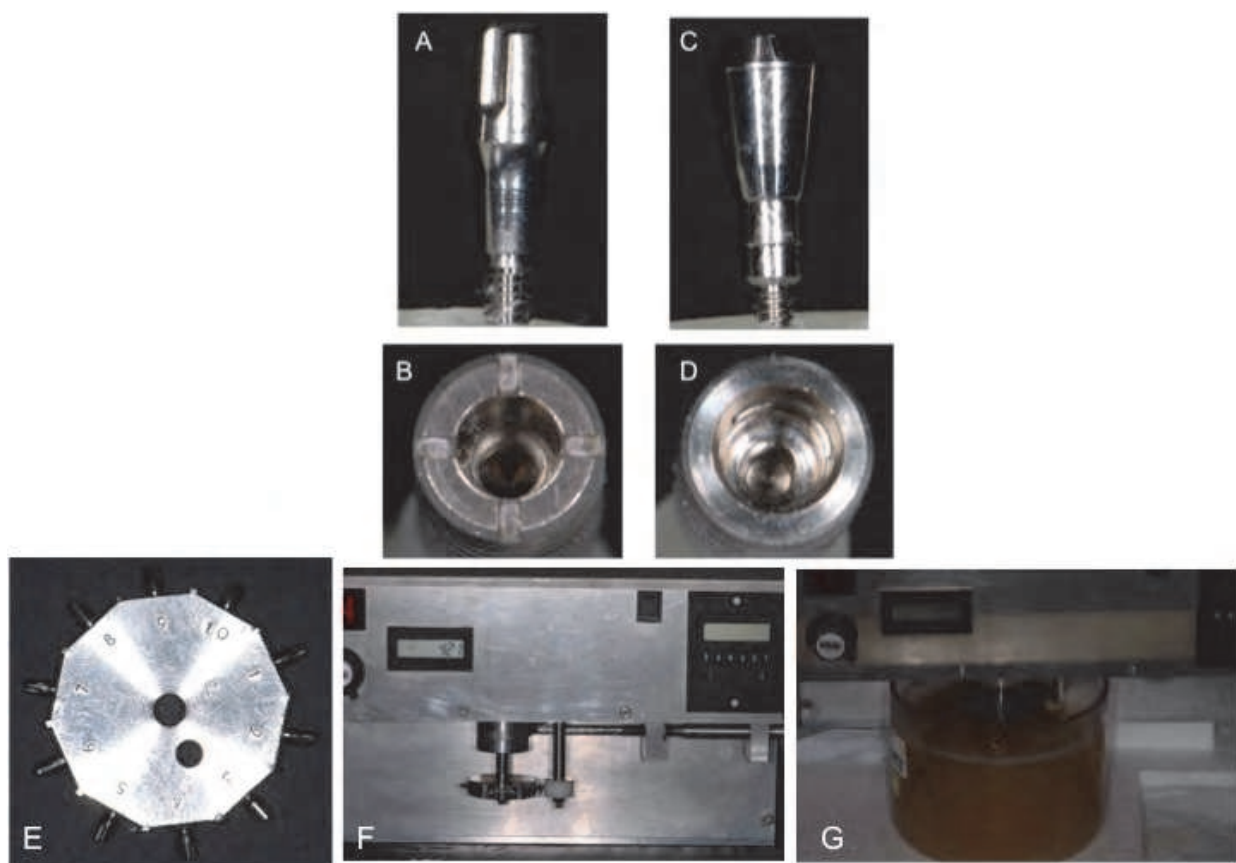


Fig. 8. A) Standard straight abutment of Group 1. B) Implant with internal Morse-taper connection of Group 1. C) Multibase abutment of Group 2. D) Implant with a four-groove conical internal connection of Group 2. E) Specimen wheel with implants and abutments of Group 1. F) Specimen and Agonist wheels. G) Specimen and Agonist wheels immersed in the bacterial solution.

summary it seems that the design and location of the FAI can have an effect on marginal bone level changes. Placement of the FAI in subcrestal position has been documented to have positive effect on marginal one level only for implants with reduced abutment diameter in relation to the fixture diameter, a Morse taper implant-abutment connection and a microstructured surface treatment which included the cervical collar and extended onto the implant shoulder.

The results of animal studies on the effect of FAI design on marginal bone level changes have been confirmed in clinical studies. Based on observations of the performance of implants with an external hex connection Albrektsson et al. 1986 observed 1mm peri-implant bone loss during the first year of function, followed by an annual loss <0.2mm after the first year in service as a criteria for implant success. Albrektsson & Isidor 1993 also proposed criterion for implant success where they suggested an average peri-implant marginal bone loss of less than 1.5 mm the first year after insertion of the prosthesis and less than 0.2 mm annual bone loss after that as a standard for successful therapy. However more current studies utilizing two-piece implant systems with an altered horizontal relationship between the fixture diameter and the abutment diameter, report minimal marginal peri-implant bone loss (Wennström et al. 2004, 2005, Norton 2006). The positive effect of this design known as platform shifting is explained by an increased distance of the FAI from the crestal bone creating an establishment of increased biologic width reducing the risk of inflammatory induced bone loss in cases of peri-implant submucosal bacterial colonization. In a 5-year prospective study Wennström et al. 2005 reported mean bone level changes from the time of crown placement to the first year follow up of 0.02 mm measured on implant level. Norton et al. 2006 reported an average of marginal bone loss of 0.65 mm from implant therapy in 54 patients where the implants had been in function for 37 months. In further clinical studies (Koutouzis & Wennström 2007, Koutouzis et al. 2010) utilizing dental implants with an altered horizontal relationship between the fixture diameter and the abutment diameter minimal marginal bone level changes have been observed even in conditions where the FAI were placed subcrestally.

Taken together the results of in-vitro studies show that differences in implant design may affect the potential risk for invasion of oral micro-organisms into the FAI under non-loading and dynamic loading conditions. Implants with internal Morse-taper connection have the highest potential to prevent bacterial contamination of the FAI interface. The results from animal studies demonstrate that implants with reduced abutment diameter in relation to the fixture diameter, a Morse taper implant-abutment connection and a microstructured surface treatment which included the cervical collar and extended onto the implant shoulder can maintain stable peri-implant bone levels even when the FAI is placed in a subcrestal position. These results are in line with clinical studies showing that implants with reduced abutment diameter in relation to the fixture diameter and a Morse taper implant-abutment connection exhibit less marginal bone loss compared to implants with an external hex connection at least at the earlier stages of healing (the interval of implant installation to prosthesis installation).

4. The effect of loading on marginal bone level changes

It has been suggested that biomechanical overload is one of the major determinants for late implant failure (Esposito et al. 1998a). The biomechanical aspects of the relation between the

applied load, the supporting capacity of the prosthesis, implant and characteristics of the alveolar bone seem to be essential for the long-term outcome of the treatment.

Based on investigations of biomechanics in the implant-supported fixed prosthesis, two main types of loading of the anchorage unit were suggested to be considered: (i) axial force and (ii) bending moment (Rangert et al 1989). The axial force was suggested as most favourable as it distributes stress more evenly through the implant, while the bending moment exerts stress gradients in the implant as well in the bone. Bending moment can be produced from axially applied forces when a cantilever extension is used, but non-axial applied forces can also induce bending movement. The extent of the bending moment is dependent on the distance from the point of occlusal contact to the abutment-fixture junction, which forms the lever arm for the bending moment induced by the non-axial force.

4.1 Laboratory and animal studies

Laboratory tests utilizing finite element analysis demonstrated that, when applying lateral or oblique loads, the highest stress concentration occurs at the marginal part of the implant (Borchers & Reichart 1983; Clelland et al. 1993, 1995; Papavasiliou et al. 1996; Holmes & Loftus 1997; Kitamura et al. 2004). With regard to the biological effects of such stress concentrations, however, animal experiments revealed conflicting results. Barbier & Schepers 1997 studied the effect of axial and non-axial loading conditions induced by either a bilaterally supported fixed partial dentures (FPDs) or a cantilever FPD on two implants. Based on the histological observations, non-axial loading for 7 weeks gave rise to a more dynamic remodeling of the surrounding cortical and trabecular bone tissue. Therefore, the authors extrapolated that a longer experimental period of loading could have resulted in marginal bone loss. Similarly, using a rabbit tibia model, Duyck et al. 2001 reported that dynamic excessive loads perpendicular to the implant axis caused crater-like bone loss around the marginal part of the implant. The hypothesis that excessive dynamic load can trigger bone resorption through the induction of micro-damage in the bone may also be supported by observations made by Isidor (1996, 1997), who demonstrated that excessive occlusal load in a lateral direction caused implant failure due to loss of osseointegration in five out of eight implants during an 18-month observation period. However, it was also observed that the bone crest remained at a position close to the margin of the implant without signs of triangular-shaped bone craters. The latter observation corroborates findings made in several other experimental studies (Hürzeler et al. 1998; Miyata et al. 1998; Gotfredsen et al. 2001a, 2001b, 2001c, 2002; Heitz-Mayfield et al. 2004) which demonstrated no detrimental effect on the marginal bone following excessive loading. In the most recent of these studies (Heitz-Mayfield et al. 2004), the effect of excessive oblique load on osseointegration of implants placed in beagle dogs was examined. Single crowns in supraocclusion with the opposing maxillary teeth were connected in one side of the mandible, while no crowns were placed on the implants in the contra-lateral side. The authors reported that no differences were found in clinical, radiographic or histological parameters between implants in supra-occlusion and unloaded controls after the 8-month experimental period.

In summary, it is obvious that conflicting results with regard to the effect of various loading conditions have been reported from animal experiments. The majority of the studies involving unfavourable loading conditions failed to confirm that excessive loading will cause marginal bone loss and/or loss of osseointegration.

4.2 Clinical studies

Limited clinical data are available in the literature regarding the possible influence of loading characteristics, such as magnitude and direction, on the marginal bone stability around implants. The assessment of the loading characteristics has been performed mainly through factors related to patient characteristics (parafunctional activity, bite force), prosthesis characteristics (cantilever length, height of the suprastructure, material of the suprastructure) and implant location characteristics (position in relation to occlusal level). In the interpretation of the available data one has to consider the difficult task to quantify the magnitude and direction of bite forces applied by the patient in relation to the biomechanical capability of the bone as well as the lack of appropriate controls.

Quirynen et al. 1992 reported that excessive marginal bone loss (more than 1 mm) after the first year of loading and/or fixture loss correlated well with the presence of overload due a lack of anterior contact, the presence of parafunctional activity and osseointegrated full fixed prostheses in both jaws. The data were generated from 84 patients having fixed total dentures in one or both jaws or overdentures. These participants had been selected from a group of 467 consecutive treated patients. However, the retrospective nature of the study with a very heterogeneous material and a large range in follow-up time may limit the validity of the findings. Parafunctional activity and bite force in relation to marginal bone loss was evaluated in a series of studies (Lindquist et al. 1988, 1996) involving patients with mandibular fixed total dentures. Using data from 3-6 years of follow-up Lindquist et al. 1988 reported that both poor oral hygiene and tooth clenching were associated with marginal bone loss. Smoking habits were not assessed in this report. Interestingly, analyzing data from 12-15 years of follow-up of the same cohort, Lindquist et al. 1996 reported that smoking and poor oral hygiene had a significant influence on marginal bone loss, and that factors such as maximal bite force and tooth clenching were of minor importance.

Studies in humans have documented an increase in vertical loading as a result of inclusion of cantilever extension. Falk et al. 1989 studied naturally occurring axially directed forces on implants supporting cross arch mandibular prostheses with bilateral posterior two-unit cantilevers. The authors found that 70% of the forces were placed on the cantilevers and 30% on the fixture-supported segment of the prostheses. Limited data have been reported regarding the possible influence of prosthesis related factors such as cantilever extension on marginal bone stability around implants. Lindquist et al. 1988 reported that seven patients with long cantilevers (>15 mm) showed more bone loss than 6 patients with short cantilevers (<15 mm). However the difference was small (0.95 mm vs 0.61 mm) and only observed in the medial fixture sites. The authors analysed the same material after 15 years of follow-up (Lindquist et al. 1996) and found that the length of the cantilever segment was of minor importance but that smoking and oral hygiene had significant effects on the amount of peri-implant bone resorption. Naert et al. 1992 reported data derived from examinations of 103 complete fixed total dentures in 91 patients. The authors concluded that after 3-years of follow-up the length of the cantilever extension did not have a significant influence on the rate of marginal bone loss around the supporting implants.

The clinical studies referred to (Lindquist et al. 1988, 1996, Naert et al. 1992) indicate that cantilever extensions might not jeopardize the stability of peri-implant bone level in a complete fixed total denture situation. However, these reports do not provide information whether in an FPD, supported by a few implants, the load exerted on the cantilever extension may cause undue bone loss.

Romeo et al. 2003 studied the effect of cantilever extension on the prognosis of fixed partial dentures and marginal peri-implant bone stability. The overall cumulative implant survival rate was 97% for an observation period of 1-7 years. Slightly greater bone loss was reported for implants close to the cantilever compared to implants more distant to the cantilever (0.82 mm vs 0.69 mm). The authors also reported that for every 1 mm increase of cantilever length there was a 0.099 mm increase in bone resorption around the fixture closest to the cantilever extension. In a retrospective study, Wennström et al. 2004 assessed whether the inclusion of a cantilever extension increased the amount of marginal bone loss at fixed partial dentures (FPDs) over a 5-year period of functional loading. The cohort comprised of 45 periodontally treated and well maintained partially dentate patients. Comparison between FPDs with and without cantilever extension was performed at FPD, implant and surface level and revealed no statistical significant differences at any level, but that jaw of treatment and smoking had a significant influence on peri-implant bone level change on the FPD level.

The influence of the height of the supra-structure on marginal bone loss has also been evaluated (Naert et al. 2001, Wennström et al. 2004). Naert et al. 2001 in a multivariate analysis of potential factors influencing marginal bone loss around implants supporting FPDs reported that long abutments significantly increased the amount of bone loss in the first 6 months, but not thereafter. Wennström et al. 2004 on the other hand found that the height of the supra-structure failed to significantly influence bone loss on the FPD level but had an effect on the most posterior implant in the FPD. In this context it should be noted that the mean height of the supra-structure was significantly greater for patients having FPDs with cantilever extension as well as for fixed partial dentures placed in the maxilla than in the mandible.

Clinical trials designed to evaluate the potential influence of oblique loading direction in relation to the implant axis on peri-implant bone stability are few. Aparicio et al. 2001 reported data derived from examinations of 29 maxillary FPDs in 25 patients supported by 101 Brånemark implants, 59 inserted in an axial and 42 in a tilted direction. No significant difference in marginal bone level change between tilted and axial positioned implants could be observed over the 5 years of follow-up. This finding is in large supported by observations made by Krekmanov et al. 2000 and Calandriello & Tomatis 2005. Balshi et al. 1997 evaluated in a 3-year study the performance of angulated abutments used to compensate for a non-ideal implant inclination, where no increase in failure rates with the use of angulated abutments was observed. In a more recent study Koutouzis & Wennström 2007 retrospectively analyzed the potential influence of implant inclination on marginal bone loss at freestanding, implant-supported, fixed partial dentures (FPDs) over a 5-year period of functional loading. The cohort was comprised of 38 periodontally treated, partially dentate patients with a total of 42 free-standing FPDs supported by implants of the Astra Tech System. Mesio-distal inclination of the implants in relation to a vertical axis perpendicular to the occlusal plane was measured with a protractor on standardized photographs of the master cast (Figure 9).

The two tail quartiles of the distribution of the implants with regard to the implant inclination were defined as axial-positioned (mean 2.41°; range 0° -4.1°) and non-axial positioned implants (mean 17.11°; range 11° -30.1°), respectively. For FPDs supported by two implants, both the mesial-distal and buccal-lingual inter-implant inclination was measured. The 5-year mean bone level change amounted to 0.4mm (SD 0.97) for the axial and 0.5mm (0.95) for non-axial-positioned implants ($P>0.05$). For the FPDs supported by

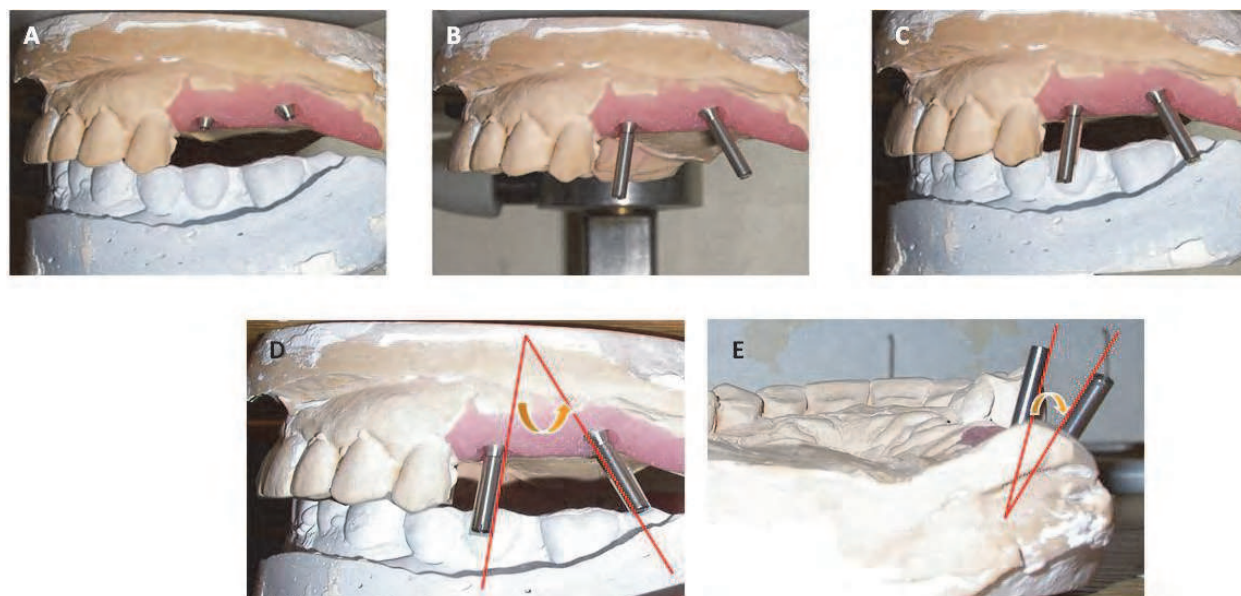


Fig. 9. Illustrations describing the photographic process for performing implant inclination measurements. (A) upper and lower casts in occlusion, (B) upper cast with guide pins abutment pick-up in place and (C) the final image produced by superimposing image b on image a, (D) mesio-distal inter-implant inclination measurements and (E) bucco-lingual inter-implant inclination measurements.

two implants, the mean inter-implant inclination was 9.21° in the mesial–distal direction and 6.71° in the buccal–lingual direction. Correlation analysis revealed lack of statistically significant correlation between inter-implant inclination (mesial–distal and buccal–lingual) and the 5-year bone level change. This study failed to support the hypothesis that implant inclination has an effect on peri-implant bone loss.

In conclusion, the findings of this 5-year study involving moderately tilted implants, as well as those reported by others who have clinically investigated the influence of more extreme non-axial loading on peri-implant bone level stability at implants of different design and surface texture (Balshi et al. 1997; Krekmanov et al. 2000; Aparicio et al. 2001; Calandriello & Tomatis 2005), indicate that a tilted position of the implant does not render an increased risk for bone loss during functional loading.

There are several aspects to consider when evaluating the outcomes of the clinical studies on the effect on loading parameters on marginal bone level changes including the retrospective nature of the majority of the studies, the lack of appropriate controls and the difficult task to quantify the magnitude and direction of bite forces. Within the limitations of the literature one can conclude that excessive loading forces and implant/prosthesis characteristics that can contribute to unfavourable loading conditions such as cantilever units, height of the prosthesis and angulation of the dental implants have limited effect on marginal bone level changes over time.

5. The effect of patient related factors

Patient selection is a fundamental part of the dental implant treatment plan. Patient related factors such as oral hygiene, smoking, diabetes, susceptibility to periodontal diseases and type of peri-implant mucosa have been evaluated in the literature with respect to their effect on the degree of marginal bone level changes. In addition peri-implantitis has been

identified as a major etiologic factor for marginal bone level changes and recent studies have explored epidemiological aspects of this condition.

5.1 Oral hygiene

In a prospective clinical study, Lindquist et al. 1997 reported an association between poor oral hygiene and peri-implant bone loss after 10-years of follow-up. Poor oral hygiene had a greater influence on marginal bone loss in smokers than non-smokers. For patients with poor oral hygiene, smokers had nearly three times the amount of bone loss than non-smokers. Ferreira et al. 2006 in a study analyzing risk variables in a Brazilian population, reported that presence of plaque and periodontal BOP at >30% of sites were associated with increased risk of peri-implant mucositis and peri-implantitis. The association between the full-mouth plaque score and peri-implantitis was dose dependent.

5.2 Smoking

The effect of cigarette smoking on the peri-implant soft and hard tissues has been documented in a number of studies. Strietzel et al. 2007 published a systematic review with meta-analysis, including 35 papers, to investigate if smoking interferes with the prognosis of implants, with and without augmentation procedures. The authors reported that smoking is a significant risk factor for failure of dental implant therapy and augmentation procedures accompanying implantations. This systematic review also included studies reporting on the influence of smoking on peri-implant marginal bone changes. Multiple studies have demonstrated a significant increase in peri-implant marginal bone loss in smokers compared with non-smokers (Haas et al. 1996, Lindquist et al. 1996, 1997, Carlsson et al. 2000, Feloutzis et al. 2003, Karoussis et al. 2004, Penarrocha et al. 2004, Wennström et al. 2004, Galindo- Moreno et al. 2005, Nitzan et al. 2005, Schwartz-Arad et al. 2005). Additional studies which have addressed risk indicators associated with peri-implant disease report a significant association of smoking with peri-implant mucositis, marginal bone loss and peri-implantitis (Roos-Jansåker et al. 2006a, Fransson et al. 2008). Chung et al. 2007 reported, significantly more bone loss in smokers in a retrospective study of 69 patients, including seven smokers followed between 3 and 24 years. Similarly, DeLuca et al. (DeLuca & Zarb 2006) showed that peri-implant bone loss was associated with a positive smoking history using a long-term retrospective study.

5.3 History of periodontitis

Tooth restorations using implant-supported prostheses for rehabilitation of patients who have experienced loss of teeth due to periodontitis has become an established and widely used treatment modality in modern dentistry (Figure 10).

A pertinent question in relation to implant therapy in patients susceptible to periodontal disease is whether this group of patients may also demonstrate an elevated risk for peri-implant tissue infections and subsequent marginal loss of hard and soft tissues. Only limited data are available on the outcomes of implant therapy in periodontitis-susceptible patients. In one study of 75 patients, Ellegaard et al. 1997 presented follow-up data (varying from 3 to 84 months) where the patients after initial periodontal treatment received prosthetic reconstructions supported by implants. The authors indicated that periodontally compromised patients can be successfully treated with dental implants. Nevins & Langer 1995 reported an overall implant survival rate of about 97% in a 1–8-year follow-up study of 59 patients whose periodontal disease had been categorized as refractory.

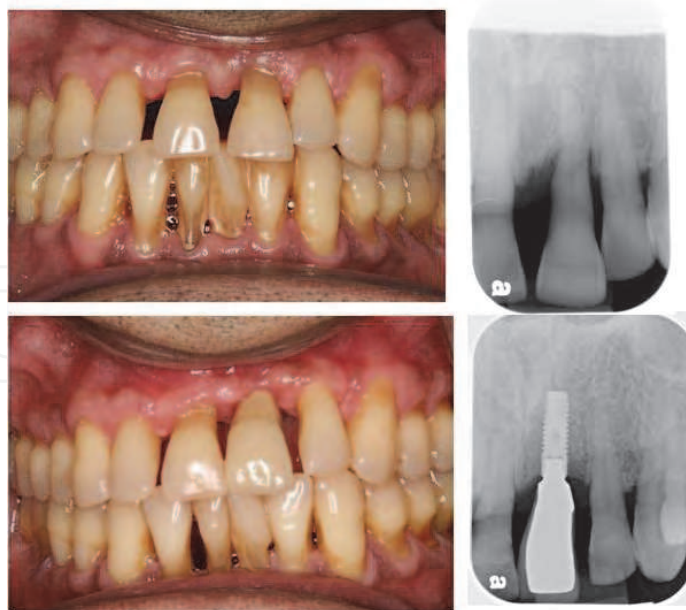

Fig. 10. #9 extracted due to loss of periodontal support and development of periodontal abscess and replaced with a dental implant

Less favorable outcomes of implant treatment in periodontal patients was reported by Brocard et al. 2000. In this multicentre study over a 5-year period the overall cumulative implant survival rate was reported to be 95% (success rate 94%) but implants placed in patients previously treated for periodontal disease showed a success rate of only 89%.

In a systematic review of prospective and retrospective cohort studies with at least a 5-year follow-up comparing the outcomes of implant treatments in partially edentulous individuals with periodontitis-associated and non-periodontitis-associated tooth loss, Schou et al. 2006 identified two studies one with 5-year follow-up (Hardt et al. 2002) and an other with 10-year follow-up (Karoussis et al. 2003). In these two studies a combined total of 121 implants were placed in 33 patients with previous tooth loss due to periodontitis and 183 implants were placed in 70 patients with non-periodontitis associated tooth loss. The endurance of the supra structures after 5 years was not significantly different when comparing these two groups. In addition, the survival rate of the implants was not significantly different, but a significantly increased peri-implant marginal bone loss was observed in patients with previous tooth loss due to periodontitis. Peri-implantitis, defined as probing depths of 5 mm or more, bleeding on probing, and radiographic signs of marginal bone loss was a more common finding in individuals with a periodontitis background than in individuals where the teeth before the implant treatment were extracted for other reasons.

All together these data indicate a potential risk for marginal bone loss in patients susceptible to periodontal disease.

5.3 Diabetes

While the association between diabetes and implant loss has been addressed in systematic reviews by Kotsovilis et al. 2006 and Mombelli & Cionca 2006 there is limited information describing the effect of diabetes on marginal bone level changes. Ferreira et al. 2006 in a recent cross-sectional study including 212 non-smoking subjects in a Brazilian population

investigated the presence of risk variables for peri-implant infection. At the time of examination, all implants had been in function between 6 months and 5 years. Glycemic data at the time of implant surgery were gathered from participant medical records. For all subjects diagnosed with diabetes at the time of surgery as well as for those who reported having the disease at the time of evaluation, a new exam was requested. Diabetes mellitus was diagnosed if an individual had fasting blood sugar >126 mg/dl or had been taking anti diabetic medicine over the past 2 weeks. The prevalence of peri-implant mucositis and peri-implantitis were 64.6% and 8.9%, respectively. The prevalence of periodontitis in these subjects was 14.2%. In multivariate analyses, the risk variables associated with increased odds for having peri-implant disease included: gender, plaque scores, and periodontal BOP. In addition presence of periodontitis and diabetes were statistically associated with greater risk of peri-implantitis. The results showed that poor metabolic control in subjects with diabetes was associated with peri-implantitis (Ferreira et al. 2006).

5.4 Presence of keratinized mucosa

It has been suggested that the presence or absence of keratinized mucosa may alter the resistance of peri-implant region to plaque-induced tissue destruction. In fact Warrer et al 1995 using an animal model reported that the absence of keratinized mucosa around dental endosseous implants increases the susceptibility of the peri-implant region to plaque-induced tissue destruction.

There is a limited number of clinical studies evaluating the influence of keratinized mucosa on marginal bone level changes. Mericske-Stern et al. 1994 followed for 5 years 66 ITI implants placed in the mandible of 33 edentulous elderly patients. The implants served as overdenture anchorage. Approximately 50% of the implants had been installed into the lining of the mucosa. The peri-implant mucosal tissue was maintained healthy during the whole observation period, and no or minimal loss of attachment was observed. Wennström et al. 1994 evaluated the soft tissue conditions at implants in relation to the width of masticatory mucosa. The results showed that 24% of the sites were lacking masticatory mucosa, and an additional 13% of the implants had a width of less than 2 mm. Mobility of the facial marginal soft tissue (i.e., lack of an attached portion of masticatory mucosa) was observed at 61% of all implants. No differences in the clinical parameters examined were found between sites with and without an "adequate" width of masticatory mucosa. Multiple regression analyses revealed that neither the width of masticatory mucosa nor the mobility of the border tissue had a significant influence on (i) the standard of plaque control or (ii) the health condition of the peri-implant mucosa, as determined by bleeding on probing. Hence, the study failed to support the concept that the lack of an attached portion of masticatory mucosa may jeopardize the maintenance of soft tissue health around dental implants.

Bengazi et al 1996 evaluated alterations in the position of the peri-implant soft tissue margin, occurring during a 2-year period after insertion of fixed prostheses. Apical displacement of the soft tissue margin mainly took place during the first 6 months of observation. Lingual sites in the mandible showed the most pronounced soft tissue recession, decrease of probing depth, and decrease of width of masticatory mucosa. The statistical analysis revealed that lack of masticatory mucosa and mobility of the peri-implant soft tissue at time of bridge installation were poor predictors of soft tissue recession occurring during the 2 years of follow-up. It was suggested that the recession of the peri-implant soft tissue margin might be the result of a remodelling of the soft tissue in order to establish "appropriate biological dimensions" of the peri-implant soft tissue barrier (i.e., the

required dimension of epithelial-connective tissue attachment in relation to the faciolingual thickness of the supracrestal soft tissue). The role of keratinized mucosa in peri-implant disease was studied by Roos-Jansåker et al. (2006b) who examined 218 patients treated with titanium implants. A multivariate analysis of potential explanatory variables for peri-implant mucositis and peri-implantitis was made, where no association between the absence of keratinized peri-implant mucosa and peri-implant disease was found.

From animal experiments there is limited evidence demonstrating differences regarding the soft tissue seal between masticatory and lining mucosa. Evidence from longitudinal retrospective and prospective clinical trials shows that, with adequate plaque control, there is no difference in the prognosis for maintaining a healthy functioning soft tissue seal as judged by clinical measures.

5.5 Peri-implant disease and epidemiology

Peri-implant disease is a collective term for inflammatory reactions in the tissues surrounding an implant (Zitzmann & Berglundh 2008). Peri-implant mucositis is used to describe the presence of inflammation in the mucosa at an implant with no signs of loss of supporting bone. Peri-implantitis in addition to inflammation in the mucosa is characterized by loss of supporting bone. Detection of inflammation in the peri-implant mucosa requires the use of periodontal probing to identify bleeding and/or suppuration. For the assessment of peri-implantitis detection of marginal bone loss in radiographs is also needed (Figure 11). It is important though to distinguish between bone remodelling that occurs early after implant installation and the loss of supporting bone that may be detected at implants during function.

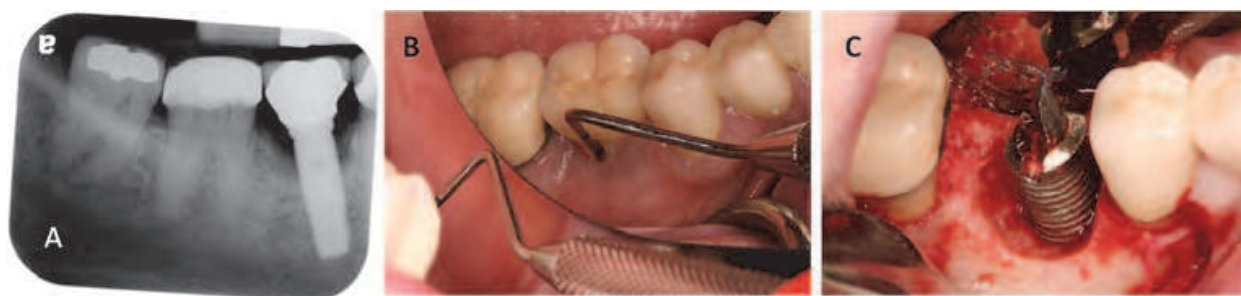

Fig. 11. Crater-form bone loss on radiographs (A) and clinical (C) and deep pocket with BoP and suppuration are the main characteristics of peri-implantitis lesions

Zitzmann & Berglundh 2008 performed a literature review in order to describe the prevalence of peri-implant diseases. Cross-sectional and longitudinal studies on implant-treated subjects with implants exhibiting a function time of at least 5 years were considered. The prevalence of peri-implant mucosa was evaluated in two studies (Roos-Jansåker et al. 2006 and Fransson et al. 2008). Roos-Jansåker et al. 2006 reported that peri-implant mucositis (BoP and no bone loss) occurred in about 79% of the subjects and 50% of the implants. In the study by Fransson et al. 2008, BoP was found in >90% of the implants without a history of bone loss. The prevalence of peri-implantitis was addressed in five publications that represented three subject samples with average function times of 9–11 years (Karoussis et al. 2004a, Brägger et al. 2005, Fransson et al. 2005, 2008, Roos-Jansåker et al. 2006). Peri-implantitis was found in 28% and ≥56% of subjects and in 12% and 43% of implant sites, respectively.

From the data available it seems that peri-implant disease is a very common problem although it is unfortunately addressed in very few studies. Careful selection of patients, effective recall program and early diagnosis are key factors for successful long term results.

6. Conclusions

Implant therapy success is dependent on other factors apart from successful osseointegration, where preservation of peri-implant bone is one of them. Marginal bone level changes are multi-factorial and only with careful considerations of the biological principles of the peri-implant soft and hard tissues, as well as the appropriate selection of implant type and position, can a functional and esthetic treatment result be achieved.

From the surgical factors that have been reviewed there is substantial evidence to support that using one-or two-stage surgical procedures have no clinically significant effect on success, survival rates and marginal bone levels. In addition several studies have shown that immediate loading does not promote marginal bone loss for implants replacing single teeth and that the majority of marginal bone level changes may occur during the first 3-6 months of loading with no significant alterations thereafter. However, no recommendations regarding patient inclusion, exclusion criteria, surgical techniques and implant characteristics can be made from the reviewed studies for immediate loading protocols.

Grafting of extraction sockets is beneficial in terms of limiting the dimensional changes of the alveolar ridge following tooth/teeth extraction. Several biomaterial and surgical techniques have been described, but no substantial evidence exists in order to support a specific technique as the most efficient. In addition there is variability on the histologic findings which may be a reflection of differences between biomaterials, surgical techniques and stages of healing. Although it is difficult to directly compare biomaterials among studies utilizing histologic evaluation, the majority of the grafting materials are osteoconductive and particles are always found in biopsies following different time intervals. Information that is commonly lacking from many histologic studies is the proportion of the particles that are in contact with new vital bone or embedded in loose connective tissue. Despite the fact that there are several reports on the survival of implants placed in grafted sockets there is very limited information regarding marginal bone level changes. One study reporting on implants placed in sockets grafted with DFDBA showed minimal amount of marginal bone loss, similar to implants placed in native bone. It is obvious that more studies are needed in order to evaluate the benefit of grafting extraction sockets and the long term effect on implant survival.

Implant positioning is a major part of implant treatment planning and should be based on careful evaluation of each individual case. Implant position can have an effect on marginal bone level changes depending on the type of implant design used. Several studies have shown that the marginal bone level at teeth adjacent to single implants with a micro-threaded conical portion is not influenced by the horizontal and vertical tooth-implant distances. However, this statement cannot be supported for implants with an external-hex design. Loss in height of the mid-proximal bone crest in the inter-implant areas is influenced by the bone loss at the two bordering implants and the horizontal inter-unit distance, while no such relationship is evident for proximal areas between implant and tooth. While this statement has been based and confirmed from studies using implants with an external hex-design it still remains controversial for implants with different internal connection designs.

Implant positioning also refers to the location of the FAI in relation to the alveolar crest (depth of implant placement). The majority of the available implant system manufacturers recommend placement of the FAI at the level of the alveolar crest (crestal) or above that level (supracrestal), depending on the design of the implant system. In clinical reality though, it is not uncommon that part of the FAI has to be placed in a subcrestal position due to anatomic variations of the implant sites. In addition placement of the FAI in a more apical position can create an ideal emergence profile for the prosthetic construction. In addition, the location of the FAI can have an effect on marginal bone level changes depending on the type of implant system used. Placement of the FAI in subcrestal position has been documented to have positive effect on marginal bone level for implants with reduced abutment diameter in relation to the fixture diameter, a Morse taper implant-abutment connection and a microstructured surface treatment including the cervical collar and extending onto the implant shoulder. The main explanation for why this FAI design favors preservation of marginal bone levels even in the subcrestal locations is the prevention of the microbial leakage into the internal part of the implant and the lack of abutment micro-movement during functional loading. Despite the positive findings of subcrestal implant placement it still remains unknown the ideal depth of the FAI in relation to the alveolar crest.

The effect of loading on marginal bone level changes has been a matter of controversy over the years. Most of the data supporting a positive effect of loading on peri-implant bone loss is coming from laboratory studies that do not take into consideration the biologic response of the bone and are poorly mimicking the biologic reality. Although many animal and clinical studies exist supporting that factors contributing to excessive loading are not related to the marginal bone level changes, there are still basic biomechanic principles which are still valuable on the long term success of implant therapy.

Apart from surgical factors and factors related to the implant design, patient selection is a fundamental part of the dental implant treatment plan. Studies suggest that there is a positive effect of poor oral hygiene with marginal bone loss and this relationship is dose depended. This observation stresses out the importance of supportive periodontal therapy for dental implant candidates. Similar findings have been reported for smoking, history of periodontal disease and uncontrolled diabetes.

At last it is apparent that peri-implant disease is not only a clinical reality but also is very common, specifically in populations that do not receive regular supportive periodontal care. Treatment of peri-implant disease although it seems to be possible it might be invasive and can lead to compromised functional and esthetic outcomes. In addition there are several aspects of the treatment of peri-implant disease that there are not adequately studied and understood. With the continuous introduction of implants with novel characteristics it will be very difficult to evaluate the effect of those innovations in the development and treatment of peri-implant disease. Thus, prevention of peri-implant disease by an appropriate supportive periodontal care program is essential for the long term success of implant therapy.

7. References

- Abrahamsson, I.; Berglundh, T.; Moon, I.S. & Lindhe, J. (1999). Peri-implant tissues at submerged and non-submerged titanium implants. *J Clin Periodontol*, vol. 26, no. 9, pp. 600-7.

- Abrahamsson, I.; Berglundh, T.; Wennstrom, J. & Lindhe, J. (1996). The peri-implant hard and soft tissues at different implant systems. A comparative study in the dog. *Clin Oral Implants Res*, vol. 7, no. 3, pp. 212-9.
- Adell, R.; Lekholm, U.; Rockler, B. & Branemark, P.I. (1981). A 15-year study of osseointegrated implants in the treatment of the edentulous jaw. *Int J Oral Surg*, vol. 10, no. 6, pp. 387-416.
- Akesson, L.; Hakansson, J.; Rohlin, M. & Zoger, B. (1993). An evaluation of image quality for the assessment of the marginal bone level in panoramic radiography. A comparison of radiographs from different dental clinics. *Swed Dent J*, vol. 17, no. 1-2, pp. 9-21.
- Albrektsson, T.; Zarb, G.; Worthington, P. & Eriksson, A.R. (1986). The long-term efficacy of currently used dental implants: A review and proposed criteria of success. *Int J Oral Maxillofac Implants*, vol. 1, no. 1, pp. 11-25.
- Aloise, J. P.; Curcio, R.; Laporta, M.Z.; Rossi, L.; Da Silva, A.M. & Rapoport, A. Microbial leakage through the implant-abutment interface of morse taper implants in vitro. *Clin Oral Implants Res*, vol. 21, no. 3, pp. 328-35.
- Andersen, E.; Haanaes, H.R. & Knutsen, B.M. (2002). Immediate loading of single-tooth iti implants in the anterior maxilla: A prospective 5-year pilot study. *Clin Oral Implants Res*, vol. 13, no. 3, pp. 281-7.
- Andersson, B.; Odman, P.; Lindvall, A.M. & Branemark, P.I. (1998). Five-year prospective study of prosthodontic and surgical single-tooth implant treatment in general practices and at a specialist clinic. *Int J Prosthodont*, vol. 11, no. 4, pp. 351-5.
- Aparicio, C.; Perales, P. & Rangert, B. (2001). Tilted implants as an alternative to maxillary sinus grafting: A clinical, radiologic, and periotest study. *Clin Implant Dent Relat Res*, vol. 3, no. 1, pp. 39-49.
- Aparicio, C.; Rangert, B. & Sennerby, L. (2003). Immediate/early loading of dental implants: A report from the sociedad espanola de implantes world congress consensus meeting in barcelona, spain, 2002. *Clin Implant Dent Relat Res*, vol. 5, no. 1, pp. 57-60.
- Araujo, M. G.; Carmagnola, D.; Berglundh, T.; Thilander, B. & Lindhe, J. (2001). Orthodontic movement in bone defects augmented with bio-oss. An experimental study in dogs. *J Clin Periodontol*, vol. 28, no. 1, pp. 73-80.
- Araujo, M. G. & Lindhe, J. (2005). Dimensional ridge alterations following tooth extraction. An experimental study in the dog. *J Clin Periodontol*, vol. 32, no. 2, pp. 212-8.
- Artzi, Z.; Tal, H. & Dayan, D. (2000). Porous bovine bone mineral in healing of human extraction sockets. Part 1: Histomorphometric evaluations at 9 months. *J Periodontol*, vol. 71, no. 6, pp. 1015-23.
- Artzi, Z.; Tal, H. & Dayan, D. (2001). Porous bovine bone mineral in healing of human extraction sockets: 2. Histochemical observations at 9 months. *J Periodontol*, vol. 72, no. 2, pp. 152-9.
- Astrand, P.; Engquist, B.; Anzen, B.; Bergendal, T.; Hallman, M.; Karlsson, U.; Kvint, S.; Lysell, L. & Rundcranz, T. (2004). A three-year follow-up report of a comparative study of iti dental implants and branemark system implants in the treatment of the partially edentulous maxilla. *Clin Implant Dent Relat Res*, vol. 6, no. 3, pp. 130-41.

- Balshi, T. J.; Ekfeldt, A.; Stenberg, T. & Vrielinck, L. (1997). Three-year evaluation of branemark implants connected to angulated abutments. *Int J Oral Maxillofac Implants*, vol. 12, no. 1, pp. 52-8.
- Barbier, L. & Schepers, E. (1997). Adaptive bone remodeling around oral implants under axial and nonaxial loading conditions in the dog mandible. *Int J Oral Maxillofac Implants*, vol. 12, no. 2, pp. 215-23.
- Barone, A.; Aldini, N.N.; Fini, M.; Giardino, R.; Calvo Guirado, J.L. & Covani, U. (2008). Xenograft versus extraction alone for ridge preservation after tooth removal: A clinical and histomorphometric study. *J Periodontol*, vol. 79, no. 8, pp. 1370-7.
- Becker, W.; Clokie, C.; Sennerby, L.; Urist, M.R. & Becker, B.E. (1998). Histologic findings after implantation and evaluation of different grafting materials and titanium micro screws into extraction sockets: Case reports. *J Periodontol*, vol. 69, no. 4, pp. 414-21.
- Becker, W.; Urist, M.; Becker, B.E.; Jackson, W.; Parry, D. A.; Bartold, M.; Vincenzzi, G.; De Georges, D. & Niederwanger, M. (1996). Clinical and histologic observations of sites implanted with intraoral autologous bone grafts or allografts. 15 human case reports. *J Periodontol*, vol. 67, no. 10, pp. 1025-33.
- Bengazi, F.; Wennstrom, J.L. & Lekholm, U. (1996). Recession of the soft tissue margin at oral implants. A 2-year longitudinal prospective study. *Clin Oral Implants Res*, vol. 7, no. 4, pp. 303-10.
- Borchers, L. & Reichart, P. (1983). Three-dimensional stress distribution around a dental implant at different stages of interface development. *J Dent Res*, vol. 62, no. 2, pp. 155-9.
- Bragger, U.; Hirt-Steiner, S.; Schnell, N.; Schmidlin, K.; Salvi, G.E.; Pjetursson, B.; Matuliene, G.; Zwahlen, M. & Lang, N. P. (2011). Complication and failure rates of fixed dental prostheses in patients treated for periodontal disease. *Clin Oral Implants Res*, vol. 22, no. 1, pp. 70-7.
- Bragger, U.; Pasquali, L.; Rylander, H.; Carnes, D. & Kornman, K. S. (1988). Computer-assisted densitometric image analysis in periodontal radiography. A methodological study. *J Clin Periodontol*, vol. 15, no. 1, pp. 27-37.
- Branemark, P. I.; Adell, R.; Breine, U.; Hansson, B.O.; Lindstrom, J. & Ohlsson, A. (1969). Intra-osseous anchorage of dental prostheses. I. Experimental studies. *Scand J Plast Reconstr Surg*, vol. 3, no. 2, pp. 81-100.
- Brocard, D.; Barthet, P.; Baysse, E.; Duffort, J. F.; Eller, P.; Justumus, P.; Marin, P.; Oscaby, F.; Simonet, T.; Benque, E. & Brunel, G. (2000). A multicenter report on 1,022 consecutively placed iti implants: A 7-year longitudinal study. *Int J Oral Maxillofac Implants*, vol. 15, no. 5, pp. 691-700.
- Brunski, J. B. (1993). Avoid pitfalls of overloading and micromotion of intraosseous implants. *Dent Implantol Update*, vol. 4, no. 10, pp. 77-81.
- Buser, D. & Von Arx, T. (2000). Surgical procedures in partially edentulous patients with iti implants. *Clin Oral Implants Res*, vol. 11 Suppl 1, pp. 83-100.
- Calandriello, R. & Tomatis, M. (2005). Simplified treatment of the atrophic posterior maxilla via immediate/early function and tilted implants: A prospective 1-year clinical study. *Clin Implant Dent Relat Res*, vol. 7 Suppl 1, pp. S1-12.
- Calandriello, R.; Tomatis, M. & Rangert, B. (2003). Immediate functional loading of branemark system implants with enhanced initial stability: A prospective 1- to 2-

- year clinical and radiographic study. *Clin Implant Dent Relat Res*, vol. 5 Suppl 1, pp. 10-20.
- Calandriello, R.; Tomatis, M.; Vallone, R.; Rangert, B. & Gottlow, J. (2003). Immediate occlusal loading of single lower molars using branemark system wide-platform titanium implants: An interim report of a prospective open-ended clinical multicenter study. *Clin Implant Dent Relat Res*, vol. 5 Suppl 1, pp. 74-80.
- Callan, D. P.; Cobb, C. M. & Williams, K. B. (2005). DNA probe identification of bacteria colonizing internal surfaces of the implant-abutment interface: A preliminary study. *J Periodontol*, vol. 76, no. 1, pp. 115-20.
- Cannizzaro, G. & Leone M. (2003). Restoration of partially edentulous patients using dental implants with a microtextured surface: A prospective comparison of delayed and immediate full occlusal loading. *Int J Oral Maxillofac Implants*, vol. 18, no. 4, pp. 512-22.
- Cardaropoli, G.; Araujo, M.; Hayacibara, R.; Sukekava, F. & Lindhe, J.(2005). Healing of extraction sockets and surgically produced - augmented and non-augmented - defects in the alveolar ridge. An experimental study in the dog. *J Clin Periodontol*, vol. 32, no. 5, pp. 435-40.
- Cardaropoli, G.; Wennstrom, J.L. & Lekholm, U.(2003). Peri-implant bone alterations in relation to inter-unit distances. A 3-year retrospective study. *Clin Oral Implants Res*, vol. 14, no. 4, pp. 430-6.
- Carlsson, G. E.; Bergman, B. & Hedegard, B. (1967). Changes in contour of the maxillary alveolar process under immediate dentures. A longitudinal clinical and x-ray cephalometric study covering 5 years. *Acta Odontol Scand*, vol. 25, no. 1, pp. 45-75.
- Carlsson G. E.; Lindquist, L. W. & Jemt, T. (2000). Long-term marginal periimplant bone loss in edentulous patients. *Int J Prosthodont*, vol. 13, no. 4, pp. 295-302.
- Carmagnola, D.; Adriaens, P. & Berglundh, T. (2003). Healing of human extraction sockets filled with bio-oss. *Clin Oral Implants Res*, vol. 14, no. 2, pp. 137-43.
- Carmagnola, D.; Berglundh, T. & Lindhe, J. (2002). The effect of a fibrin glue on the integration of bio-oss with bone tissue. A experimental study in labrador dogs. *J Clin Periodontol*, vol. 29, no. 5, pp. 377-83.
- Chang, M. & Wennstrom, J. L. (2010). Bone alterations at implant-supported FPDs in relation to inter-unit distances: A 5-year radiographic study'. *Clin Oral Implants Res*, vol. 21, no. 7, pp. 735-40.
- Chaushu, G.; Chaushu, S.; Tzohar, A. & Dayan, D. (2001). Immediate loading of single-tooth implants: Immediate versus non-immediate implantation. A clinical report. *Int J Oral Maxillofac Implants*, vol. 16, no. 2, pp. 267-72.
- Chung, D. M.; Oh, T. J.; Lee, J.; Misch, C. E. & Wang, H. L.(2007). Factors affecting late implant bone loss: A retrospective analysis. *Int J Oral Maxillofac Implants*, vol. 22, no. 1, pp. 117-26.
- Clelland, N. L.; Gilat, A.; Mcglumphy, E. A. & Brantley, W. A. (1993). A photoelastic and strain gauge analysis of angled abutments for an implant system. *Int J Oral Maxillofac Implants*, vol. 8, no. 5, pp. 541-8.
- Clelland, N. L.; Lee, J. K.; Bimbenet, O. C. & Brantley, W. A. (1995). A three-dimensional finite element stress analysis of angled abutments for an implant placed in the anterior maxilla. *J Prosthodont*, vol. 4, no. 2, pp. 95-100.

- Cochran, D. L.; Morton, D. & Weber, H. P. (2004). Consensus statements and recommended clinical procedures regarding loading protocols for endosseous dental implants. *Int J Oral Maxillofac Implants*, vol. 19 Suppl, pp. 109-13.
- De Oliveira, R. R.; Novaes, Jr. A. B.; Papalexiou, V.; Muglia, V. A. & Taba, Jr M.. (2006). Influence of interimplant distance on papilla formation and bone resorption: A clinical-radiographic study in dogs. *J Oral Implantol*, vol. 32, no. 5, pp. 218-27.
- De Smet, E.; Jacobs R.; Gijbels, F. & Naert, I. (2002). The accuracy and reliability of radiographic methods for the assessment of marginal bone level around oral implants. *Dentomaxillofac Radiol*, vol. 31, no. 3, pp. 176-81.
- Deluca, S. & Zarb, G. (2006). The effect of smoking on osseointegrated dental implants. Part ii: Peri-implant bone loss. *Int J Prosthodont*, vol. 19, no. 6, pp. 560-6.
- Donovan, R.; Fetner, A.; Koutouzis, T. & Lundgren, T. Crestal bone changes around implants with reduced abutment diameter placed non-submerged and at subcrestal positions: A 1-year radiographic evaluation. *J Periodontol*, vol. 81, no. 3, pp. 428-34.
- Duyck, J.; Ronold, H. J.; Van Oosterwyck, H.; Naert, I.; Vander Sloten, J. & Ellingsen, J. E. (2001). The influence of static and dynamic loading on marginal bone reactions around osseointegrated implants: An animal experimental study. *Clin Oral Implants Res*, vol. 12, no. 3, pp. 207-18.
- Ellegaard, B.; Baelum, V. & Karring, T. (1997). Implant therapy in periodontally compromised patients. *Clin Oral Implants Res*, vol. 8, no. 3, pp. 180-8.
- Ericsson, I.; Nilson, H.; Lindh, T.; Nilner, K. & Randow K. (2000). Immediate functional loading of branemark single tooth implants. An 18 months' clinical pilot follow-up study. *Clin Oral Implants Res*, vol. 11, no. 1, pp. 26-33.
- Ericsson, I.; Persson, L. G.; Berglundh, T.; Marinello, C. P.; Lindhe, J. & Klinge B. (1995). Different types of inflammatory reactions in peri-implant soft tissues. *J Clin Periodontol*, vol. 22, no. 3, pp. 255-61.
- Esposito, M.; Ekestubbe, A. & Grondahl, K. (1993). Radiological evaluation of marginal bone loss at tooth surfaces facing single branemark implants. *Clin Oral Implants Res*, vol. 4, no. 3, pp. 151-7.
- Esposito, M.; Grusovin, M. G.; Achille, H.; Coulthard, P. & Worthington, H. V. (2009). Interventions for replacing missing teeth: Different times for loading dental implants. *Cochrane Database Syst Rev*, no. 1, p. CD003878.
- Esposito, M.; Hirsch, J. M.; Lekholm, U. & Thomsen, P. (1998). Biological factors contributing to failures of osseointegrated oral implants. (i). Success criteria and epidemiology'. *Eur J Oral Sci*, vol. 106, no. 1, pp. 527-51.
- Falk, H.; Laurell, L. & Lundgren, D. (1989). Occlusal force pattern in dentitions with mandibular implant-supported fixed cantilever prostheses occluded with complete dentures. *Int J Oral Maxillofac Implants*, vol. 4, no. 1, pp. 55-62.
- Feloutzis, A.; Lang, N. P.; Tonetti, M. S.; Burgin, W.; Bragger, U.; Buser, D.; Duff, G. W. & Kornman, K. S. (2003). Il-1 gene polymorphism and smoking as risk factors for peri-implant bone loss in a well-maintained population. *Clin Oral Implants Res*, vol. 14, no. 1, pp. 10-7.
- Ferreira, S. D.; Silva, G. L.; Cortelli, J. R.; Costa, J. E. & Costa, F. O. (2006). Prevalence and risk variables for peri-implant disease in brazilian subjects. *J Clin Periodontol*, vol. 33, no. 12, pp. 929-35.

- Fiorellini, J. P. & Nevins, M. L. (2003). Localized ridge augmentation/preservation. A systematic review. *Ann Periodontol*, vol. 8, no. 1, pp. 321-7.
- Fransson, C.; Lekholm, U.; Jemt, T. & Berglundh, T. (2005). Prevalence of subjects with progressive bone loss at implants. *Clin Oral Implants Res*, vol. 16, no. 4, pp. 440-6.
- Fransson, C.; Wennstrom, J. & Berglundh, T. (2008). Clinical characteristics at implants with a history of progressive bone loss. *Clin Oral Implants Res*, vol. 19, no. 2, pp. 142-7.
- Froum, S.; Cho, S. C.; Rosenberg, E.; Rohrer, M. & Tarnow, D. (2002). Histological comparison of healing extraction sockets implanted with bioactive glass or demineralized freeze-dried bone allograft: A pilot study. *J Periodontol*, vol. 73, no. 1, pp. 94-102.
- Furst, M. M.; Salvi, G. E.; Lang, N. P. & Persson, G. R. (2007). Bacterial colonization immediately after installation on oral titanium implants. *Clin Oral Implants Res*, vol. 18, no. 4, pp. 501-8.
- Galindo-Moreno, P.; Fauri, M.; Avila-Ortiz, G.; Fernandez-Barbero, J. E.; Cabrera-Leon, A. & Sanchez-Fernandez, E. (2005). Influence of alcohol and tobacco habits on peri-implant marginal bone loss: A prospective study. *Clin Oral Implants Res*, vol. 16, no. 5, pp. 579-86.
- Glauser, R.; Lundgren, A. K.; Gottlow, J.; Sennerby, L.; Portmann, M.; Ruhstaller, P. & Hammerle, H. (2003). Immediate occlusal loading of branemark titanium implants placed predominantly in soft bone: 1-year results of a prospective clinical study. *Clin Implant Dent Relat Res*, vol. 5 Suppl 1, pp. 47-56.
- Gotfredsen, K.; Berglundh, T. & Lindhe, J. (2001). Bone reactions adjacent to titanium implants subjected to static load of different duration. A study in the dog (iii). *Clin Oral Implants Res*, vol. 12, no. 6, pp. 552-8.
- Gotfredsen, K.; Berglundh, T. & Lindhe, J. (2001). Bone reactions adjacent to titanium implants subjected to static load. A study in the dog (i). *Clin Oral Implants Res*, vol. 12, no. 1, pp. 1-8.
- Gotfredsen, K.; Berglundh, T. & Lindhe, J. (2001). Bone reactions adjacent to titanium implants with different surface characteristics subjected to static load. A study in the dog (ii). *Clin Oral Implants Res*, vol. 12, no. 3, pp. 196-201.
- Gotfredsen, K.; Berglundh, T. & Lindhe, J. (2002). Bone reactions at implants subjected to experimental peri-implantitis and static load. A study in the dog. *J Clin Periodontol*, vol. 29, no. 2, pp. 144-51.
- Haas, R.; Haimbock, W.; Mailath, G. & Watzek, G. (1996). The relationship of smoking on peri-implant tissue: A retrospective study. *J Prosthet Dent*, vol. 76, no. 6, pp. 592-6.
- Hammerle, C. H.; Bragger, U.; Burgin, W. & Lang N. P. (1996). The effect of subcrestal placement of the polished surface of titanium implants on marginal soft and hard tissues. *Clin Oral Implants Res*, vol. 7, no. 2, pp. 111-9.
- Hardt, C. R.; Grondahl, K.; Lekholm, U. & Wennstrom, J. L. (2002). Outcome of implant therapy in relation to experienced loss of periodontal bone support: A retrospective 5-year study. *Clin Oral Implants Res*, vol. 13, no. 5, pp. 488-94.
- Hatley, C. L.; Cameron, S. M.; Cuenin, M. F.; Parker, M. H.; Thompson, S. H. & Harvey, S. B. (2001). The effect of dental implant spacing on peri-implant bone using the rabbit (*Oryctolagus cuniculus*) tibia model. *J Prosthodont*, vol. 10, no. 3, pp. 154-9.

- Heitz-Mayfield, L. J.; Schmid, B.; Weigel, C.; Gerber, S.; Bosshardt, D. D.; Jonsson, J. & Lang N. P. (2004). Does excessive occlusal load affect osseointegration? An experimental study in the dog. *Clin Oral Implants Res*, vol. 15, no. 3, pp. 259-68.
- Henry, P. J.; Tan A. E.; Leavy, J.; Johansson, C. B. & Albrektsson, T. (1997). Tissue regeneration in bony defects adjacent to immediately loaded titanium implants placed into extraction sockets: A study in dogs. *Int J Oral Maxillofac Implants*, vol. 12, no. 6, pp. 758-66.
- Hermann, J. S.; Cochran, D. L.; Nummikoski, P. V. & Buser, D. (1997). Crestal bone changes around titanium implants. A radiographic evaluation of unloaded nonsubmerged and submerged implants in the canine mandible. *J Periodontol*, vol. 68, no. 11, pp. 1117-30.
- Hermann, J. S.; Schoolfield, J. D.; Schenk, R. K.; Buser, D. & Cochran, D. L. (2001). Influence of the size of the microgap on crestal bone changes around titanium implants. A histometric evaluation of unloaded non-submerged implants in the canine mandible. *J Periodontol*, vol. 72, no. 10, pp. 1372-83.
- Iasella, J. M.; Greenwell, H.; Miller, R. L.; Hill, M.; Drisko, C.; Bohra, A. A. & Scheetz, J. P. (2003). Ridge preservation with freeze-dried bone allograft and a collagen membrane compared to extraction alone for implant site development: A clinical and histologic study in humans. *J Periodontol*, vol. 74, no. 7, pp. 990-9.
- Isidor, F. (1996). Loss of osseointegration caused by occlusal load of oral implants. A clinical and radiographic study in monkeys. *Clin Oral Implants Res*, vol. 7, no. 2, pp. 143-52.
- Isidor, F. (1997). Histological evaluation of peri-implant bone at implants subjected to occlusal overload or plaque accumulation. *Clin Oral Implants Res*, vol. 8, no. 1, pp. 1-9.
- Jansen, V. K.; Conrads, G. & Richter, E. J. (1997). Microbial leakage and marginal fit of the implant-abutment interface. *Int J Oral Maxillofac Implants*, vol. 12, no. 4, pp. 527-40.
- Johnson, K. (1969). A study of the dimensional changes occurring in the maxilla following tooth extraction. *Aust Dent J*, vol. 14, no. 4, pp. 241-4.
- Jung, R. E.; Jones A. A.; Higginbottom, F. L.; Wilson, T. G.; Schoolfield, J.; Buser, D.; Hammerle, C. H. & Cochran, D. L. (2008). The influence of non-matching implant and abutment diameters on radiographic crestal bone levels in dogs. *J Periodontol*, vol. 79, no. 2, pp. 260-70.
- Karoussis, I. K.; Muller, S.; Salvi, G. E.; Heitz-Mayfield, L. J.; Bragger, U. & Lang, N. P. (2004). Association between periodontal and peri-implant conditions: A 10-year prospective study. *Clin Oral Implants Res*, vol. 15, no. 1, pp. 1-7.
- Karoussis, I. K.; Salvi, G. E.; Heitz-Mayfield, L. J.; Bragger, U.; Hammerle, C. H. & Lang, N. P. (2003). Long-term implant prognosis in patients with and without a history of chronic periodontitis: A 10-year prospective cohort study of the iti dental implant system. *Clin Oral Implants Res*, vol. 14, no. 3, pp. 329-39.
- Kemppainen, P.; Eskola, S. & Ylipaavalniemi, P. (1997). A comparative prospective clinical study of two single-tooth implants: A preliminary report of 102 implants. *J Prosthet Dent*, vol. 77, no. 4, pp. 382-7.
- King, G. N.; Hermann, J. S.; Schoolfield, J. D.; Buser, D. & Cochran, D. L. (2002). Influence of the size of the microgap on crestal bone levels in non-submerged dental implants: A radiographic study in the canine mandible. *J Periodontol*, vol. 73, no. 10, pp. 1111-7.

- Kotsovilis, S.; Karoussis, I. K. & Fourmoussis, I.(2006). A comprehensive and critical review of dental implant placement in diabetic animals and patients. *Clin Oral Implants Res*, vol. 17, no. 5, pp. 587-99.
- Koutouzis, T. & Wennstrom, J. L.(2007). Bone level changes at axial- and non-axial-positioned implants supporting fixed partial dentures. A 5-year retrospective longitudinal study. *Clin Oral Implants Res*, vol. 18, no. 5, pp. 585-90.
- Koutouzis, T. & Lundgren T. (2010). Crestal bone-level changes around implants placed in post-extraction sockets augmented with demineralized freeze-dried bone allograft: A retrospective radiographic study. *J Periodontol*, vol. 81, no. 10, pp. 1441-8.
- Koutouzis, T.; Richardson, J. & Lundgren T. (2010). Comparative soft and hard tissue responses to titanium and polymer healing abutments. *J Oral Implantol*. [Epub ahead of print]
- Koutouzis, T.; Wallet, S.; Calderon, N. & Lundgren T. (2010). Bacterial colonization of the implant-abutment interface utilizing an in-vitro dynamic loading model. *J Periodontol*. [Epub ahead of print]
- Koutouzis, T.; Fetner, M; Fetner, A. & Lundgren, T. (2011). Retrospective evaluation of crestal bone changes around implants with reduced abutment diameter placed non-submerged and at subcrestal positions: The effect of bone grafting at implant placement. *J Periodontol*, vol. 82, no. 2, pp. 234-42.
- Koutouzis, T.; Koutouzis, G.; Tomasi, C. & Lundgren, T. (2011). Immediate loading of implants placed with the osteotome technique: one-year prospective cohort study. [in print]
- Krekmanov, L.; Kahn, M.; Rangert, B. & Lindstrom, H. (2000). Tilting of posterior mandibular and maxillary implants for improved prosthesis support. *Int J Oral Maxillofac Implants*, vol. 15, no. 3, pp. 405-14.
- Kullman, L.; Al-Asfour, A.; Zetterqvist, L & Andersson, L. (2007). Comparison of radiographic bone height assessments in panoramic and intraoral radiographs of implant patients. *Int J Oral Maxillofac Implants*, vol. 22, no. 1, pp. 96-100.
- Lekovic, V.; Camargo, P. M.; Klokkevold, P. R.; Weinlaender, M.; Kenney, E. B.; Dimitrijevic, B. & Nedic, M.(1998). Preservation of alveolar bone in extraction sockets using bioabsorbable membranes. *J Periodontol*, vol. 69, no. 9, pp. 1044-9.
- Lekovic, V.; Kenney, E. B.; Weinlaender, M.; Han, T.; Klokkevold, P.; Nedic, M. & Orsini, M. (1997). A bone regenerative approach to alveolar ridge maintenance following tooth extraction. Report of 10 cases. *J Periodontol*, vol. 68, no. 6, pp. 563-70.
- Lindeboom, J. A.; Frenken, J. W.; Dubois, L.; Frank, M.; Abbink, I. & Kroon, F. H.(2006). Immediate loading versus immediate provisionalization of maxillary single-tooth replacements: A prospective randomized study with biocomp implants. *J Oral Maxillofac Surg*, vol. 64, no. 6, pp. 936-42.
- Lindquist, L. W.; Rockler, B. & Carlsson, G. E. (1988). Bone resorption around fixtures in edentulous patients treated with mandibular fixed tissue-integrated prostheses. *J Prosthet Dent*, vol. 59, no. 1, pp. 59-63.
- Malo, P.; Friberg, B.; Polizzi, G.; Gualini, F.; Vighagen, T. & Rangert, B. (2003). Immediate and early function of branemark system implants placed in the esthetic zone: A 1-year prospective clinical multicenter study. *Clin Implant Dent Relat Res*, vol. 5 Suppl 1, pp. 37-46.


- Mengel, R.; Kruse, B. & Flores-De-Jacoby, L. (2006). Digital volume tomography in the diagnosis of peri-implant defects: An in vitro study on native pig mandibles. *J Periodontol*, vol. 77, no. 7, pp. 1234-41.
- Mericske-Stern, R.; Steinlin Schaffner, T.; Marti, P. & Geering A.H. (1994). Peri-implant mucosal aspects of iti implants supporting overdentures. A five-year longitudinal study. *Clin Oral Implants Res*, vol. 5, no. 1, pp. 9-18.
- Miyata, T.; Kobayashi, Y.; Araki, H.; Motomura, Y. & Shin, K. (1998). The influence of controlled occlusal overload on peri-implant tissue: A histologic study in monkeys. *Int J Oral Maxillofac Implants*, vol. 13, no. 5, pp. 677-83.
- Moberg, L. E.; Kondell, P. A.; Sagulin, G. B.; Bolin, A.; Heimdahl, A. & Gynther, G. W. (2001). Branemark system and iti dental implant system for treatment of mandibular edentulism. A comparative randomized study: 3-year follow-up. *Clin Oral Implants Res*, vol. 12, no. 5, pp. 450-61.
- Mombelli, A. & Cionca, N. (2006). Systemic diseases affecting osseointegration therapy. *Clin Oral Implants Res*, vol. 17 Suppl 2, pp. 97-103.
- Nevins, M.; Camelo, M.; De Paoli, S.; Friedland, B.; Schenk, R. K.; Parma-Benfenati, S.; Simion, M.; Tinti, C. & Wagenberg, B. (2006). A study of the fate of the buccal wall of extraction sockets of teeth with prominent roots. *Int J Periodontics Restorative Dent*, vol. 26, no. 1, pp. 19-29.
- Nevins, M. & Langer B. (1995). The successful use of osseointegrated implants for the treatment of the recalcitrant periodontal patient. *J Periodontol*, vol. 66, no. 2, pp. 150-7.
- Nitzan, D.; Mamlider, A.; Levin, L. & Schwartz-Arad, D. (2005). Impact of smoking on marginal bone loss. *Int J Oral Maxillofac Implants*, vol. 20, no. 4, pp. 605-9.
- Nkenke, E. & Fenner, M. (2006). Indications for immediate loading of implants and implant success. *Clin Oral Implants Res*, vol. 17 Suppl 2, pp. 19-34.
- Nkenke, E.; Lehner, B.; Weinzierl, U.; Thams, J.; Neugebauer, J.; Steveling, H.; Radespiel-Troger, M. & Neukam, F. W. (2003). Bone contact, growth, and density around immediately loaded implants in the mandible of mini pigs. *Clin Oral Implants Res*, vol. 14, no. 3, pp. 312-21.
- Norton, M. R. (2004). A short-term clinical evaluation of immediately restored maxillary tioblast single-tooth implants. *Int J Oral Maxillofac Implants*, vol. 19, no. 2, pp. 274-81.
- Novaes, A. B., Jr.; De Oliveira, R. R.; Muglia, V. A.; Papalexiou, V. & Taba, M. (2006). The effects of interimplant distances on papilla formation and crestal resorption in implants with a morse cone connection and a platform switch: A histomorphometric study in dogs. *J Periodontol*, vol. 77, no. 11, pp. 1839-49.
- Novaes, A. B., Jr.; Papalexiou, V.; Muglia, V. & Taba, Jr., M. (2006). Influence of interimplant distance on gingival papilla formation and bone resorption: Clinical-radiographic study in dogs. *Int J Oral Maxillofac Implants*, vol. 21, no. 1, pp. 45-51.
- Otoni, J. M.; Oliveira, Z. F.; Mansini, R. & Cabral, A. M. (2005). Correlation between placement torque and survival of single-tooth implants. *Int J Oral Maxillofac Implants*, vol. 20, no. 5, pp. 769-76.
- Papavasiliou, G.; Kamposiora, P.; Bayne, S. C. & Felton, D. A. (1996). Three-dimensional finite element analysis of stress-distribution around single tooth implants as a

- function of bony support, prosthesis type, and loading during function. *J Prosthet Dent*, vol. 76, no. 6, pp. 633-40.
- Penarrocha, M.; Palomar, M.; Sanchis, J. M.; Guarinos, J & Balaguer, J. (2004). Radiologic study of marginal bone loss around 108 dental implants and its relationship to smoking, implant location, and morphology. *Int J Oral Maxillofac Implants*, vol. 19, no. 6, pp. 861-7.
- Persson, L. G.; Lekholm, U.; Leonhardt, A.; Dahlen, G & Lindhe, J. (1996). Bacterial colonization on internal surfaces of branemark system implant components. *Clin Oral Implants Res*, vol. 7, no. 2, pp. 90-5.
- Piattelli, A.; Corigliano, M.; Scarano, A.; Costigliola G. & Paolantonio, M. (1998). Immediate loading of titanium plasma-sprayed implants: An histologic analysis in monkeys. *J Periodontol*, vol. 69, no. 3, pp. 321-7.
- Piattelli, A.; Corigliano, M.; Scarano, A.; & Quaranta M. (1997). Bone reactions to early occlusal loading of two-stage titanium plasma-sprayed implants: A pilot study in monkeys. *Int J Periodontics Restorative Dent*, vol. 17, no. 2, pp. 162-9.
- Piattelli, A.; Vrespa, G.; Petrone, G.; Iezzi, G; Annibali S. & Scarano A. (2003). Role of the microgap between implant and abutment: A retrospective histologic evaluation in monkeys. *J Periodontol*, vol. 74, no. 3, pp. 346-52.
- Petrokovski, J. & Massler M. (1967). Alveolar ridge resorption following tooth extraction. *J Prosthet Dent*, vol. 17, no. 1, pp. 21-7.
- Pontes, A. E.; Ribeiro, F. S.; Da Silva, V. C.; Margonar, R.; Piattelli, A.; Cirelli, J. A. & Marcantonio, Jr., E (2008). Clinical and radiographic changes around dental implants inserted in different levels in relation to the crestal bone, under different restoration protocols, in the dog model. *J Periodontol*, vol. 79, no. 3, pp. 486-94.
- Quirynen, M.; Bollen, C. M.; Eyssen, H.; & D. Van Steenberghe D. (1994). Microbial penetration along the implant components of the branemark system. An in vitro study. *Clin Oral Implants Res*, vol. 5, no. 4, pp. 239-44.
- Quirynen, M.; Naert, I & Van Steenberghe, D. (1992). Fixture design and overload influence marginal bone loss and fixture success in the branemark system. *Clin Oral Implants Res*, vol. 3, no. 3, pp. 104-11.
- Quirynen, M. & Van Steenberghe, D. (1993). Bacterial colonization of the internal part of two-stage implants. An in vivo study. *Clin Oral Implants Res*, vol. 4, no. 3, pp. 158-61.
- Quirynen, M.; Vogels, R.; Peeters, W.; Van Steenberghe, D.; Naert, I. & A. Haffajee, A. (2006). Dynamics of initial subgingival colonization of 'pristine' peri-implant pockets'. *Clin Oral Implants Res*, vol. 17, no. 1, pp. 25-37.
- Rangert, B.; T. Jemt, T. & Jorneus, L. (1989). Forces and moments on branemark implants. *Int J Oral Maxillofac Implants*, vol. 4, no. 3, pp. 241-7.
- Romanos, G. E.; Toh, C. G.; Siar, C. H.; Wicht, H.; Yacoob, H.& Nentwig, G. H. (2003). Bone-implant interface around titanium implants under different loading conditions: A histomorphometrical analysis in the macaca fascicularis monkey. *J Periodontol*, vol. 74, no. 10, pp. 1483-90.
- Romeo, E.; Lops, D.; Margutti, E.; Ghisolfi, M.; Chiapasco, M. & G. Vogel, G. (2003). Implant-supported fixed cantilever prostheses in partially edentulous arches. A seven-year prospective study. *Clin Oral Implants Res*, vol. 14, no. 3, pp. 303-11.

- Roos-Jansaker, A. M.; Lindahl, C.; Renvert, H. & Renvert, S. (2006). Nine- to fourteen-year follow-up of implant treatment. Part ii: Presence of peri-implant lesions. *J Clin Periodontol*, vol. 33, no. 4, pp. 290-5.
- Roos-Jansaker, A. M.; Renvert, H.; Lindahl, C. & Renvert, S. (2006). Nine- to fourteen-year follow-up of implant treatment. Part iii: Factors associated with peri-implant lesions. *J Clin Periodontol*, vol. 33, no. 4, pp. 296-301.
- Schou, S.; P. Holmstrup, P.; Worthington, H. V.; & Esposito, M. (2006). Outcome of implant therapy in patients with previous tooth loss due to periodontitis. *Clin Oral Implants Res*, vol. 17 Suppl 2, pp. 104-23.
- Schropp, L.; Wenzel, A.; Kostopoulos, L. & Karring, T. (2003). Bone healing and soft tissue contour changes following single-tooth extraction: A clinical and radiographic 12-month prospective study. *Int J Periodontics Restorative Dent*, vol. 23, no. 4, pp. 313-23.
- Schwartz-Arad, D.; Kidron, N. & Dolev, E. (2005). A long-term study of implants supporting overdentures as a model for implant success. *J Periodontol*, vol. 76, no. 9, pp. 1431-5.
- Steinebrunner, L.; Wolfart, S.; Bossmann, K. & Kern, M. (2005). In vitro evaluation of bacterial leakage along the implant-abutment interface of different implant systems. *Int J Oral Maxillofac Implants*, vol. 20, no. 6, pp. 875-81.
- Strietzel, F. P.; Reichart, P. A.; Kale, A.; Kulkarni, M.; Wegner, B. & Kuchler, I. (2007). Smoking interferes with the prognosis of dental implant treatment: A systematic review and meta-analysis. *J Clin Periodontol*, vol. 34, no. 6, pp. 523-44.
- Tarnow, D. P.; Cho, S. C. & Wallace, S. S. (2000). The effect of inter-implant distance on the height of inter-implant bone crest. *J Periodontol*, vol. 71, no. 4, pp. 546-9.
- Tesmer, M.; S. Wallet, S.; Koutouzis, T. & Lundgren, T. (2009). Bacterial colonization of the dental implant fixture-abutment interface: An in vitro study. *J Periodontol*, vol. 80, no. 12, pp. 1991-7.
- Thilander, B.; Odman, J. & Lekholm, U. (2001). Orthodontic aspects of the use of oral implants in adolescents: A 10-year follow-up study. *Eur J Orthod*, vol. 23, no. 6, pp. 715-31.
- Todescan, F. F.; Pustiglioni, F. E.; Imbronito, A. V.; Albrektsson, T. & Gioso, M. (2002). Influence of the microgap in the peri-implant hard and soft tissues: A histomorphometric study in dogs. *Int J Oral Maxillofac Implants*, vol. 17, no. 4, pp. 467-72.
- Warrer, K.; Buser, D.; Lang, N. P. & Karring, T. (1995). Plaque-induced peri-implantitis in the presence or absence of keratinized mucosa. An experimental study in monkeys. *Clin Oral Implants Res*, vol. 6, no. 3, pp. 131-8.
- Weber, H. P.; Morton, D.; Gallucci, G. O.; Rocuzzo, M.; Cordaro, L. & Grutter, L. (2009). Consensus statements and recommended clinical procedures regarding loading protocols. *Int J Oral Maxillofac Implants*, vol. 24 Suppl, pp. 180-3.
- Welander, M.; Abrahamsson, I & Berglundh, T. (2009). Subcrestal placement of two-part implants. *Clin Oral Implants Res*, vol. 20, no. 3, pp. 226-31.
- Weng, D.; Nagata, M. J.; Bell, M.; Bosco, A. F.; De Melo, L. G. & Richter, E. J. (2008). Influence of microgap location and configuration on the periimplant bone morphology in submerged implants. An experimental study in dogs. *Clin Oral Implants Res*, vol. 19, no. 11, pp. 1141-7.

- Wennstrom, J.; Zurdo, J.; Karlsson, S.; Ekestubbe, A.; Grondahl, K. & Lindhe, J. (2004). Bone level change at implant-supported fixed partial dentures with and without cantilever extension after 5 years in function. *J Clin Periodontol*, vol. 31, no. 12, pp. 1077-83.
- Wennstrom, J. L.; Bengazi, F. & Lekholm, U. (1994). The influence of the masticatory mucosa on the peri-implant soft tissue condition. *Clin Oral Implants Res*, vol. 5, no. 1, pp. 1-8.
- Wennstrom, J. L.; Ekestubbe, A.; Grondahl, K.; Karlsson, S. & Lindhe, J. (2004). Oral rehabilitation with implant-supported fixed partial dentures in periodontitis-susceptible subjects. A 5-year prospective study. *J Clin Periodontol*, vol. 31, no. 9, pp. 713-24.
- Wennstrom, J. L.; Ekestubbe, A.; Grondahl, K.; Karlsson, S. & Lindhe, J. (2005). Implant-supported single-tooth restorations: A 5-year prospective study. *J Clin Periodontol*, vol. 32, no. 6, pp. 567-74.
- Zitzmann, N. U. & Berglundh, T. (2008). Definition and prevalence of peri-implant diseases. *J Clin Periodontol*, vol. 35, no. 8 Suppl, pp. 286-91.

IntechOpen



Implant Dentistry - A Rapidly Evolving Practice

Edited by Prof. Ilser Turkyilmaz

ISBN 978-953-307-658-4

Hard cover, 544 pages

Publisher InTech

Published online 29, August, 2011

Published in print edition August, 2011

Implant dentistry has come a long way since Dr. Branemark introduced the osseointegration concept with endosseous implants. The use of dental implants has increased exponentially in the last three decades. As implant treatment became more predictable, the benefits of therapy became evident. The demand for dental implants has fueled a rapid expansion of the market. Presently, general dentists and a variety of specialists offer implants as a solution to partial and complete edentulism. Implant dentistry continues to evolve and expand with the development of new surgical and prosthodontic techniques. The aim of *Implant Dentistry - A Rapidly Evolving Practice*, is to provide a contemporary clinic resource for dentists who want to replace missing teeth with dental implants. It is a text that relates one chapter to every other chapter and integrates common threads among science, clinical experience and future concepts. This book consists of 23 chapters divided into five sections. We believe that, *Implant Dentistry: A Rapidly Evolving Practice*, will be a valuable source for dental students, post-graduate residents, general dentists and specialists who want to know more about dental implants.

How to reference

In order to correctly reference this scholarly work, feel free to copy and paste the following:

Theofilos Koutouzis (2011). Crestal Bone Level Alterations in Implant Therapy, *Implant Dentistry - A Rapidly Evolving Practice*, Prof. Ilser Turkyilmaz (Ed.), ISBN: 978-953-307-658-4, InTech, Available from: <http://www.intechopen.com/books/implant-dentistry-a-rapidly-evolving-practice/crestal-bone-level-alterations-in-implant-therapy>

INTECH
open science | open minds

InTech Europe

University Campus STeP Ri
Slavka Krautzeka 83/A
51000 Rijeka, Croatia
Phone: +385 (51) 770 447
Fax: +385 (51) 686 166
www.intechopen.com

InTech China

Unit 405, Office Block, Hotel Equatorial Shanghai
No.65, Yan An Road (West), Shanghai, 200040, China
中国上海市延安西路65号上海国际贵都大饭店办公楼405单元
Phone: +86-21-62489820
Fax: +86-21-62489821

© 2011 The Author(s). Licensee IntechOpen. This chapter is distributed under the terms of the [Creative Commons Attribution-NonCommercial-ShareAlike-3.0 License](#), which permits use, distribution and reproduction for non-commercial purposes, provided the original is properly cited and derivative works building on this content are distributed under the same license.

IntechOpen

IntechOpen