

We are IntechOpen, the world's leading publisher of Open Access books Built by scientists, for scientists

4,800

Open access books available

122,000

International authors and editors

135M

Downloads

Our authors are among the

154

Countries delivered to

TOP 1%

most cited scientists

12.2%

Contributors from top 500 universities



WEB OF SCIENCE™

Selection of our books indexed in the Book Citation Index
in Web of Science™ Core Collection (BKCI)

Interested in publishing with us?
Contact book.department@intechopen.com

Numbers displayed above are based on latest data collected.
For more information visit www.intechopen.com



Computer-Guided Implantology

Rogério Margonar¹, Cássia Bellotto Corrêa²,
Ana Lúcia Roselino Ribeiro², Erika Oliveira de Almeida^{3,4},
Elcio Marcantonio² and Luís Geraldo Vaz²

¹Araraquara University Center - UNIARA, Araraquara, SP,

²São Paulo State University - UNESP, College of Dentistry, Araraquara, SP,

³São Paulo State University - UNESP, College of Dentistry, Araçatuba, SP,

⁴New York University - NYU, College of Dentistry, New York, NY,

^{1,2,3}Brazil,

⁴USA

1. Introduction

Anatomically planned and functionally optimal implant placement has long been a major goal of implant dentistry (Drago, 1994.; Garber & Belser, 1995). Many surgical procedures are necessary to the optimal placement of the implant. Thus, it would be of great clinical advantage for patients to have dental implants placed flapless and immediately loaded with prosthesis, delivered just after surgery. Post-operative morbidity and treatment times could be reduced significantly (Cannizzaro et al., 2008; Meloni et al., 2010). Thereby the growing interest for flapless surgery in conjunction with immediate loading of the edentulous patients has led to the development of software programs that allow treatment planning, fabrication of a surgical template, as well as the production of a prosthesis that can be secure to the patient immediately after the placement of the implants (Fuster-Torres et al., 2009).

However, the accurate diagnostic is the main factor for the treatment success. The edentulous patients generally have resorption when they loose their teeth.

The resorption can be related to bone loss and bone loss associated with the soft tissue. The type of resorption is decisive to determine the kind of fixed implant supported prosthesis. Patients who lost soft tissue and underlying supporting bone in addition to teeth may be considered to have a composite defect. To evaluate the relative amount of soft tissue deficiency, it is suggested to utilize a denture or denture set-up in wax that has been confirmed for proper tooth position, border extension, and relationship between the arcs (Bedrossian et al., 2008). So, an appropriate selection of the type of prosthesis is fundamental in the beginning of the treatment planing using implants.

There are two main objectives of computer-aided design (CAD), computer-aided machining (CAM): guided dental implant placement and restoration. The first allow the precise planning of implant positions on computed tomography scans, and the second is to generate an accurate surgical guide that permits the surgeon to place implants precisely into planned positions allowing the immediate prosthesis placement (Fuster-Torres et al., 2003).

Thus the objective of this chapter is to discuss the indications, contraindications, protocol preparation, maintenance problems and postoperative-guided in implantology.

2. Guided surgery

The use of software associated with digital images, acquired from computerized tomography, it is a new trend in dentistry. The CAD/CAM technologies associated with stereolithography provide to the professional tools to improve the planning and the rehabilitation with more security.

The use of software combined with three-dimensional images obtained by computerized tomography enables the professional to evaluate the optical density, to measure the bone thickness and, therefore, to choose the implant size and its appropriate positioning in the arch (Spin-Neto et al. 2011).

The guided surgery is a highly accurate in implantology. By this technique, the extensive amount of information obtained in a virtual planning is transferred for the surgical field by means of surgical guides manufactured in stereolithography (Parel & Triplett, 2004). Later, the advantages and limitation of the surgical guide will be discuss.

2.1 Indications

The guided surgery is indicated both for total edentulous patients (Casap et al., 2005 ;Van Steenberghe et al., 2004) as for partially edentulous patients (Fortin et al. 2003; Kupeyan et al., 2006; Marchack, 2007; Serry et al., 2007).

The guided surgery is counter-indicated for patients with reduced mouth opening that jeopardizes positioning of surgical instruments on the guide (Almeida et al., 2010).

This technique has several advantages compared to the conventional open flap surgery. These are the preservation of the vital anatomical structures, minimal invasive surgery, faster and simpler technique and leads to less discomfort to the patient after the surgery (Kupeyan et al., 2006; Van Steenberghe et al., 2004; Becker et al., 2005; Widmann et al., 2010) as well as lower risk of infection. However, due to the use of a range of sophisticated technology and specialized instrumentals, the guided surgery technique has a higher cost compared to the conventional surgery. In addition, some authors reports that the surgical guide can be unstable for completely edentulous patient mainly when only remaining soft tissue is present. (Bedrossian, 2007; Holst et al., 2004).

2.2 Technique

Before the tomography, some steps are necessary to assist the planning, as a specific clinical exam. In this session, it is important to evaluate the existing prosthesis of the patient, relationship between the arches, the dental occlusal pattern and the inter maxillary distance. An initial clinical exam is accomplished to evaluate the relationship among the arches, the occlusal pattern and the inter maxillary distance.

For the total edentulous patients, it is fabricated the total prosthesis with appropriate vertical dimension of occlusion (Figure 1). After that, the prosthesis should be duplicated to facilitate the tomography guide construction. To associate the edentulous arches to the tomographic guide at the software the radiopaque marks of barium sulfate are made in the guide near the canine or molar region (Figure 2). The relationship of the maxillary and mandibular arches is registered using condensation silicone.

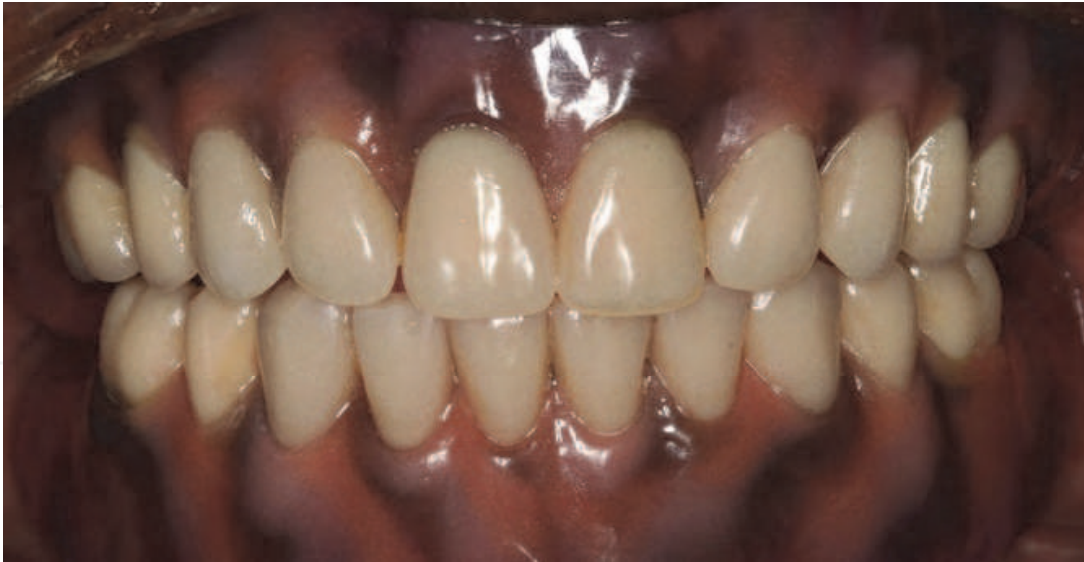

Fig. 1. Total prosthesis with appropriate vertical dimension of occlusion.

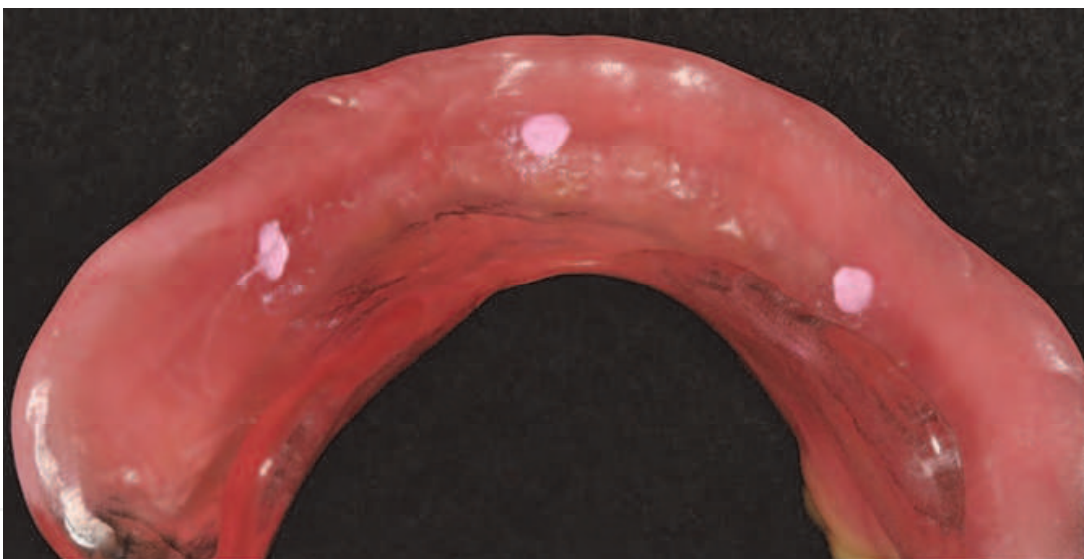


Fig. 2. Tomographic guide with radiopaque marks.

Virtual planning:

The virtual planning has two steps in the computed tomography (CT): the double scanning technique of the patient (Widmann et al., 2007) with both tomographic guide in position and the CT of the guide alone to superimpose the images later in the software. During the CT the complete denture should have adequate positioning in relation to the antagonist arch and the anatomy of the soft tissues. The patient can be asked to use an adhesive to improve stabilization of the denture during the scanning (Almeida et al., 2010). Afterwards, the CT is transformed in 3D images with DICOM extension. It is necessary conversion to a planning guide software, as DentalSlice® (Bioparts, prototipagem biomédica, São Paulo, Brazil).

At this moment, the virtual planning can be made into the software by the prosthodontics and surgery professionals. They can choose the best three-dimensional position of each

implant based in the quantity and quality of bone and at emergence profile of the artificial teeth represented by the image of the guide. Wherever possible, it is recommended to plan the posterior implant more distant to the anterior in order to reduce the cantilever. (Figure 3).

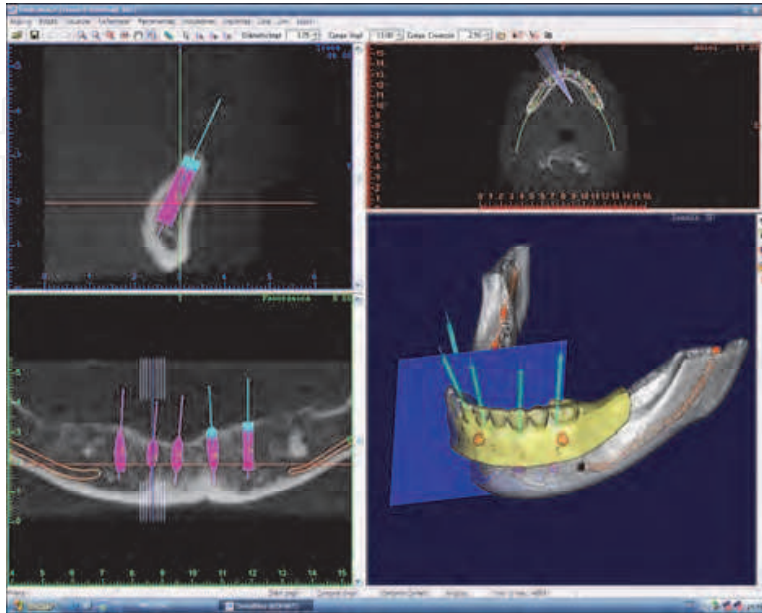


Fig. 3. Virtual planning of the surgery in the DentalSlice Software (Bioparts, Brazil).

Technique description:

After the prototyping and the guide confection, the guide is tested to verify the adequate position to the edentulous area and the dental position. The guide should touch the edentulous area being passive and avoiding ischemic areas (Figure 4).

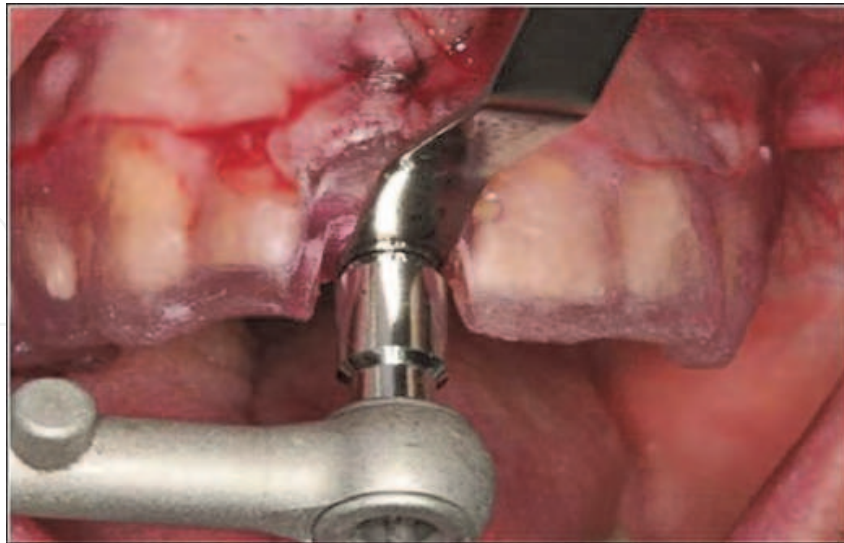


Fig. 4. Surgical guide for partially edentulous patient.

The drill guide inside the guide is important to assist the direction of the surgical drill during perforation to avoid lateral deviations (Valente et al., 2009) (Figure 5). The guides should be sterilized according to the manufacturer indications.

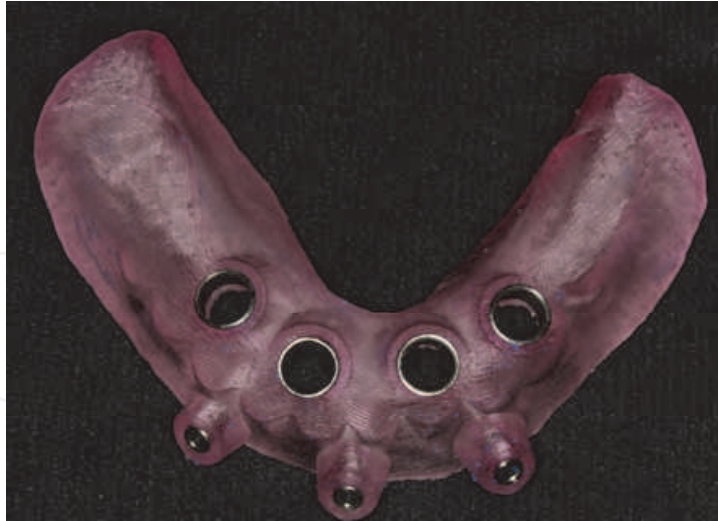

Fig. 5. Mandible surgical guide.

At the moment of the surgery, the first step is the distant local anesthesia because the region can develop edema areas and prevent the guide adaptation.

Later, the guide is stabilized at the planned dental occlusion using the silicone and the retaining pins are screwed at the buccal region to stabilize the guide in the correct position (Figure 6).

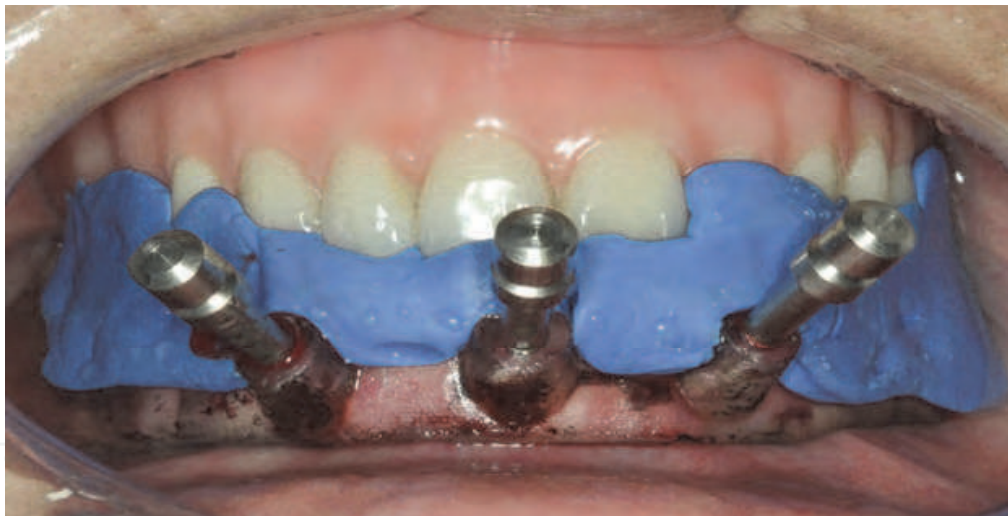

Fig. 6. Surgical guide stabilization at the planned dental occlusion.

Afterwards, the mucous membrane can be removed below the drill guide by punch (Figure 7). The perforations should respect the progressive sequence of drills with their guides corresponding to the diameter of the drill to be used (Slice-guide, Conexão Sistema de Prótese Ltda, Arujá, SP).

The sequence of drill was used with its respective guide with intermittent movement and abundant irrigation to avoid heating of the bone tissue. The speed of the drill can vary from 400 to 800 rpm, depending on the bone quality. The long length of the drill is a limitation of this technique for reduced mouth opening.

After the drill perforations, it is recommended to start the installation of the implants by the intermediary positions ones to avoid the guide displacement (Figure 8).

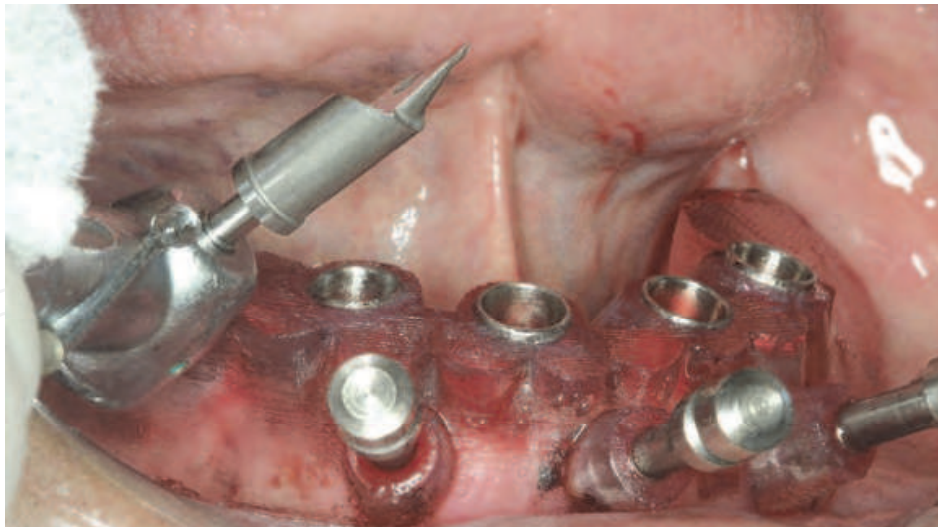


Fig. 7. Punch used to remove the mucous membrane bellow the drill guide.

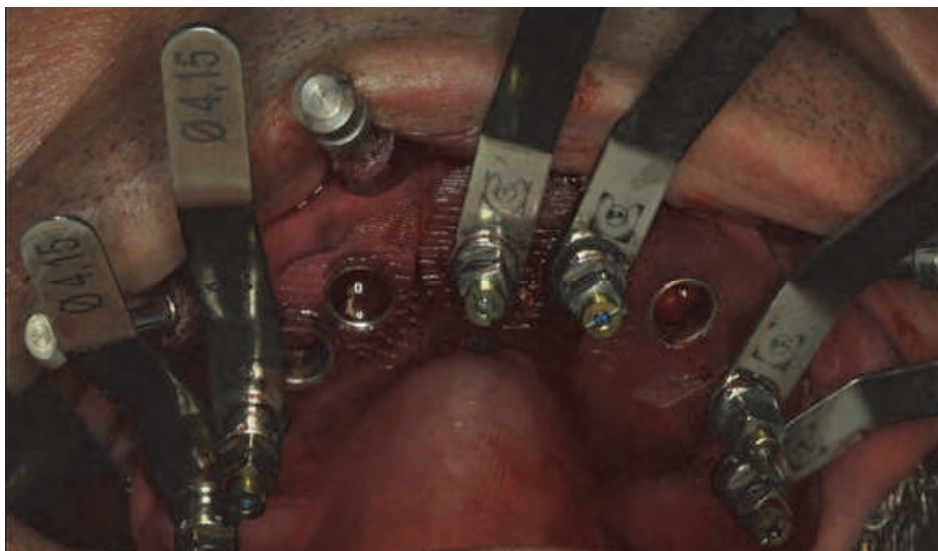


Fig. 8. Placement of implants.

When the last implant is installed, all screws and the palate fixation are removed together with the guide (Figure 9).

For the placement of an immediate prosthesis, all implants should have an appropriate primary stability, in other words, an initial torque around 40N.cm.

There are two options for prosthesis confection: prosthesis fabricated before the implants installation surgery or prosthesis fabricated after the surgery.

2.3 Manufacturing of the prosthesis

Prosthesis fabricated after the guided surgery:

Firstly, the impression coping are attached to the implant and the surgical guide is positioned (Figure 10). Thereafter, the impression coping are conected with auto polimerized resin (Pattern Resin LS; GC America, Alsip, Ill) to record the implant position (Figure 11).

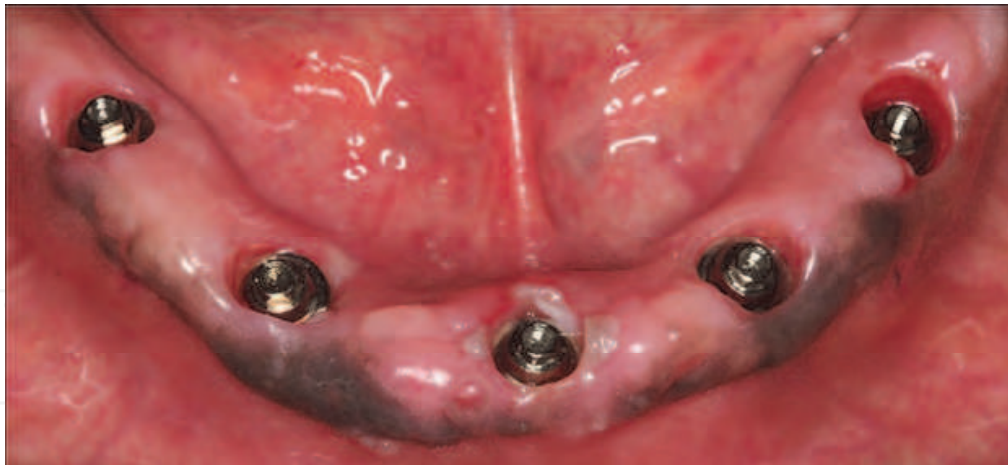

Fig. 9. Final aspect of the soft tissue after the surgical guide been removed.

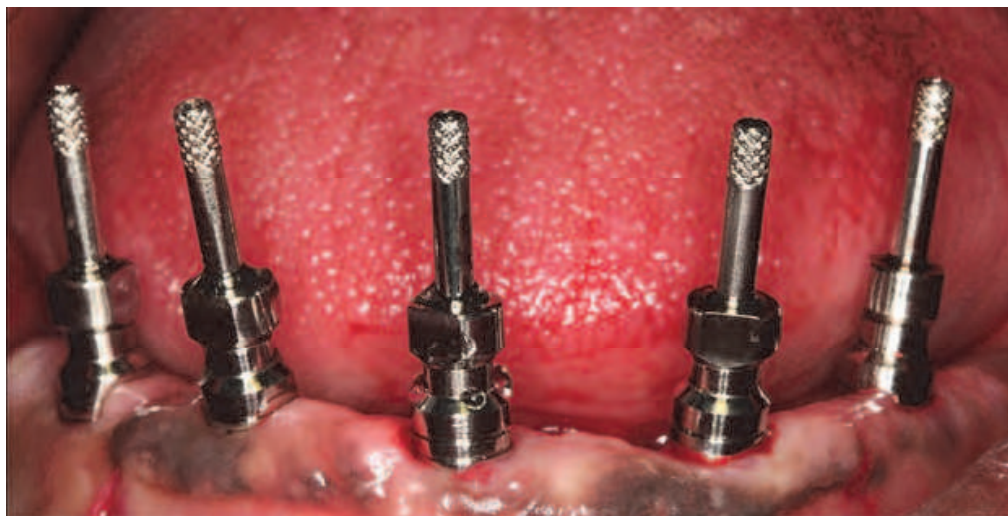

Fig. 10. Impression coping attached at the implants.

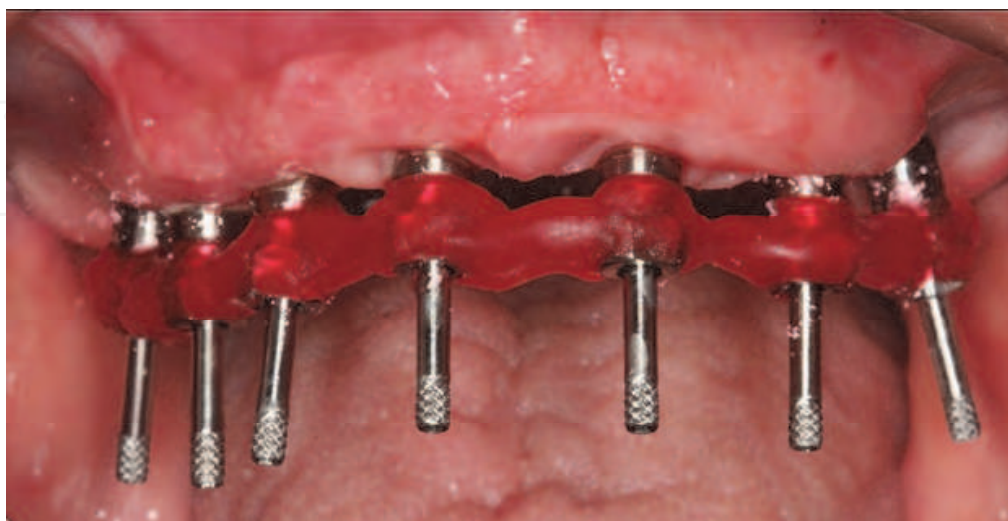


Fig. 11. Impression coping connected with autopolymerized acrylic resin (Patter Resin LS) to record the implant position

Impression coping are carried out in both arches using the same surgical guide and condensation silicone (Zetaplus/Oranwash; Zhermack, Rovigo, Italy) (Figure 12). Then, the analogs are attached to the transfer copings before dental stone pouring. In laboratorial phase, the implant superstructure and the teeth in wax are positioned on a base of light-polymerized resin on the working cast (Margonar et al., 2010a). The implant superstructure is attached to the implant to verify the passive fit (Figure 13). Later, the teeth in wax on the base of light-polymerized resin are tested on the superstructure (Sterngold Implamed, São Paulo, Brazil) during the same clinical session (Margonar et al., 2010a) (Figure 14).

On the second day, the immediate implant-supported fixed dentures are inserted and the occlusion is evaluated in order to favor the force distribution (Figure 15). The appropriate three-dimensional positioning of the implants was verified by panoramic radiography and computed tomography and that can preview the success of the treatment (Figure 16 and 17).

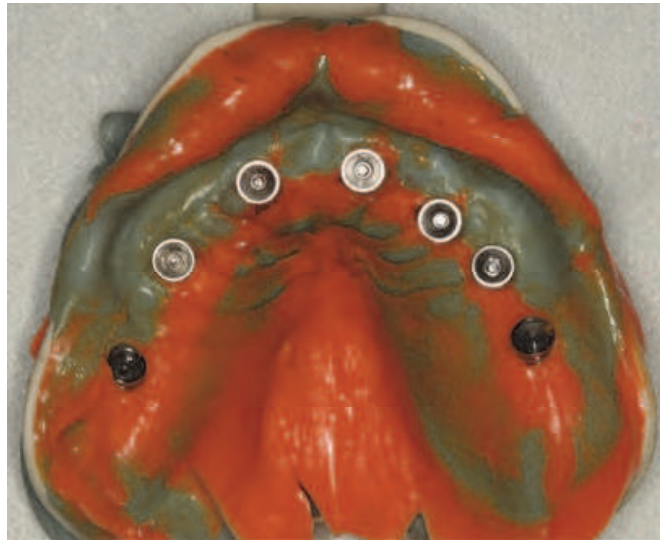

Fig. 12. Mold obtained.

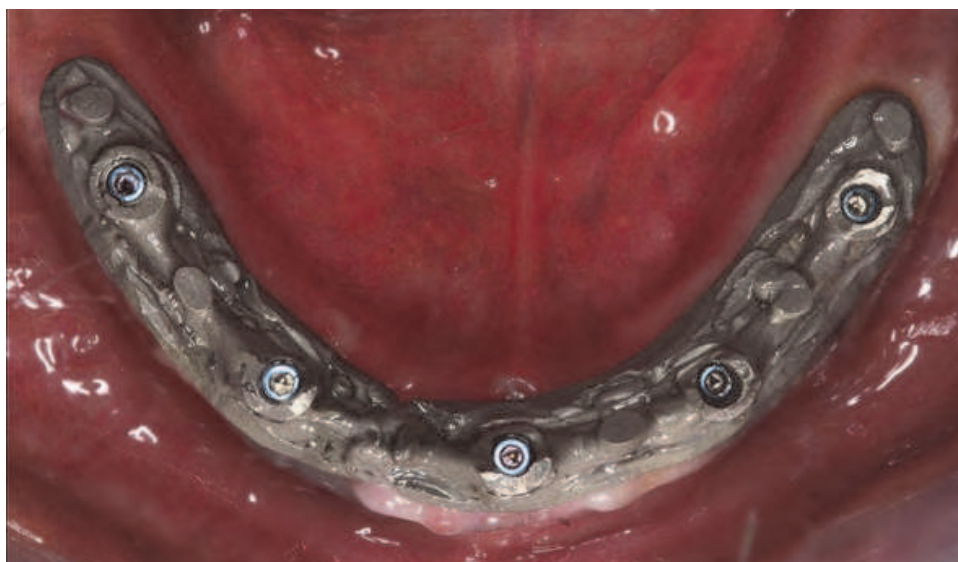

Fig. 13. The implant superstructure attached to the implant to verify the passive fit.

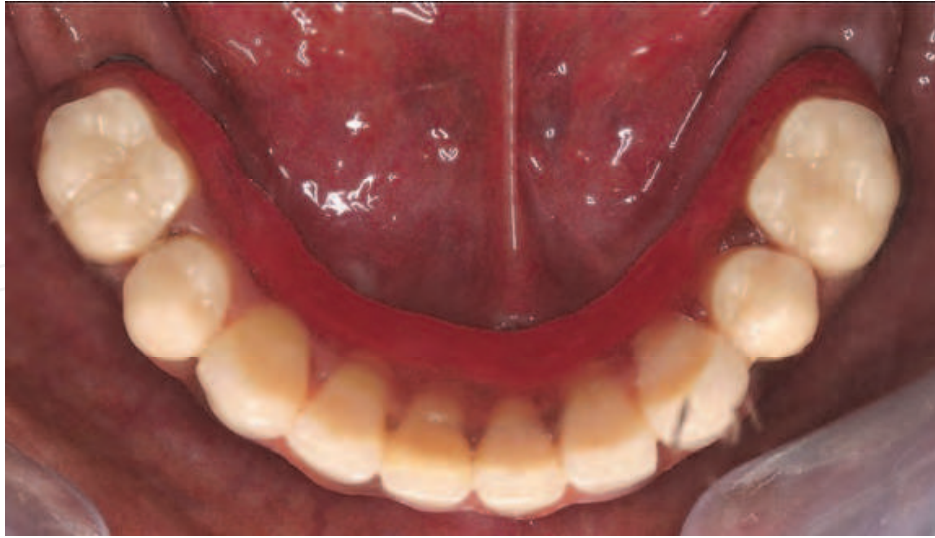

Fig. 14. Teeth in wax on the light-polymerized resin plate.

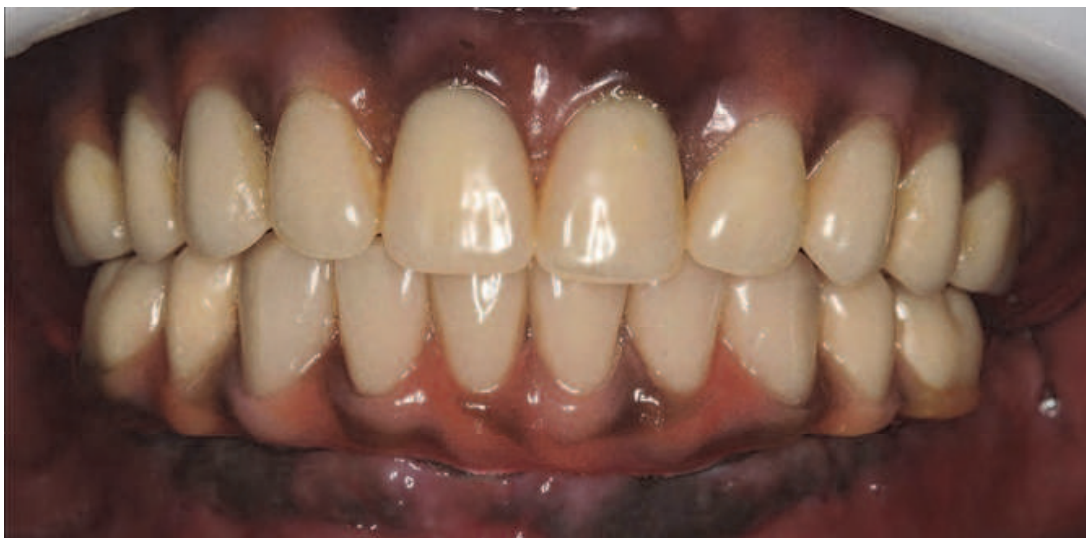

Fig. 15. Final view of the immediate implant-supported fixed denture installed.

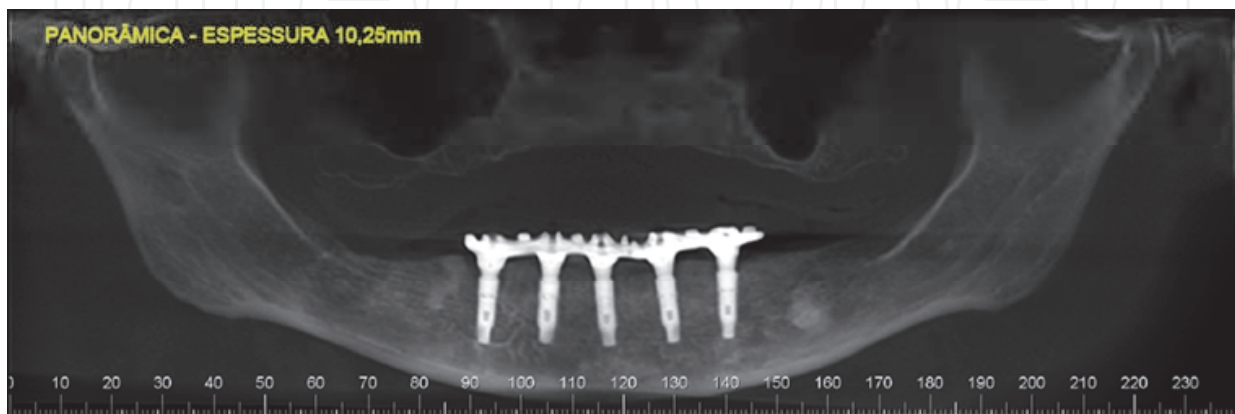


Fig. 16. Panoramic radiography showing the appropriate positioning of the implants.

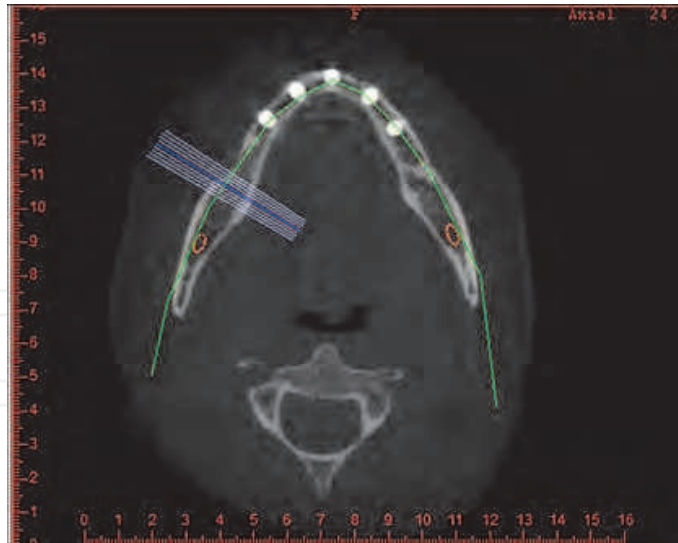


Fig. 17. Computed tomography showing the appropriate three-dimensional positioning of the implants.

Prosthesis fabricated before the guided surgery:

Some techniques have been cited in the literature for the fabrication of prosthesis before the guided surgery. These techniques use the passive cementation. One of them uses the Nobel Biocare system. In this technique the surgical guide is used to make a master model, the abutments are selected, and then the titanium cylinders are placed onto the abutments for the bridge manufacture, that is immediately secured to the implants, installed by the guided surgery (Bedrossian et al., 2008).

Another technique is the technique of the cemented cylinder (Siirilä et al. 1988; López, 1995). In this technique the components installation in the mouth is done after the guided surgery. They are selected previously with torque from 20 to 32N.cm. It is accomplished the molding of the components for the fabrication of an index. And it is made the cementation of the cylinders inside the prosthesis in agreement with the index. Then, it is made the cementation of the prosthesis in the mouth (Siirilä et al. 1988; López, 1995).

2.3 Complications

The complications in guided surgery can be divided in early complications and late complications:

Early complications: lack of primary stability (Yong & Moy, 2008), loosening of prosthesis screw (Young & Moy, 2008), slight genial tumefaction (Gillot et al., 2010), difficulty in speech and bilateral cheek occlusion (Young & Moy, 2008), jugal hematoma (Gillot et al., 2010) and heating of tissues (Figure 18).

Margonar et al., 2010b, evaluated bone tissue heating and the wear drills after repeated osteotomies for implants, simulating the guided surgery technique and comparing it with the classical technique. According to that study, the heating of the bone tissue due to the guide surgery technique was higher when compared with the conventional open flap surgery during the preparation of the surgical site, but both techniques have not reached the threshold temperature that causes immediate necrosis.

Late complications: persistent pain (Gillot et al., 2010), gingival recession (Yong & Mo, 2008), osseointegration loss (Yong & Moy, 2008). The success rate ranges from 83 to 100% (Canizzaro et al., 2008; Komiyama et al., 2008; Schneider et al., 2009; Van Steenberghe et al., 2005).

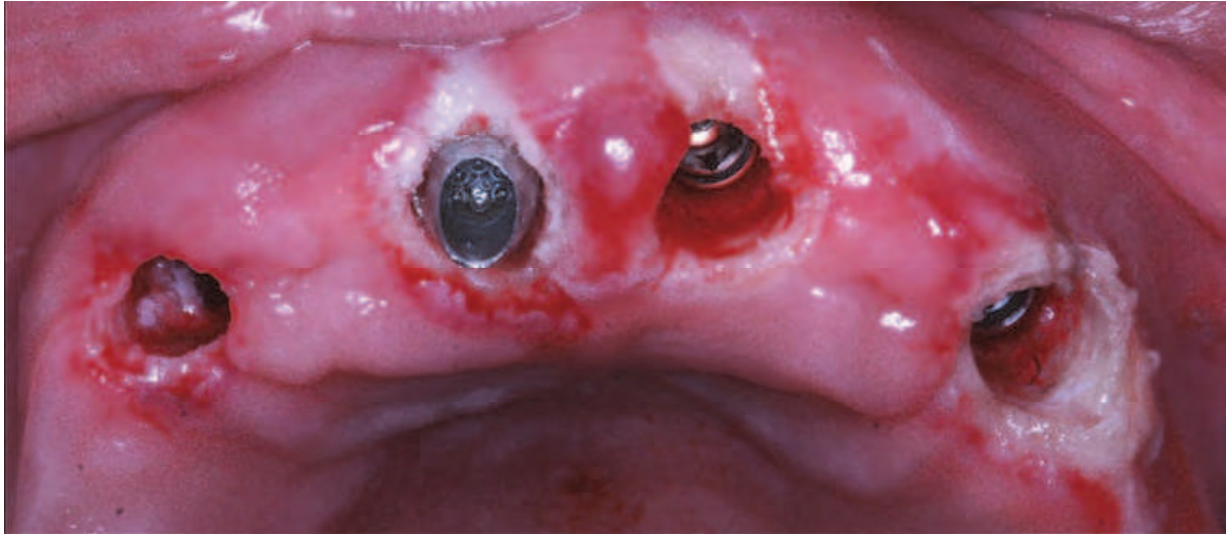


Fig. 18. Soft tissue with necrotic aspect due to heating in the region.

2.4 Mistakes in guided surgery

The computer-guided surgery has a sequence from the diagnostic stage to the prosthetic, and mistakes may occur in different stages. The most common mistakes found in the literature are as follows:

1. Mistake on acquisition of tomographic image or incorrect processing (mean of error <0.5 mm) (Reddy et al., 1994; Valent et al., 2009).
2. Deviation of 0.1 a 0.2 mm on fabrication of the surgical guide (Valent et al., 2009; Van Steenberghe et al., 2002.)
3. Inaccurate fixation of the guide resulting in displacement during perforation (Valent et al., 2009).
4. Mechanical errors caused by angulation of the drills during perforation that may cause lateral deviations (Valent et al., 2009).
5. Changed positioning of surgical instruments due to reduced mouth opening (Valent et al., 2009).
6. Human mistakes as not using the whole length of the drill during perforation (Valent et al., 2009).

3. Conclusion

The guided surgery is an excellent option of treatment for patients with satisfactory bone quantity for implant insertion. The guided surgery can be indicated for complete and partially edentulous arches in the maxilla and/or mandible.

When properly prescribed and monitoring, the virtual planning and the guide surgery are excellent tools used in implantology to perform surgical procedures with more safety, confort and predictability to the patient.

4. Acknowledgment


The authors gratefully acknowledge "Conexão Sistemas de Próteses Ltda" for supplying the implants, "DVI: Diagnóstico Volumétrico por Imagem" for providing the tomographies and "BIOPARTS: prototipagem biomédica" for supplying prototyping used in this study.

5. References

- Almeida, E.O.; Pellizzer, E.P.; Goiatto, M.C; Margonar, R.; Rocha, E.P.; Freitas-Jr, A.C. & Anchieta, R.B. (2010). Computer-Guided Surgery in Implantology: Review of Basic Concepts. *The Journal of Craniofacial Surgery*. Vol.21, No. 6, pp,1917-1921, ISSN 1049-2275.
- Azari, A. & Nikzard, S. Computer-ssisted implantology: historical background and potential outcomes - a review (2008). *The International Journal of Medical Robotics and Computer Assisted Surgery*. Vol.4, No.2, pp.95-104, ISSN 1478-596X.
- Becker, W.; Goldstein, M.; Becker, B.E. & Sennerby, L. (2005). Minimally invasive flapless surgery: a prospective multicenter study. *Clinical Implant Dentistry and Related Research*. Vol.7 (Suppl), pp.21-27, ISSN1523-0899.
- Bedrossian E. (2007). Laboratory and prosthetic considerations in computer-guided surgery and Immediate Loading. *International Journal of Oral & Maxillofacial Surgery*, Vol.66, No.1 (January 2008), Vol.65 , No.7 Suppl 1, pp.47-52, ISSN 0901-5027.
- Bedrossian, E.; Sullivan, R.M.; Fortin, Y.; Malo, P. & Intedresano, T. (2008). Fixed-prosthetic implant restoration of the edentulous maxilla: a systematic pretreatment evaluation method. *International Journal of Oral & Maxillofacial Surgery*, Vol.66, No.1 (January 2008), pp.112-122, ISSN 0901-5027.
- Cannizzaro, G.; Leone, M.; Consolo, U.; Ferri, V. & Esposito, M (2008). Immediate functional loading of implants placed with flapless surgery versus conventional implants in partially edentulous patients. A 3-year randomized controlled clinical trial. *The International Journal of Oral & Maxillofacial Implants*, Vol.23, No.5, pp. 867-875, ISSN 0882-2786.
- Casap, N.; Terazi, E.; Wexler, A.; Sonnenfeld, U. & Lustmann, J (2005). Intraoperative computerized navigation for flapless implant surgery and immediate loading in the edentulous mandible. *The International Journal of Oral & Maxillofacial Implants*, Vol.20, No.1, pp.92-98, ISSN 0882-2786.
- Drago, C. J. (1994). Prosthodontic complications related to compromised implant placement. *Journal of Oral Maxillofacial Surgery*, Vol.52, No.1, (January 1994), pp. 15–22, ISSN 0278-2391.
- Fortin, T.; Bosson, J.L.; Coudert, J,L.& Isidori, M. (2003). Reliability of preoperative planning of an image-guided system for oral implant placement based on 3-dimensional images: an in vitro study. *The International Journal of Oral & Maxillofacial Implants*, Vol.18, No.6, pp.886-893, ISSN 0882-2786.
- Fuster-Torres, M.A.; Albalat-Estrela, S.; Alcañiz-Raya, M. & Peñarrocha-Diao, M.; (2009). CAD / CAM dental systems in implant dentistry: update. *Medicina Oral , Patología Oral y Cirugía Bucal*. Vol.14, No.3 (March 2009), pp.141-145 , ISSN 1698-4447.
- Garber, D. A. & Belser, U. C. (1995). Restoration-driven implant placement with restoration-generated site development. *Compendium of Continuing Education in Dentistry*, Vol.16, No.8, (August 1995), pp. 796,798–802,804, ISSN 1548-8578.
- Gillot, L.; Noharet, R. & Cannas, B. (2010). Guided Surgery and Presurgical Prosthesis: Preliminary Results of 33 Fully Edentulous Maxillae Treated in Accordance with the NobelGuide® Protocol. *Clinical Implant Dentistry and Related Research*. Vol.12, Suppl 1, ISSN 1523-0899.
- Holst, S.; Blatz, M.B.; Wichmann, M. & Eitner, S. (2004). Clinical application of surgical fixation screws in implant prosthodontics – Part I: positioning of radiographic and

- surgical templates. *Journal of Prosthetic Dentistry*. Vol.92, No4, pp395-398, ISSN 0022-3913.
- Komiyama, A.; Klinge, B. & Hultin, M. (2008). Treatment outcome of immediately loaded implants installed in edentulous jaws following computer-assisted virtual treatment planning and flapless surgery. *Clinical Oral Implants Research*. Vol.19, No.7, pp.677-685.
- Kupeyan, H.K.; Shaffner, M. and Armstrong, J. (2006). Definitive CAD/CAM-guided prosthesis for immediate loading of bone-grafted maxilla: a case report. *Clinical Implant Dentistry and Related Research*. Vol.8, No.3, pp.161-167, ISSN1523-0899.
- Lal, K.; White, G.S.; Morea, D.N. & Wright, R.F. (2006). Use of stereolithographic templates for surgical and prosthodontics implant planning and placement. Part I. The concept. *Journal Prosthodontics*. Vol.15, No.1 (January-February 2006), pp.51-58, ISSN:1059-941X.
- López, V.J. (1995). Prótese sobre implantes: oclusão, casos clínicos e laboratório. São Paulo - Brazil. Ed. Quintessence.
- Marchack, C.B. (2007). CAD/CAM-guided implant surgery and fabrication of an immediately loaded prosthesis for a partially edentulous patient. *The Journal of Prosthetic Dentistry*. Vol.97, No.6, pp.389-394, ISSN 0022-3913.
- Margonar, R.; Almeida, E.O.; Queiroz, T.P.; Marcantonio, E. (2010a). Wax Teeth and Metallic Superstructure Trials at the Same Session: Simplified Technique for Implant-Supported Prosthesis. *The Journal of Craniofacial Surgery*. Vol.21, No.6, (November 2010), ISSN 1049-2275.
- Margonar, R.; Queiroz, T.P.; Santos, P.L.; Carvalho, E.R.; & Luvizuto, E.R.; Souza, F.A.; Okamoto, R.; Magro-Filho, O.; Hochuli-Vieira, E. & Garcia-Júnior, I.R. (2010b) Bone healing after implant osteotomies using the guided surgery. *Journal of Dental Research*, Vol. 89, Special Issue B, Retrieved from <URL> <http://iadr.confex.com/iadr/2010barce/webprogramcd/Paper137398.html>
- Meloni, S.M.; De Riu, G.; Pisano, M.; Cattina, G. & Tullio, A. (2010). Implant treatment software planning and guided flapless surgery with immediate provisional prosthesis delivery in the fully edentulous maxilla. A retrospective analysis of 15 consecutively treated patients. *European Journal of Oral Implantology*, Vol.3, No.3, pp. 245-251, ISSN 1756-2406.
- Parel, S.M. & Triplett, R.G. (2004). Interactive imaging for implant planning, placement, and prosthesis construction. *International Journal of Oral & Maxillofacial Surgery*, Vol.62, No.9 (Suppl 2), pp.41-47, ISSN 0901-5027.
- Reddy, M.S.; Mayfiel-Donahoo, T.; Vandervan, F.J. & Jeffcoat M.K. (1994). A comparison of the diagnostic advantages of the panoramic radiography and computed tomography scanning for placement of root-form dental implants. *Clinical Oral Implants Research*. Vol.5, No.4, pp.229-238.
- Schneider, D.; Marquardt, P.; Zwahlen, M. & Jung, R.E. (2009). A systematic review on the accuracy and the clinical outcome of computerguided template-based implant dentistry. *Clinical Oral Implants Research*. Vol.20, Suppl. 4, pp.73-86, ISSN 0905-7161.
- Serry, J.S.; Sims, L.O. & Balshi, S.F. (2007). A simple technique for immediate placement of definitive engaging custom abutments using computerized tomography and

- flapless guided surgery. *Quintessence International*. Vol.38, No. 9, pp.755–76, ISSN 0033-6572.
- Siirilä, H.S.; Nordberg, L.; Oikarinen, V.J. (1988). Technique for converting an existing complete denture to a tissue-integrated prosthesis. *The journal of Prosthetic Dentistry*. Vol 59, No.4, pp463-467, ISSN 0022-3913.
- Spin-Neto, R.; Marcantonio-Jr, E., Gotfredsen, E. & Wenzel, A. (2011). Exploring CBCT-Based DICOM Files. A Systematic Review on the Properties of Images Used to Evaluate Maxillofacial Bone Grafts. *Journal of Digital Imaging*. Retrieved from <URL> <http://www.ncbi.nlm.nih.gov/pubmed/21448762>.
- Valente, F.; Schioli, G. & Sbrenna, A. (2009). Accuracy of computer-aided oral implant surgery: a clinical and radiographic study. *The International Journal of Oral & Maxillofacial Implants*, Vol.24, No.2, pp.234-242, ISSN 0882-2786.
- Van Steenberghe, D.; Naert, I.; Andersson, M.; Brajnovic, I.; Van Cleynenbreugel, J. & Suetens P. (2002). A custom template and definitive prosthesis allowing immediate implant loading in the maxilla: a clinical report. *The International Journal of Oral & Maxillofacial Implants*, Vol.17, No.5, pp.663-670, ISSN 0882-2786.
- Van Steenberghe, D.; Glauser, R.; Blomback, U.; Andersson, M.; Schutyser, F.; Pettersson A. & Wenelhaq I. (2005). A computed tomographic scan-derived customized surgical template and fixed prosthesis for flapless surgery and immediate loading of implants in fully edentulous maxillae: a prospective multicenter study. *Clinical Implant Dentistry and Related Research*. Vol.8, No.3, pp.111-120, ISSN1523-0899.
- Widmann, G.; Stoffner, R.; Schullian, P.; Widmann, R.; Keiler, M.; Zangerl, A.; Puelacher, W. & Bale, R.J. (2010). Comparison of the Accuracy of Invasive and Noninvasive Registration Methods for Image-Guided Oral Implant Surgery. *International Journal of Oral & Maxillofacial Surgery*, Vol.25, No.3, pp.491-498, ISSN 0901-5027.
- Widmann, G.; Widmann, R.; Widmann, E.; Jaschke, W. & Bale, R. (2007). Use of a surgical navigation system for CT-guided template production. *The International Journal of Oral & Maxillofacial Implants*, Vol.22, No.1, pp.72-78, ISSN 0882-2786.
- Yong, L.T. & Moy, L.T. (2008). Complications of Computer-Aided-Design/Computer-Aided-Machining-Guided (NobelGuide™) Surgical Implant Placement: An Evaluation of Early Clinical Results. *Clinical Implant Dentistry and Related Research*. Vol.10, No.3, (September 2008), pp.123-127, ISSN 1523-0899.



Implant Dentistry - A Rapidly Evolving Practice

Edited by Prof. Işer Turkyilmaz

ISBN 978-953-307-658-4

Hard cover, 544 pages

Publisher InTech

Published online 29, August, 2011

Published in print edition August, 2011

Implant dentistry has come a long way since Dr. Branemark introduced the osseointegration concept with endosseous implants. The use of dental implants has increased exponentially in the last three decades. As implant treatment became more predictable, the benefits of therapy became evident. The demand for dental implants has fueled a rapid expansion of the market. Presently, general dentists and a variety of specialists offer implants as a solution to partial and complete edentulism. Implant dentistry continues to evolve and expand with the development of new surgical and prosthodontic techniques. The aim of *Implant Dentistry - A Rapidly Evolving Practice*, is to provide a contemporary clinic resource for dentists who want to replace missing teeth with dental implants. It is a text that relates one chapter to every other chapter and integrates common threads among science, clinical experience and future concepts. This book consists of 23 chapters divided into five sections. We believe that, *Implant Dentistry: A Rapidly Evolving Practice*, will be a valuable source for dental students, post-graduate residents, general dentists and specialists who want to know more about dental implants.

How to reference

In order to correctly reference this scholarly work, feel free to copy and paste the following:

Rogério Margonar, Cássia Bellotto Corrêa, Ana Lúcia Roselino Ribeiro, Erika Oliveira de Almeida, Elcio Marcantonio and Luís Geraldo Vaz (2011). Computer-Guided Implantology, *Implant Dentistry - A Rapidly Evolving Practice*, Prof. Işer Turkyilmaz (Ed.), ISBN: 978-953-307-658-4, InTech, Available from: <http://www.intechopen.com/books/implant-dentistry-a-rapidly-evolving-practice/computer-guided-implantology>

INTECH
open science | open minds

InTech Europe

University Campus STeP Ri
Slavka Krautzeka 83/A
51000 Rijeka, Croatia
Phone: +385 (51) 770 447
Fax: +385 (51) 686 166
www.intechopen.com

InTech China

Unit 405, Office Block, Hotel Equatorial Shanghai
No.65, Yan An Road (West), Shanghai, 200040, China
中国上海市延安西路65号上海国际贵都大饭店办公楼405单元
Phone: +86-21-62489820
Fax: +86-21-62489821

© 2011 The Author(s). Licensee IntechOpen. This chapter is distributed under the terms of the [Creative Commons Attribution-NonCommercial-ShareAlike-3.0 License](https://creativecommons.org/licenses/by-nc-sa/3.0/), which permits use, distribution and reproduction for non-commercial purposes, provided the original is properly cited and derivative works building on this content are distributed under the same license.

IntechOpen

IntechOpen