

We are IntechOpen, the world's leading publisher of Open Access books Built by scientists, for scientists

4,800

Open access books available

122,000

International authors and editors

135M

Downloads

Our authors are among the

154

Countries delivered to

TOP 1%

most cited scientists

12.2%

Contributors from top 500 universities



WEB OF SCIENCE™

Selection of our books indexed in the Book Citation Index
in Web of Science™ Core Collection (BKCI)

Interested in publishing with us?
Contact book.department@intechopen.com

Numbers displayed above are based on latest data collected.

For more information visit www.intechopen.com



Dental Implant Imaging: How CT Scan Became a Help to Surgery

Marion Lahutte-Auboin, Amir Ait-Ameur,
Virgine Decat and Laurent Hauret
*Val-de-Grâce Hospital
Paris
France*

1. Introduction

Imaging has always been an important part of dental implant procedures from its beginning.

Radiologists and dentists always worked together in the dental implant field, where imaging takes a major place. Year after year, their respective roles have changed, as we shall see further.

At the beginning, dentists performed imaging. Originally dental panoramic X-ray was prescribed for first screening checkup (Abrahams, 1990, 1993).

Of course the emergence of CT scan at the end of the seventies revolutionizes data collection (Bränemark, 1995, Albrektsson & Johansson, 2001), dentists had quickly understood dentascans' interest. They didn't have access to heavy medical imaging tools without radiologists. They lost the monopoly of imaging management.

These radiologists took place at the heart of radiation risk assessment, and played a major role in image generation and distribution. So collaboration between radiologists and dentists came out. Each actor's role was well-defined. Radiologist controls radiological source and imaging data management, dentist handles implant plan.

But development of dedicated software modifies habits. In fact it enables dentists recovery and utilization of imaging data. Radiologist sometimes becomes service provider, dentist managing by himself images and data.

More recently, in the last five years, a revolution is occurring with the availability of "cone beam" CT machines (Rouas et al., 2006, 2007) in dental offices and directly in dental surgery enables dentists to manage all the stages, from diagnosis, choice of imaging technique, generation and distribution of imaging data, implant planning, to surgical step. Nowadays radiologist takes place as a specialist in dental imaging, that pays attention to up-to-date and evolution of dental implant techniques.

After a fast reminder of the place of CT scan in dental implant diagnosis, this chapter takes an interest in imaging software, developed for surgical help.

The three principal softwares created for dental implant planification are called Simplant, Nobel Guide, and Robodent. They are mainly designed for surgical act.

2. Help to diagnosis (Cavézian et al., 2006)

2.1 Dental panoramic X-ray

This radiography shows at one sight lower and upper jawbone overall.

It's bringing to light missing teeth of course, but also radicular lesion, radicular granuloma, dental fillings extrusion, calcifications, demineralization, bone lesions, included tooth (Liu, 2006). It often shows maxillary canal. But this imaging does not allow dentist to take measurements, indeed it is a flat projection of curved surface. It is just a first screening checkup. However this technique is sufficient to reject implant plan because of substantial demineralization.

2.2 Denta-scanner

It is a very accurate method of jawbone's exploration. It enables dentists to obtain morphological analysis of implant site and bone structure. The initial acquisition gives millimetric slices in axial plan with high resolution. Acquisition volume is parallel to occlusal plan, which is located on a profil scout-view of the face (Muppararu, 2004).

Denta-scanner multiplanar reconstructions from axial millimetric acquisition observe perpendicular plan to maxillary or mandibular arch, but also follow panoramic plan (flat projection of curved surface) (Cazevian&Pasquet, 2008). They give different measurements as bone cortical thickness, and dental space (Cazevian et al., 1995, Chiarelli et al., 2010). There are some artifacts, caused by amalgam or metallic prosthesis.

2.3 Cone beam CT

It consists in a new device family using cone-shaped X-ray emission. It enables multiplanar reconstructions of dento-maxillary sphere (Hauret et al., 2009). The device includes X-ray source which emits cone-shaped beam with constant width. X-ray run through body to explore and finish the course on a flat detector (Hintze, 2007). This system generates a single 360 or 180 degrees rotational movement around the head of the patient. A short X-ray pulse is released each degree, giving 360 (or 180) images (Patel et al., 2007). Because of cone-shaped beam, the rotation of this complex is sufficient to give raw data, without patient's translation (Cazévian et al., 2006).

Several technical differences occur according to manufacturer:

- detection system,
- exploration field of view ,
- combination with panoramic X-ray,
- acquisition duration,
- voxel's size,
- metallic artifacts.

2.4 Purposes

The purpose of pre-implant check up to the present was to locate the implant site, to determine quantitatively and qualitatively the bone volume of implant place and to detect an anatomical obstacle. We only remind principles.

The quantitative evaluation of bone volume requires three measures and sizes:

- height to mandibular canal in mandibular level and to lower bone cortical of maxillary sinus or nasal cavity in maxillary level,

- width in vestibulo-lingual level,
- length in mesio-distal level.

Qualitative analysis of bone volume using:

- subjective specification : cortical thickness, alveolar bone density,
- objective specification: densitometry and different methods using Hounsfield unit measures, but at the present time no method is recognized (fig. 1).

The implant place has to be marked by axe and guide (fig. 2).

At last imaging has to look for anatomical obstacle restricting bone volume:

- in maxillary level: maxillary sinus or nasal cavity bottom, nasopalatine canal, dorsal palatal artery,
- in mandibular level: above all mandibular canal,
- included tooth, tumor, inflammatory or infectious lesion.

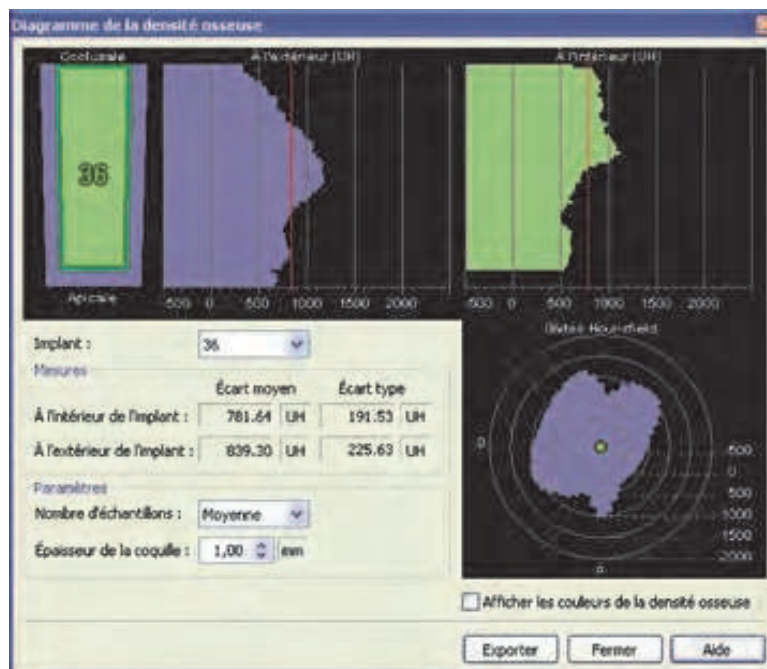


Fig. 1. Bone density around implant measurement according to Mirsch classification.

3. Help to surgery

Recent years much software for implant planification and navigation are developed. Meticulous protocol is needed to computered implant planning whichever software is choosen (Verstreken et al., 1996, 1998). The two principal softwares created for dental implant planification are called Simplant and Nobelguide, they are mainly designed for surgical act, and a work tool to show dental surgeon the way in implant installation called Robodent (Treil et al., 2009). These different examples should illustrate this topic.

3.1 Simplant

Study begins by making articulated models (Corcos, 2007). Then a wax setting simulates the final dental prosthesis and allows surgeon to visualize technical constraints. He visualizes imperatives implementation of implant prosthesis. Then the radiological guide derived from prosthetic model can be achieved (fig. 2). Either radio-opaque commercial false teeth are

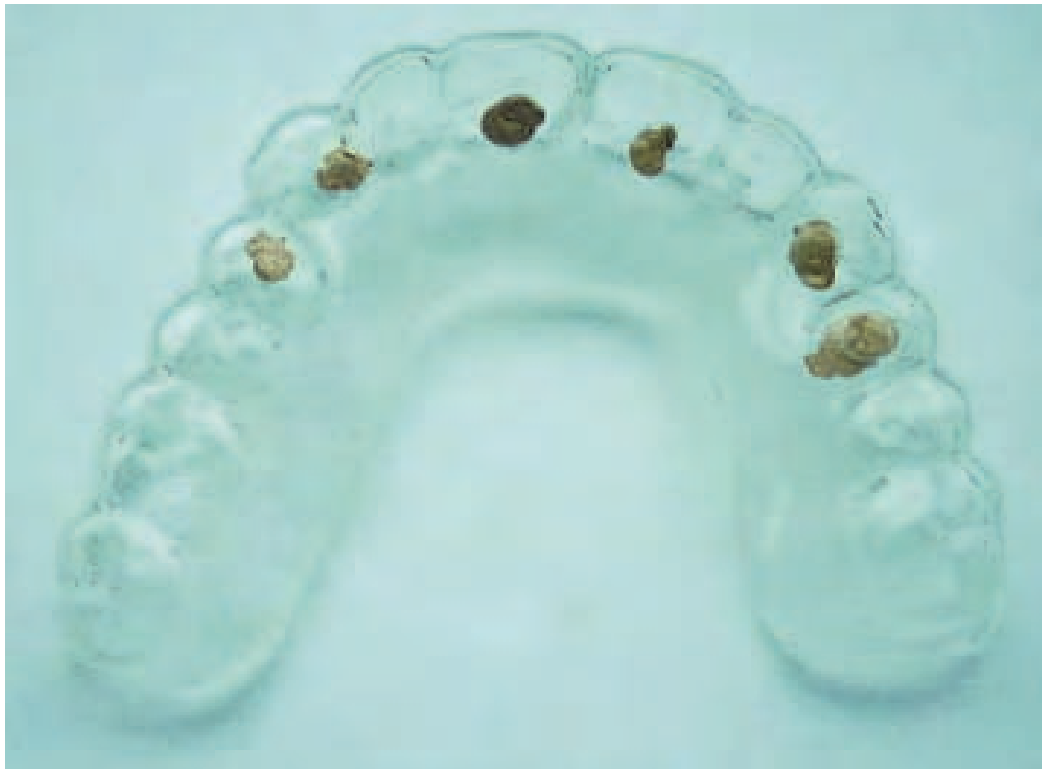

Fig. 2. Example of radiological guide with gutta percha radio-opaque spots.

inserted or baryum sulfate balls are included in wax (fig. 3 and 4). While different baryum sulfate concentrations are adjusted, we can precisely differentiate and individualize masks of different density. A cylindrical cavity focused on occlusal tooth's side and emerging from cervical side makes the main tooth axis visible (fig. 4).

3.1.1 CT scan

Patients wear the radiological guide during the CT scan acquisition. Dental arches must not be in contact together, in order to make the CT scan data processing easily. Radiologist has to take care of:

- stability and well-positioning radiological guide, with control of accommodation or adjustment with mucous membrane,
- determination of axial plane that is parallel to the teeth occlusal area,
- visibility of teeth occlusal area, that has to be full visible.

3.1.2 Implant planification

Several points have to be controlled by dentist:

- check CT scan accuracy,
- location of axial emergence on incisal side or occlusal face,
- put the implant on a lateral view,
- set up guide anchor cotters,
- check on implants parallelism, confirmed on 3D view (fig. 3 and 4),
- check bone fenestrations,
- check on bone density,
- place an order of surgical guide.

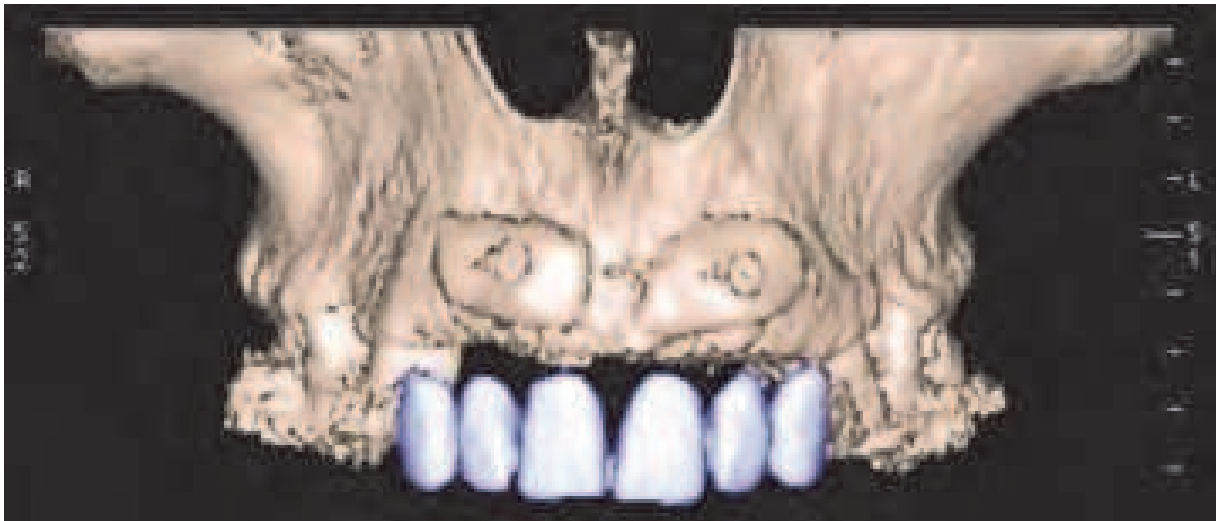

Fig. 3. Example of radiological guide with false teeth, on tridimensional reconstruction.

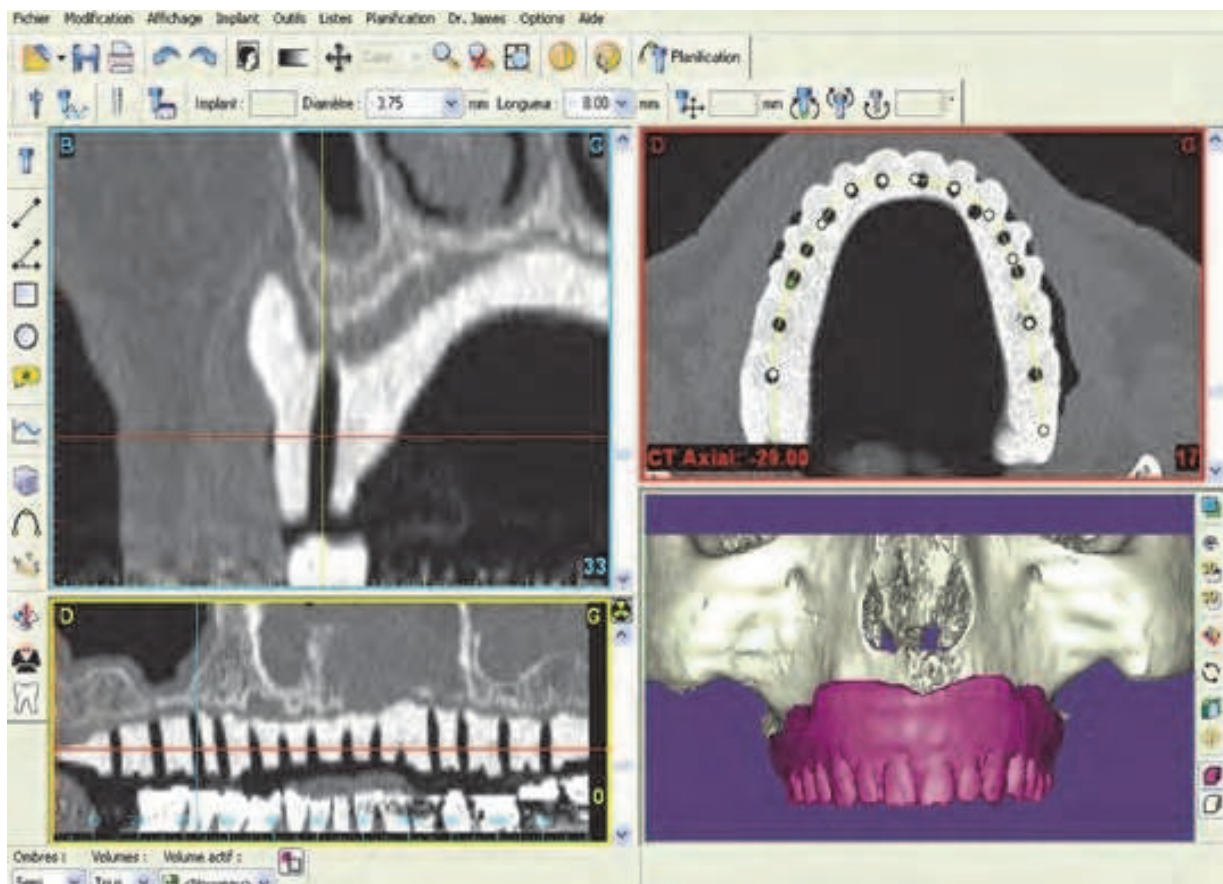


Fig. 4. Example of Simplant planification of upper jawbone.

3.1.3 Surgical time

Then after planification and dentist's control, time comes for surgical act.

The surgical guide is achieved by a stereo-lithographic system: a pure and initially clear wax hardens by laser action. This guide is aimed to laboratory technical expert, used to make a plaster model with implants duplication in order to fabricate temporary prosthesis.

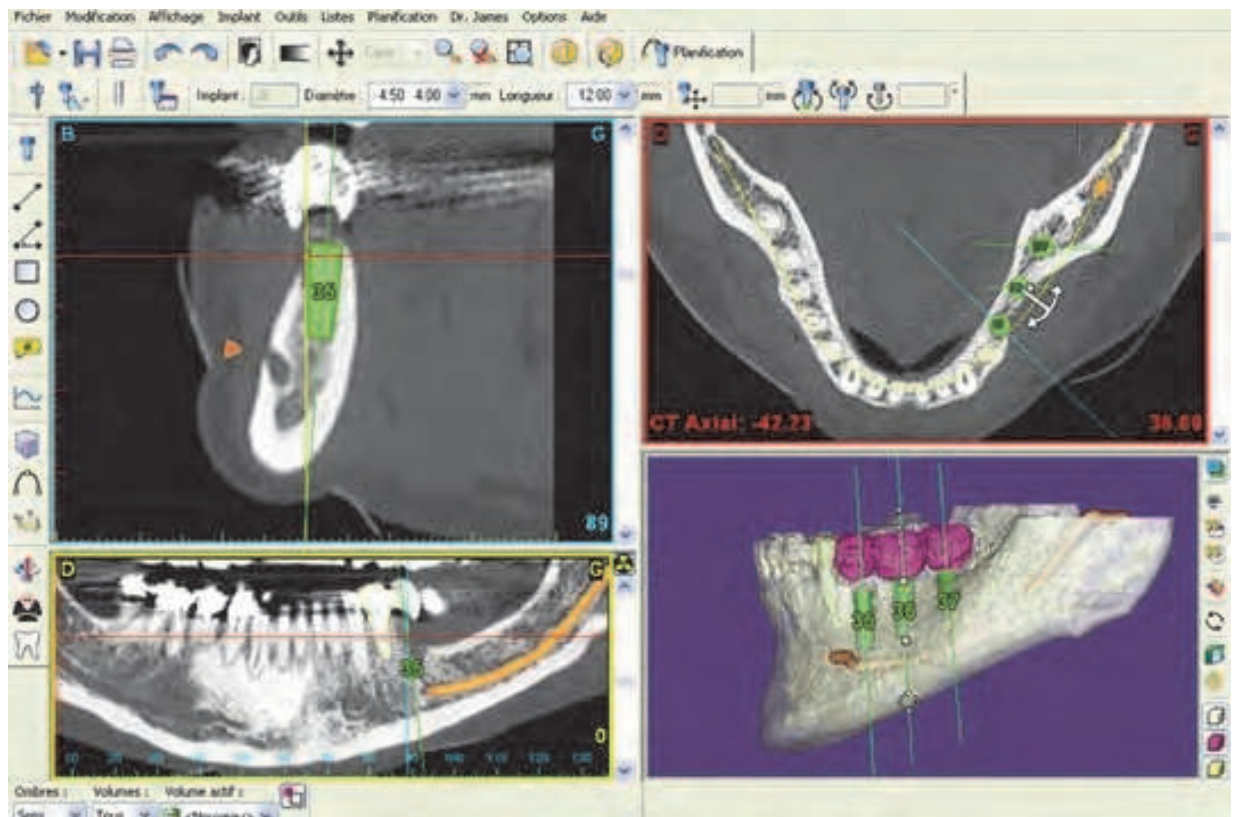


Fig. 5. Simplant planification. Implants simulation with implants parallelism.

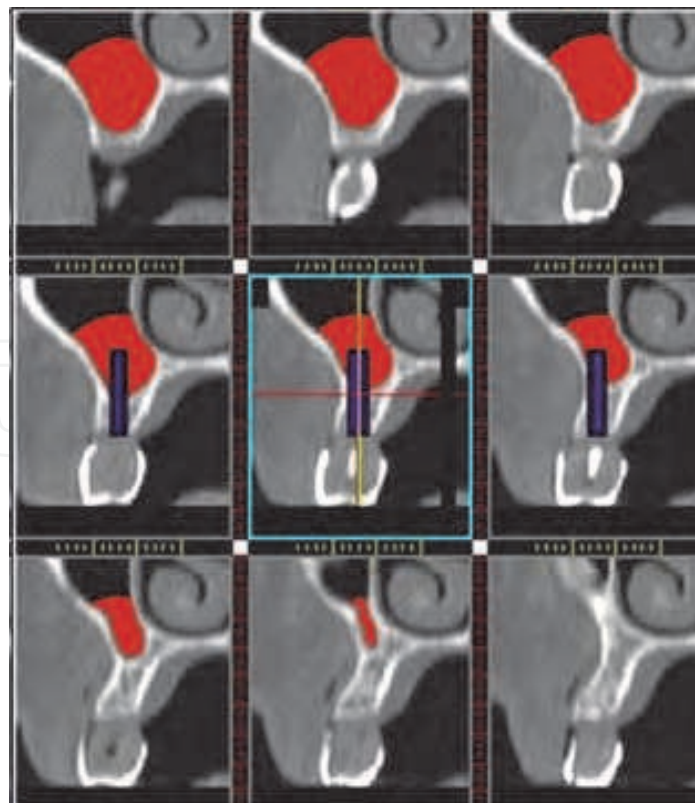


Fig. 6. Example of bone volume evaluation with implants simulation.

Simplant software allows surgeon to make a dental guide with bone or mucous support. That simplifies surgery, and enables surgery without incision reducing surgical length and post-operative complications.

Detailed precision with accuracy to within one millimeter is essential:

- maximal horizontal deviation to 0.6 mm,
- maximal vertical deviation to 0.9 mm,
- maximal angulation deviation to 6.1.

This technique allows immediate loading.

Simplant software enables dentist to mark anatomical pieces (fig. 5) and bone volume evaluation to "sinus lift" (fig. 6), choice among all existing implants, and choice of adjusted pillar.

3.2 Nobelguide

Nobelguide is the same concept as Simplant one, including five steps (Van Steenberghe et al., 2002, Vaida et al., 2007). This concept should be illustrated by an example, of this mandibule toothless man (fig. 7).

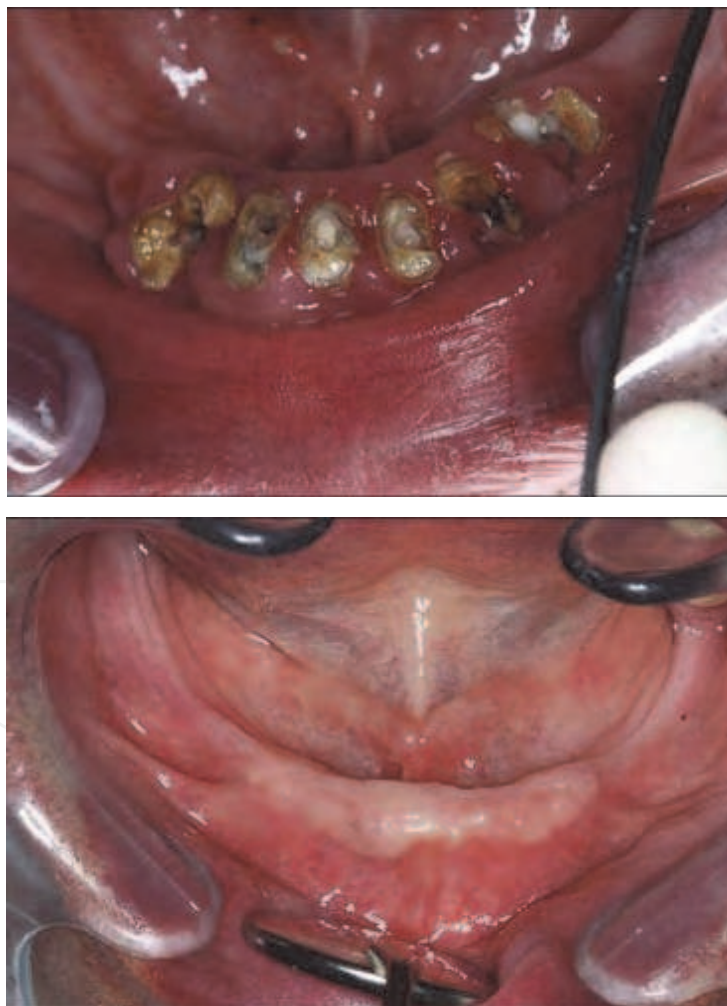

Fig. 7. Prosthesis plan NobelGuide in a toothless man mandibule

7-a: outstanding dental of tooth root

7-b: healing after dental extraction.

3.2.1 Temporary prosthesis

It is a very important step in planification, aesthetic assembly and occlusal plan are the same for the definitive prosthesis. Prosthesis efficient stability is very important and sought throughout the procedure. This temporary prosthesis is mostly used as radiological guide. It is most often made in radio-transparent acrylic resin with eight to twelve balls of radio-opaque small-diameter gutta percha (1.5 mm) (fig. 8 and 9). These balls are placed on vestibular and lingual side of prosthesis on different occlusal plans.

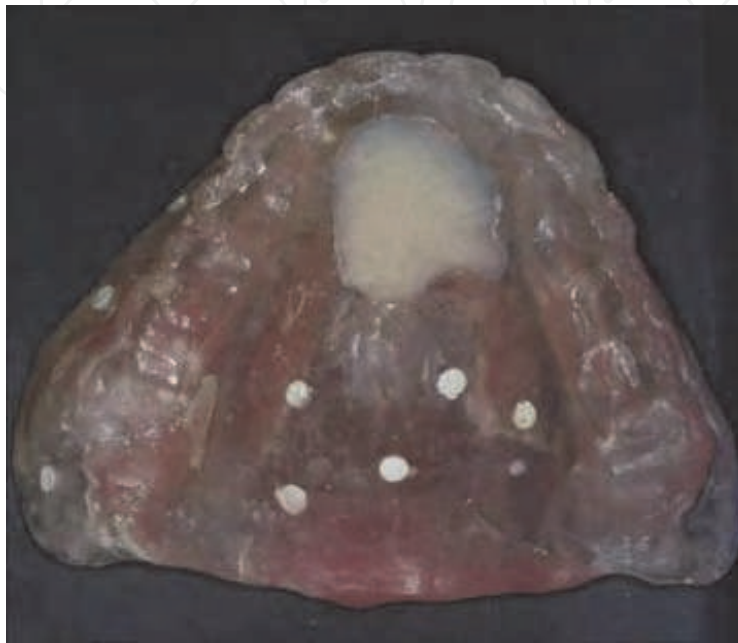

Fig. 8. Temporary prosthesis made in radio-transparent acrylic resin with radio-opaque gutta percha balls.

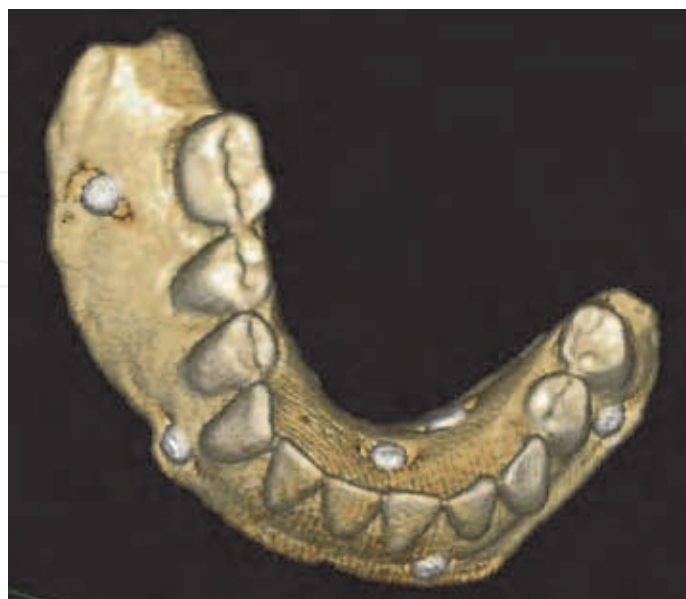

Fig. 9. Three dimensional CT scan reconstruction of temporary prosthesis with gutta percha balls.

3.2.2 Occlusal positioning index

Prosthesis should be well-positioned in mouth and above all stable. Its position compared to antagonist teeth is registered with a specific material for occlusal registration. This material must be rigid, radio-opaque or not (fig. 10) (for example polysiloxan vinyl).

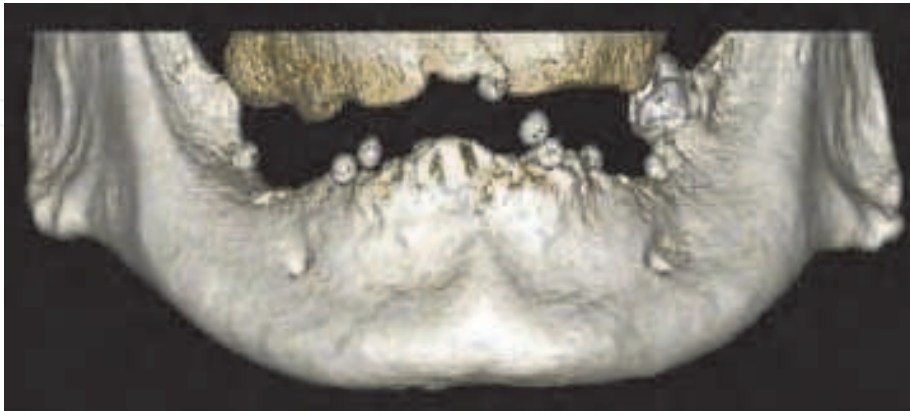


Fig. 10. Three dimensional reconstruction of radio-opaque positioning index between upper jawbone and temporary prosthesis.

3.2.3 CT scan

A double CT scan acquisition is needed to obtain a reliable account of bone on the one side and radiographic guide on the other side.

Gutta percha balls included on radiological guide are essential marks to merge accurately the two CT scans.

The first CT scan is acquired on patient bearing radiological guide stabilized and by occlusal index well-positioned. It brings to us important information about bone detail and gutta percha balls positioning through detailed data. The acquisition always follows parallelism of occlusal plan, covering lower or upper jawbone and part of antagonists teeth (fig. 11 and 12).

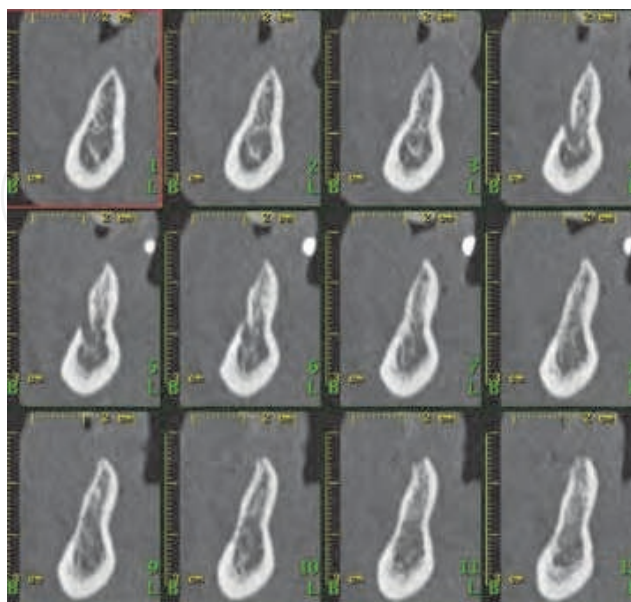

Fig. 11. Bone reconstruction as denta-scanner showing sharpened alveolar ridge.

Second CT scan is acquired with only radiologic guide, without occlusion. That gives very detailed informations about radiologic guide and gutta percha marks. This acquisition must be precisely realized in the same conditions as the previous one (fig. 9 and 13).

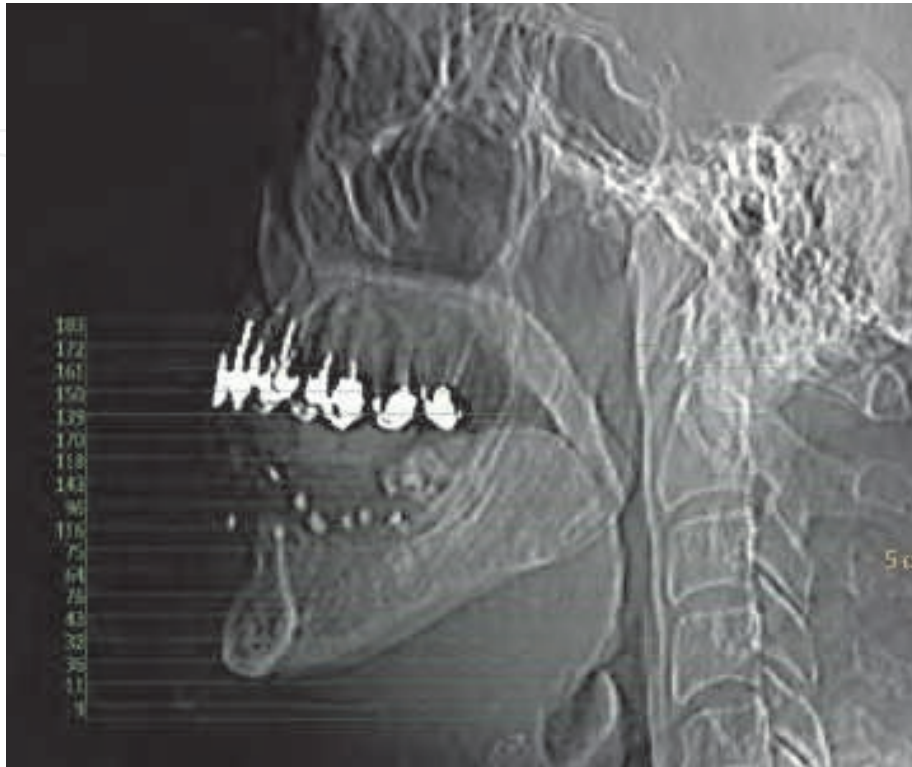


Fig. 12. Profil scout-view of the face and acquisition volume that is parallel to occlusal plan. Gutta percha balls are visible.

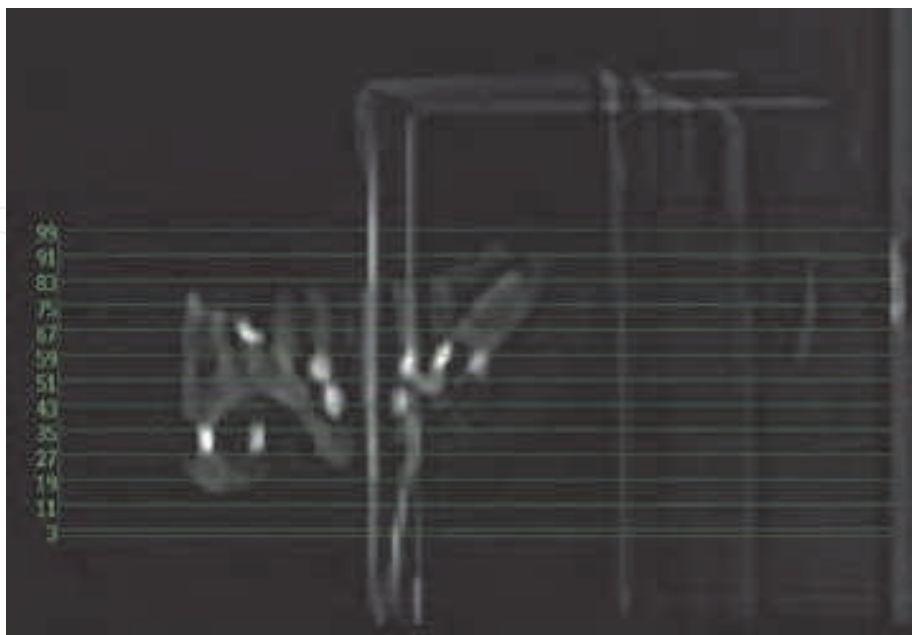


Fig. 13. Profil scout-view of temporary prosthesis in its stand. Same acquisition volume as patient CT scan.

3.2.4 Planification

Software enables practitioner to position radiologic guide on alveolar bone and as the same time to keep carefully a gap for mucous layer, and to position virtually dental implants (fig. 14 to 16).

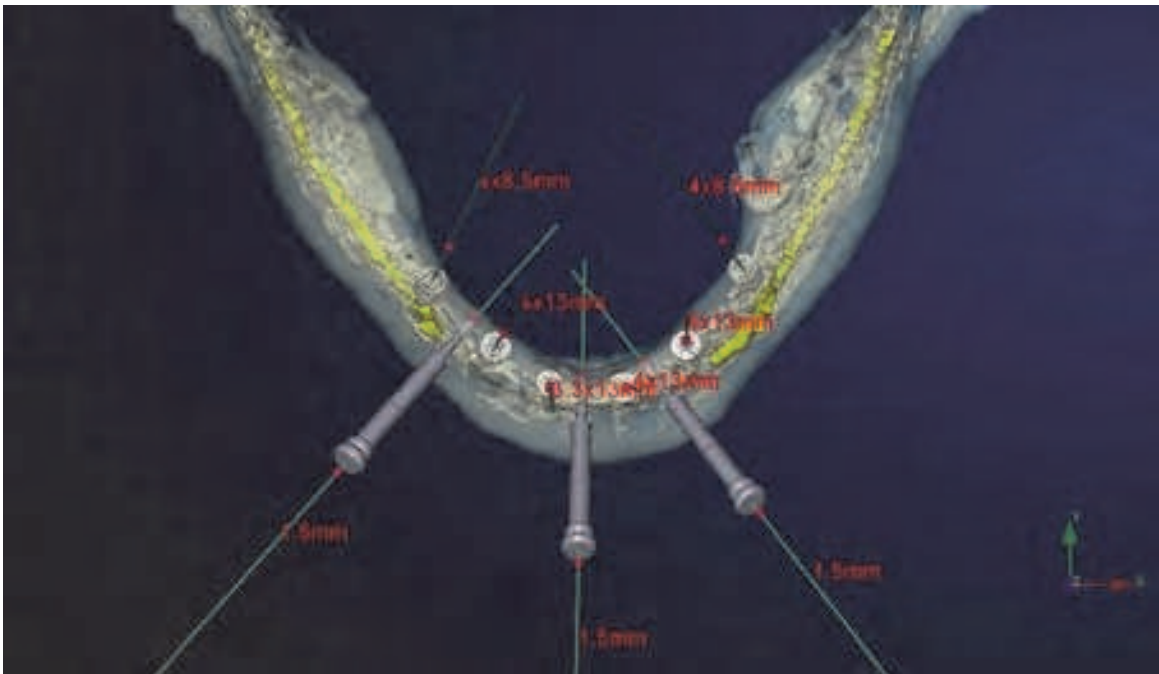


Fig. 14. 3D planification image of lower jawbone in axial incidence showing stabilization cotter and implants.

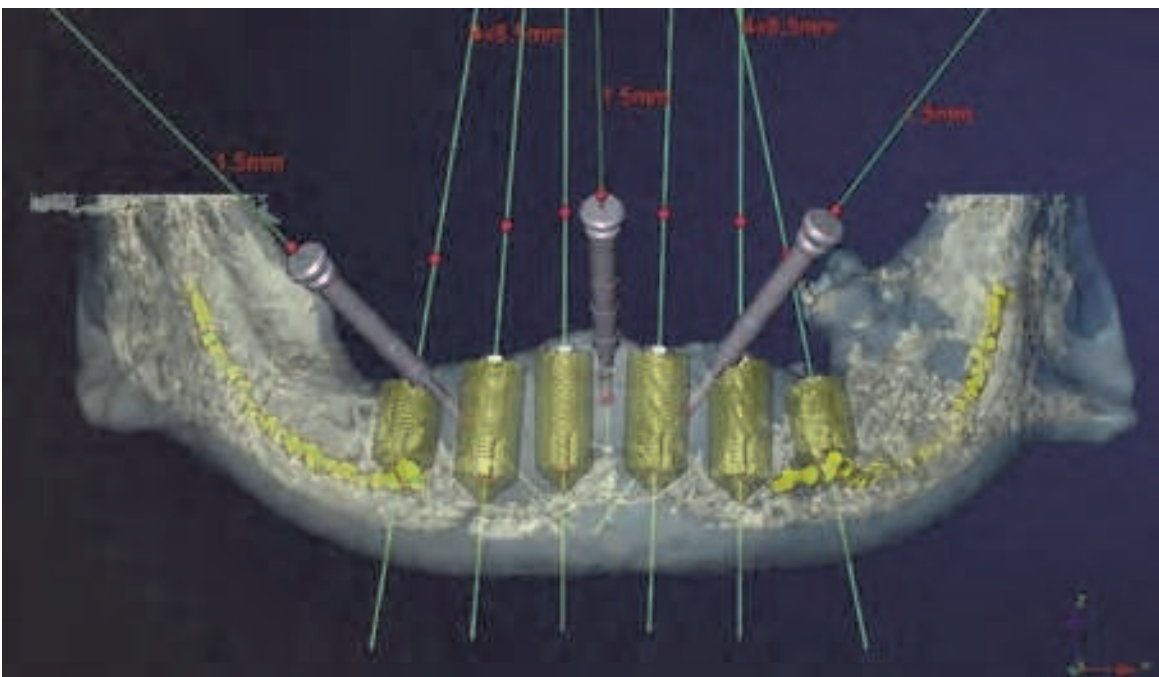


Fig. 15. 3D planification image of lower jawbone in frontal incidence showing stabilization cotter and implants.

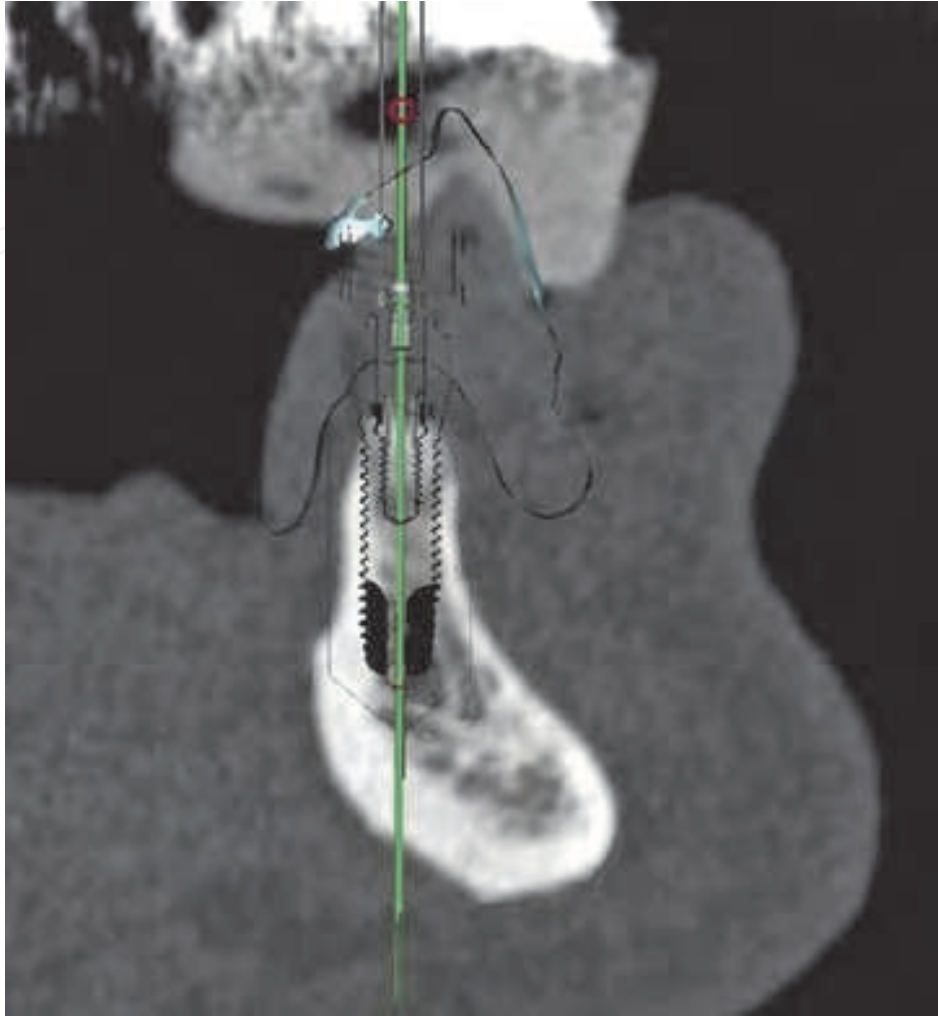


Fig. 16. Reconstruction as denta-scanner: positioning occlusal index, temporary prosthesis and mucous layer.

3.2.5 Surgical guide

Planification enables to manufacture surgical guide by scanner technique (fig. 17). It is radiological guide replica converted to allow drilling and setting up of implants. Surgical guide replaces toothprint for prosthesis laboratory, to cast the framework model.

Nobelguide concept helps to computerization of implants planification according to initial prosthetic project, to manufacturing of surgical guide and prosthesis before to put down implants. Surgical guide manufacturing should be provided at the same time as prosthesis conception. Guide conception and its stability guarantee a setting up corresponding to planification. Its initial stability when practitioner installs prosthesis in mouth depends on occlusion bite and cotter introduction in preoperative period (fig. 18 and 19). These cotters must go through surgical guide in vestibular region in wax extensions thick enough to avoid guide's wrist over drilling. Then these extensions must be apical enough so that cotters' shaft be horizontal, and to realize bone's insertion outside the anatomical hurdles.



Fig. 17. Occlusal view of surgical guide: drilling orifices, stabilization cutter and implants direction.

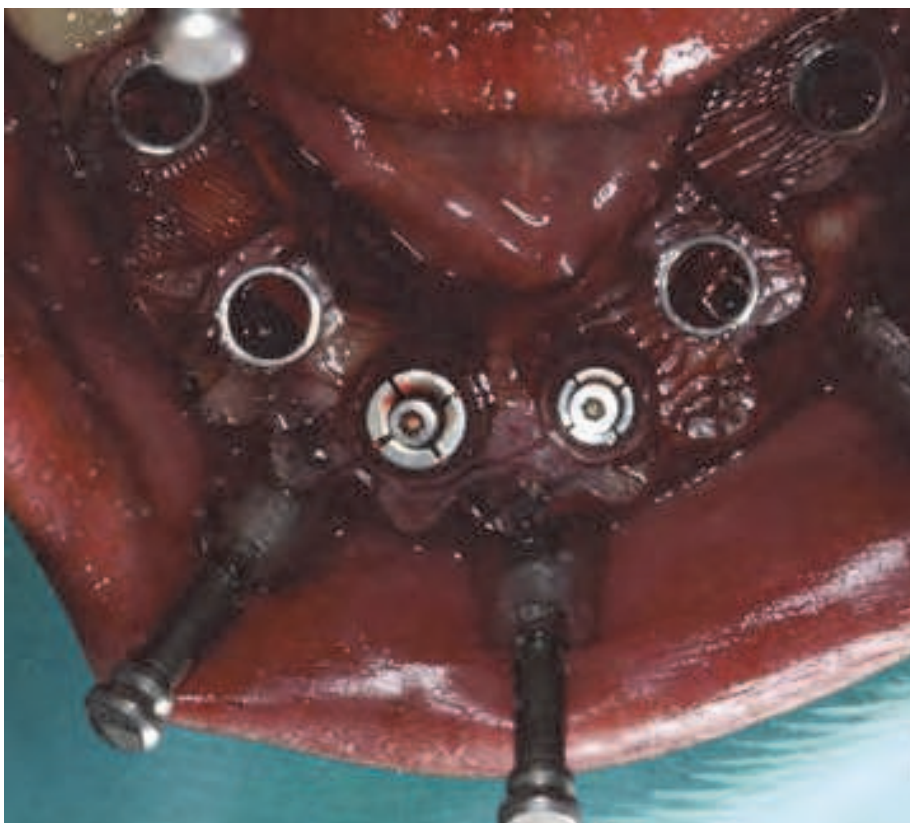


Fig. 18. Peroperative occlusal view with surgical guide and cutter, and firsts implants.

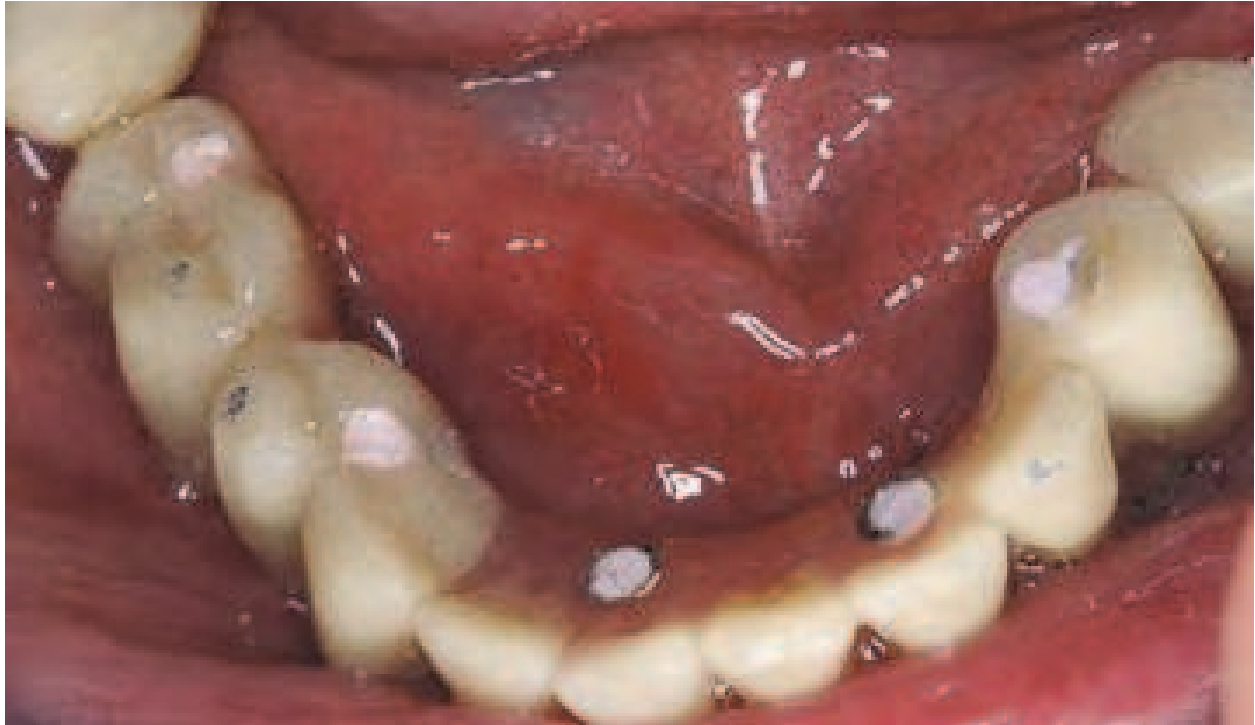

Fig. 19. Occlusal view at the end of surgical act, the prosthesis is putted down.

3.3 Robodent

Softwares such as Nobelguide or Simplant give way to undeniable surgical help, particularly for surgical step (Penel et al., 2007, Miller&Bier, 2006, Ewers, 2005, Casap, 2006). But it requires a rigorous procedure and laboratory time to transfer all the data of pre-implant check-up. New tools recently appear that leads surgeon's hand while implants installation, these tools are already used in neuro-surgery, maxilla-facial surgery and otorhinolaryngology. Softwares enable a real-time interface between pre-implant plan and rotating instrumentation for implant site.

In addition the surgical tool named Robodent is a navigational instrument. Surgeon can also follow the drills progress on line in comparison to contiguous anatomical structures.

It pilots the surgeon's hand while he drills the bone. Optical tracer is fixated on wax prosthesis, as well as on the drill. Then their motion is captured by a camera and worked out with three-way correlation. The more advanced systems use to optical tracers. Optical tracers, passive (ceramic balls) or active (LED) according to system (fig.20 a) secured with dental arch. Then their motion is captured by a camera and worked out with three-way correlation. It is a real-time tool to follow the drill in anatomical pieces (fig. 20 b).

Prosthetic analysis happens as usual. A diagnostic wax model is made for functional and aesthetic necessities. Radiological guide as a gutter, secured with facial arch contenting radiological marks is adapted to dental arch (fig. 21). This guide should serve as a support for location system in surgical navigation. The CT scan is acquired with this system on dental arch. A temporary removable prosthesis should be used for toothless jaw; it has to be secure and motionless meanwhile.

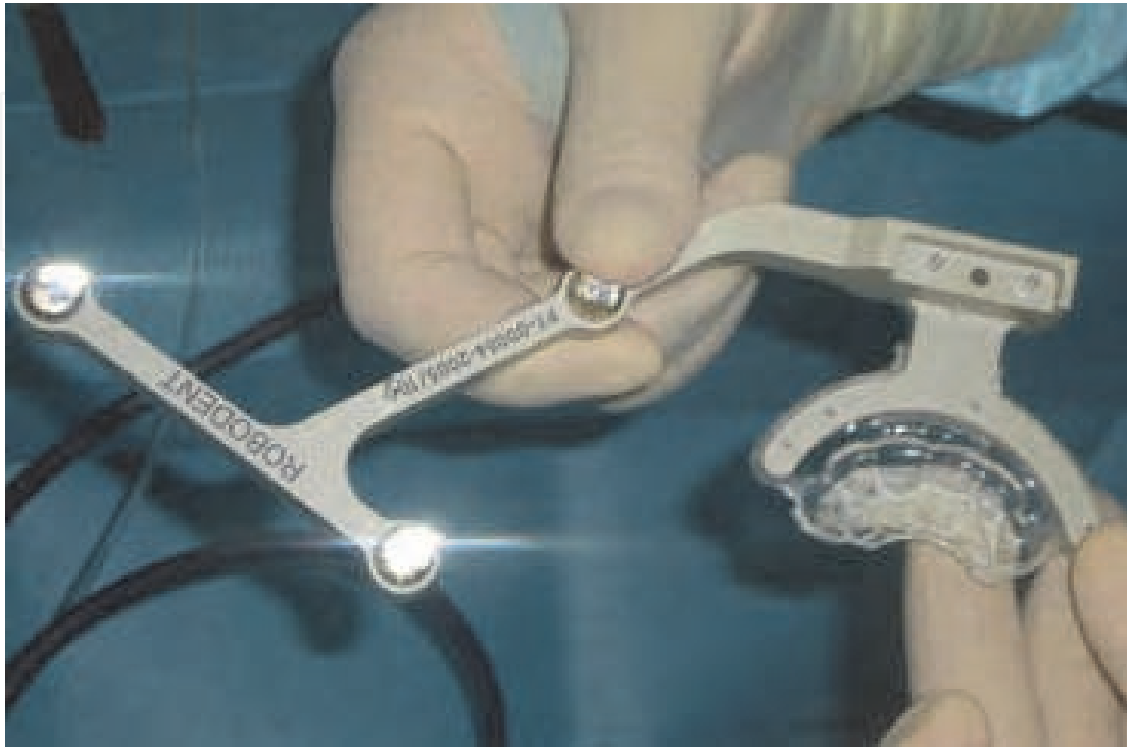

Fig. 20. a and b: Robodent: radiological guide and the extremity of drill present optical marks to give the spatial position.

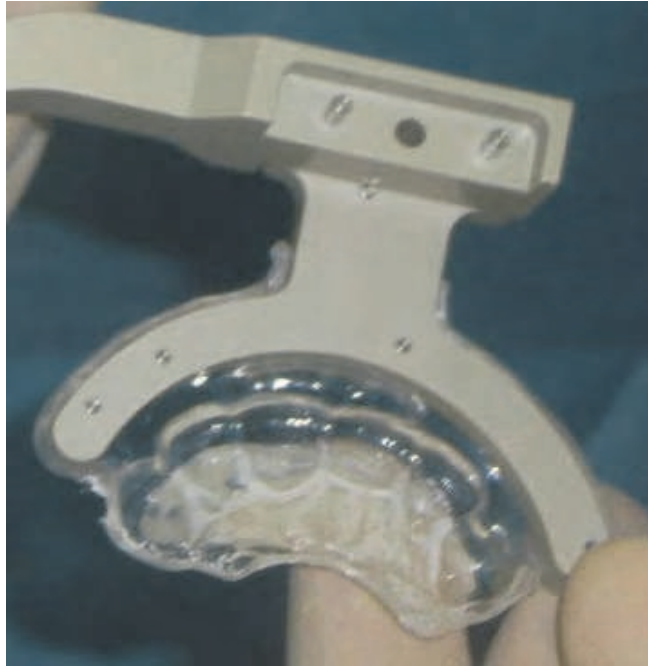

Fig. 21. Radiological guide secured with facial arch contenting radiological marks.

A CD is burned with CT images in DICOM format, given to dentist. He validates the choice of anatomic sites for implants with analyze and planification software (fig. 22).

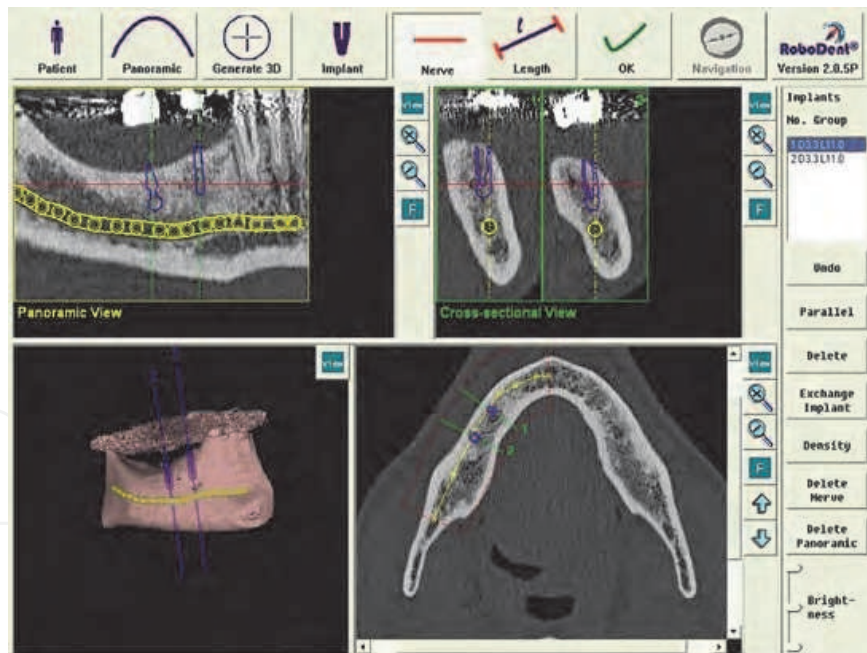


Fig. 22. Example of planification at upper jawbone level. 2D and 3D reconstructions as dentascanner. Implants simulations are made. Mandibular canal marked.

These accurate tools enable dentist to simulate whole implant plan. Two- or three-dimensional representations of implant make surgical plan easier. Furthermore this global approach enables patient to understand surgical act and to give enlightened consent. It represents a very good tool for communication with patient.

Surgical operation happens in a standard way, but surgical area and rotary instrumentation are adapted (fig. 23).

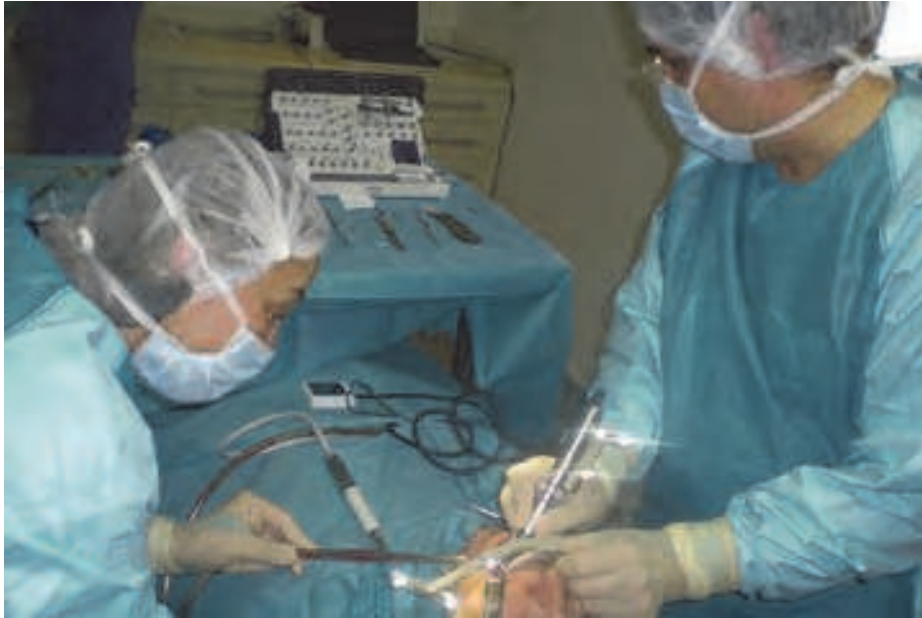

Fig. 23. The surgeon should adapt his surgical technique and controls the trajectory on the screen.

Patient's dental arch and drill carry marks, a camera check their spatial position in order to enable respective motion following. Computer calculates this position and transcribes drill coordinates in bone structures on the screen real time. Control device gives surgeons visual tracking with a sight and audible alarm (fig. 24). Sonorous alert gives constantly position control of shaft and drill depth. Accuracy and measures reliability are remarkable: 0.1 mm for linear deviation, 0.3° for angular deviation. However surgeon should acquire experience with guides' obstruction. He must also position himself to avoid crossing with optical follow-up.




Fig. 24. Control panel of point of impact and drill angulation, the drill is represented as a sight with audible alarm.

4. Conclusions

These technologies represent a real and very interesting progress.

As a conclusion, we can see that dental imaging has a major role in implant techniques, with noticeable precision and reliability in pre-implantal planification and surgical help.

If practitioner purely respects implant plan process, these technologies supply very accurate and repeatable data in user-friendly and intuitive environment. It gives security in surgical act by using positioning guides, also in drilling with drill-stop. It enables instant prosthesis' loading. Surgeon should focus on surgery accuracy and improve aesthetic and functional results. He should be able to increase aesthetic and functional results, broadening medical indications.

At present, these technologies are reserved to very experienced practitioners and surgeons and require a significant work to analyze each case and to prepare laboratory models.

At last, these systems bring competitive communication's tools for patient and prosthodontist. These tools are essential in diagnostic stage as well as surgical act. We see that dentists can manage all steps of the proceeding. What role can we assign to radiologist? What role can we assign to dentist? This problem is proper to every specialized medical field with imaging development. For radiologists, we stress upon the necessity of being attuned to these dental innovations.

5. References

- Abrahams JJ. (1990). Expanded applications of dentaScan (multiplanar computerized tomography of the mandible and maxilla). *Int J Periodontics Restorative Dent.*, Vol 10, No. 6, pp. 465-471, ISSN 0198-7569.
- Abrahams JJ. (1993). The role of diagnostic imaging in dental implantology. *Radiol Clin North Am*, Vol 31, No. 1 janvier 1993, pp.163-180, ISSN 0033-8389.
- Albrektsson T.& Johansson C. (2001) Osteoinduction, osteoconduction and osseointegration. *Eur Spine J.*, Vol. 10, No suppl 2 October 2001, pp. 96-101, ISSN 0940-6719.
- Bränemark PI. (1983). Osseointegration and its experimental background. *J Prosthet Dent.* Vol. 50, No 3 September 1983, pp. 399-410, ISSN 0022-3913.
- Casap N, Kreiner B., Wexler A.&Kohavi D. (2006). Flapless approach for removal of bone graft fixing screws and placement of dental implants using computerized navigation: a technique and case report. *Int J Oral Maxillofac Implants.*Vol. 21, No.3 (mars-avril 2006), pp.14-9. ISSN 0882-2786.
- Cavézian R, Iba-Zizen MT, Pasquet G&Cabanis EA. (1995). Computed tomography : 3D reconstructions and colour coded discrimination of dental groups. *Surg Radiol Anat.* Vol.17, No.1, pp. 77-78. ISSN 0930-1038.
- Cavézian R. (2006). Imagerie en implantologie, In *Imagerie dento-maxillaire*. Masson 3ème édition. pp. 295-322. Paris.
- Cavézian R.&Pasquet G. (2008). Imagery and orthodontics : trends, present and future. *Orthod Fr.* Vol.79, No.1 Mars 2008, pp. 3-12, ISSN 0078-6608.
- Chiarelli T., Lamma E.&Sansoni T. (2010). A fully 3D work context for oral implant planning and simulation. *Int J Comput Assist Radiol Surg.* Vol.5, No.1 Janvier 2010, pp.57-67.
- Corcos M. (2007). Imagerie et navigation chirurgicale. *Le fil dentaire.* Vol. 24, No 50 pp1.


- Ewers R, Schicho K, Undt G, Wanschitz F, Truppe M, Seeman R & Wagner A. (2005). Basic research and 12 years of clinical experience in computer-assisted navigation technology: a review. *Int J Oral Maxillofac Surg*. Vol 34, No.1 Janvier 2005, pp. 1-8, ISSN 0901-5027.
- Hauret L. & Hodez C. (2009). A new modality for dentomaxillofacial imaging : cone beam CT. *J Radiol*. Vol.90, No.5 Pt2, mai 2009, pp.604-617. ISSN 0221-0363.
- Hintze H., Wiese M. & Wenzel A. (2007). Cone beam CT and conventional tomography for the detection of morphological temporomandibular joint changes. *Dentomaxillofac Radiol*. Vol.36, No.4 Mai 2007, pp. 192-197. ISSN 0250-0832 X.
- Liu DG., Zhang WL., Zhang ZY., Wu YT. & Ma XC. (2006). Three-dimensional evaluations of supernumary teeth using cone-beam computed tomography for 487 cases. *Oral Surg Oral Med Oral Radiol Endoc*. Vol. 103, No.3 Mars 2006, pp.403-411. ISSN 1079-2104.
- Muppararu M. & Singer SR. (2004). Implant for the dentist. *J Can Dent Assoc*. Vol. 70, No.1, Janvier 2004, pp.32. ISSN 0709-8936.
- Miller RJ. & Bier J. (2006). Surgical navigation in oral implantology. *Implant Dent*. Vol. 15, No.1 (Mars 2006), pp. 41-47. ISSN 1056-6163.
- Pasquet G. & Cavézian R. (2009). Diagnostic means using oral and maxillofacial cone beam computed tomography: results. *J Radiol*. Vol. 90, No 5 Mai 2009, pp.618-623. ISSN 0221-0363.
- Patel S., Dawood A., Ford TP & Whaites E. (2007). The potential applications of cone beam computed tomography in the management of endodontic problems. *Int Endod J*. Vol. 40, No.10 Octobre 2007, pp. 818-830. ISSN 0143-2885.
- Penel G. (2007). Navigation chirurgicale assistée par ordinateur. *L'information dentaire*. Vol.29, pp. 1683-1685. ISSN 0020-0018.
- Rouas P. Bandon D., Nancy J., Delbos Y., Hauret L. & Bar D. (2006). La tomographie volumétrique numérisée par le système NewTom : intérêt de ce nouvel examen d'imagerie médicale chez l'enfant. *Arch Pediatr*. Vol. 13, No.8 Août 2006, pp. 1169-1177. ISSN 0929-693X.
- Rouas P. Nancy J. & Bar D. (2007). Identification of double mandibular canals : literature review and three case reports with CT scans and cone beam CT. *Dentomaxillofac Radiol*. Vol 36, No.1 Janvier 2007, pp. 34-38. ISSN 0250-0832X.
- Treil J., Braga J. & Aït Ameer A. Modélisation 3D du viscéro-crâne. Applications en orthodontie et chirurgie orthognatique. *Journal de Radiologie*, Vol. 90, No 5, Mai 2009, pp.634-641, ISSN 0221-0363
- Vaida C. (2007). Guide chirurgical et chirurgie robotisée le concept Nobel Guide. *L'information dentaire*. Vol.19, pp. 1073-1077. ISSN 0020-0018.
- Van Steenberghe D., Naert I., Andersson M., Brajnovic I., Van Cleynenbreugel J. & Suetens P. (2002). A custom template and definitive prosthesis allowing immediate implant loading in the maxilla: a clinical report. *Int J Oral Maxillofac Implants*. Vol. 17, No.5 Septembre-Octobre 2002, pp. 663-670. ISSN 0882-2786.
- Verstreken K., Van Cleynenbreugel J., Marchal G., Naert I., Suetens P. & Van Steenberghe D. (1996). Computer assisted planning of Oral implant surgery: A three Dimensional

approach. *Int J Oral Maxillofac Implants*. Vol. 11, No.6 Novembre-Décembre 1996, pp. 806-810. ISSN 0882-2786.

Verstreken K., Van Cleynenbreugel J., Martens K., Marchal G., Van Steenberghe D., Suetens P. (1998). An image-guided planning system for endosseous oral implants. *IEEE Transactions on medical imaging*. Vol. 17, No.5 Octobre 1998, pp. 842-852. ISSN 0278-0062.

IntechOpen

IntechOpen



Implant Dentistry - A Rapidly Evolving Practice

Edited by Prof. Ilser Turkyilmaz

ISBN 978-953-307-658-4

Hard cover, 544 pages

Publisher InTech

Published online 29, August, 2011

Published in print edition August, 2011

Implant dentistry has come a long way since Dr. Branemark introduced the osseointegration concept with endosseous implants. The use of dental implants has increased exponentially in the last three decades. As implant treatment became more predictable, the benefits of therapy became evident. The demand for dental implants has fueled a rapid expansion of the market. Presently, general dentists and a variety of specialists offer implants as a solution to partial and complete edentulism. Implant dentistry continues to evolve and expand with the development of new surgical and prosthodontic techniques. The aim of *Implant Dentistry - A Rapidly Evolving Practice*, is to provide a contemporary clinic resource for dentists who want to replace missing teeth with dental implants. It is a text that relates one chapter to every other chapter and integrates common threads among science, clinical experience and future concepts. This book consists of 23 chapters divided into five sections. We believe that, *Implant Dentistry: A Rapidly Evolving Practice*, will be a valuable source for dental students, post-graduate residents, general dentists and specialists who want to know more about dental implants.

How to reference

In order to correctly reference this scholarly work, feel free to copy and paste the following:

Marion Lahutte-Auboin, Amir Ait-Ameur, Virgine Decat and Laurent Hauret (2011). Dental Implant Imaging: How CT Scan Became a Help to Surgery, *Implant Dentistry - A Rapidly Evolving Practice*, Prof. Ilser Turkyilmaz (Ed.), ISBN: 978-953-307-658-4, InTech, Available from: <http://www.intechopen.com/books/implant-dentistry-a-rapidly-evolving-practice/dental-implant-imaging-how-ct-scan-became-a-help-to-surgery>

INTECH
open science | open minds

InTech Europe

University Campus STeP Ri
Slavka Krautzeka 83/A
51000 Rijeka, Croatia
Phone: +385 (51) 770 447
Fax: +385 (51) 686 166
www.intechopen.com

InTech China

Unit 405, Office Block, Hotel Equatorial Shanghai
No.65, Yan An Road (West), Shanghai, 200040, China
中国上海市延安西路65号上海国际贵都大饭店办公楼405单元
Phone: +86-21-62489820
Fax: +86-21-62489821

© 2011 The Author(s). Licensee IntechOpen. This chapter is distributed under the terms of the [Creative Commons Attribution-NonCommercial-ShareAlike-3.0 License](#), which permits use, distribution and reproduction for non-commercial purposes, provided the original is properly cited and derivative works building on this content are distributed under the same license.

IntechOpen

IntechOpen