

# We are IntechOpen, the world's leading publisher of Open Access books Built by scientists, for scientists

**4,800**

Open access books available

**122,000**

International authors and editors

**135M**

Downloads

Our authors are among the

**154**

Countries delivered to

**TOP 1%**

most cited scientists

**12.2%**

Contributors from top 500 universities



**WEB OF SCIENCE™**

Selection of our books indexed in the Book Citation Index  
in Web of Science™ Core Collection (BKCI)

Interested in publishing with us?  
Contact [book.department@intechopen.com](mailto:book.department@intechopen.com)

Numbers displayed above are based on latest data collected.

For more information visit [www.intechopen.com](http://www.intechopen.com)



## Two-Port Access Staging Laparoscopy for Gynecologic Cancers

Jiheum Paek<sup>1</sup> and Sang Wun Kim<sup>2</sup>

<sup>1</sup>Department of Obstetrics and Gynecology, Ajou University School of Medicine, Suwon,

<sup>2</sup>Division of Gynecologic Oncology, Department of Obstetrics and Gynecology, Yonsei University College of Medicine, Seoul, Korea

### 1. Introduction

In gynecologic cancer surgery, objectives of the surgery include optimal debulking, proper surgical staging, direct exploration by operators, and less operative morbidity (1). Comprehensive operation determines surgical stage and is important in guiding adjuvant chemotherapy. Due to these specific characteristics of gynecologic cancer operation, just surgical approaches by laparotomy have been performed for treatment of gynecologic cancers regardless of stage and kind of cancers merely until a few years ago. However, with improvements in surgical expertise with optimal instrumentation, the interests of minimally invasive surgery have increased. As a result, laparoscopic operations have become a commonly utilized approach instead of laparotomy in the gynecologic field. Recently, many surgeons have tried to reduce the number and size of ports in laparoscopic surgery for reducing morbidity and better cosmetic outcome. Compared with conventional laparoscopy, single-port access (SPA) surgery or laparoendoscopic single-site surgery (LESS) is expected to offer reduced postoperative pain (2) and better cosmetic results and, because it involves fewer trocars, may help avoid operative complications related to trocar insertion. Despite these advantages, SPA surgery has systemic limitations, including a crush between instruments or between instruments and endoscope, a limited amount of instruments, and the limited mobility of straight laparoscopic instruments because surgical instruments work through only one port. These technical problems cause lower accuracy of the operation compared to conventional laparoscopy and longer operation time. Consequently, there was few report of minimally invasive approach for a gynecologic cancer. Recently, although minimally invasive surgeries for gynecologic cancers have been attempted, it is still difficult to perform these surgical approaches widely due to the technical difficulties, despite the development of optimal instruments.

Based on these considerations, we tried to perform appropriate staging operation with minimal skin incisions using two-port access (TPA) system. The ultimate goal of the TPA system was to perform a proper cancer operation with less invasive access and to complement the technical limitations of SPA surgery.

## 2. Surgical techniques

The authors have reported a pilot study of 12 patients underwent TPA staging laparoscopy (1). This system consisted of a single multi-channel port system at the umbilicus and an ancillary 5-mm trocar in the suprapubic area (Fig. 1).

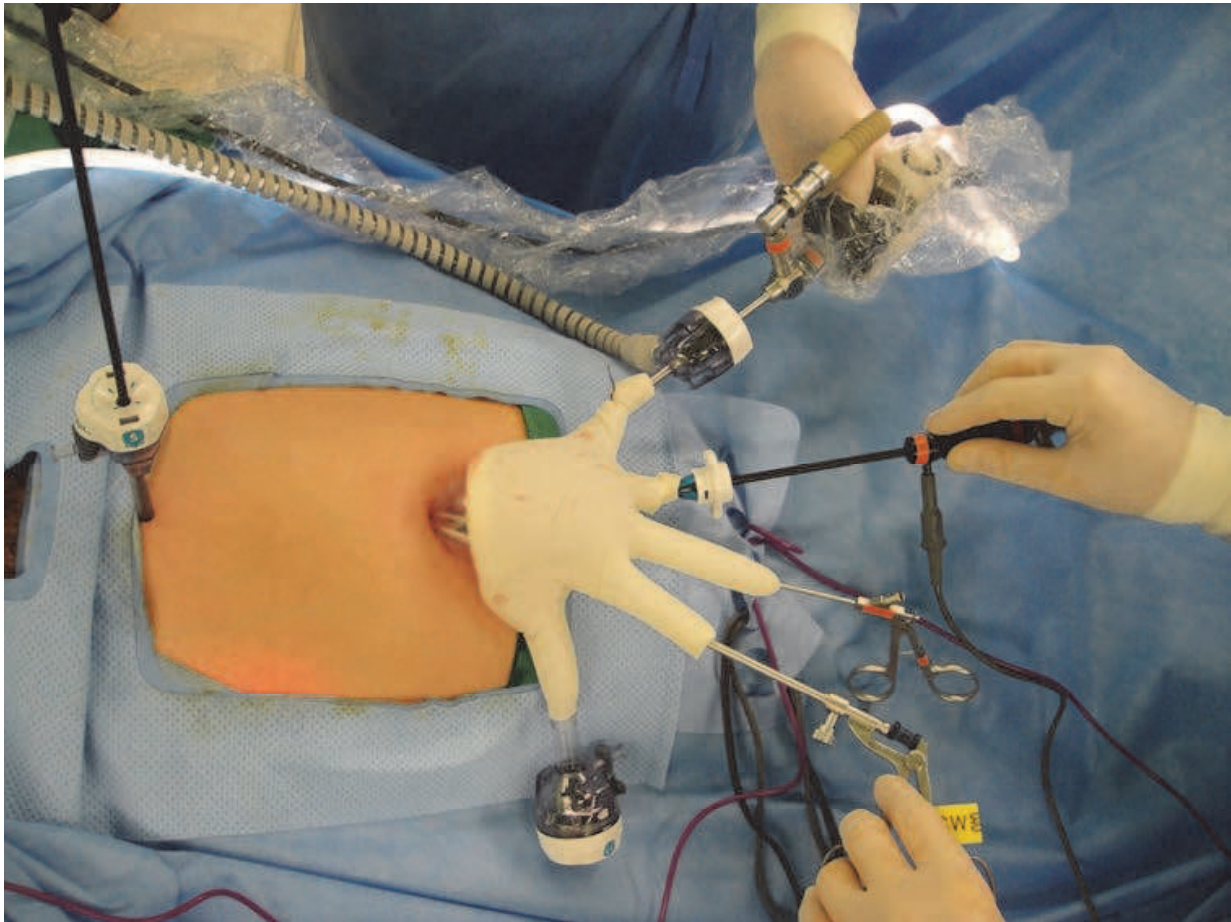


Fig. 1. Two-port system consists of a single multi-channel port system at the umbilicus and an ancillary 5-mm trocar in the suprapubic area.

TPA staging laparoscopy was performed for various gynecologic cancers from May 2009 in our institute. The inclusion criteria were patients who had newly diagnosed untreated gynecologic cancers and needed lymph node dissection for surgical staging and treatment. Procedures included endometrial cancer staging, ovarian cancer staging, and radical hysterectomy. All patients underwent pelvic lymph node dissection (PLD) and paraaortic lymph node dissection (PALD). In most of them, upper PALD extended to the renal vein level was performed. For a single multi-channel port system, after making a 1.5-cm vertical intra-umbilical skin incision, the Alexis® wound retractor (Applied Medical, CA, USA) is inserted into the peritoneal cavity through the umbilicus. A 7½ surgical glove is fixed to the outer ring of the wound retractor. After making small incisions in the finger tip portions of the glove, two 5-mm trocars and one 11-mm trocar are inserted. Another 5-mm trocar in the suprapubic area is used as the assistant port for the procedures and ventilating CO<sub>2</sub> gas. A rigid 30-degree, 5-mm, 45 cm length endoscope is used. Surgical instruments used are bipolar forceps, monopolar scissors, atraumatic

forceps, toothed grasper, laparoscopic needle holder, a suction-irrigation system, Harmonic Ace™ (Ethicon Endo-surgery, Ohio, USA) and the LigaSure Atlas™ (Covidien, CO, USA). A RUMI uterine manipulator is placed with a KOH colpotomizer system (Cooper Surgical, CT, USA).

For the pelvic lymph node dissection, the retroperitoneal space is developed by incising peritoneum lateral to the infundibulopelvic ligament from the pelvic brim to the round ligament using a monopolar hook. The paravesical and pararectal spaces are identified. After the pelvic vessels and bilateral ureters are identified, pelvic lymph nodes are isolated and removed by incising tissue that is lateral and parallel to the external iliac artery extending from the bifurcation of the common iliac artery to the point where the deep circumflex iliac vein crossed over the external iliac artery. Then, lymphatic tissues in the obturator fossa and on the internal iliac vessels are dissected (Fig. 2).

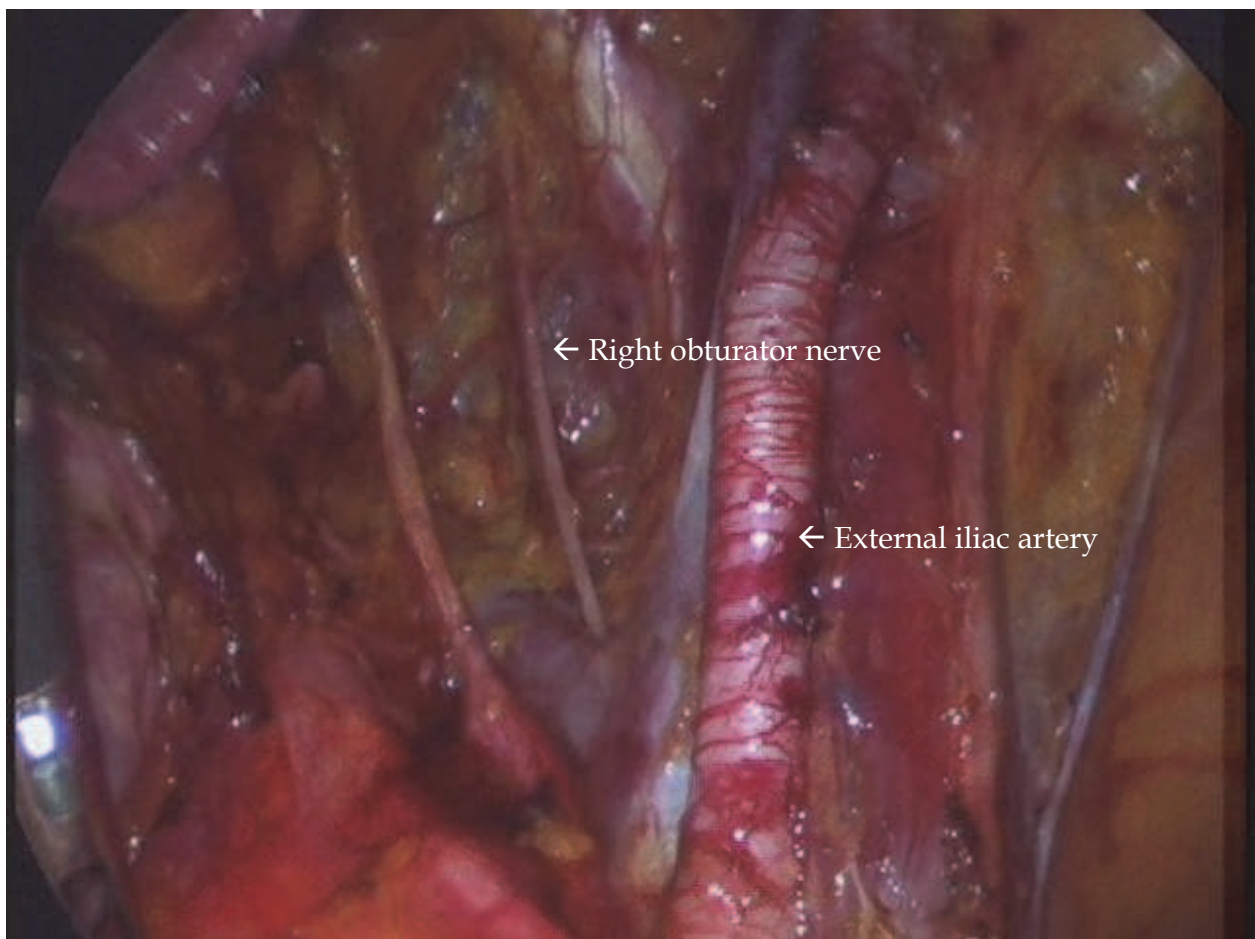


Fig. 2. Two-port laparoscopic staging; intraoperative view of right pelvic lymphadenectomy.

For the radical hysterectomy, the uterine vessels are dissected at their origins from the internal iliac vessels. The vesicocervical space is developed inferiorly and laterally. The medial edge of the divided uterine vessels is then pulled medially, and the ureter is completely freed from the retroperitoneal bed to the entry into the bladder by a complete dissection of the vesicouterine ligament (Fig.3). The cardinal ligament is transected at the medial wall of the internal iliac vessels. The anterior parametrium is transected near the bladder wall and the posterior parametrium including the uterosacral ligament is divided

midway from its origin of the uterus to the sacrum until the bulge from the colpotomizer second lower ring in the vagina was reached. After completely detaching the uterus from the vagina, the uterus is extracted through the vagina. Pneumoperitoneum is maintained with a surgical glove filled with normal saline. A 40-mm round-bodied needle is introduced through the 11-mm port and we perform the closure of vaginal cuff intracorporeally with a 1-0 Vicryl continuous running suture.

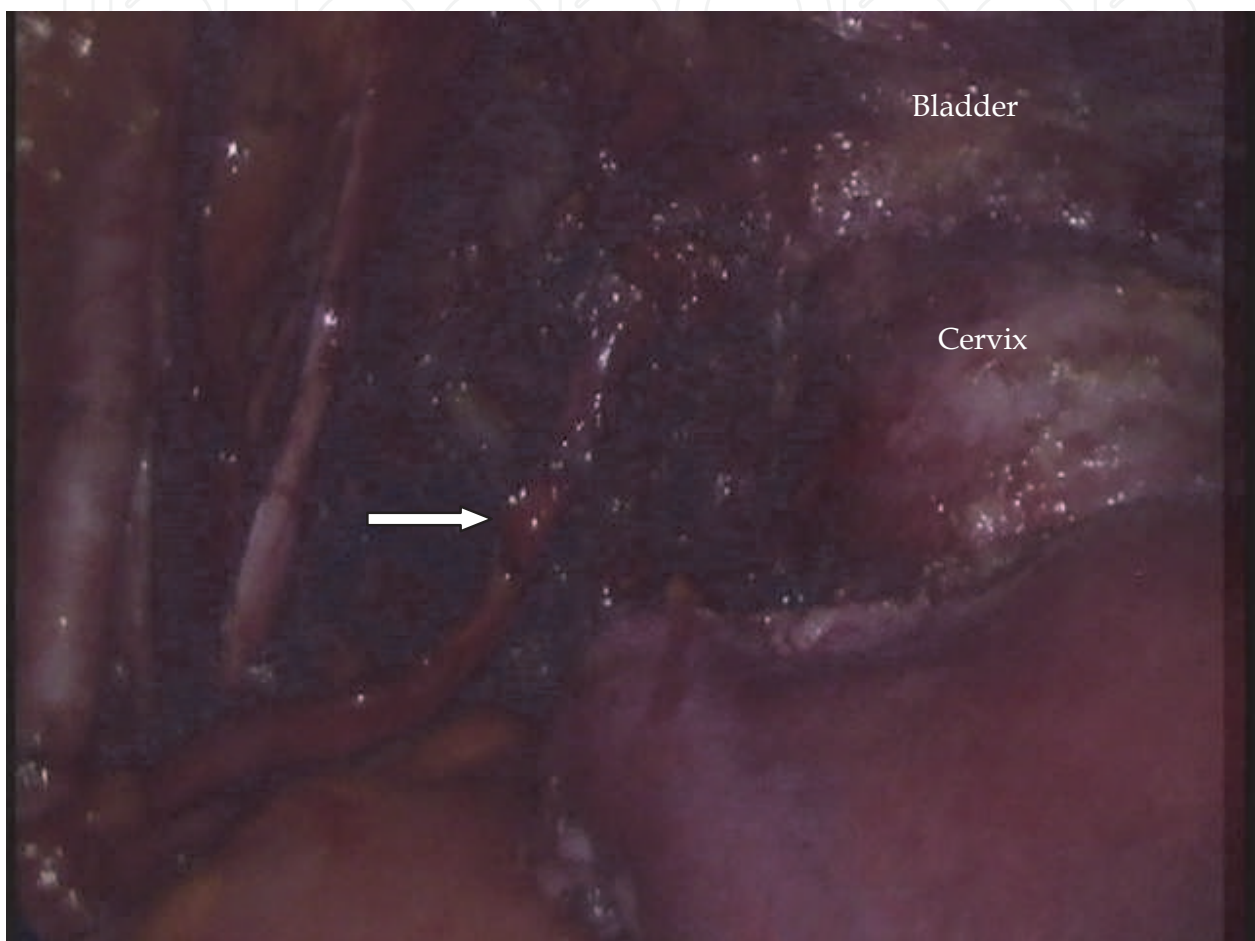


Fig. 3. Two-port laparoscopic radical hysterectomy; the left ureter (arrow) is completely freed from the retroperitoneal bed to the entry into the bladder.

Para-aortic lymph node dissection is performed using a monopolar hook and a Harmonic Ace™. The peritoneal incision extends from the aortic bifurcation up to the transverse duodenum. After the inferior mesenteric artery and bilateral ureters are isolated, lymphatic tissues on the para-aortic, paracaval and presacral space are carefully dissected (Fig. 4, 5). For Infracolic omentectomy in ovarian cancer, the infracolic omentum is divided along its superior border just adjacent to the transverse colon using Harmonic Ace™. The resected omentum is extracted through the vagina with the uterus after the hysterectomy. The drainage bag is connected through the 5-mm port in the suprapubic area. After hemostasis, the single multi-channel port and ancillary port are removed and the umbilical fascia and subcutaneous tissue is approximated with 2-0 Vicryl sutures.

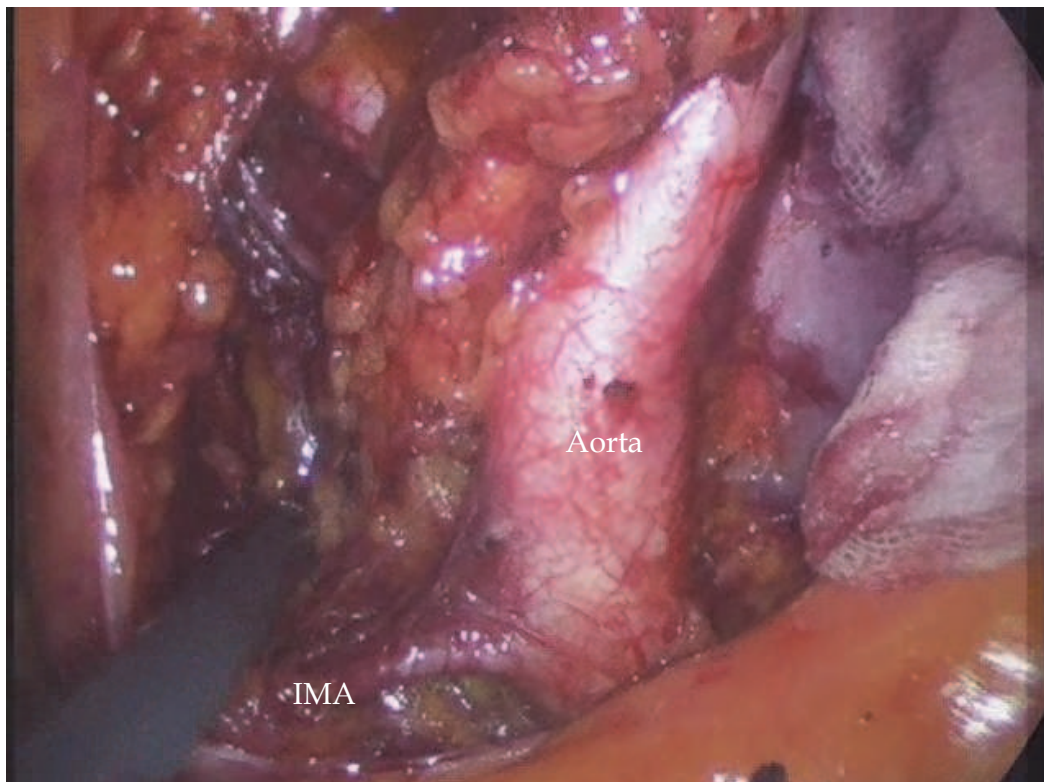


Fig. 4. Two-port laparoscopic staging; intraoperative view of left lower paraaortic lymphadenectomy.

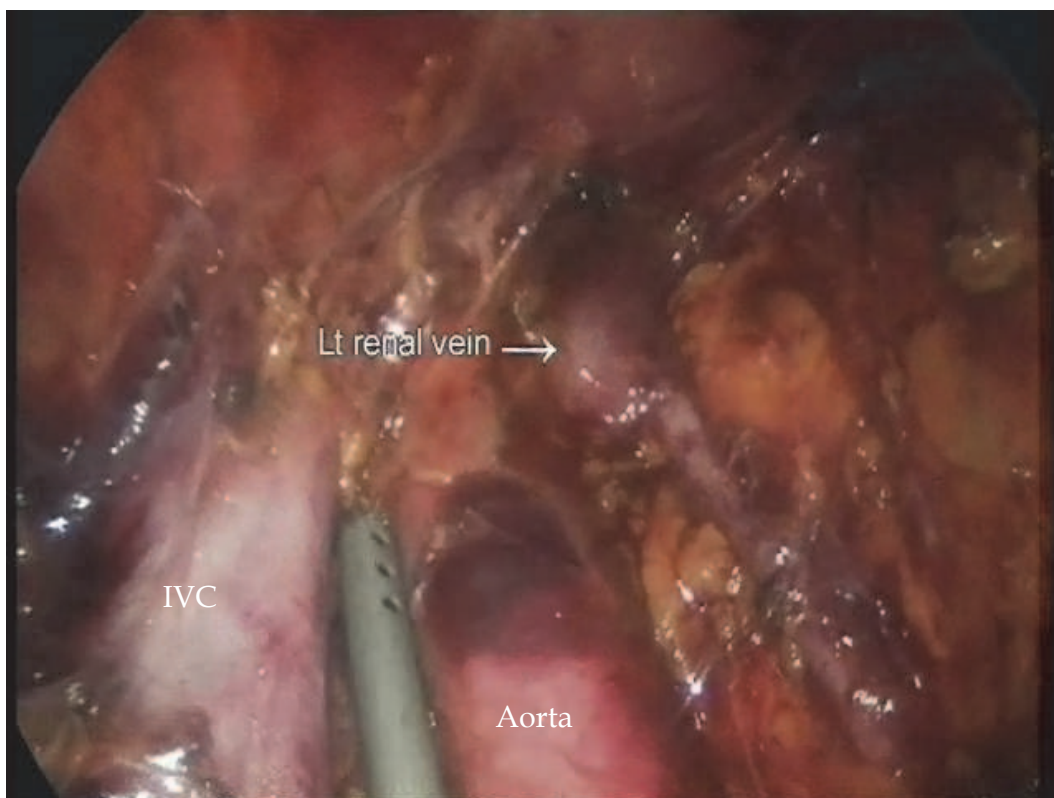


Fig. 5. Two-port laparoscopic staging; intraoperative view of upper paraaortic lymphadenectomy.

### 3. Surgical outcomes

To date, more than 60 patients underwent TPA staging laparoscopy. Of these, we performed type III radical hysterectomy in 14 patients and type II (modified) radical hysterectomy for 3 patients. All operations were completed laparoscopically with no conversion to laparotomy. The mean patient age and body mass index were 49.3 (standard deviation, 13.0) years and 23.0 (SD, 3.5) kg/m<sup>2</sup>, respectively. The mean operating time was 251.8 (SD, 69.1) minutes. The mean estimated blood loss was 144.9 (SD, 13.5) mL. The median number of lymph nodes obtained was 36 (SD, 13.5). The mean postoperative pain scores using a validated visual analogue pain scale after 6, 24, and 48 hours were 3.3, 3.1, and 2.7, respectively. The mean postoperative hospital stay was 6.4 (SD, 2.6) days. There were no intraoperative complications requiring further management.

### 4. Discussion

For benign gynecologic diseases, minimally invasive surgeries have already been considered as a popular approach, including SPA or LESS. This surgical trend does not occur in surgeries for only benign disease. In 2009, Fader and Escobar presented the first 13 cases of LESS for the treatment of various gynecologic oncology conditions (3). Since then, they showed that single-port risk-reducing salpingo-oophorectomy and staging operations were feasible in patients with cancerous conditions (4, 5). With the development of optimal instrumentation, it seems that efforts to perform minimally invasive surgery for gynecologic cancers will be continued. Although this surgical approach is new and innovative, this still remains incomplete for performance of complete cancer operation. For cancer operations, operators must have surgical skills to perform PLD or PALD. However, to date, the SPA system has limitations for traction of soft tissues, the ureter, and the bowel. This surgical action is essential for lymph node dissection. Therefore, we tried to perform a proper staging laparoscopy using the two-port technique. This system involves less invasive access, enabling operators to minimize the skin incision and the occurrence of complications from port insertion as compared to conventional or multi-port laparoscopy.

In our system, the most important role of the ancillary 5-mm port in the suprapubic area is traction from an assistant (Fig. 1). In order to minimize the scar, a 2 or 3-mm instrument may be used without trocar insertion (6). The operator can grasp tissues or push them aside slightly using these instruments. However, they are so flexible that an assistant cannot perform counter-traction of tissues against the operator. Additionally, it is difficult to maintain traction for a long time and to perform traction of fine tissues. Especially for PALD, we were able to remove lymphatic tissues safely without injury of organs with traction through a 5-mm port. An additional 5-mm port in the suprapubic area is also useful for ventilation of CO<sub>2</sub>. For the SPA system, non-ventilated air often obstructs the operator's view, complicating the procedure and leading delays in operating time. Another role of the additional 5-mm port is to perform the main action for the upper PALD. For the upper PALD, the operator exchanges his position from left to right side of patient. The assistant holds the endoscope and instrument for traction through multi-channel port at the umbilicus. At that time, the operator holds a grasper or dissector in his left hand at the umbilicus and the instrument for the main action, such as a Harmonic Ace™ or bipolar forcep, in his right through the 5-mm port in the suprapubic area. The operator's change of

position can prevent the mirror effect on his view. Furthermore, a blunt injury by the tip of the instrument can be avoided because the angle between the Harmonic Ace™ and the large vessel is not sharp but parallel through the 5-mm port in the suprapubic area (Fig. 6). Finally, we insert drainage through the ancillary 5-mm port after completion of all procedures.

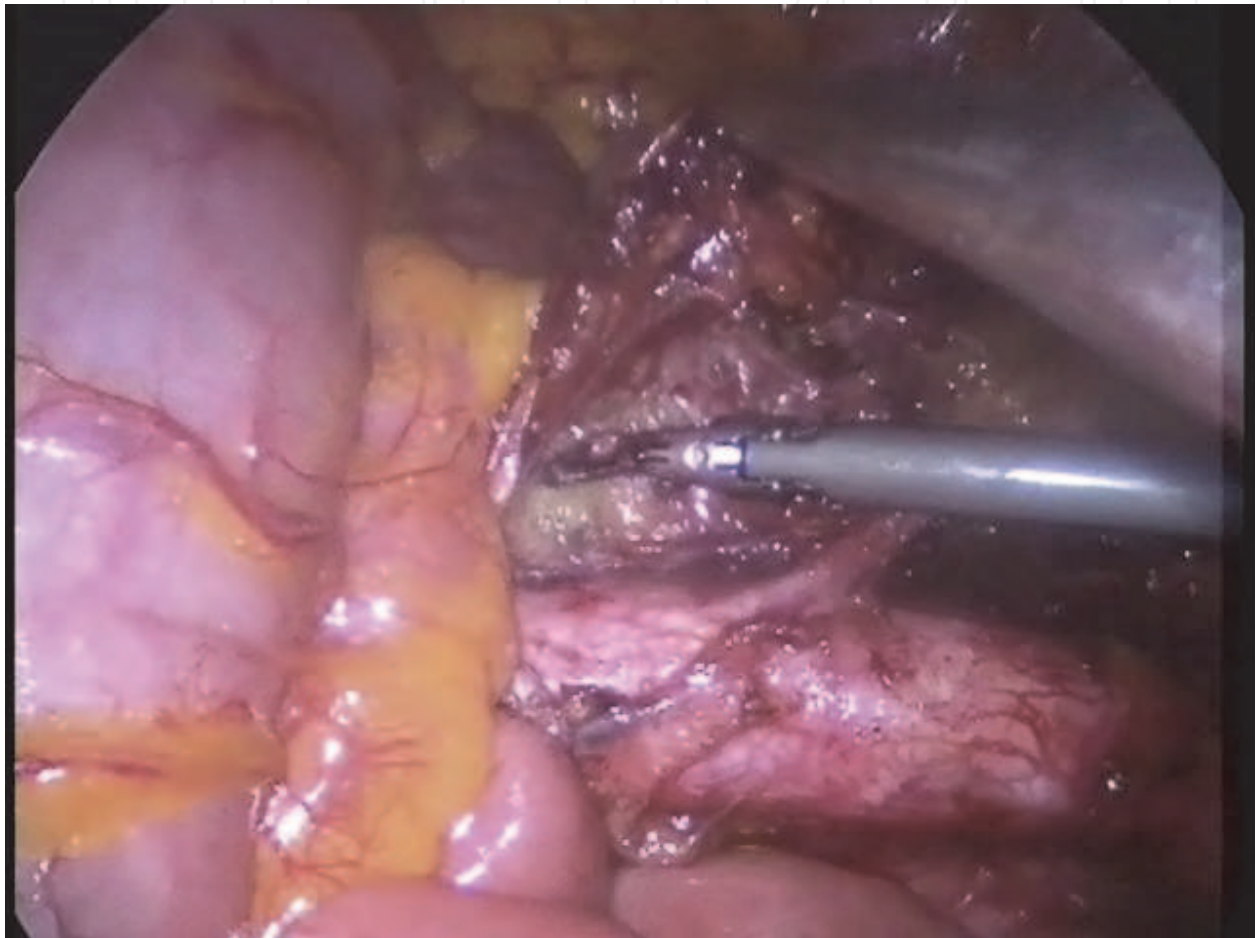


Fig. 6. A blunt injury by the tip of the instrument can be avoided because the angle between the Harmonic Ace™ and the large vessels is parallel.

Compared to commercial umbilical multi-port systems, our homemade system using surgical gloves has several advantages for performing staging operations. First, another 2- or 3-mm instrument can be added for traction. At that time, the total number of used instruments is five, including an endoscope. Also, the surgical gloves are somewhat flexible, so that the surgeon can overcome the limitation of range of motion that occurs in the small umbilical incision. Because we performed PLD and PALD after hysterectomy and closure for the vaginal cuff, the glove port system was useful for removal of lymphatic tissues or the omentum (Fig. 7).



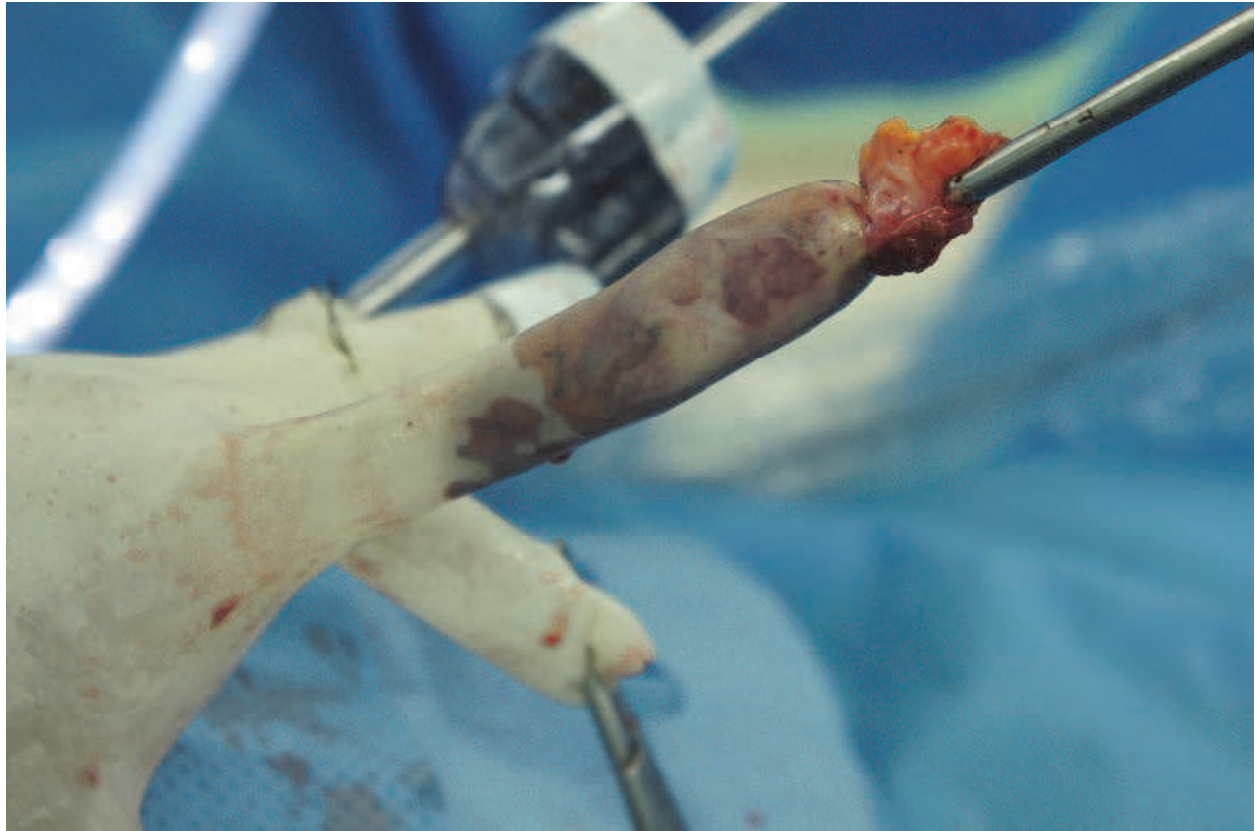

Fig. 7. Removal of lymphatic tissues through the hole of the surgical gloves.

In addition, upper PALD extending to the renal vein level was performed, although we had some troubles due to difficulty in traction of the bowel and limited angle of laparoscopic view. However, we were able to overcome this problem by using a 5-mm sized laparoscopic articulating fan retractor (Tekno Medical, Germany) through the multi-port at the umbilicus (Fig. 8).

Although operating time in TPA surgery was not short, it gradually decreased with the experiences for this surgical approach. The median number of lymph nodes resected in our study was 36, and this number is sufficient compared to the results of other studies with a conventional laparoscopic or robotic approach (7-9). For pain analysis, we showed that TPA staging laparoscopy had tolerable postoperative pain. Pain after laparoscopy is multifactorial. Mouton et al. recommended the following for reduction of pain after laparoscopy: inject port sites with local anesthesia at the start of the operation; keep intra-abdominal pressure during pneumoperitoneum below 15 mmHg, avoiding pressure peaks and prolonged insufflation; use humidified gas at body temperature if available; use nonsteroidal anti-inflammatory drugs at the time of induction; attempt to evacuate all intraperitoneal gas at the end of the operation; and use drains only when required, rather than as a routine (10). Supposing these circumstances is constant for surgery, the number and size of skin incisions is certainly related to postoperative pain. The authors have already demonstrated that SPA hysterectomy caused less immediate postoperative pain and better surgical outcome with respect to recovery time than conventional laparoscopic hysterectomy (2).

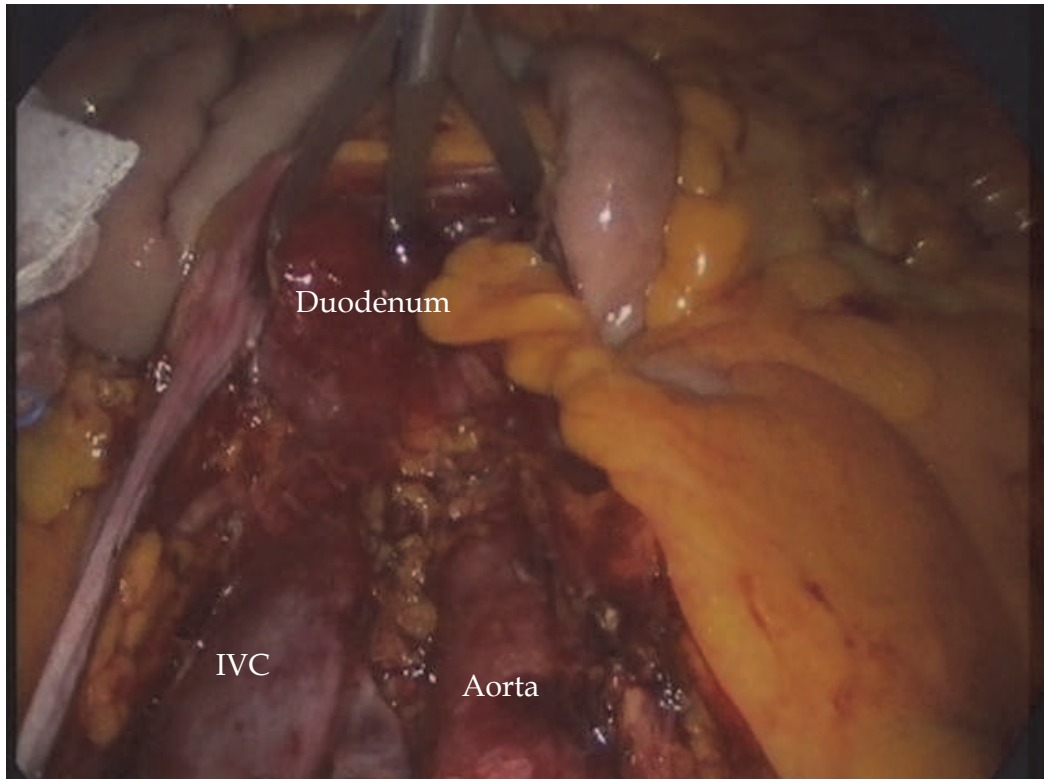


Fig. 8. The use of the 5-mm sized laparoscopic articulating fan retractor for traction of the bowel.

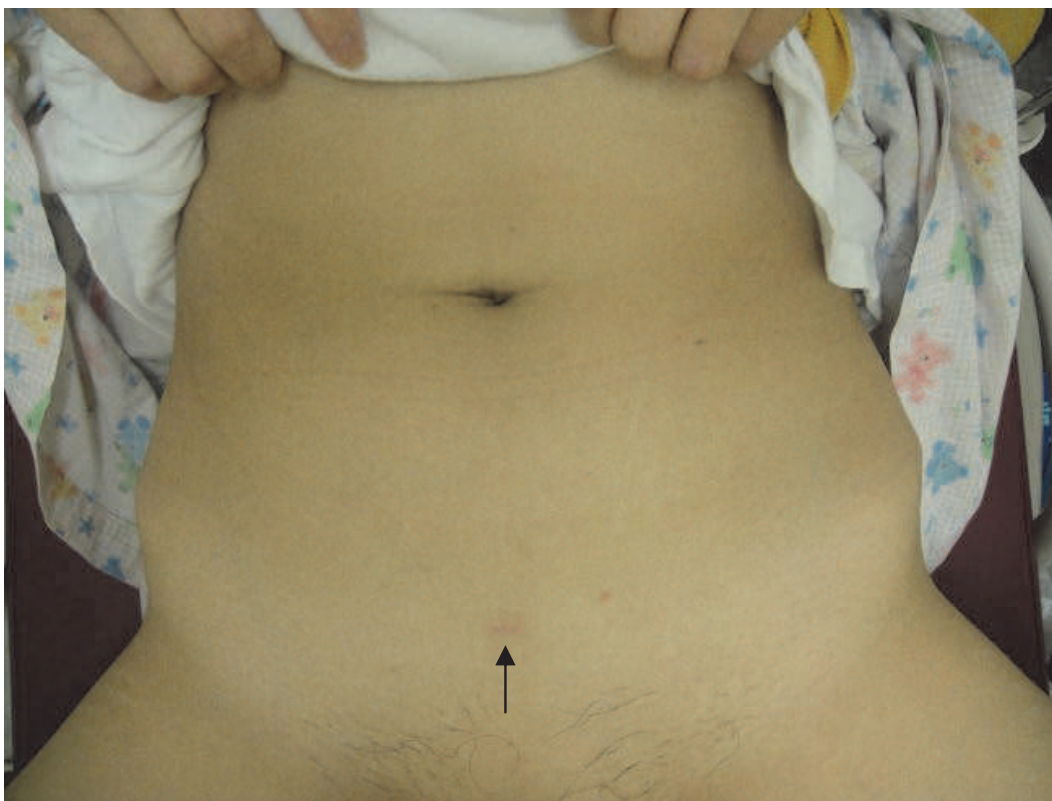


Fig. 9. Postoperative image after 2 months; There is only one small scar on the suprapubic area (arrow).

Putative advantages of the TPA system include enhanced cosmetic results from a hidden umbilical scar and 5-mm suprapubic incision that is covered by pubic hair, a decrease in morbidity related to bowel and vascular injury during trocar placement, and decreased postoperative wound infection and hernia formation (Fig 9).

To clarify the benefits of the TPA system and to complement limitations of this study, a prospective randomized trial is needed. In conclusion, TPA staging laparoscopy using a single multi-channel port and 5-mm ancillary port is a feasible procedure for gynecologic cancer patients and causes only minimal skin incisions.

## 5. References

- [1] Paek J, Nam EJ, Jung YW, Lee SH, Kim JH, Kim YT, et al. Two-port access staging laparoscopy for gynecologic cancers: a pilot study. *J Laparoendosc Adv Surg Tech A*. 2010 May;20(4):347-53.
- [2] Yim GW, Jung YW, Paek J, Lee SH, Kwon HY, Nam EJ, et al. Transumbilical single-port access versus conventional total laparoscopic hysterectomy: surgical outcomes. *Am J Obstet Gynecol*. 2010 Jul;203(1):26 e1-6.
- [3] Escobar PF, Starks DC, Fader AN, Barber M, Rojas-Espalliat L. Single-port risk-reducing salpingo-oophorectomy with and without hysterectomy: surgical outcomes and learning curve analysis. *Gynecol Oncol*. 2010 Oct;119(1):43-7.
- [4] Fader AN, Rojas-Espalliat L, Ibeanu O, Grumbine FC, Escobar PF. Laparoendoscopic single-site surgery (LESS) in gynecology: a multi-institutional evaluation. *Am J Obstet Gynecol*. 2010 Nov;203(5):501 e1-6.
- [5] Fader AN, Escobar PF. Laparoendoscopic single-site surgery (LESS) in gynecologic oncology: technique and initial report. *Gynecol Oncol*. 2009 Aug;114(2):157-61.
- [6] Nougues CP, Harmon CM, Hansen EN, Georgeson KE, Muensterer OJ. Cholecystectomy using single-incision pediatric endosurgery: technique and initial experience in the first 25 cases. *J Laparoendosc Adv Surg Tech A*. 2010 Jun;20(5):493-6.
- [7] Scribner DR, Walker JL, Johnson GA, McMeekin SD, Gold MA, Mannel RS. Laparoscopic pelvic and paraaortic lymph node dissection: analysis of the first 100 cases. *Gynecologic Oncology*. 2001;82(3):498-503.
- [8] Khler C, Klemm P, Schau A, Possover M, Krause N, Tozzi R, et al. Introduction of transperitoneal lymphadenectomy in a gynecologic oncology center: analysis of 650 laparoscopic pelvic and/or paraaortic transperitoneal lymphadenectomies. *Gynecologic Oncology*. 2004;95(1):52-61.
- [9] Holloway RW, Ahmad S, DeNardis SA, Peterson LB, Sultana N, Bigsby GE, et al. Robotic-assisted laparoscopic hysterectomy and lymphadenectomy for endometrial cancer: Analysis of surgical performance. *Gynecologic Oncology*. 2009;115(3):447-52.
- [10] Mouton WG, Bessell JR, Otten KT, Maddern GJ. Pain after laparoscopy. *Surg Endosc*. 1999 May;13(5):445-8.



## **Advanced Gynecologic Endoscopy**

Edited by Dr. Atef Darwish

ISBN 978-953-307-348-4

Hard cover, 332 pages

**Publisher** InTech

**Published online** 23, August, 2011

**Published in print edition** August, 2011

The main purpose of this book is to address some important issues related to gynecologic laparoscopy. Since the early breakthroughs by its pioneers, laparoscopic gynecologic surgery has gained popularity due to developments in illumination and instrumentation that led to the emergence of laparoscopy in the late 1980's as a credible diagnostic as well as therapeutic intervention. This book is unique in that it will review common, useful information about certain laparoscopic procedures, including technique and instruments, and then discuss common difficulties faced during each operation. We also discuss the uncommon and occasionally even anecdotal cases and the safest ways to deal with them. We are honored to have had a group of world experts in laparoscopic gynecologic surgery valuably contribute to our book.

### **How to reference**

In order to correctly reference this scholarly work, feel free to copy and paste the following:

Jiheum Paek and Sang Wun Kim (2011). Two-Port Access Staging Laparoscopy for Gynecologic Cancers, *Advanced Gynecologic Endoscopy*, Dr. Atef Darwish (Ed.), ISBN: 978-953-307-348-4, InTech, Available from: <http://www.intechopen.com/books/advanced-gynecologic-endoscopy/two-port-access-staging-laparoscopy-for-gynecologic-cancers>

**INTECH**  
open science | open minds

### **InTech Europe**

University Campus STeP Ri  
Slavka Krautzeka 83/A  
51000 Rijeka, Croatia  
Phone: +385 (51) 770 447  
Fax: +385 (51) 686 166  
[www.intechopen.com](http://www.intechopen.com)

### **InTech China**

Unit 405, Office Block, Hotel Equatorial Shanghai  
No.65, Yan An Road (West), Shanghai, 200040, China  
中国上海市延安西路65号上海国际贵都大饭店办公楼405单元  
Phone: +86-21-62489820  
Fax: +86-21-62489821

© 2011 The Author(s). Licensee IntechOpen. This chapter is distributed under the terms of the [Creative Commons Attribution-NonCommercial-ShareAlike-3.0 License](#), which permits use, distribution and reproduction for non-commercial purposes, provided the original is properly cited and derivative works building on this content are distributed under the same license.

IntechOpen

IntechOpen