

We are IntechOpen, the world's leading publisher of Open Access books Built by scientists, for scientists

4,800

Open access books available

122,000

International authors and editors

135M

Downloads

Our authors are among the

154

Countries delivered to

TOP 1%

most cited scientists

12.2%

Contributors from top 500 universities



WEB OF SCIENCE™

Selection of our books indexed in the Book Citation Index
in Web of Science™ Core Collection (BKCI)

Interested in publishing with us?
Contact book.department@intechopen.com

Numbers displayed above are based on latest data collected.

For more information visit www.intechopen.com



Laparoscopy for Diagnosis and Treatment of Endometriosis

Moamar Al-Jefout

*Department of Obstetrics & Gynecology, Mutah Medical Faculty, Mutah University,
Jordan*

1. Introduction

Endometriosis is defined as the presence of endometrial like stroma and glands outside the uterine cavity (Giudice and Kao, 2004). Laparoscopy has been recognized as the gold standard for endometriosis diagnosis and has been used for the surgical treatment of endometriosis. Diagnosis of endometriosis is currently made following laparoscopic inspection of the pelvis, preferably with histological biopsy confirmation (Mettler et al., 2003), although the correlation of biopsy with visual inspection depends on the experience of the endoscopist, inter-observer variability, the technique of excision and the care and experience of the pathologist (Poncelet and Ducarme, 2007). In one recent study, only 67% of lesions identified at laparoscopy as possible endometriosis proved to have the histological features of endometriosis (Stratton et al., 2003). Moreover, visual inspection of the pelvis also has its own limitations, particularly for the diagnosis of atypical and non-peritoneal endometriosis.

Endometriotic lesions can vary in colour, mostly non-black, red, white or like burned powder. In clinical observation the age of a lesion can be estimated from the colour of these lesions. It appears that clear papules are limited to a younger age group (17-31 years), than the red (16-43 years) and black (20-52 years) lesions (Redwine, 1987).

Many studies have clearly shown that there is a substantial delay in endometriosis diagnosis which inevitably has negative effect on quality of life of endometriosis patients (Matsuzaki et al., 2006, Hadfield et al., 1996, Zrubek et al., 1999, Ballard et al., 2006, Stratton, 2006). Ballard et al. demonstrate that the definitive diagnosis of endometriosis is frequently delayed for many years (2006). In a series of patients from southeastern England the mean delay from onset of symptoms to definitive diagnosis was 102 months (9.5 years). Delays usually occurred at every stage in the diagnostic process. An average patient waited for 18 months before been seen by a family doctor. The general practitioner subsequently waited 3 years before referring the patient for a specialized opinion by a gynaecologist, and it takes a further 9 months before the diagnosis is made. This delay is even longer in cases with deep infiltrating endometriosis and advanced endometriosis stage IV (Matsuzaki et al., 2006).

The review by Wykes, C. B showed that there are very few good quality studies in the literature regarding the role of laparoscopy in the diagnosis of endometriosis (Wykes et al., 2004). A negative laparoscopy for endometriosis is helpful and women can be adequately reassured without the need for further testing, while a positive laparoscopy is less informative without histological confirmation. A false positive laparoscopy can hugely affect the woman's quality of life, perception of her own health, fertility and even sexual life.

The aim of surgical management is to remove visible areas of endometriosis and restore anatomy by division of adhesions. Yet, treatment frequently must be individualized. However, distinguishing patients who need no treatment from patients who need intermediate or extensive treatment can be difficult. There are three recognized types of endometriosis: peritoneal endometriosis, ovarian endometriomas and deep adenomyotic nodules of the rectovaginal septum (Nisolle and Donnez, 1997).

Few principles have to be considered regarding the surgical management of endometriosis:

- Severe disease must be treated differently from mild to moderate disease.
- Patients with pain symptoms associated with endometriosis must be approached differently from patients seeking fertility.
- Clinicians and patients should be aware that the expected benefit is depending on operator skills (Vercellini et al., 2009).

Jansen and Russell have shown that peritoneum which looks completely normal does not contain histological features of endometriosis, therefore excision of all abnormally looking peritoneum, deep nodules and ovarian lesions should remove the disease (1986). Yet a downside of this approach is the risk for future adhesion formation.

2. Background

Endometriosis is a common and frequently chronic disease, characterized by the presence of endometrial like-glands and stroma outside the uterine cavity. Endometriosis is still an enigmatic disease as it still represent itself as a big challenge for patients to cope with the disease and for medical professionals dealing with this category of patients. The challenge is primarily in the diagnostic process of endometriosis as its clinical features may cross with the clinical features of other conditions such as adenomyosis, interstitial cystitis and irritable bowel syndrome. Another problem with endometriosis diagnosis is the general normalization of pain symptoms by. Moreover, there yet no diagnostic tool with significantly enough specificity and sensitivity for the diagnosis. may be difficult to diagnose, yet may cause considerable distress with pelvic pain and infertility. However, some women will be completely asymptomatic although, having severe stage of the disease incidentally found during laparoscopy for other reasons. Laparoscopy with or without histological confirmation is the gold standard for endometriosis diagnosis. However, there is often a considerable delay in diagnosis of endometriosis, partly because there is no simple tool for effective diagnosis. For many decades, surgical removal of endometriotic lesions was the primary basis for the management of endometriosis and radical removal of ectopic lesions is still the preferred way for most surgeons when dealing with endometriosis (Redwine et al., 2000). However, there is no correlation between findings at laparoscopy and symptoms and prognosis in terms of fertility and recurrence rate (Vercellini et al., 2006). It seems to be that the patient's own preference and plans for her fertility are becoming more important in controlling the management plans (Vercellini et al., 2003).

Medical treatment for endometriosis is mainly for pain symptoms, while medical treatment for infertility purposes has no benefit or may even delay pregnancy, 'more harm than good can be done by drug treatment, because of side effects and the lost opportunity to conceive' (RCOG, 2000). It seems to be that a combined medical and conservative surgical approach is beneficial for most women with endometriosis associated pelvic pain (Davis and McMillan, 2003). Moreover, evidence showed that laparoscopic surgery in terms of excision and or ablation of mild to moderate disease can in fact enhance fertility (Marcoux et al., 1997, Olive and Pritts, 2002). However, an Italian RCT showed that ablation of endometriotic lesions did not markedly improves fertility rates (Parazzini, 1999).

3. Anatomy of the anterior abdominal wall related to laparoscopic surgery for endometriosis

Any surgeon intending to perform laparoscopic surgery for endometriosis must have a complete understanding and a thorough knowledge of the anterior abdominal wall vascular anatomy. This knowledge will reduce vascular complications associated with laparoscopy especially trocar placement. Of particular concern are the superior and inferior epigastric vessels. The superior epigastric artery, one of the terminal branches of the internal thoracic artery, enters the rectus sheath first and then the rectus muscle coursing near its lateral border. This artery and its adjacent vein often can be visualized by transillumination of the abdominal wall with the laparoscope.

Visualization of the ventral abdominal wall laparoscopically will often locate the deep inferior epigastric vessels. The artery, a branch of the external iliac, and its accompanying vein course along the abdominal wall peritoneum just lateral to the rectus muscle until midway between the symphysis pubis and umbilicus, where it blends into the body of the rectus muscle. These vessels may be seen medial to the insertion of the round ligament at the deep inguinal ring. Therefore, placement of the trocar lateral to the deep inguinal ring and lateral border of the rectus muscle will avoid injury to these vessels.

If placement of the trocar is too far laterally, branches of the superficial circumflex iliac vessels may be injured. Again, transillumination of the anterior abdominal wall by using the laparoscope will assist in avoiding these vessels.

As a general guideline, the superficial and inferior epigastric vessels are located approximately 5.5 cm from the midline. The superficial circumflex iliac vessels are approximately 7 cm from the midline. Theoretically, a "safe area" would be 8 cm above the symphysis pubis and 8 cm from the midline. If transillumination is not effective due to a thick abdominal wall, the surgeon may consider insertion of a spinal needle through the abdominal wall at the selected trocar insertion site. If no bleeding is observed after removal of the needle, the location is likely safe for trocar placement.

4. Delay in diagnosis of endometriosis

Many studies have clearly shown that there is a substantial delay in endometriosis diagnosis which inevitably has negative effect on quality of life of endometriosis patients (Matsuzaki et al., 2006, Hadfield et al., 1996, Zrubek et al., 1999, Ballard et al., 2006, Stratton, 2006). Ballard et al. demonstrate that the definitive diagnosis of endometriosis is frequently delayed for many years (2006). In a series of patients from southeastern England the mean delay from onset of symptoms to definitive diagnosis was 102 months (9.5 years). Delays usually occurred at every stage in the diagnostic process. An average patient waited for 18 months before been seen by a family doctor. The general practitioner subsequently waited 3 years before referring the patient for a specialized opinion by a gynaecologist, and it takes a further 9 months before the diagnosis is made. This delay is even longer in cases with deep infiltrating endometriosis and advanced endometriosis stage IV (Matsuzaki et al., 2006).

The fundamental question about such delays is whether they matter. The work of Ballard et al. suggests that they do. The absence of a specific diagnosis left patients fearful of what was wrong with them and unable to communicate about their problems to others, particularly their employers. Learning of the correct diagnosis was associated with positive experiences in terms of reassurance about the absence of more sinister problems and in improving access to social support and accurately tailored treatment.

An open, mutually understanding relationship between doctor and patient is necessary if the diagnosis is to be made without undue delay (Kennedy, 1991) thus improving the chances of getting better results in treatment and compliance.

5. Laparoscopy as the gold standard for the diagnosis of endometriosis

5.1 Laparoscopy as gold standard

Laparoscopy (figure 2) in endometriosis is based on the visualization of superficial implants, endometriomas, adhesion distribution, bowel disease and ureteric disease. In doubtful cases, biopsies showing glands and stroma have been the basis of the diagnosis. Endometriotic lesions can vary in colour, mostly non-black, red, white or like burned powder. In clinical observation the age of a lesion can be estimated from the colour. It appears that clear papules are limited to a younger age group (17-31 years), than the red (16-43 years) and black (20-52 years) lesions (Redwine, 1987).

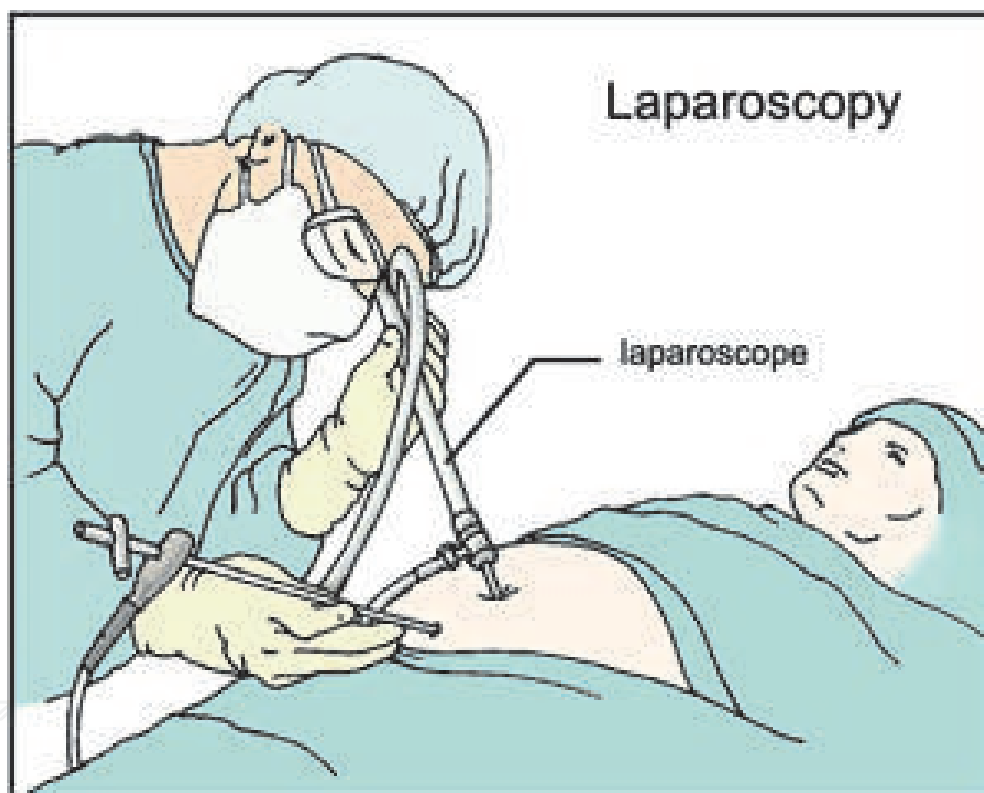


Fig. 1. Laparoscopy

In some cases asymptomatic women endometrial implants have been found in biopsies from normal peritoneum, resulting in the suggestion that mild endometriosis is not a disease and that all women have this mild form of endometriosis (Koninckx, 1994, Evers, 1994).

In the years 1994–1996 378,100 women with pelvic/abdominal pain underwent ambulatory diagnostic laparoscopy for pelvic pain. This figure excluded women undergoing laparoscopy as an in-patient procedure and represents 34% of the 1.1 million diagnostic laparoscopies performed in the U.S. during that period (Natuzzi et al., 1993).

One-third of all diagnostic laparoscopies revealed endometriosis, one-third revealed no visible pathology, and the remaining one-third demonstrated a variety of other

gynecologic conditions (Howard, 1993). Thus, two-thirds of all patients who undergo this invasive diagnostic procedure will not have endometriosis. To avoid false negative endometriotic lesion biopsy a multiple biopsy approach was proposed (Kazanegra et al., 2008).

The review by Wykes, C. B showed that there are very few good quality studies in the literature regarding the role of laparoscopy in the diagnosis of endometriosis (Wykes et al., 2004). A negative laparoscopy for endometriosis is helpful and women can be adequately reassured without the need for further testing, while a positive laparoscopy is less informative without histological confirmation (Wykes et al., 2004). A false positive laparoscopy can hugely affect the woman's quality of life, perception of her own health, fertility and even sexual life. Recently other diagnostic tools been proposed for the diagnosis of endometriosis such as blood markers and most recently an endometrial biopsy looking for nerve fibres in the functional layers been proposed (Al-Jefout et al., 2007, Al-Jefout et al., 2009), however, more studies are needed for further confirmation.

5.2 Risks of laparoscopy

As an invasive surgical procedure, laparoscopy still carries occasional risks of injuring vessels, ureter or intestine. An estimated risk of death of 0.1/1000 mainly due to vascular injuries and the risk of injury to bowel, bladder, or blood vessel of 2.4%, of whom two-thirds will require a laparotomy and this concern is still a significant contributor to the delay in diagnosis (Hadfield et al., 1996, Arruda et al., 2003, Brosens et al., 2003, Ballard et al., 2006, Schenken, 2006).

5.3 Laparoscopic conscious pain mapping

Laparoscopic conscious pain mapping was first described when it was used for laparoscopic evaluation of the appendix (Almeida et al., 1998). Pelvic pain mapping during laparoscopy performed under conscious sedation can provide useful information about visceral and somatic sources of chronic pelvic pain (Steege, 1998). Conscious laparoscopic pain mapping has been proposed as a way to improve information derived from laparoscopic evaluations in gynaecology even in an office set up (Howard, 2000, Almeida and Val-Gallas, 1998, Howard, 2003). Conscious pain mapping can be done with reasonable success in women with prior surgical evaluations and treatments for chronic pelvic pain. Chronic visceral pain syndrome, adhesions, and endometriosis were the most common diagnoses (Howard et al., 2000) Although, long term results needs to be verified in larger scale studies (Tytherleigh et al., 2004).

5.4 Transvaginal hydrolaparoscopy (THL)

In order to avoid the risks accompanied with laparoscopy a new diagnostic procedure transvaginal hydro-laparoscopy (Figure 2) has been proposed as an office based procedure (Gordts et al., 2000, Campo et al., 1999). Because it is done under local anaesthetic; the risks of general anaesthesia are avoided. The use of saline for visualization gives surgeons more sensitivity for identifying adhesions (Brosens et al., 1999). Use of this technology resulted in a 50% increase in finding peri-ovarian adhesions in comparison with conventional laparoscopy. THL also gives the surgeons and the patients more options in planning future treatment plans.

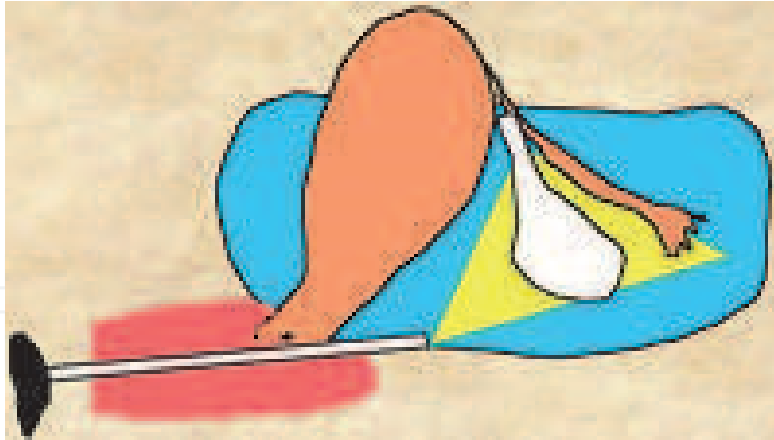


Fig. 2. Hydrolaparoscopy

6. Laparoscopy for the staging of endometriosis

6.1 Historical background of endometriosis classification

Wicks and Larson proposed the first classification of endometriosis (1949) which was based on pathological and histological examination of the endometriotic lesions. The next step was a proposed system based on macroscopic evidence of the disease (Huffman, 1951). However, this staging system did not include adhesions. The next staging system included the adhesions and for the first time guidelines were proposed to determine which patients should be treated medically and which ones surgically (Riva et al., 1962). Beecham suggested a new classification which recorded the medical data of patients (1966). It was not until 1973 that the first acceptable classification appeared and was known as the Acosta classification (Acosta et al., 1973). It was the first classification to take into account the size of the lesions, scarring and fibrosis around the implants, as well as all adhesions. However, this system did not clarify if the lesions were uni- or bilateral and did not provide any prognosis about recurrence.

6.2 The perfect classification, is there such a thing?


Endometriosis is one of the most studied diseases in gynaecology, yet the mechanisms underlying the development of endometriosis are not understood. Nor is there understanding of the relationship between the clinical picture in terms of infertility and pain symptoms with the extent of the disease. Despite numerous clinical studies and intensive research, there are still no convincing answers to these questions and probably will not be for many years to come. The perfect classification should give clinicians the ability to correctly anticipate the prognosis for conception, relief of pelvic pain and the risk of recurrence. A perfect classification should also use common medical terminology, which clinicians from all over the world can interpret in the same way.

7. The revised american society of reproductive medicine (rASRM) previously (rAFS)

The American fertility Society proposed a new classification which was at that time simple and the most informative (1979). Now a widely used classification of endometriosis (renamed as the revised American Society for Reproductive Medicine (rASRM) (Figure 1)

includes number, size and location of endometrial implants, endometriomas and if present adhesions. It is based (1) on the appearance, size, and depth of peritoneal and ovarian implants; (2) on the presence, extent and type of lesions: red (red, red-pink, and clear), white (white, yellow-brown, and peritoneal defects) and black (black and blue); (3) on the presence, extent, and type of adnexal adhesions and the degree of cul-de-sac obliteration. This helped to establish the stage of the disease as Stage I (minimal disease), Stage II (Mild disease), Stage III (Moderate disease) and Stage IV (Severe disease).

In a following meeting of the AFS this classification was revised after some comments from many experts and now it is widely for in the diagnosis of endometriosis (1985).



**THE AMERICAN FERTILITY SOCIETY
REVISED CLASSIFICATION OF ENDOMETRIOSIS**

Patient's Name _____ Date _____

Stage I (Minimal) - 1-5 Laparoscopy _____ Laparotomy _____ Photography _____
 Stage II (Mild) - 6-15 Recommended Treatment _____
 Stage III (Moderate) - 16-40
 Stage IV (Severe) - > 40
 Total _____ Prognosis _____

PERITONEUM	ENDOMETRIOSIS	< 1cm	1-3cm	> 3cm
	Superficial	1	2	4
Deep	2	4	6	

OVARY	R	Superficial	1	2	4
	Deep	4	16	20	
	L	Superficial	1	2	4
	Deep	4	16	20	

POSTERIOR CULDESAC OBLITERATION	Partial	Complete
	4	40

OVARY	ADHESIONS	< 1/3 Enclosure	1/3-2/3 Enclosure	> 2/3 Enclosure
	R Filmy	1	2	4
	Dense	4	8	16
	L Filmy	1	2	4
	Dense	4	8	16

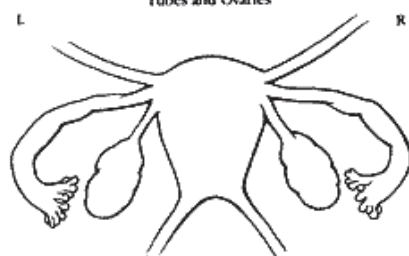
TUBE	R	Filmy	1	2	4
	Dense	4*	8*	16	
	L	Filmy	1	2	4
	Dense	4*	8*	16	

*If the fimbriated end of the fallopian tube is completely enclosed, change the point assignment to 16.

Additional Endometriosis: _____

Associated Pathology: _____

To Be Used with Normal
Tubes and Ovaries



To Be Used with Abnormal
Tubes and/or Ovaries




Fig. 3. Revised classification of endometriosis according to American Society for Reproductive Medicine.

7.1 Advantages of rASRM

The rASRM requires thorough description of the lesions and their extent, so in order to complete the classification form clinicians need to be thorough in their inspection of the abdominal cavity, thus enabling them to decrease false positive results at laparoscopies. Finally, this system can be used electronically to analyse the data later on

7.2 Disadvantages of rASRM

The American Fertility Society classification does not reflect the intensity of endometriosis-associated symptoms, probably underestimating the most active forms of this disease, and does not facilitate tracking the likely natural progression of the disease (Marana et al., 1991).

7.2.1 The ENZIAN-Score

German Authors tried to substitute the rASRM by the ENZIAN-Score which was proposed as a new system to stage and classify deep infiltrating endometriosis. The endometriotic nodules are assigned to different subgroups depending on their localization and expansion. The authors of this system claimed that the still used rASRM (rAFS)-score is of no clinical significance especially in patients with severe intestinal endometriosis (Tuttles et al., 2005).

7.3 Peritoneal endometriosis surgical management

7.3.1 Minimal or mild disease

The severity of pain symptoms in minimal disease are found not to be correlated with findings at laparoscopy (Chene et al., 2008). Surgical approaches like resection of peritoneal endometriosis; or monopolar electrocoagulation/ablation may be used. In the early stages, surgical treatment seems to reduce pain symptoms as effective as by drug therapy (Boing and Kimmig, 2007, Golfier and Sabra, 2007, Frishman and Salak, 2006). In the resection technique the peritoneum is incised near the lesion using a monopolar electrode and is dissected bluntly, separating healthy tissue from endometriotic tissue. Resection seems to be more efficient than diathermy coagulation, yet, it is more difficult, increases the time of the operation, and the cost (Martin and O'Conner, 2003). Monopolar electrocoagulation is done by applying a monopolar electrode to the visible endometriotic lesion. Extra care must be taken when treating the lateral pelvic side wall to avoid thermal damage to the ureter. To minimize this thermal effect, the peritoneum on the pelvic side wall could be opened and dissected to allow visualization of the ureter. Alternatively, 'hydroprotection' can be used. This involves injection of 0.9% saline under the diseased peritoneum, which elevates the peritoneum, allowing safe vaporization or diathermy.

For peritoneal endometriotic implants, a power setting of 40–50 W (laser CO₂) is usually used using a continuous firing mode (Donnez et al., 2004). To date, only one double-blind, RCT has been reported that examined the effect of laparoscopic treatment of endometriosis on pain (Sutton et al., 1994). This study has shown that laser excision of endometriosis significantly improves pain symptoms. However, this study has been criticized because the investigators performed simultaneously laparoscopic uterine nerve ablation and laser excision of the endometriosis and hence we cannot know which treatment has resulted in the pain relief. Sutton et al (1997) in a follow up study reported that 90% of responders had a pain relief for 1 year after laser excision, while 29% of patients had progressive disease and

the same percentage (29%) had spontaneous regression. Finally, pain symptoms reported to be improved with the use of Helica TC (thermal coagulator) in women with stages I and II endometriosis. However, this approach requires further evaluation as part of randomized controlled trials (Nardo et al., 2005).

Laparoscopic uterine nerve ablation (LUNA) and presacral neurectomy were also suggested as a treatment of pain symptoms. LUNA was found beneficial for dysmenorrhoea not associated with endometriosis (Johnson et al., 2004), while presacral neurectomy was found to reduce pain symptoms in endometriosis without significant side effects (Garcia Leon et al., 2003, Zullo et al., 2004).

7.3.2 Ovarian endometriomas

Surgical laparoscopic management of ovarian endometriomas can involve stripping of the cyst lining or laser vaporization of the internal wall of the cyst. If laser used, the depth of this vaporization may be superficial and only the glandular epithelium and the adjacent stroma have to be vaporized (Brosens et al., 1996).

Operative laparoscopy should be the first choice for management of ovarian endometrioma whenever possible (Ruhmann et al., 1996) and seems to be effective in alleviating pain associated with ovarian endometriomas (Yoshida et al., 2002). Medical therapy alone has not generally been effective in reducing endometrioma size and formed adhesions (Donnez and Nisolle, 1991).

7.3.3 Deep infiltrating endometriosis (DIE)

Deep endometriosis has been defined as endometriosis infiltrating deeper than 5 mm under the peritoneum (Koninckx and Martin, 1994). Unfortunately, the current classification of endometriosis is unsuccessful in predicting the major clinical outcomes, including pain symptoms (Vercellini et al., 2006).

In a retrospective study on 225 women with pelvic pain symptoms and DIE the anatomic locations of DIE implants and specific pain symptoms were recorded (including severe dysmenorrhoea, deep dyspareunia, non-cyclical chronic pelvic pain, painful defecation during menstruation, urinary tract symptoms, and gastrointestinal symptoms) (Fauconnier et al., 2002). There was an association between the frequency of severe dysmenorrhoea and DIE in the Douglas pouch adhesions, between the frequency of dyspareunia and DIE of uterosacral ligaments. The frequency of non-cyclical chronic pelvic pain was higher when it involved the bowel. The frequency of painful defecation during menstruation was higher when DIE involved the vagina; lower urinary tract symptoms were more frequent when DIE involved the bladder. The authors concluded that the types of pelvic pain can be broadly related to the anatomic location of DIE. Although, this study was retrospective, yet it gave good evidence of the correlation between locations of DIE and pain symptoms. Deep lesions need to be excised rather than vaporized (Koninckx and Martin, 1994). Coagulation, bipolar electrosurgery, argon laser, Potassium-Titanyl-Phosphate, (KTP) laser are also inadequate for management of lesions larger than 2 mm.

Operative laparoscopy in terms of complete excision of the disease is efficient for the treatment of painful symptoms related to deep endometriosis infiltrating uterosacral ligaments (Chopin et al., 2005). The segments of the rectum involved in the disease must be freed, leaving the deep endometriotic nodule attached to the posterior wall of the vagina. Resection of the whole lesion requires the posterior wall of the vagina to be

resected and the vagina is usually opened (Chapron et al., 2001), whereas ureterolysis is often unnecessary.

Because laparoscopic excision of deep bowel lesions has been associated with a residual of pelvic pain, laparotomy may sometimes be needed. Moreover, a new combined vaginal-laparoscopic-abdominal approach was compared with laparoscopy, laparotomy and laparoscopy followed by laparotomy for bowel resection or laparoscopy followed by vaginal bowel resection for rectovaginal endometriosis. The new approach allows intra-operative digital bowel palpation to assess bowel infiltration and reduce unnecessary bowel resections and found to minimize complication rate, re-hospitalization rate, and hospitalization time (Zanetti-Dallenbach et al., 2008).

Surgeons have been treating endometriosis using several approaches; either by laparoscopic excision, ablation or removal of endometriomata and endometriosis associated adhesions.

The laparoscopic approach seems to have more favorable outcome than open approach in terms of quality of surgery and patients acceptance. Laparoscopic surgical management is now recognized as the best approach for endometriosis associated infertility treatment followed by assisted reproductive techniques. However, for endometriosis associated pain symptoms there is no general consensus regarding the best way of dealing with these symptoms. The problems of comorbidity and recurrence is still a problem and under great debate.

7.4 Infertility and endometriosis

Infertility is common in endometriosis sufferers and is generally manifested as a reduced monthly chance of conceiving (reduced fecundability). Nevertheless, even in severe cases of endometriosis spontaneous successful conception and delivery of a healthy baby often occur. Despite enormous studies about the relationship between endometriosis and subfertility, this relationship still controversial issue. The main problems in those studies, that they don't have a defined patient population, clinical features arising from different endometriosis types are not well defined and the fact that scientists investigating endometriosis are lacking enough clinical data about patients they are studying. They just deal with tissues blindly.

However, an association between endometriosis and infertility has repeatedly been reported in the literature, but an absolute cause-and-effect relationship has yet to be confirmed (Mahutte and Arici, 2002). Many mechanisms have been proposed to cause fertility problems in endometriosis. These include altered folliculogenesis (Doody et al., 1988), leading to ovulatory dysfunction and low quality oocytes, as well as luteal phase defects (Grant, 1966), impaired fertilization (Wardle et al., 1985), and abnormal embryogenesis (Garrido et al., 2002), abnormalities in peritoneal fluid (Minici et al., 2008), eutopic endometrium and immunological abnormalities (Akoum et al., 2006).

It seems that not one mechanism is responsible for the reduced fecundability in endometriosis it is rather a complex of several mechanisms rather than one mechanism. The problem of conflicting results in different studies about infertility in endometriosis may be due to the lack of proper characterization of patient population, the defects imbedded in the current classification of endometriosis and the difficulty of elimination of other factors that affect fertility such as sperm quality and different interpretation by different laboratories.

8. References

- Acosta, A. A., Buttram, V. C., Jr., Besch, P. K., Malinak, L. R., Franklin, R. R. & Vanderheyden, J. D. (1973) A proposed classification of pelvic endometriosis. *Obstet Gynecol*, 42, 19-25.
- Akoum, A., Metz, C. N., Al-Akoum, M. & Kats, R. (2006) Macrophage migration inhibitory factor expression in the intrauterine endometrium of women with endometriosis varies with disease stage, infertility status, and pelvic pain. *Fertil Steril*, 85, 1379-85.
- Al-Jefout, M., Andreadis, N., Tokushige, N., Markham, R. & Fraser, I. (2007) A pilot study to evaluate the relative efficacy of endometrial biopsy and full curettage in making a diagnosis of endometriosis by the detection of endometrial nerve fibers. *American Journal of Obstetrics and Gynecology*, 197, 578.e1-578.e4.
- Al-Jefout, M., Dezarnaulds, G., Cooper, M., Tokushige, N., Luscombe, G. M., Markham, R. & Fraser, I. S. (2009) Diagnosis of endometriosis by detection of nerve fibres in an endometrial biopsy: A double blind study. *Human Reproduction*, 24, 3019-3024.
- Almeida, O. D., Jr. & Val-Gallas, J. M. (1998) Office microlaparoscopy under local anesthesia in the diagnosis and treatment of chronic pelvic pain. *J Am Assoc Gynecol Laparosc*, 5, 407-10.
- Almeida, O. D., Jr., Val-Gallas, J. M. & Rizk, B. (1998) Appendectomy under local anaesthesia following conscious pain mapping with microlaparoscopy. *Hum Reprod*, 13, 588-90.
- Arruda, M. S., Petta, C. A., Abrao, M. S. & Benetti-Pinto, C. L. (2003) Time elapsed from onset of symptoms to diagnosis of endometriosis in a cohort study of Brazilian women. *Hum Reprod*, 18, 756-9.
- Ballard, K., Lowton, K. & Wright, J. (2006a) What's the delay? A qualitative study of women's experiences of reaching a diagnosis of endometriosis. *Fertil Steril*, 86, 1296-301.
- Beecham, C. T. (1966) Classification of endometriosis. *Obstet Gynecol*, 28, 437.
- Boing, C. & Kimmig, R. (2007) [Surgical management of endometriosis--an overview]. *Gynakol Geburtshilfliche Rundsch*, 47, 124-31.
- Brosens, I., Campo, R. & Gordts, S. (1999) Office hydrolaparoscopy for the diagnosis of endometriosis and tubal infertility. *Curr Opin Obstet Gynecol*, 11, 371-7.
- Brosens, I. A., Van Ballaer, P., Puttemans, P. & Deprest, J. (1996) Reconstruction of the ovary containing large endometriomas by an extraovarian endosurgical technique. *Fertil Steril*, 66, 517-21.
- Brosens, J., Timmerman, D., Starzinski-Powitz, A. & Brosens, I. (2003) Noninvasive diagnosis of endometriosis: the role of imaging and markers. *Obstet Gynecol Clin North Am*, 30, 95-114, viii-ix.
- Campo, R., Gordts, S., Rombauts, L. & Brosens, I. (1999) Diagnostic accuracy of transvaginal hydrolaparoscopy in infertility. *Fertil Steril*, 71, 1157-60.

- Chapron, C., Jacob, S., Dubuisson, J. B., Vieira, M., Liaras, E. & Fauconnier, A. (2001) Laparoscopically assisted vaginal management of deep endometriosis infiltrating the rectovaginal septum. *Acta Obstet Gynecol Scand*, 80, 349-54.
- Chene, G., Jaffeux, P., Lasnier, C., Aublet-Cuvelier, B., Matsuzaki, S., Jardon, K., Mage, G., Pouly, J. L. & Canis, M. (2008) [Are there anatomical and clinical correlations between minimal and deep endometriosis? First results of Auvergne's Registry of Endometriosis]. *Gynecol Obstet Fertil*, 36, 17-22.
- Chopin, N., Vieira, M., Borghese, B., Foulot, H., Dousset, B., Coste, J., Mignon, A., Fauconnier, A. & Chapron, C. (2005) Operative management of deeply infiltrating endometriosis: results on pelvic pain symptoms according to a surgical classification. *J Minim Invasive Gynecol*, 12, 106-12.
- Davis, C. J. & Mcmillan, L. (2003) Pain in endometriosis: effectiveness of medical and surgical management. *Curr Opin Obstet Gynecol*, 15, 507-12.
- Donnez, J. & Nisolle, M. (1991) Laparoscopic management of large ovarian endometrial cyst: use of fibrin sealant. *J Gynecol Surg*, 7, 163-6.
- Donnez, J., Pirard, C., Smets, M., Jadoul, P. & Squifflet, J. (2004) Surgical management of endometriosis. *Best Pract Res Clin Obstet Gynaecol*, 18, 329-48.
- Doody, M. C., Gibbons, W. E. & Buttram, V. C., Jr. (1988) Linear regression analysis of ultrasound follicular growth series: evidence for an abnormality of follicular growth in endometriosis patients. *Fertil Steril*, 49, 47-51.
- Evers, J. L. (1994) Endometriosis does not exist; all women have endometriosis. *Hum Reprod*, 9, 2206-9.
- Fauconnier, A., Chapron, C., Dubuisson, J. B., Vieira, M., Dousset, B. & Breart, G. (2002) Relation between pain symptoms and the anatomic location of deep infiltrating endometriosis. *Fertil Steril*, 78, 719-26.
- Frishman, G. N. & Salak, J. R. (2006) Conservative surgical management of endometriosis in women with pelvic pain. *J Minim Invasive Gynecol*, 13, 546-58.
- Garcia Leon, F., Oviedo Ortega, G., Reyes Cuervo, H., Ibarrola Buenabad, E. & Von Der Meden, W. (2003) [Presacral neurectomy and uterine nerve ablation in chronic pelvic pain. Laparoscopic management. A comparative study.]. *Ginecol Obstet Mex*, 71, 137-42.
- Garrido, N., Navarro, J., Garcia-Velasco, J., Remoh, J., Pellice, A. & Simon, C. (2002) The endometrium versus embryonic quality in endometriosis-related infertility. *Hum Reprod Update*, 8, 95-103.
- Giudice, L. C. & Kao, L. C. (2004) Endometriosis. *Lancet*, 364, 1789-99.
- Golfier, F. & Sabra, M. (2007) [Surgical management of endometriosis]. *J Gynecol Obstet Biol Reprod (Paris)*, 36, 162-72.
- Gordts, S., Campo, R. & Brosens, I. (2000) Office transvaginal hydrolaparoscopy for early diagnosis of pelvic endometriosis and adhesions. *J Am Assoc Gynecol Laparosc*, 7, 45-9.
- Grant, A. (1966) Additional sterility factors in endometriosis. *Fertil Steril*, 17, 514-9.
- Hadfield, R., Mardon, H., Barlow, D. & Kennedy, S. (1996a) Delay in the diagnosis of endometriosis: a survey of women from the USA and the UK. *Hum Reprod*, 11, 878-80.

- Howard, F. M. (1993) The role of laparoscopy in chronic pelvic pain: promise and pitfalls. *Obstet Gynecol Surv*, 48, 357-87.
- Howard, F. M. (2000) The role of laparoscopy as a diagnostic tool in chronic pelvic pain. *Baillieres Best Pract Res Clin Obstet Gynaecol*, 14, 467-94.
- Howard, F. M. (2003) Chronic pelvic pain. *Obstet Gynecol*, 101, 594-611.
- Howard, F. M., EL-MINAWI, A. M. & SANCHEZ, R. A. (2000) Conscious pain mapping by laparoscopy in women with chronic pelvic pain. *Obstet Gynecol*, 96, 934-9.
- Huffman, J. W. (1951) External endometriosis. *Am J Obstet Gynecol*, 62, 1243-52.
- Jansen, R. P. & Russell, P. (1986) Nonpigmented endometriosis: clinical, laparoscopic, and pathologic definition. *Am J Obstet Gynecol*, 155, 1154-9.
- Johnson, N. P., Farquhar, C. M., Crossley, S., Yu, Y., Van Peperstraten, A. M., Sprecher, M. & Suckling, J. (2004) A double-blind randomised controlled trial of laparoscopic uterine nerve ablation for women with chronic pelvic pain. *BJOG*, 111, 950-9.
- Kazanegra, R., Zaritsky, E., Lathi, R. B., Clopton, P. & Nezhat, C. (2008) Diagnosis of stage I endometriosis: comparing visual inspection to histologic biopsy specimen. *J Minim Invasive Gynecol*, 15, 176-80.
- Kennedy, S. (1991) What is important to the patient with endometriosis? *Br J Clin Pract Suppl*, 72, 8-10; discussion 11-3.
- Koninckx, P. R. (1994) Is mild endometriosis a condition occurring intermittently in all women? *Hum Reprod*, 9, 2202-5.
- Koninckx, P. R. & Martin, D. (1994a) Treatment of deeply infiltrating endometriosis. *Curr Opin Obstet Gynecol*, 6, 231-41.
- Mahutte, N. G. & Arici, A. (2002) New advances in the understanding of endometriosis related infertility. *J Reprod Immunol*, 55, 73-83.
- Marana, R., Muzii, L., Caruana, P., Dell'acqua, S. & Mancuso, S. (1991) Evaluation of the correlation between endometriosis extent, age of the patients and associated symptomatology. *Acta Eur Fertil*, 22, 209-12.
- Marcoux, S., Maheux, R. & Berube, S. (1997) Laparoscopic surgery in infertile women with minimal or mild endometriosis. Canadian Collaborative Group on Endometriosis. *N Engl J Med*, 337, 217-22.
- Martin, D. C. & O'conner, D. T. (2003) Surgical management of endometriosis-associated pain. *Obstet Gynecol Clin North Am*, 30, 151-62.
- Matsuzaki, S., Canis, M., Pouly, J. L., Rabischong, B., Botchorishvili, R. & Mage, G. (2006a) Relationship between delay of surgical diagnosis and severity of disease in patients with symptomatic deep infiltrating endometriosis. *Fertil Steril*, 86, 1314-6; discussion 1317.
- Mettler, L., Schollmeyer, T., Lehmann-Willenbrock, E., Schuppler, U., Schmutzler, A., Shukla, D., Zavala, A. & Lewin, A. (2003) Accuracy of laparoscopic diagnosis of endometriosis. *JSLs*, 7, 15-8.
- Minici, F., Tiberi, F., Tropea, A., Orlando, M., Gangale, M. F., Romani, F., Campo, S., Bompiani, A., Lanzone, A. & Apa, R. (2008) Endometriosis and human


- infertility: a new investigation into the role of eutopic endometrium. *Hum Reprod*, 23, 530-7.
- Nardo, L. G., Moustafa, M. & Gareth Beynon, D. W. (2005) Laparoscopic treatment of pelvic pain associated with minimal and mild endometriosis with use of the Helica Thermal Coagulator. *Fertil Steril*, 83, 735-8.
- Natuzzi, E. S., Ursell, P. C., Harrison, M., Buscher, C. & Riemer, R. K. (1993) Nitric oxide synthase activity in the pregnant uterus decreases at parturition. *Biochem Biophys Res Commun*, 194, 1-8.
- Nisolle, M. & Donnez, J. (1997) Peritoneal endometriosis, ovarian endometriosis, and adenomyotic nodules of the rectovaginal septum are three different entities. *Fertil Steril*, 68, 585-96.
- Olive, D. L. & Pritts, E. A. (2002) The treatment of endometriosis: a review of the evidence. *Ann N Y Acad Sci*, 955, 360-72; discussion 389-93, 396-406.
- Parazzini, F. (1999) Ablation of lesions or no treatment in minimal-mild endometriosis in infertile women: a randomized trial. Gruppo Italiano per lo Studio dell'Endometriosi. *Hum Reprod*, 14, 1332-4.
- Poncelet, C. & Ducarme, G. (2007) [Endometriosis: good practice rules for diagnostic laparoscopy]. *J Gynecol Obstet Biol Reprod (Paris)*, 36, 135-40.
- Rafs (1979) Classification of endometriosis. *Fertil Steril*, 32, 633-4.
- Rcog (2000) The investigation and management of endometriosis. *Guidelines*. London, RCOG Press
- Redwine, D., Mann, C. H. & Wright, J. T. (2000) Evidence on endometriosis. Elitism about randomised controlled trials is inappropriate. *BMJ*, 321, 1077-8.
- Redwine, D. B. (1987a) Age-related evolution in color appearance of endometriosis. *Fertil Steril*, 48, 1062-3.
- Riva, H. L., Kawasaki, D. M. & Messinger, A. J. (1962) Further experience with norethynodrel in treatment of endometriosis. *Obstet Gynecol*, 19, 111-7.
- Ruhlmann, C., Vetrano, R., Bernaldo, D. G., Basso, F., Rolla, E. & Delger, R. (1996) Comparison of Laparoscopic versus Conventional Treatment of Ovarian Endometrioma. *J Am Assoc Gynecol Laparosc*, 3, S44.
- Schenken, R. S. (2006) Delayed diagnosis of endometriosis. *Fertil Steril*, 86, 1305-6; discussion 1317.
- Society, A. F. (1985) Revised American Fertility Society classification of endometriosis: 1985. *Fertil Steril*, 43, 351-2.
- Steege, J. F. (1998) Superior hypogastric block during microlaparoscopic pain mapping. *J Am Assoc Gynecol Laparosc*, 5, 265-7.
- Stratton, P. (2006a) The tangled web of reasons for the delay in diagnosis of endometriosis in women with chronic pelvic pain: will the suffering end? *Fertil Steril*, 86, 1302-4; discussion 1317.
- Stratton, P., Winkel, C., Premkumar, A., Chow, C., Wilson, J., Hearn-Stokes, R., Heo, S., Merino, M. & Nieman, L. K. (2003) Diagnostic accuracy of laparoscopy, magnetic resonance imaging, and histopathologic examination for the detection of endometriosis. *Fertil Steril*, 79, 1078-85.

- Sutton, C. J., Ewen, S. P., Whitelaw, N. & Haines, P. (1994) Prospective, randomized, double-blind, controlled trial of laser laparoscopy in the treatment of pelvic pain associated with minimal, mild, and moderate endometriosis. *Fertil Steril*, 62, 696-700.
- Sutton, C. J., Pooley, A. S., Ewen, S. P. & Haines, P. (1997) Follow-up report on a randomized controlled trial of laser laparoscopy in the treatment of pelvic pain associated with minimal to moderate endometriosis. *Fertil Steril*, 68, 1070-4.
- Tuttles, F., Keckstein, J., Ulrich, U., Possover, M., Schweppe, K. W., Wustlich, M., Buchweitz, O., Greb, R., Kandolf, O., Mangold, R., Masetti, W., Neis, K., Rauter, G., Reeka, N., Richter, O., Schindler, A. E., Sillem, M., Terruhn, V. & Tinneberg, H. R. (2005) [ENZIAN-score, a classification of deep infiltrating endometriosis]. *Zentralbl Gynakol*, 127, 275-81.
- Tytherleigh, M. G., Fell, R. & Gordon, A. (2004) Diagnostic conscious pain mapping using laparoscopy under local anaesthetic and sedation in general surgical patients. *Surgeon*, 2, 157-60.
- Vercellini, P., Crosignani, P. G., Abbiati, A., Somigliana, E., Vigano, P. & Fedele, L. (2009) The effect of surgery for symptomatic endometriosis: the other side of the story. *Hum Reprod Update*, 15, 177-88.
- Vercellini, P., Fedele, L., Aimi, G., De Giorgi, O., Consonni, D. & Crosignani, P. G. (2006a) Reproductive performance, pain recurrence and disease relapse after conservative surgical treatment for endometriosis: the predictive value of the current classification system. *Hum Reprod*, 21, 2679-85.
- Vercellini, P., Fedele, L., Pietropaolo, G., Frontino, G., Somigliana, E. & Crosignani, P. G. (2003) Progestogens for endometriosis: forward to the past. *Hum Reprod Update*, 9, 387-96.
- Wardle, P. G., Mitchell, J. D., Mclaughlin, E. A., Ray, B. D., Mcdermott, A. & Hull, M. G. (1985) Endometriosis and ovulatory disorder: reduced fertilisation in vitro compared with tubal and unexplained infertility. *Lancet*, 2, 236-9.
- Wicks, M. J. & Larson, C. P. (1949) Histologic criteria for evaluating endometriosis. *Northwest Med*, 48, 611-3.
- Wykes, C. B., Clark, T. J. & Khan, K. S. (2004a) Accuracy of laparoscopy in the diagnosis of endometriosis: a systematic quantitative review. *Bjog*, 111, 1204-12.
- Yoshida, S., Harada, T., Iwabe, T. & Terakawa, N. (2002) Laparoscopic surgery for the management of ovarian endometrioma. *Gynecol Obstet Invest*, 54 Suppl 1, 24-7; discussion 27-9.
- Zanetti-Dallenbach, R., Bartley, J., Muller, C., Schneider, A. & Kohler, C. (2008) Combined vaginal-laparoscopic-abdominal approach for the surgical treatment of rectovaginal endometriosis with bowel resection: a comparison of this new technique with various established approaches by laparoscopy and laparotomy. *Surg Endosc*, 22, 995-1001.
- Zrubek, H., Sikorski, M., Nasser, M., Stachowicz, N. & Chil, A. (1999a) [Endometriosis in adolescents and young women. Can we afford to delay the diagnosis?]. *Ginekol Pol*, 70, 264-9.

Zullo, F., Palomba, S., Zupi, E., Russo, T., Morelli, M., Sena, T., Pellicano, M. & Mastrantonio, P. (2004) Long-term effectiveness of presacral neurectomy for the treatment of severe dysmenorrhea due to endometriosis. *J Am Assoc Gynecol Laparosc*, 11, 23-8.

IntechOpen

IntechOpen



Advanced Gynecologic Endoscopy

Edited by Dr. Atef Darwish

ISBN 978-953-307-348-4

Hard cover, 332 pages

Publisher InTech

Published online 23, August, 2011

Published in print edition August, 2011

The main purpose of this book is to address some important issues related to gynecologic laparoscopy. Since the early breakthroughs by its pioneers, laparoscopic gynecologic surgery has gained popularity due to developments in illumination and instrumentation that led to the emergence of laparoscopy in the late 1980's as a credible diagnostic as well as therapeutic intervention. This book is unique in that it will review common, useful information about certain laparoscopic procedures, including technique and instruments, and then discuss common difficulties faced during each operation. We also discuss the uncommon and occasionally even anecdotal cases and the safest ways to deal with them. We are honored to have had a group of world experts in laparoscopic gynecologic surgery valuably contribute to our book.

How to reference

In order to correctly reference this scholarly work, feel free to copy and paste the following:

Moamar Al-Jefout (2011). Laparoscopy for Diagnosis and Treatment of Endometriosis, *Advanced Gynecologic Endoscopy*, Dr. Atef Darwish (Ed.), ISBN: 978-953-307-348-4, InTech, Available from:
<http://www.intechopen.com/books/advanced-gynecologic-endoscopy/laparoscopy-for-diagnosis-and-treatment-of-endometriosis>

INTECH
open science | open minds

InTech Europe

University Campus STeP Ri
Slavka Krautzeka 83/A
51000 Rijeka, Croatia
Phone: +385 (51) 770 447
Fax: +385 (51) 686 166
www.intechopen.com

InTech China

Unit 405, Office Block, Hotel Equatorial Shanghai
No.65, Yan An Road (West), Shanghai, 200040, China
中国上海市延安西路65号上海国际贵都大饭店办公楼405单元
Phone: +86-21-62489820
Fax: +86-21-62489821

© 2011 The Author(s). Licensee IntechOpen. This chapter is distributed under the terms of the [Creative Commons Attribution-NonCommercial-ShareAlike-3.0 License](#), which permits use, distribution and reproduction for non-commercial purposes, provided the original is properly cited and derivative works building on this content are distributed under the same license.

IntechOpen

IntechOpen