

We are IntechOpen, the world's leading publisher of Open Access books Built by scientists, for scientists

4,800

Open access books available

122,000

International authors and editors

135M

Downloads

Our authors are among the

154

Countries delivered to

TOP 1%

most cited scientists

12.2%

Contributors from top 500 universities



WEB OF SCIENCE™

Selection of our books indexed in the Book Citation Index
in Web of Science™ Core Collection (BKCI)

Interested in publishing with us?
Contact book.department@intechopen.com

Numbers displayed above are based on latest data collected.

For more information visit www.intechopen.com



The Role of Laparoscopy and Salpingoscopy in the Assessment of the Fallopian Tube

Koji Nakagawa, Masato Inoue and Rikikazu Sugiyama
*Division of Reproductive Medicine, Sugiyama Clinic,
Ohara, Setagaya, Tokyo,
Japan*

1. Introduction

In the field of gynecology, infertility treatment in particular, laparoscopy continues to be the gold standard for the evaluation of mechanical factors affecting the fallopian tubes. However, it cannot be used to directly observe the inner cavity of the fallopian tube. The fallopian tube is more than a passive conduit for gametes and early embryos; it also plays an important role in many reproductive functions such as sperm transport and capacitation, oocyte retrieval and transport, fertilization, and embryo storage. However, there are no reports that relate pregnancy outcomes to conditions inside the fallopian tube. It is, therefore, very important to evaluate the conditions both inside and outside of the fallopian tube.

The fallopian tube is easily damaged by an ascending vaginal infection, or by a uterine infection such as Chlamydia. These types of damage result in impaired fallopian tube function, and subsequently cause mechanical factors that contribute to female subfertility (Mol et al., 1997). Hysterosalpingography (HSG) is the most common test used to evaluate the fallopian tube, due to its safety and low cost. Papaioannou et al. stated that HSG is a reliable test for the diagnosis of proximal and distal obstruction, hydrosalpix and peritubal adhesions (Papaioannou et al., 2007). A recent report indicated that laparoscopy was mandatory after abnormal HSG results in the work-up prior to the start of the infertility treatment (Tanahatue, 2008), but it cannot be used to directly observe the inner cavity of the fallopian tube.

Salpingoscopy was originally performed during laparotomy for reconstructive tubal surgery to assess the mucosa of the infundibulum and ampulla. A flexible bronchoscope was initially used to improve the images obtained before the introduction of a dedicated, rigid salpingoscope (Papaioannou et al., 2007). Indeed, many clinicians performed salpingoscopy more than a decade ago, and reported abnormal results inside the fallopian tubes (Puttemans et al., 1987; Heylen et al., 1995; Surry & Surry, 1996; Marana et al., 1999; 2003; Marchino et al., 2001). They mainly focused on infertile patients with hydrosalpinges. They performed salpingoscopy during a laparoscopic procedure to repair hydrosalpinges and release patients' tubes from them. One report described normal and abnormal mucosal folds inside fallopian tubes that were damaged by hydrosalpinges (Puttemans et al., 1987). Several reports mentioned results from inside fallopian tubes, but they only described the conditions inside of the fallopian tubes. Salpingoscopy requires special equipment and expertise, making it an expensive proposition. Its risk profile is comparable to laparoscopy, since it is performed simultaneously.

Marhino et al. reported that the prediction of infertility outcomes by laparoscopy could be improved by the concomitant performance of salpingoscopy (Marhino et al., 2001). However, there is no information concerning the accuracy, reliability, prognosis or effectiveness of the procedure. Several studies have reported pregnancy rates after laparoscopy for patients with infertility of unexplained etiology (Cundiff et al. 1995; Nakagawa et al., 2007). However, there are no reports that relate pregnancy outcomes to significant results found inside the fallopian tube. The fertilization between oocyte and sperm is thought to occur at the ampulla of the fallopian tube, and therefore conditions inside of the ampulla are very important. From this point of view, observations from inside the ampulla might be used to predict pregnancy potential.

Assisted reproductive technology (ART) has become a mainstream infertility treatment, but do all patients who received ART treatment need it? It is believed that a significant number of the patients who receive ART treatment have no need for it, but existing infertility screening examination place limitations on the selection of patients who do not need to receive ART treatment, because no examination to evaluate the fallopian tube without HSG is done. Therefore, a new index for evaluation of the fallopian tube is proposed here. In this chapter, the performance of both laparoscopy and salpingoscopy for evaluation of the pelvic cavity and fallopian tube is discussed, with particular attention to the following points: [i] evaluation of the pelvic cavity; [ii] development of a new score for evaluation of the inside of the fallopian tubes (fallopian tube score; F score); and, [iii] the relationship between the F score and pregnancy outcome.

2. Laparoscopy and salpingoscopy

2.1 Procedure for laparoscopy and salpingoscopy

Laparoscopy was performed under general anesthesia. A three-port laparoscopy was used with a 3 mm umbilical port for the scope and two additional 3-mm operating ports. A 3 mm laparoscope was inserted through an umbilical port and connected to a video monitor (Karl-Storz, Germany). Pneumoperitoneum was established (8-10mmHg). Observation within the pelvic cavity, and complete adhesiolysis and mobilization of the tubes and ovaries was performed if necessary. Tubal patency was checked with indigocarmine. In addition to patency testing, the gross external appearance of the fallopian tube and fimbrial mucosa were assessed with this procedure as well as the presence of peritubal adhesions, pelvic adhesions or lesions of endometriosis, such as bluish spots or red spots. With abnormal results, adhesiolysis, electroablation or resection of endometriotic implants was undertaken to the extent possible. Periadnexal adhesions are one of the main causes of tubal infertility and have a negative impact on the ability to achieve pregnancy. Adhesiolysis and mobilization of the tubes and ovaries, which eliminated effects such as peritubal or salpingo-ovario adhesions, was performed if necessary to evaluate the correlation between salpingoscopic results and their relationship to reproductive outcomes.

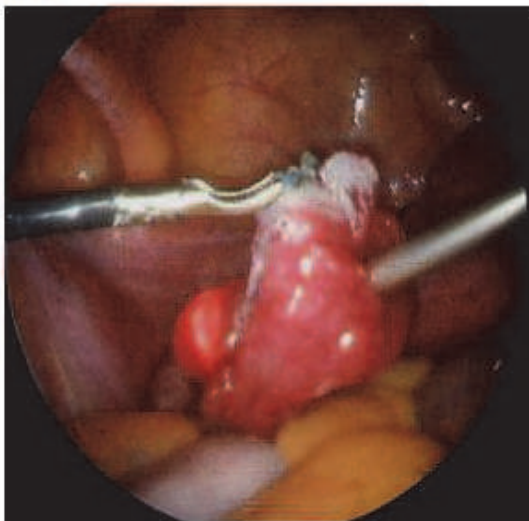
After checking the patency of the bilateral tubes, a 2.9 mm salpingoscope (Karl-Storz, Germany, Fig 1) was inserted through the right port under observational laparoscopy through the umbilical port, and the inner cavity of the fallopian tube was checked. It is particularly worth nothing that two endoscopes were used concurrently for laparoscopy and salpingoscopy, because it is quite difficult to insert a salpingosope into a fallopian tube with no other observation. An atraumatic grasping forceps was applied just behind the

fimbriae to hold the tubal wall against the salpingoscope (Fig 2-a), while an infusion of distending saline water was instilled to open up the potential space of the tubal lumen (Nakagawa et al., 2010). A salpingoscope can observe mainly the ampullary portion of the fallopian tube (Fig 2-b).



Fig. 1. This rigid scope was used as a salpingoscope (Karl-Storz, Germany). The diameter was 2.9mm, and maximum magnification was $\times 60$.

(a)



(b)

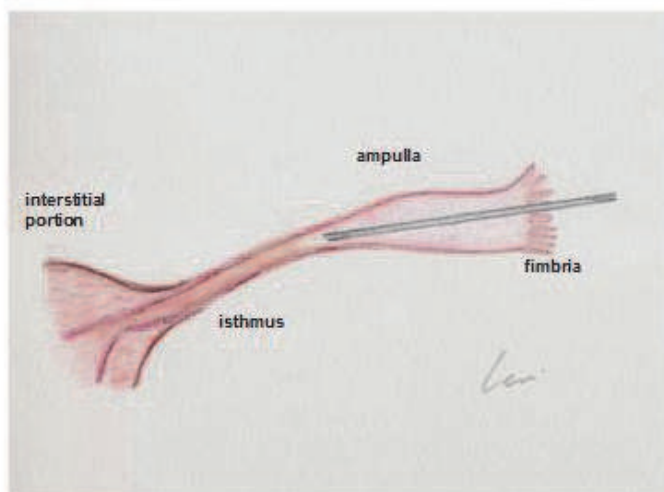


Fig. 2. (a) An atraumatic grasping forceps was applied just behind the fimbriae to hold the tubal wall against the salpingoscope. (b) The salpingoscope can observe mainly the ampullary portion of the fallopian tube.

2.2 Assessment of salpingoscopy

We observed both the right and left tubal lumens with the salpingoscope, paying particular attention to the following six abnormal results: i) adhesions, ii) loss of mucosal folds, iii) rounded edges of mucosal folds, iv) debris, v) foreign bodies, and vi) abnormal vessels.

We used an original classification system for the salpingoscopic results, based on Puttemans' classification (Puttemans et al., 1987). The mucosa of the ampullary segment in normal cases consisted of three to five major folds with secondary folds arising from them, and several minor folds interspaced among them. Examples of normal mucosa are shown in Figure 3-a, and various abnormal results are shown in figure 3-b through 3-g. 'Adhesions' indicated adhesions and/or agglutinations between folds (Fig 3-b). 'Loss of mucosal folds' indicated

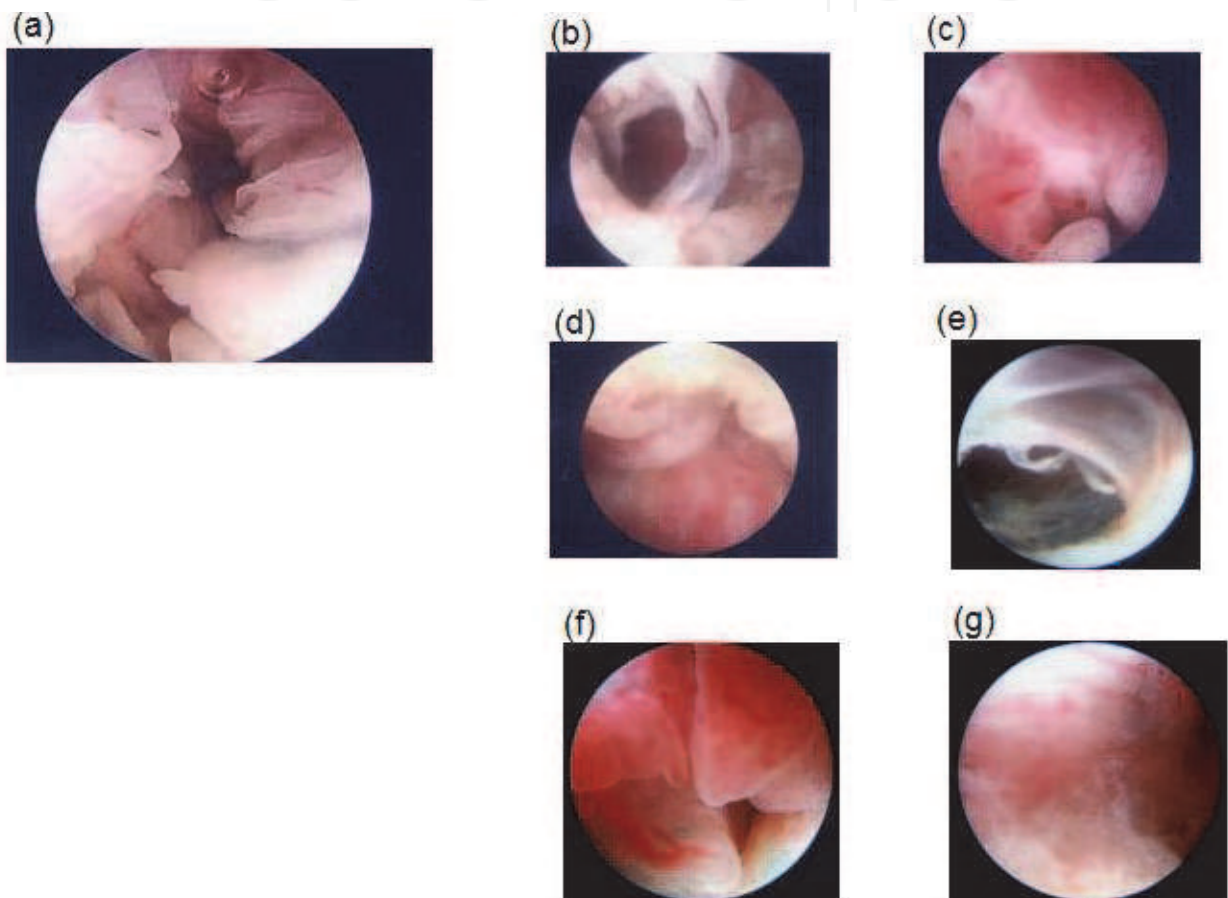


Fig. 3. Normal and abnormal results inside the fallopian tubes detected with the salpingoscope. (a) The mucosa of the ampullary segment in normal cases consisted of 3 to 5 major folds with secondary folds arising from them and several minor folds interspaced among them, and examples of normal mucosa are shown in this figure. (b) 'Adhesions' indicated adhesions and/or agglutinations between folds. (c) 'Loss of mucosal folds' indicated disseminated fold flat areas or a loss of the fold pattern of flattening folds. (d) 'Rounded edges of mucosal folds' indicated the disappearance of the secondary folds. (e) 'Debris' indicated mucus plugs, which were revealed by previous histological examination to consist of a cast of debris containing aggregates of histiocytic-like cells of an endometrial stromal or mesothelial origin. (f) 'Foreign bodies' consisted of oily contrast agents that were used for HSG. (g) 'Abnormal vessels' indicated irregularities of blood vessel diameter.

disseminated fold flat areas or a loss of the fold pattern of flattening folds (Fig 3-c). 'Rounded edges of mucosal folds' indicated the disappearance of the secondary folds (Fig 3-d). 'Debris' indicated mucus plugs, which were revealed by previous histological examination to consist of a cast of debris containing aggregates of histiocytic-like cells of an endometrial stromal or mesothelial origin (Kerin et al., 1991) (Fig 3-e). 'Foreign bodies' consisted of oily contrast agents used for HSG (Fig 3-f). 'Abnormal vessels' indicated irregularities of blood vessel diameters (Fig 3-g).

2.3 F score (fallopian tube score)

After salpingoscopy the F score was calculated which was an original score used to evaluate the tubal lumen, expressed as the sum of the abnormal results listed above. Each abnormal result was given one point with a maximum F score of 12 points.

3. Relationship between the F scores and unexplained infertility patients

3.1 Unexplained infertility patients

In the present study unexplained infertility was diagnosed using the following criteria: a) the period of infertility was more than one year; b) the patient's normal menstrual cycle and ovulation was investigated by transvaginal ultrasonography, by estimation of serum progesterone concentrations in the mid-luteal phase; c) the patient showed normal results for genital organs by ultrasonography, and the patency of at least one fallopian tube was confirmed by HSG; d) the patient showed normal values in several hormone analyses (LH, FSH, PRL, E2, P); e) the patient's male partner had normal sperm results (WHO, 1992), and the post-coital test (PCT) was normal; and f) the patient did not achieve pregnancy after more than 6 courses of timed intercourse or intrauterine insemination (IUI). Patients who showed unilateral or bilateral hydrosalpinges or tubal obstruction were excluded, as were patients who had ovarian endometrioma(s) in either ovary. The sera of all patients were checked for anti-chlamydial antibodies before laparoscopy. A total of 227 infertile women who were diagnosed with unexplained infertility and underwent both laparoscopy and salpingoscopy at this clinic were recruited from April 2008 through October 2010 for the present study.

After receiving laparoscopy and salpingoscopy, the patients started infertility treatment as soon as possible, using timed intercourse or intrauterine insemination (IUI). Patients who were in need of ART treatment due to tubal damage were excluded from this evaluation. The patients recruited for the present study were diagnosed with unexplained infertility, and their tubal patency was confirmed by HSG prior to operation. Patients who showed uni- or bilateral hydrosalpinges or tubal obstruction and were in need of ART treatment were excluded from this evaluation, in order to focus on evaluation of the correlation between the salpingoscopic results and the reproductive outcomes. Clinical pregnancy was defined as the development of a gestational sac, as determined by transvaginal ultrasonography after ovulation. The relationship between the F scores and various clinical results and pregnancy rates was analyzed. Data were recorded as the mean \pm S.D. or mean \pm S.E.M, and were analyzed statistically using the chi-square test. $P < 0.05$ was considered to be statistically significant.

3.2 Patient backgrounds

The backgrounds of the patients who underwent both laparoscopy and salpingostomy due to unexplained infertility are summarized in Table 1. The average age of the patients was

33.8 ± 0.3 years, and the mean duration of infertility was 38.6 ± 0.9 months. The percentage of nullipara was 70.8%, the percentage of patients with positive chlamydial antibodies was 26.4%, and the percentage who showed abnormal HSG results such as peritubal adhesions was 28.9% (table 2 & 3).

3.3 Distribution of F scores

The average F score was 0.9 ± 0.1 , and they ranged from 0 to 7. The distribution of the F scores is shown in Figure 4. Slightly more than half (50.7%) of the patients received an F score of 0, and the percentages of patients who received 1, 2, 3 and 4 or more points were 17.2%, 13.2%, 5.3% and 12.8%, respectively.

Number of patients	227
Average age (years)*	33.8 ± 0.2
Duration of infertility (months)*	38.6 ± 0.9
Percentage of nullipara (%)	70.8
Percentage of patients with positive chlamydial antibodies (%)	26.4
Percentage of patients with abnormal HSG (%)	28.9

*mean \pm S.E.M

Table 1. Backgrounds of patients who received laparoscopy and salpingoscopy due to unexplained infertility.

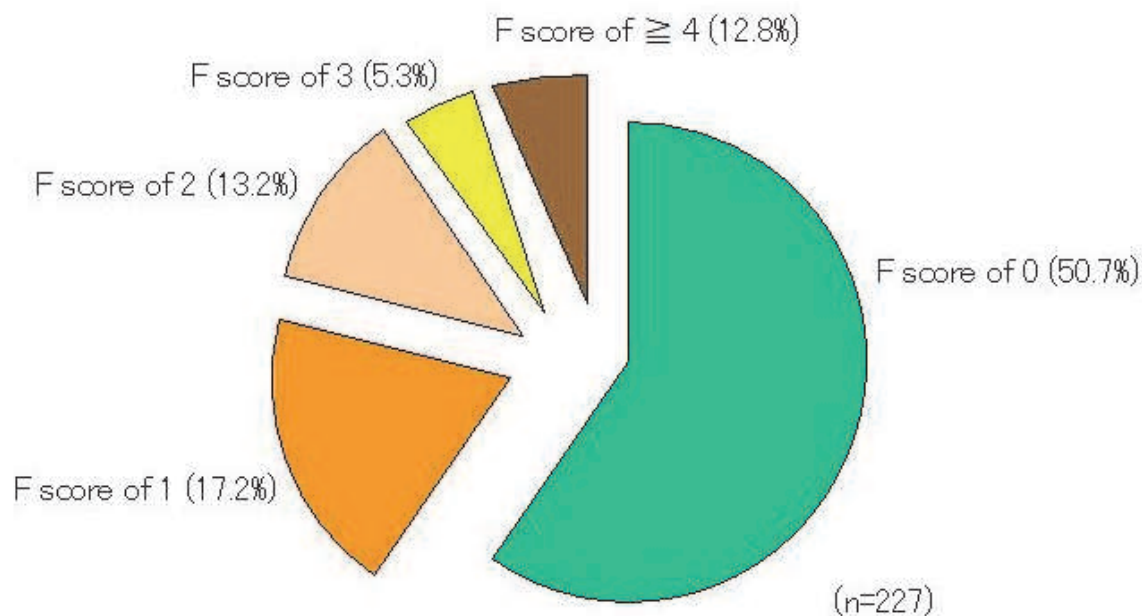


Fig. 4. The distribution of F score is shown in Figure 4. About half (50.7%) of the patients received an F score of 0, and the percentages of patients who received 1, 2, 3 and 4 or more points were 17.2%, 13.2%, 5.3% and 12.8%, respectively.

3.4 Relationship between the F scores and various clinical findings

The average F score of nullipara patients was 1.0 ± 0.2 . This was somewhat higher than the scores of patients who had a history of pregnancy (0.5 ± 0.2), but the difference was not

statistically significant (Table 2). The average F score of patients with an abnormal HSG was similar to that of patients with normal HSG results (1.2 ± 0.4 and 0.8 ± 0.2 , respectively; as shown in table 3). However, the average F score for patients who tested positive for chlamydial antibodies was 1.7 ± 0.4 , which was significantly higher than that of patients who tested negative (0.6 ± 0.1 , $p=0.0003$; table 4).

	Pregnancy history		P value
	No gravidity	Pregnant before	
F score	1.0 ± 0.2	0.5 ± 0.2	0.0945

Table 2. The relationship between pregnancy history and F score

	HSG		P value
	normal	abnormal resultss	
F score	0.8 ± 0.2	1.2 ± 0.4	0.3287

HSG: hysterosalpingography

Table 3. The relationship between HSG results and F score

	Chlamydial antibodies		P value
	positive	negative	
F score	1.7 ± 0.4	0.6 ± 0.1	0.0003

Table 4. The relationship between chlamydial antibodies and F score

3.5 Relationship between F scores and pregnancy rates

After evaluation, all patients ($n=227$) began infertility treatment, and after salpingoscopic evaluation none were in need of ART treatment due to tubal damage. Within a year using either timed intercourse or artificial insemination with the husband's semen, 71 patients achieved pregnancy. The mean duration before achievement of pregnancy after surgery was 111.1 ± 1.2 days. The pregnancy rates of patients with F scores of 0, 1, 2, 3 and 4 or more were 35.9% (42/115), 33.3% (13/39), 33.3% (10/30), 16.7% (2/12), and 13.8% (4/29), respectively. The pregnancy rates for patients with lower F scores (F score ≤ 2) were significantly higher than the rates for patients with higher F scores (F score ≥ 3) (table 5, $p<0.05$).

F score	Number of patients	Number of pregnant patients	Pregnancy rates (%)	
0	115	42	35.9	
1	39	13	33.3	35.3 ^a
2	30	10	33.3	
3	12	2	16.7	
≥ 4	29	4	13.8	14.6

a: vs the group with F score ≥ 3

Table 5. The relationship between pregnancy rate and F score.

4. Relationship between F scores and endometriosis-related infertility patients

4.1 Infertility patients with uni- or bilateral endometrioma (s)

From April 2008 through February 2010, there were 94 infertile patients who had unilateral or bilateral endometrioma(s) recruited for the present study. All patients underwent laparoscopic ovarian cystectomy at the clinic. Patients with a history of gynecological operations, other ovarian masses, tubal obstruction or male infertility were excluded from this study. All patients showed regular menstrual cycles, and none of the women received exogenous gonadotropins or clomiphene citrate for ovarian stimulation during the study period. All endometriomas were diagnosed before surgery by magnetic resonance imaging and transvaginal ultrasound. The biaxial diameter of each endometrioma was measured by sonography, and the average was used as the endometrioma size. Informed consent was obtained from all patients and this study was approved by the Institutional Review Board of the Sugiyama Clinic.

An incision was made at the antimesenteric site of the cysts. The cyst was dissected from the ovary by traction and counter traction using a pair of 3 mm atraumatic grasping forceps. Bleeding from the stripped site was stopped by bipolar cauterization of the minimally required area for the shortest possible duration, to avoid thermal damage to the ovarian cortex. None of the operated ovaries were sutured. Tubal patency was checked with indigo carmine. The pelvic cavity was checked for the presence of peritubal and pelvic adhesions and endometriotic lesions, e.g., blue or red spots. Adhesiolysis, electro-ablation, or resection of endometriotic lesions was performed to the extent that these procedures were possible.

After this procedure, salpingoscopic evaluation of the bilateral fallopian tubes was performed as described above. The F scores and several clinical results of these patients (EM group) were compared to those of the unexplained infertility patients who received both laparoscopy and salpingoscopy during the same period (n=133; control group).

4.2 Distribution of F scores among patients with endometrioma(s)

The average F score was 0.3 ± 0.1 , with a range of 0 to 4, and was significantly lower than that of the control group (0.8 ± 0.2 , $p < 0.01$). The distribution of the F scores is shown in Figure 5. About three-fourths (77.6%) of the patients in the EM group received F scores of 0,

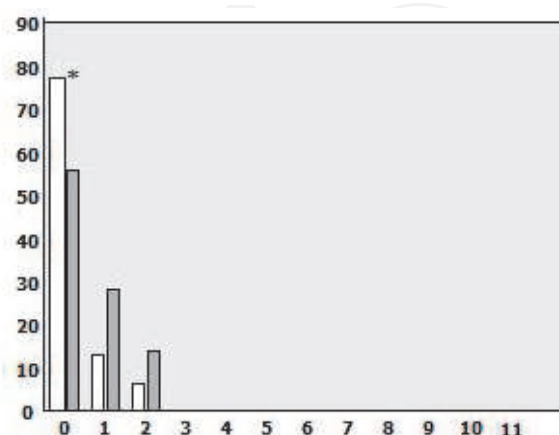


Fig. 5. This figure shows the distribution of F score in the EM group (blank bar) and control groups (dark bar). The percentage of patients with F scores of 0 was significantly lower than in the EM group (77.6%) than in the control group (79/133=59.4%, $*p < 0.05$).

and the percentages of patients who received 1, 2, and 3 or more points were 14.9%, 6.4%, and 1.0%, respectively. The percentage of the patients with F scores of 0 in the EM group was significantly lower than that of the patients in the control group (79/133=59.4%, $p<0.05$).

4.3 Relationship between F scores and pregnancy rates

After laparoscopic cystectomy and salpingoscopy, all patients (n=94) in the EM group began infertility treatment, and 27 patients achieved pregnancy using either timed intercourse or artificial insemination with the husband's semen within 1 year (pregnancy rate= 28.7%). This rate was comparable to that in the control group (46/133=34.6%). In the EM group, the pregnancy rates of patients with F scores of 0, 1, 2 and 3 or more were 21.4% (24/73), 14.9% (3/14), 0% and 0%, respectively. In the control group, the pregnancy rates of patients with F scores of 0, 1, 2 and 3 or more were 36.7% (29/79), 35.7% (10/28), 28.5% (4/14), and 37.5% (3/8), respectively (Table 6). The pregnancy rate of patients with F scores of 0 in the EM group was comparable to that in the control group. However, among the patients with F scores of 1, the pregnancy rate in the EM group was significantly lower than that in the control group ($p<0.05$; Table 6).

F score	EM group	Control	
0	21.4% (24/73)	36.7% (29/79)	n.s.
1	14.9% (3/14)	35.7% (10/28)	P<0.05
2	0	28.5% (4/14)	n.s.
≥3	0	37.5% (3/8)	n.s.

Table 6. The relationship between pregnancy rates and F scores

Based on these results, it is highly possible that infertility patients with ovarian endometrioma are more likely to have intact fallopian tubes, compared to infertility patients without ovarian endometrioma. Therefore, ovarian endometrioma itself could be one of the main causes of endometriosis-related infertility, and if these patients have abnormal results inside their fallopian tubes, they should receive ART treatment instead of conventional treatment.

5. Relationship between F scores and hydrosalpinges

5.1 Infertility patients with hydrosalpinges and reconstructive surgery

From April 2008 through February 2010, 38 infertile patients with a diagnosis of uni- or bilateral hydrosalpinges were examined by salpingoscopy at the time of reconstructive surgery under laparoscopy. The translaparoscopic salpingoscopy procedure described above was used. Following mobilization of the hydrosalpinx, the tube was opened by a small incision at the site where the scar of the occlusion could be identified. When intact fimbria was confirmed, it was inverted to the outside to prevent it from closing inside, and stitched with thin thread. Bleeding was controlled by endothermic coagulation. A 2.9-mm salpingoscope was used.

After this procedure, salpingoscopic evaluation of the bilateral fallopian tubes was performed as described above. The F scores and several clinical results of these patients (hydro-s group) were compared to those of the patients with unexplained infertility who received both laparoscopy and salpingoscopy during the same period (n=133; control group).

5.2 Distribution of F scores among patients with hydrosalpinges

The average F score was 3.4 ± 0.4 , with a range of 0 to 10, and this average was significantly higher than that of the control group (0.8 ± 0.2 , $p < 0.01$). The distribution of F scores is shown in Figure 6. Only about one-fifth (21.1%) of the patients in the hydro-s group received an F score of 0, and the percentages of patients who showed 1, 2, 3, 4, and 5 or more points were 13.2%, 7.9%, 13.2%, 13.2%, and 31.4%, respectively. The percentage of patients with F scores of 0 was significantly higher in the hydro-s group than in the control group ($79/133=59.4\%$, $p < 0.05$). Surprisingly, about one-third of the patients in the hydro-s group received a high F score.

5.3 Relationship between the F scores and pregnancy rates

After laparoscopic reconstructive surgery for hydrosalpinges and salpingoscopy, all patients ($n=38$) in the hydro-s group began infertility treatment, but only 6 patients achieved pregnancy using either timed intercourse or artificial insemination from the husband's semen within one year (pregnancy rate=15.8%). This rate was significantly lower than that in the control group ($46/133=34.6\%$). The pregnancy rates of patients with F scores of 0, 1, 2, 3, 4, and 5 or more were 12.5% (1/8), 20.0% (1/5), 33.3% (1/3), 20.0% (2/5), 0%, 8.3% (1/12), respectively. In the control group, the rates for patients with F scores of 0, 1, 2, and 3 or more were 36.7% (29/79), 35.7% (10/28), 28.5% (4/14), and 3/8 (37.5%), respectively (Table 7). In the hydro-s group, 4 additional patients achieved pregnancy using ART treatment, and a total of 10 patients achieved pregnancy (pregnancy rate=26.3%). However, in the control group an additional 16 patients achieved pregnancy using ART treatment, and a total of 62 patients achieved pregnancy (pregnancy rate=46.6%).

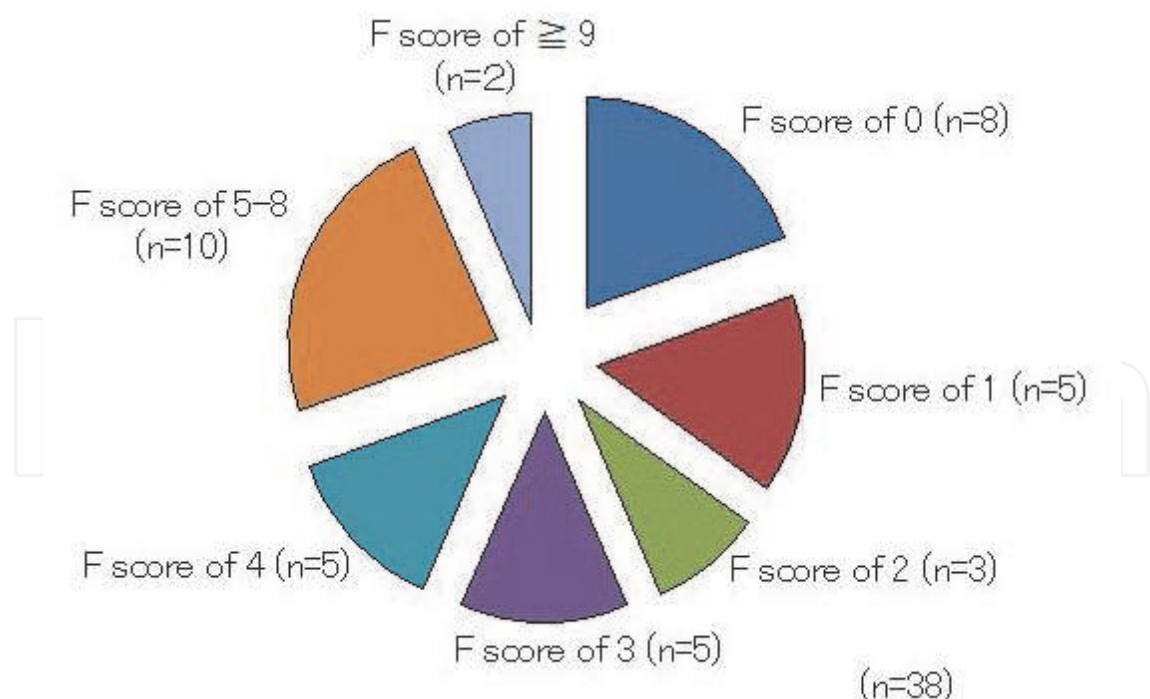


Fig. 6. The distribution of the F scores of patients with hydrosalpinges is shown in Figure 6. About one fifth (21.1%) of the patients received an F score of 0, and the percentages of patients who received 1, 2, 3, 4, and 5 or more points were 13.2%, 7.9%, 13.2%, 13.2% and 31.4%, respectively.

F score	Hydro-s group	Control	
0	12.5% (1/8)	36.7% (29/79)	n.s.
1	20.0% (1/5)	35.7% (10/28)	n.s.
2	33.3% (1/3)	28.5% (4/14)	n.s.
≥3	13.6% (3/22)	37.5% (3/8)	n.s.

Table 7. The relationship between pregnancy rates and F scores

6. Conclusions

Predictions of fertility outcome by laparoscopy can be improved by the concomitant performance of salpingoscopy (Marchino et al., 2001). The two tests probably complement rather than substitute for one another. Salpingoscopy was the first tubal assessment test that to disclose a new world of detailed *in-vivo* images of the actual site of human fertilization. It can clearly demonstrate the presence or absence of anatomical distortions, especially adhesions between, and destruction of, mucosal folds on a micro-endoscopic, i.e. mucosal, level. The proponents of Salpingoscopy argue that it could, and should, direct the infertility investigation and treatment care pathway towards either reconstructive surgery or ART. Lesions of the infundibulum and ampullary segment have been detected in patients with apparently normal tubes upon HSG and laparoscopy (Puttemans et al., 1987).


However, although the presence of ampullary mucosal adhesions has been reported to negatively affect fertility and increase the risk of ectopic pregnancy, mucosal adhesions are not incompatible with normal fertility (Maguiness & Djahanbakhch., 1992) and, unless the damage is severe, there is a poor correlation with histological assessment (Hershlag et al., 1991). Therefore, not enough is known about these lesions, and salpingoscopy remains a research tool.

Essential phenomena of the beginning of life, such as the meeting of between male and female gametes, fertilization, and development, occur inside the fallopian tube. Although in this era ART is the most popular infertility treatment, it is very important and meaningful to focus attention on the results found inside the fallopian tube. According to the data reported here, most of the patients who showed no abnormal results in their pelvic cavity and adnexa could not get pregnant by timed intercourse or IUI when they received high F scores. However, the patients who had no significant results in the fallopian tubes even if significant results were found in the pelvic cavity such as ovarian endometrioma or hydrosalpinges, could expect to achieve pregnancy without using ART treatment. These results indicate that it is very important to focus on conditions inside the fallopian tubes, and the F score might be useful for prediction of the prognosis of infertility treatments and for treatment selection decisions.

7. References

- Cundiff, G.; Carr, BR. & Marshburn, PB. (1995) Infertile couples with a normal hysterosalpingogram. Reproductive outcome and its relationship to clinical and laparoscopic findings. *Journal of Reproductive Medicine*, vol. 40, 19-24.
- Hershlag, A.; Seifer, DB.; Carcangiu, ML.; Patton, DL.; Diamond, MP. & DeCherney, AH. (1991) Salpingoscopy: light microscope and electron microscopic correlations. *Obstetrics and Gynecology*, vol. 77, 399-405.

- Heylen, SM.; Brosens, IA. & Puttemans, PJ. (1995) Clinical value and cumulative pregnancy rates following rigid salpingoscopy during laparoscopy for infertility. *Human Reproduction*, vol. 10, 2913-2916.
- Kerin, JF.; Surry, ES.; William, DB.; Daykhovsky, L. & Grundfest, WS. (1991) Falloscopic observations of endotubal mucus plugs as a cause of reversible obstruction and their histological characterization. *Journal of Laparoendoscopic Surgery*, vol. 1, 103-110.
- Maguiness, SD. & Djahanbakhch, O. (1992) Salpingoscopic findings in women undergoing sterilization. *Humun Reproduction*; vol. 7, 269-273.
- Marana, R.; Catalano, GF.; Muzii, L. & Mancuso, S. (1999) The prognostic role of salpingoscopy in laparoscopic tubal surgery. *Human Reproduction*, vol. 14, 2991-2995
- Marhino, GL.; Gigante, V.; Gennarelli, G.; Mazza, O. & Mencaglia, L. (2001) Salpingoscopy and laparoscopic investigations in relation to fertility outcome. *Journal of the American Association of Gynecological Laparoscopists*, vol.8, 218-221.
- Marana, R.; Catalano, GF. & Muzii, L. (2003) Salpingoscopy. *Current Opinion of Obstetrics and Gynecology*, vol. 13, 333-336.
- Mol, BW.; Dijkman, B.; Wertheim, P.; Lijmer, J.; van der Veen, F. & Bossuyt, PM. (1997) The accuracy of serum chlamydial antibodies in the diagnosis of tubal pathology: a meta-analysis. *Fertility and Sterility*, vol. 67,1031-1037.
- Nakagawa, K.; Ohgi, S.; Horikawa, T.; Kojima, R.; Ito, M. & Saito, H. (2007) Laparoscopy should be strongly considered for examining women with unexplained infertility. *Journal of Obstetrics and Gynecology Research*, vol.33, 665-670.
- Nakagawa, K.; Inoue, M.; Nishi, Y.; Sugiyama, R.; Motoyama, K.; Kuribayashi, Y.; Akira, S. & Sugiyama, R. (2010). A new evaluation score that uses salpingoscopy to reflect fallopian tube function in infertile women. *Fertility and Sterility*, vol. 94, 2753-2757.
- Puttemans, P.; Brosens, I. & Delattin, P.; Vasquez, G. & Boeckx, W. (1987) Salpingoscopy versus hysperosalpingography in hydrosalpinges. *Humun Reproduction*, vol. 2, 535-540.
- Papaioannou, S.; Afnan, M. & Jafettas, J. (2007) Tubal assessment tests: still have not found what we are looking for. *Reproductive BioMedical Online*, vol. 15, 376-382.
- Surry, ES. & Surry, MW. (1996) Correlation between salpingoscopic and laparoscopic staging in the assessment if distal fallopian tube. *Fertility and Steriliry*, vol. 65, 267-271.
- Tanahatoo, SJ. (2008) Diagnostin laparoscopy is needed after abnormal hysterosalpingography to prevent over-treatment with IVF. *Reproductive BioMedical Online*, vol.16, 410-415.
- WHO. WHO Laboratory Manual for the Examination of Human Semen and Sperm-Cervical Mucus Interaction. Chembridge University Press. Cambridge, UK. 1992.



Advanced Gynecologic Endoscopy

Edited by Dr. Atef Darwish

ISBN 978-953-307-348-4

Hard cover, 332 pages

Publisher InTech

Published online 23, August, 2011

Published in print edition August, 2011

The main purpose of this book is to address some important issues related to gynecologic laparoscopy. Since the early breakthroughs by its pioneers, laparoscopic gynecologic surgery has gained popularity due to developments in illumination and instrumentation that led to the emergence of laparoscopy in the late 1980's as a credible diagnostic as well as therapeutic intervention. This book is unique in that it will review common, useful information about certain laparoscopic procedures, including technique and instruments, and then discuss common difficulties faced during each operation. We also discuss the uncommon and occasionally even anecdotal cases and the safest ways to deal with them. We are honored to have had a group of world experts in laparoscopic gynecologic surgery valuably contribute to our book.

How to reference

In order to correctly reference this scholarly work, feel free to copy and paste the following:

Koji Nakagawa, Masato Inoue and Rikikazu Sugiyama (2011). The Role of Laparoscopy and Salpingoscopy in the Assessment of the Fallopian Tube, *Advanced Gynecologic Endoscopy*, Dr. Atef Darwish (Ed.), ISBN: 978-953-307-348-4, InTech, Available from: <http://www.intechopen.com/books/advanced-gynecologic-endoscopy/the-role-of-laparoscopy-and-salpingoscopy-in-the-assessment-of-the-fallopian-tube>

INTECH
open science | open minds

InTech Europe

University Campus STeP Ri
Slavka Krautzeka 83/A
51000 Rijeka, Croatia
Phone: +385 (51) 770 447
Fax: +385 (51) 686 166
www.intechopen.com

InTech China

Unit 405, Office Block, Hotel Equatorial Shanghai
No.65, Yan An Road (West), Shanghai, 200040, China
中国上海市延安西路65号上海国际贵都大饭店办公楼405单元
Phone: +86-21-62489820
Fax: +86-21-62489821

© 2011 The Author(s). Licensee IntechOpen. This chapter is distributed under the terms of the [Creative Commons Attribution-NonCommercial-ShareAlike-3.0 License](#), which permits use, distribution and reproduction for non-commercial purposes, provided the original is properly cited and derivative works building on this content are distributed under the same license.

IntechOpen

IntechOpen