

We are IntechOpen, the world's leading publisher of Open Access books Built by scientists, for scientists

4,800

Open access books available

122,000

International authors and editors

135M

Downloads

Our authors are among the

154

Countries delivered to

TOP 1%

most cited scientists

12.2%

Contributors from top 500 universities



WEB OF SCIENCE™

Selection of our books indexed in the Book Citation Index
in Web of Science™ Core Collection (BKCI)

Interested in publishing with us?
Contact book.department@intechopen.com

Numbers displayed above are based on latest data collected.

For more information visit www.intechopen.com



Laparoscopy in Gynecology - How Why When

A.Daniilidis, P.Hatzis, G.Pratilas,
P.D.Loufopoulos and K.Dinas

*University Department Of Obstetrics And Gynecology,
Aristotle University Of Thessaloniki,
Greece*

1. Introduction

Laparoscopy is a surgical procedure that has been used widely in medicine over 30 years. The faster recovery time, the minimizing of pain, hospitalization and the better aesthetic result are some of the advantages which made laparoscopy very popular among patients and surgeons. Also some technical parameters such as the magnification offered by the endoscope during the procedure and the small risk of complications resulted to the wide use of laparoscopic surgery in gynecology. Laparoscopy has gained a leading role and appears to be the gold standard method for a quiet wide range of gynecologic procedures such as tubal ligation, removal of ovarian cyst or adnexa, treatment of ectopic pregnancy, hemorrhagic rupture of a cyst, exploration of chronic pelvic pain, sterility, treatment of endometriosis, removal of fibromyomata , hysterectomy, and lately for treatment of pelvic organ prolapses, urinary incontinence and even in gynecologic cancers. Despite the advantages of laparoscopic procedures, they do not come without risk and complications for the patient. As with laparotomy there is always danger for deep vein thrombosis, inflammation and creation of adhesions. It should be noted though that compared to laparotomy there is a higher risk of injury to the major blood vessels positioned in the pelvis and the urinary system, and that is why patients considered to be subjected to laparoscopy should be carefully chosen.

2. Limitations of laparoscopy

In the case of patient selection previous abdominal surgery is the most common reason to exclude a laparoscopic approach, because of the risk of adhesions. For the same reason, patients that have a medical history of appendicitis , rupture of ectopic pregnancy, rupture of an ovarian cyst, or pelvic inflammatory disease should be selected very carefully. Also morbid obese patients (BMI >45) are in a higher risk group for laparoscopy. This is firstly because of the increased adipose tissue, so initial access to the peritoneal cavity is more difficult and also there is a need for longer trocar ports and instruments, and secondly because obese patient will have greater peak airway pressures and often cannot sustain prolonged Trendelenberg position.

3. Instruments used

As with all laparoscopic procedures the basic tool used is the endoscope-laparoscope. There are many variations in diameter size : 10 mm, 5 mm, and even 2 mm ,and laparoscopes with a 0 or 30 degrees angle of view. Trocars of 5mm and 10mm are usually used in order to gain access and insert instruments into the peritoneal cavity. Veress needle is the preferred method of a lot of surgeons in creating the pneumoperitoneum , but there are also optical-access trocars available for the same task. As with all laparoscopic procedures we use an CO2 endoflator to provide the gas needed to create the pneumoperitoneum and an imaging unit that is generally composed of a light source, a camera head that attaches to the endoscope, it's camera control unit and an display screen. While performing the operation there are a lot of different instruments that can be used (IMAGE 1). Concerning the manipulation of tissue there are different kind of forceps: dissecting and grasping, single or double action, traumatic or atraumatic depending on the design of the distal tip. The same variety can be found in scissors, with them having straight or curved blades, with some of them being also serrated, as well as the hook-like scissors. The next basic set of tools are those used to perform electrosurgery, and they consist of unipolar tools in the shape of needle, hook or spatula shaped electrodes, and of bipolar forceps and scissors. Alternative methods to electrosurgery are the use of laser and ultrasound dissection and coagulation systems. Other tools used are suction and irrigation cannulas, aspiration needles, extraction bags, needle holders for intracorporeal suturing techniques and knot tiers for extracorporeal knotting, uterine manipulators and finally morcellator systems for the removal of large tissue specimens like fibroids or the uterus.




Fig. 1. Instruments for laparoscopy in gynecology

4. Patient preparation, positioning and procedures

In preparation for surgery, bowel preparation is useful as it empties the small intestine, thus facilitating vision and manoeuvrability by flattening the intestinal loops and pushing them out of the way. It must be commented that when the case is associated with an increased risk of intestinal injury, as in endometriosis of the rectovaginal septum or in major adhesiolysis, the bowel preparation must be more complete, similar to that applied prior to major bowel surgery.

Concerning the position of the patient, her arms should be padded and carefully tucked to the side and after the anesthesia and the intubation she is placed in a low lithotomy position (IMAGE 2). The legs are held in position, supported by padded obstetric knee braces or Allen stirrups.

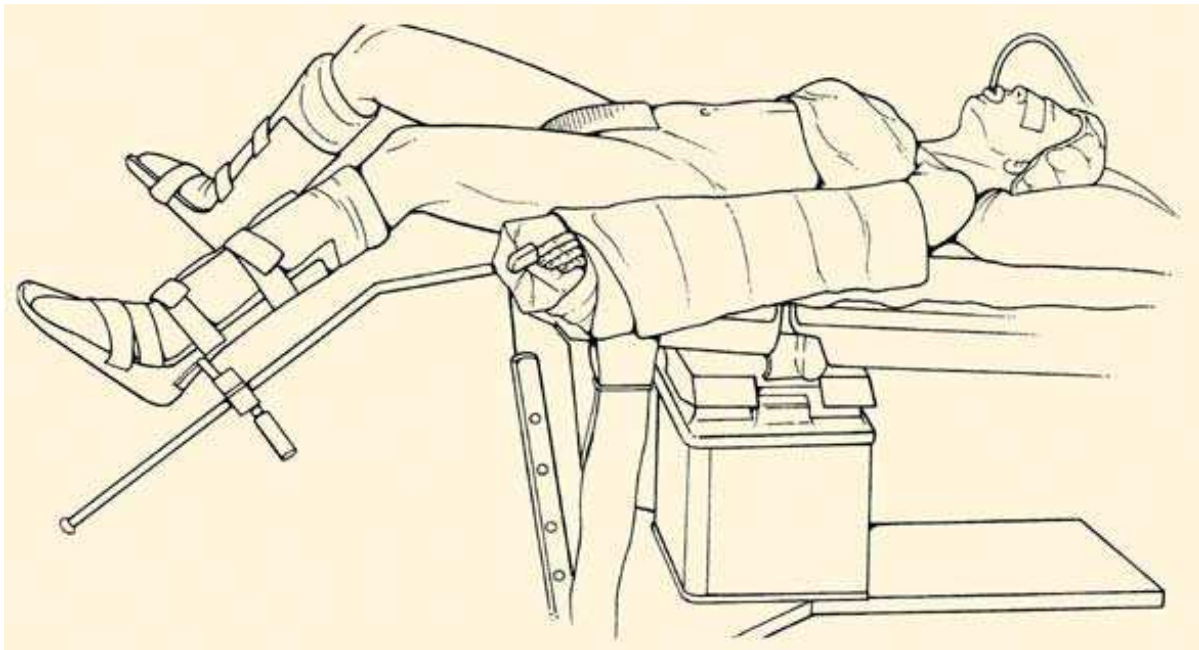


Fig. 2. Position of the patient

Abdominal and vaginal preparation follows, and afterwards a Foley catheter is placed, as is also a uterine manipulator with sterile technique.

The surgeon is placed on the left side of the patient with the first assistant on the right side and the second between the legs to use the manipulator. In cases where the surgeon is left handed he occupies the right side of the patient. The operation begins usually with an intra- or infraumbilical incision from where the Veress needle is inserted creating the pneumoperitoneum. Afterwards the main (10mm) trocar is inserted through the same incision, after removing the Veress needle, and the laparoscope is positioned through it. An alternative is open laparoscopy using a Hasson trocar, and is recommended for patients who have had prior abdominal surgery as it provides safe and easy access to the peritoneal cavity with minimal complications (0.5%). Types of trocars and placement methods are widely variable and are well described in both academic and industry literature. Usually two to three extra trocars (5mm usually or 10mm) are placed for most operative gynaecologic laparoscopic surgeries, two lateral and in some cases one suprapubic (IMAGE 3). The suprapubic port should be placed 3 to 4 cm above the symphysis pubis to avoid bladder injury. The lower

quadrant ports should be placed at the level of the iliac crest lateral to both the rectus muscle and inferior epigastric vessels, which are visible with the laparoscope through the peritoneum.[1]

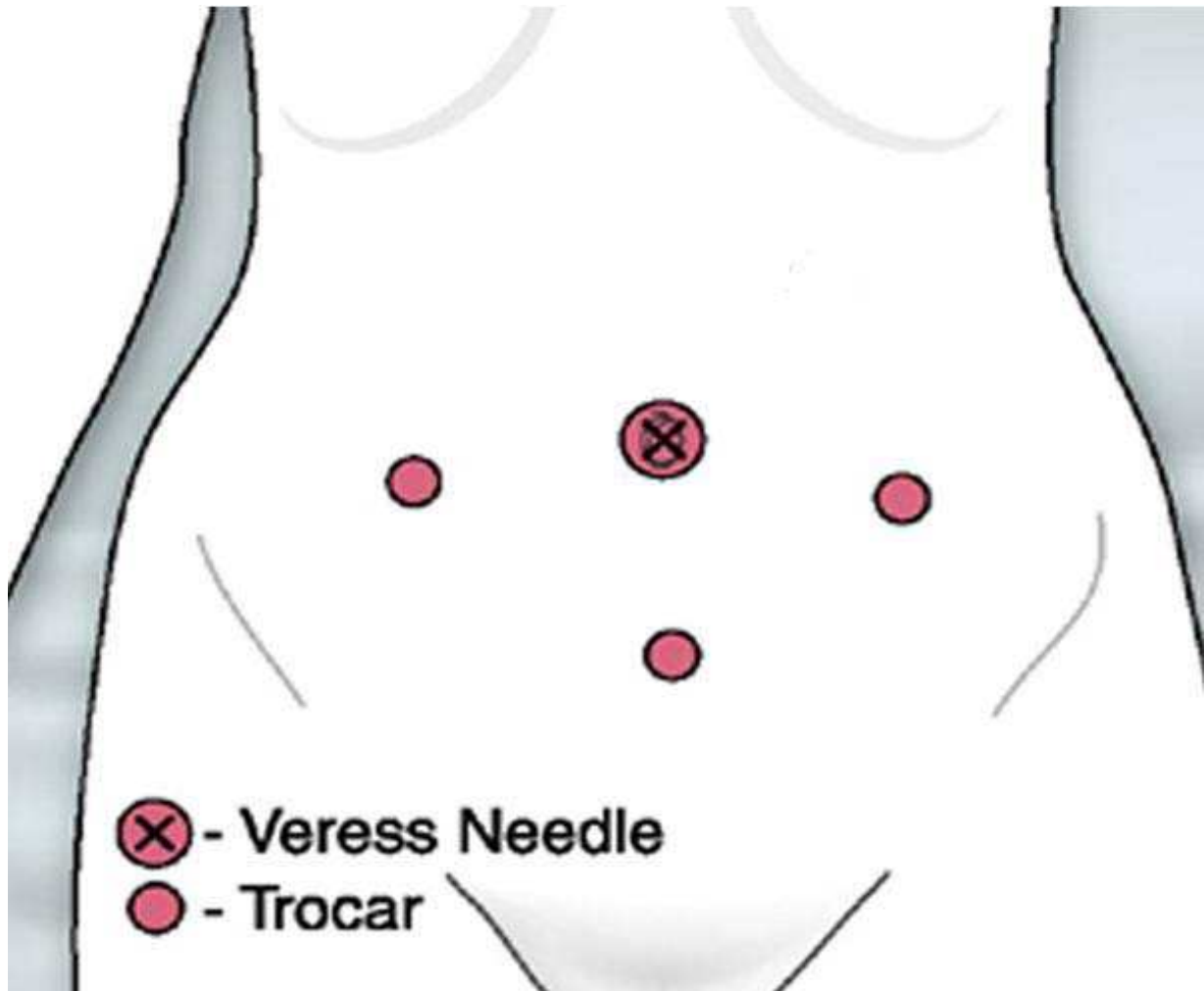


Fig. 3. Position of trocars in gynecologic operations

5. Tubal ligation

Tubal ligation is a popular and reliable method of contraception for women usually over 30 years old who have completed their family (IMAGE 4). The procedure can be executed by creating either one single umbilical port hole, if using an operative laparoscope, or usually by creating two port holes, one umbilical and one suprapubic. The general rules of gynaecological laparoscopic operations apply here also : creation of pneumoperitoneum, use of a manipulator to control the uterus and recognise well the anatomic structures of the adnexa. It is important to accurately recognise the fallopian tube and not to avoid mistaking the round ligament for it. Once recognised there are different methods for ligation : use of bipolar or monopolar current, use of metallic clips or falop ring bands, and resection with the use of sutures to ligate. When complications occur they are most commonly haemorrhage from the fallopian tube or the mesosalpinx, and they rate from 0,1 to 4,6 % . [3-7]. The occurrence of major complications (0,6 %) like vascular injury, bowel perforation

or damage to the genitourinary tract is really rare. It must be commented that depending on the technique used there are different rates of failure with the greater appearing in ligation with bipolar current and the best result when resection is used.[2,3,4]

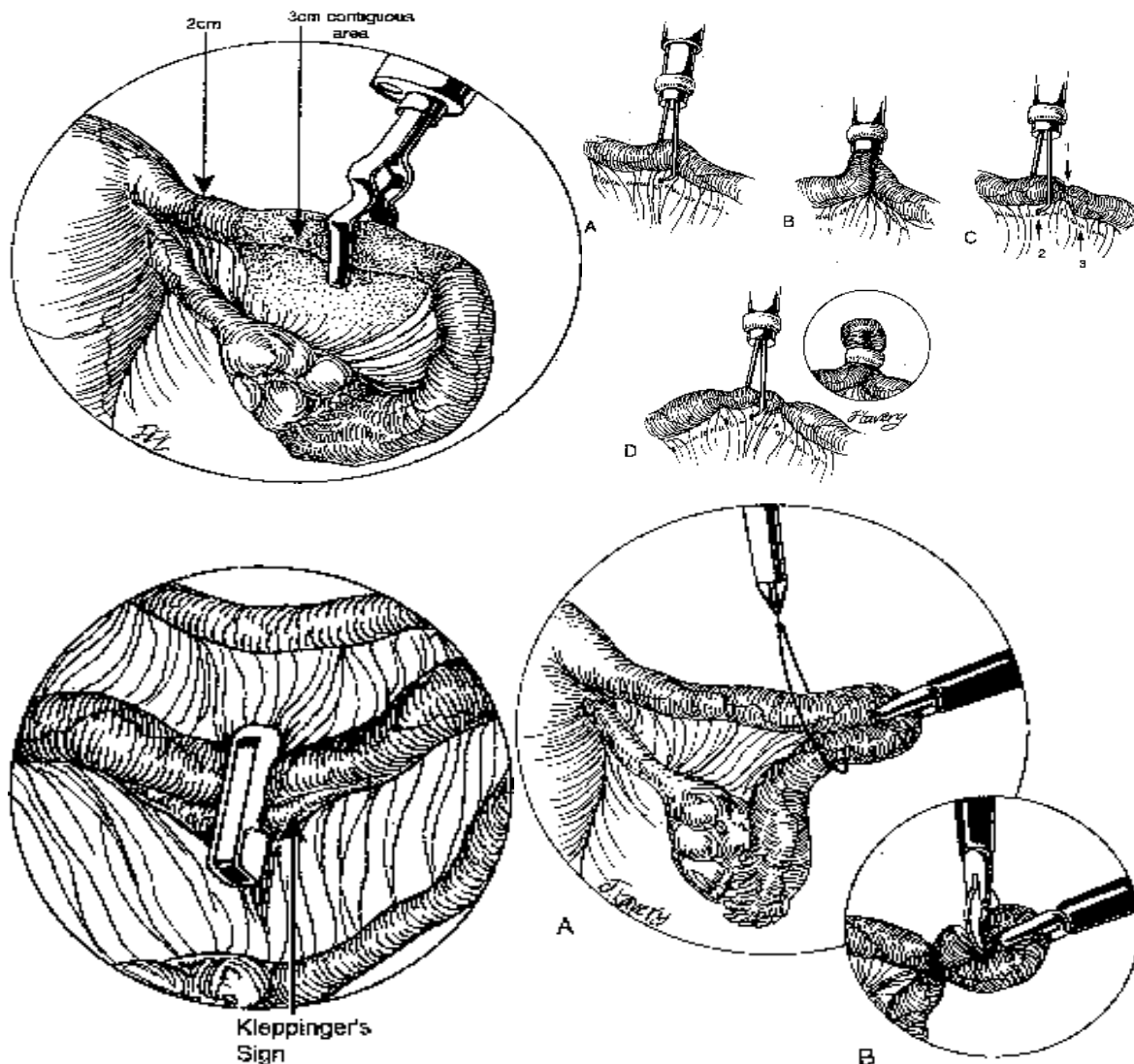


Fig. 4. Tubal ligation

6. Diagnostic laparoscopy

Another area where laparoscopy is thought to be the gold standard method is when performing a diagnostic operation. It is a minimal invasive procedure with the use of one only umbilical port that allows to visualize the lower pelvis in a great extent. Also with the introduction of more than one ports and the use of the proper instruments and technique to treat the problem that is discovered. Diagnostic laparoscopy is used for the investigation of chronic pelvic pain and infertility. In cases of women with chronic pelvic pain, various pathology might be discovered like endometriosis, adhesions, pelvic inflammatory disease, or other kind of urinary tract or bowel pathology. The first three findings are a major factor in the occurrence of female infertility, and can be explored or treated with laparoscopy. [8]

Adhesions are treated by the use of electrocautery, CO2 laser ablation and if they are in a great proximity to structures like bowel or bladder with the use of dissecting scissors, always taking care not to damage these structures. In the case of pelvic inflammatory disease the fallopian tubes are checked for patency with the infusion of a colour agent like methylene blue from the uterus manipulator and the observation if the colour agent appears from the end of the fallopian tube. In cases of fimbrial phimosis surgical repair can be performed by inserting a closed fine atraumatic grasping forceps into the area of the phimosis and gradually opening it's jaws. This manipulation must be done very gently to avoid bleeding. [1]

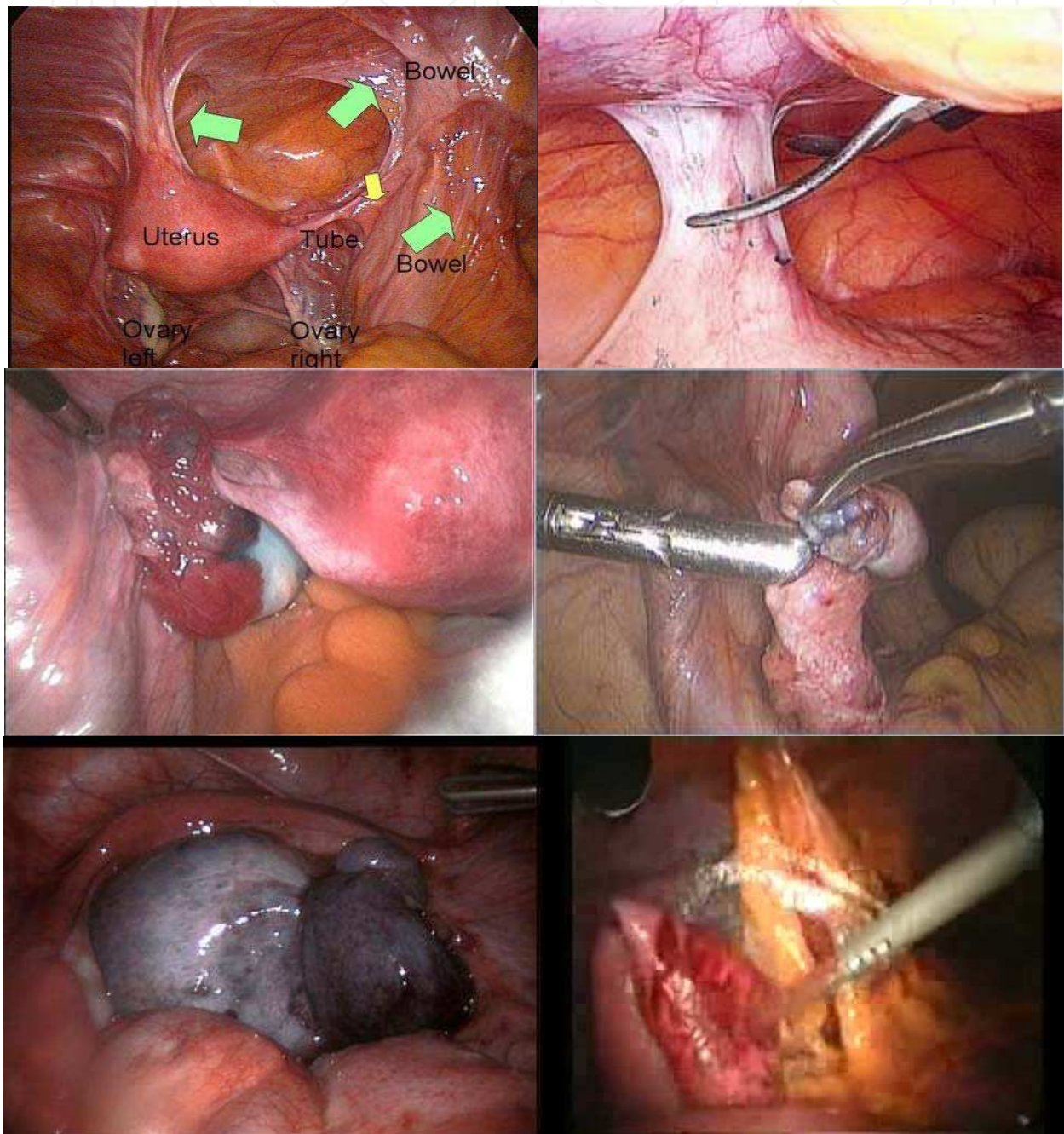


Fig. 4. Findings of diagnostic laparoscopy-adhesions, pid, tubal fimbria, ovarian abscess

In the case of tubo-ovarian abscess it can also be treated laparoscopically by perforating the wall of the abscess, then draining it's content with an aspiration device and then irrigating it until the aspirated fluid is completely clear

Endometriosis is described more thorough in the next paragraph and is treated depending on the stage it is. At early stages ablation with current or with CO2 laser is used, or if endometriotic cysts are found they are removed as described in adnexal surgery.

7. Endometriosis

Endometriosis seems to be responsible for most pathological cases of chronic pelvic pain and also for the highest percentage of cases who are referred with primary and secondary infertility [9]. Laparoscopy holds a special place in the diagnosis of this problem as it is the gold standard diagnostic test in clinical practice for the accurate diagnosis of endometriosis [10]. Compared with laparoscopy, transvaginal ultrasound (TVS) has limited value in diagnosing peritoneal endometriosis, but it is a useful tool to make or exclude the diagnosis of an ovarian endometrioma [11]. At present, there is insufficient evidence to indicate that magnetic resonance imaging (MRI) is a useful test to diagnose or exclude endometriosis compared to laparoscopy [10]. A number of markers for endometriosis have been proposed, and probably the most commonly used is the glycoprotein CA-125, an oncofetal celomic epithelium differentiation antigen. It has been suggested that 35 U/ml could be used as a cut-off serum concentration for CA-125, below which endometriosis is unlikely to be present. Unfortunately CA-125 measurements do not correlate well with either the progression of the disease or the response of endometriosis to treatment. Compared with laparoscopy, measuring serum levels of CA-125 has no value as a diagnostic tool. The test's performance in diagnosing all disease stages is limited, since it has about 28% sensitivity [12]. The test's performance for moderate to severe endometriosis is a bit better with a sensitivity reaching 47% [12].

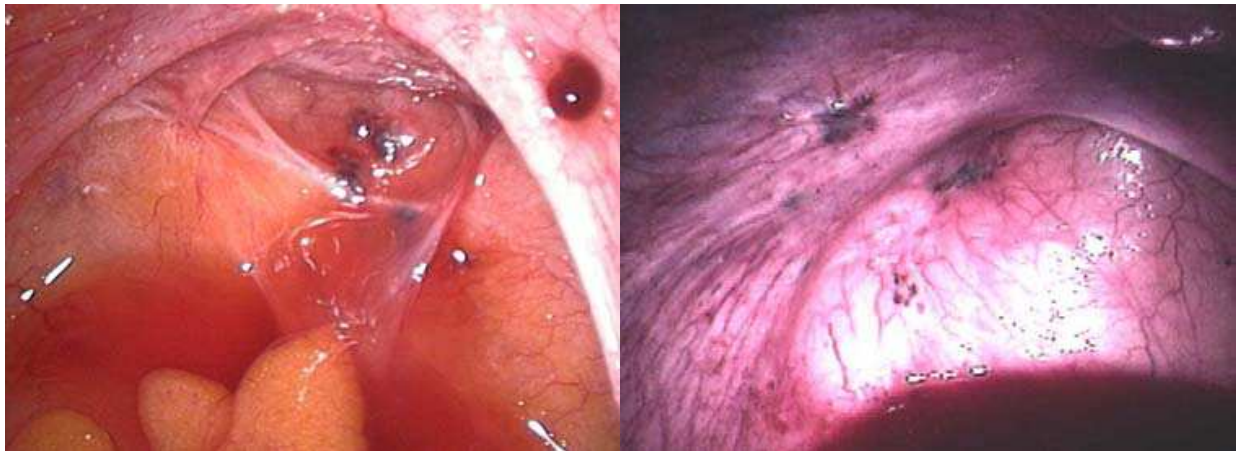


Fig. 5. Endometriosis

8. Adnexal surgery

It is important in the case of treatment of adnexal pathology, to have a full preoperative evaluation and estimation of the probability of malignancy because the manoeuvres done during laparoscopy could create peritoneal dissemination altering the stage and thus the

afterwards treatment. This evaluation includes bimanual pelvic examination, sonography, a CT scan, a full blood count, tumor markers, and a pregnancy test. Surgery of the adnexa includes ectopic pregnancy and benign cysts and tumors of the ovaries.

In the case of ectopic pregnancy the indicated methods include salpingostomy or salpingectomy. Salpingostomy is done by creating a linear incision on the dilated part of the fallopian tube and then using forceps to remove the ectopic pregnancy tissue. The fallopian tube does not need to be closed afterwards. In some occasions the fallopian tube is totally removed in order to exclude the ectopic pregnancy. It is important to use an irrigation-aspiration system to remove as much blood as possible from the peritoneal cavity in order to avoid adhesions and pain post op.

Another possibility is the removal of the tumor/cyst (hemorrhagic corpus luteum, cystadenoma, teratoma, endometrioma) while maintaining the rest of the ovarian tissue. This is done with careful dissection of the cyst, by using forceps for traction on both the cyst and the ovary and then using scissors, electrocautery or blunt dissection to separate the cyst from the ovarian tissue.

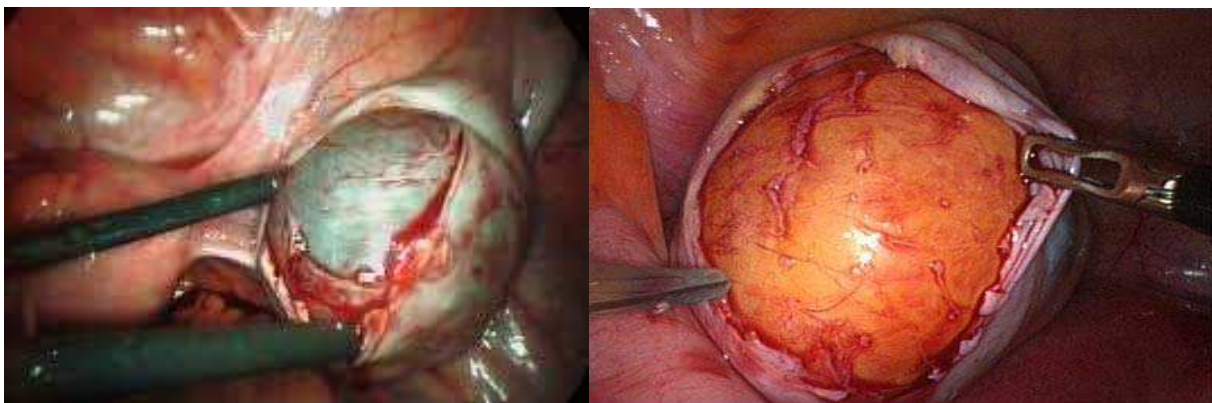


Fig. 6.

In women of older age or if excision of the cyst is not feasible, an alternative is laparoscopic salpingo-oophorectomy. In this case, the ovary is held by an atraumatic or Babcock forceps, the peritoneum is incised lateral to the ovary from the round ligament to the pelvic brim. The ureter is visualized, and the infundibulopelvic ligament is ligated and divided. The remainder of the broad ligament is dissected to the utero-ovarian ligament, which is ligated securely.

In both of the previous cases the dissected tissue is securely placed in an endo bag and is usually removed via a 10 mm trocar port. There are different kinds of cases in this phase of the operation: The cyst being small enough to be removed directly from the trocar port, or the cyst being too large, but then we can aspirate its content through the trocar port, shrinking it enough so it can exit more easily. Lastly, in cases where the cyst is too large and has a great solid portion, we can perform a mini lap by extending the incision of a trocar port and removing it through there. It is important that this is our last step after inspecting carefully the endoperitoneal cavity and irrigating and aspirating any blood, because after the mini lap is performed it is difficult to maintain the pneumoperitoneum any more.

Lastly, laparoscopy can be used for only aspirating the content of cysts, or taking only biopsies with the use of a true-cut sampler. These patients are selected cases where we are almost sure of the mass being benign and have a persistent (about 6 months) unilocular ovarian cyst on ultrasound and desire both ovarian preservation and immediate return to daily activities.

9. Myomectomy

Laparoscopic myomectomy constitutes a satisfying solution especially for women who wish to maintain fertility potential. The technique looks similar to laparotomy and is used in cases of myomas larger than 5 cm. Pedunculated uterine myomata usually are removed safely with either electrosurgery or harmonic scalpel. The removal of subserosal and intramural fibroids seem to be more challenging and requires surgical skills. The uterine incision is performed with electrosurgery and the myoma capsule is dissected in its entirety. Electrosurgery, sharp dissection and laser have been successfully performed for myomectomy. The myometrium should be closed with 0 or 2-0 absorbable suture and the serosa with 4-0 suture. Endometrial cavity's integrity can be evaluated by injecting indigo carmine dye after myomectomy. The results of myomectomy in an oncoming pregnancy or delivery are still under discussion.

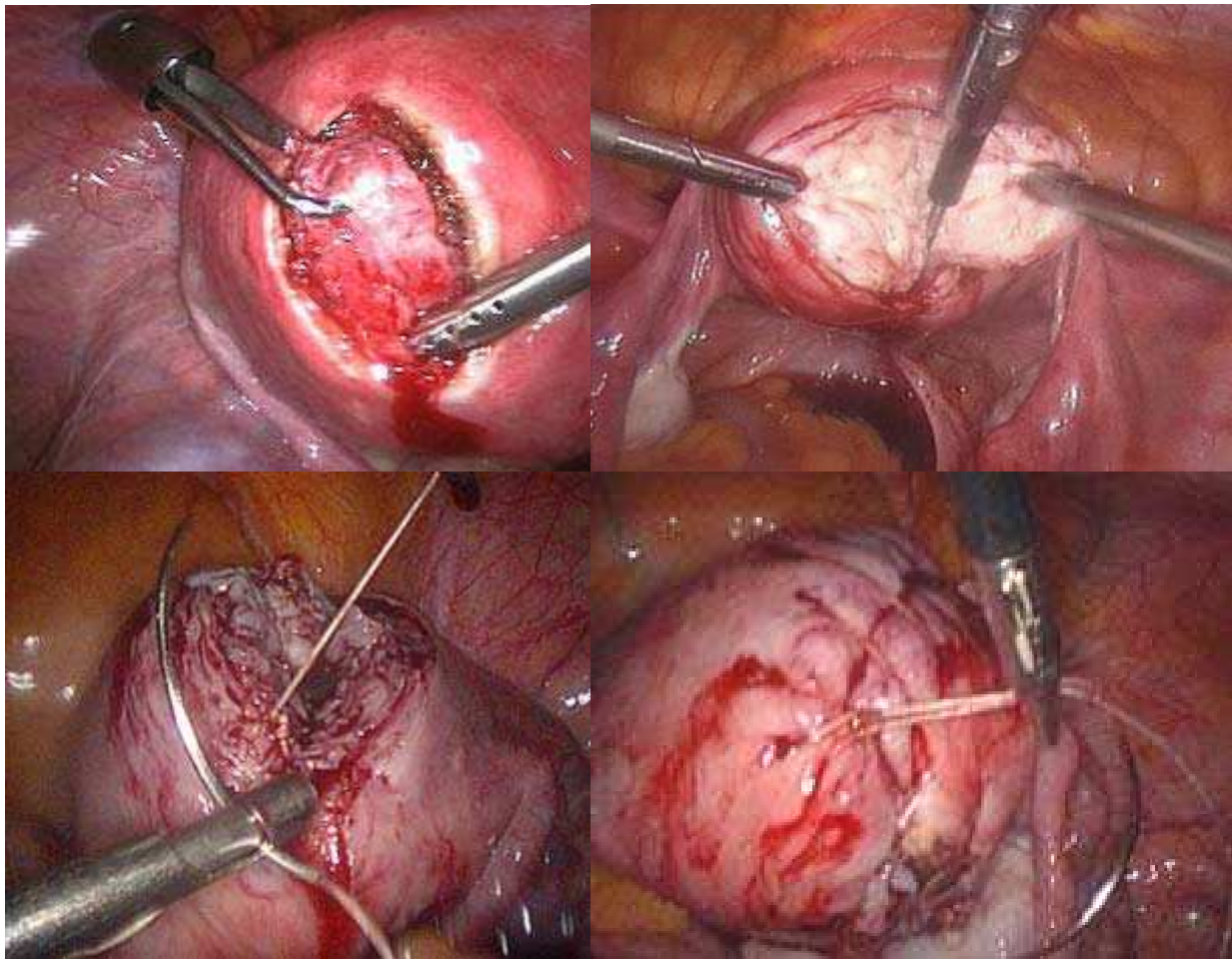


Fig. 7.

10. Hysterectomy

Hysterectomy is the commonest surgical operation in non-pregnant women. Laparoscopy was firstly performed in order to assist vaginal hysterectomy. Laparoscopic assisted vaginal hysterectomy (LAVH) increases the visualization of the upper pelvis and allows difficult operations to be performed, where extended adhesions or large ovaries consist.

Additionally, this technique has been documented by prospective, randomized, multicenter studies to be safer and more efficacy in blood loss, operative complications, postoperative pain and hospital stay than LAVH. Electrosurgical technologies, such as harmonic scalpel, Ligasure, bipolar cautery, have been developed to perform uterine artery ablation safely.

The laparoscopic hysterectomy (LSH) has a significantly shorter operative time than LAVH or total abdominal hysterectomy, shorter hospital stay and fewer complications. Essential supposition is a normal cervical cytology of the patient. Total laparoscopic hysterectomy (TLH) is a similar technique to LSH, which additionally uses a colpotomizer in order to facilitate the vaginal incision. Data by the Cochrane database have analyzed differences between TAH, TVH, and LH. Meta-analysis compared LH to TAH and found LH to be associated with reduced blood loss, shorter hospital stay, more rapid return to normal activity and fewer infections. LH had longer operating times and more frequent injuries of ureter and bladder. No difference between TVH and LH were mentioned.[14-20]

11. Laparoscopy in cancer

Endometrial cancer

Laparoscopic surgery of endometrial cancer involves resection of the uterus, cervix, tubes, ovaries and pelvic and para-aortic lymph nodes. The surgery is both diagnostic (staging) and therapeutic (80% cure). Laparoscopic pelvic and para-aortic lymph node sampling and pelvic cytology are added to the previously described hysterectomy procedures. The operative staging procedure usually includes total extrafascial hysterectomy, bilateral adnexectomy, intraperitoneal exploration, cytological washing and lymphadenectomy. Laparoscopic approach is a longer operation but involves less blood loss, a shorter hospitalization, and fewer intraoperative and postoperative complications.[21-23]

Cervical cancer

Early cervical cancers are treated surgically, by radical abdominal hysterectomy and pelvic lymphadenectomy (RAH). The main difference between RAH and TAH is that during RAH, lymphatic tissue is removed lateral to the uterus. Mobilizing the ureter makes surgeon's movements safer. Lymph nodes usually removed are common iliac, external and internal iliac. A few reports for laparoscopic radical hysterectomy and lymphadenectomy show that it is combined with larger operative time (even for experienced surgeons), less blood loss, fewer complications and a shorter hospital stay.[24,25]

Ovarian cancer

The rate of confirmed malignancy in patients with adnexal masses ranges between 0,3 to 1,2% and the publication of case histories describing undetected ovarian cancers treated by laparoscopy has given rise to criticism of this type of procedure. Ovarian cancer staging includes removal of the affected ovary and fallopian tube, pelvic and para-aortic lymph nodes, infracolic omentectomy, pelvic and subdiaphragmatic washings, and multiple peritoneal biopsies (anterior, posterior, right, and left pelvis; right and left para-colic spaces; beneath the diaphragm; and any suspicious areas). Uterus should be excised except of the cases that patient wishes to maintain fertility potential (only for Ia to Ic stage of disease). Additionally to these, laparoscopy can be performed for checking possible recurrence of disease, especially in cases of women with ovarian cancer who have a moderate elevation in the biomarker CA-125 postoperationally.

12. Training

Training for laparoscopic surgery in gynecologic oncology takes place at most fellowship programs. Dry labs can provide familiarity with instrumentation, practice with pelvic simulators, and, sometimes, realistic teaching with advanced computerized simulators. Porcine labs may allow novice surgeons an opportunity to train and learn to manage surgical complications with the laparoscope. As with most surgical procedures, confidence is gained through mentorship, careful patient selection, and repetition. Laparoscopic techniques are gaining popularity and probably will become the standard of care for endometrial cancer, because the newly trained gynecologic oncologists are well versed in these techniques.


13. Conclusions

Laparoscopic gynecologic surgery has become common place in today's gynecologic practice. As a method it provides many benefits for the patient as a minimal invasive procedure, either it is performed as a purely diagnostic procedure or as a surgical treatment. It is considered the gold standard method for exploring infertility or chronic pelvic pain as the gynecologist can explore with direct view the pelvis and the whole peritoneal cavity without subjecting the patient to the extent trauma of laparotomy. It also has a unique value in the diagnosis of endometriosis as it is the only mean of setting a sure diagnosis through direct view. Today more and more classic gynecologic operations are being replaced by laparoscopy, like tubal ligation, adnexal surgery, myomectomy, hysterectomy, and even cases of gynecologic cancer. Despite the numerous advantages it provides, it should not be considered a panacea, as it remains a surgical procedure and has the risk of complications as every other procedure. It is also important to consider that the first steps of the laparoscopic procedure are done in a "blind" way, so the selection of which patients are suitable for the procedure is something that must be done correctly, excluding patients that might be classified as high risk.

14. References

- [1] Luka Mencaglia, Luka Minelli, Arnaud Wattiez, Manual of gynecological laparoscopic surgery
- [2] Schwartz DB, Wingo PA, Antars L, et al. Female sterilization in the United States, 1987. *Fam Plann Perspect* 1989;21:209-12.
- [3] Peterson HB, Xia Z, Hughes JM, et al. The risk of pregnancy after tubal sterilization: findings from the U.S. Collaborative Review of Sterilization. *Am J Obstet Gynecol* 1996;174: 1161-8.
- [4] Peterson HB, Xia Z, Wilcox L, et al. Pregnancy after tubal sterilization with bipolar electrocoagulation. *Obstet Gynecol* 1999;94:163-7.
- [5] Huber AW, Mueller MD, Ghezzi F, et al. Tubal sterilization: complications of laparoscopy and minilaparotomy. *Eur J Obstet Gynecol Reprod Biol* 2007;134:105-9.
- [6] Chaovitsaree S, Piyamongkol W, Pongsatha S, et al. Immediate complications of laparoscopic tubal sterilization: 11 years of experience. *J Med Assoc Thai* 2004;87:1147-50.
- [7] Jamieson DJ, Hillis SD, Duerr A, et al. Complications of interval laparoscopic tubal sterilization: findings from the United States collaborative review of sterilization. *Obstet Gynecol* 2000;96:997-1002.

- [8] Christopher P. DeSimone, MD, Frederick R. Ueland, MD, *Gynecologic Laparoscopy*, *Surg Clin N Am* 88 (2008) 319–341
- [9] A. Daniilidis & H. Giannoulis & T. Tantanasis & K. Papathanasiou & A. Loufopoulos & J. Tzafettas *Diagnostic laparoscopy, infertility, and endometriosis – 5 years experience* *Gynecol Surg* DOI 10.1007/s10397-007-0357-7
- [10] Royal College of Obstetricians and Gynecologists (2006) *Greentop guideline no 24. The investigation and management of endometriosis*. RCOG, London
- [11] Moore J, Copley S, Morris J, Lindsell D, Golding S, Kennedy S (2002) *A systematic review of the accuracy of ultrasound in the diagnosis of endometriosis*. *Ultrasound Obstet Gynecol* 20: 630–634
- [12] Mol BW, Bayram N, Lijmer JG, Wiegerinck MA, Bongers MY, van der Veen F et al (1998) *The performance of CA-125 measurement in the detection of endometriosis: a meta-analysis*. *Fertile Steril* 70:1101–1118
- [13] Marana R, Busacca M, Zupi E, et al. *Laparoscopically assisted vaginal hysterectomy versus total abdominal hysterectomy: a prospective, randomized, multicenter study*. *Am J Obstet Gynecol* 1999;180:270–5.
- [14] Muzii L, Basile S, Zupi E, et al. *Laparoscopic-assisted vaginal hysterectomy versus minilaparotomy hysterectomy: a prospective, randomized, multicenter study*. *J Minim Invasive Gynecol* 2007;14:610–5.
- [15] Bojahr R, Raatz D, Schonleber G, et al. *Perioperative complications in 1706 patients after a standardized laparoscopic supracervical hysterectomy technique*. *J Minim Invasive Gynecol* 2006;13:183–9.
- [16] Milad MP, Morrison K, Sokol A, et al. *A comparison of laparoscopic supracervical hysterectomy versus laparoscopic assisted vaginal hysterectomy*. *Surg Endosc* 2001;15:286–8.
- [17] El-Mowafi D, Madkour W, Lall C, et al. *Laparoscopic supracervical hysterectomy versus laparoscopic vaginal hysterectomy*. *J Am Assoc Gynecol Laparosc* 2004;11:175–80.
- [18] Sarmini OR, Lefholz K, Froeschke HP. *A comparison of laparoscopic supracervical hysterectomy and total abdominal hysterectomy outcomes*. *J Minim Invasive Gynecol* 2005;12: 121–4.
- [19] Cheung VY, Rosenthal DM, Morton M, et al. *Total laparoscopic hysterectomy: a five-year experience*. *J Obstet Gynaecol Can* 2007;29:337–43.
- [20] O’Hanlan KA, Dibble SL, Garnier AC, et al. *Total laparoscopic hysterectomy: technique and complications of 830 cases*. *JLS* 2007;11:45–53. 340 DESIMONE & UELAND
- [21] Zapico A, Fuentes P, Grassa A, et al. *Laparoscopic-assisted vaginal hysterectomy versus abdominal hysterectomy in stages I and II endometrial cancer: operating data, follow up and survival*. *Gynecol Oncol* 2005;98:222–7.
- [22] Obermair A, Manolitsas TP, Leung Y, et al. *Total laparoscopic hysterectomy versus total abdominal hysterectomy for obese women with endometrial cancer*. *Int J Gynecol Cancer* 2005;15:319–24.
- [23] Malur S, Possover M, Michels W, et al. *Laparoscopic-assisted vaginal versus abdominal surgery in patients with endometrial cancer- a prospective randomized trial*. *Gynecol Oncol* 2001;80:239–44.
- [24] Frumovitz M, Reis R, Sun C, et al. *Comparison of total laparoscopic and abdominal hysterectomy for patients with early-stage cervical cancer*. *Obstet Gynecol* 2007;110:96–102.
- [25] Ghezzi F, Cromi A, Ciravolo G, et al. *Surgicopathologic outcome of laparoscopic versus open radical hysterectomy*. *Gynecol Oncol* 2007;106:502–6.



Advanced Gynecologic Endoscopy

Edited by Dr. Atef Darwish

ISBN 978-953-307-348-4

Hard cover, 332 pages

Publisher InTech

Published online 23, August, 2011

Published in print edition August, 2011

The main purpose of this book is to address some important issues related to gynecologic laparoscopy. Since the early breakthroughs by its pioneers, laparoscopic gynecologic surgery has gained popularity due to developments in illumination and instrumentation that led to the emergence of laparoscopy in the late 1980's as a credible diagnostic as well as therapeutic intervention. This book is unique in that it will review common, useful information about certain laparoscopic procedures, including technique and instruments, and then discuss common difficulties faced during each operation. We also discuss the uncommon and occasionally even anecdotal cases and the safest ways to deal with them. We are honored to have had a group of world experts in laparoscopic gynecologic surgery valuably contribute to our book.

How to reference

In order to correctly reference this scholarly work, feel free to copy and paste the following:

A.Daniilidis, P.Hatzis, G.Pratilas, K.Dinas and A.Loufopoulos (2011). Laparoscopy in Gynecology - How Why When, Advanced Gynecologic Endoscopy, Dr. Atef Darwish (Ed.), ISBN: 978-953-307-348-4, InTech, Available from: <http://www.intechopen.com/books/advanced-gynecologic-endoscopy/laparoscopy-in-gynecology-how-why-when>

INTECH
open science | open minds

InTech Europe

University Campus STeP Ri
Slavka Krautzeka 83/A
51000 Rijeka, Croatia
Phone: +385 (51) 770 447
Fax: +385 (51) 686 166
www.intechopen.com

InTech China

Unit 405, Office Block, Hotel Equatorial Shanghai
No.65, Yan An Road (West), Shanghai, 200040, China
中国上海市延安西路65号上海国际贵都大饭店办公楼405单元
Phone: +86-21-62489820
Fax: +86-21-62489821

© 2011 The Author(s). Licensee IntechOpen. This chapter is distributed under the terms of the [Creative Commons Attribution-NonCommercial-ShareAlike-3.0 License](#), which permits use, distribution and reproduction for non-commercial purposes, provided the original is properly cited and derivative works building on this content are distributed under the same license.

IntechOpen

IntechOpen