

# We are IntechOpen, the world's leading publisher of Open Access books Built by scientists, for scientists

**4,800**

Open access books available

**122,000**

International authors and editors

**135M**

Downloads

Our authors are among the

**154**

Countries delivered to

**TOP 1%**

most cited scientists

**12.2%**

Contributors from top 500 universities



**WEB OF SCIENCE™**

Selection of our books indexed in the Book Citation Index  
in Web of Science™ Core Collection (BKCI)

Interested in publishing with us?  
Contact [book.department@intechopen.com](mailto:book.department@intechopen.com)

Numbers displayed above are based on latest data collected.

For more information visit [www.intechopen.com](http://www.intechopen.com)



# Evolution of Operative Laparoscopy in Gynecology: A Mirage or a Challenge?

Enakpene Christopher A<sup>1</sup> and Ajayi Olukunle<sup>2</sup>

<sup>1</sup>State University of New York Medical Center, New York

<sup>2</sup>Royal Derby Hospital, Derby

<sup>1</sup>USA

<sup>2</sup>United Kingdom

## 1. Introduction

The first successful surgical treatment of ectopic pregnancy was described in 1883 by Tait<sup>1</sup>. It was not until over a century after this (1973) that Shapiro and Adler described treatment of ectopic pregnancy by laparoscopy, the emergence of laparoscopy as a credible therapeutic intervention in the early 1980s heralded a new surgical age and today it is fast replacing most of the traditional gynaecological abdominal operations<sup>2, 3, 4</sup>.

Technical developments in optics, illumination, video technology and instrumentation has further extended the frontiers from diagnostic to operative laparoscopy<sup>5</sup>. As the list of laparoscopic procedures grows, many of the traditional abdominal or pelvic surgical procedures can be done via minimal invasive approach using the laparoscope<sup>6</sup>. Advanced laparoscopic surgery is gradually evolving and may become the mainstay of operative management in gynaecologic oncology such as staging, lymphadenectomy, and radical surgery as well as in advanced endometriosis. Laparoscopic surgery contributes to remarkable improvement in cancer patients care, allows for quicker recovery and faster initiation of chemotherapy when indicated. The short hospital stay and recovery time have a positive impact in a cancer patient's quality of life, as they return to normal activities rapidly<sup>7</sup>. Furthermore, the advent and expanding roles of robotics in minimally invasive gynaecologic surgery, the future of laparoscopy promises to be brighter as this provides a means to overcome the limitations of conventional laparoscopy through the use of 3-dimensional imaging and more dextrous and precise instruments. Current studies clearly demonstrate the feasibility and safety of applying robotics to the entire spectrum of gynecologic procedures<sup>8</sup>. Laparoscopic surgery has gained ground due to its many advantages over laparotomy. To the patient; avoidance of the discomfort of a large abdominal incision, reduction of post-operative pain, reduction of wound complications and better cosmetic effect. Others are early mobilization, early discharge from the hospital, early resumption of routine activities and less adhesion formation<sup>4, 7, 8</sup>. It thus minimizes the burden on patients, their employers and their families<sup>9</sup>. On the part of the surgeon, improved visualisation offers the opportunity of more precise and accurate surgery<sup>10</sup>.

As the shift of minor treatment to day, ambulatory or even office care is becoming inexorable, and major surgeries performed via laparoscopy, the resultant reduced length of

hospital stay has the potential to release many more resources, thus, harnessing the advantages of laparoscopic surgery as appropriate can alleviate the problems of rising hospital costs and hospital-acquired infections<sup>11</sup>. Although the magnitude of saving resulting from the shorter hospital stay has been controversial, it is difficult to place a monetary value on the reduction in pain and discomfort, a shorter convalescence in an economically active group<sup>12,13,14,15,16,17,18</sup>. Although, steep learning curve and cost of training continue to limit universal usage of laparoscopy, the above benefits outweighs the limitations of laparoscopic surgery in addition. Vascular and bowel injuries continue to be obstacles to universal uptake of laparoscopic surgery.

## 2. Over viewing of the previous studies

The growth of laparoscopic surgery and its widespread acceptance into the mainstream of gynaecological practice have been faced with many challenges and pessimism. There was a great deal of opposition and pessimism of adopting laparoscopy at the inception which some antagonist termed " Foreveroscopy " because it took longer to perform than open surgery<sup>10, 19, 20</sup>. Some recent studies such as; the eVALuate study<sup>20</sup> also concluded that there is an increase in the risk of major complications associated with laparoscopic hysterectomy as compared with abdominal hysterectomy. Like many innovative and groundbreaking technologies of modern day medical practice, the introduction of laparoscopy into contemporary gynecology continue to evolve and develop. With the advances in laparoscopic surgery, potential risks of complications are no longer accepted as argument against using laparoscopic surgery rather than laparotomy for gynaecological surgeries when indicated<sup>21 -25</sup>. (Level A evidence).

The current trend is towards an increasing adoption of laparoscopic surgery by gynaecologists in a number of conditions such as hysterectomy (total laparoscopic hysterectomy, supra-cervical hysterectomy and laparoscopic assisted vaginal hysterectomy), endometriosis, adhesiolysis, adnexal surgery, laparoscopic pelvic floor repair, laparoscopic urogynecology<sup>26</sup>. Increasingly, gynecologic oncologists are adopting the laparoscopic approach for the treatment of endometrial and cervical and ovarian cancer. Laparoscopy facilitates lymphadenectomy by providing an excellent view, haemostasis and lymph node harvest.<sup>27,28,29</sup>. The Royal College of Obstetricians and Gynaecologists (RCOG) as part of the list of competencies to be gained by trainees include various laparoscopic surgeries as part of the sub-speciality modules in obstetrics and gynaecology training. An important aspect of training, should be the performance of the surgical technique under the supervision of an experienced advanced laparoscopic surgeon which is at the moment a challenge to an average gynaecology training program since a significant learning curve exists with learning laparoscopic surgery<sup>31,32</sup>.

## 3. Evidenced based studies on laparoscopic surgeries

Vaginal hysterectomy should be performed in preference to abdominal hysterectomy, whenever possible. Where vaginal hysterectomy is not possible, a laparoscopic approach may avoid the need for an abdominal hysterectomy. Risks and benefits of different approaches may however be influenced by the surgeon's experience. More research is needed, particularly to examine the long-term effects of the different types of surgery<sup>33</sup>. (Level A evidence). A recent Cochrane review found no evidence to help quantify the value of laparoscopy for the

management of early stage ovarian cancer as routine clinical practice<sup>34</sup>. (Level A evidence). Current available data and worldwide interest clearly demonstrate that laparoscopic techniques must now be part of the armamentarium of the gynaecologic oncologist. Postoperative morbidity and recurrence risk do not seem to be affected. Cost-effectiveness of laparoscopic procedures is based on the reduction of hospital stay and recovery time, although operating room time is increased in some procedures. Combined training in gynaecologic oncology and in laparoscopic and/or vaginal surgery is more than ever mandatory to avoid the risk of inadequate staging or management of pelvic malignancies<sup>35</sup>.

#### 4. Preoperative preparation

**Patients selections:** Appropriate patients selection for laparoscopic surgery is paramount. Ascertain a suitable indication, no contraindication for the proposed route, consideration should be given to other routes and coexisting pathologies such as pelvic organ prolapse, medical co-morbidities, expertise and equipment availability. In addition to the traditional routine of ensuring patient is of optimal health, pre operative assessment in operative laparoscopy should take cognizance of previous abdominal or pelvic surgeries or conditions that could predispose to intra-abdominal adhesions such as diverticulitis, pelvic abscess, ruptured appendix.

**Body habitus of patients:** This should be considered before any elective procedures. Obese patients should be encouraged to loose weight in order to reduce the risk of complications.

**Assessment of abdominal and pelvic masses:** This is to decide best approach to entry techniques, gas insufflations, consideration to open technique or the use of palmers point entry and gasless laparoscopy.

**Anesthetic assessment:** This is very essential because with the head down tilt of Lloyd Davies position or steep Trendelenburg positioning, it is not uncommon to have anaesthetic problems due to pressure of bowels on the diaphragm. Hence, communication with anaesthetic is vital. General anesthesia is the most favored as compared with regional anesthesia in laparoscopy. Operative laparoscopy necessitates optimal surgical condition, steep Trendelenburg positioning, muscle relaxation, a large pneumoperitoneum and multiple incisions all make general anesthesia the safest and most comfortable choice of anesthesia. Consent for operative laparoscopy should always include conversion to open laparotomy in case of technical difficulty or intra-operative complication.

#### 5. Decision-making, anatomy, and key steps in the operations

Veress needle check for spring action, free gas flow in addition to laparoscopic stack check and trouble shooting know-how are important to any laparoscopic surgeon to avoid delays and complications. The click heard on piercing the rectus sheath and then again on entering the peritoneum (**double click test**). The **palmer's test** is when saline placed at veress' outer end is sucked into the peritoneal cavity due to the negative intra-abdominal pressure, and the **saline test** describes 5 ml of normal saline injected through veress needle and then withdrawn, there should then be no aspirate if the needle is in the peritoneal cavity. An opening pressure of less than 8 mmHg and loss of hepatic dullness are the other means of confirming intra-peritoneal placement of veress needle. These tests are not absolute but may be taken as an indication of intra-peritoneal entry and placement of the needle. Obviously, if one inadvertently sticks the Veress needle into a major vessel such as the aorta, it should be left and immediate vascular surgeon's help summoned in addition to conversion to laparotomy.

**Entry points:** The periumbilical veress placement and gas insufflations; intra-umbilical or sub-umbilical are the most common sites for primary port placement in laparoscopy. The **Palmers point** entry, the least likely point to have adhesions, is in the mid-clavicular line 3 cm below the costal margin is useful in the presence of large pelvic mass or suspected periumbilical adhesion.

**Open laparoscopy**, first described by Hasson, a gynaecologist in 1970, is favoured by most surgeons. There is no difference in the risk of vascular or bowel injury using either of the above entry techniques. In a recent Cochrane review of the entry techniques by Ahmad et al, 17 included randomised controlled trials concerned 3,040 individuals undergoing laparoscopy. Overall there was no evidence of advantage using any single technique in terms of preventing major complications<sup>36</sup>. Insufflations pressure of 20 to 25 mmHg is recommended as it offers more room for intra-peritoneal manipulations and pushes away the gut. Other ports should be inserted under direct visualization, avoiding the blood vessels, especially inferior epigastric arteries.

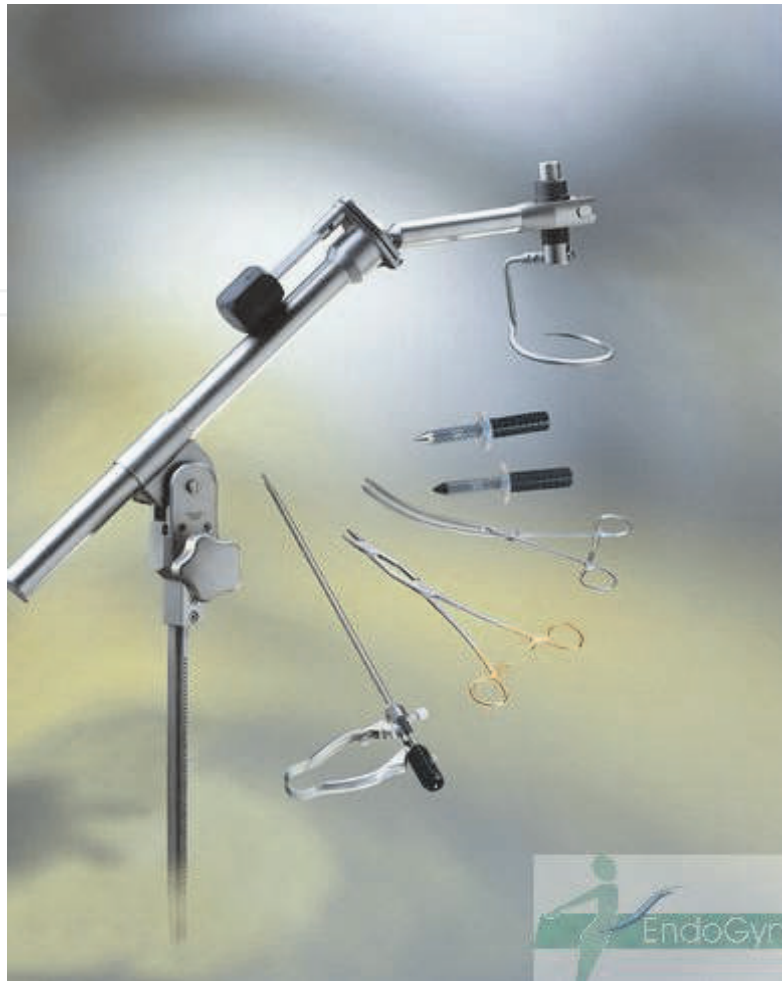## 6. Gasless laparoscopy

The use of gasless laparoscopy eliminates need for carbon dioxide gas for pneumoperitoneum to create space in the intra-peritoneal cavity for surgery. The physiological problems associated with carbon dioxide pneumoperitoneum are: hypothermia, cardiac arrhythmia, cardiovascular collapse, pulmonary insufficiency, gas embolism, venous thrombosis, cerebral edema / ischemia, ocular hypertension, extra-peritoneal insufflations such as subcutaneous emphysema, and pneumomediastinum<sup>37, 38</sup>. Gasless laparoscopy is a cost effective procedure which offers enormous benefits for the patients, surgeons, hospitals and health care system. Several devices have been used to carry out gasless laparoscopy. I am more familiar with the "Abdo-Lift Laparoscopy" which combines the use of the abdo-lift device to lift the anterior abdominal wall and modification of other ancillary laparoscopic instruments to adapt to use of abdo-lift device. These ancillary instruments are short, strong, re-usable and durable for several years.

The ancillary instruments with abdo-lift device are: flexible silicone cannula, Metzenbaum and double jointed scissors, sponge holder, needle holder, Bozeman-Douglas clamps, tenaculum forceps, claw forceps, atraumatic clamp, knot tier and myoma fixation instrument. These re-usable, appropriate, acceptable, available, accessible and affordable instruments reduce the cost of minimal access surgery when compared with both standard laparoscopy and Da-Vinci. The problems and complications associated from iatrogenic insufflations of carbon dioxide are also completely eliminated so that minimally invasive operations can also be performed in high risks patients such as cardiac insufficiency, obstructive lung disease or during pregnancy.

## 7. Specific laparoscopic surgical techniques

**Cross bag techniques:** This was first developed by Jim Kondrup and it is used for big ovarian cystectomy without spillage of the cyst contents inside the peritoneal cavity. The ovarian mass is freed completely and carefully placed inside the endo-catch bag. The cyst is aspirated while inside the endo-catch bag and the cyst wall is completely excised without spillage of the cyst contents.



Permission obtained from EndoGyn, Germany.

Fig. 1.

**Snag and bag:** The cyst wall is snagged with help of negative pressure from the suction and a needles is passed through the same pot to aspirate the cyst content without spillage. Thereafter, the cyst wall is excised preserving the ovarian tissues and preventing spillage of cyst contents.

**Simplified laparoscopic abdominal morcellation (SLAM):** This is the use of number 11 surgical blade to cut into pieces surgical specimens and remove them in piece-meal through the 10 mm port. This is a better and faster technique than the mechanical or electrical morcellators.

## 8. Anatomical challenges in laparoscopy

**Challenges of Obesity:** The umbilicus may be displaced downward thus reference points of the aorta is distorted making injury more likely. Also one may need a longer Veress needle and trochar and cannula for entry. Insufflation through the uterus has been describes as well. Technical obstacles associated with open pelvic surgery in the obese patients are primarily those related to exposure of the operative field and access to deep pelvic structures. These obstacles present similar challenges when laparoscopy is attempted<sup>39, 40</sup>, and there is unique difficulty of establishing pneumoperitoneum in obese patients<sup>41</sup>. These limitations place the obese patient undergoing laparoscopy at an inherently increased risk of conversion to

laparotomy<sup>17-19</sup>. In a review of 2,530 attempted gynecologic laparoscopic surgeries, Sokol et al determined that a BMI greater than 30 kg/m<sup>2</sup> placed patients at a more than 2-fold increased risk of unintended laparotomy<sup>42</sup>. Eltabbakh et al noted similar findings in a review of 47 obese patients who underwent operative gynecologic laparoscopies<sup>43</sup>.

**Challenges of Adhesions:** Patients with previous pelvic and abdominal surgeries or when extensive adhesions are envisaged as in severe endometriosis, the use of Palmer's point entry or open laparoscopy is advisable. Adnexal masses and cancers or severe endometriosis may distort the pelvic anatomy and alter the course of ureters making it more liable to damage. Extended hysterectomy may pose a challenge as well. The use of trans-illuminating ureteric stents such as Uriglow™ placed cystoscopically allows ureters to be easily identified and reduce risk of damage at surgery<sup>44</sup>.

The ancillary ports are most usually placed well lateral to the inferior epigastric vessels, and should be inserted high enough so that any instrument can be used on both sides of the pelvis. If there is to be anything more than the occasional suturing, a 10 mm port will allow the insertion of curved needles. Tricks to avoid the epigastric vessels at insertion of ancillary ports are trans-illumination before inserting the trochar ensures no vessel in the path and also injection of saline through a needle confirms the path when visualised in the abdomen.

### Key steps

1. Appropriate patient selection
2. Pre operative assessment and consent
3. Equipments check
4. Personnel: Anaesthetist, assistants and scrub nurse
5. Positioning and ergonomics
6. Entry techniques
7. Surgery: prevent complications
8. Closure and prevention of adhesions
9. Immediate post operative
10. Discharge and Follow up

**Positioning:** Laparoscopy may take longer to perform in comparison to laparotomy. It is crucial to ensure optimal patients positioning and equipments set to make operators comfortable and ergonomically surgeon friendly. We preferred Lloyd Davis position to modified lithotomy, (Trendelenburg) during laparoscopic surgery because, the flexed thigh does not restrict movement during manoeuvres of the instruments. It is important to position the patient correctly on the operating table. Again, this means ensuring that the buttocks are over the edge of the table to allow full uterine ante-version. The legs are ideally placed in hydraulic leg supports with the thighs at about 45° to the horizontal while ensuring that the hips can be extended sufficiently to bring the thighs in line with the trunk should the need arise for any abdominal surgery. In addition, the legs would not interfere with manipulation of the instruments. The height of the bed should be such that surgeon should be comfortable. The visual display unit should be at the eye level in front of the surgeon and the assistants screen should be so adjusted to his or her specifications. I personally supervise the positioning of patients and ensure that operators are comfortable in order to avoid unnecessary strain. I ensure the bottom juts over the edge of the bed to allow adequate manipulation of the uterus by the second assistant.

While most gynecologists use the sub-umbilical approach, we prefer to use the vertical incision, about 10mm long to accommodate the primary port. Transverse sub umbilical or intra-umbilical incisions are used by various gynaecologists.

Virtually all the major abdominal operations described in Operative Surgery books have been performed with laparoscopic access or assistance. "What was advanced laparoscopic surgery yesterday is routine today."

Different operation room set ups are described (figure 2) as shown.

### Operation room set up

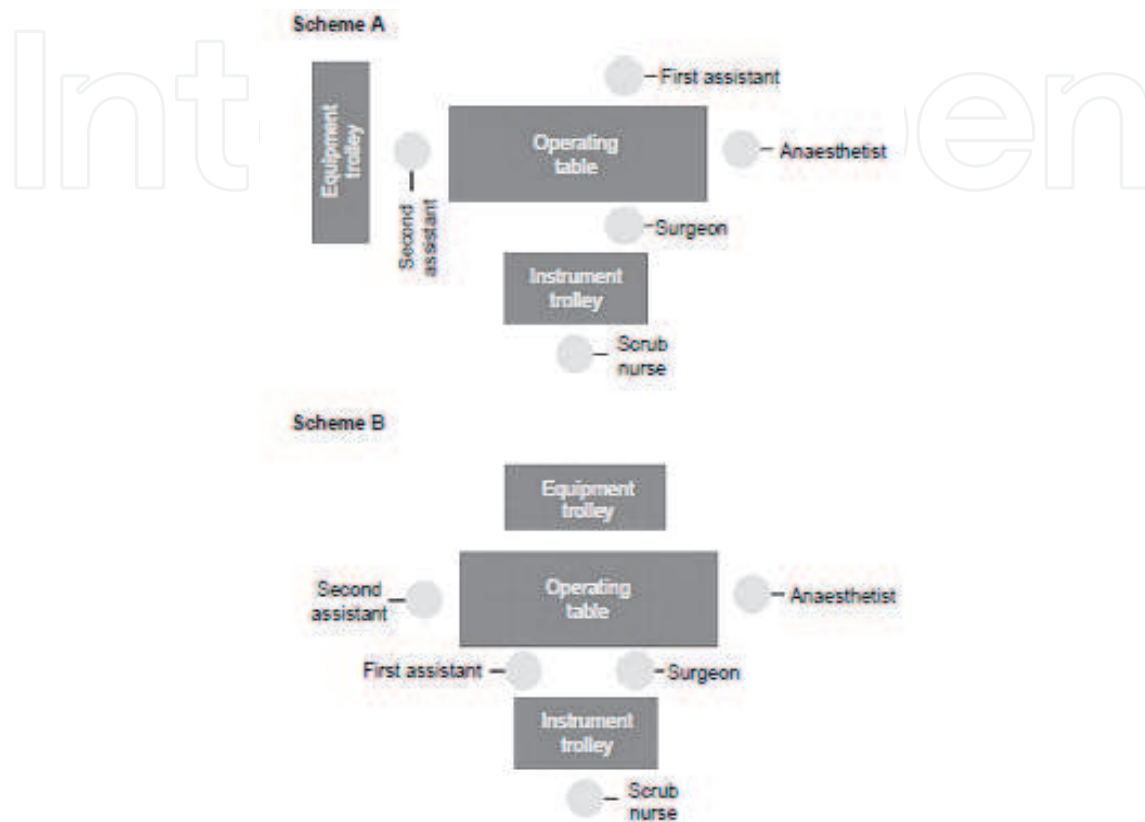


Fig. 2. From Dewhurst's Textbook of obstetrics and gynecology.

1. Lyses of adhesions
2. Appendicectomy
3. Investigations for infertility
4. Cholecystectomy
5. Ovarian/fallopian tube surgery
6. Ectopic pregnancy
7. Investigation of abdominal/pelvic pain (sub-acute intestinal obstruction and chronic pelvic inflammatory diseases) and intestinal surgery
8. Laparoscopic staging of cancer, biopsy and lymphadenectomy.
9. Myomectomy (removal of fibroids)
10. Hysterectomy
11. Morbid obesity surgery
12. Endometriosis
13. Hernia repair
14. Ovarian cysts

Table 1. Common indications of laparoscopy



1. Smaller incisions
2. Improved anatomical view to the surgeon and better visualization
3. Less collateral tissue handling and damage
4. Less internal scar (adhesions) formation
5. Less external scar formation like keloids or hypertrophic scars
6. Less general anaesthesia
7. Less post-operative pain and analgesia usage
8. Early ambulation
9. Less hospitalization time
10. Early return to normal activities and work

Table 2. Advantages of endoscopic surgeries

### 9. Impact of these techniques on modern practice

Laparoscopy is considered one of the first truly consumer-driven medical advances <sup>45</sup>.

In the light of the various advantages of laparoscopic surgeries catalogued above, increased access to health information and increasing participation of patients in decision making; it is just a matter of time before we start experiencing demand for laparoscopic surgery by patients. The need for organised training and retraining of gynaecologists can therefore not be over emphasised in the interim. Laparoscopic surgical training and perfection of various techniques are influenced by: Patients demand, cost of healthcare, cost of training, length of training and increasing application of laparoscopy for most gynecological abdominal and pelvic procedures.

#### Recommendations and conclusions:


- Every gynaecologist should be trained in laparoscopy
- Laparoscopy should be available for all and sundry
- It is the main surgical technique of the future
- Robotic surgery development and introduction should be introduced gradually into mainstream gynecology
- Gasless laparoscopy should be part of the surgical armamentarium in any gynaecological laparoscopic surgical unit. Severe criticism that embroiled the adoption of standard (Straight stick) laparoscopy has also been melted down to the introduction of gasless laparoscopy. This important technique of minimal invasive surgery will also overcome many of the hurdles that often confront introduction of new technologies. Training and acquisition of knowledge and skills of its use should be encouraged as part of comprehensive training in minimal access surgeries in gynaecology. Its inexpensiveness, ease of use and short learning curve may eliminate most of the barriers that hinder widespread adoption of laparoscopy in gynaecological surgeries

### 10. References

- [1] Tait RL. Five cases of extra-uterine pregnancy operated upon at the time rupture. *BMJ*. 1884;1:1250.
- [2] Togas T, Ahmed S. Surgical Management of Ectopic Pregnancy. *Clinical Obstetrics & Gynecology* 1999, 42(1):31-38.
- [3] Berci G, Sackier JM, Paz-Partlow M: Emergency laparoscopy. *Am J Surg* 1991, 161(3):332-335.
- [4] Warren O, Kinross J, Parasceva P, Darzi A. Emergency laparoscopy - Current Best Practice. *World Journal of Emergency Surgery* 2006, 1:24.
- [5] Semm K, Mettler L. Technical progress in pelvic surgery via operative laparoscopy. *Am. J. Obstet. Gynecol* 1980, 138: 121-7

- [6] Howard, F.M. Breaking new ground or just digging a hole? An evaluation of gynecologic operative laparoscopy. *J. Gynecol. Surg* 1992, 8: 143-158
- [7] Theodoros DT, John NB. Laparoscopy and Oncology: Where Do We Stand Today? *Annals of the New York Academy of Sciences* 2006, 997 (1).
- [8] Arnold PA, Karen W. Evolving Role and Current State of Robotics in Minimally Invasive Gynecologic Surgery. *Journal of Minimally Invasive Gynaecology* 2009, 16 (3): 291-301.
- [9] Nezhat CR, Nezhat FR, Metzger DA, Luciano AA. Adhesions formation after reproductive surgery by video-laparoscopy. *Fertility and Sterility* 1990, 53: 1008.
- [10] Gitsch E, Vytiska-Binstorfer E, Skodler W. Various effects of abdominal and vaginal hysterectomy in benign diseases. *European Journal of Obstetrics, Gynecology, and Reproductive Biology* 1990, 36: 259-63
- [11] Paraiso MF. Laparoscopic Burch colposuspension and the tension-free vaginal tape procedure. *Current Opinion in Obstetrics & Gynecology* 2006, 18(4):385 - 390.
- [12] Ray G. Laparoscopic surgery Best Practice & Research Clinical Obstetrics & Gynaecology, Volume 20, Issue 1, February 2006, Pages 89-104
- [13] Trehan AK. Hysterectomy: Towards an Overnight Stay. *Gynaecological Endoscopy* 2002, 11 (4).
- [14] Scrimgeour JB, Ng KB, Gaudoin MR. Laparoscopy in vaginal hysterectomy *Lancet* 1991, 338: 1465-6.
- [15] Summit RL, Stovall TG, Lipscomb GH, Ling FW. Randomised comparison of laparoscopy assisted vaginal hysterectomy with standard vaginal hysterectomy in an out patient setting. *Obstetrics and Gynecology* 1992, 80: 895-901.
- [16] Hill DJ. Complication of hysterectomy. *Baillière's Clinical Obstetrics and Gynaecology* 1997, 11: 181-97.
- [17] Hulka J, Brown Levy BS, Parker WH, Phillips JM. Laparoscopic assisted vaginal hysterectomy. American Association of Gynecologic Laparoscopists' Membership Survey. *J Am Assoc Gynecol Laparosc* 1997, 4: 167-71.
- [18] Nezhat, F., Nezhat, C., Gordon, S. and Wilkins, E. Laparoscopic versus abdominal hysterectomy. *J. Reprod. Med* 1992, 37: 247-250.
- [19] Raju KS, Auld BJ. A randomised prospective study of laparoscopic vaginal hysterectomy and bilateral salpingo-oophorectomy with conventional abdominal hysterectomy, each with bilateral salpingo-oophorectomy. *B JOG* 1994, 101: 1068-71.
- [20] Bronitsky C, Payne RJ, Stuckey S, Wilkins D. A comparison of laparoscopically assisted vaginal hysterectomy versus traditional total abdominal and vaginal hysterectomies. *Journal of Gynecologic Surgery* 1993, 9: 219-24.
- [21] Shushan A, Mohamed H, Magos AL. How long does laparoscopic surgery really take? Lessons learned from 1000 operative laparoscopies. *Hum Reprod* 1999, 14 (1): 39-43.
- [22] Ray G, Fountain J, Mason S, Hawe J, Napp V, Abbott J, Clayton R, Phillips G, Whittaker M, Lilford R, Bridgman S, Brown J. The eVALuate study: two parallel randomised trials, one comparing laparoscopic with abdominal hysterectomy, the other comparing laparoscopic with vaginal hysterectomy. *BMJ* 2004, 328:129.
- [23] Chapron C, Fauconnier A, Goffinet F, Bréart G, Dubuisson J.B. Laparoscopic surgery is not inherently dangerous for patients presenting with benign gynaecologic pathology. Results of a meta-analysis, *Hum Reprod.* 2002, 17 (5): 1334-1342.
- [24] Simon WA. Results of eVALuate study of hysterectomy techniques: Conversion to open surgery should not be regarded as major complication. *BMJ* 2004, 328: 642.
- [25] Stephen MFS. Results of eVALuate study of hysterectomy techniques: Degree of pain cannot be commented. *BMJ.* 2004, 328: 642.

- [26] Canis MJ, Wattiez A, Mage G, Bruhat MA. Results of eVALuate study of hysterectomy techniques: Laparoscopic hysterectomy may yet have a bright future BMJ 2004, 328: 642-643.
- [27] Donnez J, Squifflet J, Jadoul P, Smets M. Results of eVALuate study of hysterectomy techniques: High rate of complications needs explanation. BMJ 2004, 328: 643.
- [28] Lin, Lawrence La; Ho, Mat Ha; Haessler, Alexandra La; Betson, Lance Ha; Alinsod, Red M b; Liu, CY c; Bhatia, Narender Na. A review of laparoscopic uterine suspension procedures for uterine preservation. *Current Opinion in Obstetrics & Gynecology* 2005, 17(5):541-546.
- [29] Pittaway DE, Takacs P, Bauguess P. Laparoscopic Adnexectomy: A Comparison With Laparotomy. *AJOG* 1994, 171(2):385-391.
- [30] Leblanc E, Sonoda Y, Narducci F, Ferron G, Querleu D. Laparoscopic staging of early ovarian carcinoma. *Current Opinion in Obstetrics & Gynecology* 2006, 18(4):407-412.
- [31] Burnett AF. Radical trachelectomy with laparoscopic lymphadenectomy: review of oncologic and obstetrical outcomes. *Current Opinion in Obstetrics & Gynecology* 2006, 18(1):8-13.
- [32] Rosen D, Cario G. The learning curve for laparoscopic hysterectomy. *Gyn Endosc* 1998, 7:289-294.
- [33] Wattiez A, Soriano D, Cohen SB, et al. The learning curve of total laparoscopic hysterectomy: comparative analysis of 1647 cases. *J Am Assoc Gynecol Laparosc* 2002, 9:339-345.
- [34] Nieboer TE, Johnson N, Lethaby A, Tavender E, Curr E, Garry R, van Voorst S, Mol BWJ, Kluivers KB. Surgical approach to hysterectomy for benign gynaecological disease. *Cochrane Database of Systematic Reviews* 2009, Issue 3. Art. No.: CD003677. DOI: 10.1002/14651858.CD003677.pub4.
- [35] Medeiros LRF, Rosa DD, Bozzetti MC, Rosa MINES, Edelweiss MI, Stein AT, Zelmanowicz A, Ethur AB, Zanini RR. Laparoscopy versus laparotomy for FIGO Stage I ovarian cancer. *Cochrane Database of Systematic Reviews* 2008, Issue 4. Art. No.: CD005344. DOI: 10.1002/14651858.CD005344.pub2.
- [36] Querleua D, Leblanc E, Ferrona G, Narduccib F. Laparoscopic surgery in gynaecological oncology. *European Journal of Surgical oncology* 2006, 32 (8): 853-858.
- [37] Ahmad G, Duffy JMN, Phillips K, Watson A. Laparoscopic Entry Techniques. *Cochrane Database of Systematic Reviews* 2008, Issue 2. Art. No.: CD006583. DOI: 10.1002/14651858.CD006583.pub2
- [38] Wolf J S, Stoller ML. The physiology of laparoscopy: basic principles, complications and other considerations. *J Urol.* 1994; 152: 294-302
- [39] Chiu AW, Chang LS, Birkett DH, Babayan RK. The impact of pneumoperitoneum, retroperitoneum, and gasless laparoscopy on the systemic and renal hemodynamics. *J Am Coll Surg.* 1995; 181: 397-406.
- [40] Holtz G. Laparoscopy in the massively obese female. *Obstet Gynecol* 1987;69:423-4.
- [41] Halpern NB. Access problems in laparoscopic cholecystectomy: postoperative adhesions, obesity, and liver disorders. *Semin Laparosc Surg* 1998;5:92-106.
- [42] Loffer FD, Pent D. Laparoscopy in the obese patient. *Am J Obstet Gynecol* 1976;125:104-7.
- [43] Sokol AI, Chuang K, Milad MP. Risk factors for conversion to laparotomy during gynecologic laparoscopy. *J Am Assoc Gynecol Laparosc* 2003;10:469-73.
- [44] Eltabbakh GH, Piver MS, Hempling RE, Recio FO. Laparoscopic surgery in obese women. *Obstet Gynecol* 1999;94:704-08
- [45] Phipps JH. Laparoscopic hysterectomy and oophorectomy a Practical Manual and Color atlas. Churchill livingstone 1993
- [46] Geier WS. An overview of consumer-driven ambulatory surgery: operative laparoscopy. *Nurse Pract* 1995, 20 (36): 46 - 51.



## **Advanced Gynecologic Endoscopy**

Edited by Dr. Atef Darwish

ISBN 978-953-307-348-4

Hard cover, 332 pages

**Publisher** InTech

**Published online** 23, August, 2011

**Published in print edition** August, 2011

The main purpose of this book is to address some important issues related to gynecologic laparoscopy. Since the early breakthroughs by its pioneers, laparoscopic gynecologic surgery has gained popularity due to developments in illumination and instrumentation that led to the emergence of laparoscopy in the late 1980's as a credible diagnostic as well as therapeutic intervention. This book is unique in that it will review common, useful information about certain laparoscopic procedures, including technique and instruments, and then discuss common difficulties faced during each operation. We also discuss the uncommon and occasionally even anecdotal cases and the safest ways to deal with them. We are honored to have had a group of world experts in laparoscopic gynecologic surgery valuably contribute to our book.

### **How to reference**

In order to correctly reference this scholarly work, feel free to copy and paste the following:

Enakpene Christopher A and Ajayi Olukunle (2011). Evolution of Operative Laparoscopy in Gynecology: A Mirage or a Challenge?, *Advanced Gynecologic Endoscopy*, Dr. Atef Darwish (Ed.), ISBN: 978-953-307-348-4, InTech, Available from: <http://www.intechopen.com/books/advanced-gynecologic-endoscopy/evolution-of-operative-laparoscopy-in-gynecology-a-mirage-or-a-challenge->

**INTECH**  
open science | open minds

### **InTech Europe**

University Campus STeP Ri  
Slavka Krautzeka 83/A  
51000 Rijeka, Croatia  
Phone: +385 (51) 770 447  
Fax: +385 (51) 686 166  
[www.intechopen.com](http://www.intechopen.com)

### **InTech China**

Unit 405, Office Block, Hotel Equatorial Shanghai  
No.65, Yan An Road (West), Shanghai, 200040, China  
中国上海市延安西路65号上海国际贵都大饭店办公楼405单元  
Phone: +86-21-62489820  
Fax: +86-21-62489821

© 2011 The Author(s). Licensee IntechOpen. This chapter is distributed under the terms of the [Creative Commons Attribution-NonCommercial-ShareAlike-3.0 License](#), which permits use, distribution and reproduction for non-commercial purposes, provided the original is properly cited and derivative works building on this content are distributed under the same license.

IntechOpen

IntechOpen