

We are IntechOpen, the world's leading publisher of Open Access books Built by scientists, for scientists

4,800

Open access books available

122,000

International authors and editors

135M

Downloads

Our authors are among the

154

Countries delivered to

TOP 1%

most cited scientists

12.2%

Contributors from top 500 universities

**WEB OF SCIENCE™**Selection of our books indexed in the Book Citation Index
in Web of Science™ Core Collection (BKCI)

Interested in publishing with us?
Contact book.department@intechopen.com

Numbers displayed above are based on latest data collected.

For more information visit www.intechopen.com

Physiologic Risk Assessment in Stable Ischemic Heart Disease – Functional Evaluation Versus Coronary Anatomy

Alessia Gimelli and Paolo Marzullo

Fondazione Toscana Gabriele Monasterio, CNR, Pisa, Italia

1. Introduction

The prognostic power of angiographic coronary anatomy has been definitively established since the CASS registry (1), where the 12-year survival rate of medically treated patients with no significant coronary lesions was 91%, compared with 74, 59 and 50% for patients with one, two and three vessel disease. Survival rate is known to further decrease in the presence of a left main coronary artery disease, and of a severe proximal left anterior descending stenosis (2).

However, several lines of evidence, obtained with different approaches, demonstrate that a physiologic risk assessment is superior to an angiographically oriented approach in prognostic stratification of patients with stable ischemic heart disease. In particular, in a recent study, Gimelli et al (3), in order to predict patient survival rate, analyzed a group of 676 consecutive in-patients who underwent a complete diagnostic work-up that included gated single photon emission computed tomography (SPECT) and coronary arteriography for known or suspected ischemic heart disease. Patients with acute myocardial infarction (MI), previous coronary artery bypass surgery, overt hyperthyroidism or who were undergoing dialysis treatment were excluded.

To predict patient survival rate, the Authors utilized an angiographic semi-quantitative score, that takes into account the number of stenotic coronary arteries, the location of coronary stenoses (proximal, middle, or distal), and the degree of luminal diameter reduction (using a 50 and a 70% coronary stenosis threshold). As expected, this score was an independent predictor of event-free survival. However, the prognostic impact of this score disappeared once gated SPECT variables were included into the model (3).

The notion that the prognostic impact of functional risk assessment is superior to angiography is not novel. In patients with defined coronary artery disease, exercise variables primarily relating to the functional state are known to provide an incremental prognostic information over coronary anatomy (4). The treadmill score also adds independent prognostic information to that provided by clinical data, coronary arteriography and left ventricular (LV) ejection fraction (5). The predictive power of clinical data is also strengthened by adding the results of dobutamine echocardiography (6); however, the power of the model was increased to a minor degree by the addition of coronary anatomy data. In a group of patients who underwent stress echocardiography with

either dipyridamole or dobutamine, and who also underwent coronary angiography within a year without an intervening procedure, coronary angiography parameters did not add significant predictive power to the model compared with stress echocardiographic variables (7). As to nuclear cardiology, the superiority of myocardial perfusion imaging over coronary angiography in risk stratification of patients with ischemic heart disease is also well known. In 1992, Pollock et al. demonstrated that myocardial perfusion is superior to coronary angiography in risk stratification of ischemic heart disease patients (8); at variance with our study, these authors used Thallium-201 (Tl-201) and static planar imaging. In a series of 316 medically treated patients, Iskandrian et al. (9) showed the independent and incremental prognostic information of exercise SPECT Tl-201 imaging even when catheterization data are available. All these evidences definitively underline the superiority of functional risk stratification over an approach based solely on angiographic coronary anatomy.

These observations can be partly explained by the limitations of coronary angiography. First of all, coronary angiography has a limited sensitivity when compared to necropsy studies (10) and to intravascular ultrasound investigations (11). Furthermore, the identification of significant lesions may be confounded by coronary remodeling and by the extraluminal location of some plaques (12). Finally, coronary angiography does not allow to study coronary microcirculation, increasingly recognized as independent determinant of impaired blood flow, disease progression and adverse prognosis (13).

2. The role of nuclear medicine as functional imaging

The clinical use of radioisotopes in the evaluation of patients with ischemic heart disease is largely based on noninvasive methodology suitable for visualizing myocardial perfusion. Although contrast echocardiography and magnetic resonance imaging have been proposed recently for the same purpose, at present most of the noninvasive tests for assessing myocardial perfusion reside in nuclear cardiology. The most popular radioactive flow tracers are characterized by a rapid myocardial extraction followed by either a sequestration (for Technetium 99m labeled agents – Tc 99m) or a very slow washout (for Tl-201). These features make the tracer uptake proportional to blood flow in each myocardial region, even if, up to now, the quantitation of absolute flow is not possible with these techniques. Despite this limitation, myocardial perfusion can be imaged and underperfusion can be detected as a relative uptake defect compared with the better perfused myocardium. As “significant” coronary stenosis regionally impairs flow reserve, myocardial perfusion imaging has become a common tool for the diagnosis of coronary artery disease and coronary angiography the gold standard for defining its sensitivity and specificity.

The main strength of radionuclide cardiac imaging in patients with coronary artery disease is to provide pathophysiologic and clinical information related to major objectives of assessment which include myocardial perfusion, viability and their relationship with left ventricular function. For these hypothesis, these data have additional value over anatomic information, provided by other imaging techniques, for patient management and outcome.

3. Overview of imaging principles

The two different approaches used to evaluate myocardial perfusion by nuclear imaging are SPECT and positron emission tomography (PET). SPECT gamma-emitting tracers include Tl-201, Tc-99m Sestamibi and Tetrofosmine. PET positron emitting tracers include O-15 water, N-13 ammonia and rubidium-82, a generator produced readily available agent.

As potassium analogue, Tl-201 has high myocardium uptake and has been the most commonly used perfusion tracer during the past years (14). Tl-201 is distributed into the myocardium proportionally to the flow over a wide range of values. However, some limitations have recently reduced its use: the low photon energy is associated with a lower resolution and significant attenuation by overlying tissues; the prolonged physical half-life (73 hours) causes a significant radiation exposure to the patient.

Tc-99m labeled tracers, having a shorter physical half life (6 hours) and better imaging capabilities, replaced Tl-201 in several indications for clinical SPECT (15). Tc-99m labeled tracers are readily available, the images obtained show higher spatial resolution and tissue attenuation is also less significant. Tc-99m Sestamibi and Tetrofosmine, the two most commonly used labeled tracers, distribute into the myocardium proportionally to the flow but their uptake is also dependent on normal mitochondrial function. After myocardial uptake, the retention of Tc-99 m labeled tracers in the myocardium is high so that two separate tracer injections are required to compare stress and resting perfusion.

Up to now, one of the major advantages of PET over SPECT is the possibility to correct myocardial tissue radioactivity for attenuation of the surrounding organs so that, using appropriate models to describe the kinetics of the single tracer, it is possible to quantitate myocardial blood flow (MBF) in absolute terms ($\text{mL}\cdot\text{g}^{-1}\cdot\text{min}^{-1}$) (16-17). O-15 water is considered the gold standard for MBF quantitation because its kinetic in the heart is independent of myocardial metabolism (18). However, the tracer is freely diffusible and has a very short physical half-life (120 sec) so that images have not a high myocardial definition and approaches to correct for radioactivity in the vascular compartment are required for MBF quantitation (19).

N-13 Ammonia is highly extracted and retained by the heart and has a relatively longer physical half-life than O-15 water (9.96 min) resulting in good to excellent images of the myocardium. However, the uptake and retention are dependent on myocardial metabolism (20), which may also cause regional differences in tracer accumulation (21). Rest and stress studies should be separated by 30 to 40 minutes to allow decay of the previously injected dose. There are a number of approaches for MBF quantitation with N-13 ammonia using one, two or three compartments models (22-24) and corrections for lower extraction at higher flows is used from empirical relationships obtained in experimental studies.

Rubidium-82, is a potassium analog like Tl-201, allows good quality myocardial images and is available by a generator. The very short physical half-life (76 sec) allows to perform rest and stress studies with minimal time intervals but also introduces some challenges for the absolute quantitation of MBF (16).

A typical myocardial perfusion imaging exam includes a rest-stress protocol where either a physical (bicycle or treadmill exercise in conjunction with SPECT) or a pharmacological (dipyridamole, adenosine or dobutamine in conjunction with SPECT or PET) stressor is applied. In general SPECT is finalized to the detection of relative regional differences in myocardial perfusion while PET adds the potential of measuring absolute regional MBF and MBF reserve. The development of ECG-gated SPECT and PET has also enabled accurate regional and global cardiac function measurements based on a true tomographic approach. The methods are relatively operator-independent and comprehensive software packages allow the evaluation of the extent and severity of regional LV dysfunction, in hypoperfused but viable myocardium, as well as of global LV ejection fraction, volumes, diastolic function and geometry (25-27).

4. Endothelial dysfunction and myocardial perfusion imaging

Another confirmation that myocardial perfusion imaging remains one of the best predictor of prognosis in patients with ischemic heart disease comes from coronary microvascular alterations in various heart diseases.

A specific alteration of coronary endothelial function has been found in patients with different diseases such as atherosclerosis (28), dilated cardiomyopathy (29) and arterial hypertension (30). However, the relevance of endothelial dysfunction to physiologic flow control has not been directly documented. Accordingly, coronary artery stenosis is still considered the only factor able to affect coronary blood flow regulation in a relevant fashion during daily life. Nevertheless, endothelium is an important factor in the integrated response of hyperemic flow, even to agents affecting vasomotor tone, through direct action on smooth muscle cells. In fact, the lack of the endothelial contribution might limit the effect of endothelium-independent agents on flow.

Several studies have actually documented abnormal flow responses to dipyridamole or atrial pacing in the myocardium supplied by angiographically normal coronary arteries in patients with dilated cardiomyopathy (31) or arterial hypertension (32) and even in patients with single vessel disease on control coronary arteries (33).

Thus far, the link between reduced vasodilator response and endothelial dysfunction has not been tested directly. However, the coincidence of both abnormalities in populations with various heart diseases suggests their possible association in the same patient and thus a potential pathophysiologic link between the two. With regard to myocardial perfusion imaging, the reduction in maximal flow capacity due to microvascular alterations causes a reduction in perfusion differences between territories perfused by angiographically normal and stenotic vessels during vasodilator stress, thus explaining the relative decrease in sensitivity of myocardial perfusion scintigraphy in the detection of single-vessel coronary artery disease (34). On the other side, microvascular dysfunction might produce regional flow abnormalities per se, thus hampering the postulated cause-effect relationship between epicardial stenosis and perfusion defect.

In agreement with this concept, Zeiher et al (35) demonstrated that coronary microvascular endothelial dysfunction was associated with a high incidence of reversible perfusion defects at stress myocardial perfusion imaging despite the absence of coronary stenosis. According to the traditional criteria, the abnormal scan results of these patients are considered to be “false positive”. In contrast, this feature might represent an actual stenosis-independent abnormality in blood flow distribution rather than the effect of technical artifacts such as attenuation or partial-volume effect. This concept seems of great relevance, as monitoring of microvascular function can also be used for assessing the efficacy of therapy. Gould (36) demonstrated that aggressive cholesterol lowering is able to reduce reversible perfusion defects induced by dipyridamole. Guethlin et al (37) showed that statin therapy improves myocardial blood flow response to adenosine independently of stenosis severity in the related vessel. The most striking feature of these findings is that the interventions thought to improve endothelial function actually improved the flow response to endothelial independent stimuli, underlining the relevance of the endothelium in the integrated tuning of vasomotor tone.

5. Functional risk assessment vs. noninvasive coronary angiography

The prognostic value of coronary artery calcium (CAC) has been consistently demonstrated in large series of patients (39-41). Current evidence also suggests that the use of CAC is

independently predictive of outcome over and above traditional cardiac risk factors. As to functional risk assessment, CAC scores are predictive of a higher likelihood of ischemia on PET myocardial perfusion imaging (42). More importantly, patients with and without ischemia on PET perfusion imaging exhibit a stepwise increase in their risk of cardiac events with increasing calcium scores. These findings suggest that imaging approaches that combine quantitative information on the anatomic burden of ischemic heart disease with its physiological consequences offer improved risk stratification over conventional approaches that use myocardial perfusion alone. However, an independent and incremental prognostic value of CAC over clinical, electrocardiographic, laboratory, echocardiographic and angiographic variables has not been demonstrated yet.

A similar consideration applies to computed tomography (CT) of the coronary arteries. Although the presence of obstructive coronary lesions at 64-slice CT angiography was a predictor of an adverse outcome (death, nonfatal myocardial infarction, unstable angina, and coronary revascularization) as compared to the patients with normal coronary arteries (43), an independent and incremental prognostic value of CT angiography over clinical, electrocardiographic, echocardiographic and scintigraphic variables has not been demonstrated. Up to now, two studies have been designed to test the impact of a combined anatomic and functional non-invasive imaging for detection and characterization of ISCHEMIC HEART DISEASE: the EVINCI study in Europe and the SPARC trial in the United States of America. While we are waiting for the results of these two trials, patients outcome in stable ischemic heart disease should be estimated using the evidences so far collected.

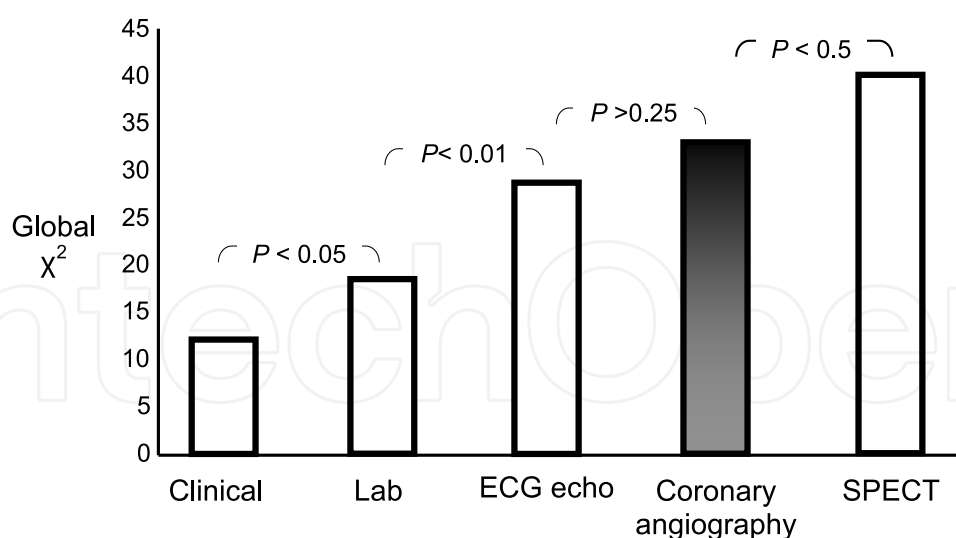
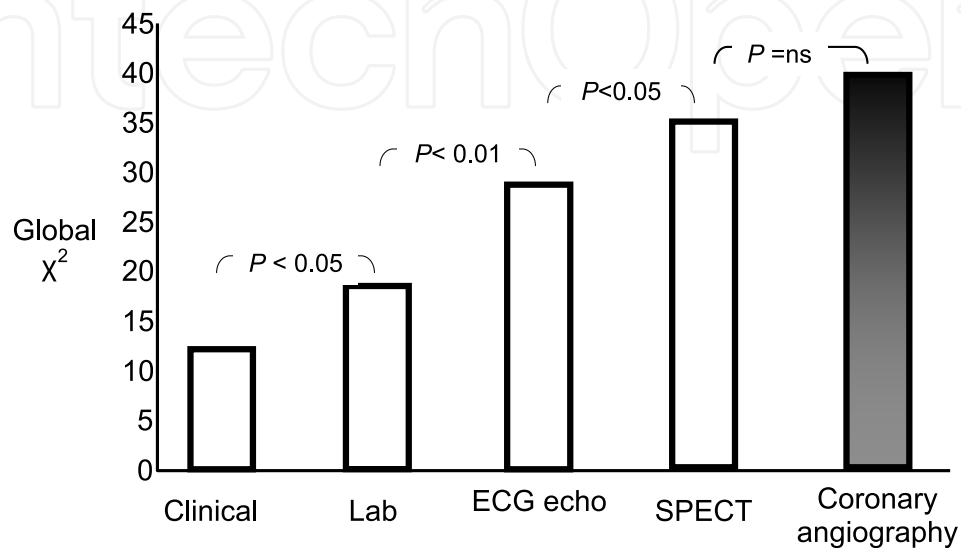
6. Myocardial perfusion imaging and revascularization

No differences in the composite of death, acute myocardial infarction and stroke was found between patients with stable ischemic heart disease, objective evidence of ischemia and significant coronary stenoses randomized to optimal medical therapy with or without percutaneous coronary intervention in the COURAGE trial (44). The relationship between extent of myocardial ischemia at gated SPECT and coronary revascularization has been explored in a subset of patients enrolled in a nuclear substudy of the COURAGE trial (45). In these patients, the addition of percutaneous coronary intervention to optimal medical therapy resulted in more effective reduction of ischemia than optimal medical therapy alone. This greater reduction in ischemic burden was associated with improvements in angina class and less reliance on nitrate therapy for symptom relief. Moreover, patients with moderate to severe ischemia randomized to percutaneous coronary intervention plus optimal medical therapy more commonly experienced a significant reduction in ischemia at follow-up compared with those receiving optimal medical therapy (78% versus 52%). Thus, the results of the nuclear substudy suggest that gated SPECT could be utilized for the identification of patients who will benefit more from coronary revascularization.

7. The proper diagnostic work-up

In patients with stable ischemic heart disease, myocardial perfusion imaging may be sometimes regarded as an unnecessary, or even redundant investigation. The study of Gimelli and Colleagues shows that myocardial perfusion abnormalities at rest and after stress are still the best predictors of cardiac event-free survival, even when compared with

an extensive diagnostic work-up. Specifically, when gated SPECT data were added to the clinical, laboratory, electrocardiographic and echocardiographic variables, the prognostic stratification significantly improved; however, when coronary angiography was added to gated SPECT, prognostic stratification did not further improve (Figure 1, top panel). On the other hand, if the information provided by gated SPECT was made available after clinical, laboratory, electrocardiographic, echocardiographic and angiographic variables, the prognostic stratification still improved significantly (Figure 1, lower panel). Thus, gated



Modified from Gimelli et al, JNucl Med 2009;50:546-53

Fig. 1. Incremental prognostic value during the diagnostic work-up. In the upper panel, the information provided by stress/ rest gated SPECT is available after clinical examination, laboratory tests, electrocardiography and echocardiography but before coronary angiography. In the lower panel, the information provided by gated SPECT is available after coronary angiography.

SPECT adds a prognostic information that is greater than that provided by coronary angiography. This observation suggests that the indications for myocardial perfusion imaging in risk stratification of patients with known or suspected ischemic heart disease should be broadened.

In current clinical practice, a functional risk assessment may conflict with a health care delivery policy oriented towards cost saving and direct reperfusion. In this respect, a recent survey of the European Society of Cardiology has shown that non-invasive functional tests are under-utilized, with wide variability between different countries (46), so that several patients without significant ischemic heart disease directly undergo invasive coronary angiography. On the other hand, coronary lesions detected by coronary angiography are often revascularized even without the evidence that either myocardial blood supply or mechanical function is altered (47). This “anatomically oriented” invasive approach may negatively affect patient management, with consequent suboptimal medical treatment, inappropriate revascularizations, additional risks and increased health costs.

8. Conclusions

Several lines of evidence, collected with different approaches, demonstrate that a physiologic risk assessment is superior to an angiographically oriented approach in prognostic stratification of patients with stable ischemic heart disease. On these basis, stress/ rest myocardial perfusion abnormalities should be known – whenever possible - before coronary angiography in order to guide decision making, provided that appropriateness and patient’s risk/ benefits ratio are correctly considered.


9. References

- [1] Emond M, Mock MB, Davis KB, Fisher LD, Holmes DR Jr, Chaitman BR, et al. Long-term survival of medically treated patients in the Coronary Artery Surgery Study (CASS) Registry. *Circulation* 1994;90:2645-57.
- [2] Mark DB, Nelson CL, Califf RM, Harrell FE Jr, Lee KL, Jones RH, et al. Continuing evolution of therapy for coronary artery disease. Initial results from the era of coronary angioplasty. *Circulation*. 1994;89:2015-25.
- [3] Gimelli A, Rossi G, Landi P, Marzullo P, Iervasi G, L'abbate A, et al. Stress/ Rest Myocardial Perfusion Abnormalities by Gated SPECT: Still the Best Predictor of Cardiac Events in Stable Ischemic Heart Disease. *JNucl Med* 2009;50:546-53.
- [4] Weiner DA, Ryan TJ, McCabe CH, Chaitman BR, Sheffield LT, Ferguson JC, et al. Prognostic importance of a clinical profile and exercise test in medically treated patients with coronary artery disease. *JAm Coll Cardiol*. 1984;3:772-9.
- [5] Mark DB, Hlatky MA, Harrell FE Jr, Lee KL, Califf RM, Pryor DB. Exercise treadmill score for predicting prognosis in coronary artery disease. *Ann Intern Med*. 1987;106:793-800.
- [6] Marwick TH, Case C, Sawada S, Rimmerman C, Brenneman P, Kovacs R, et al. Prediction of mortality using dobutamine echocardiography. *J Am Coll Cardiol*. 2001;37:754-60.
- [7] Sicari R, Pasanisi E, MD, Venneri L, MD, Landi P, BSC, Cortigiani C, MD, Picano E, MD, PHD, on behalf of the Echo Persantine International Cooperative (EPIC) and Echo Dobutamine International Cooperative (EDIC) Study Groups. Stress Echo Results

- Predict Mortality: A Large-Scale Multicenter Prospective International Study. *J Am Coll Cardiol* 2003;41:589–95.
- [8] Pollock SG, Abbott RD, Boucher CA, Beller GA, Kaul S. Independent and incremental prognostic value of tests performed in hierarchical order to evaluate patients with suspected coronary artery disease: validation of models based on these tests. *Circulation*. 1992;85:237–48.
- [9] Iskandrian AS, Chae SC, Heo J, Stanberry CD, Wasserleben V, Cave V. Independent and incremental prognostic value of exercise single-photon emission computed tomographic (SPECT) thallium imaging in coronary artery disease. *J Am Coll Cardiol*. 1993;22:665–70.
- [10] Michalodimitrakis M, Mavroforou A, Giannoukas AD. Lessons learnt from the autopsies of 445 cases of sudden cardiac death in adults. *Coron Artery Dis*. 2005;16:385–89.
- [11] Nissen SE. Pathobiology, not angiography, should guide management in acute coronary syndrome/ non-ST-segment elevation myocardial infarction: the non-interventionist's perspective. *J Am Coll Cardiol*. 2003; 41:103S–112S.
- [12] Sipahi I, Tuzcu EM, Schoenhagen P, Nicholls SJ, Chen MS, Crowe T, et al. Paradoxical increase in lumen size during progression of coronary atherosclerosis: Observations from the REVERSAL trial. *Atherosclerosis*. 2006 Jan 19; 189:229–35.
- [13] Neglia D, Michelassi C, Trivieri MG, Sambuceti G, Giorgetti A, Pratali L, et al. Prognostic role of myocardial blood flow impairment in idiopathic left ventricular dysfunction. *Circulation*. 2002;105:186–93.
- [14] Verani MS. Thallium-201 and technetium-99m perfusion agents: where we are in 1992. In: Zaret BL, Beller GA, eds. *Nuclear Cardiology: State of the Art and Future Directions*. St Louis, Mo: Mosby; 1993: 216–24.
- [15] Maddahi J, Kiat H, Friedman JD, et al. Technetium-99m-sestamibi myocardial perfusion imaging for evaluation of coronary artery disease. In: Zaret BL, Beller GA, eds. *Nuclear Cardiology: State of the Art and Future Directions*. St Louis, Mo: Mosby; 1993:191–200.
- [16] Bergmann SR. Quantification of myocardial perfusion with positron emission tomography. In: Bergmann SR, Sobel BE, editors. *Positron emission tomography of the heart*. Mount Kisco (NY): Futura Publishing; 1992. p. 97–127.
- [17] Phelps ME. *PET-Molecular imaging and its biological applications*. Springer-Verlag, New York, 2004
- [18] Bergmann SR, Herrero P, Markham J, Weinheimer CJ, Walsh MN. Noninvasive quantitation of myocardial blood flow in human subjects with oxygen-15-labeled water and positron emission tomography. *J Am Coll Cardiol* 1989;14:639–52.
- [19] Araujo LI, Lammertsma AA, Rhodes CG, et al. Noninvasive quantification of regional myocardial blood flow in coronary artery disease with oxygen-15-labeled carbon dioxide inhalation and positron emission tomography. *Circulation* 1991;83:875–85.
- [20] Krivokapich J, Huang S-C, Phelps ME, MacDonald NS, Shine KI. Dependence of $^{13}\text{NH}_3$ myocardial extraction and clearance on flow and metabolism. *Am J Physiol Heart Circ Physiol* 1982;242:H536–42.
- [21] de Jong RM, Blanksma PK, Willemsen AT, et al. Posterolateral defect of the normal human heart investigated with nitrogen-13-ammonia and dynamic PET. *J Nucl Med* 1995;36:581–5.

- [22] Bellina RC, Parodi O, Camici P, et al. Simultaneous in vitro and in vivo validation of nitrogen-13 ammonia for the assessment of regional myocardial blood flow. *JNucl Med*. 1990;31:1335–1343.
- [23] Krivokapich J, Smith GT, Huang SC, et al. ¹³N ammonia myocardial imaging at rest and with exercise in normal volunteers. Quantification of absolute myocardial perfusion with dynamic positron emission tomography. *Circulation* 1989;80:1328-37.
- [24] Hutchins GD, Schwaiger M, Rosenspire KC, Krivokapich J, Schelbert H, Kuhl DE. Noninvasive quantification of regional blood flow in the human heart using N-13 ammonia and dynamic positron emission tomographic imaging. *J Am Coll Cardiol* 1990;15:1032-42.
- [25] Germano G., Kiat H., Kavanagh P.B. et al. Automatic quantification of ejection fraction from gated myocardial perfusion SPECT. *JNucl Med* 1995; 36: 2138-2147.
- [26] Germano G, Erel J, Lewin H, Kavanagh PB, Berman DS. Automatic quantitation of regional myocardial wall motion and thickening from gated technetium-99m sestamibi myocardial perfusion singlephoton emission computed tomography. *J Am Coll Cardiol* 1997;30:1360-7.
- [27] Bateman TM, Heller GV, McGhie AI, et al. Diagnostic accuracy of rest/ stress ECG-gated Rb-82 myocardial perfusion PET: comparison with ECG-gated Tc-99m sestamibi SPECT. *JNucl Cardiol* 2006;13:24-33.
- [28] Chilian WM, Dellsperger KC, Layne SM, Eastham CL, Armstrong MA, Marcus ML, et al. Effect of atherosclerosis on the coronary microcirculation. *Am J Physiol* 1990;258: H529-H539.
- [29] Treasure CB, Vita JA, Cox DA, Fish RD, Gordon JB, Mudge GH, et al. Endothelium-dependent dilation of the coronary microvasculature is impaired in dilated cardiomyopathy. *Circulation* 1990;81:772-9.
- [30] Panza JA, Quyyumi AA, Brush JE, Epstein SE. Abnormal endothelium-dependent relaxation in patients with essential hypertension. *N Engl JMed* 1990;323:22-7.
- [31] Neglia D, Parodi O, Gallopin M, Sambuceti G, Giorgetti A, Pratali L, et al. Myocardial blood flow response to pacing tachycardia and to dipyridamole infusion in patients with dilated cardiomyopathy without overt heart failure. A quantitative assessment by positron emission tomography. *Circulation* 1995; 92:796-804.
- [32] Parodi O, Neglia D, Palombo C, Sambuceti G, Giorgetti A, Marabotti C, et al. Comparative effects of enalapril and verapamil on myocardial blood flow in systemic hypertension. *Circulation* 1997;96:864-73.
- [33] Sambuceti G, Marzullo P, Giorgetti A, Neglia D, Marzilli M, Salvadori P, et al. Global alteration in perfusion response to increasing oxygen consumption in patients with single vessel coronary artery disease. *Circulation* 1994;90:1696-705.
- [34] Beller GA, Zaret BL. Contributions of nuclear cardiology to diagnosis and prognosis of patients with coronary artery disease. *Circulation* 2000;101:1465-78.
- [35] Zeiher AM, Krause T, Schachinger V, Minners J, Moser E. Impaired endothelium-dependent vasodilation of coronary resistance vessels is associated with exercise-induced myocardial ischemia. *Circulation* 1995;91:2345-52.
- [36] Gould KL. Myocardial perfusion after cholesterol lowering. *Atheroscler Thromb* 1996;3:59-61.

- [37] Guethlin M, Kasel AM, Coppentrath K, Ziegler S, Delius W, Schwaiger M. Delayed response of myocardial flow reserve to lipid-lowering therapy with fluvastatin. *Circulation* 1999;99: 475-81.
- [38] Sambuceti G, Marzilli M, Marraccini P, Schneider-Eicke J, Gliozheni E, Parodi O, et al. Coronary vasoconstriction during myocardial ischemia induced by rises in metabolic demand in patients with coronary artery disease. *Circulation* 1997;95:2652-9.
- [39] Budoff MJ, Shaw LJ, Liu ST, Weinstein SR, Mosler TP, Tseng PH, et al. Long-term prognosis associated with coronary calcification: observations from a registry of 25,253 patients. *J Am Coll Cardiol*. 2007;49:1860-70.
- [40] Taylor AJ, Bindeman J, Feuerstein I, Cao F, Brazaitis M, O' Malley PG. Coronary calcium independently predicts incident premature coronary heart disease over measured cardiovascular risk factors: mean three-year outcomes in the Prospective Army Coronary Calcium (PACC) project. *J Am Coll Cardiol* 2005;46: 807–14.
- [41] Greenland P, LaBree L, Azen SP, Doherty TM, Detrano RC. Coronary artery calcium score combined with Framingham score for risk prediction in asymptomatic individuals. *JAMA* 2004;291:210 –5.
- [42] Schenker MP, Dorbala S, Cho Tek Hong , et al. Interrelation of coronary calcification, myocardial ischemia and outcomes in patients with intermediate likelihood of coronary artery disease: A combined positron emission tomography/ computed tomography study. *Circulation*. 2008;117:1693-1700.
- [43] Gaemperli O, Valenta I, Schepis T, Husmann L, Scheffel H, Desbiolles L, et al. Coronary 64-slice CT angiography predicts outcome in patients with known or suspected coronary artery disease. *Eur Radiol* 2008;18:1162-73.
- [44] Boden WE, O'Rourke RA, Teo KK, Hartigan PM, Maron DJ, Kostuk WJ, et al. Optimal medical therapy with or without PCI for stable coronary disease. *N Engl J Med*. 2007;356:1503–16.
- [45] Shaw LJ, Barman DS, Maron DJ et al. Optimal Medical Therapy With or Without Percutaneous Coronary Intervention to Reduce Ischemic Burden Results From the Clinical Outcomes Utilizing Revascularization and Aggressive Drug Evaluation (COURAGE) Trial Nuclear Substudy. *Circulation*. 2008;117:1283-91.
- [46] Breeman A, Hordijk-Trion M, Lenzen M, Hoeks S, Ottervanger JP, Bertrand ME et al. Euro Heart Survey on Coronary Revascularization. Treatment decisions in stable coronary artery disease: insights from the Euro Heart Survey on Coronary Revascularization. *J Thorac Cardiovasc Surg* 2006;132:1001-9.
- [47] Daly CA, Clemens F, Sendon JL, Tavazzi L, Boersma E, Danchin N, et al. Euro Heart Survey Investigators. The clinical characteristics and investigations planned in patients with stable angina presenting to cardiologists in Europe: from the Euro Heart Survey of Stable Angina. *Eur Heart J* 2005; 26:996-1010.



Coronary Angiography - Advances in Noninvasive Imaging Approach for Evaluation of Coronary Artery Disease

Edited by Prof. Baskot Branislav

ISBN 978-953-307-675-1

Hard cover, 414 pages

Publisher InTech

Published online 15, September, 2011

Published in print edition September, 2011

In the intervening 10 years tremendous advances in the field of cardiac computed tomography have occurred. We now can legitimately claim that computed tomography angiography (CTA) of the coronary arteries is available. In the evaluation of patients with suspected coronary artery disease (CAD), many guidelines today consider CTA an alternative to stress testing. The use of CTA in primary prevention patients is more controversial in considering diagnostic test interpretation in populations with a low prevalence to disease. However the nuclear technique most frequently used by cardiologists is myocardial perfusion imaging (MPI). The combination of a nuclear camera with CTA allows for the attainment of coronary anatomic, cardiac function and MPI from one piece of equipment. PET/SPECT cameras can now assess perfusion, function, and metabolism. Assessing cardiac viability is now fairly routine with these enhancements to cardiac imaging. This issue is full of important information that every cardiologist needs to now.

How to reference

In order to correctly reference this scholarly work, feel free to copy and paste the following:

Alessia Gimelli and Paolo Marzullo (2011). Physiologic Risk Assessment in Stable Ischemic Heart Disease – Functional Evaluation Versus Coronary Anatomy, *Coronary Angiography - Advances in Noninvasive Imaging Approach for Evaluation of Coronary Artery Disease*, Prof. Baskot Branislav (Ed.), ISBN: 978-953-307-675-1, InTech, Available from: <http://www.intechopen.com/books/coronary-angiography-advances-in-noninvasive-imaging-approach-for-evaluation-of-coronary-artery-disease/physiologic-risk-assessment-in-stable-ischemic-heart-disease-functional-evaluation-versus-coronary-a>

INTECH
open science | open minds

InTech Europe

University Campus STeP Ri
Slavka Krautzeka 83/A
51000 Rijeka, Croatia
Phone: +385 (51) 770 447
Fax: +385 (51) 686 166
www.intechopen.com

InTech China

Unit 405, Office Block, Hotel Equatorial Shanghai
No.65, Yan An Road (West), Shanghai, 200040, China
中国上海市延安西路65号上海国际贵都大饭店办公楼405单元
Phone: +86-21-62489820
Fax: +86-21-62489821

© 2011 The Author(s). Licensee IntechOpen. This chapter is distributed under the terms of the [Creative Commons Attribution-NonCommercial-ShareAlike-3.0 License](#), which permits use, distribution and reproduction for non-commercial purposes, provided the original is properly cited and derivative works building on this content are distributed under the same license.

IntechOpen

IntechOpen