

We are IntechOpen, the world's leading publisher of Open Access books Built by scientists, for scientists

4,800

Open access books available

122,000

International authors and editors

135M

Downloads

Our authors are among the

154

Countries delivered to

TOP 1%

most cited scientists

12.2%

Contributors from top 500 universities



WEB OF SCIENCE™

Selection of our books indexed in the Book Citation Index
in Web of Science™ Core Collection (BKCI)

Interested in publishing with us?
Contact book.department@intechopen.com

Numbers displayed above are based on latest data collected.

For more information visit www.intechopen.com



New Noninvasive Modalities in Coronary Angiography: Cardiac Computed Tomography Angiography

Ryotaro Wake and Minoru Yoshiyama
Osaka City University Graduate School of Medicine
Japan

1. Introduction

Coronary artery disease (CAD) is a leading cause of mortality and morbidity in most developed countries [1]. CAD is a common and sometimes disabling disorder, although medication therapy, percutaneous coronary intervention and coronary artery bypass grafting have developed recently. Medical doctors need to prevent from developing acute coronary syndrome. The development of non-invasive cardiac imaging tools (particularly, cardiac computed tomography, echocardiography and so on) for the diagnostic and prognostic assessments of patients is evolving evidence for various treatment strategies. Cardiac catheterization is golden standard for the diagnosis of CAD. Although the risk of adverse events for invasive coronary angiography is generally considered to be low, potential life-threatening complications can arise, including not only coronary artery dissection, but also arrhythmia, stroke, hemorrhage, myocardial infarction (MI), and death [2]. Non-invasive imaging devices for CAD have been developing, such as echocardiography, scintigraphy, computed tomography (CT) and magnetic resonance imaging (MRI) and so on. Particularly, the development of cardiac CT is remarkable in the last 10 years.

Prior report suggested a hierarchical model of efficacy to assess the contribution of diagnostic imaging to the patient management process. Level 1 is technical quality of the images. Level 2 is diagnostic accuracy, sensitivity, and specificity associated with interpretation of the images. Level 3 is whether the information produces change in the referring physician's diagnostic thinking. Level 4 is efficacy, which concerns effect on the patient management plan. Level 5 is effect of the information on patient outcomes. Level 6 is societal costs and benefits of a diagnostic imaging technology [3].

CT imaging was introduced in 1972 [4]. The ability to obtain cross-sectional images of the computer-assisted tomography, Sir Geoffrey N. Hounsfield and Allan M. Cormack were awarded the Nobel prize in Medicine in 1979.

Since a 4 detector row cardiac CT angiography was launched in 1998. Cardiac CT has experienced rapid improvement of imaging qualities with the ongoing evolution of cardiac CT. The diagnostic accuracy of the 64 detector cardiac CT to detect coronary stenoses is available. Cardiac CT is useful for the diagnosis and risk stratification of CAD. Cardiac CT presently has not been considered a routine replacement for invasive coronary angiography,

because the diagnostic accuracy of cardiac CT is not greater than that of invasive coronary angiography yet. Invasive coronary angiography is more appropriate than cardiac CT for patients with a high pretest likelihood of CAD. Cardiac CT is appropriate for stable patients with acute chest pain [5]. A recently published guideline reports several appropriate indications for cardiac CT. At First, they are symptomatic patients with intermediate likelihood of CAD. Particularly, the patients are indicated in whom stress testing, including in electrocardiography, echocardiography, and scintigraphy is not possible because of severe aortic stenosis, severe heart failure and aortic dissection etc., or the result of stress testing is equivocal or uninterpretable with acute chest pain. Secondly, they are patients with acute chest pain and intermediate likelihood of CAD but absence of ECG changes and normal myocardial enzyme levels [6]. Cardiac CT is useful for the diagnosis of CAD in complete left bundle branch block patients, because the diagnostic accuracy is slight lower with stress test of electrocardiography, echocardiography and scintigraphy [7].

The best approaches to the care of CAD, improving not only the efficacy and safety of treatments, but also the cost.

We discuss the usefulness of cardiac CT for the risk stratification of CAD.

2.1 The technique and limitation of cardiac CT imaging

The clinical value of CT for imaging of the heart has been very limited for the long time. Cardiac imaging requires a very high temporal resolution, because the heart is rapid motion. Therefore, dedicated scanner designs needed to be developed to increase acquisition speed. Furthermore, cardiac CT imaging requires providing contiguous cross-sectional images of the heart. Every displayed image must be of the same cardiac phase. Gaps may occur if adjacent images depict the heart in different phases of the cardiac cycle. Data acquisition must be triggered by the patient's electrocardiogram (ECG), image reconstruction must be synchronized to a function correlated to cardiac motion. The heart is subjected to intrinsic motion by cardiac contraction and to motion by breathing. CT imaging of the complete heart has to be performed within one single breath-hold.

Recently, the number of detectors expands from 64 to 320. With a detector width of 0.5 mm, this will be able to be coverage of about 160 mm. It can be obtained in one rotation and can be performed during one heartbeat [8-10]. This will decrease the length of the necessary breath-hold, decrease the amount of contrast agents to achieve intravascular enhancement during scan, and may be useful in patients with an inconstant heart rate or arrhythmia.

2.2 Atherosclerosis of the coronary artery

Cardiac CT has several potential applications for patients with CAD. Cardiac CT can demonstrate the morphological features of CAD and estimate ventricular function, perfusion. Recently, the visualization of coronary artery has been developing with coronary artery calcium (CAC), coronary artery stenosis.

The pathology of coronary artery is important in order to understand the image of cardiac CT, taking into account the pathology of coronary artery. CAC is a surrogate marker for coronary atherosclerotic plaque. In the coronary arteries, calcifications occur almost exclusively in the context of atherosclerotic changes [11,12]. In the most patients with acute coronary syndromes, CAC can be detected, and the amount of calcium in these patients is substantially greater than in matched control subjects without CAD [13]. With the exception of patients in the renal failure, nonatherosclerotic calcification of the coronary artery wall is

rare. The amount of CAC correlates moderately with the extent of atherosclerotic plaque burden in a coronary artery [11,12]. On the other hand, not every atherosclerotic coronary plaque is calcified. The presence or absence of CAC is not closely associated with an individual atherosclerotic plaque to rupture. And CAC is not associated with stability or instability of an individual plaque [12]. Plaques with healed ruptures almost invariably contain calcium, whereas plaque erosions are frequently not calcified.

Although there is a quantitative relationship between CAC and coronary plaque burden, there is only a weak correlation between the amount of CAC and the angiographic severity of coronary artery stenoses [11]. Cardiac CT has several potential applications for patients with coronary artery disease. Cardiac CT can demonstrate the morphological features of coronary artery disease and estimate ventricular function, perfusion. Recently, the visualization of coronary artery has been developing with CAC, coronary artery stenoses. Non-enhanced CT studies of the heart are almost exclusively performed to assess calcified structures within the heart and CAC.

The absence of detectable CAC rules out the presence of significant coronary artery stenoses with high negative predictive value [11].

2.3 Coronary calcium in cardiac CT

Non-enhanced CT studies of the heart are almost exclusively performed to assess calcified structures within the heart and coronary arteries.

Cardiac CT detects and quantifies the amount of CAC. It is a marker of atherosclerotic disease burden. Calcification does not occur in a normal coronary artery wall, it therefore indicates the presence of atherosclerosis, but is not specific for coronary artery stenoses. CAC scores predict the total atherosclerotic plaque burden.

However, the absence of detectable CAC rules out the presence of significant coronary artery stenoses with high negative predictive value [11]. Although these findings are consistent with the concept that the calcified plaque burden parallels the overall plaque burden, CAC testing is not appropriate as an alternative for angiographic disease detection, because of the modest relationship between CAC and coronary artery stenoses [14]. Because even coronary atherosclerotic plaque burden is not necessarily associated with significant coronary artery stenoses, even the detection of large amounts of calcium does not imply the presence of the significant stenoses. The CAC detection could be as a marker for CAD prognosis in asymptomatic patients. The presence and severity of CAC has independent and incremental value in the estimation of death or nonfatal MI [15]. CAC is important in the risk stratification, and noncalcified atherosclerosis is also important. Some studies against intravascular ultrasound have reported a sensitivity of 91% and 95% to detect calcified and 78% and 58% for noncalcified lesions by 16 slice CT [16,17] and increased the sensitivity to detect noncalcified lesions to 83% by 64 slice CT [18]. Because of the high CT attenuation of calcified lesions, their differentiation from fibrous and lipid-rich lesions is easy. Noncalcified plaque is consisted of lipid-rich plaques and fibrous plaques. Lipid-rich plaque (less than 50 HU) is lower CT Hounsfield attenuation numbers than fibrous plaques (50 to 120 HU) and calcified plaque (more than 121 HU) [17,19]. Patients with acute coronary syndromes were found to have a higher prevalence of noncalcified as compared with calcified plaque than stable coronary artery disease [20].

We show the algorithm to diagnose ischemic heart disease with cardiac CT in American Heart Association guideline and Japanese Circulation Society guideline.

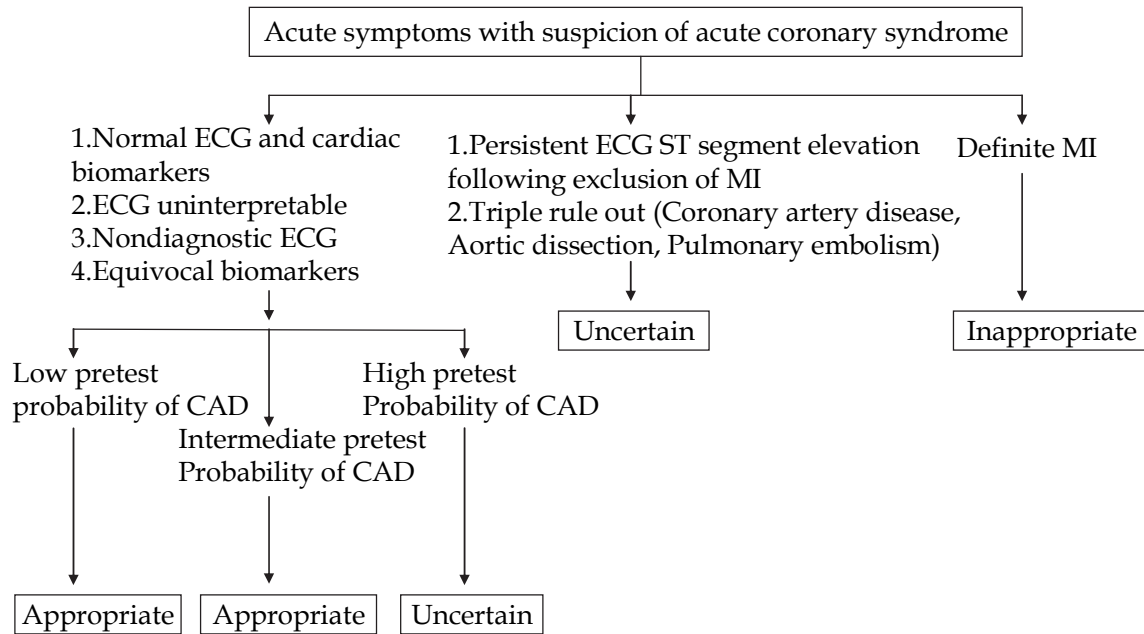


Fig. 1. Detection of CAD in symptomatic patients without known heart disease symptomatic acute presentation [21]. The stratification of pretest probability of CAD are shown in Table 1.

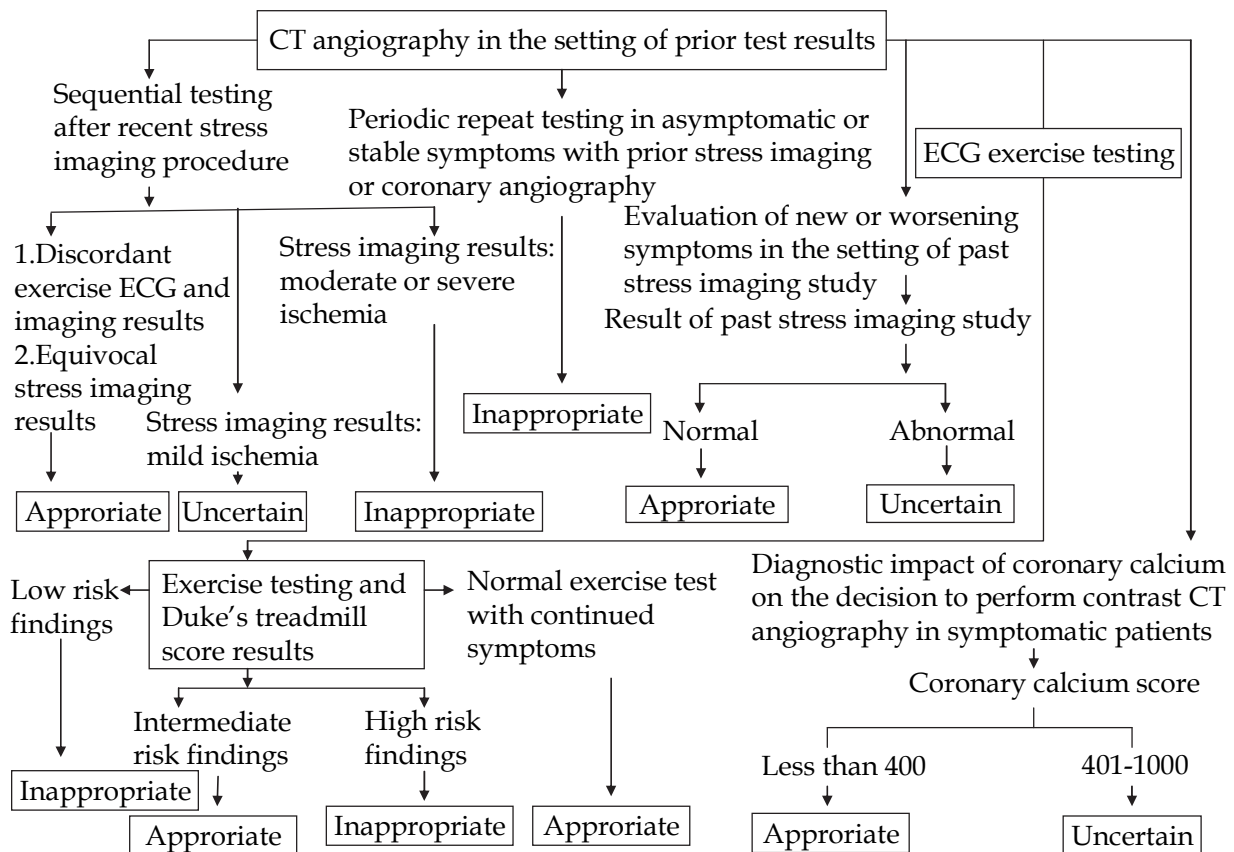


Fig. 2. Use of CT angiography in the setting of prior test results [6].

Age	Sex	Typical/Definite Angina Pectoris	Atypical/Probable Angina Pectoris	Nonanginal Chest pain	Asymptom
<39	Men	Intermediate	Intermediate	Low	Very low
	Women	Intermediate	Very low	Very low	Very low
40-49	Men	High	Intermediate	Intermediate	Low
	Women	Intermediate	Low	Very low	Very low
50-59	Men	High	Intermediate	Intermediate	Low
	Women	Intermediate	Intermediate	Low	Very low
>60	Men	High	Intermediate	Intermediate	Low
	Women	High	Intermediate	Intermediate	Low

- 1) Very low pretest probability: Less than 5% pretest probability of CAD
- 2) Low pretest probability: Between 5% and 10% pretest probability of CAD
- 3) Intermediate pretest probability: Between 10% and 90% pretest probability of CAD
- 4) High pretest probability: More than 90% pretest probability of CAD

Table 1. Pretest Probability of CAD by Age, Sex, and Symptom [22]

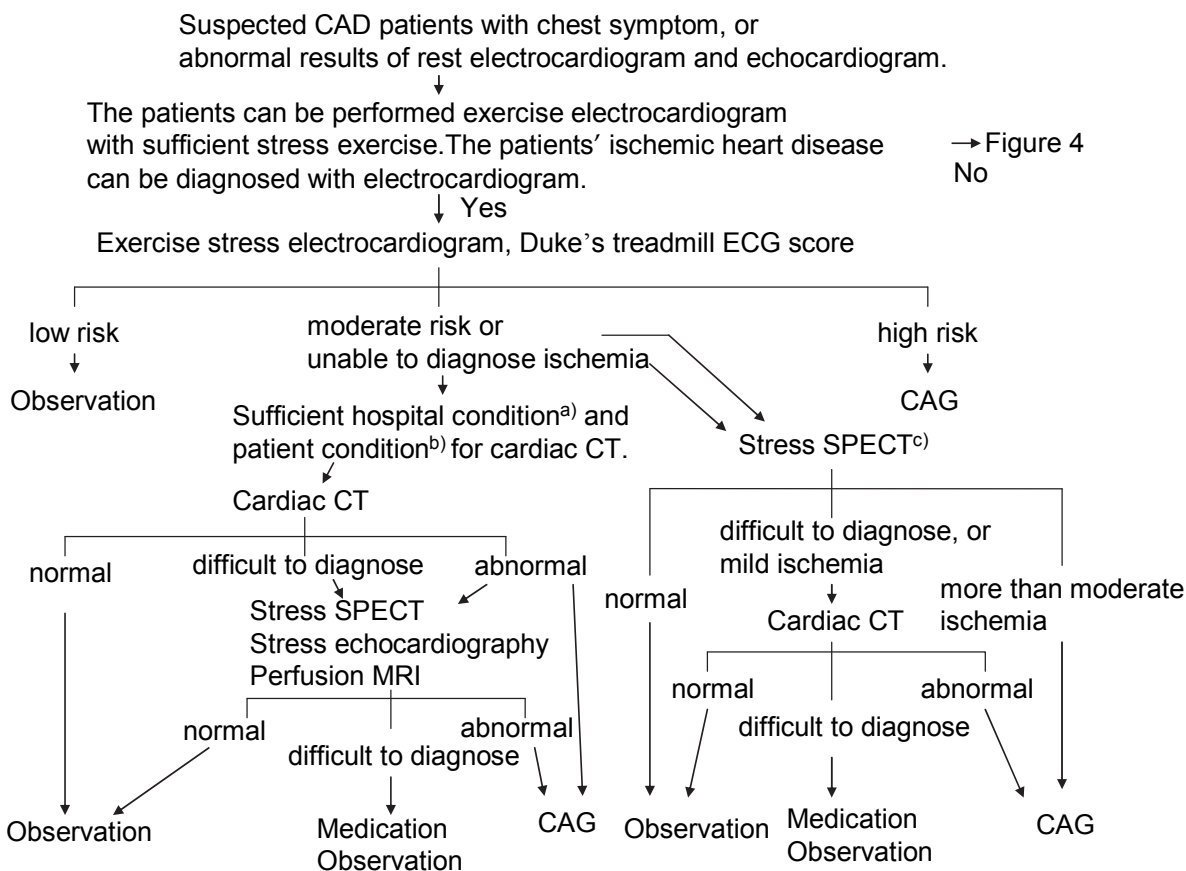


Fig. 3. Algorithm to diagnose stable angina pectoris for the patients who are able to exercise (revised Japanese Circulation Society Guideline 2009, Circulation Journal Vol 73, Suppl. III,1019-1089, 2009).

The Duke's treadmill score (Bruce protocol) is calculated as follows:

- duration of exercise in minutes - (5 x the maximal ST segment deviation
- during or after exercise, in millimeters) - (4 x the treadmill angina index).

- The angina index has a value of 0: if the patient had nonlimiting angina,
 - 1: if exercise angina occurred, and 2: if angina was the reason the patient stopped exercising. The score had a range from -25 (highest risk) to +15 (lowest risk).
- The outpatients had treadmill scores indicating low risk ($\geq +5$) and their four-year survival rate was 99% (average annual mortality rate, 0.25%). The outpatients had scores indicating high risk (< -10) and their four-year survival rate was 79% (average annual mortality rate, 5.0%)[23].

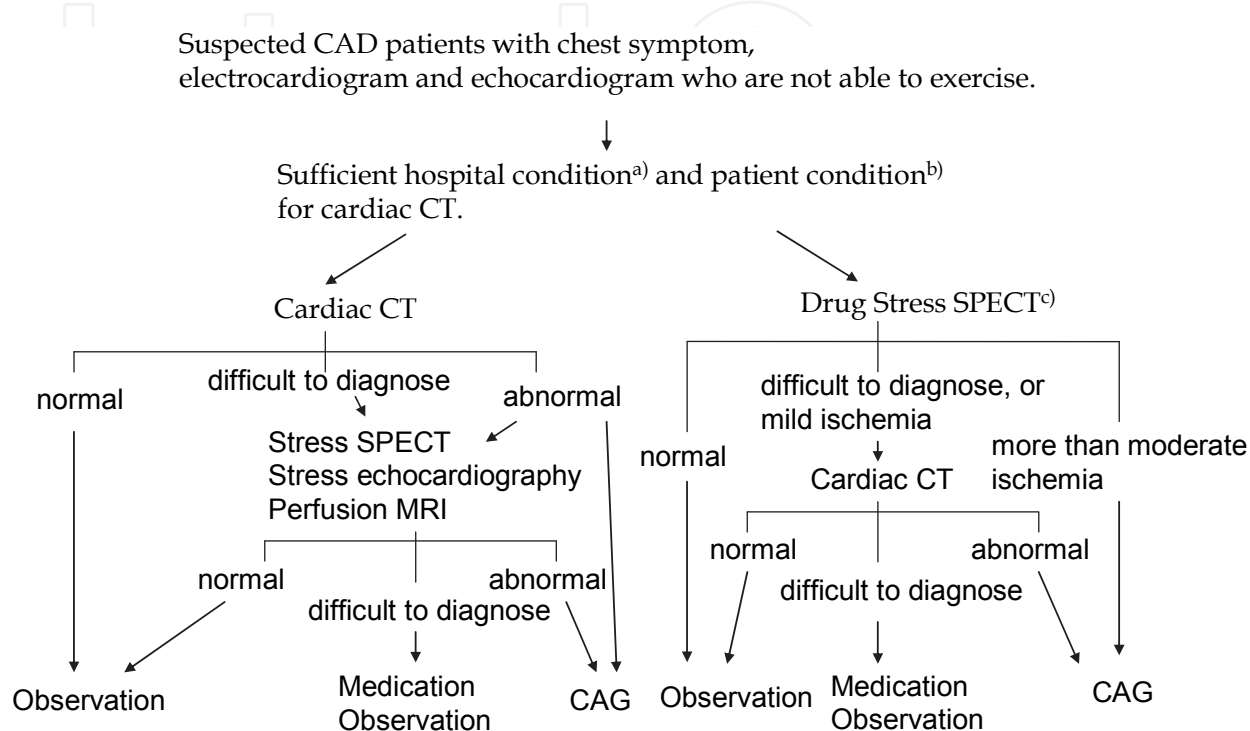


Fig. 4. Algorithm to diagnose stable angina pectoris for the patients who are not able to exercise (revised Japanese Circulation Society Guideline 2009, Circulation Journal Vol 73, Suppl. III, 1019-1089, 2009).

a. Hospital condition for cardiac CT

1. The staffs have sufficient experience on cardiac CT.
2. The hospital equips with cardiac CT which is better than 64 slice.
3. The staffs are able to show good images and work the proper reporting system.
4. The staffs understood the feature of each CAG and cardiac CT.
5. The staffs try to make the protocol for lowering the radiation exposure.

b. Patient condition for cardiac CT

1. The staffs are careful of the risk of radiation exposure in women which is less than 50 years old.
2. It is difficult to diagnose in the patients with many calcified coronary arteries, for example, the patients with hemodialysis, and the elderly patients.
3. Serum creatinin is less than 2.0 mg/dL.
4. The eGFR is more than 60 mL/min/1.73m².
5. Diabetes mellitus nephropathy patients, including to microalbuminuria are not recommended
6. The contrast allergy patients are not recommended.
7. Asthma patients are not recommended.

c. Stress SPECT

1. The stress test is recommend exercise stress, rather than drug stress.
2. The diagnosis is recommended 17 or 20 segment method to diagnose the area and degree of ischemia.
3. The staff confirm whether the patients have contraindication of the stress drug.
4. Echocardiogram and perfusion MRI can be alternative stress test depending on the facilities.
5. Less than 50% count of maximum count in the defect area is more than moderate ischemia.
6. The count between 50% and 70% count of maximum count in the defect area is mild ischemia.
7. More than 70% count of maximum count is normal myocardium.

2.4 Visualization of the coronary artery lumen in cardiac CT

Cardiac CT can be applied for visualization of the coronary artery lumen after intravenous injection of a contrast agent. The administration of beta blockers before the cardiac CT scan and the use of sublingual nitroglycerin can achieve coronary vasodilation and maximize image quality. Studies for the diagnosis of coronary artery stenoses using 64 slice CT scanning with invasive coronary angiography report sensitivities and specificities of 87-99% and 86-97%, respectively, and importantly, a negative predictive value of 98-100% [24-27].

Cardiac CT could be an efficient initial triage tool in patients with acute chest pain with low to intermediate risk, because of the high sensitivity and negative predictive value. In the symptomatic population, there is lack of study that shows an improved prognostic power of cardiac CT over other modalities including coronary artery calcium scores and carotid intima media thickness [28]. The clinical use of cardiac CT to detect plaque for purposes of risk stratification asymptomatic individuals has not recommended yet, although the clinical use of risk stratification in asymptomatic high risk individuals has been reported repeatedly [29-31].

Patency and occlusion of bypass grafts can be established with sensitivity and specificity of nearly 100% in cardiac CT, because of the large size and limited mobility of these structures [14,32,33]. But, the limitations are the detection of stenoses at the site of anastomosis to the coronary artery and in the peripheral run-off coronary artery. Metallic clips and severe coronary calcium lead to reduced sensitivity and specificity in post CABG patients. Before re-operative coronary surgery, cardiac CT can be used to define the relationship of sternal wires to cardiac and graft structures for the purpose of planning surgical reentry techniques. Cardiac CT with volume rendering images is useful to patients with known or suspected congenital coronary artery anomalies. Cardiac CT can classify the origin and the complex course of anomalous coronary arteries [34,35].

Although artifacts caused by metal and partial volume effects limit the evaluation of in-stent restenosis with 64-slice CT, high accuracy, approximately 90%, can be obtained in stents 3mm or greater in diameter [36,37].

3. Conclusion

Cardiac CT is a rapidly developing and advancing technology. The increase of radiation will reduce artifact, improve coronary artery visualization, although an excess of radiation exposure leads to cancer. Cardiac CT is useful in the non-invasive diagnosis of coronary

artery disease for the stable and acute chest pain patients, especially who cannot be sufficiently evaluated by electrocardiography, echocardiography, scintigraphy or cardiac MRI.

4. Acknowledgments


The authors thank Dr. James D. Thomas (Department of Cardiovascular Medicine, The Cleveland Clinic Foundation, Cleveland, Ohio, USA) for the education of the cardiovascular imagings.

5. References

- [1] Bonow, R.O. et al. (2002) World Heart Day 2002: the international burden of cardiovascular disease: responding to the emerging global epidemic. *Circulation* 106 (13), 1602-1605
- [2] Bashore, T.M. et al. (2001) American College of Cardiology/Society for Cardiac Angiography and Interventions Clinical Expert Consensus Document on cardiac catheterization laboratory standards. A report of the American College of Cardiology Task Force on Clinical Expert Consensus Documents. *J Am Coll Cardiol* 37 (8), 2170-2214
- [3] Fryback, D.G. and Thornbury, J.R. (1991) The efficacy of diagnostic imaging. *Med Decis Making* 11 (2), 88-94
- [4] Hounsfield, G.N. (1973) Computerized transverse axial scanning (tomography). 1. Description of system. *Br J Radiol* 46 (552), 1016-1022
- [5] Hoffmann, U. et al. (2006) Coronary multidetector computed tomography in the assessment of patients with acute chest pain. *Circulation* 114 (21), 2251-2260
- [6] Taylor, A.J. et al. ACCF/SCCT/ACR/AHA/ASE/ASNC/NASCI/SCAI/SCMR 2010 Appropriate Use Criteria for Cardiac Computed Tomography: A Report of the American College of Cardiology Foundation Appropriate Use Criteria Task Force, the Society of Cardiovascular Computed Tomography, the American College of Radiology, the American Heart Association, the American Society of Echocardiography, the American Society of Nuclear Cardiology, the North American Society for Cardiovascular Imaging, the Society for Cardiovascular Angiography and Interventions, and the Society for Cardiovascular Magnetic Resonance. *Circulation* 122 (21), e525-555
- [7] Ghostine, S. et al. (2006) Non-invasive detection of coronary artery disease in patients with left bundle branch block using 64-slice computed tomography. *J Am Coll Cardiol* 48 (10), 1929-1934
- [8] Dewey, M. et al. (2009) Noninvasive coronary angiography by 320-row computed tomography with lower radiation exposure and maintained diagnostic accuracy: comparison of results with cardiac catheterization in a head-to-head pilot investigation. *Circulation* 120 (10), 867-875
- [9] Mori, S. et al. (2004) Physical performance evaluation of a 256-slice CT-scanner for four-dimensional imaging. *Med Phys* 31 (6), 1348-1356
- [10] Uehara, M. et al. Quality of coronary arterial 320-slice computed tomography images in subjects with chronic atrial fibrillation compared with normal sinus rhythm. *Int J Cardiol*

- [11] Budoff, M.J. et al. (2006) Assessment of coronary artery disease by cardiac computed tomography: a scientific statement from the American Heart Association Committee on Cardiovascular Imaging and Intervention, Council on Cardiovascular Radiology and Intervention, and Committee on Cardiac Imaging, Council on Clinical Cardiology. *Circulation* 114 (16), 1761-1791
- [12] Burke, A.P. et al. (2003) 34th Bethesda Conference: Task force #2--What is the pathologic basis for new atherosclerosis imaging techniques? *J Am Coll Cardiol* 41 (11), 1874-1886
- [13] Pohle, K. et al. (2003) Coronary calcifications in young patients with first, unheralded myocardial infarction: a risk factor matched analysis by electron beam tomography. *Heart* 89 (6), 625-628
- [14] Miller, J.M. et al. (2008) Diagnostic performance of coronary angiography by 64-row CT. *N Engl J Med* 359 (22), 2324-2336
- [15] O'Malley, P.G. et al. (2000) Prognostic value of coronary electron-beam computed tomography for coronary heart disease events in asymptomatic populations. *Am J Cardiol* 85 (8), 945-948
- [16] Achenbach, S. et al. (2004) Detection of calcified and noncalcified coronary atherosclerotic plaque by contrast-enhanced, submillimeter multidetector spiral computed tomography: a segment-based comparison with intravascular ultrasound. *Circulation* 109 (1), 14-17
- [17] Leber, A.W. et al. (2004) Accuracy of multidetector spiral computed tomography in identifying and differentiating the composition of coronary atherosclerotic plaques: a comparative study with intracoronary ultrasound. *J Am Coll Cardiol* 43 (7), 1241-1247
- [18] Leber, A.W. et al. (2006) Accuracy of 64-slice computed tomography to classify and quantify plaque volumes in the proximal coronary system: a comparative study using intravascular ultrasound. *J Am Coll Cardiol* 47 (3), 672-677
- [19] Pohle, K. et al. (2007) Characterization of non-calcified coronary atherosclerotic plaque by multi-detector row CT: comparison to IVUS. *Atherosclerosis* 190 (1), 174-180
- [20] Hoffmann, U. et al. (2006) Noninvasive assessment of plaque morphology and composition in culprit and stable lesions in acute coronary syndrome and stable lesions in stable angina by multidetector computed tomography. *J Am Coll Cardiol* 47 (8), 1655-1662
- [21] Taylor, A.J. et al. ACCF/SCCT/ACR/AHA/ASE/ASNC/NASCI/SCAI/SCMR 2010 Appropriate Use Criteria for Cardiac Computed Tomography. A Report of the American College of Cardiology Foundation Appropriate Use Criteria Task Force, the Society of Cardiovascular Computed Tomography, the American College of Radiology, the American Heart Association, the American Society of Echocardiography, the American Society of Nuclear Cardiology, the North American Society for Cardiovascular Imaging, the Society for Cardiovascular Angiography and Interventions, and the Society for Cardiovascular Magnetic Resonance. *Circulation* 122 (21), e525-555
- [22] Gibbons, R.J. et al. (2002) ACC/AHA 2002 guideline update for exercise testing: summary article: a report of the American College of Cardiology/American Heart Association Task Force on Practice Guidelines (Committee to Update the 1997 Exercise Testing Guidelines). *Circulation* 106 (14), 1883-1892

- [23] Mark, D.B. et al. (1991) Prognostic value of a treadmill exercise score in outpatients with suspected coronary artery disease. *N Engl J Med* 325 (12), 849-853
- [24] Leschka, S. et al. (2005) Accuracy of MSCT coronary angiography with 64-slice technology: first experience. *Eur Heart J* 26 (15), 1482-1487
- [25] Mollet, N.R. et al. (2005) High-resolution spiral computed tomography coronary angiography in patients referred for diagnostic conventional coronary angiography. *Circulation* 112 (15), 2318-2323
- [26] Mowatt, G. et al. (2008) 64-Slice computed tomography angiography in the diagnosis and assessment of coronary artery disease: systematic review and meta-analysis. *Heart* 94 (11), 1386-1393
- [27] Raff, G.L. et al. (2005) Diagnostic accuracy of noninvasive coronary angiography using 64-slice spiral computed tomography. *J Am Coll Cardiol* 46 (3), 552-557
- [28] Taylor, A.J. et al. (2003) 34th Bethesda Conference: Executive summary--can atherosclerosis imaging techniques improve the detection of patients at risk for ischemic heart disease? *J Am Coll Cardiol* 41 (11), 1860-1862
- [29] Cho, I. et al. Coronary atherosclerosis detected by coronary CT angiography in asymptomatic subjects with early chronic kidney disease. *Atherosclerosis* 208 (2), 406-411
- [30] Nucifora, G. et al. (2009) Prevalence of coronary artery disease across the Framingham risk categories: coronary artery calcium scoring and MSCT coronary angiography. *J Nucl Cardiol* 16 (3), 368-375
- [31] Zeina, A.R. et al. (2008) Coronary artery disease among asymptomatic diabetic and nondiabetic patients undergoing coronary computed tomography angiography. *Coron Artery Dis* 19 (1), 37-41
- [32] Budoff, M.J. et al. (2008) Diagnostic performance of 64-multidetector row coronary computed tomographic angiography for evaluation of coronary artery stenosis in individuals without known coronary artery disease: results from the prospective multicenter ACCURACY (Assessment by Coronary Computed Tomographic Angiography of Individuals Undergoing Invasive Coronary Angiography) trial. *J Am Coll Cardiol* 52 (21), 1724-1732
- [33] Maluenda, G. et al. Perioperative outcomes in reoperative cardiac surgery guided by cardiac multidetector computed tomographic angiography. *Am Heart J* 159 (2), 301-306
- [34] Datta, J. et al. (2005) Anomalous coronary arteries in adults: depiction at multi-detector row CT angiography. *Radiology* 235 (3), 812-818
- [35] Schmid, M. et al. (2006) Visualization of coronary artery anomalies by contrast-enhanced multi-detector row spiral computed tomography. *Int J Cardiol* 111 (3), 430-435
- [36] Kumbhani, D.J. et al. (2009) Meta-analysis of diagnostic efficacy of 64-slice computed tomography in the evaluation of coronary in-stent restenosis. *Am J Cardiol* 103 (12), 1675-1681
- [37] Sun, Z. and Almutairi, A.M. Diagnostic accuracy of 64 multislice CT angiography in the assessment of coronary in-stent restenosis: a meta-analysis. *Eur J Radiol* 73 (2), 266-273



Coronary Angiography - Advances in Noninvasive Imaging Approach for Evaluation of Coronary Artery Disease

Edited by Prof. Baskot Branislav

ISBN 978-953-307-675-1

Hard cover, 414 pages

Publisher InTech

Published online 15, September, 2011

Published in print edition September, 2011

In the intervening 10 years tremendous advances in the field of cardiac computed tomography have occurred. We now can legitimately claim that computed tomography angiography (CTA) of the coronary arteries is available. In the evaluation of patients with suspected coronary artery disease (CAD), many guidelines today consider CTA an alternative to stress testing. The use of CTA in primary prevention patients is more controversial in considering diagnostic test interpretation in populations with a low prevalence to disease. However the nuclear technique most frequently used by cardiologists is myocardial perfusion imaging (MPI). The combination of a nuclear camera with CTA allows for the attainment of coronary anatomic, cardiac function and MPI from one piece of equipment. PET/SPECT cameras can now assess perfusion, function, and metabolism. Assessing cardiac viability is now fairly routine with these enhancements to cardiac imaging. This issue is full of important information that every cardiologist needs to now.

How to reference

In order to correctly reference this scholarly work, feel free to copy and paste the following:

Ryotaro Wake and Minoru Yoshiyama (2011). New Noninvasive Modalities in Coronary Angiography: Cardiac Computed Tomography Angiography, *Coronary Angiography - Advances in Noninvasive Imaging Approach for Evaluation of Coronary Artery Disease*, Prof. Baskot Branislav (Ed.), ISBN: 978-953-307-675-1, InTech, Available from: <http://www.intechopen.com/books/coronary-angiography-advances-in-noninvasive-imaging-approach-for-evaluation-of-coronary-artery-disease/new-noninvasive-modalities-in-coronary-angiography-cardiac-computed-tomography-angiography>

INTECH
open science | open minds

InTech Europe

University Campus STeP Ri
Slavka Krautzeka 83/A
51000 Rijeka, Croatia
Phone: +385 (51) 770 447
Fax: +385 (51) 686 166
www.intechopen.com

InTech China

Unit 405, Office Block, Hotel Equatorial Shanghai
No.65, Yan An Road (West), Shanghai, 200040, China
中国上海市延安西路65号上海国际贵都大饭店办公楼405单元
Phone: +86-21-62489820
Fax: +86-21-62489821

© 2011 The Author(s). Licensee IntechOpen. This chapter is distributed under the terms of the [Creative Commons Attribution-NonCommercial-ShareAlike-3.0 License](#), which permits use, distribution and reproduction for non-commercial purposes, provided the original is properly cited and derivative works building on this content are distributed under the same license.

IntechOpen

IntechOpen