

# We are IntechOpen, the world's leading publisher of Open Access books Built by scientists, for scientists

4,800

Open access books available

122,000

International authors and editors

135M

Downloads

Our authors are among the

154

Countries delivered to

TOP 1%

most cited scientists

12.2%

Contributors from top 500 universities



WEB OF SCIENCE™

Selection of our books indexed in the Book Citation Index  
in Web of Science™ Core Collection (BKCI)

Interested in publishing with us?  
Contact [book.department@intechopen.com](mailto:book.department@intechopen.com)

Numbers displayed above are based on latest data collected.

For more information visit [www.intechopen.com](http://www.intechopen.com)



# Transthoracic Echocardiography in the Assessment of Coronary Arteries

Alla Boshchenko, Alexander Vrublevsky and Rostislav Karpov  
*Cardiology Research Institute, Tomsk  
Russian Federation*

## 1. Introduction

Quantitative coronary angiography remains the reference standard for assessing coronary anatomy, measuring anatomic severity of the stenotic lesion and assisting in the process of intracoronary interventions. Thus, treatment of coronary artery disease (CAD) is performed primarily on the basis of anatomic measurements of stenosis severity, although the disease severity correlates better with physiologic disturbances which can be revealed by the analysis of coronary artery flow and coronary flow reserve (CFR). Direct invasive measurements of coronary flow signal using Doppler flow wires and catheters provide a lot of information on the pathophysiology of coronary flow dynamics (Chamuleau et al, 2001; Bax et al, 2006; Braden, 2006; Werner et al., 2006; Kaul & Jayaweera, 2008; Courtis et al., 2009). But in clinical practice, these invasive techniques are rarely applied because of the time and expense required. Alternative methodology in detecting coronary flow and CFR is positron emission tomography which is feasible but expensive and scarcely available (West & Kramer, 2009). In fact, a large-scale assessment of such important functional parameters is hampered by the lack of a reliable, low-cost, noninvasive method that might be used for this purpose (Pellikka, 2004). Some years ago transesophageal echocardiography was proposed for evaluation of coronary flow and CFR in man. However, this method demonstrates some important limitations: it is semiinvasive, and has optimal feasibility in visualizing the flow in only very proximal part of the left anterior descending coronary artery (LAD) (ranging from 69% to 97%) and right coronary artery (RCA) (ranging from 66% to 83%) which allows the assessment of transstenotic or prestenotic CFR but not poststenotic CFR (Vrublevsky et al., 2001, 2004). Until recently, transthoracic echocardiography (TTE) evaluation of the CAD was aimed at the assessment of regional and global left ventricular function (Youn & Foster, 2004). Direct transthoracic visualization of the coronary arteries was attempted in children and occasionally in adults with coronary artery anomalies, arteriovenous fistulas, and aneurysms (Harada et al., 1999; Hiraishi et al, 2000; P.C. Frommelt & M.A. Frommelt, 2004). However, with the advent of harmonic imaging, contrast agents and high-frequency transducers, direct transthoracic Doppler visualization of non-dilated arteries and measurement of coronary artery flow is now relevant in the majority of patients. The aims of this review are to outline the technical aspects of coronary artery visualization and flow measurements both at rest and with pharmacological stress, to demonstrate pathologic coronary artery flow patterns by TTE and to discuss clinical implications of TTE for patients with suspected or confirmed CAD.

## 2. How coronary arteries should be visualized by TTE

### 2.1 New technical considerations for transthoracic echocardiography evaluation of coronary arteries: high-frequency transducers, multi-frequency transducers, harmonic imaging and contrast agents

One of the first reports on TTE visualization of distal LAD as a vessel with a most superficial location (3-7 cm from skin) was presented by Fusejima et al., 1987. However, clinical application of the method was limited by a low success rate of the LAD assessment because adequate signals were available in only 35% of control subjects and 50% of patients with cardiac disease. The introduction of high-frequency (7.5-MHz) transducers allowed a more frequent visualization of distal LAD (Ross et al., 1990; Kenny & Shapiro, 1992). But a major limitation of Doppler evaluation of blood flow in distal LAD associated with a low-intensity Doppler signal caused by ultrasound attenuation was overcome with echocontrast agents alone. Several reports on echocardiographic contrast enhancement of coronary artery images have been published and shown considerable improvement of visualization rate of distal LAD. Caiati et al., 1999a, 1999b, during TTE gave a peripheral injection of Levovist, a contrast agent consisting of a suspension of galactose microbubbles, and demonstrated enhanced coronary color flow Doppler signals. Lambertz et al., 1999, reported the increase of visualization rate of mid-distal LAD during high-frequency TTE from 40% without a contrast agent to 88% with Levovist. In addition, contrast administration facilitated the positioning of the pulsed sample Doppler volume. Okayama et al., 2002, demonstrated a success rate of CFR assessment in the LAD in 70% of cases without an echocontrast agent and in 97% after a Levovist injection with particular improvement of systolic pattern quality. With the routine use of contrast, coronary flow and CFR measurements in the distal LAD become feasible in the majority of patients. Several reports gave little information on transthoracic visualization of the posterior descending coronary artery (PDA) (Voci et al., 2002; Tokai et al., 2003). Voci et al., 2002, could estimate coronary blood flow in the PDA in 76% of patients at rest, but CFR assessment was performed in 54% of patients only because of hyperventilation caused by adenosine. Tokai et al., 2003, demonstrated beneficial effect of Levovist on coronary blood flow signals in the PDA, with increase of visualization rate from 30% without a contrast agent to 86% with it.

High frequency transducers can be most successfully used for scanning the apical area, that is for examination of distal LAD or PDA. Unlike distal LAD and PDA, non-distal LAD, circumflex artery (Cx) and right coronary artery (RCA) are located too deep for TTE, and high-frequency transducers preferred by many investigators can not be used (Boshchenko et al., 2008). Standard low-frequency transducers provide a good penetration and seem to be the optimal choice for scanning the RCA, Cx and proximal and mid LAD. Unfortunately, as standard cardiac low-frequency transducers have lower resolution and lower sensitivity of Doppler exam, low success rate of visualization of non-distal coronary arteries was reported in earlier studies (Voci & Pizzuto, 2001). In recent years, the advantage of using a multifrequency (1.7- to 3.5-MHz) transducer with second tissue harmonics lies in the fact that coronary flow imaging and standard TTE can be readily alternated (Pellikka, 2004), and it is true for estimating both distal LAD and PDA, and proximal-mid segments of coronary vessels. Wideband of low ultrasound frequencies of multifrequency transducers at the exit (1.7-3.5 MHz) provides a good scanning depth which is particularly important for visualizing non-distal LAD and PDA, and second tissue harmonics enables to receive reflected ultrasonic waves of high-frequency range (3,5-7 MHz) at the entrance improving

the image quality for both near and far setting zones. According to our data the feasibility of LAD and PDA visualization with second harmonics has progressively improved, and harmonic imaging facilitated the examination considerably (**Table 1**).

<b>Authors</b>	<b>N of patients</b>	<b>Transducers, contrast agents</b>	<b>Success rate, %</b>
<b>distal LAD</b>			
Fusejima et al., 1987		high-frequency transducer	35% healthy volunteers 50% CAD patients
Hozumi et al., 1998a	23	high-frequency transducer	78
Lambertz et al., 1999	45	high-frequency transducer, contrast agent	80
Caiati et al., 1999a	56	harmonic, contrast agent	88
Lethen et al., 2003	33	high-frequency transducer	91
Boshchenko et al., 2008	150	harmonic	93
Sicari et al., 2008	1779	harmonic, contrast agent	96
<b>PDA</b>			
Krzanowski et al., 2000	50	harmonic	33
Tokai et al., 2003	50	harmonic, contrast agent	86
Takeuchi et al., 2004	151	harmonic, contrast agent	83
Otsuka et al., 2005	129	harmonic, contrast agent	97
Boshchenko et al., 2008	150	harmonic	91
<b>distal Cx</b>			
Krzanowski et al., 2000	50	harmonic	0
Boshchenko et al., 2008	150	harmonic	33

Table 1. Success rate in visualizing distal coronary arteries by TTE

## 2.2 Main ultrasonic windows, positions, views by which main coronary arteries can be visualized, and hints concerning optimization of ultrasound images of coronary arteries such as setting depth, Nyquist limit, Doppler angle, size of the sample volume

Modern, high quality ultrasound systems are required for success scanning. In most cases TTE is performed with the help of Acuson Sequoia 512 (Acuson) or HDI 5000, HDI 5000 SonoCT and iE33 (Philips). We used Vivid 7 (GE HealthCare) with 1.7-3.5 MHz narrow-band transducers with second harmonic mode (Boshchenko et al., 2008, 2009).

After obtaining optimal quality B-mode image, the search for coronary arteries is started with color Doppler mapping with or without the use of harmonics. To achieve the best image quality the sample size of color Doppler should be kept at minimum. As the Doppler velocities of coronary blood flow are low, the velocity range should be set with a low Nyquist limit (15-20 cm/s), and filters should be decreased. Too low Nyquist limit can be a cause of more color Doppler artifacts obscuring the images (<10-13 cm/s), too high Nyquist limit is not able to detect low blood flow velocity within coronary arteries (Pellikka, 2004; Korsarz & Stein, 2004; Boshchenko et al., 2008, 2009). Some ultrasound systems offer special color maps for coronary artery examination including second or third harmonics of B-mode and color Doppler mapping, low Nyquist limit, special gain for B-mode and Doppler mode, etc.

### 2.2.1 Technique of examination for each segment of main coronary arteries

There are several windows by which coronary arteries can be visualized with the patients in the supine or left decubitus positions (Krzanowski et al., 2000, 2003; Saraste et al., 2005; Boshchenko et al., 2008). Standard parasternal short- and long-axis views from second- or third intercostal space or low parasternal short- or long-axis views from fourth- or fifth intercostal space should be used. Alternatively, a modified apical 2, 3 or 5-chamber view or subcostal scanning can be performed. TTE has a very high time resolution, while spatial resolution is low due to a small size of scanning windows. So, coronary arteries appear as linear intramyocardial color fragmental structures of approximately 0.5-2.5 cm in length and 2 to 4 mm in diameter. Initially, a short part of arteries can be visualized. Then, by step-by-step movement of the transducer according to the course of the vessel, a longer fragment of arteries can be assessed.

The scanning depth for the search of proximal and mid coronary artery segments should be set at 10-15 cm. The transducer should be placed at the left parasternal position from second or third intercostal space and a modified short-axis B-view of great vessels should be obtained. The search of the left main coronary artery (LMCA) and proximal LAD can be started in B-mode (figure 1A, B) by consecutive clockwise and cranial rotation of the transducer, but color Doppler mapping which makes images clearer can also be recommended for initial search. The LMCA has approximately 1-3 cm in length, and the vessel should be visualized along its entire extension.

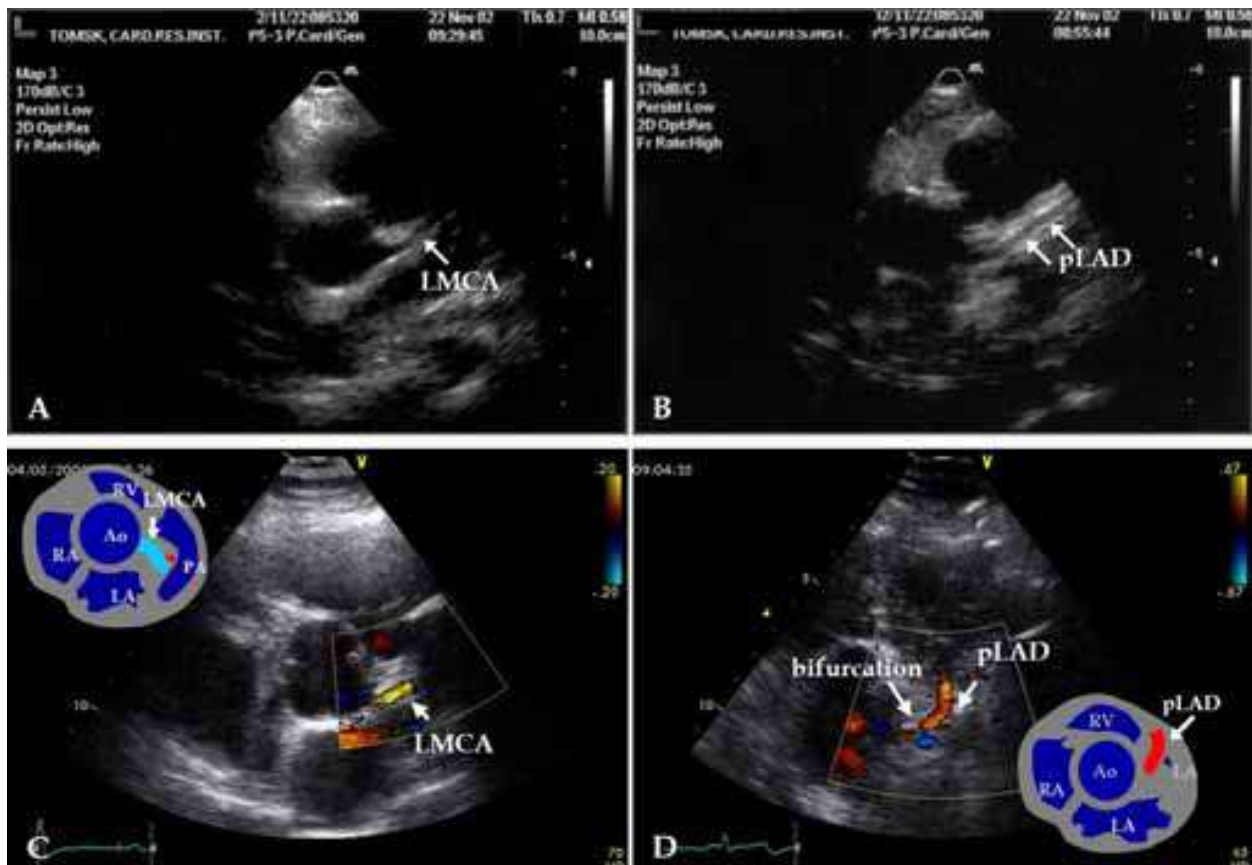


Fig. 1. Images of the LMCA and proximal LAD (pLAD). The left parasternal position, a modified parasternal short axis view of great vessels, Nyquist limit is 20-67 cm/s. A – LMCA, B-mode; B – pLAD, B-mode; C – LMCA, Color Doppler mapping; D – bifurcation of the LMCA; Color Doppler mapping.



The normal anterograde blood flow in the LMCA is identified on color Doppler map as a linear structure dawning from left coronary sinus of Valsalva and has a red or blue color depending on the placement of the transducer, anatomic features of chest and LMCA origin (figure 1C). Bifurcation of the vessel into the LAD and Cx is a marker of LMCA distal board (figure 1D). If the origin of the Cx can not be found, the LMCA and proximal LAD should be assessed as a common segment. Proximal LAD should be assessed after the LMCA by a slight change of the imaging plane in a parasternal or low parasternal short-axis B-view or by change of the position in a modified parasternal long-axis view. The origin of the first diagonal branch can be used as a distal mark of proximal LAD (fig. 2A). Mid LAD should be searched in the low left parasternal position from third- to fifth intercostal spaces and a modified short- or long-axis view of the left ventricle in the anterior interventricular groove (fig 2B, C). Distal LAD should be assessed from the low left parasternal position to a modified apical five-chamber position at varying levels using different short- and long-axis views in the anterior interventricular groove before, at or after the apex of the left ventricle (fig 2D,E). The setting depth should be reduced approximately to 6-10 cm, and the transducer may be substituted for a high-frequency one, because the location of distal LAD is superficial. The LAD is the best vessel for TTE assessment as there are clear anatomic marks for its search and segmentation, such as: anterior interventricular groove, origin of the first diagonal branch and papillary muscles. The segment of the LAD from the origin of diagonal branch to papillary muscles in the short-axis view should be assessed as its mid segment, and the segment of the LAD apical to papillary muscles should be marked as distal LAD. Apical window is usually the best one to obtain low Doppler angles for velocity measurements in the LAD. The normal anterograde blood flow in the entire LAD before the apex is identified as a red linear color signal on color Doppler map, which reflects the direction of the flow from base to apex of the left ventricle.

Unlike the LAD, the scanning depth for the RCA and Cx should be set at 12-15 cm. Proximal Cx should be visualized in the left parasternal position and a modified short-axis B-view of great vessels with the slight caudal tip of the transducer. The normal anterograde blood flow in proximal Cx is identified as a blue linear color signal on color Doppler map, reflecting the direction of the flow from the transducer (fig. 3A). There are no clear anatomic marks for the distal border of proximal Cx. Visualization of mid and distal segments of the Cx is very difficult and possible in a few patients only. Mid and distal Cx should be examined with the same position of the transducer as proximal Cx. As the mid and distal Cx are located in the coronary sulcus at the border between the left atrium and left ventricle, the angulation from heart basis to apex at the level of papillary muscles is usually required (fig 3B). The posterior papillary muscle can be used as a symbolic border between mid and distal Cx. The first or second obtuse marginal branches (OMB) presenting distal parts of the Cx can be assessed from fourth- and fifth intercostal spaces in the apical long-axis position in a modified four- or five-chamber view at either lateral or inferior wall of the left ventricle (fig. 3C).

Proximal RCA should be examined in the left parasternal position from second- or third intercostal spaces in modified short- or long-axis B-views as a structure dawning from right coronary sinus of Valsalva and lying along the anterior wall of the aorta (fig. 4A, B). It may be relatively easy to visualize proximal RCA in B-mode and Color Doppler mapping but pulse-wave Doppler examination is rarely correct because the angle between the direction of coronary blood flow and Doppler beam exceeds 60 degrees. The mid and distal RCA should be searched using Color Doppler mapping only. The subcostal position, a short-axis B-view or a modified apical two-chamber position with cranial angulation of the transducer should be used for the search of mid RCA (fig. 4C). Good quality images of the PDA - usually distal

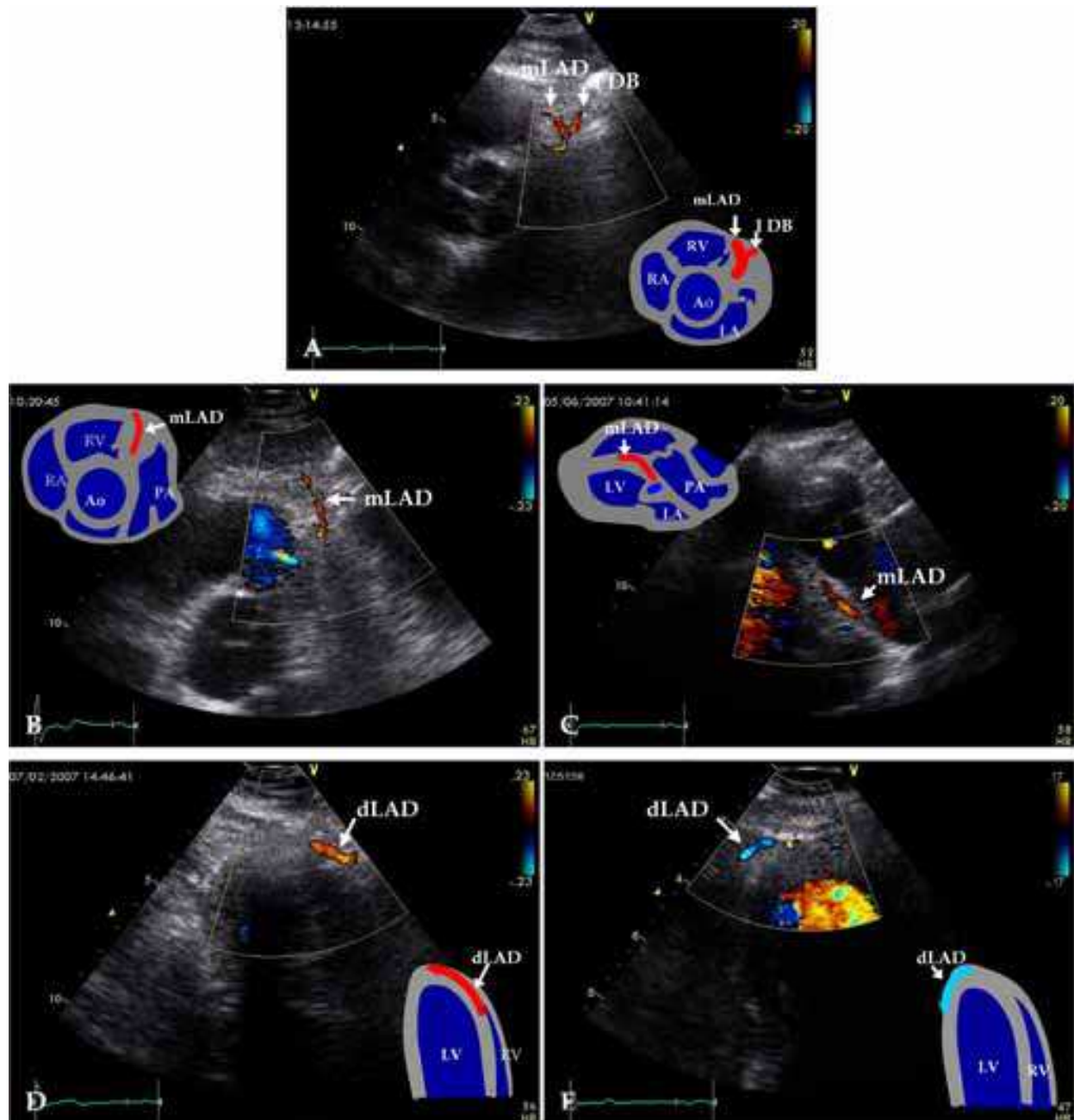


Fig. 2. Doppler Color images of the LAD. A - distal board of proximal LAD with origin of the first diagonal branch (I DB); B - mid LAD (mLAD), the left parasternal position, a modified parasternal short axis view of great vessels; C - mLAD, the left parasternal position, a modified parasternal long axis view; D - distal LAD (dLAD) before circumflexing the cardiac apex, a modified apical five chamber position; E - dLAD after circumflexing the apex of the left ventricle.

RCA - can be obtained from fourth- and fifth intercostal spaces in the apical long-axis position in a modified two- or three-chamber view with caudal tip of the transducer in the posterior interventricular groove (fig. 4D). There are no anatomic marks for segmentation of the entire RCA. The direction of the normal mid RCA and PDA flow is the same as that of the normal LAD flow.

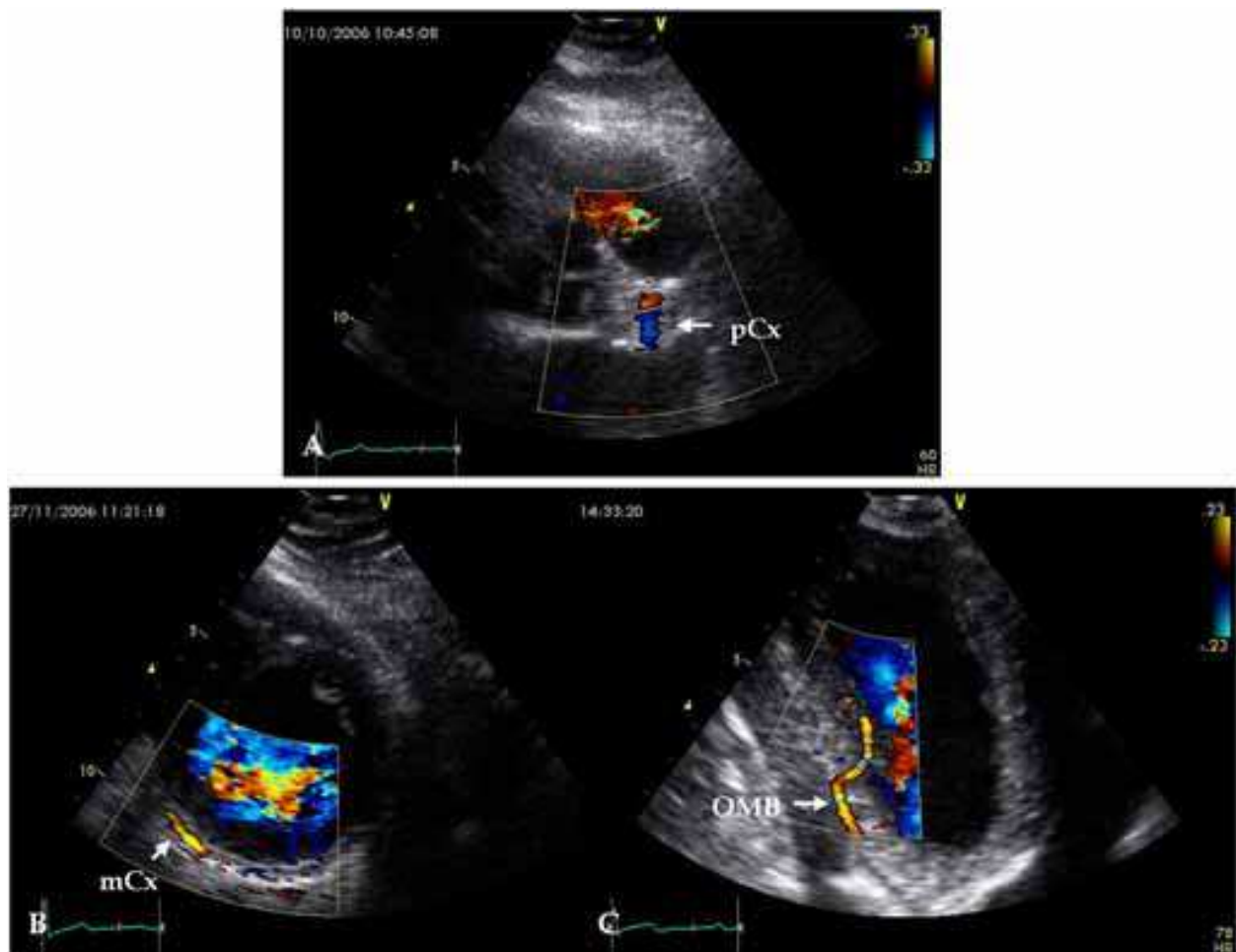


Fig. 3. Color Doppler images of the Cx, Nyquist limit is 20-33 cm/s. A – proximal Cx (pCx); the left parasternal position, a modified parasternal short-axis view of great vessels; B - mid Cx (mCx); the left parasternal position, a modified parasternal short-axis view at the level of papillary muscles; C – the first obtuse marginal branches (OMB) presenting distal Cx, the apical long-axis position, a modified five-chamber view.

### 2.2.2 Main pitfalls at visualizing coronary arteries by TTE

Main pitfalls of assessment of coronary arteries by TTE arise due to partial visualization of the vessels and anatomic features of coronary bed (Boshchenko et al., 2008). Certain large branches of coronary arteries – the intermediate coronary artery, diagonal and marginal branches can occasionally be visualized and confused with main coronary arteries, most frequently with the LAD (fig. 5A, B). It is more typical for the occluded main artery in which case the branches enlarge and take over its function (Krzanowski et al., 2003). To avoid this mistake, the LAD should be searched in the anterior interventricular groove along its entire extension with the end points in the LMCA and distal LAD. By moving step-by-step towards the aorta or downwards to the left ventricle apex without losing the LAD sight, the LAD can be correctly identified. The diagonal and marginal branches have no connections with either the LMCA or distal LAD or both.

The distinction between various vessels seen at the lateral and inferior walls of the ventricle can be challenging (Krzanowski et al., 2003). As first and second OMB is lying parallel and close to the PDA, they may be taken for the PDA. If the artery is circumflexing the posterior



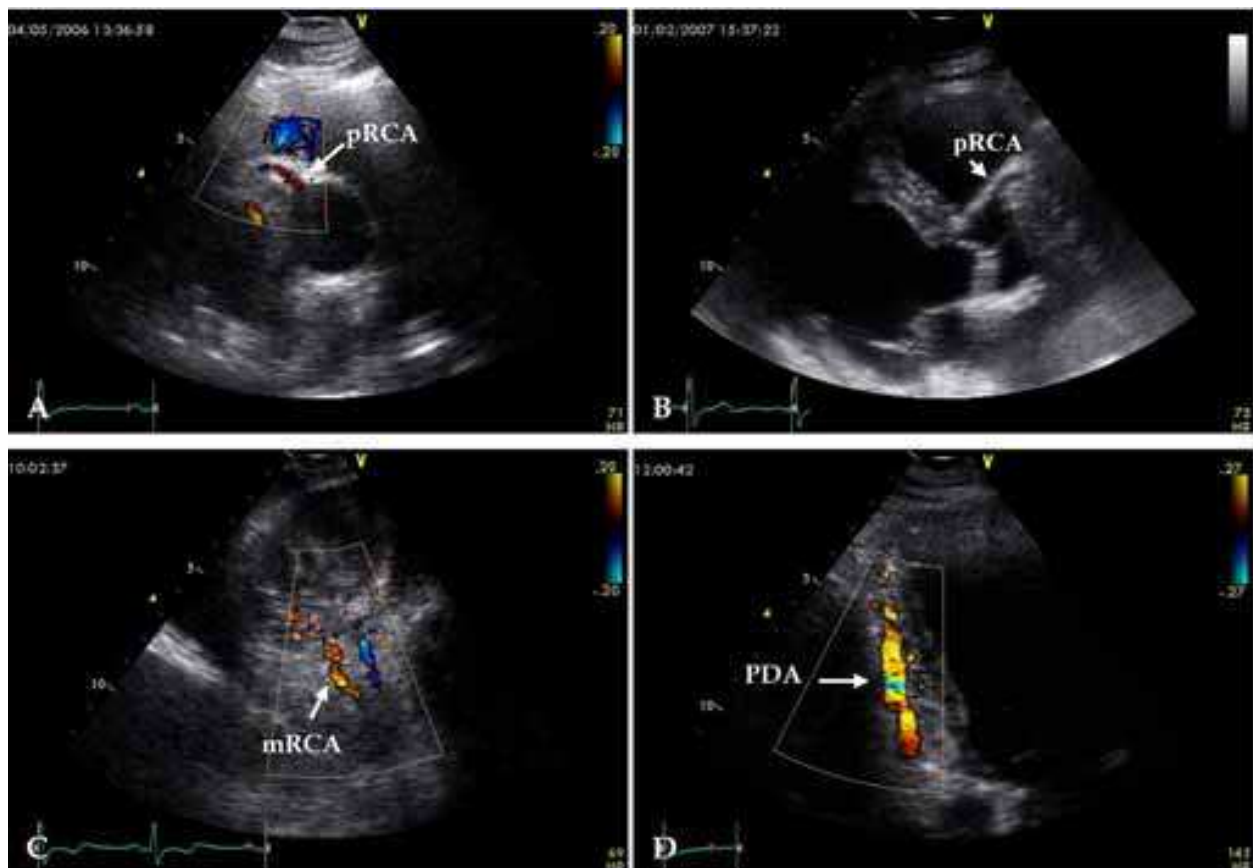


Fig. 4. Color Doppler images of the RCA. Nyquist limit is 17-20 cm/s. A – proximal RCA (pRCA); the left parasternal position, a modified parasternal short-axis view of great vessels; B – pRCA; the left parasternal position, a modified parasternal long-axis view. C – mid RCA (mRCA); a modified apical two-chamber position with cranial angulation of the transducer; D – the PDA as distal RCA, the apical long-axis position, a modified two-chamber view.

surface of the apex of the left ventricle, this vessel is detected by coronary angiography as the PDA in the majority of cases. On the other hand, if the artery is sending a branch to the posterior papillary muscle or lying next to the lateral wall of the left ventricle, this vessel is identified by coronary angiography as the OMB. The PDA which is usually a distal RCA may arise from the Cx if the left coronary artery is strongly dominant, and this fact may result in diagnostic mistakes too.

In scanning mid or distal LAD, certain extracardiac arteries visualized on color Doppler mapping may be confused with the LAD, for example, the left internal thoracic artery (LIMA). However, the pulse-wave Doppler assessment allows an accurate distinction between them: unlike coronary arterial flow which is biphasic systole-diastolic with predominant diastolic phase, the extracardiac arteries show a typical peripheral arterial flow with high velocity predominantly systolic flow and very low anterograde or retrograde diastolic flow.

As there are no clear anatomic marks for segmentation of the Cx and RCA, the pitfalls in assessing the place of coronary stenoses can be observed.

Frequently, in coronary artery occlusions and retrograde filling distal to occlusions in particular, the mistakes in distinction between coronary artery and concomitant vein may be made, i.e. mid cardiac vein may be assessed as the LAD or posterior cardiac vein – as the

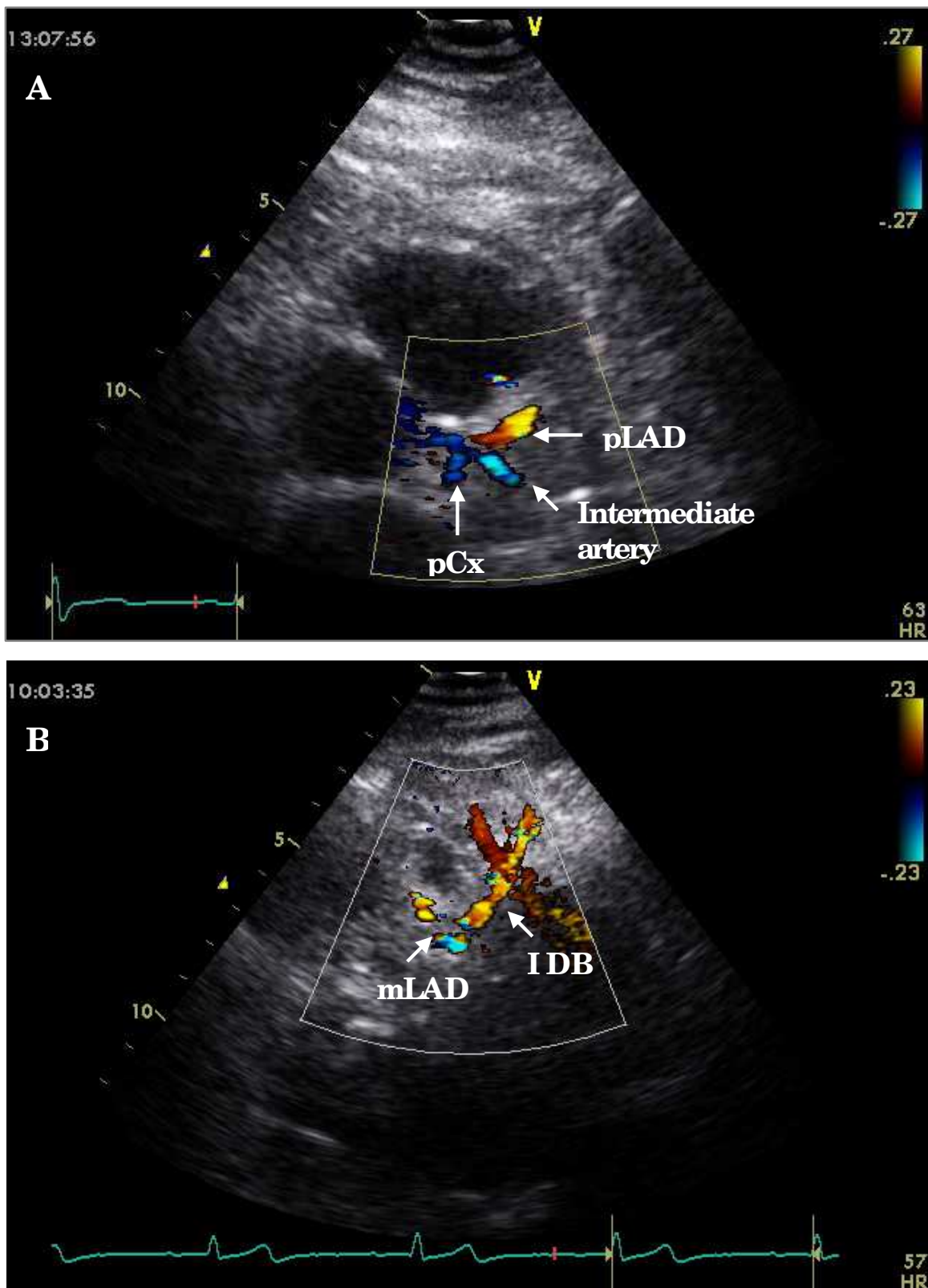


Fig. 5. Large branches of coronary arteries confused with main coronary arteries: A - the intermediate coronary artery, the diameter of which is equal to those of the LAD and Cx; pLAD - proximal LAD, pCx - proximal Cx; B - the first diagonal branch (I DB), which is larger, than mother LAD; mLAD - mid LAD.

PDA (fig 6). As veins are larger, located closer to the right ventricle than arteries and demonstrate a three-phase predominantly systolic flow with very high respiratory variations, it is not very difficult to differentiate between the vessels. Krzanowski et al., 2003 and Youn & Foster, 2004, observed that a strong signal confusing coronary artery flow may

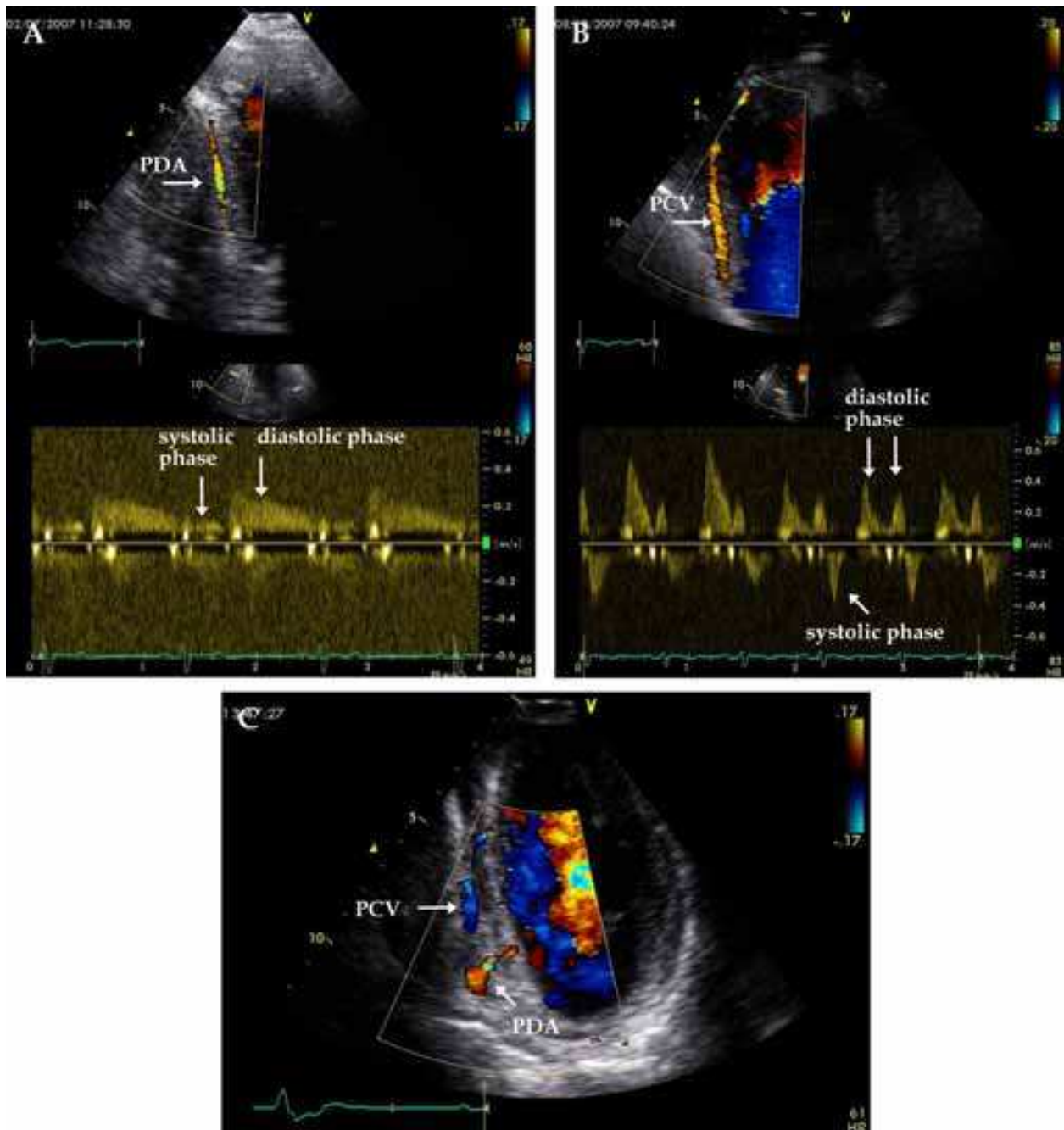


Fig. 6. Distinction between the posterior descending coronary artery (PDA) and concomitant posterior cardiac vein (PCV): A – the PDA is slighter, located closer to the left ventricle and demonstrates a biphasic predominantly diastolic flow without respiratory variations; B – the PCV is larger, located closer to the right ventricle and demonstrates a three-phase predominantly systolic flow with high respiratory variations; C- simultaneous image of the PDA and PCV.

be generated by pericardial fluid, but the flow within the pericardial sac is most pronounced in systole while the coronary artery flow is predominantly diastolic. We did not have similar difficulties in our practice.

### 2.3 Feasibility of transthoracic echocardiography in visualizing coronary arteries

Feasibility of TTE in visualizing coronary arteries with the addition of harmonics, newer transducers, and contrast agents has been reported to be as high as 100% for distal LAD and 33-97% for the PDA (table 1). Imaging of the entire Cx and proximal and mid RCA has been possible with a low rate (table 1, Kenny & Shapiro, 1992; Krzanowski et al., 2000, Watanabe et al., 2001; Saraste et al, 2006, etc.). Our data (Boshchenko et al., 2008) of TTE feasibility in the assessment of main coronary arteries with both success Color Doppler mapping and good quality of pulse-wave Doppler recording presented in tables 2 and 3 agree with the data of other authors. TTE demonstrated adequate success rate of color Doppler mapping of the LMCA, all LAD segments and PDA, and poor feasibility in detecting other segments of main coronary arteries.

Vessel	proximal segment	mid segment	distal segment
LMCA	70		
LAD	82	83	93
Cx	35	5	31
RCA	25	35	95

Table 2. Success rate of the detection of main coronary arteries by TTE (%) (Boshchenko et al, 2008)

Vessel	one segment (proximal or mid or distal)	two segments (proximal and mid or proximal and distal or mid and distal)	three segments (proximal and mid and distal)
LAD	93	92	68
Cx	35	0	0
RCA	95	51	6

Table 3. Success rate of the detection of one and more segments of each coronary artery by TTE (%) (Boshchenko et al, 2008)

Thus, although this technique requires experience and practice, and only skilled operators can be expected to achieve a 90% success rate in visualizing the coronary arteries, it is possible to use current technology in a clinical setting.

### 2.4 Normal Doppler systole-diastolic coronary flow pattern and coronary blood flow velocity at rest

#### 2.4.1 Pulse-wave Doppler recording of coronary blood flow velocity by TTE

With pulse-wave Doppler assessment efforts should be directed at maintaining the optimal Doppler angle, and size of the sample volume (Hozumi et al., 1998a, 1998b; Caiati et al, 1999a, 1999b). The angle of incidence between the Doppler beam and flow direction should



be minimized, less than 30 degrees being optimal for coronary artery. The sample volume or gate should be reduced (1.5-3.0 mm) and positioned within the coronary artery (Pellikka, 2004). We usually use a 2-3 mm gate for pulse-wave Doppler, a 3 mm gate for proximal segments and a smaller gate (2 mm) for distal segments.

#### 2.4.2 Normal Doppler systole-diastolic coronary flow pattern in coronary arteries

According to coronary physiology, most coronary flow occurs during diastole with a smaller systolic component (fig. 7) (Gould et al, 1974; Bax, 2006). So, coronary blood flow on pulse-wave Doppler image is presented as continuous, biphasic systole-diastolic flow with predominant diastolic phase and low velocities.

#### 2.4.3 Normal Doppler coronary flow velocities at rest

Transthoracic measurements of coronary flow velocity are proved to be highly reproducible and correlate with invasive measurements and measurements with positron emission tomography (Hozumi et al., 1998a; Caiati et al, 1999a, 1999b, Lethen et al., 2003; Ueno et al., 2002b). The measurements can include assessment of peak velocity, time velocity integral, and mean velocity in systole and diastole (fig. 8). But, in evaluating coronary flow, most investigators measure the diastolic component, and peak diastolic blood flow velocity is assessed most frequently as an easily and quickly estimated characteristic. The duration of diastolic and systolic flow is another potential measure (Crowley & Shapiro, 1998; Hozumi et al., 2000; Daimon et al., 2005; Youn et al., 2005).

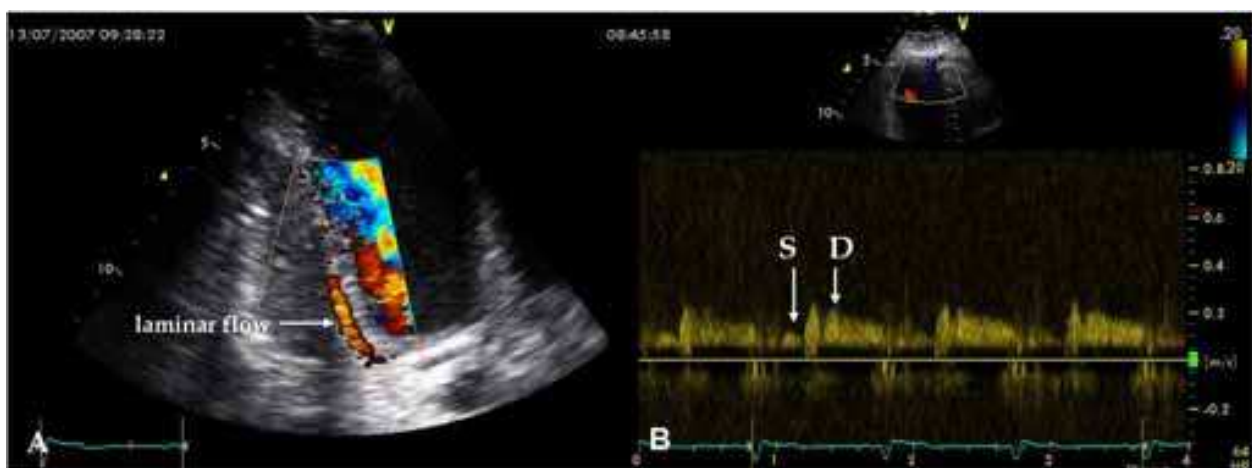

Fig. 7. Doppler examination in the PDA: A - laminar flow in the PDA is presented by red linear structure on color Doppler map; B - velocity pattern registered by pulse-wave Doppler; s - systolic phase, d - diastolic phase.

In previous works, control subjects with normal coronary angiograms and normal left ventricular systolic function showed that the peak diastolic velocity in distal LAD was  $21.2 \pm 7.9$  cm/s and the duration of diastolic coronary artery flow was  $58.5 \pm 6.4\%$  of the R-R interval at rest within the range of physiologic heart rates (60-100 b/m) (Youn et al, 2002). In studies including the participants without significant LAD stenosis, the peak diastolic velocity in distal LAD was ranging from  $21 \pm 8$  cm/s to  $28 \pm 9$  cm/s (Hozumi et al, 1998a, 1998b; Youn et al, 2002; Pizzuto et al, 2004). In our study (Boshchenko et al., 2008) with

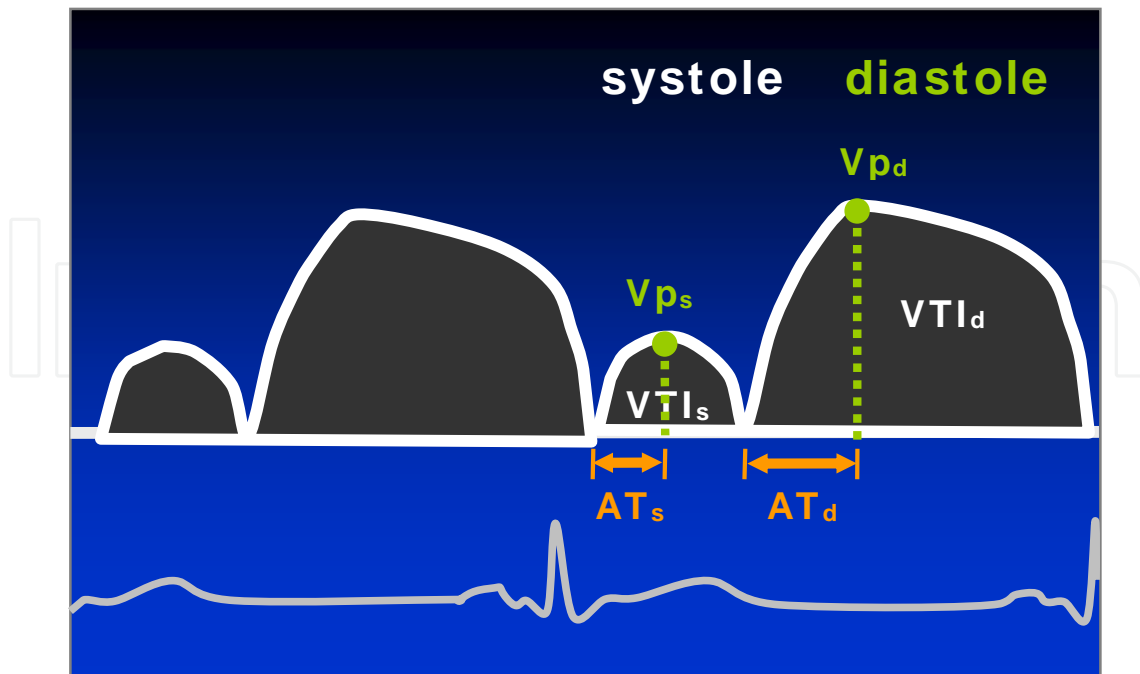


Fig. 8. Scheme of normal coronary blood flow pattern;  $Vp_s$  and  $Vp_d$  – systolic and diastolic peak coronary flow velocities,  $VTI_s$  and  $VTI_d$  – systolic and diastolic time velocity integrals,  $AT_s$  and  $AT_d$  – acceleration time in systole and diastole.

healthy volunteers the coronary flow characteristics were comparable in the conforming segments of the LAD, Cx and RCA, and coronary flow velocities showed a non-significant decrease from proximal segments to distal segments of coronary arteries (tab. 4). But the limits of normal distal LAD flow at rest have not yet been largely settled due to the multitude of variables affecting the baseline coronary flow velocity.

Characteristics	proximal LAD (n=17)	mid LAD (n=16)	distal LAD (n=17)
$Vp_s$ , cm/s	17 (15-21)	14 (12-16)	14 (13-15)
$Vm_s$ , cm/s	13 (12-16)	11 (9-12)	11 (9-12)
$VTI_s$ , cm	3.7 (3.2-4.9)	3.3 (2.7-3.7)	2.8 (2.2-3.6)
$AT_s$ , ms	118 (107-126)	111 (89-118)	111 (96-111)
$Vp_d$ , cm/s	28 (22-35)	25 (22-30)	25 (21-27)
$Vm_d$ , cm/s	22 (16-27)	19 (16-22)	19 (16-20)
$VTI_d$ , cm	10.9 (7.9-13.8)	10.6 (8.8-13.5)	10.4 (8.6-11.9)
$AT_d$ , ms	204 (126-244)	200 (155-222)	156 (133-171)

Table 4. Coronary blood flow in the LAD (mediana (range)).  $Vp_s$  and  $Vp_d$  – systolic and diastolic peak coronary flow velocity,  $Vm_s$  and  $Vm_d$  – systolic and diastolic mean coronary flow velocity,  $VTI_s$  and  $VTI_d$  – systolic and diastolic time velocity integrals,  $AT_s$  and  $AT_d$  – acceleration time in systole and diastole.

### 3. Detection of coronary artery stenosis and occlusion by TTE at rest

In adults, TTE is successfully attempted for detection of coronary artery anomalies, arteriovenous fistulas, and coronary aneurysms (Harada et al., 1999; Hiraishi et al., 2000; P.C. Frommelt & M.A. Frommelt, 2004). Thus, the overall sensitivity and specificity of TTE for accurate identification of coronary aneurysms are 95% and 99%, respectively (Hiraishi et al, 2000). Unlike aneurysms, direct visualization of atherosclerotic plaques in non-dilated or mild-dilated coronary arteries with the help of TTE is rather an exception. Accordingly, TTE can not assess correctly the structure and length of atherosclerotic plaques. Unlike computed tomography, TTE as well as coronary angiography detects coronary stenoses basing not on visualizing atherosclerotic plaque *per se* but revealing stenosis of coronary artery lumen in the site of the plaque. But coronary angiography examines anatomy of the entire coronary tree by assessing multipositional images of coronary artery lumen, while TTE assesses primarily the function of coronary vessels by detecting stenosis as focal zones with acceleration and turbulence of coronary blood flow.

#### 3.1 Direct detection of atherosclerotic plaques and assessment of coronary artery wall thickness

Direct detection of atherosclerotic plaques is rarely possible. It is reliable only in case of a major proximal plaque with acoustic shadow due to calcium (fig. 9). Maxted et al, 1998, tried to search for coronary artery stents in proximal and mid LAD, using increased echogenicity, markedly thickened walls of the artery in the stent site, and a stented lumen

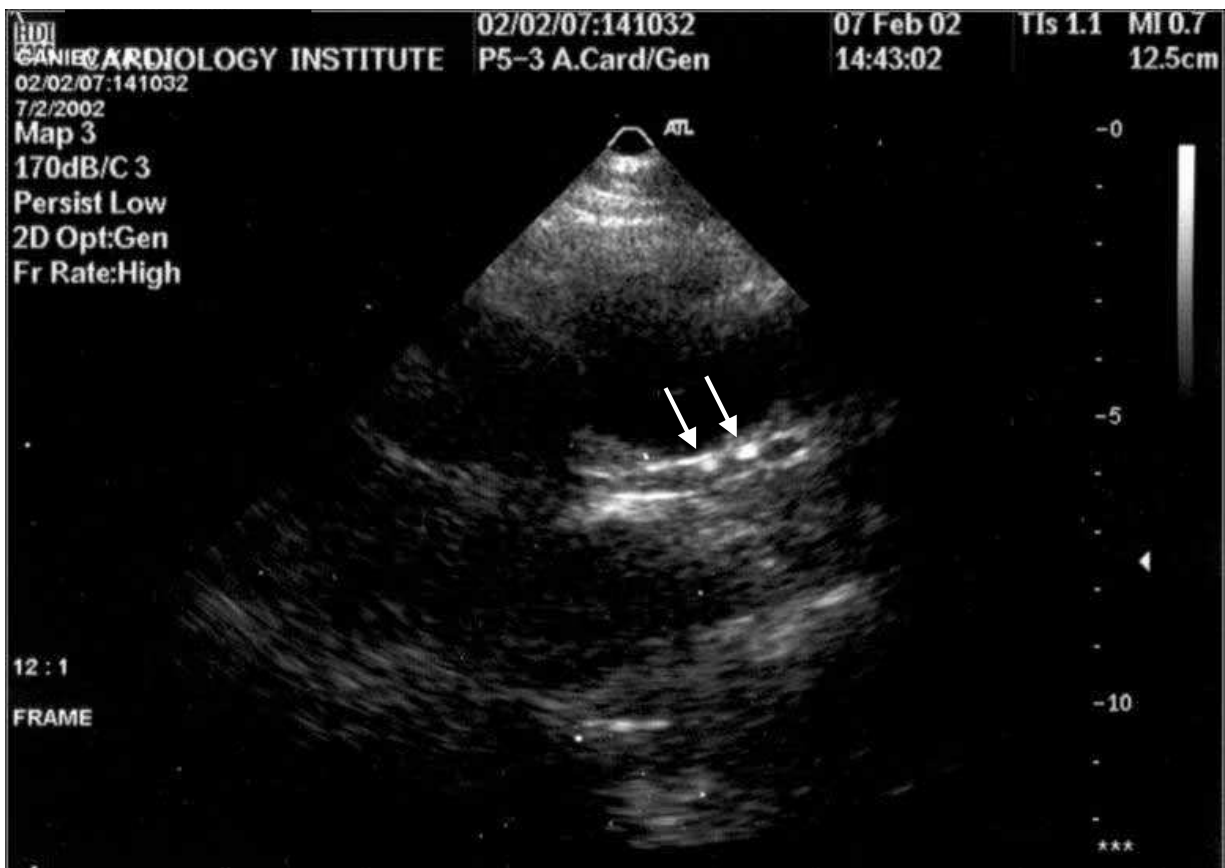

Fig. 9. The cascade proximal plaques with calcium in proximal LAD. B-mode.

with relatively straight edges and a diameter approximately equal to that of the deployed stent. Stents were determined in 10 of 13 cases, but examinations were time consuming, each taking approximately 60 minutes to obtain, process, and review the images. Despite our optimism with this technology, we realize that this method for direct assessment of the plaques and stents *per se* has several limitations.

On the other hand, intravascular ultrasound and epicardial echocardiography studies have demonstrated that coronary atherosclerosis is a diffuse pathological process and before CAD is clinical evident, >90% of the coronary artery tree is atherosclerotic. So, coronary artery wall structure, artery lumen diameter and their qualitative or quantitative changes can be predictors of coronary artery stenosis and direct markers of coronary vasomotor function (Voci & Pizzuto, 2001). High-frequency TTE using a 7.5 or 10 MHz transducer can be used to correctly and accurately measure the wall thickness and diameter of distal LAD and to detect their changes (Kenny et al., 1990; Perry et al., 2008a, 2008b). Takeuchi et al, 2006, demonstrated that wall thickness and external diameter of the LAD enlarged with the increase of the number of CAD risk factors, and wall thickness of the LAD >0.72 mm was a predictor of LAD stenosis with 74% sensitivity and 87% specificity. Perry et al, 2008a, found the wall thicknesses and external diameters of the LAD in patients with CAD to be significantly larger than those in normal volunteers, indicating atherosclerotic buildup. TTE can detect vasodilating effects of nitroglycerin and salbutamol on the LAD, correlating with peripheral vascular reactivity to these vasodilators (Perry et al, 2008b). So, TTE is a probably useful tool for noninvasive assessment of coronary vasoreactivity and provides a chance to be a surrogate marker of coronary stenosis (Perry et al, 2008a, 2008b).

### 3.2 Main Doppler principles of the detection of coronary stenosis by TTE

The detection of coronary stenosis by TTE should be performed basing on Doppler methods - color Doppler mapping and pulse-wave Doppler recoding.

#### 3.2.1 Focal aliasing and flow acceleration in the site of a significant stenosis

First, Color Doppler mapping should be used for stenoses search. Even at low Nyquist limits (13-18 cm/s), the color Doppler flow pattern in the normal coronary artery is uniformly consistent with laminar flow. The focal flow acceleration and turbulence may be detected as aliasing zone on color Doppler map and can assist in localizing the stenosis site (Krzanowski et al, 2000; Hozumi et al., 2000; Takeuchi et al., 2001; Saraste et al., 2005). Second, Doppler velocity patterns should be registered by pulse-wave Doppler. If Doppler color mapping shows a color laminar flow, Doppler velocity patterns should be obtained in the site with the best signal on color Doppler map. If a local increase of the velocity appears on Doppler colour flow map as a localized area of aliased and disturbed signal, Doppler velocity patterns should be obtained in the site of alising (fig. 10).

Third, coronary blood flow should be measured. Velocities of coronary blood flow in the stenosis site are increased compared with non-stenosis sites (both prestenotic and poststenotic) (Hozumi et al., 2000, Okayama et al., 2008). Some authors have shown redistribution of coronary flow in LAD stenosis with the increase of systolic wave due to stenosis and decrease of diastolic-to-systolic velocity ratio in the poststenotic site (Crowley & Shapiro, 1998; Daimon et al., 2005). There are transthoracic quantitative diagnostic markers of coronary artery stenosis >50%, offered by Krzanowski et al, 2000, and Anjaneyulu et al., 2008, based on the measurement of peak diastolic velocity in the stenosis site. The peak diastolic velocity >1.5 m/s has demonstrated 85% sensitivity and 88%



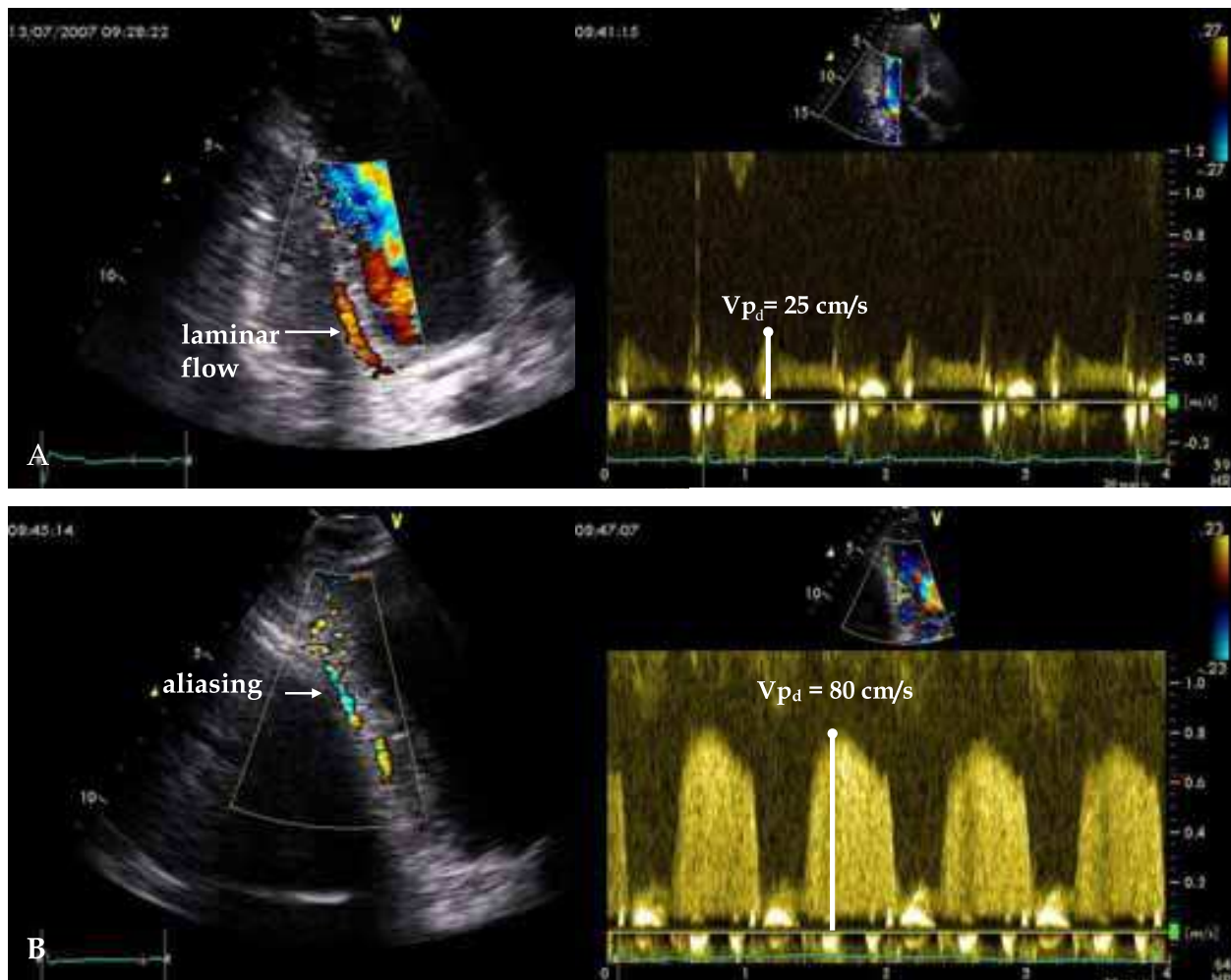


Fig. 10. Examples of Color Doppler flow mapping of distal RCA presented by PDA: upper panel – patient C. without RCA stenosis: artery color flow map is red indicating low velocity with peak diastolic flow velocity ( $V_{pd}$ ) equal to 25 cm/s; lower panel – patient S. with 75% stenosis of mid RCA: Changes in the color flow map for color aliasing in the stenosis site and distal to it with  $V_{pd}$  acceleration up to 80 cm/s.

specificity diastolic velocity  $>1.5$  m/s has demonstrated 85% sensitivity and 88% specificity in the detection of LMCA stenosis  $>50\%$  (Anjaneyulu et al., 2008). Krzanowski et al., 2000, and Saraste et al., 2005, showed that a local peak diastolic flow velocity  $>2.0$  m/s could be used as a sign of diameter reduction  $>50\%$  for all three main coronary arteries. It seems attractive and easy to detect coronary stenoses basing on the search of the aliasing zone and the measurement of peak diastolic flow velocity only, but both methods are semi-quantitative and, unfortunately, inaccurate. As previously reported, laminar peak diastolic velocity in the coronary artery is from  $0.21 \pm 0.08$  m/s (Youn et al., 2002, Hozumi et al., 1998) to  $0.28 \pm 0.09$  m/s (Pizzuto F., 2004), and the velocity will not exceed 1 m/s even in case of its 3-4-fold increase in the stenosis site. So, local peak diastolic flow velocity  $>2.0$  m/s is a highly specific, but low sensitive marker of coronary artery stenosis. On the other hand, some other reasons, such as reologic factors, heart rate, etc. can cause disturbed Doppler signal, hence local aliasing may be a highly sensitive but low specific sign of coronary stenosis. So, Hozumi et al, 2000, have observed localized aliasing by color flow mapping in 100% of patients with LAD restenosis  $>50\%$  after percutaneous transluminal coronary

angioplasty (PTCA), and 56% of patients without restenosis. Finally, both markers are strongly dependent on different hemodynamic factors (perfusion pressure, heart rate, blood pressure, myocardial mass, etc.) and technical setting (depth of scanning, quality of pulse-wave Doppler pattern, angle of incidence between the Doppler beam and flow direction, etc). So, most authors have supposed that the ratio of stenotic-to-prestenotic diastolic velocity is more correct and allows an exclusion or minimization of hemodynamic influence.

### 3.2.2 The ratio of stenotic to prestenotic blood flow velocity

To measure the stenotic to prestenotic velocity ratio, the localized color aliasing corresponding to local flow acceleration should be searched first to obtain coronary flow velocity in the stenosis site. When localized aliasing is detected, the sample volume of pulse-wave Doppler should be set at the aliasing and Doppler velocity pattern should be recorded. Then, the sample volume should be slightly moved from the aliasing to the prestenosis site and spectral Doppler recording should be made again (fig. 11).

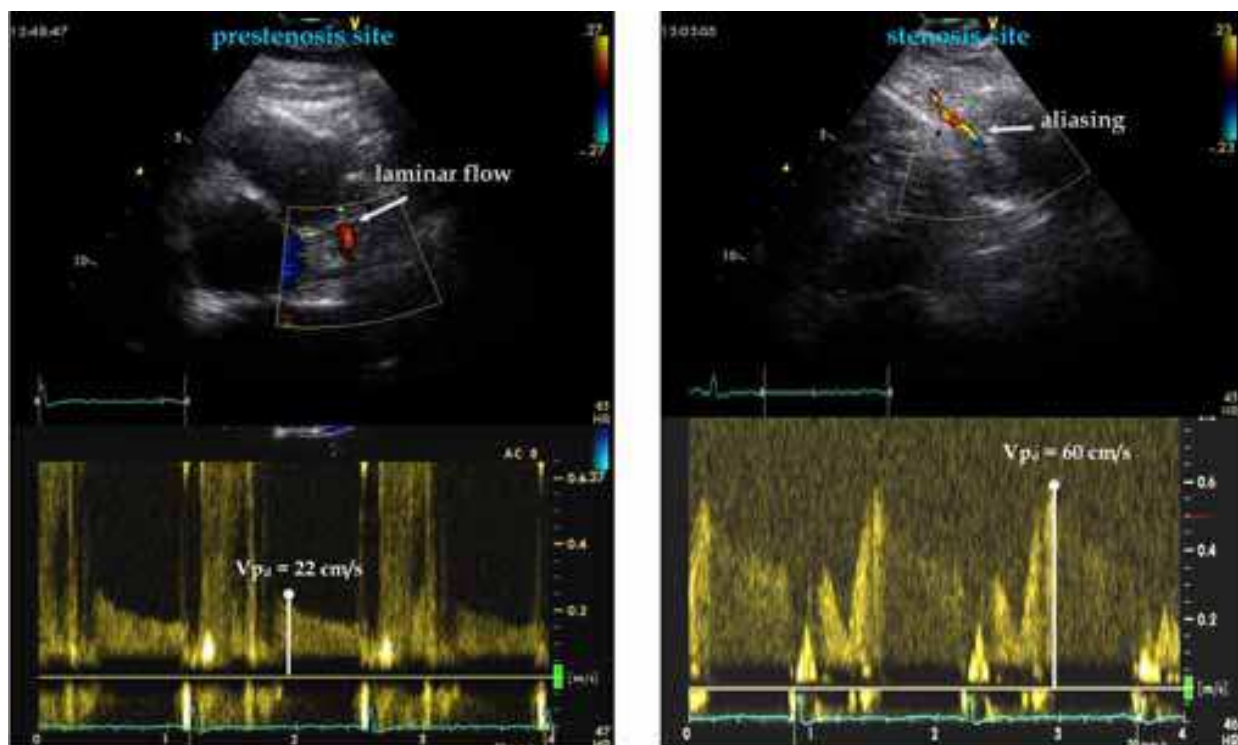


Fig. 11. 70% stenosis in mid LAD. Left panel – prestenosis site; right panel – stenosis site;  $V_{pd}$  – peak diastolic blood flow velocity. The stenotic to prestenotic flow velocity ratio is  $60/22 = 2.72 (>2.0)$ .

Krzanowski et al., 2000, and Saraste et al., 2005, determined the stenotic-to-prestenotic peak blood flow velocity ratio over than 2.0 to be a sign of >50% stenosis with 62-100% sensitivity and 92-100% specificity for the LAD, 63% sensitivity and 96% specificity for the RCA, and 38% sensitivity and 99% specificity for the Cx. The same sensitivity (86%) and specificity (93%) were demonstrated by Hozumi et al., 2000, for the ratio of prestenotic-to-stenotic mean diastolic velocity  $<0.45$  in the detection of LAD restenosis after PTCA. TTE with the use of both a local peak diastolic flow velocity  $>2.0$  m/s and stenotic-to-prestenotic peak blood flow velocity ratio  $>2.0$  permitted to reveal 48% of all LAD stenoses, 30% of all Cx

stenoses and 14% of all RCA stenoses (Krzanowski et al., 2000). Like the assessment of peak diastolic velocity this approach is easy, semi-quantitative and, though to a lesser extent, dependent on hemodynamic factors too. On the other hand, it is known that volume blood flow velocity in the prestenosis site is equal to that in the stenosis one, and, assuming the constant artery diameter and measuring diastolic time velocity integrals in both stenosis and prestenosis sites, the vessel % stenosis can be calculated according to a modified continuity equation. The feasibility of this approach for transthoracic echocardiography was demonstrated by Isaaq et al, 1998 (as cited in Vrublevsky et al., 2001). We use this concept for TTE. Diastolic time velocity integral ( $VTI_d$ ) is measured in stenosis and prestenosis sites, and the stenosis % area is calculated as: stenosis, % =  $100 \times (1 - \text{prestenotic } VTI_d / \text{stenotic } VTI_d)$  (fig.12). The sensitivity and specificity of >50% stenosis identification by a modified continuity equation in the LAD are 72% and 96%, in the Cx - 40% and 94%, and in the RCA - 50% and 93%, respectively, for the segments which are successfully visualized (Boshchenko et al., 2008). The data on all segments, successfully visualized and unvisualized, are shown in table 5.

Coronary artery	Coronary angiography		Transthoracic echocardiography					
	stenosis	stenosis	false positive	false negative	sensitivity	specificity	positive predictive value	negative predictive value
LMCA (n=100)	1	0	0	1	-	100	-	97
LAD (n=300)	55	39	8	24	56	96	79	89
Cx (n=300)	28	6	4	26	7	94	33	70
RCA (n=300)	47	21	9	35	26	93	57	78

Table 5. Diagnostic accuracy of Doppler TTE in the detection of >50% stenosis in main coronary arteries (Boshchenko et al., 2008).

Thus, TTE is highly specific for identification of coronary stenosis >50%, but, being low sensitive for Cx and RCA stenosis, may be helpful as a screening tool for LMCA and LAD stenosis >50%, limiting the use of groundless catheterization.

### 3.3 Main Doppler principles of the detection of coronary occlusion by TTE

TTE permits visualizing separate segments of coronary arteries only, and the detection of coronary occlusion as well as stenoses by TTE should be performed basing on Doppler color-coding of the flow velocity and direction. The first offered TTE sign of coronary artery occlusion was the absence of coronary blood flow on color Doppler map, and it demonstrated very low feasibility of the method (Krzanowski et al., 2000) because it was difficult to differentiate between real absence of coronary flow due to occlusion and absence of visualization of coronary artery due to TTE limitations. So, at present, TTE does not seem to be a suitable method for the assessment of acute coronary occlusions. But transthoracic color-Doppler ultrasound can be useful after acute myocardial infarction for the detection of an open LAD, reflecting adequate myocardial reperfusion basing on antegrade flow in the LAD alone or together with perforators (Voci et al, 2002).



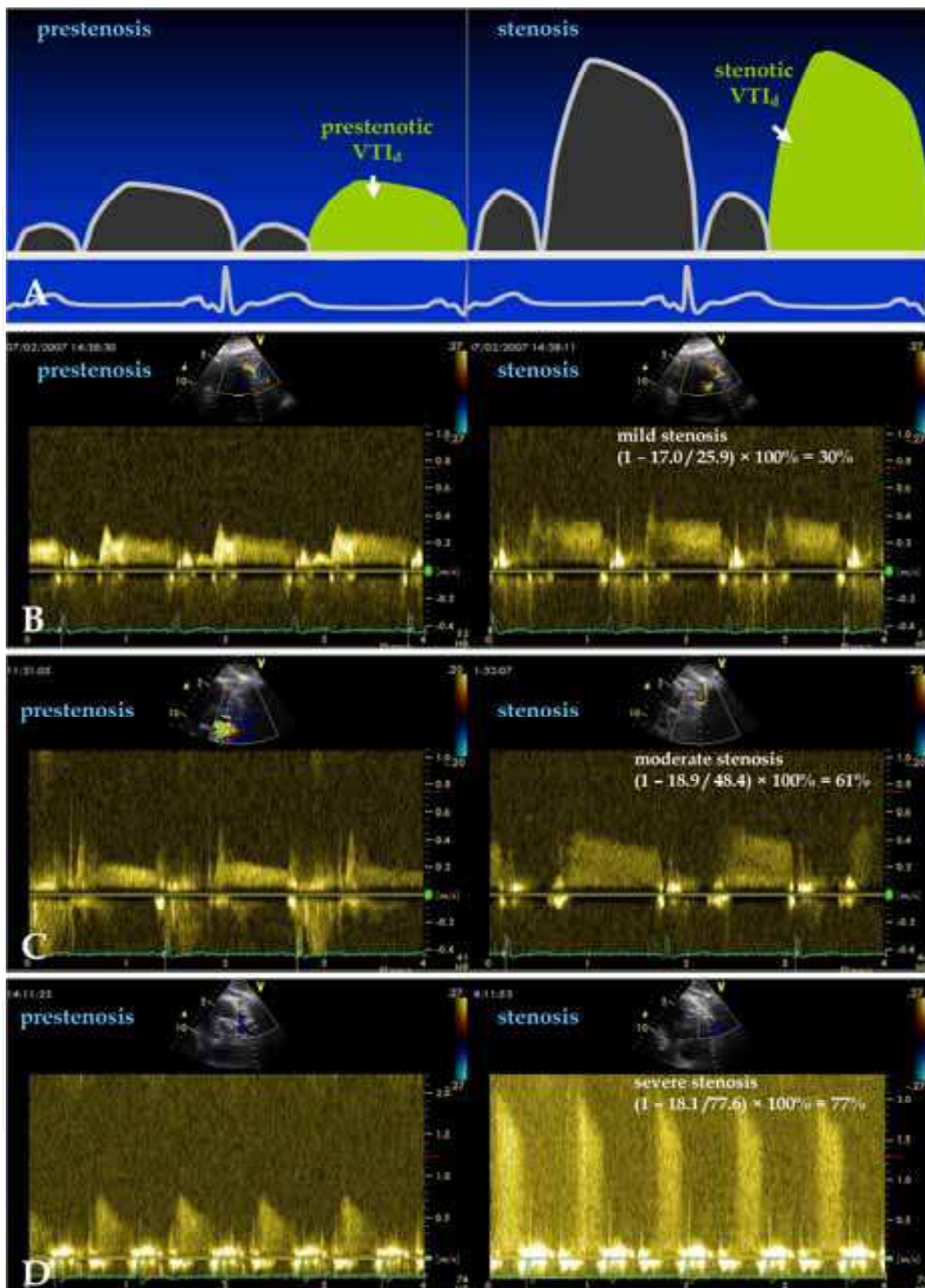


Fig. 12. Calculation of stenosis % area of proximal LAD according a modified continuity equation by TTE. A - scheme of calculation by TTE; B - example of Doppler flow patterns in patient with 35% stenosis according to coronary angiography data; C - Doppler flow patterns in patient with 60% stenosis; D - Doppler flow patterns in patient with 80% stenosis; VTI<sub>d</sub> - diastolic time velocity integral



Unlike acute occlusion, chronic total coronary occlusion (CTO) of over 1-month duration leads to the formation of stable collateral coronary pathways (Werner & Figulla, 2002; Braden, 2006; Werner et al., 2006). Recently, feasibility of TTE for the CTO identification of the LAD and RCA has been established. Watanabe et al., 2001, proposed the inversion of the coronary blood flow in the epicardial collateral vessels on color Doppler map to be a main ultrasound sign of CTO. It has been established that retrograde flow in distal LAD is a good marker of LAD occlusion with 88% sensitivity and 100% specificity (Hirata et al., 2004) and retrograde flow in the PDA is a good marker of RCA occlusion with 67% sensitivity and 100% specificity (Otsuka et al., 2005). But Pizzuto et al., 2006, doubted such a high sensitivity of TTE in the detection of LAD occlusion having revealed a retrograde flow in distal LAD in only 43% of patients with CTO and normal antegrade flow in more than half patients (55%). Angiography data demonstrate that in LAD and RCA occlusions, besides collateral flow distal to the occluded region through the connections on the epicardial surface, 63-86% of patients have intramyocardial collateral channels lying usually in the interventricular septum. According to these findings an additional examination of the retrograde flow in the septal branches of the LAD and RCA has demonstrated the increase of TTE sensitivity in the CTO detection from 88 to 96% for the LAD (Hirata et al., 2004) and from 67 to 80% for the RCA (Otsuka et al., 2005, Saraste et al., 2005).

According to our data (Boshchenko et al., 2009), the sensitivity and specificity of retrograde flow for identification of the occluded LAD by TTE in distal LAD alone were 77% and 97%, and those in both distal LAD and septal branches of the LAD - 85% and 97%, respectively. The sensitivity and specificity of retrograde flow for identification of the occluded RCA by TTE in the PDA alone were 77% and 98%, and those in both the PDA and septal branches of the RCA - 88% and 98%, respectively. Basing on these data the following order of TTE detection of LAD and RCA occlusion could be offered. First, potential epicardial collateral vessels should be examined. The retrograde flow in distal LAD will be a highly specific marker of LAD occlusion, and the retrograde flow in the PDA will be a sign of RCA occlusion, respectively. In this case, the examination can be stopped. Second, if the flow in distal LAD and RCA is antegrade, the septal (intramyocardial) collateral pathways of the LAD and RCA should be examined additionally, because 8% of patients with LAD CTO and 11% of patients with RCA CTO demonstrate an inversion of the flow direction in the septal branches only (Boshchenko et al, 2009) (fig. 13). Unlike the LAD and RCA, low success rate of visualization of the Cx does not allow the use of TTE for CTO detection.

TTE detection of CTO is based on the identification of coronary blood flow direction alone without the assessment of the rest Doppler coronary flow velocities and, thus, it does not depend on the hemodynamic conditions of the patients and does not require discontinuation of the therapy including antianginal, hypotensive, and antiarrhythmic drugs. So, TTE can be used in unstable patients, patients with life-threatening rhythm and conductance disturbances. TTE can be rather an attractive non-invasive method with little time consumption and good specificity in standardized approach, answering the principal question - whether the LAD or RCA is chronically opened or closed. The length and accurate site of CTO can not be assessed by TTE.

#### **4. Noninvasive assessment of coronary flow reserve in main coronary arteries by TTE**

Over the last two decades it has been demonstrated that measurements of coronary flow reserve (CFR) are a diagnostic approach providing a lot of additional information on the

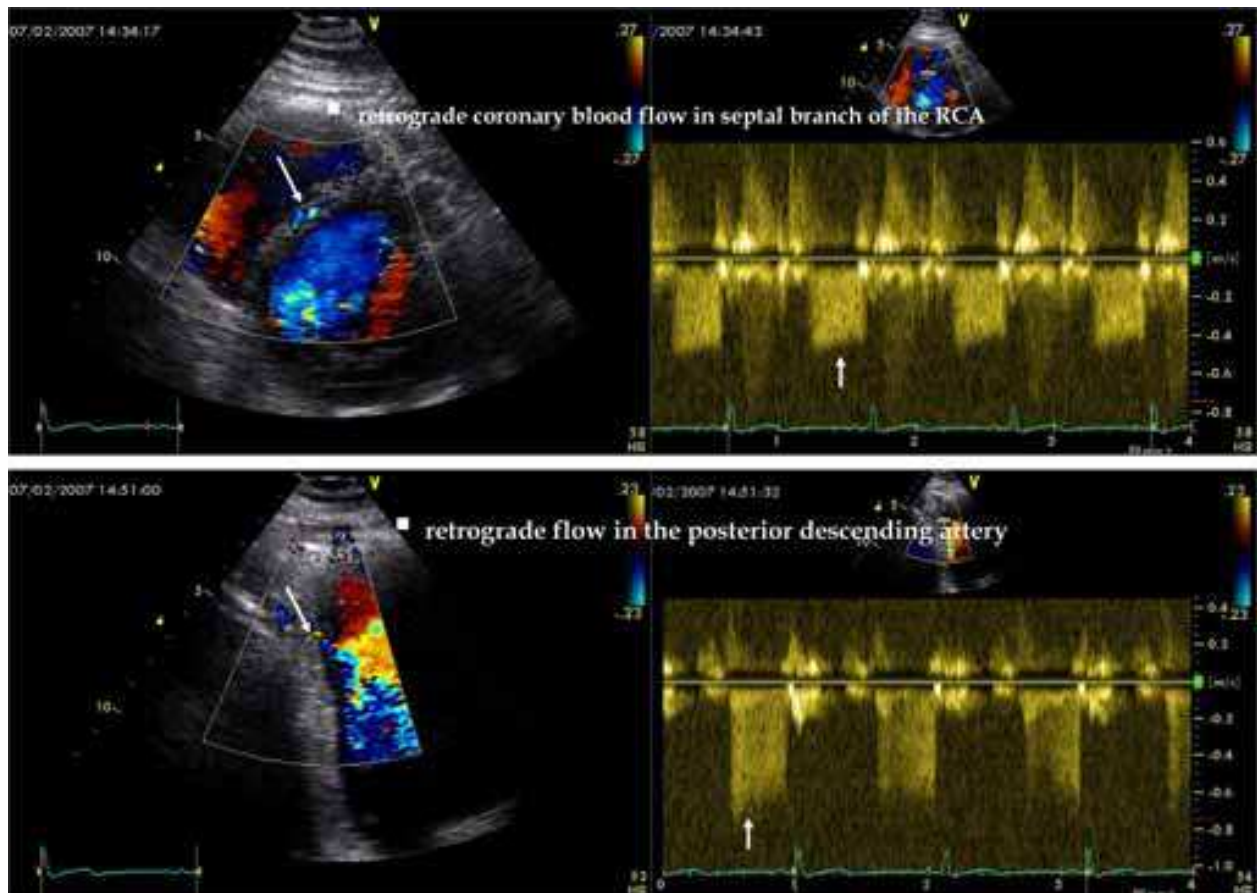


Fig. 13. Patient B. Proximal occlusion of the right coronary artery (RCA). Examples of the retrograde coronary blood flow in septal branch of the RCA and in the PDA (intramyocardial and epicardial collateral flow, respectively).

function of coronary artery and assisting in the decision-making process of cardiac interventions. Reserve of coronary blood flow is defined as the ability of coronary flow volume to increase under maximal coronary hyperemia when compared with coronary flow volume at rest. Coronary flow velocity correlates well with flow volume, and measurements of the ratio of hyperemic-to-rest coronary flow velocity can substitute direct measurements of the ratio of hyperemic-to-rest flow volume. At present, intracoronary Doppler with adenosine or papaverine infusion remains to be the reference standard for the assessment of coronary flow velocity reserve (CFVR) *in vivo*. In normal coronary bed, microvascular flow at rest is low-optimal for the maintenance of wall perfusion, and it increases at stress due to maximal peripheral vasodilatation according to myocardial demand; normal epicardial coronary artery with a high degree of elasticity under these conditions demonstrates a high CFVR. In agreement with experimental and intracoronary wire studies (Gould et al., 1974; Gould & Lipscomb, 1974), three main mechanisms, alone or in combination, may explain why coronary flow does not increase or even decreases during adenosine infusion in stenosis. First, in mild, moderate or tight severe stenoses, CFVR reflects the state of microcirculation to a greater degree. Epicardial stenoses induce increased resistance to flow, and microvascular resistant vessels already are dilated maximally at rest to maintain the basal flow. Therefore, a hyperemic stimulus results in a smaller increment of poststenotic flow, and the change of flow or the ratio of hyperemic-to-rest flow are less, and CFVR distal

to the stenosis site is reduced. Second, in incompletely calcified severe coronary stenosis, the coronary artery preserves some degree of elasticity and may collapse during adenosine infusion allowing a decrease in intraluminal tense pressure, which is induced by flow acceleration in the stenosis site. This collapse may translate distally into a damped flow producing at times a coronary steal effect. Third, prestenotic collaterals may be opened at stress, causing coronary redistribution from the critically hypoperfused bed to less stenotic regions. So, CFVR should be measured in the most distal part of the epicardial artery for assessing its function along the entire length.

TTE is a good method for detection of distal flow in the LAD and PDA (usually distal RCA), and it has the main advantage among other noninvasive technologies being valid for easy, fast, direct assessment of distal CFVR. That is particularly important in cases of repeated monitoring of stenosis progressive changes. Hozumi et al, 1998a, 1998b, performed the first validation of TTE comparing CFVR in the LAD with simultaneous intracoronary Doppler guide wire assessment. TTE reflected invasive measurement of coronary flow velocity and CFVR accurately, and the agreement between the two methods was 0.97 for averaged diastolic and systolic peak velocities, 0.98 for diastolic peak velocity and 0.97 for CFVR. A very good correlation was observed between TTE and intracoronary Doppler guide wire not only for the LAD (Caiati et al., 1999a, 1998b; Lethen et al., 2003) but for the PDA as well (Ueno et al., 2002b). The correlation ranging from 0.79 to 0.97 has been reported for noninvasive techniques compared with invasive ones in cases of decision-making process (Hozumi et al., 1998a, 1998b; Caiati et al., 1999a, 1998b) and intracoronary intervention (Lethen et al., 2003). Thus, TTE can be used as a possible substitute of the invasive method for correct clinical measurement of CFVR, particularly in the LAD.

#### **4.1 Comparison and choice of optimal stress agents for transthoracic measurement of CFR**

A variety of agents can be used as vasodilators to examine CFVR by TTE including adenosine, dipyridamole and dobutamine with or without additional atropine (Pellikka, 2004; Korsarz & Stein, 2004). All drugs have potent endothelium-independent vasodilating properties, but act by different mechanisms. Dobutamine increases metabolic myocardial demand inducing the rise of rate-pressure product, and accordingly contributes to the increase of coronary flow. Both adenosine and dipyridamole induce coronary arteriolar vasodilatation associated with hyperemic coronary flow as a result of stimulation of adenosine A<sub>2</sub>-receptors on arteriolar smooth-muscle cells causing vasorelaxation.

As dobutamine stress echocardiography is widely available, it is appropriate to consider a combination of CFVR examinations and these tests (Pellikka, 2004). But dobutamine infused with the traditional rate of 5-10-20 mcg/kg/min induces a smaller acceleration of the flow and lower CFVR than adenosine as a reference standard (Meimoun et al., 2006). Similar CFVR values can be obtained with two drugs at peak dobutamine infusion only (with the infusion rate of 40 mcg/kg/min). But it is not always possible in patients with positive dobutamine stress echocardiography and chest pain. Furthermore, CFVR assessment with recording of the LAD or RCA flow velocity at each step is time-consuming and requires an average of 25-30 minutes. A number of technical difficulties during TTE with dobutamine also must be stressed because a high heart rate and consequently a reduced diastolic filling time and increased myocardial contractility can impair good-quality recording of the coronary flow pattern. This is particularly true for very high heart rates at peak stress test.



Like intracoronary Doppler wire assessment of CFVR, adenosine, a direct coronary vasodilator, seems to be a drug of the first choice for TTE. Intravenous adenosine has a short half-life (8-10 seconds) inducing rapid onset of vasodilatation and resulting in short examination periods. CFVR assessment may be performed at bedside within a few minutes. Adenosine should be infused intravenously at the rate of 140 mcg/kg/min for 2 minutes. Coronary flow velocities are measured before and immediately after the cessation of adenosine infusion. But if simultaneous evaluation of regional function is necessary, repeated infusion of adenosine is required, and the effect of ischemic preconditioning can be observed. Adenosine may be a cause of adverse effects, attributed to nonselective stimulation of the A1-, A2B-, and A3-receptors, because of its lack of specificity for the A2-receptors. Among these effects, arterial hypotension, dyspnea and chest discomfort are frequent and tend to impair LAD flow velocity recording during hyperemia.

Dipyridamole is an indirect vasodilator, decreasing the cellular uptake of adenosine and increasing its endogenous level. Compared with adenosine, the duration of the infusion is longer (0.56 mg/kg for 4 minutes or 0.84 mg/kg for 6 minutes) and, depending on the dose administered and infusion rate, its effects can last up to 30 minutes allowing a combined CFVR and wall motion evaluation. Peak vasodilating activity is obtained 2 to 4 minutes after the cessation of dipyridamole infusion. In agreement with the comparative TTE study of Lim et al, 2000, dipyridamole with the infusion rate of 0.56 mg/kg may induce lower CFVR than adenosine, and CFVR value, achieved with adenosine, can be obtained with dipyridamole infusion rate of 0.84 mg/kg only. Adverse effects after dipyridamole infusion appear slowly and have a less intensity than those after adenosine, without marked dyspnea and arterial hypotension. Both adenosine and dipyridamole are contraindicated in patients with active asthma or severe chronic obstructive pulmonary disease with wheezing. The vasodilative effect of both drugs is reversed by antagonists, such as methylxanthines, which compete for the A2 receptor, and therefore, foods and drinks containing xanthines (chocolate, coffee, tea, colas, etc.) should be avoided for at least 12 hours before testing.

In summary, adenosine should be a drug of choice for TTE, if CFVR assessment is required in one artery only. If combined evaluation of regional function and CFVR assessment in the LAD or both the LAD and PDA are planned, the choice should be made in favor of dipyridamole with the infusion rate of 0.84 mg/kg. Dobutamine could be a good alternative to adenosine and dipyridamole for CFVR assessment in patients with contraindications to both drugs or scheduled dobutamine stress echocardiography. If echocontrast infusion is necessary, a separate intravenous line should be made.

## **4.2 Cut-off level for normal and pathologic CFVR**

### **4.2.1 TTE calculation of CFVR**

For CFVR assessment, the correction of angle incidence between the Doppler beam and flow direction may be used; however, as evaluation is performed on the basis of ratio values, the absolute velocity is of less importance. However, the angle should not change between the baseline and hyperemic phases of the test, so the differences in blood flow velocity can still be compared. After obtaining the baseline and hyperemic coronary flow velocities, CFVR should be expressed as the ratio of coronary flow velocity under maximal vasodilatation to coronary flow velocity at rest (fig.14) (Picano et al., 1999; Korcarz & Stein, 2004).

Various investigators consider that the peak diastolic flow velocity ( $V_{pd}$ ), mean diastolic flow velocity ( $V_{md}$ ), and average peak diastolic flow velocity ( $AV_{pd}$ ) can be used as a reference parameter for CFVR assessment.  $V_{pd}$ , being a most easily and quickly measured



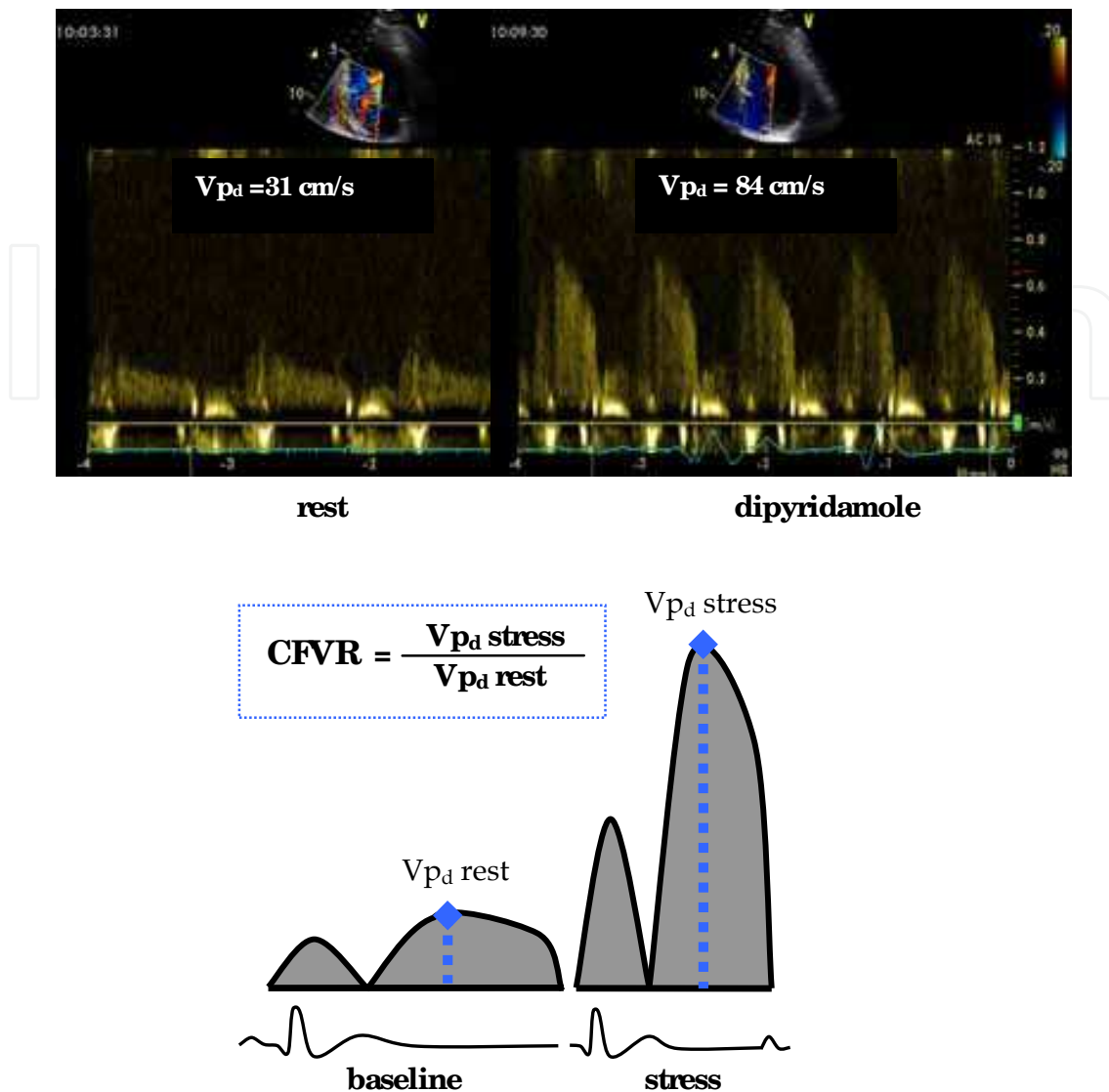


Fig. 14. Example of CFVR evaluation in the PDA.  $V_{pd}$  - peak diastolic coronary flow velocity.

index, demonstrates a higher inter- and intra-observed variability of assessment than  $V_{pm}$  and  $AV_{pd}$ . But CFVR evaluation is based on the ratio values of the same parameters, and similar values of CFVR were reported for  $V_{pd}$  and  $V_{md}$  (Hozumi et al., 1998; Caiati et al., 1999b). The time required to complete a CFVR test in one artery is around 5–8 minutes depending on the investigators' experience.

#### 4.2.2 Cut-off level of CFVR for significant stenosis in the LAD and RCA

Pizzuto et al, 2001, 2003 revealed CFVR value for the LAD ranging from  $2.90 \pm 0.58$  to  $3.05 \pm 0.81$  in control group of patients with angiographically normal coronary arteries, and similar values for CFVR were found in <50% LAD in-stent restenosis (Lambertz et al., 1999; Pizzuto et al, 2003). Later, CFVR in angiographically normal LAD patients with remote CAD (presence of previous remote myocardial infarction and wall motion abnormalities) was determined also as preserved (Pizzuto et al, 2004). According to numerous studies using

TTE the cut-off value of CFVR is generally accepted to be 2.0 for predicting significant LAD stenosis in patients under decision-making process, after intracoronary intervention, and with in-stent restenosis (table 6). The sensitivity and specificity of Doppler TTE measurement of CFVR for detecting significant angiographic disease were satisfactory, ranging from 77% to 94% and 65% to 100%, respectively, slightly depending on the study population, dose of stress medications and cut-off value of diameter % stenosis. In one study, CFVR with a cut-off value  $<2.0$  was a significantly better predictor (90% sensitivity, 96% specificity) of LAD stenosis than multidetector computed tomography (80% sensitivity, 93% specificity) and improved the diagnostic accuracy of the latter from 90 to 96% (Pizzuto et al., 2009). A cut-off value  $<2.0$  was appropriate even for the diagnosis of significant stenosis of donor LAD giving collaterals to other arteries (Pizzuto et al., 2004; Iwata et al., 2006).

Several investigators studied the accuracy of Doppler TTE measurement of CFVR in the PDA to detect stenosis in the RCA, and the same cut-off value of CFVR ( $<2.0$ ), demonstrating sensitivity 84-89% and specificity 83-96%, was accepted for predicting significant RCA stenosis (Voci et al., 2002; Takeuchi et al., 2004).

Authors	Diameter stenosis, %	CFVR, cut-off value	Reference parameter	Stress agent	Sens	Specif	Population
Hozumi et al., 1998b	$>70\%$	$<2.0$	$V_{pd}$ , $V_{md}$	adenosine	92%	82%	unselected
Caiati et al., 1999a	$>70\%$	$<2.0$	$V_{pd}$ , $V_{md}$	dipyridamole	86%	90%	unselected
Voci et al., 2002	$>70\%$	$<2.0$	$V_{pd}$	adenosine	89%	100%	unselected
Voci P et al., 2003	$>90\%$	$<1.0$	$V_{pd}$	adenosine	92%	98%	unselected
Nohtomi Y. et al., 2003	$>50\%$	$<2.0$	$V_{pd}$	dipyridamole	94%	65%	unselected
Lethen et al., 2003	$>70\%$	$<2.0$	S/D mean velocity	adenosine	89%	90%	after PTCA
Takeuchi et al., 2004	$>50\%$	$<2.0$	$AV_{pd}$	adenosine	91%	75%	unselected
Matsumura et al., 2003	$>70\%$	$<2.0$	$V_{md}$	adenosine	90%	93%	unselected
Rigo et al., 2003	$>50\%$	$<1.9$	$V_{pd}$	dipyridamole	81%	84%	unselected
Okayama et al., 2002	$>70\%$	$<2.0$	$AV_{pd}$	adenosine	94%	88%	unselected
Pizzuto et al., 2003	$>70\%$	$<2.0$	$V_{pd}$ , $V_{md}$	adenosine	91%	95%	after stenting
Lowenstein et al., 2003	$>70\%$	$<2.0$	$V_{pd}$	dipyridamole	87%	73%	unselected
Hirata et al., 2006	$>50\%$	$<2.0$	$V_{md}$	adenosine	77%	100%	after PTCA
Pizzuto et al., 2009	$>70\%$	$<2.0$	$V_{pd}$	adenosine	90%	96%	unselected

Table 6. Sensitivity and specificity of Doppler TTE measurement of CFVR for detecting significant LAD stenosis.  $V_{pd}$  - and  $V_{md}$  - peak and mean diastolic coronary flow velocities,  $AV_{pd}$  - average peak diastolic velocity of coronary blood flow, S/D mean velocity - systole-diastolic mean velocity of coronary blood flow, Sens - sensitivity, Specif - specificity.

#### 4.2.3 Cut-off value of CFVR for occluded LAD and RCA

CFVR can be a marker of chronic occluded LAD or RCA function. CFVR is always depressed in the collateral dependent vascular area, and the value  $<2.0$  is registered in the LAD or PDA distal to the occlusion in all cases (Takeuchi et al., 2005, Pizzuto et al., 2006). But TTE is able to reveal patients with CFVR  $<1.0$  reflecting coronary steal effect which

develops in 33% to 47% of occluded vessel territories (Takeuchi et al., 2005, Pizzuto et al., 2006). Coronary steal effect occurs when collateral circulation is poor and the donor artery is significant stenotic (Pizzuto et al, 2006; Braden, 2006).

#### **4.3 CFVR for detecting myocardial ischemia and assisting in the decision-making process in patients with chest pain**

Transthoracic CFVR measurement may have incremental predictive value in addition to stress echocardiography for detecting CAD in LAD and RCA distribution. In the study by Rigo et al., 2003, CFVR<1.9 in the LAD correlated well with stenosis severity and wall-motion abnormalities. The inverse correlation between CFVR and peak wall motion score index in the overall study population was significant ( $r=0.46$ :  $p<0.001$ ), and the concordance between the 2 techniques was good (80%) (Rigo et al, 2003). CFVR had excellent sensitivity (81-94%) but moderate or good specificity (65-84%) in detecting significant LAD stenosis whereas wall motion score index showed lower sensitivity (69-74%) and higher specificity (82-95%), and both techniques demonstrated a similar diagnostic accuracy ranging from 82 to 86% for CFVR and from 81 to 84% for wall motion score index (Rigo et al, 2003; Lowenstein et al., 2003; Nohtomi et al., 2003). So, the data for flow and function may be complementary in predicting the underlying angiographic findings and increase the diagnostic accuracy up to 94% (Nohtomi et al., 2003), because abnormal wall motion may confirm and negative CFVR may exclude CAD more accurately. So, CFVR measurement is more important in patients with negative stress echocardiography by wall motion criteria.

Similarly, transthoracic CFVR by Doppler is associated with perfusion abnormalities, as it has been shown with exercise single photon emission computed tomography thallium imaging. Most patients with abnormal perfusion in the LAD territory had abnormal CFVR in the LAD; those with perfusion defect in the RCA territory had abnormal CFVR in the PDA; vice versa, patients with normal exercise perfusion had CFVR greater than 2.0. A transthoracic CFVR in the LAD <2.0 provided data consistent with those obtained by single photon emission computed tomography for physiologic estimation of stenosis severity with 94% sensitivity and 100% specificity (Hirata et al., 2006). Tokai et al., 2003, showed the equivalent potential of transthoracic CFVR in the PDA for detecting myocardial ischemia in the left ventricular inferior region and RCA stenosis. As has been reported by Fujimoto et al, 2004, CFVR in the Cx could be obtained in 72% of patients and CFVR<2.0 had 92% sensitivity and 96% specificity for predicting the perfusion defect in the Cx territory.

In one comparative study (Osorio et al., 2007) with simultaneous CFVR assessment and quantitative analysis of myocardial contrast perfusion, CFVR was a much better index for detecting LAD stenosis than myocardial blood flow reserve (sensitivity 92% and 84%, specificity 94% and 87%, and accuracy 93% and 86% for CFVR and myocardial reserve, respectively).

In summary, CFVR measurement may be a useful tool for detecting myocardial ischemia in the LAD distribution and, probably, in the RCA and Cx territory.

#### **4.4 CFVR in moderate and severe coronary artery stenosis**

Evaluation of patients with angiographic moderate coronary artery stenosis is challenging. Neither visual assessment of an angiogram nor quantitative coronary angiography can accurately predict the significance of most moderate stenoses (50–70%). Rest coronary flow is preserved until severe narrowing occurs (>80%), but according to the experimental study

in mice (Wikstrom et al., 2005), there is a close correlation between CFVR in the left coronary artery and coronary minimal lumen diameter of this vessel ( $r=0.87$ ,  $p<0.005$ ), and CFVR depends on the diameter % stenosis. In clinical studies, the degree of angiographic stenosis also is related to CFVR in both the LAD and RCA (Lambertz et al., 1999; Pizzuto et al., 2001; Voci et al., 2002, 2003; Sicari et al., 2009). With insignificant LAD stenosis ( $<50\%$ ), CFVR in the LAD is normal (Lambertz et al., 1999; Voci et al., 2002), equal to  $2.6\pm 0.6$  in subjects with totally normal coronary arteries,  $2.6\pm 0.6$  in subjects with LAD stenosis of 0-20% and  $2.2\pm 0.5$  in subjects with LAD stenosis of 20-40% (Sicari et al., 2009). In cases with moderate stenosis, overall group CFVR is intermediate (from  $2.23\pm 0.20$  to  $2.33\pm 0.32$ ); and only in high-grade stenosis CFVR is low (from  $1.12\pm 0.49$  to  $1.64\pm 0.30$ ). But according to individual analysis data, CFVR reduction is found upstream in the classical ischemic cascade, and can well detect stenosis unable to induce regional wall motion abnormalities during stress echo (see 4.3). CFVR is often  $<2.0$  when stenosis is still moderate (50%-60%) (fig. 15) mirroring the decrease of subendocardial blood flow without total wall perfusion deficit and wall motion disturbance. So, demonstrating a higher negative predictive value in the detection of ischemia, compared with wall motion score index or nuclear cardiac imaging, CFVR is very useful in moderate stenosis to assess its functional significance and to help consider the necessity of revascularization (when  $CFVR<2.0$ ).

In severe stenosis, CFVR is more preserved in subjects with stenosis of 70-90% than in subjects with stenosis greater than 90% (Voci et al., 2003). Pizzuto et al., 2001 and Voci et al., 2003, found the cut-off value of  $CFVR<1.0$  to be a marker of coronary flow steal effect in patients with severe LAD stenosis ( $>90\%$ ) with 92% sensitivity, 98% specificity, and 97% diagnostic accuracy. This finding is in agreement with the experimental work of Gould et al., 1974, who showed that CFVR in over 90% stenosis of the lumen diameter is blunted mainly due to either stenosis site collapse or development of coronary steal through collateral vessels.

So, CFVR by Doppler TTE may be a useful tool for: 1) selection of patients with moderate stenosis and  $CFVR<2.0$  for revascularization and 2) detection of patients with  $>90\%$  stenosis basing on coronary steal effect ( $CFVR<1.0$ ).

#### 4.5 CFVR after intracoronary interventions

Another important application of TTE is assessment of early efficacy and remote coronary restenosis after intracoronary interventions. In the study of Pizzuto et al., 2001, CFVR measurement was performed before and within 1 day after LAD stenting. Pre-stent impaired CFVR increased after success stent implantation from  $1.45\pm 0.5$  to  $2.58\pm 0.7$  in groups with 70-90% and  $>90\%$  stenosis, and an absence of CFVR change was revealed only in 3 patients with  $>90\%$  stenosis due to reactive hyperemia, microvascular stunning or post-procedure vasoconstriction. Unlike intracoronary Doppler studies with the guide wire or guiding catheter, the influence of which on the vascular endothelium and coronary flow dynamics is unpredictable and may be a cause of high rate of impaired CFVR after balloon angioplasty or stenting (50% and 30%, respectively) even in the absence of any residual angiographic stenosis, TTE, being a non-invasive technique, is deprived of this effect, and can more accurately reflect changes of coronary flow.

In the study including 53 patients, coronary angiography and CFVR detection were performed 6 months after PTCA of the LAD (Lethen et al., 2003). The investigators observed CFVR to significantly differ in the groups with and without restenosis, and CFVR with the cut-off value  $<2.0$  demonstrated 89% sensitivity and 90% specificity for predicting



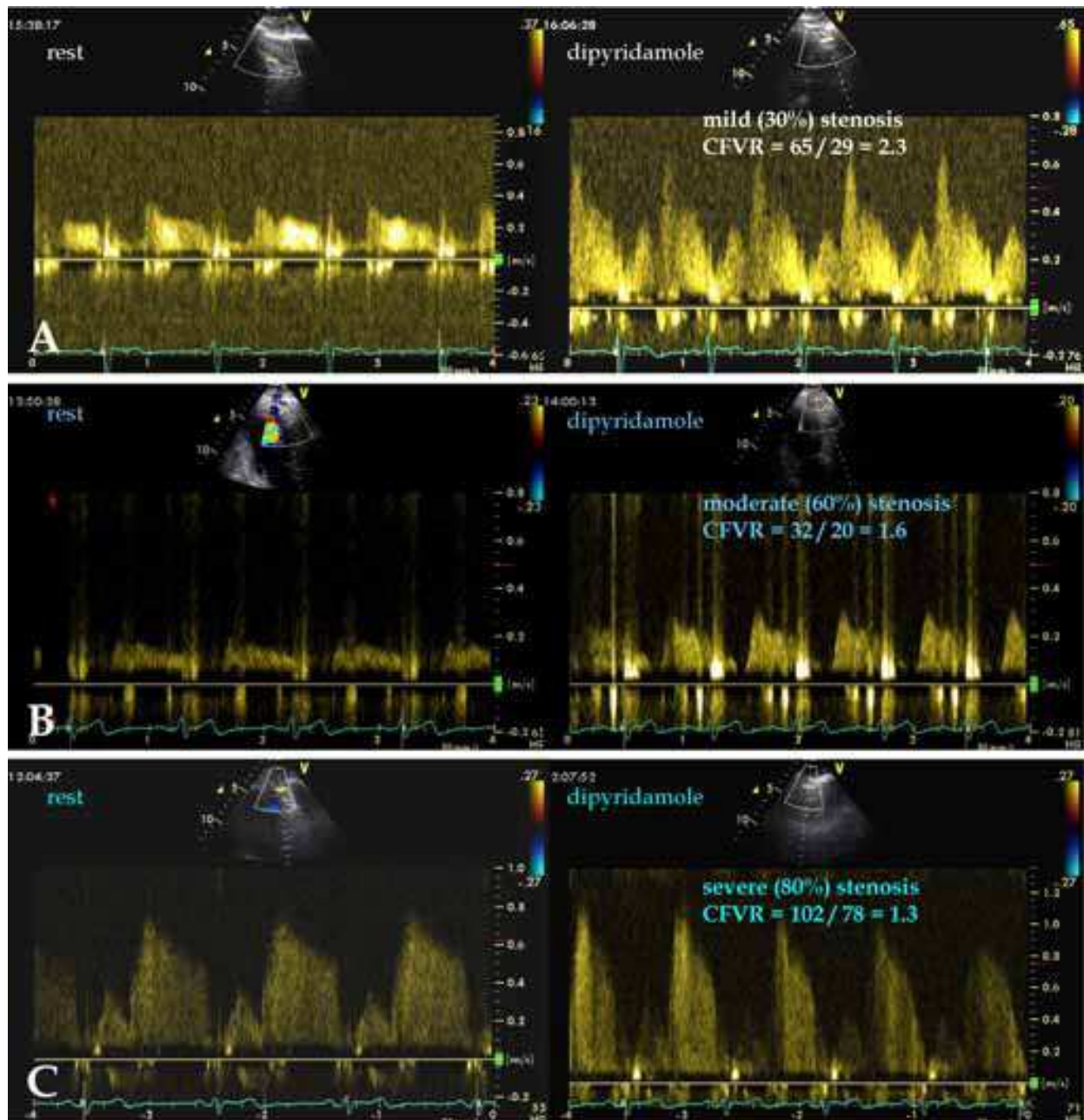


Fig. 15. Examples of CFVR in distal LAD in patients with LAD stenosis are presented. A - case with mild proximal LAD stenosis, CFVR is 2.3; B - case with moderate LAD stenosis; the basal peak diastolic flow velocity is normal, but it increases less than 2 times after dipyridamole, and CFVR is decreased (1.6); C - case with proximal severe LAD stenosis and basal poststenotic acceleration of coronary flow with high peak diastolic flow velocity in distal LAD at rest; after dipyridamole the increase of peak diastolic flow velocity is slight, CFVR is equal to 1.3.

significant LAD restenosis. Similar studies were carried out after LAD stent, and CFVR with the cut-off value  $<2.0$  also demonstrated sensitivity ranging from 77% to 93% and specificity ranging from 78% to 100% for predicting LAD restenosis (Ruscasio et al., 2002; Pizzuto et al, 2003a; Hirata et al., 2006). One of the criticisms of TTE is that assessment has been limited to the LAD, but progress is being made in examining other vessels. High success rate of CFVR

measurements in the PDA permits to hope for the forthcoming appearance of CFVR studies before and after RCA intracoronary interventions.

Thus, noninvasive CFVR assessment by TTE is a very promising tool in monitoring early efficacy of LAD angioplasty or stenting and detecting remote restenosis after LAD intracoronary interventions.

#### **4.6 Factors influencing CFVR**

Besides stenosis, several factors can influence the baseline or hyperemic coronary flow and cause decreased CFVR. Elevation of the basal flow can occur with hypertension, tachycardia, anemia, thyrotoxicosis, or valvular disease, or after caffeine intake (coffee, tea, cola, etc.). The conditions which can decrease the maximum hyperemic flow include not only epicardial coronary stenosis but also microvascular disease with impaired structure, function, rheology, and lower density of capillaries, polycythemia and elevated left ventricle end-diastolic pressure (Baumgart et al., 1998; Hirata et al., 2001; Neishi et al., 2005; de Grigorio et al., 2005; Sherrid et al., 2006; Kaul & Jayaweera, 2008).

#### **4.7 CFVR and prognosis in CAD patients**

According to the data of studies in patients with acute anterior myocardial infarction, CFVR is able to reflect an absence of microvascular reperfusion in the presence of a patent epicardial coronary artery, and is a negative determinant for myocardial viability (Ueno et al., 2002a; Rigo et al., 2004; Meimoun et al., 2009). Ueno et al., 2002a, reported that CFVR measured in open infarct-related LAD on day 1 after success primary angioplasty was a good predictor of the recovery of regional left ventricle function at discharge, whereas Rigo et al., 2004, found CFVR in the LAD  $<2.0$  to be useful also in predicting an unfavorable long-term (6-month) outcome. In the study of Meimoun et al., 2009, a cut-off CFVR value of 1.7 was an independent predictor of both the left ventricle recovery at a 3-month follow-up, and in-hospital adverse cardiac events including death, recurrent myocardial infarction, and acute heart failure.

CFVR  $<2.0$  was associated with an unfavorable outcome in an unselected cohort of patients with positive and negative stress echocardiograms by wall motion criteria (Rigo et al., 2008), in patients with intermediate LAD stenosis (Rigo et al., 2007), and in patients with chest pain and normal or near-normal coronary arteries (Sicari et al., 2009). CFVR  $<1.8$  provided independent information for prognostic stratification in patients with inducible ischemia during stress echocardiography, and it was associated with an increase of event rate (death and myocardial infarction) by 46% during 19-month follow-up (Cortigiani et al., 2010). But LAD CFVR demonstrated an extremely high additional prognostic value (up to 160%) in patients with negative stress echocardiography by wall motion criteria, and a reduced CFVR was associated with a less benign long-term outcome (Rigo et al., 2006; Cortigiani et al., 2010). In the study of Rigo et al., 2006, CFVR  $<1.92$  was the best predictor of future events (sensitivity = 77%, specificity = 85%), and the 3-year event-free survival was higher in patients with normal CFVR ( $>1.92$ ) compared with patients with reduced CVFR (98% versus 64%,  $P < 0.0001$ ). The main reasons for CFVR importance in the prognosis in patients with negative stress echocardiography are the following: (1) CFVR can detect moderate coronary stenoses inducing no wall motion abnormalities during stress test (see 4.3, 4.4); (2) CFVR can be useful for the detection of severe stenosis in patients on antiischemic therapy. When

ischemia-dependent wall motion abnormality is the diagnostic end point, concomitant antiischemic therapy modifies the prognostic value of stress echocardiography, markedly reducing TTE sensitivity; in fact, a positive test result in on therapy patients is more prognostically malignant, and a negative test result is less prognostically benign. The flow information in patients with known or suspected coronary artery disease is relatively unaffected by concomitant antiischemic therapy, and does not influence CFVR significantly. In the study with 1779 patients performed by Sicari et al., 2008, the symptoms-free survival was higher in patients with normal CFVR ( $>2.0$ ) and lower in patients with abnormal CFVR (87% versus 34%,  $P = 0.0001$ ), and it was comparable to that in patients with normal CFVR on and off therapy and in patients with abnormal CFVR on and off therapy; so, antiischemic therapy at the time of testing did not modify the prognostic value of Doppler CFVR. (3) CFVR can identify severe microvascular disease (Rigo et al., 2006; Cortigiani et al., 2007; Sicari et al., 2009). Coronary microvascular dysfunction does not normally induce wall motion abnormalities but has been linked to an adverse outcome, which can be accurately detected by abnormal CFVR. So, in a prospective study in 394 patients with angiographically normal or near-normal coronary arteries and preserved regional and global left ventricular function at baseline and during stress, CFVR  $<2.0$  adds incremental value to the prognostic stratification achieved with clinical and angiographic data (Sicari et al., 2009), and selects a subgroup of patients with a less benign prognosis. During a median follow-up of 51 months, long-term survival estimated for adverse events (death and myocardial infarction) showed an extremely better outcome for the patients with a normal CFVR compared with those with an abnormal CFVR (96% versus 55%).

In summary, CFVR provides independent information for prognostic stratification, and a reduced CFVR is associated with a less benign long-term outcome in patients with acute anterior myocardial infarction, known or suspected CAD with positive and particularly negative stress echocardiography by wall motion criteria. CFVR measurement is offered to be added to routine stress echocardiography.

## 5. Transthoracic visualization of internal thoracic artery grafts and venous grafts

We do not have our own sufficient experience of coronary graft assessment. But in published studies TTE visualization of the left internal mammary artery (IMA) graft has varied from 70% to 100%, the venous grafts to the LAD could be assessed in 91%, to the RCA – in 96%, to the Cx – in 90% (Chirillo et al., 2001, 2004; Chong et al., 2004). The Nyquist limits should be set at 20 cm/s for the IMA grafts and 10-12 cm/s for the venous grafts (Youn & Foster, 2004). In the proximal part next to the subclavian artery, patent IMA grafts demonstrate a flow pattern with predominant systolic velocity, and next to distal anastomosis site the flow pattern has predominant diastolic velocity similar to that of the coronary artery. Some researchers made an effort to detect dipyridamole-induced CFVR in the IMA and venous grafts. Meyer et al., 2004, compared CFVR in the proximal left IMA graft with the help of simultaneous TTE and intracoronary Doppler guide wire assessment. TTE reflected invasive measurement of CFVR accurately, and the agreement between the two methods was 0.97, and patients with CFVR  $>2.1$  showed patent IMA graft. According to the data of Chirillo et al., 2001, 2004, CFVR  $<1.9$  in proximal IMA grafts and CFVR  $<1.6$  in



venous grafts demonstrated a higher sensitivity in the detection of 50-100% graft stenoses in comparison with wall motion score index. But recently, Pizzuto et al., 2005 have determined distal CFVR in the IMA grafts to depend on flow interrelation in the graft and native LAD, and to be a better predictor of LAD function than IMA graft patency in the presence of flow competition. So, TTE value for identification of graft patency is not yet established, and further studies are required.

## 6. Conclusion

In summary, with the advent of harmonic imaging, contrast agents and high-frequency transducers, TTE can be used for the diagnosis of coronary narrowing as a noninvasive, inexpensive, non-X-ray, high time resolution and widely used in clinical practice method. After a period of investigators' training, detection and measurement of distal LAD and RCA flow and CFVR by TTE is feasible in more than 90% of patients and correlates well with invasive measurements. Clinical applications of TTE for direct assessment of coronary stenoses and occlusions are limited due to partial artery visualization, and TTE can not be accepted as an alternative to coronary angiography. But Doppler TTE in CAD patients can be a helpful method providing additional information on the coronary artery function for:

- noninvasive clinical repeated or serial measurements of coronary flow velocity at rest after stress which are necessary for understanding the physiology and pathophysiology of coronary flow; in this case the LAD can be used as a reference vessel;
- preliminary identification of coronary stenosis in the LMCA, LAD and PDA;
- detection of restenosis after percutaneous intracoronary interventions in the LMCA, LAD and PDA;
- diagnosis of reperfusion in the acute phase of myocardial infarction in the LAD territory with evaluation of no-reflow after recanalization;
- identification of chronic occluded LAD and RCA;
- assessment of endothelial function;
- measurement of CFVR in the following groups of patients: (1) with suspected or confirmed CAD in those who undergo stress echocardiography (dobutamine or dipyridamole) for reflecting perfusion, function, prognosis-risk stratification, and selection of significant coronary stenosis ( $CFR < 2.0$ ) of the LAD and RCA; (2) with intermediate-grade coronary obstruction where the functional assessment of the lesion is doubtful, and CFVR can be used in considering *pro et contra* of coronary interventions; (3) with not reliable stress tests due to left bundle-branch block or right bundle-branch block because of the high rate of the false-positive results where CFVR may be used for noninvasive detection of LAD or RCA stenosis; (4) after coronary angioplasty, stent or coronary bypass graft of the LAD and RCA where serial follow-up for the assessment of efficacy and early or remote restenosis is required; (5) with ongoing drug therapy for serial follow-up, particularly if the drug effect is uncertain; (6) with typical or atypical chest pain and angiographically normal coronary arteries where microvascular disease is possible (syndrome X, left ventricle hypertrophy, diabetes mellitus, etc.); and (7) with acute anterior myocardial infarction for the assessment of viability, prognosis and prediction of improvement of the regional left ventricular function.



## 7. Acknowledgments

We would like to thank Tatyana Taushkanova for her assistance in the preparation of this chapter.

## 8. References

- Anjaneyulu, A., Raghu, K., Chandramukhi, S., Satyajit, G.M., Arramraja, S., Raghavaraju, P., Krishnamraju, P. & Somaraju, B. (2008). Evaluation of left main coronary artery stenosis by transthoracic echocardiography. *JAm Soc Echocardiogr*, Vol. 21, No. 7, (July 2008), pp. 855-860, ISSN 0894-7317
- Bax, M., de Winter, R.J., Koch, K.T., Schotborgh, C.E., Tijssen, J.G.P. & Piek, J.J. (2006). Time course of microvascular resistance of the infarct and noninfarct coronary artery following an anterior wall acute myocardial infarction. *Am JCardiol*, Vol. 97, No. 8, (April 2006), pp. 1131-1136, ISSN 0002-9149
- Baumgart, D., Haude, M., Liu, F., Ge, J., Goerge, G., Erbel, R. (1998). Current concepts of coronary flow reserve for clinical decision making during cardiac catheterization *Am Heart J* Vol. 136, No. 1, (July 1998), pp. 136-149, ISSN 0002-8703
- Braden, G.A. (2006). Chronic Total Coronary Occlusions. *Cardiol Clin*, Vol. 24, No. 2, (May 2006), pp. 247-254, ISSN 0733-8651
- Boshchenko, A.A., Vrublevsky, A.V. & Karpov, R.S. (2008). Transthoracic echocardiography in the assessment of main coronary arteries: methodological aspects, potentials, and limitations. *Ultrasound & Functional Diagnostics*, Vol. 72, No. 6, (November 2008), pp. 60-75, ISSN 1607-0771
- Boshchenko, A.A., Vrublevsky, A.V. & Karpov, R.S. (2009). Transthoracic echocardiography in the detection of chronic total coronary artery occlusion. *Eur JEchocardiogr*, Vol. 10, No. 1, (January 2009), pp. 62-68, ISSN 1525-2167
- Caiati, C., Montaldo, C., Zedda, N., Bina, A. & Iliceto, S. (1999). New noninvasive method for coronary flow reserve assessment: contrast-enhanced transthoracic second harmonic echo Doppler. *Circulation*, Vol. 99, No. 6, (February 1999), pp. 771-778, ISSN 0009-7322
- Caiati, C., Montaldo, C., Zedda, N., Montisci, R., Ruscazio, M., Lai, G., Cadeddu, M., Meloni, L. & Iliceto, S. (1999). Validation of a new noninvasive method (contrast-enhanced transthoracic second harmonic echo Doppler) for the evaluation of coronary flow reserve: comparison with intracoronary Doppler flow wire. *JAm Coll Cardiol*, Vol. 34, No. 4, (October 1999), pp.1193-1200, ISSN 0735-1097
- Cortigiani, L., Rigo, F., Gherardi, S., Sicari, R., Galderisi, M., Bovenzi, F. & Picano, E. (2007). Additional prognostic value of coronary flow reserve in diabetic and nondiabetic patients with negative dipyridamole stress echocardiography by wall motion criteria. *JAm Coll Cardiol*, Vol. 50, No. 14, (October 2007), pp. 1354-1361, ISSN 0735-1097
- Cortigiani, L., Rigo, F., Gherardi, S., Bovenzi, F., Picano, E. & Sicari, R. (2010). Implication of the continuous prognostic spectrum of Doppler echocardiographic derived coronary flow reserve on left anterior descending artery. *Am JCardiol*, Vol. 105, No. 2, (January 2010), pp. 158-162, ISSN 0002-9149
- Courtis, J., Rodes-Cabau, J., Larose, E., Potvin, J.-M., Dery, J.-P., De Larochelliere, R., Cote, M., Cousterousse, O., Nguyen, C. M., Proulx, G., Rinfret, S. & Bertrand, O. F. (2009).

- Usefulness of coronary fractional flow reserve measurements in guiding clinical decisions in intermediate or equivocal left main coronary stenoses. *Am J Cardiol*, Vol. 103, No. 7, (April 2009), pp. 943-949, ISSN 0002-9149
- Crowley, J.J. & Shapiro, L.M. (1998). Noninvasive analysis of coronary artery poststenotic flow characteristics by using transthoracic echocardiography. *JAm Soc Echocardiogr*, Vol. 11, No. 1, (January 1998), pp. 1-9, ISSN 0894-7317
- Chamuleau, S.A. J., Meuwissen, M., van Eck-Smit, B.L.F., Koch, K.T., de Jong, A., de Winter, R.J.I., Schotborgh, C.E., Bax, M., Verberne, H.J., Tijssen, J.G. & Piek, J.J. (2001). Fractional flow reserve, absolute and relative coronary blood flow velocity reserve in relation to the results of technetium-99m sestamibi single-photon emission computed tomography in patients with two-vessel coronary artery disease. *JAm Coll Cardiol*, Vol. 37, No. 5, (April 2001), pp. 1316-1322, ISSN 0735-1097
- Chirillo, F., Bruni, A., Balestra, G., Cavallini, C., Olivari, Z., Thomas, J.D. & Stritoni, P. (2001). Assessment of internal mammary artery and saphenous vein graft patency and flow reserve using transthoracic Doppler echocardiography. *Heart*, Vol. 86, No. 4, (October 2001), pp. 424-431, ISSN 1355-6037
- Chirillo, F., Bruni, A., De Leo, A., Olivari, Z., Franceschini-Grisolia, E., Totis, O. & Stritoni, P. (2004). Usefulness of dipyridamole stress echocardiography for predicting graft patency after coronary artery bypass grafting. *Am J Cardiol*, Vol. 93, No. 1, (January 2004), pp. 24-30, ISSN 0002-9149
- Chong Ng, D.W., Vlachonassios, K., Nimalasuriya, A.R., Nguyen, V.T., Wijesekera, C., Khan, A. & Chandraratna P. A. N. (2004). Usefulness of transthoracic echocardiography in demonstrating coronary blood flow after coronary artery bypass grafting. *Am J Cardiol*, Vol. 93, No. 7, (April 2004), pp. 923-925, ISSN 0002-9149
- Daimon, M., Watanabe, H., Yamagishi, H., Kuwabara, Y., Hasegawa, R., Toyoda, T., Yoshida, K., Yoshikawa, J. & Komuro, I. (2005). Physiologic assessment of coronary artery stenosis without stress tests: noninvasive analysis of phasic flow characteristics by transthoracic Doppler echocardiography. *JAm Soc Echocardiogr*, Vol. 18, No. 9, (September 2005), pp. 949-955, ISSN 0894-7317
- de Gregorio, C., Micari, A., Grimaldi, P., Bragadeesh, T., Arrigo, F. & Coglitore S. (2005) Behavior of both epicardial and intramural coronary artery flow velocities in various models of myocardial hypertrophy: Role for left ventricular outflow tract obstruction. *Am Heart J* Vol. 149, No. 6, (June 2005), pp. 1091-1098, ISSN 0002-8703
- Frommelt, P.C. & Frommelt, M.A. (2004). Congenital coronary artery anomalies. *Pediatr Clin North Am*, Vol. 51, No. 5, (October 2004), pp. 1273-1278, ISSN 0031-3955
- Fujimoto, K., Watanabe, H., Hozumi, T., Otsuka, R., Hirata, K., Yamagishi, H., Yoshiyama, M., & Yoshikawa, J. (2004). New noninvasive diagnosis of myocardial ischemia of the left circumflex coronary artery using coronary flow reserve measurement by transthoracic Doppler echocardiography: comparison with thallium-201 single photon emission computed tomography. *JCardiol*, Vol. 43, No. 3, (March 2004), pp. 109-116, ISSN 0914-5087
- Fusejima K. (1987). Noninvasive measurement of coronary artery blood flow using combined two-dimensional and Doppler echocardiography. *JAm Coll Cardiol*, Vol. 10, No. 5, (November 1987), pp.1024-1031, ISSN 0735-1097

- Gould, K.L. & Lipscomb, K. (1974). Effects of coronary stenoses on coronary flow reserve and resistance. *Am J Cardiol*, Vol. 34, No. 1, (January 1974), pp. 48–55, ISSN 0002-9149
- Gould, K.L., Lipscomb, K. & Hamilton, G.W. (1974). Physiologic basis for assessing severe coronary stenosis instantaneous flow response and regional distribution during coronary hyperemia as measures of coronary flow reserve. *Am J Cardiol*, Vol. 33, No. 1, (January 1974), pp. 87–94, ISSN 0002-9149
- Harada, K., Orino, T., Hironaka, C., Takahashi, Y. & Takada, G. (1999). Coronary blood flow velocity in normal infants and young adults assessed by transthoracic echocardiography. *Am J Cardiol*, Vol. 83, No. 11, (June 1999), pp. 1583–1585, ISSN 0002-9149
- Hiraishi, S., Misawa, H., Takeda, N., Horiguchi, Y., Fujino, N., Ogawa, N. & Hirota, H. (2000). Transthoracic ultrasonic visualisation of coronary aneurysm, stenosis, and occlusion in Kawasaki disease. *Heart*, Vol. 83, No. 4, (April 2000), pp. 400–405, ISSN 1355-6037
- Hirata, K., Shimada, K., Watanabe, H., Muro, T., Yoshiyama, M., Takeuchi, K., Hozumi, T. & Yoshikawa, J. (2001). Modulation of coronary flow velocity reserve by gender, menstrual cycle and hormone replacement therapy. *J Am Coll Cardiol*, Vol. 38, No. 7, (December 2001), pp. 1879–1884, ISSN 0735-1097
- Hirata, K., Watanabe, H., Hozumi, T., Tokai, K., Otsuka, R., Fujimoto, K., Shimada, K., Muro, T., Yoshiyama, M. & Yoshikawa, J. (2004). Simple detection of occluded coronary artery using retrograde flow in septal branch and left anterior descending coronary artery by transthoracic Doppler echocardiography at rest. *J Am Soc Echocardiogr*, Vol. 17, No. 2, (February 2004), pp. 108–113, ISSN 0894-7317
- Hirata, K., Watanabe, H., Otsuka, R., Fujimoto, K., Tokai, K., Yamagishi, H., Yoshiyama, M. & Yoshikawa, J. (2006). Noninvasive diagnosis of restenosis by transthoracic Doppler echocardiography after percutaneous coronary intervention: comparison with exercise TI-SPECT. *J Am Soc Echocardiogr*, Vol. 19, No. 2, (February 2006), pp. 165–171, ISSN 0894-7317
- Hozumi T., Yoshida K., Akasaka T., Asami Y., Ogata Y., Takagi T., Kaji, S., Kawamoto, T., Ueda, Y. & Morioka, S. (1998). Noninvasive assessment of coronary flow and coronary flow velocity reserve in the left anterior descending coronary artery by Doppler echocardiography. Comparison with invasive technique. *J Am Coll Cardiol*, Vol. 32, No. 5, (November 1998), pp. 1251–1259, ISSN 0735-1097
- Hozumi, T., Yoshida, K., Ogata, Y., Akasaka, T., Asami, Y., Takagi, T. & Morioka, S. (1998). Noninvasive assessment of significant left anterior descending coronary artery stenosis by coronary flow velocity reserve with transthoracic color Doppler echocardiography. *Circulation*, Vol. 97, No. 16, (April 1998), pp. 1557–1562, ISSN 0009-7322
- Hozumi, T., Yoshida, K., Akasaka, T., Asami, Y., Kanzaki, Y., Ueda, Y., Yamamuro, A., Takagi, T. & Yoshikawa, J. (2000). Value of acceleration flow and the prestenotic to stenotic coronary flow velocity ratio by transthoracic color Doppler echocardiography in noninvasive diagnosis of restenosis after percutaneous transluminal coronary angioplasty. *J Am Coll Cardiol*, Vol. 35, No. 1, (January 2000), pp. 164–168, ISSN 0735-1097

- Iwata, S., Hozumi, T., Matsumura, Y., Sugioka, K., Yoshitani, H., Murata, E., Takemoto, Y., Kobayashi, Y., Yoshiyama, M. & Yoshikawa, J. (2006). Cut-off value of coronary flow velocity reserve by transthoracic Doppler echocardiography for the assessment of significant donor left anterior descending artery stenosis in patients with spontaneously visible collaterals. *Am J Cardiol*, Vol. 98, No. 3, (August 2006), pp. 298-302, ISSN 0002-9149
- Kaul, S. & Jayaweera, A.R. (2008). Myocardial capillaries and coronary flow reserve. *J Am Coll Cardiol*, Vol. 52, No. 17, (October 2008), pp. 1399-1401, ISSN 0735-1097
- Kenny, A. & Shapiro, L.M. (1992). Transthoracic high-frequency two-dimensional echocardiography, Doppler and color flow mapping to determine anatomy and blood flow patterns in the distal left anterior descending coronary artery. *Am J Cardiol*, Vol. 69, No. 16, (May 1992), pp. 1265-1268, ISSN 0002-9149
- Korcarz, C.E. & Stein, J.H. (2004). Noninvasive assessment of coronary flow reserve by Echocardiography: technical considerations. *J Am Soc Echocardiogr*, Vol. 17, No. 6, (June 2004), pp. 704-707, ISSN 0894-7317
- Krzanowski, M., Bodzoń, W., Brzostek, T., Nizankowski, R. & Szczeklik, A. (2000). Value of transthoracic echocardiography for the detection of high-grade coronary artery stenosis: prospective evaluation in 50 consecutive patients scheduled for coronary angiography. *J Am Soc Echocardiogr*, Vol. 13, No. 12, (December 2000), pp. 1091-1099, ISSN 0894-7317
- Krzanowski, M., Bodzoń, W. & Dimitrow, P.P. (2003). Imaging of all three coronary arteries by transthoracic echocardiography. An illustrated guide. *Cardiovascular Ultrasound*, Vol. 1, (January 2003). p. 16, ISSN 1476-7120, Available from <http://www.cardiovascularultrasound.com/content/1/1/16>
- Lambertz, H., Tries, H.P. & Lethen, H. (1999). Noninvasive assessment of coronary flow reserve with transthoracic signal-enhanced Doppler echocardiography. *J Am Soc Echocardiogr*, Vol. 12, No. 3, (March 1999), pp. 186-195, ISSN 0894-7317
- Lethen, H., Tries, H.P., Brechtken, J., Kersting, S. & Lambertz, H. (2003). Comparison of transthoracic Doppler echocardiography to intracoronary Doppler guidewire measurements for assessment of coronary flow reserve in the left anterior descending artery for detection of restenosis after coronary angioplasty. *Am J Cardiol*, Vol. 91, No. 4, (February 2003), pp. 412-417, ISSN 0002-9149
- Lim, H.E., Shim, W.J., Rhee, H., Kim, S.M., Hwang, G.S., Kim, Y.H., Seo, H.S., Oh, D.J. & Ro Y.M. (2000). Assessment of coronary flow reserve with transthoracic Doppler echocardiography: comparison among adenosine, standard-dose dipyridamole, and high-dose dipyridamole. *J Am Soc Echocardiogr*, Vol. 13, No. 4, (April 2000), pp. 264-270, ISSN 0894-7317
- Lowenstein, J., Tiano, C., Marquez, G., Presti, C. & Quiroz, C. (2003). Simultaneous analysis of wall motion and coronary flow reserve of the left anterior descending coronary artery by transthoracic doppler echocardiography during dipyridamole stress echocardiography. *J Am Soc Echocardiogr*, Vol. 16, No. 6, (June 2003), pp. 606-613, ISSN 0894-7317
- Matsumura, Y., Hozumi, T., Watanabe, H., Fujimoto, K., Sugioka, K., Takemoto, Y., Shimada, K., Muro, T., Yoshiyama, M., Takeuchi, K. & Yoshikawa, J. (2003). Cut-off value of coronary flow velocity reserve by transthoracic Doppler echocardiography for diagnosis of significant left anterior descending artery stenosis in patients with



- coronary risk factors. *Am J Cardiol*, Vol. 92, No. 12, (December 2003), pp. 1389–1393, ISSN 0002-9149
- Maxted, W. C. Jr., Swanson, S.T., Huntley, M., Segar, D.S., Sawada, S.G. & Feigenbaum, H. (1998). Location of stents in the left anterior descending coronary artery using three dimensionally acquired, two dimensionally displayed transthoracic echocardiography. *Am J Cardiol*, Vol. 82, No. 11, (December 1998), pp. 1434–1436, A9, ISSN 0002-9149
- Meimoun, P., Sayah, S., Tcheuffa, J.C., Benali, T., Luyck-Bore, A., Levy, F. & Tribouilloy, C. (2006). Transthoracic coronary flow velocity reserve assessment: comparison between adenosine and dobutamine. *J Am Soc Echocardiogr*, Vol. 19, No. 10, (October 2006), pp. 1220–1228, ISSN 0894-7317
- Meimoun, P., Malaquin, D., Benali, T., Boulanger, J., Zemir, H., Sayah, S., Luyck-Bore, A., Doutrelan, L. & Tribouilloy, C. (2009). Non-Invasive coronary flow reserve after successful primary angioplasty for acute anterior myocardial infarction is an independent predictor of left ventricular recovery and in-hospital cardiac events. *J Am Soc Echocardiogr*, Vol. 22, No. 9, (September 2009), pp. 1071–1079, ISSN 0894-7317
- Meyer, G.P., Laudenberg, B., Hausmann, D., Mügge, A., Cremer, J., Hornig, B., Weiss, T., Hecker, H., Haverich, A., Drexler, H. & Schaefer, A. (2004). Transthoracic Doppler validation in mammary artery grafts after minimal invasive direct coronary artery bypass operation. *J Am Soc Echocardiogr*, Vol. 17, No. 9, (September 2004), pp. 954–961, ISSN 0894-7317
- Neishi, Y., Akasaka, T., Tsukiji, M., Kume, T., Wada, N., Watanabe, N., Kawamoto, T., Kaji, S. & Yoshida, K. (2005). Reduced coronary flow reserve in patients with congestive heart failure assessed by transthoracic Doppler echocardiography. *J Am Soc Echocardiogr*, Vol. 18, No. 1, (January 2005), pp. 15–19, ISSN 0894-7317
- Nohtomi, Y., Takeuchi, M., Nagasawa, K., Arimura, K., Miyata, K., Kuwata, K., Yamawaki, T., Kondo, S., Yamada, A. & Okamoto, S. (2003). Simultaneous assessment of wall motion and coronary flow velocity in the left anterior descending coronary artery during dipyridamole stress echocardiography. *J Am Soc Echocardiogr*, Vol. 16, No. 5, (May 2003), pp. 457–463, ISSN 0894-7317
- Okayama, H., Sumimoto, T., Hiasa, G., Morioka, N., Yamamoto, K. & Kawada, H. (2002). Usefulness of an echo-contrast agent for assessment of coronary flow velocity and coronary flow velocity reserve in the left anterior descending coronary artery with transthoracic doppler scan echocardiography. *Am Heart J*, Vol. 143, No. 4, (April 2002), pp. 668–675, ISSN 0002-8703
- Okayama, H., Nishimura, K., Saito, M., Inoue, K., Hiasa, G., Sumimoto, T., Ogimoto, A., Ohtsuka, T., Shigematsu, Y. & Higaki, J. (2008). Significance of the distal to proximal coronary flow velocity ratio by transthoracic Doppler echocardiography for diagnosis of proximal left coronary artery stenosis. *J Am Soc Echocardiogr*, Vol. 21, No. 6, (June 2008), pp. 756–760, ISSN 0894-7317
- Osorio, A.I.F.F., Tsutsui, J.M., Kowatsch, I., Guerra, V.C., Ramires, J.A.F., Lemos, P.A., Cesar, L.A.M. & Mathias, Jr. W. (2007). Evaluation of blood flow reserve in left anterior descending coronary artery territory by quantitative myocardial contrast and Doppler echocardiography. *J Am Soc Echocardiogr*, Vol. 20, No. 6, (June 2007), pp. 709–716, ISSN 0894-7317


- Otsuka, R., Watanabe, H., Hirata, K., Tokai, K., Muro, T., Hozumi, T., Yoshiyama, M. & Yoshikawa, J. (2005). A novel technique to detect total occlusion in the right coronary artery using retrograde flow by transthoracic Doppler echocardiography. *JAm Soc Echocardiogr*, Vol. 18, No. 7, (July 2005), pp. 704-709, ISSN 0894-7317
- Pellikka, P. (2004). Going for the money: transthoracic assessment of coronary artery flow reserve. *JAm Soc Echocardiogr*, Vol. 17, No. 6, (June 2004), pp. 700-703, ISSN 0894-7317
- Perry, R., De Pasquale, C.G., Chew, D.P., Brown, L., Aylward, P.E. & Joseph, M.X. (2008). Changes in left anterior descending coronary artery wall thickness detected by high resolution transthoracic echocardiography. *Am J Cardiol*, Vol. 101, No. 7, (April 2008), pp. 937-940, ISSN 0002-9149
- Perry, R., Joseph, M.X., De Pasquale, C.G., Chew, D.P., Yiu, D., Aylward, P.E., Mangoni, A.A. (2008). High-resolution transthoracic echocardiography of the left anterior descending coronary artery: a novel noninvasive assessment of coronary vasoreactivity. *JAm Soc Echocardiogr*, Vol. 21, No. 2, (February 2008), pp. 134-138, ISSN 0894-7317
- Picano, E., Sicari, R. & Vagra, A. (1999). Dipyridamole stress echocardiography. *Cardiol Clin*, Vol. 17, No. 3, (August 1999), pp. 481-499, ISSN 0733-8651
- Pizzuto, F., Voci, P., Mariano, E., Puddu, P. E., Sardella, G. & Nigri, A. (2001). Assessment of flow velocity reserve by transthoracic Doppler echocardiography and venous adenosine infusion before and after left anterior descending coronary artery stenting. *JAm Coll Cardiol*, Vol. 38, No. 1, (July 2001), pp. 155-162, ISSN 0735-1097
- Pizzuto, F., Voci, P., Mariano, E., Puddu, P.E., Chiavari, P.A. & Romeo, F. (2003). Noninvasive coronary flow reserve assessed by transthoracic coronary Doppler ultrasound in patients with left anterior descending coronary artery stents. *Am J Cardiol*, Vol. 91, No. 5, (March 2003), pp. 522-526, ISSN 0002-9149
- Pizzuto, F., Voci, P., Mariano, E., Puddu, P.E., Spedicato, P. & Romeo, F. (2004). Coronary flow reserve of the angiographically normal left anterior descending coronary artery in patients with remote coronary artery disease. *Am J Cardiol*, Vol. 94, No. 5, (September 2004), pp. 577-582, ISSN 0002-9149
- Pizzuto, F., Voci, P., Mariano, E., Puddu, P. E., Aprile, A. & Romeo, F. (2005). Evaluation of flow in the left anterior descending coronary artery but not in the left internal mammary artery graft predicts significant stenosis of the arterial conduit. *JAm Coll Cardiol*, Vol. 45, No. 3, (February 2005), pp. 424-432, ISSN 0735-1097
- Pizzuto, F., Voci, P., Puddu, P.E., Chiricolo, G., Borzi, M. & Romeo, F. (2006). Functional assessment of the collateral-dependent circulation in chronic total coronary occlusion using transthoracic Doppler ultrasound and venous adenosine infusion. *Am J Cardiol*, Vol. 98, No. 2, (July 2006), pp. 197-203, ISSN 0002-9149
- Pizzuto, F., Voci, P., Bartolomucci, F., Puddu, P.E., Strippoli, G., Brogna, L. & Rossi, P. (2009). Usefulness of coronary flow reserve measured by echocardiography to improve the identification of significant left anterior descending coronary artery stenosis assessed by multidetector computed tomography. *Am J Cardiol*, Vol. 92, No. 11, (December 2003), pp. 1320-1324, ISSN 0002-9149
- Rigo, F., Richieri, M., Pisanisi, E., Cutaia, V., Zanella, C., Valentina, P.D., Di Pede, F., Raviele, A. & Picano, E. (2003). Usefulness of coronary flow reserve over regional

- wall motion when added to dual-imaging dipyridamole echocardiography. *Am J Cardiol*, Vol. 91, No. 3, (February 2003), pp. 269–273, ISSN 0002-9149
- Rigo, F., Varga, Z., Di Pede, F., Grassi, G., Turiano, G., Zuin, G., Coli, U., Raviele, A. & Picano E. (2004). Early assessment of coronary flow reserve by transthoracic Doppler echocardiography predicts late remodeling in reperfused anterior myocardial infarction. *JAm Soc Echocardiogr*, Vol. 17, No. 7, (July 2004), pp. 750-755, ISSN 0894-7317
- Rigo, F., Cortigiani, L., Pasanisi, E., Richieri, M., Cutaia, V., Celestre, M., Raviele, A. & Picano, E. (2006). The additional prognostic value of coronary flow reserve on left anterior descending artery in patients with negative stress echo by wall motion criteria. A Transthoracic Vasodilator Stress Echocardiography Study. *Am Heart J*, Vol. 151, No. 1, (January 2006), pp. 124-130, ISSN 0002-8703
- Rigo, F., Sicari, R., Gherardi, S., Djordjevic-Dikic, A., Cortigiani, L. & Picano, E. (2007). Prognostic value of coronary flow reserve in medically treated patients with left anterior descending coronary disease with stenosis 51% to 75% in diameter. *Am J Cardiol*, Vol. 100, No. 10, (November 2007), pp. 1527–1531, ISSN 0002-9149
- Rigo, F., Sicari, R., Gherardi, S., Djordjevic-Dikic, A., Cortigiani, L. & Picano, E. (2008). The additive prognostic value of wall motion abnormalities and coronary flow reserve during dipyridamole stress echo. *Eur Heart J*, Vol. 29, No. 1, (January 2008), pp. 79–88, ISSN 0195-668x
- Ross, J.J., Mintz, G.S. & Chandrasekaran, K. (1990). Transthoracic two-dimensional high frequency (7.5 MHz) ultrasonic visualization of the distal left anterior descending coronary artery. *JAm Coll Cardiol*, Vol. 15, No. 2, (February 1990), pp. 373–377, ISSN 0735-1097
- Ruscasio, M., Montisci, R., Colonna, P., Caiati, C., Chen, L., Lai, G., Cadeddu, M., Pirisi, R. & Iliceto, S. (2002). Detection of coronary restenosis after coronary angioplasty by contrast-enhanced transthoracic echocardiographic Doppler assessment of coronary flow velocity reserve. *JAm Coll Cardiol*, Vol. 40, No. 5, (September 2002), pp. 896–903, ISSN 0735-1097
- Saraste, M., Vesalainen, R.K., Ylitalo, A., Saraste, A., Koskenvuo, J.W., Toikka, J.O., Vaittinen, M.-A., Hartiala, J.J. & Airaksinen K.E.J. (2005). Transthoracic Doppler echocardiography as a noninvasive tool to assess coronary artery stenoses – a comparison with quantitative coronary angiography. *JAm Soc Echocardiogr*, Vol. 18, No. 6, (June 2005), pp. 679-685, ISSN 0894-7317
- Sherrid, M.V., Mahenthiran, J., Casteneda, V., Fincke, R., Gasser, M., Barac, I., Thayaparan, R. & Chaudhry, F.A. (2006). Comparison of diastolic septal perforator flow velocities in hypertrophic cardiomyopathy versus hypertensive left ventricular hypertrophy. *Am J Cardiol*, Vol. 97, No. 1, (January 2006), pp. 106–112, ISSN 0002-9149
- Sicari, R., Rigo, F., Gherardi, S., Galderisi, M., Cortigiani, L. & Picano, E. (2008). The prognostic value of Doppler echocardiographic-derived coronary flow reserve is not affected by concomitant antiischemic therapy at the time of testing. *Am Heart J*, Vol. 156, No. 3, (September 2008), pp. 573-579, ISSN 0002-8703
- Sicari, R., Rigo, F., Cortigiani, L., Gherardi, S., Galderisi, M. & Picano, E. (2009). Additive prognostic value of coronary flow reserve in patients with chest pain syndrome and

- normal or near-normal coronary arteries. *Am J Cardiol*, Vol. 103, No. 5, (March 2009), pp. 626–631, ISSN 0002-9149
- Takeuchi, M., Miyazaki, C., Yoshitani, H., Otani, S., Sakamoto, K. & Yoshikawa J. (2001). Assessment of coronary flow velocity with transthoracic Doppler echocardiography during dobutamine stress echocardiography. *JAm Coll Cardiol*, Vol. 38, No. 1, (July 2001), pp. 117–123, ISSN 0735-1097
- Takeuchi, M., Ogawa, K., Wake, R., Takise, H., Miyazaki, C., Otani, S., Sakamoto K. & Yoshikawa, J. (2004). Measurement of coronary flow velocity reserve in the posterior descending coronary artery by contrast-enhanced transthoracic Doppler echocardiography. *JAm Soc Echocardiogr*, Vol. 17, No. 1, (January 2004), pp. 21-27, ISSN 0894-7317
- Takeuchi, M., Yoshitani, H., Otani, S. & Yoshikawa, J. (2005). Direct demonstration by transthoracic Doppler echocardiography of adenosine-induced coronary steal in the collateral-dependent vessel. *Am J Cardiol*, Vol. 95, No. 11, (June 2005), pp. 1363–1366, ISSN 0002-9149
- Takeuchi, M., Yoshitani, H., Miyazaki, C. & Yoshikawa, J. (2006). Relationship between the number of coronary risk factors and coronary atherosclerosis assessed by high-frequency transthoracic echocardiography. *JAm Soc Echocardiogr*, Vol. 19, No. 8, (August 2006), pp. 1056-1062, ISSN 0894-7317
- Tokai, K., Watanabe, H., Hirata, K., Otsuka, R., Muro, T., Yamagishi, H., Yoshiyama, M., Hozumi, T. & Yoshikawa, J. (2003). Noninvasive assessment of myocardial ischemia in the left ventricular inferior regions by coronary flow reserve measurement using transthoracic doppler echocardiography. *JAm Soc Echocardiogr*, Vol. 16, No. 12, (December 2003), pp. 1252-1257, ISSN 0894-7317
- Ueno, Y., Nakamura, Y., Kinoshita, M., Fujita, T., Sakamoto T. & Okamura, H. (2002). Can coronary flow velocity reserve determined by transthoracic Doppler echocardiography predict the recovery of regional left ventricular function in patients with acute myocardial infarction? *Heart*, Vol. 88, No. 2, (August 2002), pp. 137–141, ISSN 1355-6037
- Ueno, Y., Nakamura, Y., Takashima, H., Kinoshita, M. & Soma, A. (2002). Noninvasive assessment of coronary flow velocity and coronary flow velocity reserve in the right coronary artery by transthoracic Doppler echocardiography: Comparison with intracoronary Doppler guidewire. *JAm Soc Echocardiogr*, Vol. 15, No. 10 Pt 1, (October 2002), pp. 1074-1079, ISSN 0894-7317
- Voci, P. & Pizzuto, F. (2001). Coronary flow: how far can we go with echocardiography? *J Am Coll Cardiol*, Vol. 38, No. 7, (December 2001), pp. 1885–1887, ISSN 0735-1097
- Voci, P., Mariano, E., Pizzuto, F., Puddu, P. E. & Romeo, F. (2002). Coronary recanalization in anterior myocardial infarction. The open perforator hypothesis. *JAm Coll Cardiol*, Vol. 40, No. 7, (October 2002), pp. 1205–1213, ISSN 0735-1097
- Voci, P., Pizzuto, F., Mariano, E., Puddu, P.E., Chiavari, P.A. & Romeo, F. (2002). Measurement of coronary flow reserve in the anterior and posterior descending coronary arteries by transthoracic Doppler ultrasound. *Am J Cardiol*, Vol. 90, No. 9, (November 2002), pp. 988–991, ISSN 0002-9149
- Voci, P., Pizzuto, F., Mariano, E., Puddu, P.E., Sardella, G. & Romeo, F. (2003). Usefulness of coronary flow reserve measured by transthoracic coronary Doppler ultrasound to



- detect severe left anterior descending coronary artery stenosis. *Am J Cardiol*, Vol. 92, No. 11, (December 2003), pp. 1320–1324, ISSN 0002-9149
- Vrublevsky, A.V., Boshchenko, A.A. & Karpov, R.S. (2001). Diagnostics of main coronary artery stenosis and Occlusions: multiplane transoesophageal Doppler echocardiographic assessment. *Eur J Echocardiogr*, Vol. 2, No. 3, (September 2001), pp. 170–177, ISSN 1525-2167
- Vrublevsky, A.V., Boshchenko, A.A. & Karpov, R.S. (2004). Simultaneous transesophageal Doppler assessment of coronary flow reserve in the left anterior descending artery and coronary sinus allows differentiation between proximal and non-proximal left anterior descending artery stenoses. *Eur J Echocardiogr*, Vol. 5, No. 1, (January 2004), pp. 25–33, ISSN 1525-2167
- Watanabe, N., Akasaka, T., Yamaura, Y., Akiyama, M., Koyama, Y., Kamiyama, N., Neishi, Y., Kaji, S., Saito, Y. & Yoshida, K. (2001). Noninvasive detection of total occlusion of the left anterior descending coronary artery with transthoracic Doppler echocardiography. *J Am Coll Cardiol*, Vol. 38, No. 5, (November 2001), pp.1328–1332, ISSN 0735-1097
- Werner, G.S. & Figulla, H.R. (2002). Direct assessment of coronary steal and associated changes of collateral hemodynamics in chronic total coronary occlusions. *Circulation*, Vol. 106, No. 4, (July 2002), pp. 435–440, ISSN 0009-7322
- Werner, G.S., Fritzenwanger, M., Prochnau, D., Schwarz, G., Ferrari, M., Aarnoudse, W., Pijls, N.H. & Figulla, H.R. (2006). Determinants of coronary steal in chronic total coronary occlusions: donor artery, collateral, and microvascular resistance. *J Am Coll Cardiol*, Vol. 48, No. 1, (July 2006), pp. 51–58, ISSN 0735-1097
- West, A.M. & Kramer, C.M. (2009). Noninvasive imaging of the heart and coronary arteries. *Surg Clin North Am*, Vol. 89, No. 4, (August 2009), pp. 763-780, vii, ISSN 0039-6109
- Wikstrom, J., Gronros, J., Bergstrom, G. & Gan, L.-M. (2005). Functional and morphologic imaging of coronary atherosclerosis in living mice using high-resolution color Doppler echocardiography and ultrasound biomicroscopy. *J Am Coll Cardiol*, Vol. 46, No. 4, (August 2005), pp. 720–727, ISSN 0735-1097
- Youn, H.-J., Jeon, H.-K., Cho, E.-J., Oh, Y.-S., Chung, W.-S., Kim, J.-H., Choi K.-B., & Hong, S.-J. (2002). Slow flow on distal left anterior descending coronary artery demonstrated by transthoracic Doppler echocardiography predicts pathologic flow dynamics. *J Am Coll Cardiol*, Vol. 39, Suppl. 2, (March 2002), pp.268–269, ISSN 0735-1097
- Youn, H.-J. & Foster E. (2004). Demonstration of coronary artery flow using transthoracic Doppler echocardiography. *J Am Soc Echocardiogr*, Vol. 17, No. 2, (February 2004), pp. 178-185, ISSN 0894-7317
- Youn, H.-J., Park, C.-S., Cho, E.-J., Jung, H.-O., Jeon, H.-K., Lee, J.-M., Oh, Y.-S., Chung, W.-S., Kim, J.-H., Choi, K.-B. & Hong, S.-J. (2005). Left bundle branch block disturbs left anterior descending coronary artery flow: study using transthoracic Doppler echocardiography. *J Am Soc Echocardiogr*, Vol. 18, No. 10, (October 2005), pp. 1093-1098, ISSN 0894-7317



## **Coronary Angiography - Advances in Noninvasive Imaging Approach for Evaluation of Coronary Artery Disease**

Edited by Prof. Baskot Branislav

ISBN 978-953-307-675-1

Hard cover, 414 pages

**Publisher** InTech

**Published online** 15, September, 2011

**Published in print edition** September, 2011

In the intervening 10 years tremendous advances in the field of cardiac computed tomography have occurred. We now can legitimately claim that computed tomography angiography (CTA) of the coronary arteries is available. In the evaluation of patients with suspected coronary artery disease (CAD), many guidelines today consider CTA an alternative to stress testing. The use of CTA in primary prevention patients is more controversial in considering diagnostic test interpretation in populations with a low prevalence to disease. However the nuclear technique most frequently used by cardiologists is myocardial perfusion imaging (MPI). The combination of a nuclear camera with CTA allows for the attainment of coronary anatomic, cardiac function and MPI from one piece of equipment. PET/SPECT cameras can now assess perfusion, function, and metabolism. Assessing cardiac viability is now fairly routine with these enhancements to cardiac imaging. This issue is full of important information that every cardiologist needs to now.

### **How to reference**

In order to correctly reference this scholarly work, feel free to copy and paste the following:

Alla Boshchenko, Alexander Vrublevsky and Rostislav Karpov (2011). Transthoracic Echocardiography in the Assessment of Coronary Arteries, *Coronary Angiography - Advances in Noninvasive Imaging Approach for Evaluation of Coronary Artery Disease*, Prof. Baskot Branislav (Ed.), ISBN: 978-953-307-675-1, InTech, Available from: <http://www.intechopen.com/books/coronary-angiography-advances-in-noninvasive-imaging-approach-for-evaluation-of-coronary-artery-disease/transthoracic-echocardiography-in-the-assessment-of-coronary-arteries>

**INTECH**  
open science | open minds

### **InTech Europe**

University Campus STeP Ri  
Slavka Krautzeka 83/A  
51000 Rijeka, Croatia  
Phone: +385 (51) 770 447  
Fax: +385 (51) 686 166  
[www.intechopen.com](http://www.intechopen.com)

### **InTech China**

Unit 405, Office Block, Hotel Equatorial Shanghai  
No.65, Yan An Road (West), Shanghai, 200040, China  
中国上海市延安西路65号上海国际贵都大饭店办公楼405单元  
Phone: +86-21-62489820  
Fax: +86-21-62489821

© 2011 The Author(s). Licensee IntechOpen. This chapter is distributed under the terms of the [Creative Commons Attribution-NonCommercial-ShareAlike-3.0 License](#), which permits use, distribution and reproduction for non-commercial purposes, provided the original is properly cited and derivative works building on this content are distributed under the same license.

IntechOpen

IntechOpen