

We are IntechOpen, the world's leading publisher of Open Access books Built by scientists, for scientists

4,800

Open access books available

122,000

International authors and editors

135M

Downloads

Our authors are among the

154

Countries delivered to

TOP 1%

most cited scientists

12.2%

Contributors from top 500 universities



WEB OF SCIENCE™

Selection of our books indexed in the Book Citation Index
in Web of Science™ Core Collection (BKCI)

Interested in publishing with us?
Contact book.department@intechopen.com

Numbers displayed above are based on latest data collected.

For more information visit www.intechopen.com



The Role of 3D Ultrasound in Assessment of Endometrial Receptivity and Follicular Vasculature to Predict the Quality Oocyte

T. Žáčková^{1,2}, I.Y. Järvelä¹ and T. Marděšič

¹*Department of Obstetrics and Gynecology, Oulu University Hospital, Oulu*

²*Institute for the Care of Mother and Child (UPMD), Department of IVF*

Charles University, Prague

³*Sanatorium Pronatal, Praha*

¹*Finland*

^{2,3}*Czech Republic*

1. Introduction

The success of human and embryo implantation depends on maternal and embryonic factors and their interactions. To assess uterine receptivity one must take various factors into account. Current advances in transvaginal 3D ultrasonography have allowed us to examine in detail and visualize pelvic organ structures to analyse their volumes with great accuracy (Alcazar et al., 2006), (Raga et al., 1999). It is reasonable to believe that an analysis of power Doppler signals in a volume better reflects the overall vascularization in an organ than analysis of a two-dimensional (2D) ultrasound image or measurement of blood flow velocity in a single or a few vessels. Using 3D Power Doppler Angiography we can assess both arterial and venous circulation also the whole architecture of the vascular net into a volumetric image with the possibility of an overall evaluation of blood flows, and computer analysis makes this assessment objective (Jokubkiene et al., 2006). The VOCAL (Virtual Organ Computer - aided Analysis) and volume calculation is semi-automatic type of calculating volumes starting from the rotation of the organ target of study. Allows to calculate partial volumes and at the same time the of vascular system and flows into the region of interest. Two dimensional Doppler sonography provides a subjective estimation of uterine and ovarian vascularity. Is it limited, however, by providing flow depiction in a single plane as opposed to the sample volume as obtained by free dimensional imaging. Therefore, three dimensional ultrasound and power Doppler angiography (3D US-PDA) have advantage of assessing simultaneously both the endometrial blood flow and endometrial volume (EV) (Merce et al., 2008) and improves better traditional ultrasound scanning imaging with the possibility of storing information for further analysis or share datasets through telemedicine.

The follicular blood flow seems to play a major role during the growth and development of the follicle containing the oocyte (Chui et al., 1997), (Coulam et al., 1999). The surge in perifollicular angiogenesis during selection of dominant follicles and following the LH surge or HCG can be detected by measurement of perifollicular flow/velocities. This allows identification of those follicles likely to produce high quality eggs and embryos. 3D surface

rendering at 4x magnification can show the blood vessels in the follicular wall and can identify features incompatible with successful oocyte retrieval (Cambell, 2010).

2. Evaluation of endometrial receptivity

Failure of implantation remains the main reason why most IVF treatment fails to result in pregnancy. Angiogenesis plays a critical role in various female reproductive processes such as development of dominant follicle, formation of a corpus luteum, growth of endometrium and implantation. A good blood supply towards the endometrium is usually considered as an essential requirement for implantation. The ability to identify a receptive uterus prospectively by a noninvasive method would have an invaluable clinical impact on treatment efficiency and success rates. This chapter explores the role of transvaginal three dimensional ultrasound (3D US) and 3D power -Doppler ultrasound (3D-PDA) in evaluation of endometrial receptivity.

2.1 Technical aspects and three dimensional data analysis

3D US images can be obtained by two methods: freehand and automated. The freehand method requires manual movement of the transducer through the ROI. The automated method acquires the images using dedicated 3D transducers. When these probes are activated, the transducer elements automatically sweep through the ROI selected by the operator (the so-called "volume box") while the probe is held stationary. This provides more accuracy to this method as compared with the freehand systems, in which speed of sweep is more difficult to maintain constant manually by the operator. The digitally stored volume data can be manipulated and presented in various displays: multiplanar display, "niche" mode or surface rendering mode. Probably, the most used and useful display is multiplanar display, which simultaneously shows three perpendicular planes (axial, sagittal and coronal), allowing navigation through these three planes with the possibility of switch over any desired plane (Alcazar et al, 2006). There are two basic methods employed to calculate volume from a three dimensional dataset: the conventional „full planar,, or „contour,, method and the more recently introduced „rotational,, method possible through the VOCAL -imaging program (Virtuala Organ Computer aided analysis). This rotational method based on rotations in given steps (6°, 9°, 15°, 30°) on a given orthogonal plane (A, B or C). Vascularization of tissues within the ROI can be also assessed using 3D Power -Doppler ultrasound (3D PDA) and the VOCAL program. Three Indices of vascularity are calculated: the Vascularization Index (VI) reflects the ratio of power Doppler information within the total dataset relative to both colour and grey information, the Flow Index (FI) represents the mean power Doppler signal intensity and the Vascularisation Flow index represents a combination of the two (Pairleitner et al., 1999). Using the „shell,, function it is possible to calculate a volume at different thickness around the predetermined endometrium and estimate the vascularization in this „shell,,. This allows the assessment of the so-called „subendometrial region,, (Alcazar et al, 2006).

2.2 Results and authors studies

The pregnancy outcome of frozen embryo transfer is known to be dependent on multiple clinical and embryological factors, including the age of the woman at IVF/ICSI treatment; (Salumets et al, 2006), (Wang et al, 2001), the method of oocyte fertilization used (Van Steirteghem et al, 1994), (Salumets et al, 2006), the developmental stage of embryos at freezing (Salumets et al, 2003), the embryo quality before freezing (Schalkoff et al, 1993), the extent of embryo damage after thawing (Edgar et al, 2000) and the resumption of post-thaw

blastomere divisions (Van der Elst et al., 1997). On the other hand the risk of pregnancy loss is similar after cryopreservation and fresh IVF or ICSI (Aytoz et al., 1999) and embryo morphology is not related to the miscarriage rates in any of the treatment modalities studied (Veleva et al., 2008). Several ultrasound parameters of the endometrium and the evaluation of uterine and endometrial blood flow have been proposed for assessing endometrial receptivity, including endometrial thickness, endometrial pattern and endometrial and subendometrial blood flow and considered as implantation markers in vitro fertilization (IVF) and embryo transfer cycles. These parameters may identify patients with low implantation potential. However, their positive predictive value is low. No differences were found in endometrial thickness, endometrial volume, endometrial pattern, uterine PI, uterine RI, endometrial and subendometrial 3D power Doppler flow indices between the nonpregnant and pregnant groups on LH+1 (1 day after the LH surge) during frozen-thawed embryo transfer cycles (Ng et al., 2006). Nevertheless another studies suggested any correlations between the thickness of endometrium and pregnancy rate during the treatment with assisted reproductive technology. There was the endometrial thickness decreases as function of the patients age on the day of HCG administration during an IVF cycle. (Amir et al., 2007). In our study at the time of embryo transfer only the structure of endometrium seems to be of significance and 3D power Doppler ultrasound and steroids levels does not provide us any additional information at this point. The 3D transvaginal ultrasound measurements (Voluson Expert 730, Kretz, Zipf, Austria) were performed on the day of the FET and repeated about one week later, at the time of the expected implantation. The 3D ultrasound technique enabled the determination of endometrial, subendometrial, and ovarian volume, including possible changes in the vascular network. Identical preinstalled instrument settings (frequency, mid; dynamic set, 2; balance, G>170; smooth, 5/5; ensemble, 16; line density, 7; power Doppler map, 5; and the setting conditions for the power Doppler mode were gain, -5.6; quality, normal; wall motion filter, low 1; peak repetitive frequency PRF, 0.9 kHz) were applied for all patients. At the second visit, the power Doppler mode was not used to examine the uterus. During the ultrasound examination, the uterus was first visualized in two-dimensional (2D) B-mode after the patient had emptied her bladder. The power Doppler mode was switched on, and the power Doppler box was positioned to cover the whole uterus. The 3D facility was engaged by switching to 'volume mode. The volume sector angle was preset to 80°, and the fast volume acquisition (low-resolution) setting was selected to avoid artifacts. Thereafter, the ovaries were examined similarly. The ultrasonographic volume data were saved on the hard drive and analyzed later using the built-in virtual organ computer-aided analysis imaging program (VOCAL, GE Healthcare, Zipf, Austria) for 3D power Doppler histogram analysis. The manual mode of the VOCAL Contour Editor was used to cover the whole 3D volume of the region of interest (ROI), with 15° rotation steps. Hence, 12 contour planes were analyzed for each ROI to cover 360°. After obtaining the total volume of the ROI, the program calculated the ratio of color voxels to all the voxels; this ratio (%) was expressed as the vascularization index (VI). The vascularized volume (unit mL) in the endometrium or in the ovary was calculated by multiplying the total volume of the ROI by its VI. The VOCAL program automatically calculated the index for mean grayness (MG) in the ROI, which presents the average grayness in the gray-scale voxels. We have reported only vascularization index and vascularized volume (VI x volume), since only the last one has been shown to reflex corpus luteal function in several studies (Järvelä et al., 2007; Järvelä et al., 2008; Niinimäki et al 2009). We have not analysed any data concerning VI or VFI, neither do we have any intention to analyse them, because we are unaware what kind of physiological phenomena they reflect (Zackova et al., 2009).

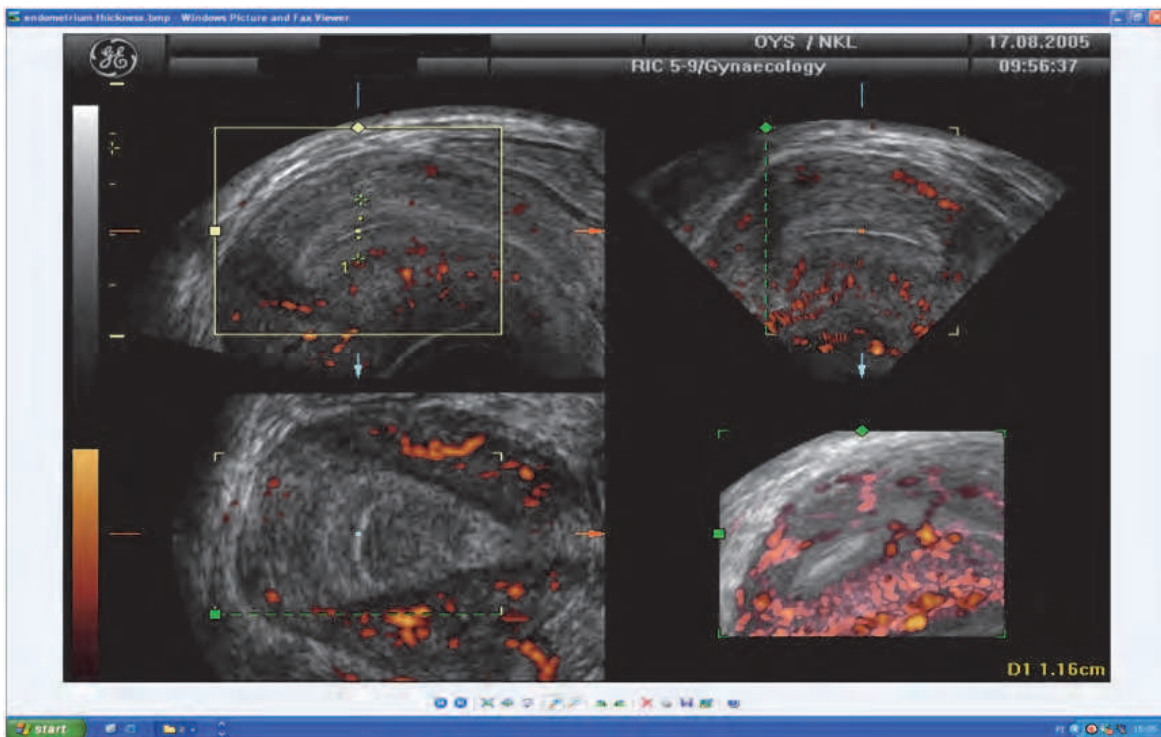


Fig. 1. Three dimensional multiplanar depicting multiplanar display of the uterus. All three orthogonal planes can be displayed using this technique. Endometrium thickness measurement.

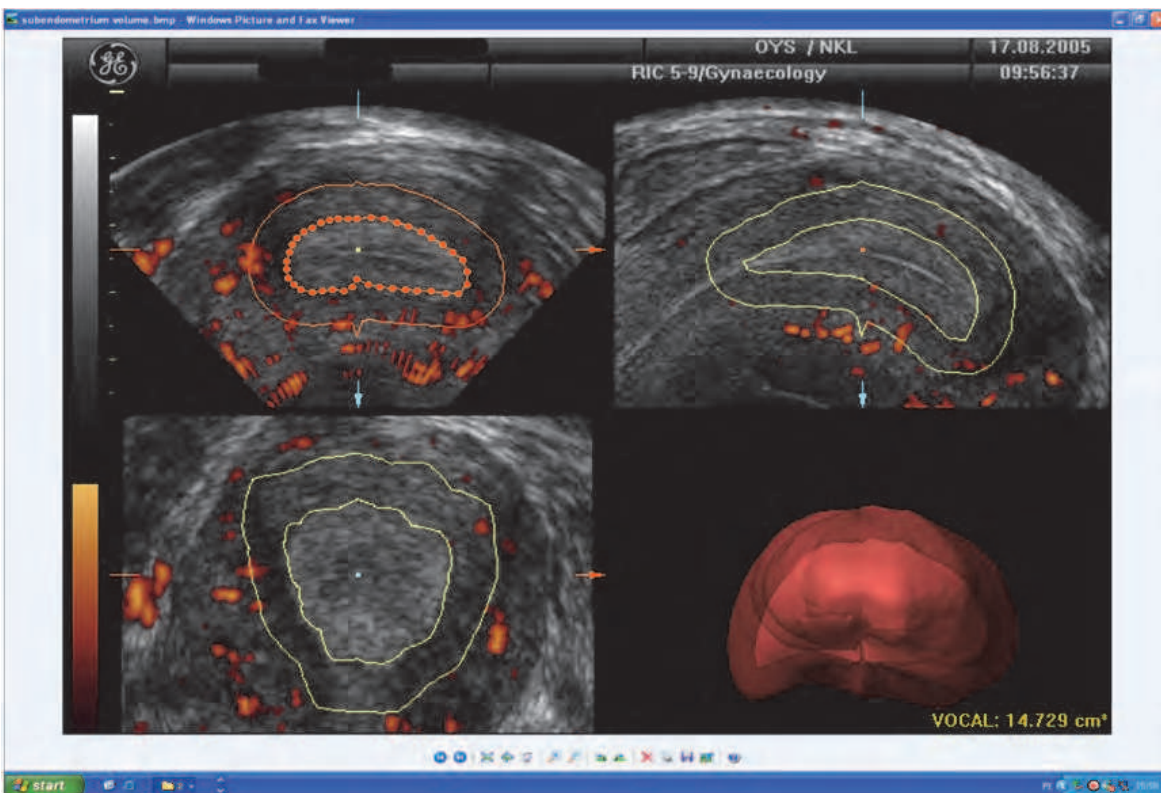


Fig. 2. Endometrial volume calculation by using VOCAL software after three dimensional ultrasound . Determination of the subendometrial area volume by using the „shell „ facility. In this case 5 mm has been chosen.

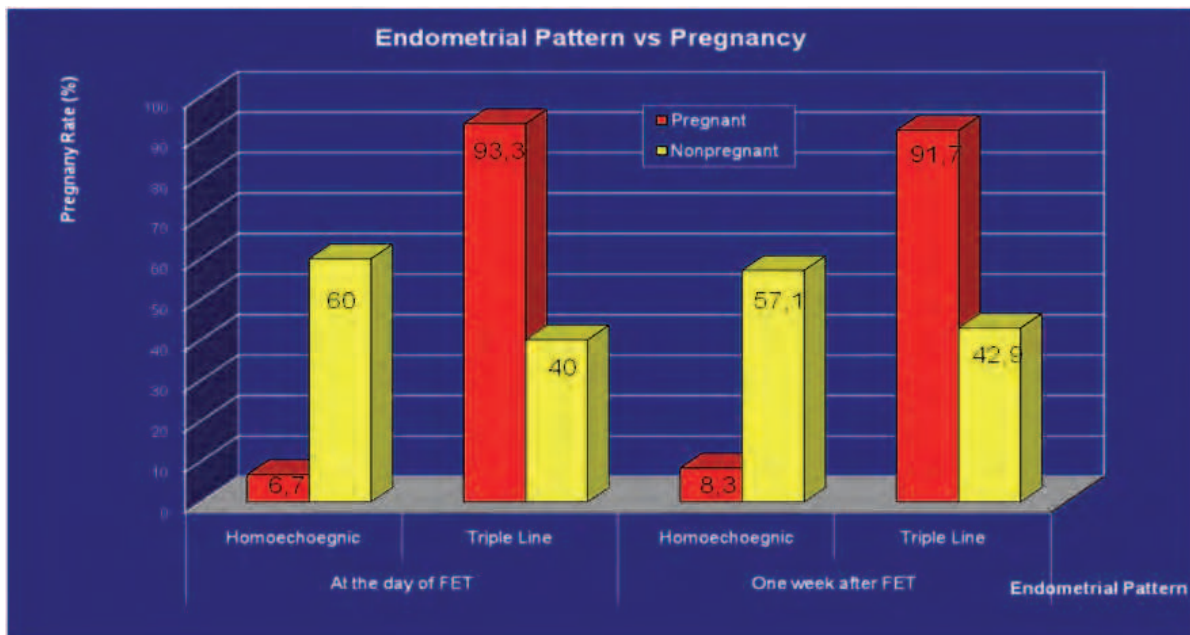


Fig. 3. The endometrial echo patterns in the pregnant group (93.3% vs. 40.0%, 95% CI 25.5-81.2%) on the day of FET and one week after (91.7% vs. 42.9%, 95% CI 18.5-79.1%). No differences were observed in the dominant ovarian vasculature.

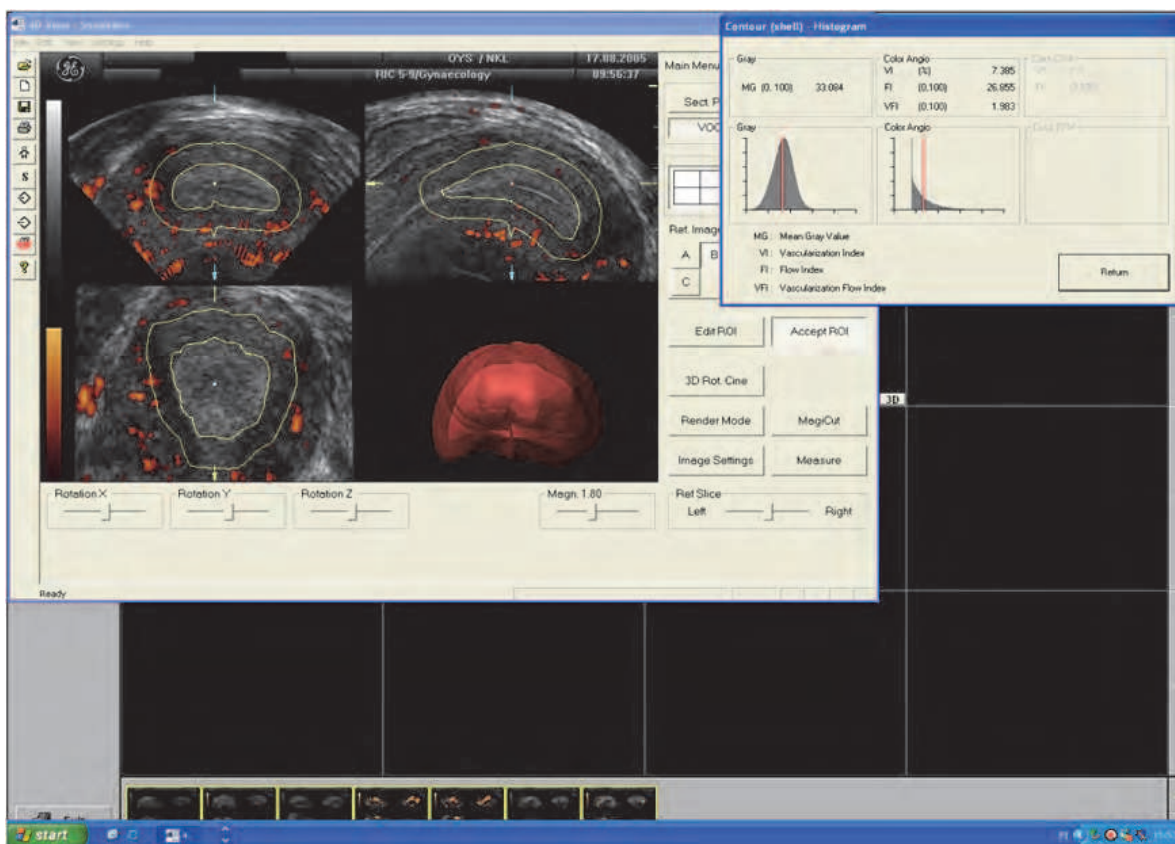


Fig. 4. Vascularization of the subendometrial area by 3D -Power Doppler . 3D power doppler indexes VI,FI, and VFI refers to the shell area- subendometrium. Determination of the subendometrial area volume by using the „shell „ facility. In this case 5 mm has been chosen

2.3 Assessment of endometrial echogenicity

In the recent literature there has been interest in the possible relationship between the degree of endometrial echogenicity an IVF-ET outcome and the cycles sorted into six groups according to the extent of the upward hyperechogenic transformation of the endometrium. In contrast to the similarity in individual, control ovarian hyperstimulation /COH / and embryology data among groups, they observed a dramatic decrease in clinical and ongoing pregnancy as well as in implantation rates from the lowest to the highest endometrial

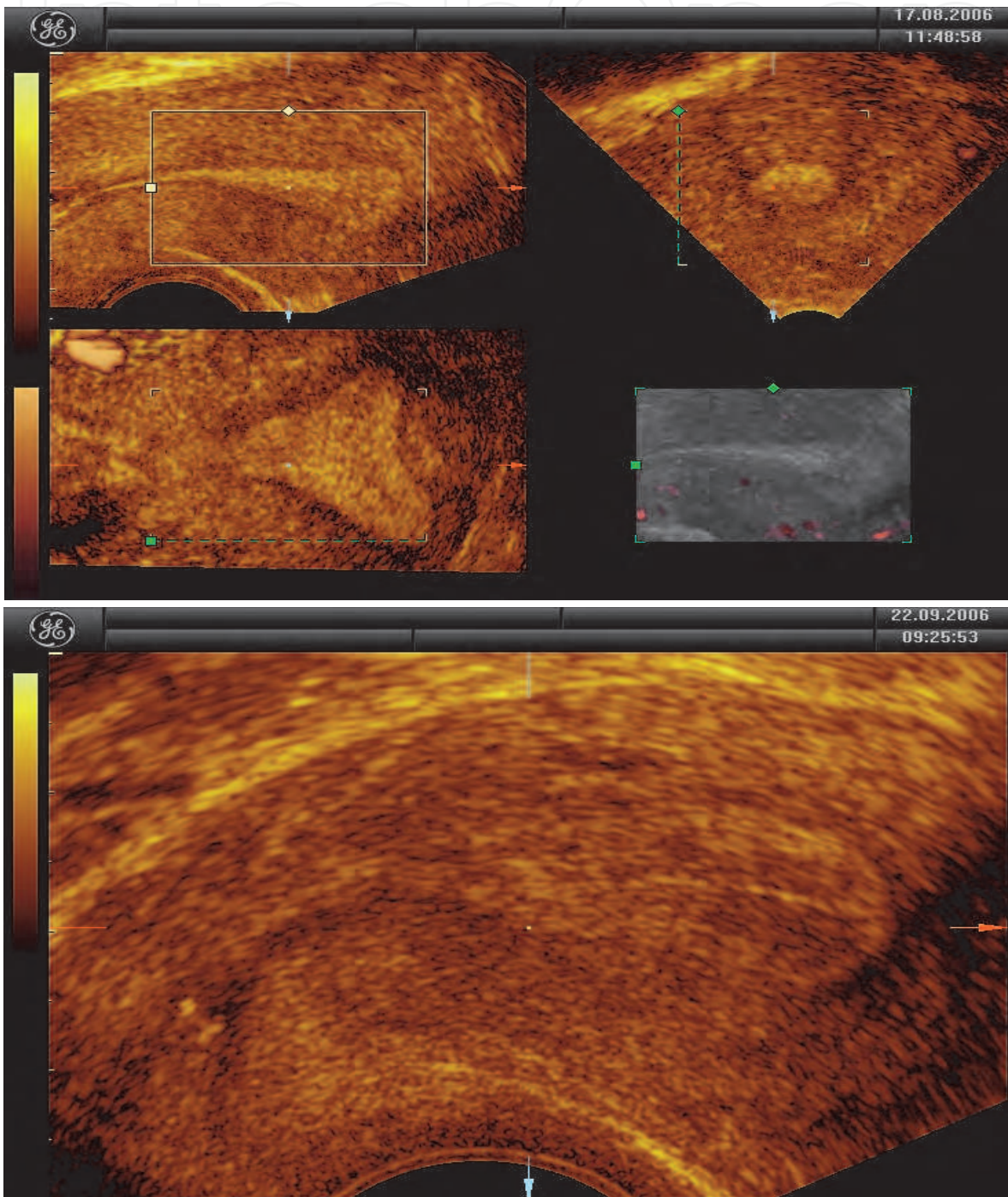


Fig. 5. The endometrial pattern, which was assessed in the longitudinal section and described as triple-line or homoechogenic.

echogenicity groups. Conversely, no relationship between endometrial thickness on the day of hCG administration and IVF-ET outcome was observed (Fanchin et al., 2001). This ultrasonographic aspect may be reflection of glandular straightness, reduced glandular secretion, and reduced stromal edema that characterize the proliferative endometrium, with a decreased number of interfaces to ultrasound. Since the echogenicity of the secretory endometrium is usually higher than in the surrounding myometrium, we assessed the echogenicity in these two areas subjectively and used software to provide the MG values. A strong correlation between these two methods was observed. Future studies will show whether this index has clinical value (Zackova et al., 2009).

3. Color Doppler sonography for the the optimization of follicular vascularity

The 2D color Doppler studies have show that perifollicular blood flow of individual follicles during IVF treatment correlates with oocyte recovery (Nargund et al., 1996) ,oocyte developmental potential (Van Blerkom et al., 1997), embryo quality (Nargund et al., 1996), (Chui et al., 1997) and pregnancy rate (Coulam et al.,1999). We analysed relationship between kind of stimulated protokol and cause of sterility to determine ovarian and dominant follicle blood flow characteristics using three dimensional power Doppler ultrasound , grading system of perifollicular vascularity (Chui et al, ,1997) and power doppler index PI and RI of dominant follicle artery in the prospective pilot study of 17 women in IVF/ICSI stimulation.

Materials and methods. 17 the patients were stimulated in a long protocol (GnRh agonist-Zoladex, Decapeptyl) on 22-th day of their period and subsequently with rekombinant FSH (puregon /gonal pen) 15 days after downregulation / no follicles more than 10 mm, endometrium thickness less than 5 mm and level of Estradiol /E2/ less than 50 pg/ml. We excluded the women, who didn ' t agree with the examination on the day of ovum pick up futher such as women , whose stimulation was stopped for the risk of OHSS, women with the operation of right or left ovary, women with ovaectomy , women with uterine malformation , women with FSH level more than 10 mIU/l in early follicular period or women with ovarian cysts. On the basis of male factor infertility exclusion we provided always ICSI Method. The 3D ultrasound examinations and power doppler sonography of the ovary and dominant follicle we provided on the day HCG (pregnyl) before ovum pick up. All the 3D ultrasound and PDA examinations were carried out by a single observer (T.Z) and all the patients were explored in a gynaecological position using Voluson Expert 760, Kretz, Zipf, Austria equipped with vaginal multifrequency (from 3 to 9 mHz) volume transducer, which has a 146 ° field of view. The volume of the ovary and dominant follicle, vascularization index /VI/, flow index /FI/, vascularization flow index / VFI / , mean grayness , perifollicular vascularity and PI a RI of the dominant follicle was determined for each ovary separately. The dominant follicle is presented by maximal mean diameter (MD). Follicular volume (FV) was etermined for each follicle according to the sphere formula : $FV (ml) = 4,1888 \times (MD/2 (cm))^3$. The power dopler Windows was placed on the maximum longitudinal plane of both ovaries,including the whole ovarian surface. The following Doppler predetermined characteristics were applied in every patient (colour gain from -3 to -7 ,normal colour quality, wall motion filter,low 1, peak repetitive frequency PRF ,0.9 KHz). When an adequate power Doppler signal was achieved, we placed the 3D box to aquire the volume from the region of interest (ROI). The VOCAL imaging program was used tu calculate the ovarian volume and 3D power Doppler indices . Using the manual mode, the contour of the different ovarain slices was traced by taking 15° rotational steps by using the longitudinal plane as the work plane. 3D power Doppler indices were calculated using the histogram

facility. Vascularization Index (VI) is the number of colour voxels in the volume studied, symbolizing in this way the number of vessels arriving to the organ, expressed as a percentage. The Flow Index (FI) is the mean colour value of the colour voxels, thus representing the average blood flow intensity, expressed as a whole number rating from 0 to 100. VFI integrates both vascularization and blood flow (tissues perfusion). It is also expressed as a whole number rating from 0 to 100, and represents color value of grey and colour voxels in the studied ROI (Paireleitner et al., 1999). The Grading system (Chui, et al. 1997) was used to assess perfollicular vascularity. (a) shows 25% circumferential flow (Grade 1); (b) 26–50% flow (Grade 2); (c) 51–75% flow (Grade 3) and (d) 75% flow (Grade 4), where follicles of high grade follicular vascularity are associated with grade 3 and 4. The oocyte of the dominant follicle from both ovaries was fertilized by ICSI and observed his embryogeny. The embryos were classified into four morphological grades in accordance with our conventional criteria (Kondo et al., 1996) consisting of blastomere size and the amount of anucleate fragmentation (conventional method): grade 1 (g1), blastomere uniform in size and shape and little or no fragmentation; grade 2 (g2), blastomeres uneven in size and shape and/or fragmentation <10% of the embryonic surface; grade 3 (g3), fragmentation of 10–30% of the embryonic surface; and grade 4 (g4), fragments >30% of the embryonic surface. On the day of ovum pick up we have collected the samples of follicular fluid of dominant follicle without of blood contamination. After the collecting of samples of follicular fluid of dominant follicle and serum we provided their centrifugate and stored at -40 C until their planned biochemical analysis after the completed collection of the samples at all intended 80 patients.

Results .The IVF/ICSI cycle was evaluated in 17 women, among which 5 were pregnant (29.4 %) and 12 non-pregnant (70.6 %). The median age of the women was 32 (range 26-36). The causes of the infertility were male in 12 cases (70.6 %), tubal in 2 cases (11.8 %) and mixed in 3 cases (17.6 %). There were 11 cases (64.7 %) of primary and 6 cases (35.3 %) of secondary infertility. Statistical analysis of the data was performed with R programming language (<http://cran.r-project.org>), version 2.4.1. We have computed descriptive statistics and p-values of hypothesis tests for comparing the group of pregnant and non-pregnant patients. For continuous data the normality is not assumed because of small sample sizes and asymmetry of the data distribution. The following tables give the median and range (minimum and maximum) of each continuous variable together with the p-value of the two-sample Wilcoxon test. For categorical data we list the tables of counts with percentages of cases. To compare the two groups, the p-value of Fisher's exact test is computed (also for tables larger 2 by 2). Ultrasonography and Doppler angiography parameters measured on both ovaries are analyzed for each ovary separately. There is no significant difference between groups in the age of patients, type and causes of infertility and other general and clinical characteristics. In the group of pregnant women, there is a significantly larger number of grade 1 embryos on transfer day, a significantly larger flow index dx and there is a significant difference in the degree of morphological preimplantation quality of the 1. and 2. transferred embryos and in the degree of perfollicular vascularity of the right follicle dx. Other variables yield a non-significant difference between the pregnant and non-pregnant group because of small sizes of the data samples; however the p-values are near the 5%-level for the vascularization index and vascularization flow index, for which the observed values have the tendency to be larger for pregnant women and a future research with a larger number of patients is intended to attain significant results.

Implications. The follicular vascularity assesment with 3D ultrasonography and PDA of ovaries may represent a possible predictors of the the outcome of assisted conception therapy. Future research with a larger number of patients is intended to attain significant results ant to confirm these findings .

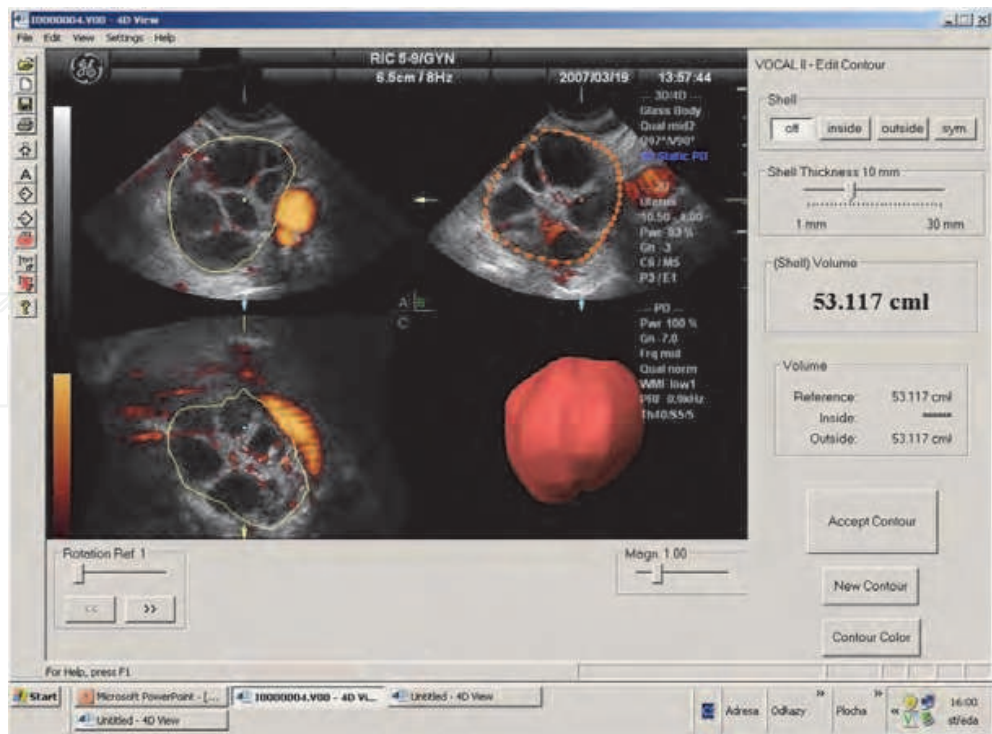


Fig. 6. Assessment of the ovarian volume by the virtual organ computer-aided analysis (VOCAL). Using the manual mode, the contour of different ovarian slices was traced by rotational steps every 15 ° taking the longitudinal plane as the work pattern.

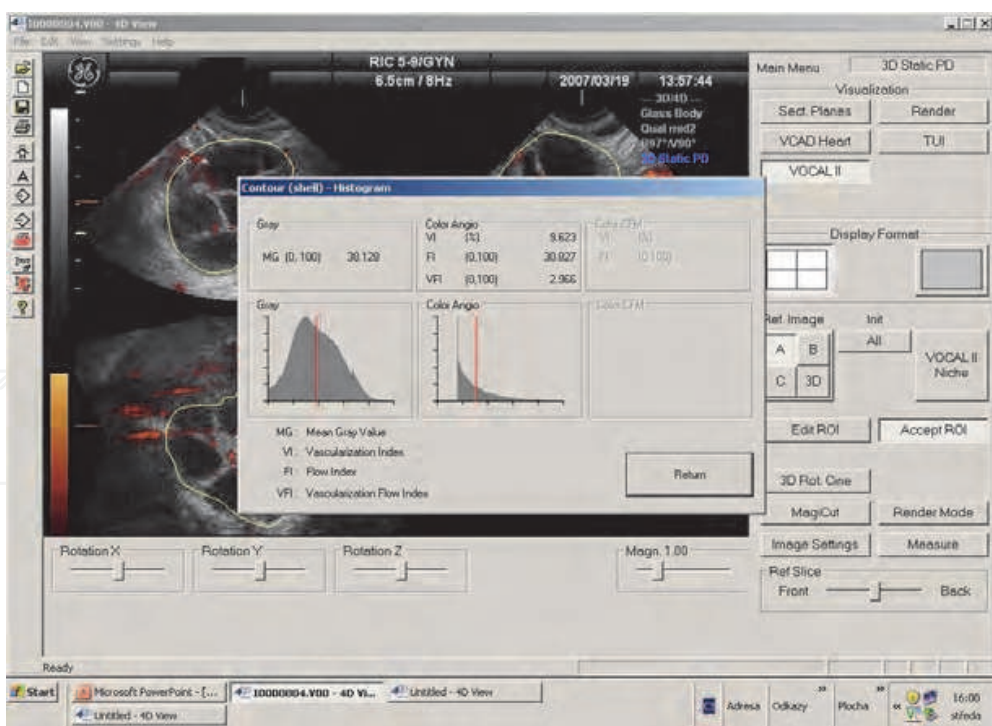


Fig. 7. Evaluation of the ovarian vascularity by three-dimensional power Doppler indices: vascularization index (VI), flow index (FI) and vascularization flow index (VFI). These indices were calculated using the histogram facility provided by the virtual organ computer-aided analysis (VOCAL) program.

Parametrs	Pregnant (n=5)	Non pregnant (n=12)	P-value
Age (years)	32 (26-34)	32 (29-36)	0.488
Total dosage of FSH (IU)	2250 (1500-2825)	2250 (1 800-3 750)	0.560
Days of FSH treatment	14 (10-15)	13 (10-19)	0.873
Number of follicles > 16 mm on day of OPU	10 (6-28)	10 (5-17)	1.000
Number of retrieved oocytes	6 (4-21)	7.5 (3-14)	0.792
Number of fertilized oocytes	6 (3-16)	4.5 (3-10)	0.486
Number of grade 1 embryos on transfer day	3 (2-4)	0 (0-2)	0.001
Day of embryo transfer	3 (2-5)	3 (0-5)	0.914
Type of infertility			0.600
Primary	4 (36.3)	7 (63.6)	
Secondary	1 (16.7)	5 (83.3)	
Cause of infertility			0.547
Male factor	4 (33.3)	8 (66.7)	
Tubal factor	1 (50.0)	1 (50.0)	
Mixed	0 (0.0)	3 (100.0)	
Number of transferred embryos			1.000
1	0 (0.0)	1 (100.0)	
2	5 (31.2)	11 (68.8)	

Table 1. General and clinical parameters in relation to IVF/ICSI outcome

Parameters	Pregnant (n=5)	Non pregnant (n=12)	P-value
Degree of morphological preimplantation quality of transferred embryos 1.			0.029
1	5 (55.6)	4 (44.4)	
2	0 (0.0)	8 (100.0)	
3	0	0	
4	0	0	
Degree of morphological preimplantation quality of transferred embryos 2.			0.020
1	4 (80.0)	1 (20.0)	
2	1(14.3)	6 (85.7)	
3	0 (0.0)	4 (100.0)	
4	0	0	
Not obtained	0 (0.0)	1 (100.0)	
Grade of morphological reimplantation quality of selected oocytes from 3D measures dominant follicles dx			0.080
1	2 (100.0)	0 (0.0)	
2	3 (33.3)	6 (66.7)	
3	0 (0.0)	4 (100.0)	
4	0 (0.0)	1 (100.0)	
Not obtained	0 (0.0)	1 (100.0)	
Grade of morphological preimplantation quality of selected oocytes from 3D measures dominant follicles sin			0.755
1	2 (66.7)	1 (33.3)	
2	1 (33.3)	2 (66.7)	
3	2 (28.6)	5 (71.4)	
4	0	0	
Not obtained	0 (0.0)	4 (100.0)	

Table 2. Embryological parameters in relation to IVF/ICSI outcome

Parameters	Pregnant(n=5)	Nonpregnant (n=12)	p-value
Total ovarian volume OV (ml) dx	43.96 (41.69-138.13)	42.55 (19.52-108.60)	0.279
Total ovarian volume OV (ml) sin	45.06 (43.86-116.96)	42.06 (11.32-102.38)	0.316
Volume of the dominant follicle FV (ml) l.dx	6.08 (5.28-6.43)	5.38 (2.36-7.05)	0.154
Volume of the dominant follicle FV (ml) l.sin	5.09 (4.08-5.65)	4.98 (3.26-9.63)	0.570
Vascularization index VI l.dx	12.47 (8.66-20.06)	8.22 (2.61-19.06)	0.066
Vascularization index VI l.sin	10.38 (5.02-25.43)	8.54 (6.20-11.72)	0.107
Flow index FI l.dx	47.85 (42.78-52.25)	40.46 (32.31-57.66)	0.044
Flow index FI l.sin	46.90 (35.23-48.90)	41.91 (28.83-51.47)	0.099
Vascularization flow index VFI l.dx	4.95 (2.85-8.46)	4.00 (0.90-10.05)	0.065
Vascularization flow index VFI l.sin	4.84 (2.30-10.05)	3.91 (2.82-4.62)	0.087
Resistance index Doppler of the dominant follicle l.dx	0.56 (0.55-0.62)	0.53 (0.42-0.67)	0.081
Resistance index Doppler of the dominant follicle l.sin	0.58 (0.50-0.62)	0.55 (0.38-0.71)	0.691
Pulsatility index Doppler of the dominant follicle l.dx	0.89 (0.83-1.00)	0.82 (0.65-1.24)	0.224

Table 3. Three - dimensional ultrasonography , Power doppler angiography parametrs on the HCG day in relation to IVF/ICSI outcome . Date are presented as mean +/- standart deviation.

Parameters	Pregnant(n=5)	Nonpregnant (n=12)	p-value
Degree of perfollicular vascularity of the dominant follicle l.dx			0.029
1.	1 (11.1)	8 (88.9)	
2.	1 (20.0)	4 (80.0)	
3.	3 (100.0)	0 (0.0)	
Degree of perfollicular vascularity of the dominant follicle l.sin			0.093
1.	1 (12.5)	7 (87.5)	
2.	2 (33.3)	4 (66.7)	
3.	2 (100.0)	0 (0.0)	

Table 4. Perifollicular vascularity grading score on the HCG day in relation to IVF/ICSI outcome. Data are presented as mean +/- standard deviation. Grading system (Chui, et al. 1997) used to assess perifollicular vascularity.

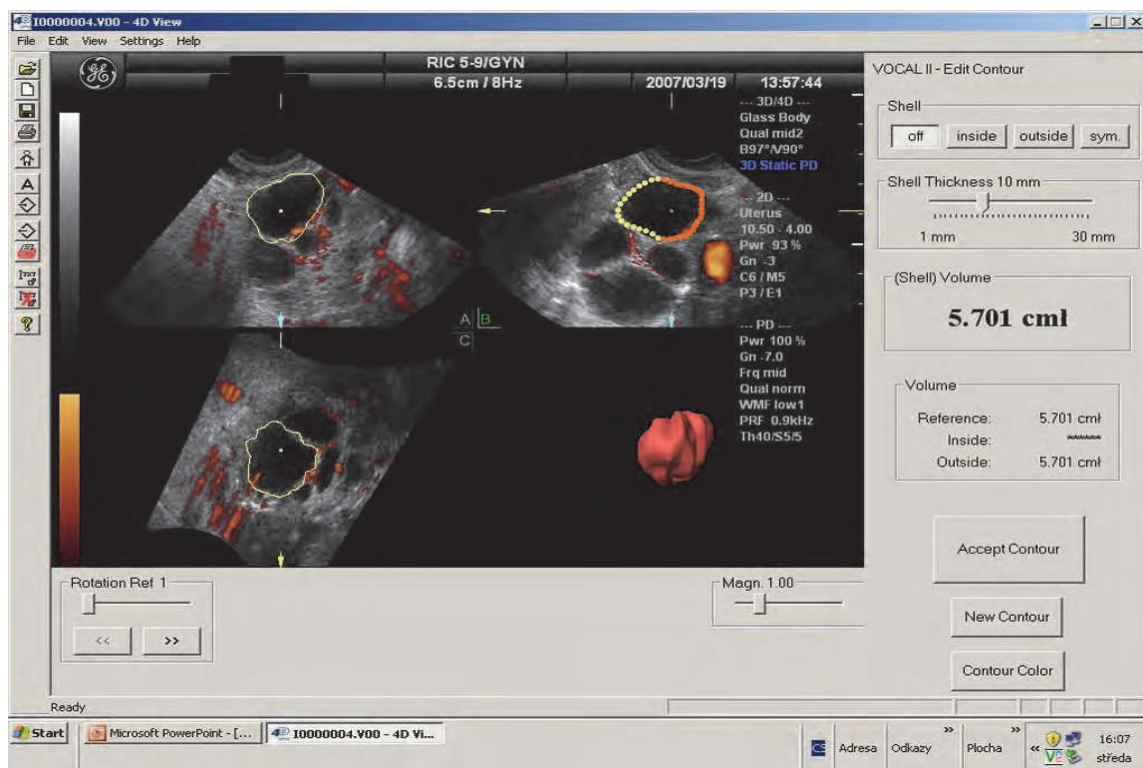


Fig. 8. Dominant follicle volume calculation by using the VOCAL software after three-dimensional ultrasound. The dominant follicle is presented by maximal mean diameter (MD). Follicular volume (FV) was determined for each follicle according to the sphere formula : $FV (ml) = 4,1888 \times (MD/2 (cm))^3$.

4. Conclusions

Developments in infertility treatment assisted reproduction methods are directed to transfer a single high quality embryo, while maintaining a high standard of treatment success. In this context, in recent years recede into the background, the standard "stimulation protocols using higher doses of FSH, often with a higher number of oocytes. The importance of more and more become "soft stimulation protocols aimed at, although a smaller number of growing follicles, which are a source of high-quality oocytes. The Natural / Mild IVF management / ISMAAR / requires greater understanding of medical physiology, follicular growth and endometrial receptivity, which can be investigated using high-quality 2D and 3D ultrasound Doppler ultrasound and ultrasound, as evidenced by the results of our work. In this context, early identification of high-quality follicles might serve as one means of enabling a timely selection of oocytes and embryos with high developmental competence and the hope of a successful implantation. The follicular vascularity assessment with 3D ultrasonography and PDA of ovaries may represent a possible predictors of the the outcome of assisted conception therapy. Future research with a larger number of patients is intended to attain significant results and to confirm these findings . Definition of new applications of 3D ultrasound in the diagnosis of women enrolled in the program of assisted reproduction and the definition of predictive factors in the evaluation of the oocyte quality would have a significant contribution to our everyday clinical practice.

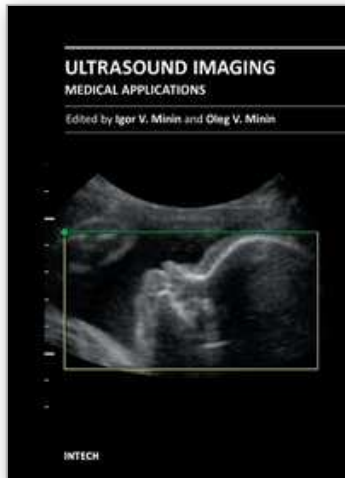
5. References

- Alcazar ,JL.(2006). Three-dimensional ultrasound assessment of endometrial receptivity: a review. *Reprod Biol Endocrinol. Vo.4* , November 9,pp.56, ISSN1477-7827
- Amir ,W.; Micha, B.; Ariel ,H.; Liat, LG.; Jehoshua ,D. &Adrian, S. (2007) Predicting factors for endometrial thickness during treatment with assisted reproductive technology. *Fertil Steril. 2007 Apr; Vol. 87, No. 4, pp.799-804. Epub 2007 Jan 4.*
- Aytoz, A.; Van den Abbeel, E.; Bonduelle. M.; Camus, M.; Joris, H.; Van Steirteghem, A. & Devroey, P.(1999).Obstetric outcome of pregnancies after the transfer of cryopreserved and fresh embryos obtained by conventional in-vitro fertilization and intracytoplasmic sperm injection. *Hum Reprod. 1999 Oct;Vol. 14, No. 10, pp.2619-24.*
- Campbell, S. (2010)The role of advanced ultrasound in the managment of natural/mild ART, Proceedings of The Third World congress on Mild Approaches in assisted Reproduction –embracing Mild IVF and IVM, venue: Pacifik Yokohama, Japan, July 30 and 31, 2010.
- Coulam, CB.; Goodman, C. & Rinehart JS.(1999) Colour Doppler indices of follicular blood flow as predictors of pregnancy after in-vitro fertilization and embryo transfer. *Hum Reprod. 1999 Aug; Vol.14, No.8, pp.1979-82.*
- Chui, DK.; Pugh ,ND.; Walker ,SM.; Gregory L.& Shaw, RW. (1997) . Follicular vascularity-- the predictive value of transvaginal power Doppler ultrasonography in an in-vitro fertilization programme: a preliminary study. *Hum Reprod. 1997 Jan; vol.12 No.1, pp :191-6.*
- Edgar ,DH.; Bourne, H.; Jericho, H. & McBain, JC.(2000). The developmental potential of cryopreserved human embryos. *Mol Cell Endocrinol. 2000 Nov 27; Vol. 169, No.1-2), pp.69-72.*

- Fanchin R. (2001). Assessing uterine receptivity in 2001: ultrasonographic glances at the new millennium. *Ann N Y Acad Sci.* 2001 Sep; Vol.943, pp.185-202.
- Järvelä ,IY.; Niinimäki, M.; Martikainen, H.; Ruokonen, A. & Tapanainen ,JS.(2007). Ovarian response to the human chorionic gonadotrophin stimulation test in normal ovulatory women: the impact of regressing corpus luteum. *Fertil Steril.* 2007 May; Vol. 87, No.5 , pp.1122-30. Epub 2007 Jan 22.
- Järvelä, IY.; Ruokonen ,A. & Tekay, A.(2008). Effect of rising hCG levels on the human corpus luteum during early pregnancy. *Hum Reprod.* 2008 Dec;Vol. 23,No.12, pp.2775-81. Epub 2008, Aug 10
- Jokubkiene L.; Sladkevicius ,P.; Rovas, L. &Valentin L.(2006). Assessment of changes in endometrial and subendometrial volume and vascularity during the normal menstrual cycle using three-dimensional power Doppler ultrasound. *Ultrasound Obstet Gynecol.* 2006 Jun; Vol 27 No. 6, pp.672-9.
- Kondo, I.; Suganuma, N.; Ando, T.; Asada,Y.; Furuhashi ,M. & Tomoda, Y.(1996). Clinical factors for successful cryopreserved-thawed embryo transfer. *J Assist Reprod Genet.* 1996 Mar;Vol.13, No. 3, pp.201-6.
- Mercé, LT.; Barco ,MJ.; Bau ,S. & Troyano, J. Are endometrial parameters by three-dimensional ultrasound and power Doppler angiography related to in vitro fertilization/embryo transfer outcome? *Fertil Steril.* 2008 Jan;89(1) pp.111-7. Epub 2007 Jun 6.
- Nargund, G.; Bourne, T.; Doyle, P.; Parsons, J.; Cheng, W.; Campbell , S & Collins, W.(1996). Associations between ultrasound indices of follicular blood flow, oocyte recovery and preimplantation embryo quality. *Hum Reprod.* 1996 Jan; Vol. 11,No.1, pp.109-13.
- Ng , EH.; Chan ,CC.; Tang ,OS.; Yeung, WS. & Ho ,PC.(2006). The role of endometrial and subendometrial vascularity measured by three- dimensional power Doppler ultrasound in the prediction of pregnancy during frozen-thawed embryo transfer cycles. *Hum Reprod.* 2006 Jun; Vol.21, No.6, pp .1612-7. Epub 2006 Jan 31.
- Niinimäki, M.; Ruokonen, A.; Tapanainen, JS & Järvelä ,IY.(2009). Effect of mifepristone on the corpus luteum in early pregnancy. *Ultrasound Obstet Gynecol.* 2009 Oct; Vol.34 , no.4,pp.448-53.
- Pairleitner, H.; Steiner, H.; Hasenoehrl ,G. & Staudach A.(1999). Three-dimensional power Doppler sonography: imaging and quantifying blood flow and vascularization. *Ultrasound Obstet Gynecol.* 1999 Aug; vol. 14, No.2, pp.139-43.
- Raga, F.; Bonilla-Musoles, F.; Casan, E. M.; Klein, O. & Bonilla, F.(1999). Assessment of endometrial volume by three-dimensional ultrasound prior to embryo transfer: clues to endometrial receptivity. *Hum Reprod.* Vol 14 ,No11, pp.2851-4,
- Salumets, A. ;Suikkari ,AM.; Mäkinen, S.; Karro, H.; Roos, A. & Tuuri ,T.(2006). Frozen embryo transfers: implications of clinical and embryological factors on the pregnancy outcome. *Hum Reprod.* 2006 Sep; Vol.21, no. 9, pp. 2368-74. Epub 2006 May 9.
- Salumets , A.; Tuuri ,T.; Mäkinen, S.; Vilska, S.; Husu ,L.; Tainio ,R. & Suikarri Am (2003). Effect of developmental stage of embryo at freezing on pregnancy outcome of frozen-thawed embryo transfer. *Hum Reprod.* 2003 Sep; Vol. 18, No. 9, pp.1890-5.

- Schalkoff , ME. ; Oskowitz ,SP . & Powers ,RD.(1993). A multifactorial analysis of the pregnancy outcome in a successful embryo cryopreservation program. *Fertil Steril*. 1993 May; Vol. 59, No. 5, pp :1070-4.
- Van Blerkom, J.; Antczak, M. & Schrader, R.(1997). The developmental potential of the human oocyte is related to the dissolved oxygen content of follicular fluid: association with vascular endothelial growth factor levels and perifollicular blood flow characteristics. *Hum Reprod*. 1997 May; Vol. 12, No. 5, pp .1047-55.
- Van Steirteghem, AC .; Van der Elst , J.; Van den Abbeel, E.; Joris, H.;Camus ,M.& Devroey P(1994). Cryopreservation of supernumerary multicellular human embryos obtained after intracytoplasmic sperm injection. *Fertil Steril*. 1994 Oct;Vol. 62, No. 4, pp .775-80.
- Van der Elst, J.; Van den Abbeel ,E.; Vitrier, S.; Camus, M.; Devroey, P. & Van Steirteghem ,AC.(1997) Selective transfer of cryopreserved human embryos with further cleavage after thawing increases delivery and implantation rates. *Hum Reprod*. 1997 Jul;Vol. 12, No. 7, pp. 1513-21.
- Veleva, Z. ;Tiitinen, A.; Vilska ,S.; Hydén-Granskog, C.; Tomás, C.; Martikainen, H & Tapanainen, JS. (2005) High and low BMI increase the risk of miscarriage after IVF/ICSI and FET. *Hum Reprod*. 2008 Apr;Vol.23, No.4,pp. 878-84. Epub 2008 Feb 15.
- Wang, JX.; Yap ,YY. & Matthews ,CD.(2001). Frozen-thawed embryo transfer: influence of clinical factors on implantation rate and risk of multiple conception. *Hum Reprod*. 2001 Nov; Vol. 16, No. 11, pp .2316-9.
- Zackova, T.; Järvelä ,IY.; Tapanainen, JS. . & Feyereisl, J. (2009).Assessment of endometrial and ovarian characteristics using three dimensional power Doppler ultrasound to predict response in frozen embryo transfer cycles. *Reprod Biol Endocrinol*. 2009 Dec 25; Vol. 7, pp.151.

IntechOpen



Ultrasound Imaging - Medical Applications

Edited by Prof. Oleg Minin

ISBN 978-953-307-279-1

Hard cover, 330 pages

Publisher InTech

Published online 23, August, 2011

Published in print edition August, 2011

This book provides an overview of ultrafast ultrasound imaging, 3D high-quality ultrasonic imaging, correction of phase aberrations in medical ultrasound images, etc. Several interesting medical and clinical applications areas are also discussed in the book, like the use of three dimensional ultrasound imaging in evaluation of Asherman's syndrome, the role of 3D ultrasound in assessment of endometrial receptivity and follicular vascularity to predict the quality oocyte, ultrasound imaging in vascular diseases and the fetal palate, clinical application of ultrasound molecular imaging, Doppler abdominal ultrasound in small animals and so on.

How to reference

In order to correctly reference this scholarly work, feel free to copy and paste the following:

T. Žáčková, I.Y. Järvelä and T. Marděšić (2011). The Role of 3D Ultrasound in Assessment of Endometrial Receptivity and Follicular Vascularity to Predict the Quality Oocyte, *Ultrasound Imaging - Medical Applications*, Prof. Oleg Minin (Ed.), ISBN: 978-953-307-279-1, InTech, Available from:
<http://www.intechopen.com/books/ultrasound-imaging-medical-applications/the-role-of-3d-ultrasound-in-assessment-of-endometrial-receptivity-and-follicular-vascularity-to-pre>

INTECH

open science | open minds

InTech Europe

University Campus STeP Ri
Slavka Krautzeka 83/A
51000 Rijeka, Croatia
Phone: +385 (51) 770 447
Fax: +385 (51) 686 166
www.intechopen.com

InTech China

Unit 405, Office Block, Hotel Equatorial Shanghai
No.65, Yan An Road (West), Shanghai, 200040, China
中国上海市延安西路65号上海国际贵都大饭店办公楼405单元
Phone: +86-21-62489820
Fax: +86-21-62489821

© 2011 The Author(s). Licensee IntechOpen. This chapter is distributed under the terms of the [Creative Commons Attribution-NonCommercial-ShareAlike-3.0 License](https://creativecommons.org/licenses/by-nc-sa/3.0/), which permits use, distribution and reproduction for non-commercial purposes, provided the original is properly cited and derivative works building on this content are distributed under the same license.

IntechOpen

IntechOpen