

We are IntechOpen, the world's leading publisher of Open Access books Built by scientists, for scientists

4,800

Open access books available

122,000

International authors and editors

135M

Downloads

Our authors are among the

154

Countries delivered to

TOP 1%

most cited scientists

12.2%

Contributors from top 500 universities



WEB OF SCIENCE™

Selection of our books indexed in the Book Citation Index
in Web of Science™ Core Collection (BKCI)

Interested in publishing with us?
Contact book.department@intechopen.com

Numbers displayed above are based on latest data collected.

For more information visit www.intechopen.com



Post-Transplant Glomerulonephritis in Live-Donor Renal Transplant Recipients: Clinical Course and Risk Factors

Ahmed Akl, Hany Adel and Ehab Wafa
Urology and Nephrology center, Mansoura,
Egypt

1. Introduction

Kidney transplantation is the treatment of choice for end-stage renal disease. It offers better quality of life and minimizes the mortality risk for patients when compared with maintenance dialysis therapy (Chailimpamontree W, et al., 2009). Little data are available concerning the impact of the post-transplantation glomerulonephritis (GN) on graft outcome (Gaston R, 2006). The post-transplant glomerulonephritis may be *de novo* GN or recurrence of the original kidney disease. *De novo* GN appear to have poorer prognosis than the recurrent type. Different types of glomerulonephritis were reported to recur in the graft with different recurrence rates (Briganti EM, et al., 2002). The recurrent glomerulonephritis was reported to be important cause of impaired graft function and consequent graft loss (Choy B. et al., 2006). Studies on recurrent disease are difficult since not all patients have undergone native kidney biopsy or it was non-representative. The reported incidence of recurrent GN is thus judged by clinical suspicion and could be over- or under-estimates of the true incidence (Hariharan S, 2000). Precise diagnosis of recurrent disease in view of concomitant histological features of chronic allograft nephropathy or chronic drug nephrotoxicity by calcineurine inhibitors is often difficult to be determined (Requião-Moura LR, et al., 2007). There is accumulating evidence that recurrent GN is an important and clinically relevant cause of graft loss in the long-term follow-up of renal allograft recipients. It was reported that recurrent GN is considered to be the third most common cause for graft loss 10 years after kidney transplantation. The risk of graft loss from recurrence was found to be increased from 0.6% during the first year post-transplant to 8.4% after 10 year of follow up (Briganti EM, et al., 2002). The introduction of newer immunosuppressive agents and induction protocols improved the graft survival. The improvement of graft survival was through the direct reduction of the incidence of acute rejection. The incidence of post-transplant glomerulonephritis whether recurrence or *de novo* was not influenced (Hariharan S, et al., 2000). The aim of our study is to focus on the incidence, risk factors of GN after kidney transplantation and their impact on the graft function & survival.

The risk for allograft loss as a result of PTGN is thus an important factor in the decision to proceed with transplantation, and an accurate understanding of the probability of PTGN is essential for the transplant team, the patient, and a potential live donor (Choy B, et al., 2006). There was a marked disparity in risk for PTGN according to histological type; the

most common forms were IgA nephropathy and FSGS, whereas all other forms occurred in less than 1% of patients (Worawon Chailimpamontree, et al., 2009). The prognosis of each of the forms depend on various factors, including the severity or type of histological lesion (Little M, et al., 2006), or whether the disease is recurrent or de novo (Bela Ivanyi, 2008). There is as yet no effective treatment for PTGN, although intensive plasma exchange or Rituximab may be of benefit in some cases of FSGS (Gossmann J, et al., 2007).

2. Classification of post transplantation GN (PTGN):

Recurrent and De Novo glomerular diseases can be classified according to clinical criteria (William A. Golgert, 2008):

1. **True recurrence:** Native kidney disease and transplant kidney disease are the same as confirmed by kidney biopsies.
2. **Transplant glomerulopathy:** Unknown primary disease. Biopsy-proven transplant kidney disease is possibly the same disease as the native kidney disease; however, the native kidney diagnosis was never documented by renal biopsy.
3. **De novo:** Biopsy-proven kidney disease that occurs in the transplant kidney is different from the native kidney disease.

Histological classification can be divided into four types, according to the type of the disease (William A. Golgert, 2008):

- a. **Recurrence of primary GN:** Recurrent FSGS, membranoproliferative GN (MPGN), IgA nephropathy (IgAN), Henoch-Schönlein purpura, membranous nephropathy (MN).
- b. **Recurrence of secondary GN:** Systemic lupus erythematosus (SLE), hemolytic uremic syndrome/thrombotic thrombocytopenic purpura (HUS-TTP), rapidly progressive-crescentic GN, anti-glomerular basement membrane (anti-GBM) disease.
- c. **Recurrence of metabolic or systemic disease:** Diabetic nephropathy, oxalosis, amyloidosis, Fabry disease, scleroderma, cystinosis, fibrillary GN.
- d. **De novo diseases:** Anti-GBM disease in patients with Alport syndrome, MN, FSGS.

3. Diagnosis of GN after renal transplantation

Proteinuria and hematuria remain the hallmark findings suggesting recurrence of GN. Many transplant centers do not include a urinalysis for detecting proteinuria and hematuria as part of their routine transplant surveillance or even for some patients with worsening renal function before transplant renal biopsy. In a majority of renal transplant patients who undergo renal biopsy, tissue is not routinely submitted for immunofluorescence (IF) and for electron microscopy (EM), which is essential for the diagnosis of some forms of GN. Patients with early or mild recurrence of IgAN, MN, and lupus nephritis thus easily receive a misdiagnosis. There is no unified approach for evaluating renal transplant patients for the diagnosis of recurrent GN after renal transplantation (William A. Golgert, 2008). The challenges in diagnosis of post transplantation GN are numerous and include (1) misdiagnosis or mislabeling of native kidney disease, (2) lack of a unified approach in using diagnostic tools for the diagnosis of recurrent GN, and (3) difficulties in differentiating GN from drug toxicity and alloantigen-dependant chronic immunologic damage to the transplant kidney (Hariharan S, 1999).

4. Recurrent glomerulonephritis post-renal transplantation

Recurrent disease is a significant cause of allograft failure estimated to affect 1-8 % grafts (Cameron JS, 1991), (Floege J, 2003) and (Ramos EL, et al., 1994). Accumulating evidence indicates that recurrent glomerulonephritis is the third most important cause of renal allograft loss at 10 years after transplantation. All forms of glomerular disease can recur after transplantation, but the likelihood of recurrence differs according to type. Focal

Usually recur > 50 % - Adverse effects (graft loss > 5%) - Little or no adverse effects	<ul style="list-style-type: none"> • 1ry Hemolytic Uremic Syndrome (HUS). • 1ry oxalosis • Dense deposit disease • Collapsing FSGS • DM • Systemic light chain disease
Commonly recur (5- 50 %) Adverse effects Little or no adverse effects	<ul style="list-style-type: none"> • FSGS • MPGN I. • Anti-Neutrophilic-CytoplasmicAntibody(ANCA) diseases (Wegner'sgranulomatosis-microscopic polyarteritis) • Progressive systemic sclerosis • Sickle cell nephropathy • IgA nephropathy • Henoch-schönlein purpura • Amyloidosis
Rarely recur (< 5%) - Adverse effects - Little or no adverse effects	<ul style="list-style-type: none"> • Anti-GBM • SLE • Fabry's disease
Recurrence reported (too few cases)	<ul style="list-style-type: none"> • Thrombotic Thrombocytopenic Purpura (TTP) • Adenosine phosphoribosyl transferase deficiency • Familial fibronectin glomerulopathy • Lipoprotein glomerulopathy
Never recur 0 % - Unique complications	<ul style="list-style-type: none"> • Hereditary nephritis/Alport's syndrome (Anti-GBM disease) • Congenital nephrosis(nephrotic syndrome)
- No unique complication	<ul style="list-style-type: none"> • Poly Cystic Kidney Disease (PCKD). • Osteo-onchodysplasia (nail-patella) • Acquired cystic disease • 2ry HUS(infection) • 2ry focal segmental glomerulosclerosis • Familial focal segmental glomerulosclerosis • Post-infectious acute GN

Table 1. Frequency and clinical significance of recurrent renal diseases

segmental glomerulosclerosis (FSGS), membranoproliferative glomerulonephritis, IgA nephropathy and idiopathic diarrhea-negative hemolytic uremic syndrome often recur (**Bela Ivanyi, 2008**). Isografts (identical twins) have the highest recurrence rate (**Glassock RJ, et al., 1968**). Frequency and clinical significance of recurrence varies with the disease (**Peter J. Morris, et al., 2008**) as shown in table (1).

5. Risk of recurrence

The recurrence rates vary for different types of glomerulonephritis, and the risk of subsequent graft loss also differs as shown in table (2) (**Bela Ivanyi, 2008**).

Type of glomerulonephritis	Clinical recurrence rate (% of recipients)	Rate of graft loss
FSGS	20–40	20
Membranous GN	10–30	50
MPGN type I	20–33	High
MPGN type II	67–100	34–66
Anti-GBM nephritis	<5	Can occur
ANCA-positive crescentic GN	0–20	8
IgA Nephropathy	7–30	3–16
Iopathic D- HUS	33–82	90

Table 2. Risk of Recurrence and Graft Loss for Different Types Glomerulonephritis

Only 1ry focal segmental glomerulosclerosis and MPGN recur with sufficient frequency and aggressiveness to affect graft survival (**Briganti E, et al., 2002**) and (**Busch GJ, et al., 1995**). Recurrent GN is diagnosed by exclusion of donor-transmitted disease and de novo GN. It has a negative impact on graft survival and causes 8.4% allograft losses by 10 years in recipients with renal failure from GN (**Briganti E, et al., 2002**). The relative impact of recurrent GN increases as graft survival lengthens, or in some population in whom 1ry GN is prevalent or severe, the clinical course and severity of recurrent glomerular disease often copies that of the patient's original disease (**Chadban S, 2001**), except for patients with vasculitis and lupus nephritis; these conditions usually controlled by transplantation immunosuppression. Focal segmental glomerulosclerosis (20%-50% recurrence rate) and dense deposit disease (50%-90% recurrence rates) have the worst prognosis and together constitute 55%-60% of all recurrent GN (**Bela Ivanyi, 2008**). Membranous GN recurs in 29%-50%, MPGN type I recurs in 20%-33%, and IgA nephropathy recurs in 58%, although with limited early (but increased later) clinical impact (**Chadban S, 2001**). Diabetic glomerulopathy also may recur but with variable clinical effects, Eighty to 100 percent of diabetic transplant recipients develop histological changes of recurrent diabetic nephropathy (DN). The time of development of nephropathy may be as little as six years post-transplantation (**Bhalla V, et al., 2003**). However, the incidence of DN as a cause of graft failure is poorly studied and has been thought to be rare (**Siddqi N, et al., 2005**).

6. Minimal change glomerulonephritis

Fourteen cases of renal transplant recipients developing nephrotic syndrome with minimal glomerular abnormalities have been reported although the cases do not represent true

recurrence of a disease (**Cheigh JS, et al., 1980**). The prognosis is variable and follow-up often very short but in some reports there is progression to renal failure (**Gephardt GN, et al., 1988**). It is notable that re-biopsy in two patients showed focal segmental glomerulosclerosis (FSGS) (**Hoyer JR, et al., 1972**). Not all of the reports included venography or other imaging to exclude renal vein thrombosis and drug-associated effects are impossible to rule out.

7. Focal Segmental Glomerulosclerosis (FSGS)

FSGS has the greatest clinical impact of recurrent glomerular disease because of its high recurrence rate, poor intermediate outcome, and the number of young patients with FSGS who undergo transplantation (**Briganti EM, et al., 2002**). Graft loss from recurrent FSGS predicts recurrence in 70% of subsequent allografts, and most of these fail, possibly precluding that individual from future transplantation (**Briganti EM, et al., 2002**). Frequency of recurrence of focal segmental glomerulosclerosis and clinical progress of FSGS is an important problem in pediatric practice as it is responsible for about 10% of childhood idiopathic nephrotic syndrome (**Kibert S, et al., 1994**). The prognosis is poor with about one-third of patients progressing to end-stage renal failure within 5 years (**Kershaw DB, et al., 1994**). Recurrence of nephrotic syndrome after renal transplantation in patients with FSGS was first reported in 1972 (**Hoyer JR, 1972**). Those individuals who do experience recurrent disease are also at high risk of delayed graft function. The recurrence rate varies with different series, but a large North American experience (**Tejani A, et al., 1992**) reported 27 out of 132 patients (20.5%), and in Europe in the same year Broyer M et al reported a rate of 20% in a series collected by the Paediatric European Dialysis and Transplant Association (**Broyer M, et al., 1992**).

More recent North American experience was reported in 1998 (**Hariharan S, et al., 1998**), 1557 renal transplants performed at a single centre between 1984 and 1994 were reviewed and FSGS was discovered in 25 patients. Some individuals will have proteinuria but adequate renal function for a number of years (**Stephanian E, et al., 1992**). A retrospective analysis of a cohort of 29 paediatric patients who received 32 grafts between 1987 and 1998 in Northern Italy was published in 1999 (**Dall'Amico R, et al., 1999**). In these individuals, proteinuria of >1g/day occurred in 15 (52%) after the first transplant and in three out of three who received a second graft. The proteinuria almost always occurred early, in 14 out of 18 occasions in this report within the first month. In about 70% of cases a transplant biopsy was performed. Recurrence of proteinuria was associated with a poor outcome compared with those individuals who did not experience recurrent disease. In the latter group normal renal function after a mean follow up of 44 months was reported (**Dall'Amico R, et al., 1999**).

Recurrence of disease is not invariably associated with a dire prognosis. For five out of eight patients aged <25 years who lost primary renal transplants to recurrence FSGS, there was prolonged function of the graft of between 4 and 10.5 years (**Stephanian E, et al., 1992**). Although one review article has recommended bilateral native nephrectomy as a prophylactic measure prior to transplantation, in the text the only reference is to a paper which points out that the manoeuvre will make the diagnosis of a recurrent FSGS posttransplantation easier (**Srivasta RN, et al., 1994**). Familial focal and segmental glomerulosclerosis, although rare, is important to recognize, as it is a different syndrome to idiopathic FSGS of childhood. A recent large multinational survey identified 26 families

with multigenerational involvement and 34 families with more than one individual in a single generation affected (Conlon PJ, et al., 1999). Patients presented on average in their third or fourth decade and, important in the context of recurrent disease post-transplantation, 41 individuals received a renal transplant and only one experienced recurrent disease; overall 10-year graft survival was 62%. A similarly good outcome after transplantation has been reported by others. Adults with 'secondary' FSGS, for example due to renal artery stenosis or some other long standing conditions that lead to renal insufficiency, would not be expected to be at risk of recurrent disease in a renal transplant.

8. Risk factors for recurrent FSGS

It is notable that certain factors, particularly age <15 years (Cameron JS, 1991 and Ingulli E, et al., 1991), aggressive clinical course of the original disease with time from diagnosis to end-stage renal failure of less than 3 years (Cameron JS, 1991 and Cheong HI, et al., 2000), and diffuse mesangial proliferation (DMP) on native biopsy (Conlon PJ, et al., 1999 and Senguttuvan P, et al., 1990), are considered predictive of relapse. There is no 'cut off' that separates by age those patients destined to experience recurrence and those who will not (Dall'Amico R, et al., 1999). Although in general age <15 years is considered to have a poor prognosis there is evidence that, within the pediatric group, those aged >6 years have a less poor prognosis. In a pediatric registry report in 1990, only 17% of children who were aged <6 years had relapse of nephrotic syndrome after transplantation compared with 40% of those aged >6 years at the time of diagnosis of the original glomerular disease (Rizzoni G, et al. 1991). In the Northern Italian experience (Dall'Amico R, et al. 1999), there was no difference in the gender distribution or age at onset of dialysis between the group with and without recurrent disease. However, the mean interval between diagnosis and end-stage renal failure was significantly shorter in the group with recurrence. Disease duration from onset to dialysis was <2 years in nine of 15 patients with recurrent FSGS and two of 14 patients with non-recurrent FSGS ($P<0.014$). The importance of the native glomerular histology was explored in a publication that reported on 24 children who received 37 transplants. The native renal histology was divided into three groups: pure FSGS, FSGS with focal mesangial proliferation (FMP) and FSGS with diffuse mesangial Proliferation (DMP) (Striegel JE, et al., 1986). The finding of mesangial proliferation had a sinister prognosis for subsequent graft function.

9. Laboratory tests to predict recurrent FSGS

The reported observation that sera from patients with a recurrent FSGS causes an immediate profound increase in the albumin permeability of isolated rat glomeruli clearly offers the exciting possibility that at least the risk of recurrent disease for an individual patient could be more accurately predicted (Savin V, et al., 1996). Subsequent experiments that have separated the sera obtained mostly during therapeutic apheresis into sub-fractions have demonstrated that the permeability factor is a protein of molecular weight between 30 and 50 kDa (Sharma M, et al., 1999). A Northern Italian group examined pre-transplant serum samples from 25 patients tested in an in vitro assay of glomerular permeability to albumin. FSGS recurred in 11 of 13 children who tested positive for the permeability factor and four of 12 patients with a negative test (Dall'Amico R, et al., 1999).

10. Membranous Nephropathy (MN)

Recurrence of membranous nephropathy (MN) in the transplant is infrequent, with most studies reporting rates between 10 and 30 percent (Choy BY, et al., 2006 and Cosyns JP, et al., 1998). The mean time to recurrence, which typically presents as nephrotic range proteinuria, is approximately 10 months (Josephson MA, et al., 1994). Affected patients appear to have more aggressive initial disease as evidenced by progression to end-stage renal failure at a mean of four years (Josephson MA, et al., 1994). Recurrent disease can lead to loss of the graft (Cosyns JP, et al., 1998 and Briganti EM, et al., 2002). Perhaps the best estimate of the incidence of graft loss due to recurrent membranous nephropathy was provided by a study of 1505 renal transplant recipients with a history of end-stage renal disease due to biopsy-proven glomerulonephritis (Briganti EM, et al., 2002). Among the 81 patients with membranous disease, the incidence of allograft loss at 10 years due to recurrent disease was 12.5 percent (CI of 7.3 to 21.6 percent). Initial studies suggested that patients with living-related transplants are at higher risk for recurrence (Berger BE, et al., 1983). Although this hypothesis remains unproven, recurrent disease may occur earlier in living-related as compared to deceased donor transplants (Josephson MA, et al., 1994).

11. Membrano-Proliferative GN (MPGN)

Both idiopathic type 1 (mesangial and subendothelial deposits) and the less common type 2 (dense-deposit disease) MPGN commonly recur after renal transplantation (Denton MD, et al., 2000). Although these disorders have different sites of electron dense deposits, they are both associated with the other classic histologic changes of MPGN: increased glomerular cellularity and a double contour appearance of the glomerular basement membrane due to mesangial cell interposition and new basement membrane formation.

11.1 Type 1 MPGN

The reported rate of recurrent disease in idiopathic type 1 MPGN has usually ranged between 20 and 30 percent (Glicklich D, et al., 1987 and Floege J, 2003), although the incidence in children may be somewhat higher (Habib R, et al., 1987). Reported recurrence rates may represent an overestimate, since similar histologic changes can occur as part of chronic transplant rejection (transplant glomerulopathy) (Cheigh JS, et al., 1980). Nevertheless, findings on electron microscopy (such as the absence of immune complex deposition in transplant glomerulopathy) may help distinguish between these two disorders (Andresdottir MB, et al., 1998). Patients with recurrent disease may remain asymptomatic, although the majority of patients with recurrent MPGN tend to present with proteinuria, hematuria and hypertension. Hypocomplementemia may be associated with recurrent disease (McLean RH, et al., 1976), however, disease recurrence can occur in the absence of this finding. There is no proven beneficial therapy for the treatment of recurrent idiopathic MPGN, although the combination of aspirin and dipyridamole may stabilize renal function, similar to its efficacy in primary MPGN (Glicklich D, et al., 1987).

11.2 Type 2 MPGN

Type 2 MPGN “dense deposit disease” tends to recur more frequently than type 1 MPGN, ranging from 50 to 100 percent in various series (Choy BY, et al., 2006). Affected patients typically presented within one year following transplantation with non-nephrotic range

proteinuria. Graft loss due to recurrent disease is thought to occur in only 10 to 20 percent of cases, although some centers have reported rates as high as 30 to 50 percent (**Braun MC, et al., 2005** and **Andresdottir MB, et al., 1999**).

11.3 Type 3 MPGN

Type 3 MPGN is an immune complex disease which is similar to type 1 but with prominent subepithelial deposits and a complex disruption of the glomerular basement membrane. Little is known concerning recurrent disease among patients with type 3 MPGN who undergo renal transplantation. A case report described a patient with end-stage renal disease due to type 3 MPGN who presented with hematuria and proteinuria 16 months after undergoing renal transplantation (**Morales JM, et al., 1997**). Renal biopsy revealed recurrent type 3 MPGN; graft loss occurred seven years later.

12. Immunoglobulin A (IgA) nephropathy

Recurrent IgA deposition, as determined on biopsy, may result in a wide spectrum of manifestations, ranging from an incidentally noted histologic finding to mesangioproliferative glomerulonephritis associated with hematuria, proteinuria, and progressive renal dysfunction. IgA deposition may occur alone or be concurrent with other significant pathology, including chronic rejection (**Kowalewska J, et al. 2005**).

13. De Novo Glomerulonephritis

Patients without previous glomerular disease occasionally develop lesions in the allograft that resemble 1ry glomerular disease, rather than the usual chronic transplant glomerulopathy. Although some lesions may be coincidental, at least 3 are related to an alloimmune response to the allograft: membranous nephropathy, anti-GBM in Alport's syndrome and recurrent nephrotic syndrome in congenital nephrosis. A fourth common de novo GN, focal segmental glomerulosclerosis, is believed to be related to hyper filtration injury or marked compromise as a result of calcineurin inhibitor toxicity (**Meehan SM, et al., 1998** and **Cosio FG, et al., 1999**).

14. Membranous Nephropathy (MN)

De novo MN is typically a late complication affecting about 1%-2% grafts. The risk factors for de novo MN include time after transplantation, de novo MN in a first graft (**Heidet L, et al., 1994**), HCV infection (**Josep M. Cruzadoa, et al., 2001**). Light microscopy usually shows mild glomerular basement membrane changes. Mesangial hypercellularity is found in about 33% of biopsies (**Morales JM, et al., 1997**). In most cases, MN in the transplant is a de novo disease, occurring in patients who had a different primary renal disorder (**Truong L, et al., 1989**). The cumulative incidence of this complication is approximately 1.5 to 2 percent, but the frequency rises with time, reaching 5.3 percent at eight years in one report (**Schwarz A, et al., 1994**).

15. Pathogenesis

De novo MN is thought to be related to chronic rejection, since renal biopsy reveals signs of vascular and interstitial rejection in addition to the classic findings of MN (basement

membrane thickening and immune deposits in the subepithelial space). The mechanism by which de novo MN occurs is unknown (Truong L, et al., 1989). Rejection leads to exposure of previously unseen glomerular antigens, resulting in a secondary antibody response. Glomerular injury due to rejection makes the capillary wall more permeable, thereby facilitating the deposition of immune complexes. Circulating antibodies may be directed against HLA antigens that are expressed on the graft. Indirect evidence in support of the importance of host factors is the seemingly high incidence of recurrence (4 of 7 in one report) in a second transplant (Heidet L, et al., 1994). Alloimmunization against neutral endopeptidase (NEP) is a novel pathomechanism of MN that might also account for some cases of MN after renal transplantation. Other types of alloimmunization should be investigated in MN but also in other renal and nonrenal diseases, particularly those that affect the pediatric age (Ronco P, et al., 2005). In comparison, de novo MN seems to be rare when a second transplant is performed in patients who did not have de novo MN in the first graft (Heidet L, et al., 1994).

15.1 Anti-Glomerular Basement Membrane glomerulo-nephritis (Anti-GBM)

Patients with Alport's syndrome or hereditary nephritis commonly develop anti-GBM alloantibody because they genetically lack self tolerance to GBM collagen components, however GN develops in few cases only and de novo crescentic and necrotizing GN 2ry to anti-GBM post transplantation is uncommon, seen in only 5% of adult male recipients with Alport's syndrome (Kashtan CE, 2000). The overall 5-year graft survival is equal to that of recipients without Alport's syndrome (Gobel J, et al., 1992).

15.2 Transplant Glomerulopathy (TG)

Transplant glomerulopathy (TG) is a separate histologic entity. Current evidence supports the postulate that TG is a unique pathologic and pathogenic entity distinct from other forms of chronic allograft injury (F.G. Cosio, et al., 2008). Evidence is accumulating that TG has a unique pathogenesis that distinguishes it from other chronic pathologic conditions of kidney allografts (Gloor JM, et al., 2007). Detailed electron microscopic studies have shown basement membrane abnormalities in glomerular and peri-tubular capillaries, indicating that this is a disease of the entire renal capillary network. Staining biopsies for the complement fragment, C4d, showed positivity in subgroups of TG, suggesting the participation of anti-donor antibodies (F.G. Cosio, et al., 2008). Transplant Glomerulopathy is defined by the characteristic duplication of glomerular basement membrane (GBM) observed by light microscopy as recommended by the Banff working group (Racusen LC, et al., 2002). It is a focal lesion particularly in its early histologic phases, affecting only a few glomeruli. However, sequential biopsies show progression with increasing percentage of affected capillary loops in an increasing number of glomeruli (Gloor JM, et al., 2007). The incidence of TG is increased in patients with anti-donor HLA antibodies prior to the transplant. The use of surveillance biopsies has demonstrated that TG can develop during the first few months after transplantation, although it may remain clinically quiescent for several years. However, TG is progressive, leading to reduced graft survival. Current therapies for TG are likely of limited value (F.G. Cosio, et al., 2008). The importance of this disease is that TG is associated with very poor allograft survival and TG is perhaps the first distinct pathologic entity arising that was first called 'chronic rejection', and then 'chronic allograft nephropathy'. The distinctiveness of TG from other forms of chronic allograft

pathologies is given by the coexistence of three features: (i) histologic pattern, (ii) association with the presence of anti-HLA antibodies and (iii) the absence of other conditions that may cause duplication of GBM (F.G. Cosio, et al., 2008).

Transplant Glomerulopathy is associated with poor long-term graft survival; the factors associated with reduced graft survival include graft function and proteinuria at diagnosis and the severity of GBM duplication (F.G. Cosio, et al., 2008). The clinical manifestations of early TG are nonspecific, consisting of progressive, unexplained loss of kidney function, minor proteinuria and mild hypertension (Sis B, et al., 2007). Histological classifications of kidney allograft pathology did not separate TG from 'chronic allograft nephropathy', a nonspecific term indicating the presence of interstitial fibrosis and tubular atrophy, however, recent investigations showed that TG, particularly in its early stages, might develop independently from interstitial fibrosis, tubular atrophy and/or transplant arteriopathy (Yamamoto I, et al., 2007). It is important to note that glomerular inflammation coexists with TG and, in fact, becomes more common and severe as the duplication of the GBM progresses, suggesting that TG and its progression is associated with persistent capillaritis (Gloor JM, et al., 2007). Transplant glomerulopathy must primarily be distinguished histologically from those disorders that can cause a MPGN-pattern and/or a predominant interstitial fibrosis on renal biopsy. The MPGN-pattern of transplant glomerulopathy must be distinguished from other glomerular disorders, particularly MPGN that is associated with hepatitis C virus infection or is due to recurrent or de novo disease. These disorders may appear similar on light microscopy. The distinction may be made on electron microscopy, which typically shows thickening and duplication of the glomerular basement membranes without immune deposits in transplant glomerulopathy; by comparison, there are prominent subendothelial immune deposits in HCV-associated MPGN (Andresdottir MB, et al., 1998). The presence of marked interstitial fibrosis due to chronic renal transplant nephropathy must be differentiated from other causes of fibrosis, particularly that induced by calcineurin inhibitors (eg, cyclosporine or tacrolimus). In this setting, histologic evidence of the characteristic glomerulopathy, or the presence of peritubular capillary basement membrane splitting and lamination are most consistent with chronic renal allograft nephropathy. By comparison, the detection of newly formed hyaline arteriolar changes is specific for cyclosporine nephrotoxicity (Racusen LC, et al., 2002).

15.3 Management of Transplant Glomerulopathy

Currently, there are no known effective therapies for TG. There is strong evidence that control of blood pressure and angiotensin II inhibition are effective in slowing down the progression of glomerular diseases in native kidneys (F. G. Cosio, et al., 2008).

15.4 Treatment of Post Transplant Glomerulonephritis (PTGN)

15.4.1 Focal Segmental Glomerulosclerosis (FSGS)

There are only anecdotal reports of therapy in recurrent focal segmental glomerulosclerosis (FSGS). Removal of a circulating toxin with protein adsorption or plasmapheresis, or the administration of cyclophosphamide or meclufenamate (an NSAID) have been tried in selected cases with variable success (Matalon A, et al., 2001). Protein adsorption and plasmapheresis can markedly reduce protein excretion or even induce complete remission in at least some cases if begun early after the onset of recurrent disease before hyalinosis or more severe histologic changes have occurred (Vincenti F, 2005). The administration of plasmapheresis plus

cyclosporine prior to transplantation has been postulated to prevent recurrent disease in high-risk patients (**Hariharan S, 2000**). A retrospective study in children found that preoperative plasmapheresis (without cyclosporine) decreased the rate of recurrent disease; four of six recurred in the nonprophylactic group versus 5 of 15 in the prophylactic group; (**Ohta T, et al., 2001**). Prolonged, daily, high dose corticosteroid is routinely used for the treatment of FSGS in non-transplant patients. Although there are only limited reports of this treatment modality for recurrent FSGS, there may be a role for steroids in this setting. In one report, two children developed recurrent FSGS after they were changed to every other day steroids (**Hanevold CD, 2003**), both patients initially responded to prolonged, daily, high dose corticosteroids, but subsequently relapsed with lower dose daily steroids. Other agents, such as Rituximab, have been tried with variable success (**Yabu JM, et al., 2008**).

15.4.2 Membrano-Proliferative Glomerulonephritis (MPGN)

There is no proven beneficial therapy for the treatment of recurrent idiopathic MPGN, although the combination of aspirin and dipyridamole may stabilize renal function, similar to its efficacy in primary MPGN (**Glicklich D, et al., 1987**). In the setting of stable graft function, especially associated with non-nephrotic range proteinuria, conservative management is generally preferred. This should include blood pressure control, the use of angiotensin converting enzyme inhibitors or angiotensin receptor blockers along with a statin. The role of cyclosporine is uncertain. Some investigators have found it to be ineffective in recurrent disease, while others have suggested that the rate of recurrence fell from 30 to 10 percent after the introduction of cyclosporine (**Lien YH, et al., 2000**). There are also case reports describing successful treatment with cyclophosphamide or plasmapheresis (**Muczynski KA, 1995**).

While no specific treatment exists for the treatment of recurrent idiopathic MPGN, aggressive treatment using plasmapheresis and adjuvant immunosuppression may be warranted in the setting of rapidly worsening graft function or histologic findings suggestive of rapidly progressive disease. The treatment of recurrent disease in the setting of active hepatitis C virus infection is somewhat controversial; however, it should be considered in appropriate candidates (**Zeman M, et al., 2006**). The use of a wide variety of treatments has been reported. In the setting of rapidly worsening graft function or histological findings suggestive of rapidly progressive disease; plasmapheresis, substitution of tacrolimus for cyclosporine, reduction in the dose or discontinuation of the calcineurin inhibitor, increase in the corticosteroid dose, or the administration of pulse methylprednisolone may be warranted (**Braun MC, et al., 2005**). Several other treatment options; Rituximab may be useful in treating MPGN in renal transplant recipients in this setting (**Basse G, et al., 2005**).

15.4.3 Membranous Nephropathy (MN)

Cyclosporine, Tacrolimus, and Mycophenolate Mofetil do not seem to protect against or change the course of recurrent disease (**Choy BY, et al., 2006**); there is no evidence that additional immunosuppressive therapy alters the course of the membranous nephropathy. The use of Cyclosporine has not changed the incidence of de novo MN, and pulse therapy with Methylprednisolone does not appear to lower protein excretion (**Schwarz A, et al., 1994**). In a case report, the administration of Rituximab was successful in treating recurrent disease (**Gallon L, et al., 2006**).

15.5 Immunoglobulin A Nephropathy (IgAN)

There is some evidence that the use of mycophenolate mofetil may decrease the risk of IgAN recurrence, although long-term data are lacking (Kim YS, et al., 2001). In contrast, one analysis of transplant glomerulopathy that used recurrent IgAN as a comparative control group found no difference in the incidence of recurrence with the use of mycophenolate mofetil and/or tacrolimus (Chandrakantan A, et al., 2005). Retrospective analysis reported that the prevalence of recurrent IgA following transplantation was significantly reduced in patients receiving antithymocyte globulin, compared to either IL-2 induction or no induction treatment (Berthoux F, et al., 2008). Adapted from its use in treating IgAN in native kidneys, angiotensin converting enzyme inhibitor therapy may delay progression of recurrent disease in allografts (Courtney AE, et al., 2006). However, it is not clear that graft survival is actually improved by initiating either an angiotensin converting enzyme inhibitor or an angiotensin receptor blocker following the detection of recurrent IgAN (Chandrakantan A, et al., 2005).

16. Conclusions

The incidence of Recurrent and De novo GN occur earlier than transplant Glomerulopathy and recurrent GN is the earliest glomerular lesion observed in the first 3 months post transplantation. FSGS is the most common type of PTGN and MPGN represents the second common type.

Pre-transplant glomerulonephritis, donor age 31-40 years old, and Sirolimus protocol are risk factors for developing PTGN. Difference in blood group between the donor and recipient carries a favorable significant delay in the development of PTGN. The risk factors associated with graft loss in PTGN are; recipient age between 40 and 50 years, induction therapy with polyclonal antibody (ATG), incidence and number of acute rejection episodes, and development of chronic rejection.

Significant drop of graft survival is observed in recipients who developed PTGN after the first 2 years post-transplant. The graft survival in the recipients with Recurrent GN is significantly lower than the graft survival of recipients who developed De novo GN and Transplant glomerulopathy. De novo GN has an independent negative impact on the long term graft loss. Middle aged donor grafts, patient receive their grafts from their off springs, and different blood groups between recipients and donors have favorable significant effect on graft survival. The patient survival in the recipients with PTGN is comparable to those without PTGN in the first 5 years post transplantation. Thereafter, significant drop of patient survival is observed in the group of recipients who suffered from De novo GN and Transplant Glomerulopathy.

17. References

- Andresdottir MB; Assmann KJ; Koene RA; Wetzels JF. Immunohistological and ultrastructural differences between recurrent type I membranoproliferative glomerulonephritis and chronic transplant glomerulopathy. *Am J Kidney Dis* 1998 Oct; 32(4):582-8.
- Basse G; Ribes D; Kamar N; Mehrenberger M; Esposito L; Guitard J; Lavayssiere L; Oksman F; Durand D; Rostaing L. Rituximab therapy for de novo mixed cryoglobulinemia in renal transplant patients. *Transplantation* 2005 Dec 15; 80(11):1560-4.

- Bela Ivanyi, A primer on recurrent and de novo glomerulonephritis in renal allografts. *NATURE CLINICAL PRACTICE NEPHROLOGY* august 2008; 4 (8):446-457.
- Berger BE; Vincenti F; Biava C; Amend WJ Jr; Feduska N; Salvatierra O Jr. De novo and recurrent membranous glomerulopathy following kidney transplantation. *Transplantation* 1983 Apr; 35(4):315-9.
- Berthoux F; El Deeb S; Mariat C; Diconne E; Laurent B; Thibaudin L. Antithymocyte globulin (ATG) induction therapy and disease recurrence in renal transplant recipients with primary IgA nephropathy. *Transplantation*. 2008 May 27; 85(10):1505-7.
- Bhalla V; Nast CC; Stollenwerk N; Tran S; Barba L; Kamil ES; Danovitch G; Adler SG. Recurrent and de novo diabetic nephropathy in renal allografts. *Transplantation*. 2003 Jan 15; 75(1):66-71.
- Branten AJ; Vervoort G; Wetzels JF. Serum creatinine is a poor marker of GFR in nephrotic syndrome. *Nephrol Dial Transplant* 2005 Apr; 20(4):707-11.
- Braun MC; Stablein DM; Hamiwka LA; Bell L; Bartosh SM; Strife CF. Recurrence of membranoproliferative glomerulonephritis type II in renal allografts: The North American Pediatric Renal Transplant Cooperative Study experience. *J Am Soc Nephrol* 2005 Jul; 16(7):2225-33.
- Briganti E, Russ G, McNeil J, Atkins R, Chadban S. Risk of renal allograft loss from recurrent glomerulonephritis. *N Engl J Med* 2002; 347:103-109.
- Briggs J, Jones E: Recurrence of glomerulonephritis following renal transplantation. Scientific Advisory Board of the ERA-EDTA Registry. European Renal Association-European Dialysis and Transplant Association. *Nephrol Dial Transplant* 1999; 14: 564-565.
- Broyer M, Selwood N, Brunner F. Recurrence of primary renal disease on kidney graft: a European pediatric experience. *J Am Soc Nephrol* 1992; 2 [Suppl 12]: S255-S257.
- Busch GJ, Chavers BM, Gillingham KJ, et al: Chronic renal allograft rejection in the first 6 months post-transplantation. *Transplantation*, 1995 60:1413.
- Cameron JS. Recurrent primary disease and de novo nephritis following renal transplantation. *Pediatr Nephrol* 1991; 5:412-421.
- Chadban S: Glomerulonephritis recurrence in renal allograft. *J Am Soc Nephrol* 12:394-402, 2001.
- Chailimpamontree W, Dmitrienko S, Li G, Balshaw R, Magil A, Shapiro RJ, Landsberg D, Gill J, Keown PA; Genome Canada Biomarkers in transplantation Group. Probability, predictors, and prognosis of posttransplantation glomerulonephritis. *J Am Soc Nephrol*. 2009 Apr;20(4):843-51.
- Chandrakantan A; Ratanapanichkich P; Said M; Barker CV; Julian BA. Recurrent IgA nephropathy after renal transplantation despite immunosuppressive regimens with mycophenolate mofetil. *Nephrol Dial Transplant* 2005 Jun; 20(6):1214-21.
- Cheigh JS; Mouradian J; Susin M; Stubenbord WT; Tapia L; Riggio RR; Stenzel KH; Rubin AL. Kidney transplant nephrotic syndrome: relationship between allograft histopathology and natural course. *Kidney Int* 1980 Sep;18(3):358-65.

- Cheong HI, Han HW, Park HW. Early recurrent nephritic syndrome after renal transplantation in children with focal segmental glomerulosclerosis. *Nephrol Dial Transplant* 2000; 15:78–81.
- Choy BY; Chan TM; Lai KN. Recurrent glomerulonephritis after kidney transplantation. *Am J Transplant*. 2006 Nov; 6(11):2535-42.
- Conlon PJ, Lynn K, Winn MP et al. Spectrum of disease in familial focal and segmental glomerulosclerosis. *Kidney Int* 1999; 56: 1863–1871.
- Cosio FG; Frankel WL; Pelletier RP; Pesavento TE; Henry ML; Ferguson RM. Focal segmental glomerulosclerosis in renal allografts with chronic nephropathy: implications for graft survival. *Am J Kidney Dis* 1999 Oct; 34(4):731-8.
- Cosyns JP; Couchoud C; Pouteil-Noble C; Squifflet JP; Pirson Y. Recurrence of membranous nephropathy after renal transplantation: probability, outcome and risk factors. *Clin Nephrol* 1998 Sep; 50(3):144-53.
- Courtney AE; McNamee PT; Nelson WE; Maxwell AP. Does angiotensin blockade influence graft outcome in renal transplant recipients with IgA nephropathy. *Nephrol Dial Transplant*. 2006 Dec; 21(12):3550-4.
- Dall'Amico R, Ghiggeri GM, Carraro M. Prediction and treatment of recurrent focal segmental glomerulosclerosis after renal transplantation in children. *Am J Kid Dis* 1999; 34: 1048–1055.
- Denton MD; Singh AK. Recurrent and de novo glomerulonephritis in the renal allograft. *Semin Nephrol* 2000 Mar;20(2):164-75.
- F. G. Cosio, J. M. Gloor, S. Sethi and M. D. Stegall Transplant Glomerulopathy. *American Journal of Transplantation* 2008; 8: 492–496.
- Floege J: Recurrent glomerulonephritis following renal transplantation: an update. *Nephrol dial transplant*, 2003 18:1260.
- Gallon L; Perico N; Dimitrov BD; Winoto J; Remuzzi G; Leventhal J; Gaspari F; Kaufman D. Long-term renal allograft function on a tacrolimus-based, pred-free maintenance immunosuppression comparing sirolimus vs. MMF. *Am J Transplant*. 2006 Jul; 6(7):1617-23.
- Gaston RS. Current and evolving immunosuppressive regimens in kidney transplantation. *Am J Kidney Dis*. 2006 Apr;47(4 Suppl 2):S3-21.
- Gephardt GN, Tubbs RR, Braun WE et al. Nephrotic range proteinuria with 'minimal change glomerulopathy' in human renal allografts: report of four cases. *Am J Kid Dis* 1988; 12:51–61.
- Glasscock RJ, Feldman D, Reynolds ES: Human renal isografts: a clinical and pathologic analysis. *Medicine (Baltimore)* 1968; 47:411.
- Glicklich D; Matas AJ; Sablay LB; Senitzer D; Tellis VA; Soberman R; Veith FJ. Recurrent membranoproliferative glomerulonephritis type 1 in successive renal transplants. *Am J Nephrol* 1987;7(2):143-9.
- Gloor JM, Sethi S, Stegall MD et al. Transplant glomerulopathy: Subclinical incidence and association with alloantibody. *Am J Transplant* 2007; 9: 2124-2132.
- Gobel J, Olbricht CJ, Offner G, et al: Kidney transplantation in Alport's syndrome: long-term outcome and allograft anti-GBM nephritis. *Clin nephrol* 1992; 38:299.

- Gossmann J, Scheuermann EH, Porubsky S, Kachel HG, Geiger H, Hauser IA. Abrogation of nephrotic proteinuria by rituximab treatment in a renal transplant patient with relapsed focal segmental glomerulosclerosis. *Transpl Int.* 2007 Jun;20(6):558-62.
- Habib R, Antignac C, Hinglais N, Gagnadoux M-F, Broyer M. Glomerular lesions in the transplanted kidney in children. *Am J Kidney Dis* 1987; 10: 198-207.
- Hanevold CD, Greenbaum LA. Nephrotic syndrome after conversion to alternate day steroids in two children with a history of recurrent FSGS. *Pediatr Transplant.* 2003 Oct;7(5):395-9.
- Hariharan S, Adams M, Brennan D, Davis C, First M, Johnson C, Ouseph R, Peddi V, Pelz C, Roza A, Vincenti F, George V: Recurrent and de novo glomerular disease after renal transplantation: A report from Renal Allograft Disease Registry (RADR). *Transplantation* 1999; 68:635-641.
- Hariharan S, Johnson C, Bresnahan B, Taranto S, McIntosh M, Stablein D: Improved graft survival after renal transplantation in the United States, 1988 to 1996. *N Engl J Med* 2000; 342: 605-612.
- Hariharan S, Peddi VR, Savin VJ et al. Recurrent and de novo renal diseases after renal transplantation: a report from the renal allograft disease registry. *Am J Kid Dis* 1998; 31:928-931.
- Heidet L, Gagnadoux ME, Beziau A, et al: Recurrence of de novo membranous glomerulonephritis on renal grafts. *Clin nephrol* 41:314, 1994.
- Hoyer JR, Vernier RL, Najarian JS et al. Recurrence of idiopathic nephrotic syndrome after renal transplantation. *Lancet* 1972; 11: 344-448.
- Ingulli E, Tejani A. Incidence, treatment, and outcome of recurrent focal segmental glomerulosclerosis post-transplantation in 42 allografts in children – a single-center experience. *Transplantation* 1991; 51: 401-405
- Josep M. Cruzadoa, Marta Carrerab, Joan Torrasa and Josep M. Grinyo. Hepatitis C Virus Infection and de Novo Glomerular Lesions in Renal Allografts. *American Journal of Transplantation* 2001; 1: 171±178.
- Josephson MA; Spargo B; Hollandsworth D; Thistlethwaite JR. The recurrence of recurrent membranous glomerulopathy in a renal transplant recipient: case report and literature review. *Am J Kidney Dis* 1994 Nov; 24(5):873-8.
- Kashtan CE: Alport syndrome: Renal transplantation and donor selection. *Ren fail* 2000; 22:765.
- Kershaw DB, Sedman AB, Kelsch RC, Bunchman TE. Recurrent focal segmental glomerulosclerosis in pediatric renal transplant recipients: successful treatment with oral cyclophosphamide. *Clin Transplant* 1994; 8: 546-549.
- Kibert S, Schwartz MM, Lewis E. Primary focal segmental glomerulosclerosis: clinical course and response to therapy. *Am J Kidney Dis* 1994; 23: 773-781.
- Kim YS; Moon JI; Jeong HJ; Kim MS; Kim SI; Choi KH; Lee HY; Han DS; Park K. Live donor renal allograft in end-stage renal failure patients from immunoglobulin A nephropathy. *Transplantation* 2001 Jan 27; 71(2):233-8.
- Kowalewska J; Yuan S; Sustento-Reodica N; Nicosia RF; Smith KD; Davis CL; Alpers CE. IgA nephropathy with crescents in kidney transplant recipients. *Am J Kidney Dis* 2005 Jan; 45(1):167-75.

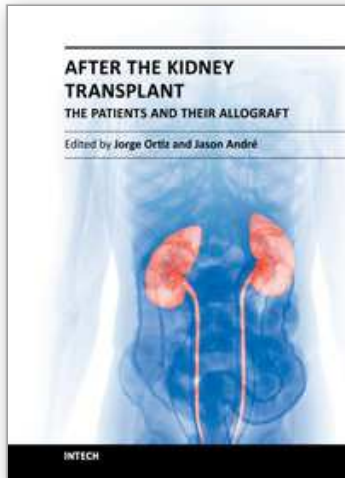
- Lien YH; Scott K. Long-term cyclophosphamide treatment for recurrent type I membranoproliferative glomerulonephritis after transplantation. *Am J Kidney Dis* 2000 Mar; 35(3):539-43.
- Little MA; Dupont P; Campbell E; Dorman A; Walshe JJ. Severity of primary MPGN determines renal survival and post-transplantation recurrence risk. *Kidney Int.* 2006 Feb; 69(3):504-11.
- Matalon A, Markowitz GS, Joseph RE, Cohen DJ, Saal SD, Kaplan B, D'Agati VD, Appel GB. Plasmapheresis treatment of recurrent FSGS in adult renal transplant recipients. *Clin Nephrol.* 2001 Oct;56(4):271-8.
- McLean RH; Geiger H; Burke B; Simmons R; Najarian J; Vernier RL; Michael AF. Recurrence of membranoproliferative glomerulonephritis following kidney transplantation. Serum complement component studies. *Am J Med* 1976 Jan; 60(1):60-72.
- Meehan SM; Pascual M; Williams WW; Tolloff-Rubin N; Delmonico FL; Cosimi AB; Colvin RB SO: De novo collapsing glomerulopathy in renal allografts. *Transplantation* 1998 May 15; 65 (9):1192-7.
- Morales JM, Pascual-Capdevila J, Campistol JM, et al: Membranous glomerulonephritis associated with hepatitis C virus in renal transplant patients. *Transplantation* 63:1634, 1997.
- Morales JM; Martinez MA; Munoz de Bustillo E; Munoz MA; Gota R; Usera G. Recurrent type III membranoproliferative glomerulonephritis after kidney transplantation. *Transplantation* 1997 Apr 27; 63(8):1186-8.
- Muczynski KA. Plasmapheresis maintained renal function in an allograft with recurrent membranoproliferative glomerulonephritis type I. *Am J Nephrol* 1995; 15(5):446-9.
- Ohta T, Kawaguchi H, Hattori M et al. Effect of pre- and postoperative plasmapheresis on posttransplant recurrence of focal segmental glomerulosclerosis in children. *Transplantation* 2001; 71: 628-633.
- Peter J. Morris: kidney transplantation: principles and practice. 6th edition, 2008.
- Racusen LC, Solez K, Colvin R. Fibrosis and atrophy in the renal allograft. Interim report and new directions. *Am J Transplant* 2002; 2: 203-206.
- Ramos EL, Tisher CC: Recurrent diseases in the kidney transplant. *Am j kidney dis*, 1994 24:142.
- Requião-Moura LR, Moscoso-Solorzano GT, Franco MF, Ozaki KS, Pacheco-Silva A, Kirsztajn GM, Câmara NO. Prognostic factors associated with poor graft outcomes in renal recipients with post-transplant glomerulonephritis. *Clin Transplant.* 2007 May-Jun;21(3):363-70.
- Rizzoni G, Ehrich JHH, Bunner FP et al. Combined report on regular dialysis and transplantation of children in Europe, 1990. *Nephrol Dial Transplant* 1991; 6: 31-42.
- Ronco P, Debiec H. Molecular pathomechanisms of membranous nephropathy: from Heymann nephritis to alloimmunization. *J Am Soc Nephrol.* 2005 May;16(5):1205-13.
- Savin V, Sharma R, Sharma M et al. Circulating factor associated with increased glomerular permeability to albumin in recurrent focal segmental glomerulosclerosis. *N Engl J Med* 1996; 334: 878-883.

- Schwarz A; Krause PH; Offermann G; Keller F. Impact of de novo membranous glomerulonephritis on the clinical course after kidney transplantation. *Transplantation* 1994 Sep 27; 58(6):650-4.
- Senguttuvan P, Cameron JS, Hartley RB et al. Recurrence of focal segmental glomerulosclerosis in transplanted kidneys: analysis of incidence and risk factors in 59 allografts. *Pediatr Nephrol* 1990; 4: 21-28
- Sharma M, Sharma R, McCarthy ET, Savin VJ. 'The FSGS Factor': enrichment and in vivo effect of activity from focal segmental glomerulosclerosis plasma. *J Am Soc Nephrol* 1999; 10: 552-561.
- Siddqi, N, Hariharan, S, Danovitch, G. Evaluation and Preparation of Renal Transplant Candidates. *Handbook of Kidney Transplantation, Fourth Ed., Lippincott Williams Wilkins, Philadelphia* 2005.
- Sis B, Campbell PM, Mueller T et al. Transplant glomerulopathy, late antibody-mediated rejection and the ABCD tetrad in kidney allograft biopsies for cause. *Am J Transplant* 2007; 7: 1743-1752.
- Srivasta RN, Kalia A, Travis LB, Diven SC, Gugliuzza KK, Rajaraman S. Prompt remission of post-renal transplant nephrotic syndrome with high-dose cyclosporine. *Pediatr Nephrol* 1994; 8: 94-95.
- Stephanian E, Matas AJ, Mauer SM. Recurrence of disease in patients retransplanted for focal segmental glomerulosclerosis. *Transplantation* 1992; 53: 755-757.
- Striegel JE, Sibley RK, Fryd DS, Mauer M. Recurrence of focal segmental sclerosis in children following renal transplantation. *Kidney Int* 1986; 19: S44-S50.
- Tejani A, Nicastrì AD, Sen D, Chen CK, Phadke K, Adamson O, Butt KM. Long-term evaluation of children with nephritic syndrome and focal segmental glomerular sclerosis. *Nephron* 1983; 35: 225-231.
- Truong L; Gelfand J; D'Agati V; Tomaszewski J; Appel G; Hardy M; Pirani CL. De novo membranous glomerulonephropathy in renal allografts: a report of ten cases and review of the literature. *Am J Kidney Dis* 1989 Aug; 14(2):131-44.
- Vincenti F, Ghiggeri GM. New insights into the pathogenesis and the therapy of recurrent focal glomerulosclerosis. *Am J Transplant*. 2005 Jun; 5(6):1179-85.
- William A. Golgert, Gerald B. Appel, and Sundaram Hariharan Recurrent Glomerulonephritis after Renal Transplantation: An Unsolved Problem. *Clin J Am Soc Nephrol* 2008; (3): 800-807.
- Worawon Chailimpamontree, Svetlana Dmitrienko, Guiyun Li, Robert Balshaw, Alexander Magil, R. Jean Shapiro, David Landsberg, John Gill, Paul A. Keown: Probability, Predictors, and Prognosis of Posttransplantation Glomerulonephritis. *J Am Soc Nephrol* 2009; 20: 843-851.
- Yabu JM, Ho B, Scandling JD, Vincenti F. Rituximab failed to improve nephrotic syndrome in renal transplant patients with recurrent focal segmental glomerulosclerosis. *Am J Transplant*. 2008 Jan; 8(1):222-7.
- Yamamoto I, Horita S, Takahashi T et al. Glomerular expression of plasmalemmal vesicle-associated protein-1 in patients with transplant glomerulopathy. *Am J Transplant* 2007; 7: 1954-1960.

Zeman M, Campbell P, Bain VG. Hepatitis C eradication and improvement of cryoglobulinemia-associated rash and membranoproliferative glomerulonephritis with interferon and ribavirin after kidney transplantation. *Can J Gastroenterol.* 2006 Jun; 20(6):427-31.

IntechOpen

IntechOpen



After the Kidney Transplant - The Patients and Their Allograft

Edited by Prof. Jorge Ortiz

ISBN 978-953-307-807-6

Hard cover, 386 pages

Publisher InTech

Published online 17, August, 2011

Published in print edition August, 2011

There are many obstacles in kidney transplantation. For the transplant team, there is the balance between immunosuppression to aid in the recipient's tolerance of the allograft and the infection risk of a suppressed immune system. These potential long term complications of kidney transplantation are relatively well known, but there are many other complications that patients and families do not consider when preparing themselves for a kidney transplant. Although the benefits of attempting a kidney transplant far outweigh downfalls of the long term sequelae, kidney transplantation is by no means a benign procedure. It is the hope of these authors that the reader will leave with a sense of understanding towards the kidney recipients.

How to reference

In order to correctly reference this scholarly work, feel free to copy and paste the following:

Ahmed Akl, Hany Adel and Ehab Wafa (2011). Post-Transplant Glomerulonephritis in Live-Donor Renal Transplant Recipients: Clinical Course and Risk Factors, *After the Kidney Transplant - The Patients and Their Allograft*, Prof. Jorge Ortiz (Ed.), ISBN: 978-953-307-807-6, InTech, Available from: <http://www.intechopen.com/books/after-the-kidney-transplant-the-patients-and-their-allograft/post-transplant-glomerulonephritis-in-live-donor-renal-transplant-recipients-clinical-course-and-ris>

INTECH
open science | open minds

InTech Europe

University Campus STeP Ri
Slavka Krautzeka 83/A
51000 Rijeka, Croatia
Phone: +385 (51) 770 447
Fax: +385 (51) 686 166
www.intechopen.com

InTech China

Unit 405, Office Block, Hotel Equatorial Shanghai
No.65, Yan An Road (West), Shanghai, 200040, China
中国上海市延安西路65号上海国际贵都大饭店办公楼405单元
Phone: +86-21-62489820
Fax: +86-21-62489821

© 2011 The Author(s). Licensee IntechOpen. This chapter is distributed under the terms of the [Creative Commons Attribution-NonCommercial-ShareAlike-3.0 License](#), which permits use, distribution and reproduction for non-commercial purposes, provided the original is properly cited and derivative works building on this content are distributed under the same license.

IntechOpen

IntechOpen