

# We are IntechOpen, the world's leading publisher of Open Access books Built by scientists, for scientists

**4,800**

Open access books available

**122,000**

International authors and editors

**135M**

Downloads

Our authors are among the

**154**

Countries delivered to

**TOP 1%**

most cited scientists

**12.2%**

Contributors from top 500 universities



**WEB OF SCIENCE™**

Selection of our books indexed in the Book Citation Index  
in Web of Science™ Core Collection (BKCI)

Interested in publishing with us?  
Contact [book.department@intechopen.com](mailto:book.department@intechopen.com)

Numbers displayed above are based on latest data collected.

For more information visit [www.intechopen.com](http://www.intechopen.com)



## Effect of Vitamin E on the Development of Testis in Sheep

Hailing Luo, Suyun Ge, Dubing Yue, Leyan Yan,  
Xu Xu, Kun Liu and Fei Yuan

*State Key Laboratory of Animal Nutrition, College of Animal Science and Technology,  
China Agricultural University, Beijing,  
PR China*

### 1. Introduction

Vitamin E (VE) is a term that encompasses a group of potent, lipid-soluble, chain-breaking antioxidants. Structural analyses have revealed that molecules having VE antioxidant activity include four tocopherols ( $\alpha$ -,  $\beta$ -,  $\gamma$ -, and  $\delta$ -tocopherols) and four tocotrienols ( $\alpha$ -,  $\beta$ -,  $\gamma$ -, and  $\delta$ -tocotrienols). One form,  $\alpha$ -tocopherol, is the most abundant form in nature, has the highest biological activity. As a naturally occurring antioxidant, VE is located in biological membranes where it acts to protect the membrane PUFA—polyunsaturated fatty acid (PUFA) from oxidation and attenuate oxidative damage to the cellular membranes (Sugiyama, 1992). Tappel (1962), Burton and Ingold (1986) and Esterbauer et al. (1991) found VE was effective in preventing lipid peroxidation and other radical-driven oxidative events. VE was first isolated from green leafy vegetables by Herbert Evans and Katherine Bishop, two prominent researchers from Berkeley and described as a fertility factor in 1922, then was named tocopherol in 1924 and synthesized in 1938 (Sen et al., 2007). The role of VE in reproductive performance was shown up that supplementing VE increased total sperm output and sperm concentration in boars (Brzezinska-Slebodzinska et al., 1995), rabbits (Yousef et al., 2003) and rams (Luo et al., 2004; Yue et al., 2010).

Impairment of mammalian fertility has also been attributed to VE deficiency. The crucial role of VE in animal reproduction has been recognized since 1922 (Evans and Bishop, 1922). To date, there are approximately 100 publications on this topic, which highlight the beneficial effects of this antioxidant on viability, membrane integrity and motility of spermatozoa of different species. The protective effects of VE against oxidative damage of sperm cells become even more significant when hygienic conditions are poorly controlled, as they frequently occur in field. Such conditions are associated with increased incidence of infections/inflammations of reproductive apparatus. During inflammation, the antioxidant defence of reproductive system downplays and generates an oxidative stress (Potts and Pasqualotto, 2003), which may impair testis function and affect negatively semen characteristics (O'Bryan et al., 2000). Because of high content of polyunsaturated membrane lipids, testicular tissue becomes one of the targets for oxidative stress (Mishra and Acharya, 2004).

VE supplementation in diet can protect the cell membrane from oxidation and improve the survival rates of cells. Adding VE in diet also increased activity of total anti-oxidation

competence (T-AOC), superoxide dismutase (SOD) and glutathione peroxidase (GSH-PX), decreased content of nitric oxide (NO), malondialdehyde (MDA) and activity of nitric oxide synthase (NOS) in testis in Boer goat (Zhu et al., 2010). In Aohan fine-wool sheep, supplementing VE have a positive role in reducing MDA level and improving the activities of SOD and GSH-PX in testicular cell membrane and mitochondria (Yue et al, 2010) and improving testicular marker enzyme, such as ATPase, lactate dehydrogenase (LDH), sorbitol dehydrogenase (SDH), and alkaline phosphatase (ALP) activity (Yan et al, 2010).

Some reports proved that VE had effects on reproductive organs. Marin-Guzman et al. (1997) found the length and width of testis in boar were larger in group of VE supplementation at 220 IU/kg in diet than in group without VE supplementation ( $P>0.05$ ). Soleimani et al. (2009) found testis volume of rat in VE treated group (100 mg/kg per day) was bigger than in Control ( $P>0.05$ ), the thickness of germinal epithelium and diameter of seminiferous tubules in VE treated group was increased compared with Control ( $P<0.05$ ). VE deficiencies caused testicular degeneration in poultry (Todorovic et al., 2002), rat and hamster (Sidney et al., 1975) and resulted in a lower number of germ cells and a reduction in sperm production (Cooper et al., 1987). Wu et al. (1973) and Wilson et al. (2003) found deficiency of VE may lead to reproductive organ damage, such as degenerative spermatogonium, testicular damage and degeneration of the seminiferous tubules.

In view of the above, VE can reduce the oxidative damage on reproductive organs and the effects of VE on reproductive efficiency have been described in several species. But for growing fine-wool sheep, the evidence of effects on the development of reproductive organs has been scant. Therefore, the objective of the present study was conducted to determine the effect of VE on the development of the testis of Aohan fine-wool sheep.

## 2. Material and methods

### 2.1 Animals and management

Thirty male growing Aohan fine-wool sheep (local breed, 5 months old) weighing an average of  $24.58\pm 3.12$  kg were purchased from the Aohan fine-wool sheep breeding farm of Inner Mongolia Autonomous Region, China. A basic ration was fed with a forage/concentrate ratio of 6/4. The formulation is shown in Table 1 and was made according to the NRC feeding standard (1985). The sheep were divided randomly into five groups, one control and four treatments. Each group was supplemented VE with 0, 20, 200, 1000 or 2400 IU sheep<sup>-1</sup> d<sup>-1</sup> for 12 months, which are 0, 1, 10, 50, 120 times of NRC feeding standard. These levels were based on previous research (Luo et al., 2004; Liu et al., 2005; Zhu et al., 2009, 2010). The Control received 4.3 IU sheep<sup>-1</sup> d<sup>-1</sup> VE which existed in basal diet. VE powder consisting of VE acetate (1 mg contains 1 IU VE) was bought from the Zhejiang Guobang Pharmaceutical Co., Ltd (China). In this study, all procedures involving animals were conducted under the approval of China Agricultural University Animal Care and Use Committee.

### 2.2 Methods

Three Aohan fine-wool sheep in each group were randomly chosen for slaughter at the age of 17 months to collect the testis. Ipsilateral testis were dissected from their surrounding connective tissues and put into phosphate buffer to prepare for biopsy. H&E stained slides were used according to the system described by Karl et al. (2005) and the Motic Image Manipulation system was used to measure sample indexes.

Ingredients	%	Nutrient contents of DM	
Forage	60	CP (%)	4.86
Concentrate	40	EE (%)	8.97
		NDF (%)	31.23
		ADF (%)	22.33
		Vitamin E (IU/Kg)	3.42
The composition and nutrient level of the concentrate			
Ingredients	%	Nutrient content of DM	
Corn	62	CP (%)	18.68
Soybean meal	26	EE (%)	14.41
Wheat bran	8	NDF (%)	10.14
CaHPO <sub>4</sub>	2	ADF (%)	6.52
Salt	1	Vitamin E (IU/Kg)	7.56
Additives	1		

CP: crude protein; EE: ether extract; NDF: neutral detergent fiber; ADF: acid detergent fiber

Table 1. The composition and nutrient level of the diet

### 2.3 Statistical analyses

Data were subjected to one-way analysis of variance (ANOVA) followed by Duncan's new multiple range tests with the SAS 9.1 software program to determine the level of significance among mean values. Results were expressed as a mean and standard error. Values of  $P < 0.05$  were considered significant.

### 3. Results

Table 2 showed the effect of different levels of VE in diet on testis indexes. The width, length, transverse girth, vertical girth and testis volume in treatments were larger than Control respectively ( $P > 0.05$ ), the order was Group 2 > Group 3 > Group 1 > Group 4 > Control.

Item	Control	Group 1	Group 2	Group 3	Group 4
Width (cm)	5.59±0.65	5.90±1.35	6.69±0.40	6.23±0.78	5.89±1.12
Length (cm)	8.64±0.82	9.56±2.09	10.51±0.63	10.14±1.60	9.32±1.48
Transverse girth (cm)	13.42±1.85	14.85±2.77	16.90±0.28	15.58±1.52	14.63±2.79
Vertical girth (cm)	19.63±2.01	21.03±3.54	24.22±1.71	22.67±3.04	20.93±3.96
Volume (cm <sup>3</sup> )	289.63±98.12	383.85±255.42	495.17±81.67	426.81±156.44	358.20±172.70

Values in same row with same superscript differ insignificantly ( $P > 0.05$ ), with different superscripts differ significantly ( $P < 0.05$ ).

Table 2. Effect of Vitamin E on testis indexes

The effect of VE supplementation in diet on histological indexes of testicle was presented in Table 3 and Fig.1. VE supplementation in diet increased the thickness of germinal epithelium, that in Group 2 (143.72  $\mu\text{m}$ ), Group 4 (141.28  $\mu\text{m}$ ) was significantly larger ( $P < 0.05$ ) than in Control (75.05  $\mu\text{m}$ ) respectively, but Groups 1 (91.31  $\mu\text{m}$ ) and 3 (116.02  $\mu\text{m}$ ) did not significantly differ with Control ( $P > 0.05$ ).

Item	Control	Group 1	Group 2	Group 3	Group 4
Density of sertoli cell (number per seminiferous tubule)	10.03±2.08 <sup>b</sup>	11.20±2.13 <sup>ab</sup>	13.57±0.56 <sup>a</sup>	13.40±1.13 <sup>a</sup>	13.33±1.27 <sup>a</sup>
Density of spermatogenic cell (number per seminiferous tubule)	60.13±25.18 <sup>b</sup>	93.03±44.90 <sup>ab</sup>	145.10±52.79 <sup>a</sup>	137.35±19.59 <sup>ab</sup>	113.80±36.05 <sup>ab</sup>
Density of leydig cell (number/mm <sup>2</sup> )	285.14±14.82	299.74±18.30	325.87±15.69	320.49±6.52	313.57±38.10
Thickness of germinal epithelium (µm)	75.05±17.21 <sup>b</sup>	91.31±36.23 <sup>ab</sup>	143.72±28.17 <sup>a</sup>	116.02±15.24 <sup>ab</sup>	141.28±29.48 <sup>a</sup>
Diameter of seminiferous tubule (µm)	303.93±51.41 <sup>c</sup>	334.02±57.55 <sup>bc</sup>	465.78±56.16 <sup>a</sup>	374.32±16.73 <sup>abc</sup>	443.66±64.45 <sup>ab</sup>

Values in same row with same superscript differ insignificantly ( $P>0.05$ ), with different superscripts differ significantly ( $P<0.05$ ).

Table 3. Effect of Vitamin E on histological indexes of testicle

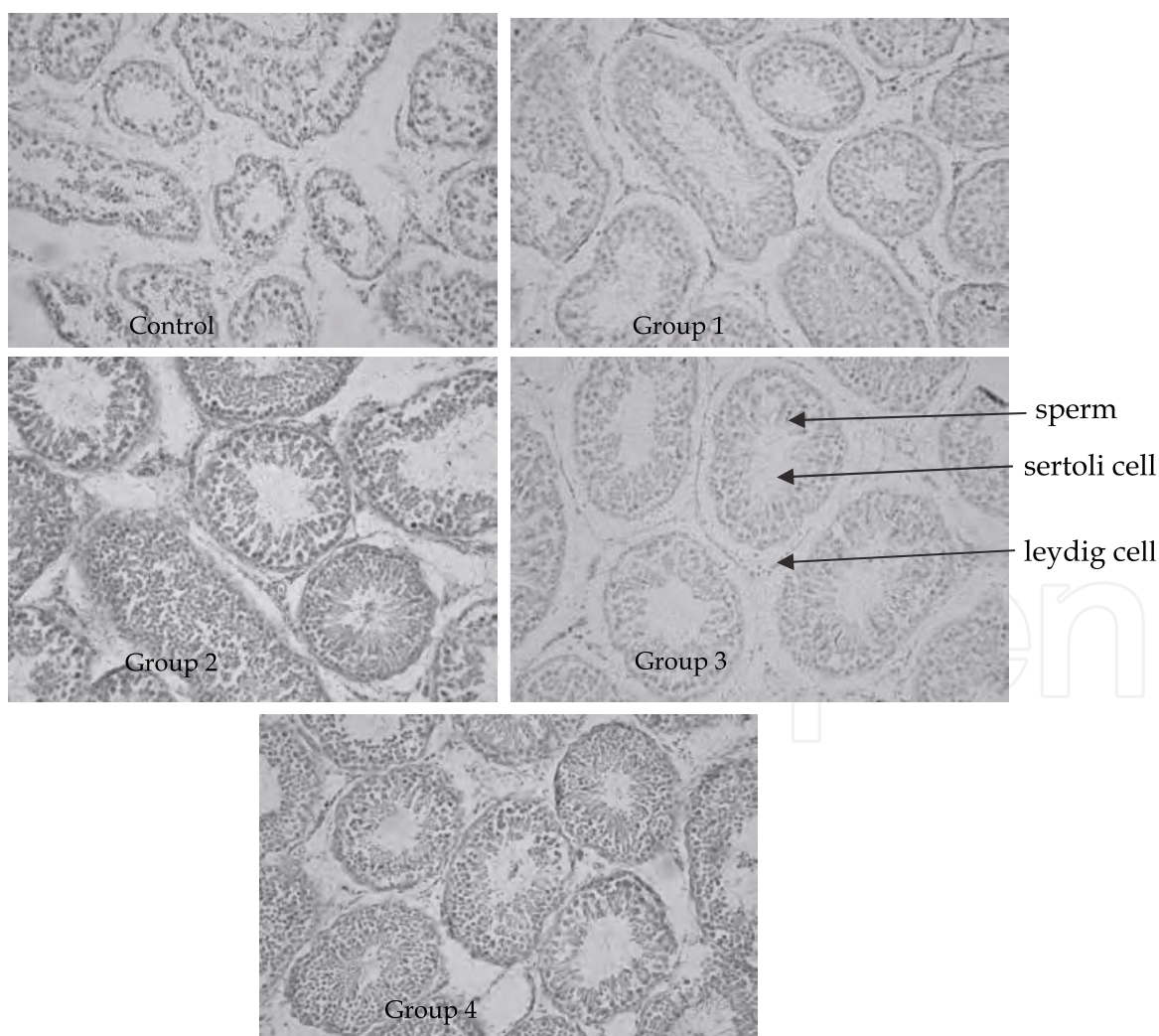


Fig. 1. Effect of Vitamin E level in diet on histological structure of testis (400×)



Compared with the Control, supplementing VE in diets increased the diameter of seminiferous tubule, it was significantly wider in Group 2 (at the level of 200 IU sheep<sup>-1</sup> d<sup>-1</sup>) than in Control and Group 1 ( $P < 0.05$ ). Furthermore, the diameter of seminiferous tubule in Group 4 was also significantly wider than in Control ( $P < 0.05$ ). No significant differences were observed between Control and Group 1, or Group 3 ( $P > 0.05$ ).

Although the density of leydig cell in treatment groups was larger than in Control, no significant differences were observed among Control and treatment groups ( $P > 0.05$ ). Feeding with dietary VE tended to have a higher density of sertoli cell, it was significantly increased in Group 2, Group 3 and Group 4 compared with Control ( $P < 0.05$ ). VE supplementation improved the density of spermatogenic cell, that was significantly higher in Group 2 than in Control ( $P < 0.05$ ) and no significant differences were observed between Control and other treatment groups ( $P > 0.05$ ).

#### 4. Discussion

Marin-Guzman et al. (1997) presented the length and width of testis in boar were larger in group of VE supplementation at 220 IU·kg<sup>-1</sup> in diet than in group without VE supplementation, testis volume of rat in VE treated group (100 mg·kg<sup>-1</sup>·d<sup>-1</sup>) was bigger than in Control (Soleimani Mehranjani et al., 2009,  $P > 0.05$ ). Similar results were observed in the present study, the width, length, transverse girth, vertical girth and volume of testis in VE treated groups were higher than Control, but no significant differences were observed between Control and treatment groups ( $P > 0.05$ ).

This study proved that for Aohan fine-wool sheep, the thickness of germinal epithelium, diameter of seminiferous tubule and the density of spermatogenic cell, sertoli cell and leydig cell in VE treatment groups were larger than in Control. Similar results have been proved in Boer goats in our previous research (Zhu et al., 2009), which showed that diameters of seminiferous tubules and numeric density of spermatogenic cells tended to be larger in 80 IU kid<sup>-1</sup> d<sup>-1</sup> VE supplemented group compared to the control group ( $P < 0.05$ ). However, no significant effects were observed on thickness of germinal epithelium and numeric density of leydig cells ( $P > 0.05$ ).

Sertoli cells are the nurse cells for the spermatogonium in the seminiferous tubules and can thus influence the development of the sperm precursor cells and the subsequent number of spermatids. This effect may be accomplished through their production of various factors such as plasminogen activator, transferrin, and sertoli cell growth factor (Lacroix et al., 1977; Feig et al., 1980; Skinner and Griswold, 1980). Besides, sertoli cells can maintain high concentrations of androgens in seminiferous tubules and epididymis (Lacroix et al., 1977), they can also transport testosterone from the testis into epididymis (Krishnamoorthy et al., 2005). Our research showed supplementing VE in diet increased the density of sertoli cell, which in Group 2, Group 3 and Group 4 was significantly higher than in Control respectively ( $P < 0.05$ ) and Group 2 was the highest. The results indicated that VE supplementation can promote the growth of sertoli cells.

The spermatogenic cell is the sum of spermatogenous cell, spermatocyte, spermatoblast and sperm male germ cells may be susceptible to oxidative stress because of high concentrations of PUFAs and low antioxidant capacity (Vernet et al., 2004). It is reported that dietary deficiencies of VE in growing males causes degenerative spermatogonium, resulting in a lower sperm concentration (Cooper et al., 1987; Lin et al., 2005). In this study, the density of spermatogenic cell in VE supplemented groups increased, that in Group 2 (200 IU sheep<sup>-1</sup> d<sup>-1</sup>) was significantly higher than in Control ( $P < 0.05$ ).

Testosterone secretion is critical for male secondary sexual differentiation and leydig cells are the principal source of testosterone production in the males (Ren-Shan et al., 2007). ROS can be produced in leydig cells through mitochondrial respiration (Chen et al., 2001) as well as through the cytochrome P450 enzymes of the steroidogenic pathway (Hornsby, 1989; Peltola et al., 1996). VE's function as an antioxidant, can quench lipid peroxidation and eliminate the ROS to protect the leydig cells from damage. Mather et al. (1983) reported that VE could prolong the survival and function of porcine leydig cells cultured in vitro. In our study, the density of leydig cell in treatment groups was larger than in Control, but no significant differences were observed among Control and treatment groups ( $P>0.05$ ).

VE supplementation in diet increased the thickness of germinal epithelium. Significant differences were observed between Group 2, Group 4 and Control ( $P<0.05$ ). The seminiferous epitheliums contained three different germ cell generations: spermatogonia, spermatocytes and spermatids and one kind of sertoli cell, which suggests the thickness of germinal epithelium was determined by the numbers of the spermatogenic cells and sertoli cells (Garcia-Gil et al., 2002). The spermatogenic cells and sertoli cells in VE supplemented groups increased in our research. This is in agreement with the findings of Soleimani Mehranjani et al. (2009), who found the thickness of germinal epithelium in VE treated rat increased compared with Control ( $P<0.05$ ). Zhu et al. (2009) also presented the thickness of germinal epitheliums in Boer kids were higher with VE than in Control, but differences between the Control and treatment groups were not significant ( $P>0.05$ ).

In our study, compared with the Control, supplementing VE in diets increased the diameter of seminiferous tubule. At the level of 200 IU sheep<sup>-1</sup> d<sup>-1</sup>, the diameter of seminiferous tubule was significantly wider than Control and Group 1 ( $P<0.05$ ), the result was similar to the research of Zhu et al. (2009), who reported that when Boer kids were supplemented with 0, 80, 320 and 880 IU kid<sup>-1</sup> d<sup>-1</sup> VE for 5 months, the diameter of seminiferous tubule of the testis in Group 2 (80 IU kid<sup>-1</sup> d<sup>-1</sup>) increased significantly compared to other groups ( $P<0.01$ ). The diameter increased to maximum level at a different supplementation dose for different breeds (80 IU kid<sup>-1</sup> d<sup>-1</sup> in Boer goat, Zhu et al., 2009 and 200 IU sheep<sup>-1</sup> d<sup>-1</sup> in Aohan fine-wool sheep in this study). The differences could be attributed to differences species or supplementation practices.

## 5. Conclusion

This study shows VE supplemented in diet can improve density of spermatogenic cell, sertoli cell, diameter of seminiferous tubule and thickness of germinal epithelium, especially at 200 IU sheep<sup>-1</sup> d<sup>-1</sup> VE supplement concentration. These results indicate that VE has a positive role in improving the development of testis in Aohan fine-wool sheep.

## 6. Acknowledgements

The present study is supported by the project from the China Agricultural Ministry (200903060) and the earmarked fund for China Agriculture Research System-39.


## 7. References

- Brzezinska-Slebodzinska, E.; Slebodzinski, AB.; Pietras, B.; Wieczorek, G. (1995). Antioxidant effect of Vitamin E and glutathione on lipid peroxidation in boar semen plasma. *Biol. Trace Elem. Res*, 47: 69-74

- Burton, GW.; Ingold KU. (1986). Vitamin E: application of the principles of physical organic chemistry to the exploration of its structure and function. *Acc. Chem. Res*, 19: 194-201
- Chen, H.; Cangello, D.; Benson, S.; Folmer, J.; Zhu, H.; Trush, MA.; Zirkin, BR. (2001). Age-related increase in mitochondrial superoxide generation in the testosterone-producing cells of Brown Norway rat testes: relationship to reduced steroidogenic function. *Exp. Gerontol*, 36 (8): 1361-1373
- Cooper, DR.; King, OR.; Carpenter, MP. (1987). Effect of Vitamin E deficiency on serum concentrations of follicle stimulating hormone and testosterone during testicular maturation and degeneration. *Endocrinology*, 120: 83-90
- Esterbauer, H.; Dieber-Rotheneder, M.; Striegl, G.; Waeg, G. (1991). Role of Vitamin E in preventing the oxidation of low density lipoprotein. *Am. J. Clin. Nutr*, 53: 314-321
- Evans, HM.; Bishop, KS. (1922). On the existence of a hitherto unrecognized dietary factor essential for reproduction. *Science*, 56: 650-651
- Feig, LA.; Bellve, AR.; Erickson, NH.; Klagsburn, M. (1980). Sertoli cells contain a mitogenic polypeptide. *Proc. Natl. Acad. Sci. USA*, 77: 4774-4778
- Garcia-Gil, N.; Pinart, E.; Sancho, S.; Badia, E.; Bassols, J.; Kádár, E.; Briz, M.; Bonet S. (2002). The cycle of the seminiferous epithelium in Landrace boars. *Anim. Reprod. Sci*, 73 (3-4): 211-225
- Ge, RS.; Chen, GR.; Cigdem T.; Matthew, PH. (2007). Phthalate ester toxicity in leydig cells: developmental timing and dosage considerations. *Reprod. Toxicol*, 23 (3): 366-373
- Hornsby PJ. (1989). Steroid and xenobiotic effects on the adrenal cortex: mediation by oxidative and other mechanisms. *Free Radic. Biol. Med*, 6 (1): 103-115
- Karl, L.; Patrick, K.; Fredrik, H.; Andrzej, M.; Leif, N.; Stig, EH.; Rodriguez, M. (2005). Delayed effects on plasma concentration of testosterone and testicular morphology by intramuscular low-dose di (2-ethylhexyl) phthalate or estradiol benzoate in the prepubertal boar. *Theriogenology*, 64 (5): 1170-1184
- Krishnamoorthy, G.; Murugesan, P.; Muthuvel, R.; Gunadharini, DN.; Vijayababu, MR.; Arunkumar, A.; Venkataraman, P.; Aruldas, MM.; Arunakaran, J. (2005). Effect of Aroclor 1254 on Sertoli cellular antioxidant system, androgen binding protein and lactate in adult rat in vitro. *Toxicology*, 212 (2-3): 195-205
- Lacroix, M.; Smith, FE.; Fritz, IB. (1977). Secretion of plasminogen activator by Sertoli cell enriched cultures. *Mol. Cell. Endocrinol*, 9: 227-236
- Lacroix M, Smith FE, Fritz IB. 1977. Secretion of plasminogen activator by Sertoli cell enriched cultures. *Mol. Cell Endocrinol*. 9 (2): 227-236
- Lin, YF.; Chang, SJ.; Yang, JR.; Lee, YP.; Hsu, AL. (2005). Effects of supplemental Vitamin E during the mature period on the reproduction performance of Taiwan native chicken cockerels. *Br. Poultry Sci*, 46 (3): 366-373
- Liu, HB.; Luo, HL.; Liu, ZH.; Shi, ZH.; Zhao, HB. (2005). Effect of dietary Vitamin E concentration on semen quality of goat. *Chin. J. Anim. Sci*, 10: 12-14 (in Chinese)
- Luo, HL.; Jia, ZH.; Zhu, SE.; Ding, JZ. (2004). Effect of Vitamin E on the qualities of fresh and frozen thawed ram semen. *China Herbivores* 24: 14-16 (in Chinese)
- Marin-Guzman, J.; Mahan, DC.; Chung, YK.; Pate, JL.; Pope, WF. (1997). Effects of dietary selenium and Vitamin E on boar performance and tissue responses, semen quality, and subsequent fertilization rates in mature gilts. *J. Anim. Sci*, 75: 2994-3003
- Mather, JP.; Saez, JM.; Dray, F.; Haour, F. (1983). Vitamin E prolongs survival and function of porcine Leydig cells in culture. *Acta Endocrinol. (Copenh.)*, 102 (3): 470-475



- Mishra, M.; Acharya, UR. (2004). Protective action of vitamins on the spermatogenesis in lead-treated Swiss mice. *J. Trace Elem. Med. Biol*, 18 (2): 173-178
- O'Bryan, MK.; Schlatt, S.; Phillips, DJ.; De Kretser, DM.; Hedger, MP. (2000). Bacterial lipopolysaccharide-induced inflammation compromises testicular function at multiple levels in vivo. *Endocrinology*, 141: 238-246
- Peltola, V.; Huhtaniemi, I.; Metsa-Ketela, T.; Ahotupa, M. (1996). Induction of lipid peroxidation during steroidogenesis in the rat testis. *Endocrinology*, 137 (1): 105-112
- Potts, JM.; Pasqualotto, FF. (2003). Semilal oxidative stress in patients with chronic prostatitis. *Andrologia*, 35: 304-308.
- Regina BF.; Maret, GT. (1999). Vitamin E: function and metabolism. *FASEB J*, 13: 1145-1155
- Sen, CK.; Khanna, S.; Rink, C.; Roy, S. (2007). Tocotrienols: the emerging face of natural vitamin E. *Vitam Horm*, 76: 203-61
- Sidney, I.; Mauey, KE.; Mason. (1975). Antisterility Activity of d-a-Tocopheryl Hydroquinone in the Vitamin E-deficient Male Hamster and Rat. *J. Nut*, 105: 491-494
- Skinner, MK.; Griswold, MD. (1980). Sertoli cells synthesize and secrete transferrin-like protein. *J. Biol. Chem*, 225: 9523-9525
- Soleimani, MM.; Noorafshan, A.; Momeni, HR.; Abnosi, MH.; Mahmoodi, M.; Anvari, M.; Hoseini, SM. (2009). Stereological study of the effects of Vitamin E on testis structure in rats treated with para-nonylphenol. *Asian J. Androl*, 11: 508-516
- Sugiyama, M. (1992). Role of physiological antioxidants in chromium (VI)-induced cellular injury. *Free Radical Biol. Med*, 12: 397-407
- Tappel, AL. (1962). Vitamin E as the biological lipid antioxidant. *Vitam. Horm*, 20: 493-510
- Todorovic, M.; Jokic, Z.; Davidovic, V. (2002). The influence of selenium and Vitamin E in poultry nutrition. *Biotech. Anim. Husb*, 18: 231-238
- Vernet, P.; Aitken, RJ.; Drevet, JR. (2004). Antioxidant strategies in the epididymis. *Mol. Cell. Endocrinol*, 216 (1-2): 31-39
- Wilson, MJ. Kaye, D.; Edward, SW.; Quach, HT.; Sinha, AA.; Vatassery, GT. (2003). Effect of Vitamin E deficiency on the growth and secretory function of the rat prostatic complex. *Exp. Mol. Pathol*, 74: 267-275
- Wu, SH., Oldfield, JE.; Whanger, PD.; Weswig, PH. (1973). Effect of selenium, Vitamin E and antioxidants on testicular function in rats. *Biol. Reprod*, 8 (5): 625-629
- Yan, LY.; Yue, DB.; Luo, HL.; Jin, XX.; Xu, X. (2010). Effect of Vitamin E supplementation on the enzymatic activity of selected markers in Aohan fine-wool sheep testis. *Anim. Reprod. Sci*, 122: 264-269
- Yousef, MI.; Abdallah, GA.; Kamel, KI. (2003). Effect of ascorbic acid and Vitamin E supplementation on semen quality and biochemical parameters of male rabbits. *Anim. Reprod. Sci*, 76: 99-111
- Yue, DB.; Yan, LY.; Luo, HL.; Jin, XX.; Xu, X. (2010). Effect of Vitamin E supplementation on semen quality and the testicular cell membranal and mitochondrial antioxidant abilities in Aohan fine-wool sheep. *Anim. Reprod. Sci*, 118: 217-222
- Zhu, H.; Luo, HL.; Meng, H.; Zhang, GJ.; Yan, LY.; Yue, DB. (2010). Effect of Vitamin E supplement in diet on antioxidant ability of testis in Boer Goat. *Anim. Reprod. Sci*, 117: 90-94
- Zhu, H.; Luo, HL.; Meng, H.; Zhang, GJ. (2009). Effect of Vitamin E supplementation on development of reproductive organs in Boer goat. *Anim. Reprod. Sci*, 113: 93-101



## **Artificial Insemination in Farm Animals**

Edited by Dr. Milad Manafi

ISBN 978-953-307-312-5

Hard cover, 300 pages

**Publisher** InTech

**Published online** 21, June, 2011

**Published in print edition** June, 2011

Artificial insemination is used instead of natural mating for reproduction purposes and its chief priority is that the desirable characteristics of a bull or other male livestock animal can be passed on more quickly and to more progeny than if that animal is mated with females in a natural fashion. This book contains under one cover 16 chapters of concise, up-to-date information on artificial insemination in buffalos, ewes, pigs, swine, sheep, goats, pigs and dogs. Cryopreservation effect on sperm quality and fertility, new method and diagnostic test in semen analysis, management factors affecting fertility after cervical insemination, factors of non-infectious nature affecting the fertility, fatty acids effects on reproductive performance of ruminants, particularities of bovine artificial insemination, sperm preparation techniques and reproductive endocrinology diseases are described. This book will explain the advantages and disadvantages of using AI, the various methodologies used in different species, and how AI can be used to improve reproductive efficiency in farm animals.

### **How to reference**

In order to correctly reference this scholarly work, feel free to copy and paste the following:

Hailing Luo, Suyun Ge, Dubing Yue, Leyan Yan, Xu Xu, Kun Liu and Fei Yuan (2011). Effect of Vitamin E on the Development of Testis in Sheep, *Artificial Insemination in Farm Animals*, Dr. Milad Manafi (Ed.), ISBN: 978-953-307-312-5, InTech, Available from: <http://www.intechopen.com/books/artificial-insemination-in-farm-animals/effect-of-vitamin-e-on-the-development-of-testis-in-sheep>

**INTECH**  
open science | open minds

### **InTech Europe**

University Campus STeP Ri  
Slavka Krautzeka 83/A  
51000 Rijeka, Croatia  
Phone: +385 (51) 770 447  
Fax: +385 (51) 686 166  
[www.intechopen.com](http://www.intechopen.com)

### **InTech China**

Unit 405, Office Block, Hotel Equatorial Shanghai  
No.65, Yan An Road (West), Shanghai, 200040, China  
中国上海市延安西路65号上海国际贵都大饭店办公楼405单元  
Phone: +86-21-62489820  
Fax: +86-21-62489821

© 2011 The Author(s). Licensee IntechOpen. This chapter is distributed under the terms of the [Creative Commons Attribution-NonCommercial-ShareAlike-3.0 License](#), which permits use, distribution and reproduction for non-commercial purposes, provided the original is properly cited and derivative works building on this content are distributed under the same license.

IntechOpen

IntechOpen