

We are IntechOpen, the world's leading publisher of Open Access books Built by scientists, for scientists

4,800

Open access books available

122,000

International authors and editors

135M

Downloads

Our authors are among the

154

Countries delivered to

TOP 1%

most cited scientists

12.2%

Contributors from top 500 universities



WEB OF SCIENCE™

Selection of our books indexed in the Book Citation Index
in Web of Science™ Core Collection (BKCI)

Interested in publishing with us?
Contact book.department@intechopen.com

Numbers displayed above are based on latest data collected.

For more information visit www.intechopen.com



Use of Pseudocolor for Detecting Otologic Structures in CT

Moon Suh Park, MD, Jae Yong Byun, MD,
Seung Geun Yeo, MD and Ho Yun Lee, MD
*Kyunghee University
Republic of Korea*

1. Introduction

Visualization of the fine structures of the ear is not easy because they may not be well contrasted and their shapes in ear may be variable in CT; for instance the incudostapedial joint often cannot be visualized separately and the stapes foot plate is barely visible in CT. Black-and-white images may not reflect actual anatomy in CT because the human eye is capable of detecting only 30 different shades of gray and intensity variations of less than 200 Hounsfield units (HU) are invisible to the naked eye (Tringali et al., 2007). However, the human eye can discriminate between hundreds of colors and human beings have a superior memory for colors, which means that color has wider dynamic range than gray scale (Addrews et al., 1972). There were some reports to support the effectiveness of the pseudocolor for the interpretation and detection of small periodontal defects (Brägger U et al., 1989; Reddy et al., 1991). An endoscopic pseudocolor imaging system has been used for color processing of ulcer images observed using an electronic endoscope (Tamada et al., 1996) and images of paranasal sinuses for endoscopic sinus surgery (Christmas et al., 1999). Besides there was an experiment showing that contrasting-color scales was the most efficient to detect small changes in radionuclide images (Crowe et al., 1988).

Recently color transformation of radiologic images has come into wide use because of the popularization of picture archiving and communication systems (PACS) for digital radiology. This has made it easier to manipulate image enhancement systems such as pseudocolor transformation. Converting a gray scale intensity level to a specific pseudocolor would be helpful for detecting small and difficult-to-find lesions in temporal bone CT (Park et al., 2009).

Pseudocolor could be used with various combinations. The rainbow scale is a standard and popular process that has been applied to density data to improve visual clarity, which is the result of traversing the color solid along a path through all the hues of the rainbow. Even the single pseudocolor could be applied for easy concentration on a specific area, for example otosclerotic foci in CT if needed.

Otosclerosis is a primary focal disease of the otic capsule. This disease involves principally the stapes footplate and the bone around the base of the stapes, which reduces normal sound transmission resulting in a conductive hearing loss. In temporal bone CT, the appearance of otosclerotic foci differs depending on the stage of the disease. In the active

stage, they appear to be radiolucent areas due to active bone resorption and remodeling of the otic capsule. But, in the inactive stage, they look like the normal adjacent bone of the cochlear capsule. In the active stage of otosclerosis, otosclerotic foci tend to occur in the area just in front of the oval window (fissula ante fenestram, FAF), round window, and pericochlear area. If the size of the lesions or the difference of radio-opacity is too small to detect, it will be not easy for otolaryngologists without much experience to find out them in CT images and to explain them to patients.

It has been known that the normal otic capsule has about 1800 to 2000 HU; however the optic capsule with otospongiotic change has about 1000 to 1400 HU (Huizing et al., 1987). So, the difference which numerical value of normal otic capsule and otospongiotic change occurred ranges from 400 to 1000 HU, which is correspondent to only several shades when the values is converted to gray color scale. But, if we convert the difference of HU to various colors or specific color then there will be lots of color shades. The pseudocolor transformation of the original image can widen capability of dynamic range. So, we supposed that converting gray scale intensity level to specific pseudocolor would be helpful to detect small lesions as well as fine structures of the ear in temporal bone CT.

2. Methods

2.1 Pseudocolor transformation of normal ossicles

Thirty-six CT studies of healthy ears were studied. Healthy ears were defined as having normal hearing ability with hearing loss of less than 20dBHL and showed a typical type A tympanogram. There was no past history of ear infection or inner ear diseases.

Both axial and coronal CT images were used. One mm thick contiguous non-overlapping sections were acquired. The scanner used was a Lightspeed 16(GE, Milwaukee, USA). The window width and level were adjusted to 3200 and +400 respectively.

The entire middle ear of the temporal bone was scanned; *i.e.* 24-32 planes were taken. The software used was Image- Pro Plus 4.0. (Media Cybernetics, MD, USA).

Pseudocolor transformation of the middle ear was performed using the following procedures: 2 planes of the axial CT image immediately below the plane showing the incudomalleolar joint were selected. After the CT images were scanned, they were converted to gray-scale images, because the pseudocolor command is only relevant to monochrome images. In Process menu, the intensity range was specified using the upper limit and lower limit buttons. The specified range was divided into the numbers of intervals and a default color was assigned to each interval, *i.e.* 255 colors were selected using the Divisions tool that showed entire and colorized part of the intensity range. Because red to blue and blue to red patterns of color spread (rainbow scale) were chosen in the pseudocolor scale's predefined assignments the process of the color assignments changing and refining of the intensity division widths were omitted. Blue to red arrays the colors in a spectrum with blue assigned to a lower value than red. Red to blue arrays the colors in a spectrum with red assigned to a lower value than blue. Two planes of the coronal CT image showing the bony lip of the oval window were selected and pseudocolor transformation was performed in the same manner. However typical variables such as the continuous zone of soft tissue or higher attenuation between the incus and stapes were excluded in this study.

Two otolaryngologists examined each image twice: plain, blue to red and red to blue transformed. They knew nothing about the history and audiometric findings for the

subjects. They were informed that the images were given from randomly selected temporal bone CTs. They compared the detectability of the stapes and IS joint using pseudocolor-transformed images with that of plain images.

Using Lemmerling's rating; scale the examination of CT images was done. For each image one of 5 scores concerning the visibility of the stapes (head of stapes, anterior & posterior crura, footplate, oval window) and IS joint (lenticular process, IS joint, crus of stapes) was given: 1-not seen, 2-probably not seen, 3-not sure, 4-probably seen, 5-definitely seen. The stapes footplate was defined as the structure that had higher attenuation than the fluid in the vestibule at the interface. The oval window was defined as the structure at the interface between the air in the tympanum and the fluid in the vestibule and the IS joint was defined as the small gap of hypoattenuation between the most medial part of the lenticular process of the incus and the most lateral part of the stapes head (Lammering et al., 1997). The determination of visualization sensitivity was done through statistical analysis using a paired t-test.

2.2 Pseudocolor transformation of otosclerotic foci

Temporal bone CT images of sixty patients were reviewed. Of them, thirty-two ears were normal and twenty-eight ears were diagnosed as otosclerosis by radiologists experienced in evaluating otosclerosis in CT images.

Two otolaryngologists with experience of 3 years independently evaluated the sixty temporal bone CT images, randomly selected in a conventional manner (gray scale). They knew nothing about the history and audiometric findings for the subjects. 1 month later, they were educated about the technique of real time pseudocolor transformation (RTPT) and reevaluated the images randomly selected using it. The sensitivity, specificity, and inter-observer agreement rate were evaluated.

The method of RTPT is as follows: The axial CT images were used. 0.6mm thickness contiguous non-overlapping sections were acquired. The CT was a BRILLIANCE TM CT 64 Slice (PHILIPS, Yerusalem, Israel). The entire middle ear was scanned. The whole scanned images were transported to Picture Archiving and Communication System (PACS). The PACS was a STARPACS 5.0.8.1 (INFINITT, Seoul, Korea)

After opening the images of a selected patient in PACS, one or two planes of the axial CT image showing the anterior portion of oval window or stapes crura were selected and the observers amplified the image twice using zoom button menu, built-in PACS. And the observers chose "T" button menu located upper tool bar and selected the "Pseudo" sub-menu, then pseudocolor mapping working window appeared. There were variable predefined pseudocolor scales in the palette menu. But, we selected the same gray-scale for the reference. Using the color mask function, we chose specific color (red color in this case) to be applied to the specific intensity range of scanned image. Moving the control bar of the "color mask" up and down between soft tissue density and bone density range, red color was dressed on the selected gray-scale intensity area (figure 1).

If observers find out the presence of focal thickenings of red color in the otic capsule, especially in FAF, oval window, and pericochlear area, then it can be diagnosed as otosclerosis. It is excluded that focal thickening at the boundary where soft tissue and bone are contiguous, because it shows false radiolucent area where soft tissue and bone are abut by the interference during scanning the image.

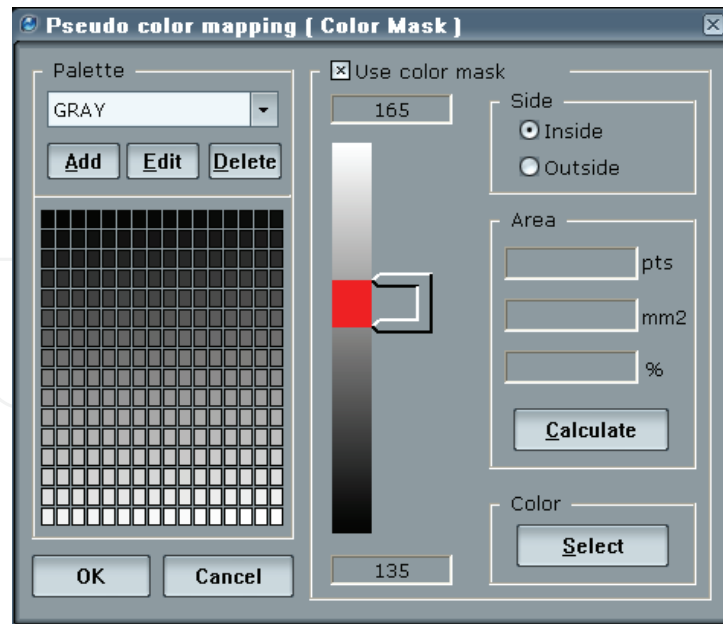


Fig. 1. Pseudocolor mapping task window showing the range of intensity to be applied by red color.

3. Results

3.1 Pseudocolor transformation of normal ossicles

The result indicated increased visibility of the stapes and IS joint in CT images after pseudocolor transformation. But, pseudo-colored images often showed slightly distorted bony structures.

Figure 2 shows an example of plain and pseudocolor-transformed images of the stapes. The footplate and oval window were more easily identifiable in the pseudocolor image compared with the plain image. In the red to blue image (b), the green-colored crura showed sharp contrast. The air in the tympanum appeared as blue, the fluid in the vestibule appeared as green to sky blue. The radiolucent area between the otic bones in the plain image was a light green color after the transformation, which was considered the area of the

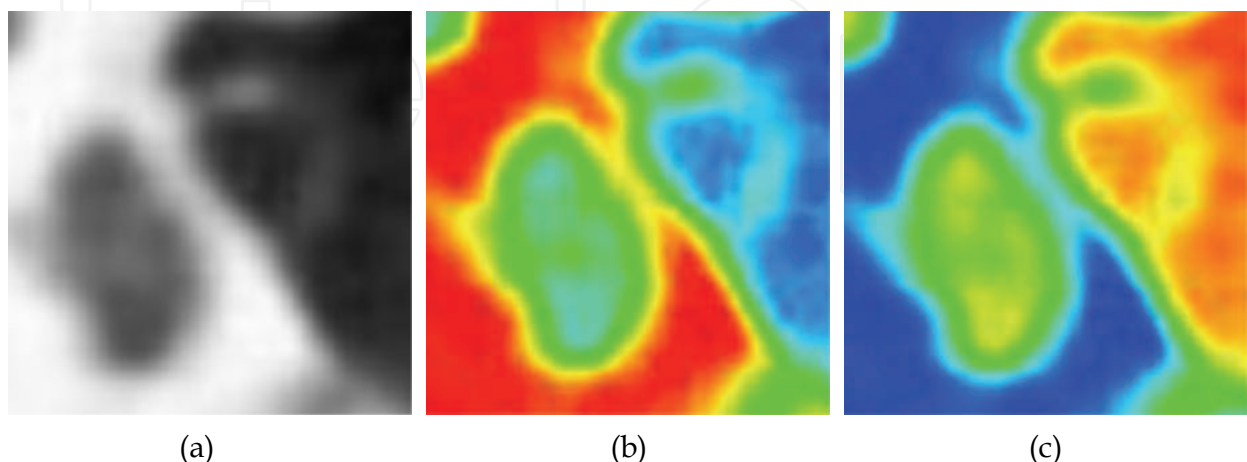


Fig. 2. Axial image of CT showing pseudocolor transformation of stapes. a) plain image b) pseudocolor transformed image (red to blue) c) pseudocolor transformed image (blue to red)

foot plate. In the blue-to-red image(c), the otic bone appeared blue. The crura of the stapes appeared thicker compared with the plain image.

Figure 3 shows an example of plain and pseudocolor-transformed images of the IS joint. The gap of hypoattenuation in the IS joint appeared to be more prominent in the pseudocolor-transformed image.

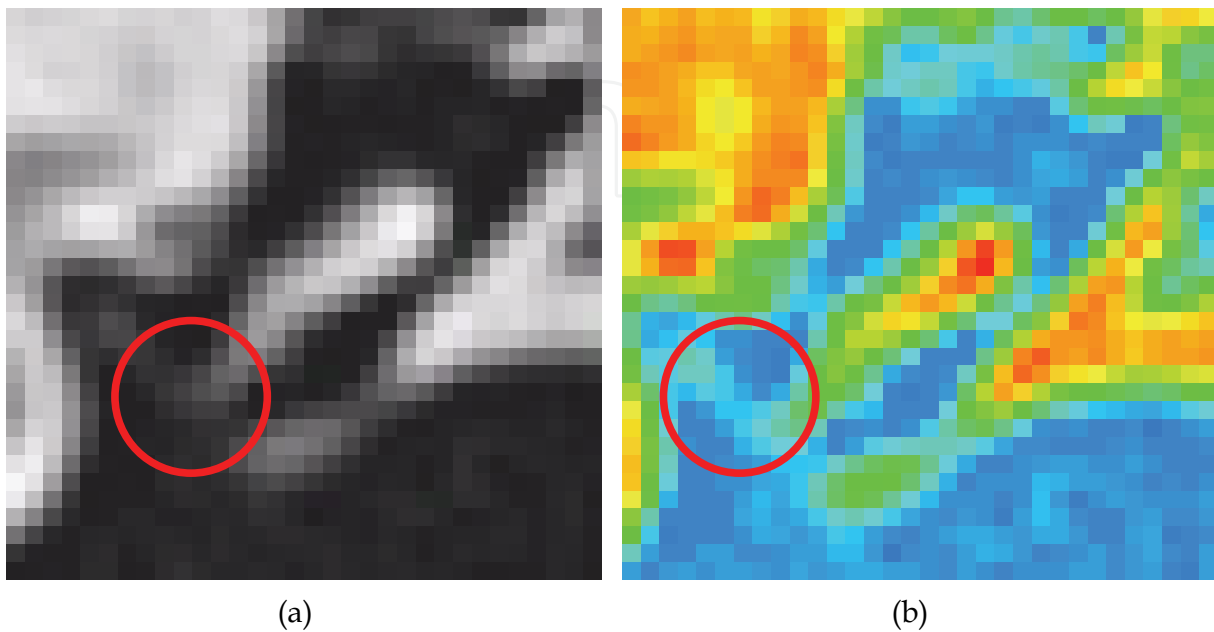


Fig. 3. Coronal image of CT showing pseudocolor transformation of incudostapedial joint. a) plain image. b) pseudocolor transformed image (red to blue). Red circles indicate incudostapedial joint.

The visibility of the stapes was increased after pseudocolor transformation. The oval window and footplate in particular were more easily distinguishable in both pseudocolor-transformed images compared with the plain images ($p < 0.05$) (Figure 4). The visualization sensitivity of the IS joint including surrounding structures was increased after pseudocolor transformation. In particular the IS joint was more easily identifiable in both pseudocolor-transformed images as compared with plain images ($p < 0.05$).

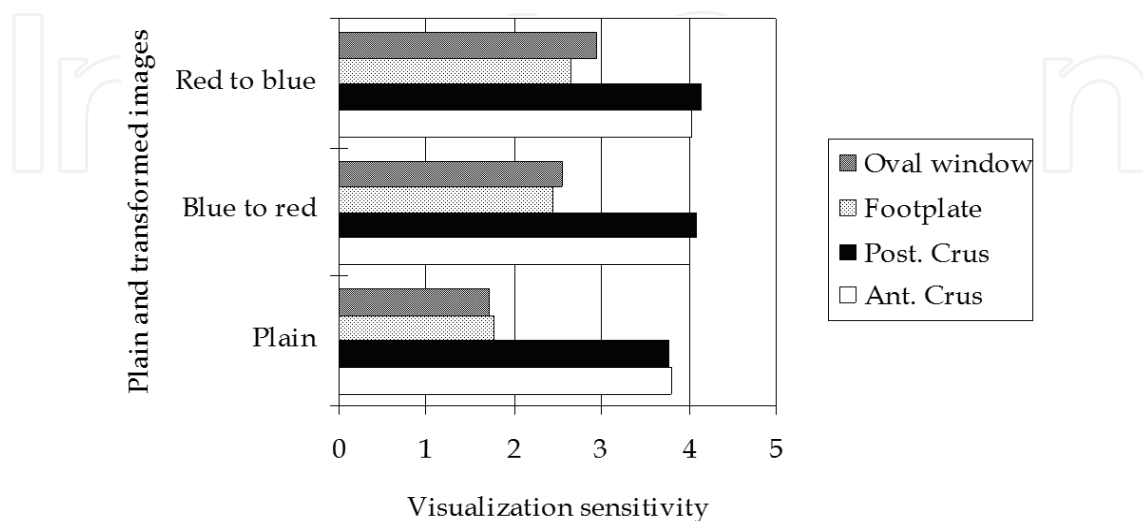
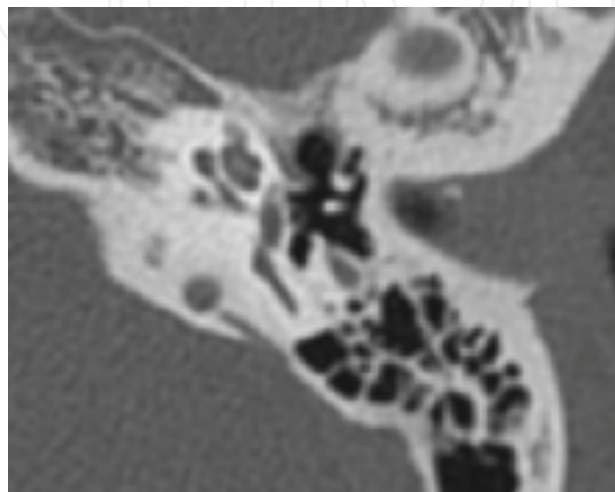


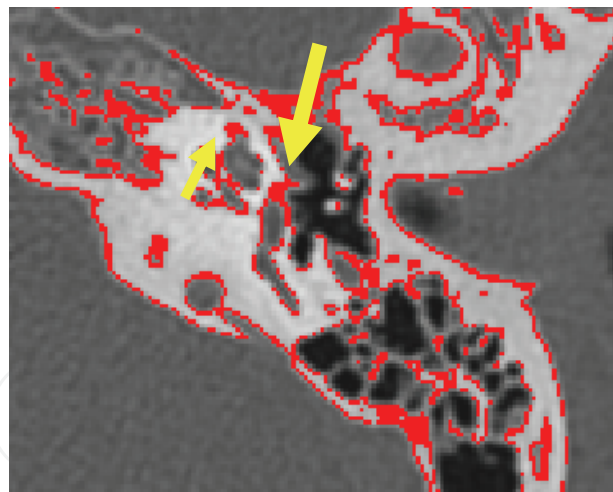
Fig. 4. Changed visibility of the stapes structures after pseudocolor transformation

3.2 Pseudocolor transformation of otosclerotic foci

The study cases consisted of 30 patients (60 ears), including 16(53.3%) women and 14(46.7%) men. Age ranged from 26 to 65 years, with a mean of 46.8 years. 15 patients were healthy and 15 patients (28 ears) were otosclerosis. Among otosclerotic patients, 13 patients had bilateral otosclerotic foci and 2 patients had unilateral foci. Distribution of otosclerotic foci consisted of fenestral(71.43%), cochlear(7.14%), and mixed type(21.43%). Figure 5 showed one CT image of otosclerosis after pseudocolor transformation.



(a)



(b)

Fig. 5. Axial image of CT showing foci of radiolucent area anterior to the oval window (yellow arrow) and the apex of cochlear (small yellow arrow). a) plain image, b) pseudocolor transformed image.

When they were classified according to the distribution of otosclerotic foci, the sensitivity was increased in fenestral and mixed type and was equal in cochlear type (Fig.6).

Inter-observer agreement rate of conventional technique and RTPT technique was similar each other. The kappa value was 0.528($p < 0.05$) in conventional technique and 0.539($p < 0.05$) in RTPT.

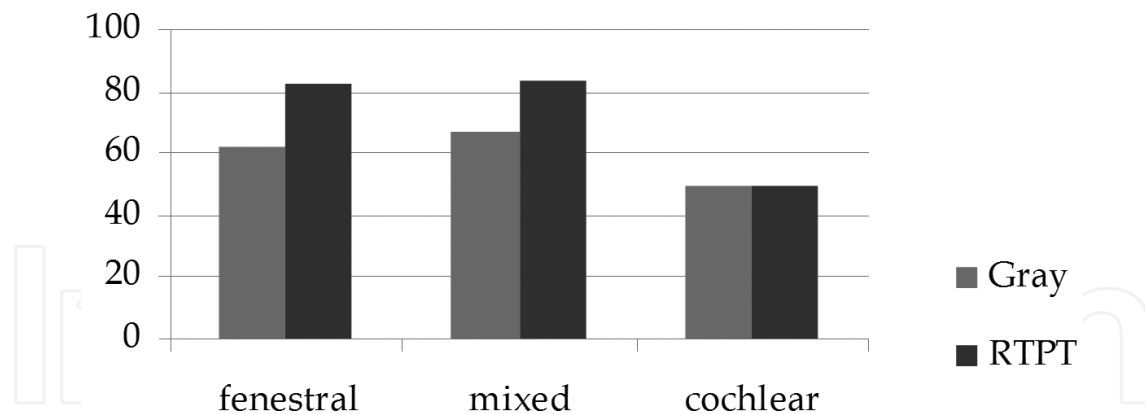


Fig. 6. Comparison of the sensitivity according to the distribution of otosclerotic foci. Increased sensitivity of fenestral and mixed type was seen when using the RTPT than conventional technique and same sensitivity of cochlear type was seen in each techniques

4. Conclusion

Nowadays, digital technology has been commonly used to transform an original image into various forms without damaging it. And the creative combinations of pseudocolor could make it possible to producing various impressive images. In our studies, a new visualization method using pseudocolor transformation was described to increase detection rate of ossicles in many CT images. And also we showed that pseudocolor transformation could be helpful for detecting ear pathology such as otosclerosis. These procedures may be performed by use of the image analyzer or PACS with real time processing.

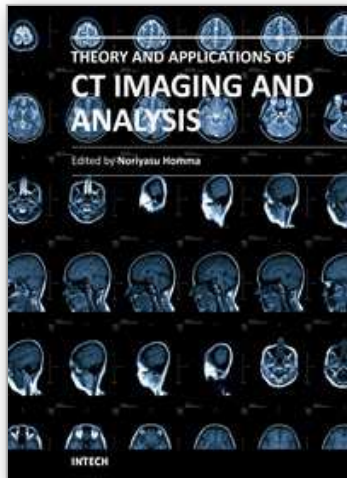
Variable color transformation can be examined for increasing detectability of CT image in the future.

5. References

- Addresss HC, Tescher AG, Kruger RP. (1972) Image processing by digital computer. *IEEE Spectrum* 9(7): 20-33.
- Brägger U, Pasquali L (1989). Color conversion of alveolar bone density changes in digital subtraction images. *J Clin Periodontol.* 16:209-14.
- Christmas DA, Mirante JP, Yanagisawa E.(1999) Rainbow scale in computer-aided sinus surgery. *Ear, Nose & Throat Journal* 78:670-2.
- Crowe EJ, Sharp PF, Undrill PE, Ross PG.(1988) Effectiveness of colour in displaying radionuclide images. *Med Biol Eng Comput.* 26:57-61.
- Huizing EH, de Groot JA.(1987) Densitometry of the cochlear capsule and correlation between bone density loss and bone conduction hearing loss in otosclerosis. *Acta Otolaryngol.* 103:464-8.
- Lemmerling MM, Stambuk HE, Mancuso AA, Antonelli PJ, Kubilis PS. (1997)Normal and opacified middle ears: CT appearance of the stapes and incudostapedial joint. *Radiology* 203:251-6.
- Park MS, Byun JY, Cha CI. (2009)Pseudocolor transformation for visualization of ossicles in CT images. *Acta Otolaryngol.* 129:515-20.

- Reddy MS, Bruch JM, Jeffcoat MK, Williams RC.(1991) Contrast enhancement as an aid to interpretation in digital subtraction radiography. *Oral Surg Oral Med Oral Pathol.* 71:763-9.
- Tamada F, Hirohata S, Honsako Y, Kumada H, Kashio Y, Konishi M, et al. (1995) Quantitative analysis of the gastric ulcer healing process using video endoscopic pseudocolor imaging systems. *J Clin Gastroenterol*; 20 (Suppl 2): 52-5.
- Tringali S, Pouget JF, Bertholon P, Dubreuil C, Martin C. (2007) Value of temporal bone density measurements in otosclerosis patients. *Ann Otol Rhinol Laryngol.* 116:195-8.

IntechOpen



Theory and Applications of CT Imaging and Analysis

Edited by Prof. Noriyasu Homma

ISBN 978-953-307-234-0

Hard cover, 290 pages

Publisher InTech

Published online 04, April, 2011

Published in print edition April, 2011

The x-ray computed tomography (CT) is well known as a useful imaging method and thus CT images have continually been used for many applications, especially in medical fields. This book discloses recent advances and new ideas in theories and applications for CT imaging and its analysis. The 16 chapters selected in this book cover not only the major topics of CT imaging and analysis in medical fields, but also some advanced applications for forensic and industrial purposes. These chapters propose state-of-the-art approaches and cutting-edge research results.

How to reference

In order to correctly reference this scholarly work, feel free to copy and paste the following:

Moon Suh Park, Jae Yong Byun, Seung Geun Yeo and Ho Yun Lee (2011). Use of Pseudocolor for Detecting Otologic Structures in CT, Theory and Applications of CT Imaging and Analysis, Prof. Noriyasu Homma (Ed.), ISBN: 978-953-307-234-0, InTech, Available from: <http://www.intechopen.com/books/theory-and-applications-of-ct-imaging-and-analysis/use-of-pseudocolor-for-detecting-otologic-structures-in-ct>

INTECH

open science | open minds

InTech Europe

University Campus STeP Ri
Slavka Krautzeka 83/A
51000 Rijeka, Croatia
Phone: +385 (51) 770 447
Fax: +385 (51) 686 166
www.intechopen.com

InTech China

Unit 405, Office Block, Hotel Equatorial Shanghai
No.65, Yan An Road (West), Shanghai, 200040, China
中国上海市延安西路65号上海国际贵都大饭店办公楼405单元
Phone: +86-21-62489820
Fax: +86-21-62489821

© 2011 The Author(s). Licensee IntechOpen. This chapter is distributed under the terms of the [Creative Commons Attribution-NonCommercial-ShareAlike-3.0 License](#), which permits use, distribution and reproduction for non-commercial purposes, provided the original is properly cited and derivative works building on this content are distributed under the same license.

IntechOpen

IntechOpen