

We are IntechOpen, the world's leading publisher of Open Access books Built by scientists, for scientists

4,800

Open access books available

122,000

International authors and editors

135M

Downloads

Our authors are among the

154

Countries delivered to

TOP 1%

most cited scientists

12.2%

Contributors from top 500 universities



WEB OF SCIENCE™

Selection of our books indexed in the Book Citation Index
in Web of Science™ Core Collection (BKCI)

Interested in publishing with us?
Contact book.department@intechopen.com

Numbers displayed above are based on latest data collected.

For more information visit www.intechopen.com



CT-Image Guided Brachytherapy

Janusz Skowronek, MD, PhD, Ass. Prof.
*Brachytherapy Department, Greater Poland Cancer Centre, Poznań
Poland*

1. Introduction

The name “Brachytherapy” is derived from ancient Greek words for short distance (*brachios*) and treatment (*therapy*) and refers to the therapeutic use of encapsulated radionuclides placed within or close to the tumor. Brachytherapy (BT), used as an integral part of cancer treatment for almost a century, developed in last three decades a rapid growth with the development of afterloading devices and the introduction of artificial radionuclides. The impressive progress of three dimensional (3D) imaging, the rapidly increasing speed and capacity of computers, and the sophisticated techniques developed for the treatment planning, opened a new era.

Brachytherapy plays a crucial role in the curative treatment of many tumors. CT and/or MRI compatible applicators allow a sectional image based approach with a better assessment of GTV (Gross Tumor Volume) and CTV (Clinical Target Volume) compared to traditional approaches. Accurate and reproducible delineation of GTV and CTV, as well as healthy (critical) organs, has a direct impact on treatment planning, especially it is possible to optimize the reference isodoses to the target.

A two-film typical localization technique does not allow the definition of the three-dimensional (3D) extensions of the planning target volume (PTV) and organs at risk (OARs). Furthermore, using traditional dosimetry systems the dose report is related to the geometry of the implant and not to the target volume. In modern BT both treatment planning and plan evaluation have to be based on real 3D volume of the PTV and OARs.

2. Rationale for CT- Image Guided Brachytherapy

Utilization of 3D sectional imaging in brachytherapy (BT) planning of different tumor sites allows for a clinically meaningful dose escalation in the target, while respecting normal tissue tolerance. 3D treatment planning has made promising progress in the last decade of radiotherapy. Currently, the conformal 3D external beam radiation therapy (EBRT) is the permanent part of routine clinical work in most of the radiotherapy departments. Moreover, the 3D brachytherapy treatment planning has just become the center of interest.

As far as the method of sectional imaging is concerned, there are some important advantages afforded by CT compared to other imaging modalities (Barrett et al., 2009). CT scanning provides detailed cross-sectional anatomy of the normal organs, as well as 3D tumor information. These images provide density data for radiation dose calculations by conversion of CT Hounsfield units into relative electron densities using calibration curves. Compton scattering is the main process of tissue interaction for megavoltage beams and is

directly proportional to electron density. Hence CT provides ideal density information for dose corrections for tissue inhomogeneity, such as occurs in lung tissue. Clinical studies have shown that 30%-80% of patients undergoing radiotherapy benefit from the increased accuracy of target volume delineation with CT scanning compared with conventional simulation. It has been estimated that the use of CT improves overall 5-year survival rates by around 3.5%, with the greatest impact on small volume treatments (Barrett et al., 2009).

CT scans taken for brachytherapy treatment planning usually differ from those taken for diagnostic use. Ideally, planning CT scans are taken on a dedicated brachytherapy CT scanner by a therapy trained radiographer. Protocols for CT scanning are developed with the radiologist to optimize tumor information, to ensure full body contour in the reconstruction circle and scanning of relevant whole organs for DVHs. CT scans are transferred digitally to the target volume localization console using an electronic network system. The CTV, PTV, body contour and normal organs (OARs) are outlined by a team of radiation oncologist and physicist (Barrett et al., 2009).

The rationale behind CT guidance in BT is twofold: (1) to assure an optimal position of BT catheters within the target volume by controlling their insertion and (2) to assist the process of detection and contouring of the target volume and organs at risk (OARs). CT guidance of insertion can be accomplished preoperatively or during an intraoperative procedure. Standard preoperative strategy is based on integration of initial CT findings and clinical and/or ultrasound findings at BT. CT-guided treatment planning is in this case most commonly performed only after the procedure, limiting the ability to correct an eventually suboptimal implantation. Obtaining an additional pre-planning CT just a few days before the application can facilitate the ability for an accurate insertion. An overview of the current approaches in CT guided BT is presented in this chapter.

One of the best approaches for CT-guided brachytherapy was made by Kolotas and al. (Kolotas et al., 1999). They described development of a CT-based brachytherapy catheter application and treatment planning procedure which is focused on anatomy (PTV and healthy tissues) based optimization, and with evaluation using the conformal index COIN of the 3D dose distribution. The clinical feasibility of this new method, which is essentially a new philosophy in the practice of interstitial brachytherapy, has been proved for several tumor sites (Kolotas et al., 1999). Catheter implantation using CT imaging is first performed to localize the tumor and the surrounding critical tissues. Then, CT-guided catheter implantation is performed in the CT room and, if necessary, contrast enhanced, cross-sectional images are made. This imaging procedure determines the choice of the application technique including the type of catheters to be used. Aluminum skin markers and painting can also be used for this localization procedure. The CT table top drive mechanism and the markers are then used to navigate between the CT slices and the patient. In cases where a template can be used this offers an additional navigation possibility for catheter insertion through the numbered holes of the template which are also visible on the CT slices. Based on the pre-implantation imaging and clinical information, and after local anesthesia and sedation, catheter insertion is commenced with the patient remaining on the CT table. The maximum insertion depth and direction as well as position (in case of template the whole number) of the catheter can be estimated from the CT information. This information is displayed on a monitor within the CT room and therefore is immediately available to the physician. This is a real advantage for the physician when implanting the catheters since this provides rapid and effective control of catheter position and geometry and ensures avoidance of injuries to neighboring critical structures. Control of the position of an inserted

catheter is achieved by taking CT images with the catheters in situ, and then if necessary correcting the catheter position. This procedure is repeated until all catheters needed to cover the tumor volume have been implanted. After reconstruction of catheters all the graphical information, including body contour, PTV, critical structures and catheters are displayed in a 3D view window. The 3D view is fully scalable and can be rotated. For simplification in an individual patient, the user can select the graphical elements needed to be viewed in 3D, using simple button menus, and exclude all others that may be confusing. The 3D window is extremely useful for real time monitoring of the reconstruction of catheters. It also offers an efficient method of viewing the position of critical organs by reference to the PTV and to the catheters (Kolotas et al., 1999).

3. Gynecological tumors

In gynecological tumors image-guided 3D conformal BT planning postimplant CT images are useful to control and report the dose to treated volume and OARs (e.g. for rectum, sigmoid, and bladder). This allows better assessment of dose distributions in different volumes, such as the gross tumor volume (GTV), clinical target volume (CTV), and OARs. Clinical target volume (CTV), bladder volume, rectum volume, sigmoid colon, and small bowel should be delineated on CT images. Advantages of 3D imaging in gynecologic brachytherapy that may lead to improved patient outcome, irrespective of the dose rate, include avoiding or early detection of a uterine perforation, ensuring target coverage, and avoiding excessive dose to the OAR. Disadvantages include an increased amount of physician and physicist time to coordinate imaging and incorporate this into treatment planning, as well as the need for additional training to gain familiarity with the contouring methodology (Viswanathan & Erickson, 2010). For post-implantation imaging, the advantages of 3D imaging with either CT or MRI include clear target definition as well as better localization and target delineation of the OARs. With MRI, one may contour residual cervical tumor. With CT, one visualizes the cervix and parametrium as one structure, resulting in potential overcontouring of the lateral aspect of the volume (Viswanathan et al., 2007) Nevertheless, CT allows visualization of tumor that may lie beyond Point A, thereby ensuring adequate dosing of the target volume (Viswanathan & Erickson, 2010).

To unify 3D plan evaluation concepts and to provide a common set of terms to be used, Gynecologic (GYN) GEC-ESTRO Working Group (GEC-ESTRO) published guidelines on 3D image-based treatment planning in cervical cancer brachytherapy (Haie-Meder et al., 2005; Pötter et al., 2006).

One of the first reports describing the volumetric dose distributions from BT was published in 1987 (Ling et al., 1987). Since the 1990s, widespread implementation of CT simulation for EBRT treatment planning in radiation oncology departments has enabled physicians to contour and perform dose volume histogram (DVH) analysis of the OARs. Several centers have published results with CT simulation or MRI based gynecologic brachytherapy. To standardize some aspects of nomenclature, the American Brachytherapy Society (ABS) published guidelines for image-guided gynecologic brachytherapy in 2004 (Nag et al., 2004). Viswanathan and Erickson in their recently published (2010) paper determined current practice patterns with regard to three-dimensional (3D) imaging for gynecologic brachytherapy among American Brachytherapy Society (ABS) members. Material was based on a 19-item survey sent to physicians from ABS. The results show that after insertion, 70% of physicians routinely obtain a computed tomography (CT) scan. The majority (55%) use

CT rather than X-ray films (43%) or magnetic resonance imaging (MRI; 2%) for dose specification to the cervix. However, 76% prescribe to Point A alone instead of using a 3D-derived tumor volume (14%), both Point A and tumor volume (7%), or mg/h (3%). Those using 3D imaging routinely contour the bladder and rectum (94%), sigmoid (45%), small bowel (38%), and/or urethra (8%) and calculate normal tissue dose-volume histogram (DVH) analysis parameters including the D_{2cc} (49%), D_{1cc} (36%), $D_{0.1cc}$ (19%), and/or D_{5cc} (19%). Authors concluded that more ABS physician members use CT post-implantation imaging than plain films for visualizing the gynecologic brachytherapy applicators. However, the majority prescribes to Point A rather than using 3D image based dosimetry (Viswanathan & Erickson, 2010).

Another authors concluded that calculating dose-volume histograms (DVHs) using 3D-based volumetric planning may provide a more accurate evaluation of the dose to the target volume and OARs (Al-Halabi et al., 2010). In addition, better imaging of the target and OARs allows for a more precise delineation of the target volume and OARs and, consequently, a better assessment of the dose delivered to these structures (Nag et al., 2004). Studies of CT-based 3D brachytherapy planning have shown that the ICRU-defined bladder and rectum doses in fact underestimate the true maximal doses to these organs.

Hellebust et al. recently published recommendations from gynaecological (GYN) GEC-ESTRO Working Group including considerations and pitfalls in commissioning and applicator reconstruction in 3D image-based treatment planning (Hellebust et al., 2010). The aim of these guidelines was to unify 3D plan evaluation concepts and to provide a common set of terms to be used. They concluded that image-guided brachytherapy in cervical cancer is increasingly replacing X-ray based dose planning. In image-guided brachytherapy the geometry of the applicator is extracted from the patient 3D images and introduced into the treatment planning system; a process referred to as applicator reconstruction. Due to the steep brachytherapy dose gradients, reconstruction errors can lead to major dose deviations in target and organs at risk. Appropriate applicator commissioning and reconstruction methods must be implemented in order to minimize uncertainties and to avoid accidental errors. Applicator commissioning verifies the location of source positions in relation to the applicator by using auto-radiography and imaging. Sectional imaging can be utilized in the process, with CT imaging being the optimal modality. The importance of proper commissioning is underlined by the fact that errors in library files result in systematic errors for clinical treatment plans (Hellebust et al., 2010). The next step, reconstruction of the applicator, can be performed by different methods: library plans (LIB), direct reconstruction (DR) or a combination of these two methods. Applicator reconstruction using CT images offers the good visualisation of the lumen of the applicator and this means that a markerstring is not always necessary. Authors indicate some X-ray catheters may produce artifacts in the CT images resulting in larger uncertainties in the reconstruction and contouring process. Slice thickness ≤ 3 mm is recommended to give the best visualization. The lumen of the ring will be visible in several slices, e.g. 3–4 images for 3 mm slice thickness. In order to visualize the ring in one image a multiplanar reconstructed image through the ring can be used. The reconstructed image can be used during direct reconstruction or for positioning of a library applicator (Hellebust et al., 2010). In another paper similar authors analyzed the impact of the applicator orientation and the reconstruction method used on the calculated dose around a reconstructed ring applicator set using CT imaging (Hellebust et al., 2007). Their results showed that it was not possible to identify one applicator orientation that gave lower uncertainties with regard to the

calculated dose around the applicator. However, all orientations and all reconstruction methods resulted in limited variation in calculated dose, i.e. both LIB and DR are feasible for applicator reconstruction in CT images. With CT-based reconstruction the visibility of the applicator is usually excellent and it has been shown that the dose variation between different CT reconstruction methods is limited - below 4% (1 standard deviation) in clinically relevant dose points (Hellebust et al., 2010).

Davidson et al. analyzed whether customized 3D plans generated for the first insertion (using CT planning) can be applied to subsequent insertions without significant changes in dose distributions if identical applicators are used (Davidson et al., 2008). They concluded that a duplication of planned dwell times and positions from one insertion to the next does not duplicate dose distributions in HDR cervix applications. A single plan used for an entire course of BT can result in significant increases to OAR doses for tandem and ring (TR) and unpredictable OAR doses for tandem and ovoids (TO) applicators. Treatment plans should be tailored for each insertion to reflect current applicator and anatomical geometry. They emphasized also that ideally, 3D imaging with MRI should be performed after each BT implantation for individual treatment planning of each HDR fraction. This is, unfortunately, not possible for many radiotherapy departments due to limited MRI resources. In cases where MRI is unavailable for BT planning, CT may be a more accessible alternative. Although CT does not provide a clear clinical target volume for BT planning due to poorer soft-tissue contrast than MRI, it can identify surrounding OARs and define dose distributions in 3D. This allows for the determination of problematic volumetric doses to OAR and instances where dose shapes should be altered to reduce the risk of complications (Davidson et al., 2008).

Another authors investigated two-dimensional (2D) radiograph-based plans using 3D dose-volume histogram (DVH) parameters following guidelines from Gynecologic GEC-ESTRO Working Group (Gao et al., 2010). Clinical target volume (CTV), bladder volume, rectum volume, sigmoid colon, and small bowel were delineated on CT images. CTV included the whole cervical mass visualized as aided by implanted marker seeds. DVHs were calculated for these structures. 3D plan evaluation parameters recommended by GYN-GEC-ESTRO guidelines (Pötter et al., 2006) were adopted. CTV coverage was evaluated using D100, D90, and V100 (i.e., dose covering 100% of the volume, dose covering 90% of the volume, and volume covered by 100% of prescription dose). High dose volume in CTV was estimated using V200. For organs at risk (OARs), D0.1_{cc}, D1_{cc}, and D2_{cc} (i.e., minimum dose received by 0.1-, 1-, and 2-cm³ tissue volume) were calculated. In conclusions we can read that the DVH analysis of 2D plans revealed a suboptimal coverage of CT-based cervix and a negative correlation between coverage and cervical size. Rectum dose to 2 cc weakly correlated with ICRU point dose. Currently published constraints for bladder in 3D planning were tighter than ABS guidelines in past 2D planning.

Shin et al. compared the conventional point A plan (conventional plan) and computed tomography (CT)-guided clinical target volume-based plan (CTV plan) by analysis of the quantitative dose-volume parameters and irradiated volumes of organs at risk in patients with cervical cancer (Shin et al., 2006). In 30 plans CT images were acquired at the first intracavitary radiotherapy (ICR) session with artifact-free applicators in place. The gross tumor volume, clinical target volume (CTV), point A, and International Commission on Radiation Units and Measurements (ICRU) Report 38 rectal and bladder points were defined on reconstructed CT images. They concluded that the results have shown that CT-guided CTV planning of ICR is superior to conventional point A planning in terms of both

conformity of target coverage and avoidance of overdosed normal tissue volumes (Shin et al., 2006).

In another paper Wang et al. evaluated and reported volumetric dose specification of clinical target volume (CTV) and organs at risk with three-dimensional CT-based brachytherapy. They analyzed CTV volumes and correlated the dose specification from CT-based volumes with doses at classical point A and International Commission on Radiation Units and Measurements (ICRU) points (Wang et al., 2009). Their main conclusion was that excellent dose coverage of CTV can be achieved with image-guided CT-based planning with geometric optimization although maximal sparing of rectum was not achieved. Careful dose constraints and standardization of D90 should be considered when optimizing doses to target tissues such that normal tissue constraints can be met (Wang et al., 2009).

These several studies have shown that traditional ICRU reference points underestimate dose to normal organs when compared to CT-based 3-dimensional (3D) imaging. On figure 1 example of typical 3D treatment plan in cervical cancer is presented.

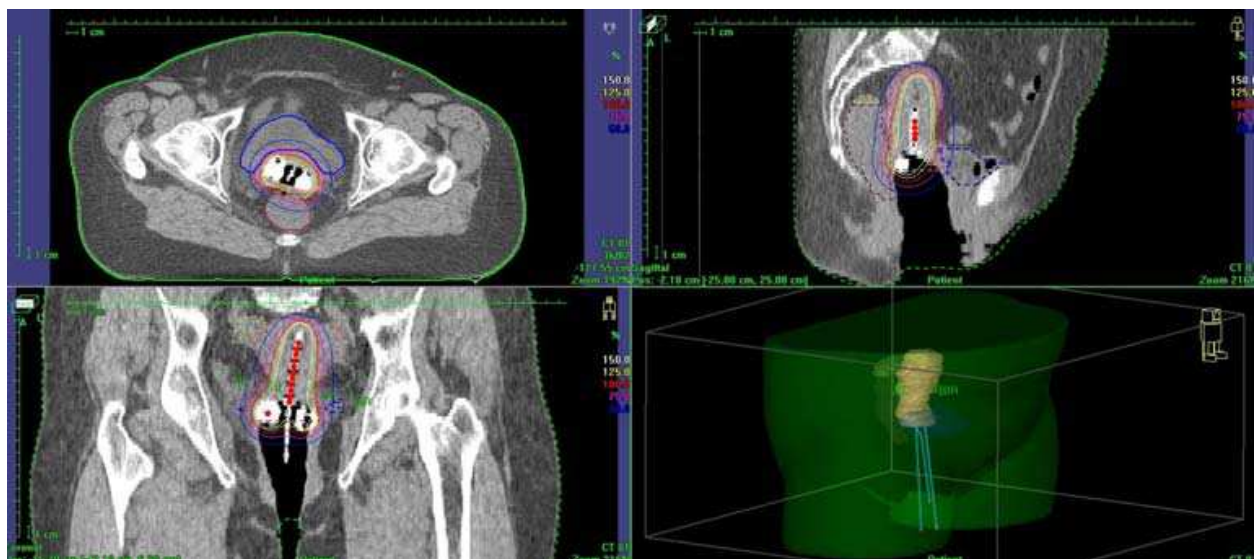

Fig. 1. Cervical cancer - reconstruction of plastic applicator in a 3D CT study. Plastic catheters - intrauterine tube and ovoids are inserted into vaginal vaults and uterus. (a) Para-transverse image at the level of the ovoids, (b) Para-coronal image and (c) Para-sagittal image with a reconstructed tube and ovoids. On (d) 3D-visualisation of application is presented.

4. Prostate cancer

Real-time rectal ultrasonography (US) guidance has been accepted as a standard technique for prostate BT. However, post-implant CT (and MRI) imaging have also been implemented for 3D treatment planning for temporary HDR implants and for the verification of postimplant dose distribution of permanent seed implants. Paper published by Merrick et al. investigated the magnitude of the effect that various methods of treatment volume delineation have on dosimetric quality parameters for a treatment planning philosophy that defines a target volume as the prostate with a periprostatic margin. They noticed that postoperative computed tomography (CT) based dosimetric analysis provides detailed information regarding the coverage and the uniformity of an implant. CT-based

postoperative dosimetric analysis provides detailed information regarding the dose distribution to the prostate/periprostatic region, urethra, and rectum (Wallner et al., 1995; Willins & Wallner, 1997; Merrick et al., 1998; Prestidge et al., 1998; Merrick et al., 1999).

Prestidge et al., 1998 found that the majority of institutions performing postimplant assessment employ CT scans, although MRI has also recently been described for this purpose. Typically, scans are taken at 3–5-mm slice intervals from the base to the apex of the gland. The brachytherapist is then asked to outline the prostate on the film of each axial slice on which it is identified. Accurately discerning the prostate from the rectal wall, levator ani musculature, periprostatic venous plexus, preprostatic fat, seminal vesicles, and urethral sphincter requires some experience.

American Brachytherapy Society guidelines for postimplant dosimetric analysis recommend CT-based imaging (Nag et al., 2000). This represents a dramatic improvement over prior postimplant dosimetric methods. The weakness of this method is poor definition of prostate volume by CT imaging relative to MRI or ultrasound imaging (Roach et al., 1996). This is especially true in the postimplant state, when significant anatomical distortion is present due to implanted radioactive sources (seeds) and edema. MRI imaging by pelvic coil or rectal coil provides greater definition of the prostate volume postimplant. Ideally, this clarity of the prostate volume could be combined with the clarity of seed definition by CT to allow improved postimplant dosimetry. Another reason for CT-imaging is assessment of edema associated with ^{125}I or ^{103}Pd prostate brachytherapy and its impact on post-implant dosimetry (Waterman et al., 1998). Pelvic CT scanning is used to determine the necessity of preoperative evaluation of pubic arch interference in patients with small prostate volumes. Bellon et al. concluded that the degree of pubic arch interference is highly variable from one patient to the next and the TRUS volume cannot reliably predict patients who do or do not need a pelvic CT to detect potential arch interference (Bellon et al., 1999).

Another authors compared real-time intraoperative ultrasound-based dosimetry with postoperative computed tomography-based dosimetry for prostate brachytherapy (Nag et al., 2008). Although dosimetry using intraoperative US-based planning provides preliminary real-time information, it does not accurately reflect the postoperative CT-based dosimetry. Until studies have determined whether US-based dosimetry or postoperative CT-based dosimetry can better predict patient outcomes, the American Brachytherapy Society recommendation of CT-based postimplant dosimetry should remain the standard of care (Nag et al., 2008).

An interesting conclusion drew Al-Qaisieh et al. They analyzed computed tomography (CT)-based dosimetry performed to evaluate the variability of different observers' judgements in marking the prostate gland on CT films, and its effect on the parameters that characterize the prostate implantation quality. They observed that the evaluation of prostate gland volume on CT films varies between different observers. This has an effect on the dosimetric indices that characterize the implant quality in particular the D90 (Al-Qaisieh et al., 2002).

CT-imaging is also useful in HDR brachytherapy of prostate cancer. Mullokandov & Gejerman investigated the constancy of catheter position and its impact on dose distribution using serial dosimetric CT scans. During initial CT treatment planning, transverse images of the implant volume were collected, and all structures were digitized into the Planning System. They concluded that interstitial catheters did not slip within the template and were not caudally displaced independently but rather in conjunction with the template (Mullokandov & Gejerman, 2004).

Figure 2 presents example of CT-dosimetry after permanent implants application in Greater Poland Cancer Centre.

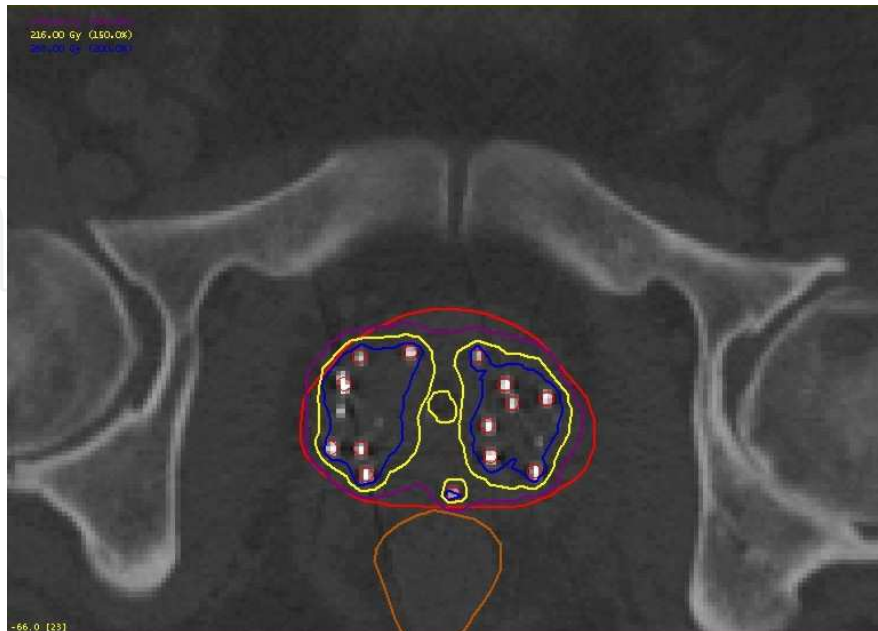


Fig. 2. Prostate cancer – Scan made on next day after permanent seeds implantation. Example of CT-dosimetry after application in Greater Poland Cancer Centre. Prostate is underlined with red line, violet line presents the 100% isodose, yellow line – 150% and blue – 200%, respectively. Urethra (yellow in the middle of prostate) and rectum (brown line) are marked too. Seeds are clearly visible.

5. Breast cancer

Today the availability of modern diagnostic imaging facilities allows to detect early stage of breast cancer, what along with the integration of sophisticated RT techniques, the Breast Conserving Therapy (BCT) makes widely accepted an alternative to mastectomy in the management of early breast cancer (Gerbaulet et al., 2002). The main purpose of radiation in BCT is to prevent any local recurrence without effecting cosmetic outcome (Van Limbergen et al., 1987). Conventionally RT in the BCT includes Whole Breast Radiation Therapy (WBRT) that is usually delivered by tangential beams. A supplementary tumor bed boost dose of 10-20 Gy (either through electrons, photons or an interstitial implants) is added to decrease the rate of local recurrence. The use of BT as additional irradiation to the tumor site with early stage breast cancer has increased significantly over the past several years (Polgar et al., 2002). The big advantage of BT above external beam radiotherapy (EBRT) results in much smaller and more conformal irradiation to the target volume due to the rapid dose fall-off (Frazier et al., 2001; Hammer et al., 2009). Nowadays the indication of the boost after BCT and selection of proper technique in order to deliver extra dose, should be depending on clinical and morphologic criteria as well as patient agreement. At present there are several techniques used in maintaining better coverage of the target volume. However, the irregular 3-D shape of the excision cavity and the normal tissue structures can only be accurately localized by visual information acquired from cross-sectional imaging (Kubaszewska et al., 2008). The use of surgical clips and CT at the same time seems to be the

best method to determine the target volume, since both titanium clips and borders of the excision cavity can be visualized exactly from slice to slice (Polgar et al., 2000). CT scan with visible clips is presented in figure 3a, the target volume is then outlined (figure 3b).

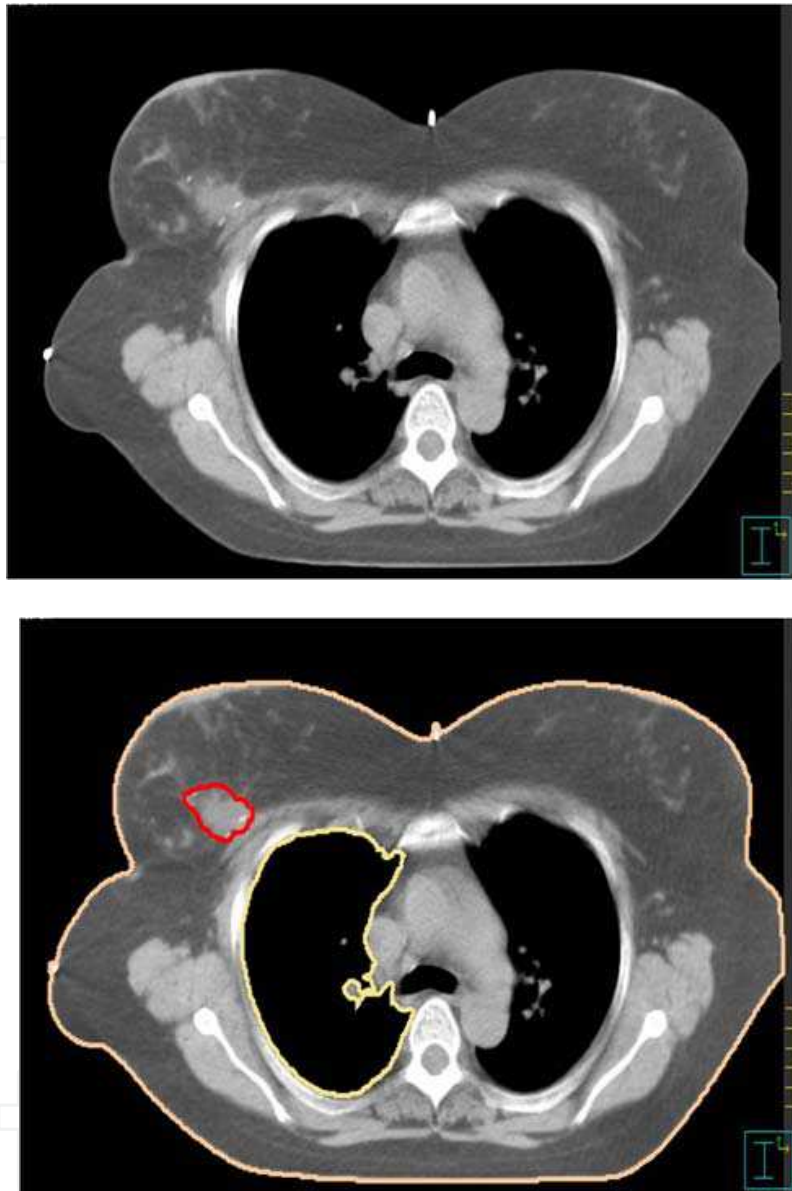


Fig. 3. Breast cancer - (a) CT scan after breast conserving surgery before catheter implantation. Visible three clips, (b) the target (tumor bed) volume (red line), lung and skin (OARs) are outlined.

CT based treatment boost planning - target volume delineation

Every individual case of BT target volume is based on combined information from the pathologic evaluation (factors considered included excision specimen size, tumor location within the resected specimen, characteristic of surgical margins, histological type) mammographic and ultrasound findings, clinical examination (scar position, size and location of any palpable seroma), localization of surgical clips, as well as CT pre-implant cross-sectional imaging (both exact visibility of titanium clips and borders of the slice to slice

excision cavity). An intraoperative implantation demands good collaboration and time management between the surgeons and radiation oncologists. The majority of authors suggested the best orientation given by titanium clips marker that are implanted intraoperatively (Hammer et al., 1999; Polgar et al., 2000). Placing of 6 clips into the walls of the excision cavity according to latero - medial, antero - posterior, inferior and superior dimensions seem to be the ideal approach. However, the titanium clips do not alter the dose distribution during RT and the quality of diagnostic MR images after the procedure. The irregular 3 dimensional (3D) shape of the target volume and the normal tissue structures can only be correctly localized on the basis of visual information obtained from cross-sectional CT-imaging. In addition to this, better local control rate with fewer side effects might be achieved with this technique based on CT-imaging (Polgar et al., 2000). The combined use of surgical clips and CT or MRI appear to be the best method to determine the target volume, since both titanium clips and borders of the excision cavity can be visualized exactly from slice to slice. Vicini et al. implemented 3D virtual brachytherapy based on two sets (pre- and postimplant) of CT scans. In their researches, the 3D BT showed excellent agreement in target volume coverage between the preplanned virtual implant geometry and the actual positioning of the final afterloading needles (Vicini et al., 1998).

CT based treatment planning procedure

The advantages of conformal brachytherapy boost treatment planning in the management of breast cancer are as follow: 1. as a useful tool helps to avoid geographical miss, 2. the irregular 3D shape of the target volume and the normal tissue structures can only be localized correctly on the basis of visual information obtained from cross-sectional CT-imaging (better local control rate with less side effects might be achieved with these technique based on CT-imaging), 3. the primary role of the treatment planning and dose optimization for a given implantation is to achieve as best coverage of the target volume as possible (the adequate homogeneity is relatively important) 4. verification of the positioning of the plastic tubes with the use of CT unit (Vicini et al., 1997). With CT-based planning, the distances between implant tubes and overlying skin and underlying ribs are directly visible and measurable. The skin dose should not exceed 60% of prescribed dose (executed only in case of a superficial plane implanted at least 10 mm from the skin).

In the 3D treatment planning based on CT sectional-cross the main aspect is to achieve such dose distribution, where all surgical clips would receive at least 85 % of the prescribed dose (Kubaszewska et al., 2008). Planning concepts are based on the 3D reconstruction of the catheters, tumor bed clips maintaining proper distances (at least 10 mm) from critical structures (skin, ribs). The clinical target volume (CTV) is defined by a margin of 2 cm breast tissue of the primary tumor, since this area contains 80% of the microscopic tumor extensions. The planning target volume (PTV) is comparable to the CTV for the reason that extra margin added in case of organ motion or set-up errors is not required in interstitial BT. The CTV of boost irradiation is not focused on such critical structures like ribs and breast skin with tissues beyond the fascia such as thoracic wall muscle. The minimum distance from the PTV to skin and underling ribs should be 10 mm. This helps to define the dimensions of the boost volume, as well as the choice between electron beam boost and interstitial implants. Some examples of 3-D treatment plans are presented in Figures 4-8. The active source positions, dwell times and reference dose points are defined individually in each catheter as well as dose optimization. To avoid skin and rib injury, the most peripheral

active source positions are kept at a minimum of 10 mm distance from the skin and rib surface (Kubaszewska et al., 2008).

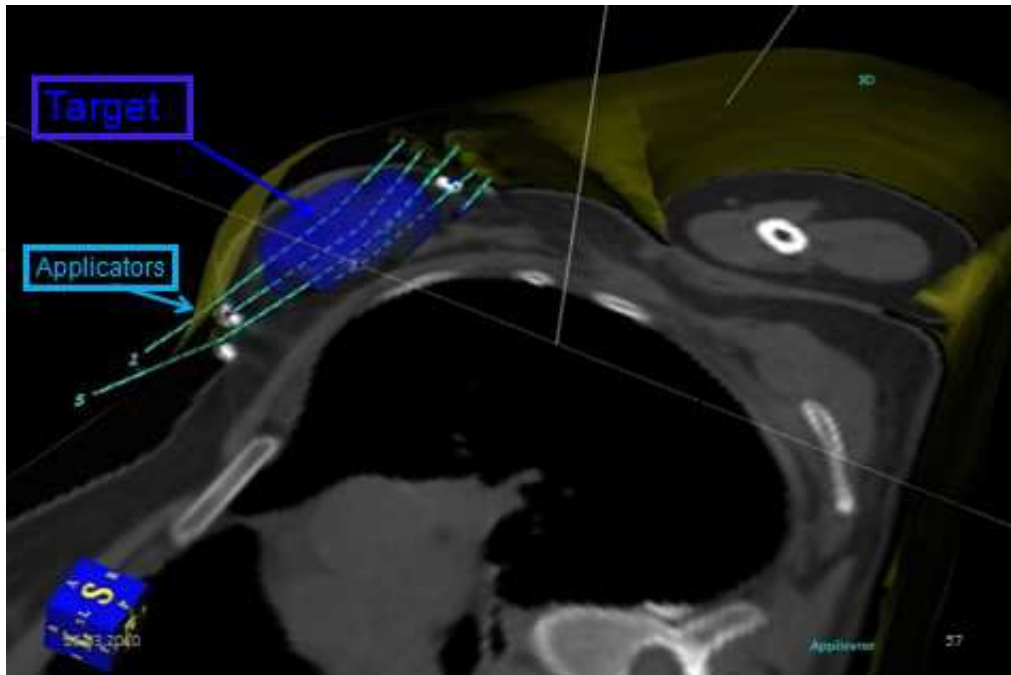


Fig. 4. Breast cancer – CT-based 3D image of Oncentra Planning System® (Nucletron), with target and applicators.

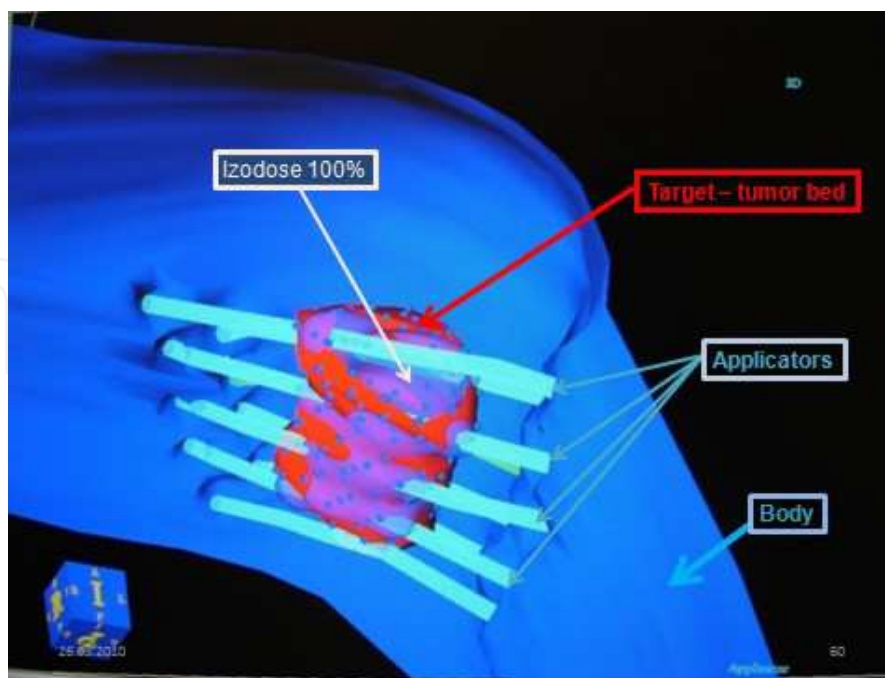


Fig. 5. Breast cancer – CT-based 3D image showing target, applicators and coverage of 100% isodose of target.

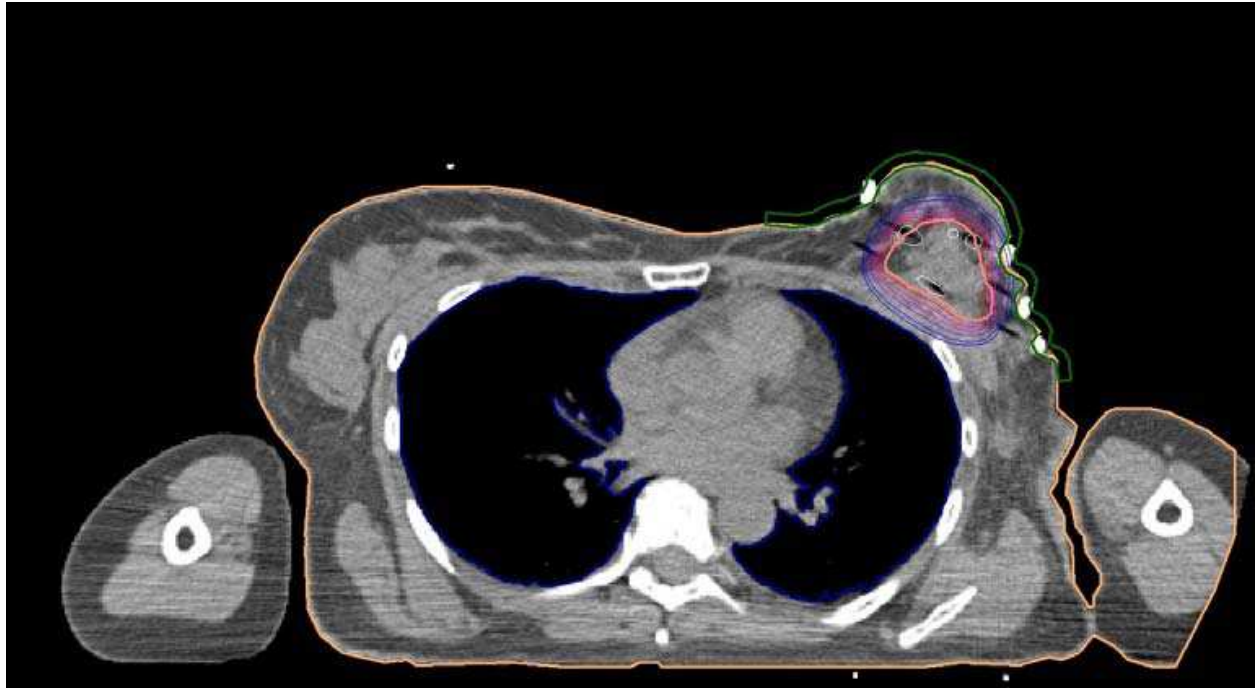


Fig. 6. Breast cancer – Transverse CT scan with final plan – different isodoses allow to assess value of dose in tumor bed (target) lung, skin and other tissues.

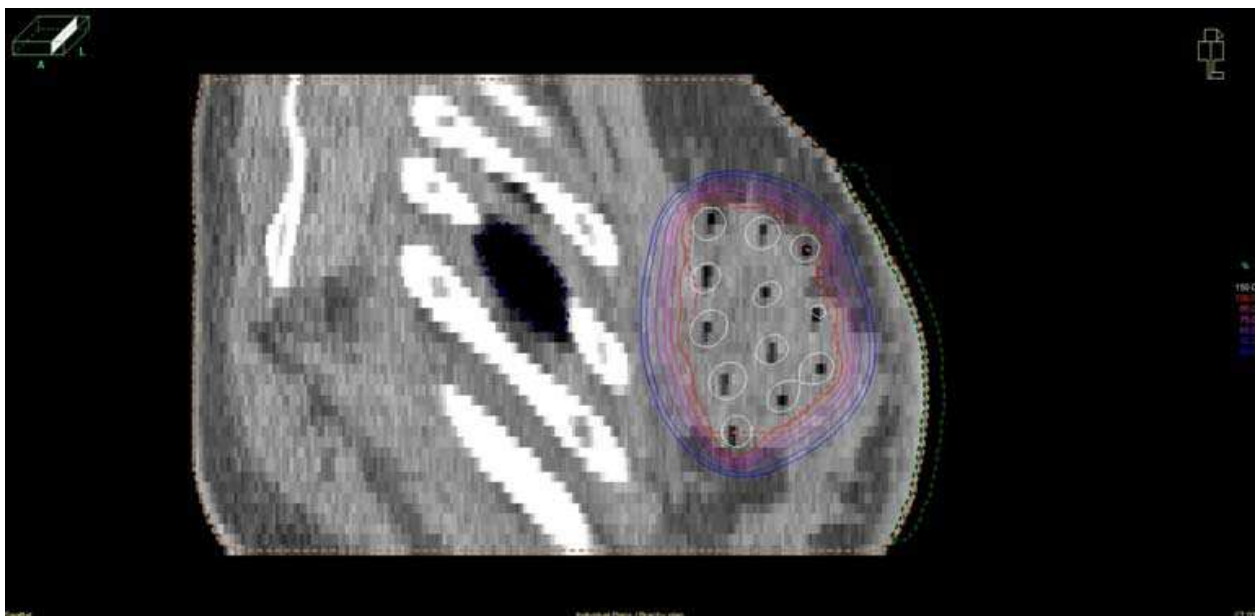


Fig. 7. Breast cancer – Saggital CT scan makes possible assessment of distance from ribs (white structures) and applicators, also from skin to applicators. Values of isodoses are visible.

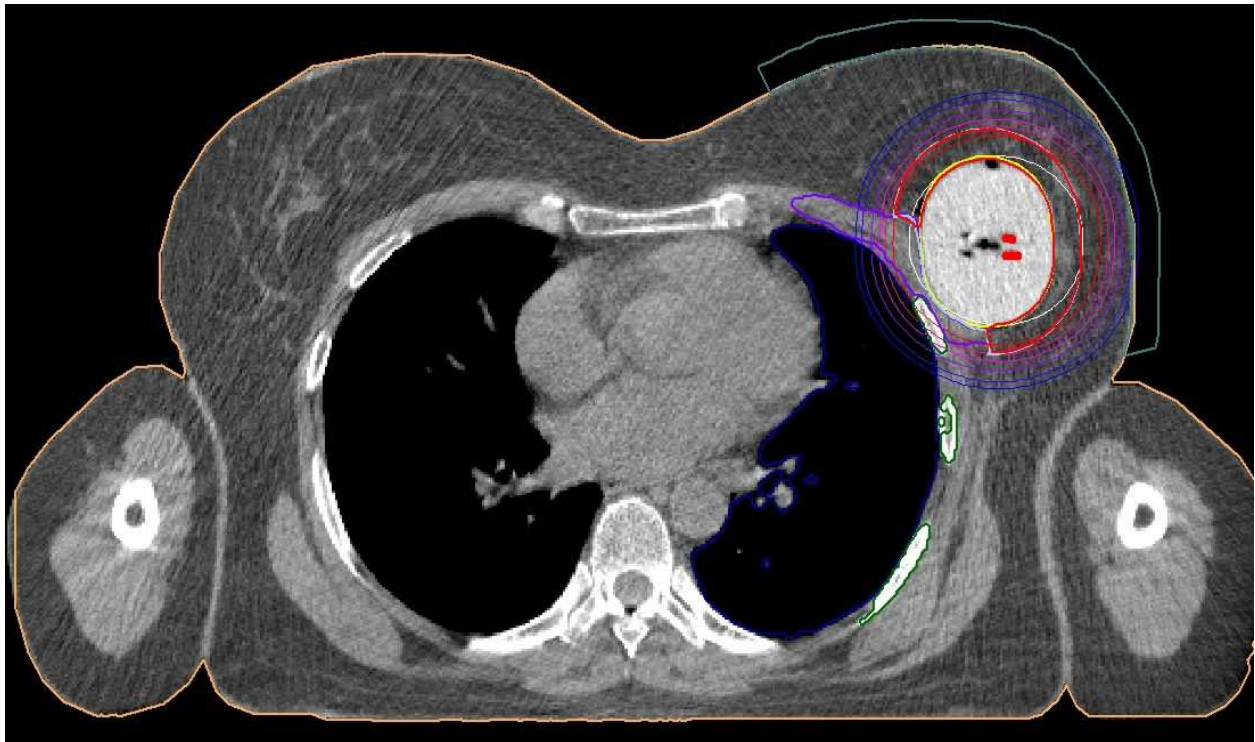


Fig. 8. Breast cancer – Transverse CT scan of Contura® application. Final treatment plan. CT makes possible visualisation of all 5 catheteres within Contura balloon, assessment of isodoses in CTV, lung and skin (OARs).

Polgar et al. compared the conventional 2D, the simulator-guided semi 3D and the recently developed CT-guided 3D brachytherapy treatment planning in the interstitial radiotherapy of breast cancer. With the help of conformal semi 3D and 3D brachytherapy planning they defined reference dose points, active source positions and dwell times individually. This technique decreased the mean skin dose with 22.2% and reduced the possibility of geographical miss. The best conformity between the planning target volume and the treated volume with the CT-image was achieved by 3D treatment planning, however at the cost of worse dose homogeneity. The mean treated volume was reduced by 25.1% with semi 3D planning, however, it was increased by 16.2% with 3D planning, compared to the 2D planning. Authors concluded that the application of clips into the tumor bed and the conformal (semi 3D and 3D) planning help to avoid geographical miss. CT is suitable for 3D brachytherapy planning. Better local control with fewer side effects might be achieved with these new techniques. Conformal 3D brachytherapy calls for new treatment planning concepts, taking the irregular 3D shape of the target volume into account. The routine clinical application of image-based 3D brachytherapy is a real aim in the very close future (Polgar et al., 2000). In conclusion, in breast BT, CT-based PTV definition and implant simulation can be effectively used to obtain improved dose distribution regarding PTV coverage, dose homogeneity and conformality, and dose to OARs (e.g. skin, lung, and heart for left sided tumors). Much better PTV coverage can be achieved with CT image-based implant technique than with conventional one. These dosimetric results reinforce that image-guided BT planning for breast implants can be effectively used to improve dose delivery regarding both target coverage and dose homogeneity, which may turn into improved clinical results.

6. Head and neck cancers

There is limited clinical evidence supporting the routine use of CT image guidance for BT planning of interstitial implants in the H&N region (e.g. oral cavity and base of tongue). Organ (and tumor) motion during implantation limits the possible advantages of preimplant cross-sectional imaging in PTV definition. Thus, clinical examination (palpation) remains the basic element for definition of the target volume for H&N implants. However, CT images are useful to control the dose to OARs for example to avoid radionecrosis of the mandible.

Takácsi-Nagy et al. examined the feasibility and efficacy of interstitial HDR brachytherapy in the treatment of carcinoma of the tongue base (Takácsi-Nagy et al., 2004). Extent of the disease was diagnosed by clinical and computed tomography (CT). Brachytherapy treatment planning was performed by the use of two postimplant isocentric X-ray films or CT images. CT images made possible calculation of the coverage index, which is the fraction of the target volume receiving a dose equal to or greater than the prescribed dose. One of the important conclusions was that successful radiation therapy of base of tongue carcinomas requires total dose above 70 Gy, which, however, increases the risk of osteoradionecrosis and xerostomia. In those locations CT-image based planning reduces this risk.

Another authors analyzed usefulness of CT-imaging in salvage brachytherapy for cervical recurrences of head and neck cancer (Pellizzon et al., 2006). For HDR planning and reconstruction, CT scans were used in order to calculate exactly the dose distribution to the target volume and adjacent healthy tissues. In GEC-ESTRO recommendations we can read, that CT-guided pre-treatment work-up is useful (Mazeron et al., 2009). The CT scan depicts both soft tissue and bone, and is more sensitive than MRI for evaluating lymph nodes. This is the reason for use CT in cases of treatment planning of recurrences in irradiated neck area. Example of CT-image guided brachytherapy is presented in figure 9.

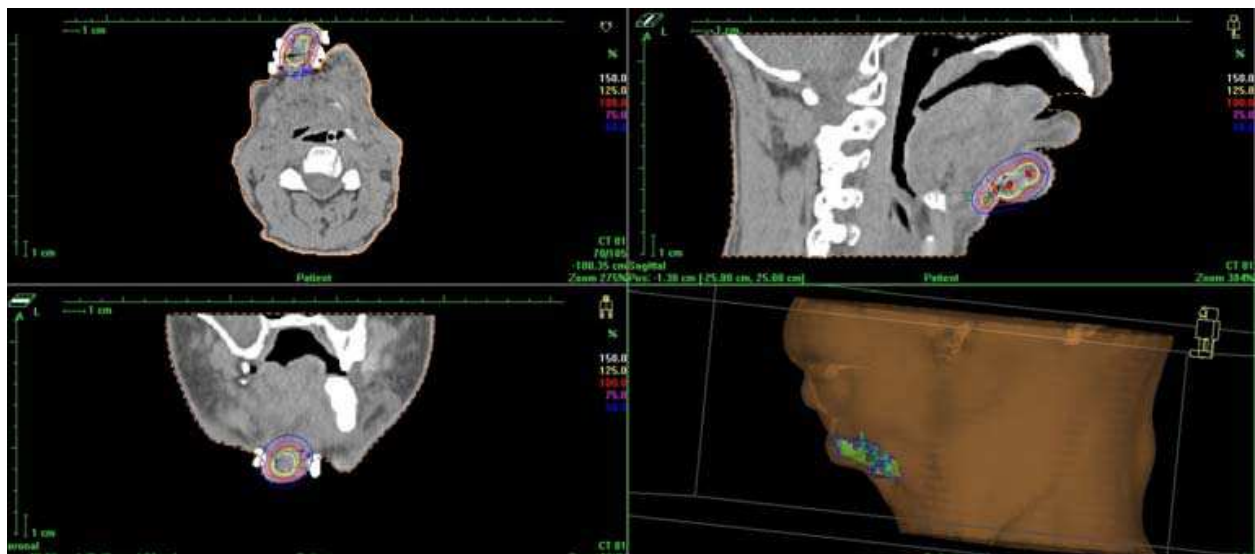

Fig. 9. Head and Neck cancer - CT-image based treatment plan. Tumor (recurrence in lymph node system) is located in chin region. (a) Para-transverse image at the level of the tumor, (b) Para-coronal image and (c) Para-sagittal image. On (d) 3D-visualisation of application is presented.

7. Sarcomas

In 1994 Griffin et al. presented one of the first experiences of using CT-image guided BT. A technique was presented for computer tomography - guided interstitial catheter placement and treatment planning for high-dose-rate brachytherapy. In a 66-year-old woman with adenocarcinoma of unknown origin that had metastasized to the right ilium, interstitial brachytherapy catheters were placed by means of CT guidance. With use of a treatment planning system with dose optimization, an excellent dose distribution was obtained with minimal dose being delivered to the surrounding critical tissues. Authors concluded that for selected patients, this procedure can provide effective and safe local treatment for solid tumors.

Report published by the American Brachytherapy Society (ABS) presents guidelines for the use of brachytherapy for patients with soft tissue sarcoma (Nag et al., 2001). Brachytherapy used alone or in combination with external beam irradiation is an established means of safely providing adjuvant local treatment after resection for soft tissue sarcomas in adults and in children. Brachytherapy options include low dose rate techniques with iridium 192 or iodine 125, fractionated high dose rate brachytherapy, or intraoperative high dose rate therapy. Recommendations are made for patient selection, techniques, dose rates, and dosages. In treatment planning they recommended the cross-section imaging (CT or MRI) which allows for the 3D reconstruction of catheter position and sources within. This approach minimizes errors and furthermore permits 3D treatment planning and dose distribution.

8. Lung cancer and other tumors

There are few reports concerning the use of CT in brachytherapy of lung cancer. Lagerwaard et al. investigated the consequences of using different dose prescription methods for endobronchial brachytherapy (EB), both with and without the use of a centered applicator. A CT scan was performed during EB procedures in 13 patients after insertion of the lung applicator. A dosimetric analysis was subsequently performed in five of these patients using a 3D-brachytherapy treatment planning system (PLATO v13.3®, Nucletron). CT images made possible confirmation of the rapid dose fall-off in EB mucosal dose prescription which should be used with caution in curative treatments where EB, without additional external radiotherapy, was used as the sole treatment modality (Lagerwaard et al., 2000). The CT measurements of the diameter of the different bronchial segments generally correlated well with the calculated values.

In another paper Senan et al. described a CT-based planning method which, by improving target volume definition and volumetric dose information, can improve the therapeutic ratio of EB (Senan et al., 2000). Sixteen CT-assisted EB procedures were performed in patients who were treated with palliative high-dose-rate EB. The CT data were used to analyze applicator position in relation to anatomy. An example of a three-dimensional optimized treatment plan was generated and analyzed using different types of dose-volume histograms. Authors initial experience highlights both the potential benefits and limitations of using "CT-assisted EB", which we have defined as EB characterized by the following: 1. use of CT imaging to supplement the findings of bronchoscopy, particularly in determining the distal extent of the target volume; 2. visualization of the position of the applicator in relation to the target volume; 3. facilitation of dose prescription to the bronchial mucosa by

identifying the position of branching of the different subsegments of the bronchial tree and allowing the use of actual measurements of the diameter of each segment; 4. generation of a 3D dosimetric database for correlation with toxicity. Authors concluded that: CT-assisted EB was feasible and underlines the need for using centered applicators for proximally located tumors. By enabling accurate mucosal dose prescription, CT-assisted EB may reduce the toxicity of fractionated EB in the curative setting. However, faster online EB treatment planning is needed for the routine clinical application of this technique (Senan et al., 2000).

In their review article Jansen et al. analyzed usefulness of CT-imaging in treatment planning of brain tumors. They mentioned that delineation of the clinical target volume (CTV) in radiation treatment planning of high-grade glioma is a controversial issue. The use of CT has greatly improved the accuracy of tumor localization in 3D planning. Their review aims at critically analyzing available literature data in which tumor extent of high-grade glioma has been assessed using CT and/or MRI and relating this to postmortem observations. Attention was given to the pattern of tumor spread at initial presentation and to tumor recurrence pattern after external beam irradiation. Special emphasis was given to the site of tumor regrowth after radiation treatment in relation to the boundaries of the CTV. Guidelines for delineating CTV were inferred from this information, taking data on radiation effects on the normal brain into account (Jansen et al., 2000). Hochberg & Pruitt were among the first to demonstrate the value of CT in radiation treatment planning of gliomas. But, they research another subject. They related CT scans in 127 untreated GBM patients with postmortem examination and found that only 3% had multicentric GBM at presentation (Hochberg & Pruitt, 1980). In another study by the same group on 15 patients, CT and postmortem findings were related to the intended radiation treatment plan (Halperin et al., 1989). Studies on CT focused also on reports in which tumor delineation assessed with CT and/or MRI were correlated with documented recurrence patterns after radiation treatment. Accordingly, in a study of 42 patients treated with WBI and followed up with serial CT scanning, 90% of the cases showed tumor recurrence within a 2-cm margin of the primary site (Hochberg & Pruitt, 1980). A similar recurrence pattern was observed after WBI with a cone-down boost field (Gaspar et al., 1992). This results where the basis for limiting the fields in 3D external beam radiation therapy.

In rectal cancer there is an interest in CT-guided needle insertion into tumor or tumor bed. Sakurai et al. described developing of high-dose-rate (HDR) conformal interstitial brachytherapy by means of combined CT-fluoroscopy guidance with CT-based treatment planning for locally recurrent rectal carcinoma. They concluded that CT fluoroscopy guidance ensures safety and increases the accuracy of needles placement in brachytherapy. Conformal high-dose-rate (HDR) interstitial brachytherapy with CT-based treatment planning is a method worth considering for locally recurrent rectal cancer (Sakurai et al., 2004).

9. Conclusions

The target volume is currently generally defined using radiologic imaging (e.g., plane radiography, CT, MRI). The improvements required include increased tissue resolution; improved boundary definition; functional imaging (i.e., PET); and antibody-based imaging. Radiographs are conventionally used for source localization and calculation of the dose distribution around brachytherapy applicators, whether they are placed manually or with a computerized treatment planning system. The doses to normal tissues such as the bladder

and the rectum have traditionally been calculated from the implant localization films with contrast in the bladder or catheter bulb and a radiopaque marker or contrast in the rectum. The inability of the orthogonal film pair method to delineate organ boundaries diminishes the reliability of the normal tissue dose point determinations and compromises the understanding of the dose distributions to the non infiltrated soft tissues. An improvement in the spatial resolution may also bring about improved target volume definition of the imaging modality and fusion of various imaging modalities (e.g., transrectal ultrasonography with MRI or CT).

10. Acknowledgements

Author thanks Grzegorz Bieleńda, MSc from Greater Poland Cancer Centre, for preparing excellent figures from Oncentra Planning system (Nucletron®, Netherlands).

11. References

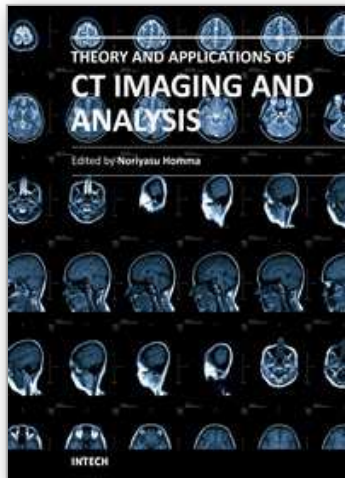
- Al-Halabi, H., Portelance, P., Duclos, M. et al. (2010). Cone Beam Ct-Based Three-Dimensional Planning In High-Dose-Rate Brachytherapy For Cervical Cancer. *Int J Radiat Oncol Biol Phys*; 77: pp 1092-1097.
- Al-Qaisieh, B., Ash, D., Bottomley, D.M. et al. (2002). Impact of prostate volume evaluation by different observers on CT-based post-implant dosimetry. *Radiother Oncol*; 62: pp 267-273.
- Barrett, A., Dobbs, J., Morris, S., et al. (2009). *Practical Radiotherapy Planning, 4th Edition*. Hodder Arnold, London. pp 15-19.
- Bellon, J., Wallner, K., Ellis, W. et al. (1999). Use of Pelvic CT Scanning to Evaluate Pubic Arch Interference of Transperineal Prostate Brachytherapy. *Int J Radiat Oncol Biol Phys*; 43: pp 579-581.
- Davidson, M.T.M., Yuen, J., D'Souza, D.P. et al. (2008). Image-guided cervix high-dose-rate brachytherapy treatment planning: Does custom computed tomography planning for each insertion provide better conformal avoidance of organs at risk? *Brachytherapy*; 7: pp 37-42.
- Frazier, R.C., Kestin, L.L., Kini, V., et al. (2001). Impact of boost technique on outcome in early-stage breast cancer patients treated with breast conserving therapy. *Am J Clin Oncol*; 24: pp 26-32.
- Gao, M., Albuquerque, K., Chi, A. et al. (2010). 3D CT-based volumetric dose assessment of 2D plans using GEC-ESTRO guidelines for cervical cancer brachytherapy. *Brachytherapy*; 9: pp 55-60.
- Gaspar, L.E., Fisher, B.J. & Macdonald, D.R. (1992). Supratentorial malignant glioma: patterns of recurrence and implications for external beam local treatment. *Int J Radiat Oncol Biol Phys*; 24: pp 55-57.
- Gerbaulet, A., Pötter, R., Mazeron, J.J. et al. (2002). *The GEC ESTRO Handbook of Brachytherapy*. Brussels. pp 435-454.
- Griffin, P.C., Amin, P.A., Hughes, P. et al. (1994). Pelvic Mass: CT-guided Interstitial Catheter Implantation with High-Dose-Rate Remote Afterloader. *Radiology*; 191: pp 581-583.
- Haie-Meder, C., Pötter, R., Van Limbergen, E. et al. (2005). Recommendations from Gynaecological (GYN) GEC-ESTRO Working Group (I): Concepts and terms in 3D

- image based 3D treatment planning in cervix cancer brachytherapy with emphasis on MRI assessment of GTV and CTV. *Radiother Oncol*; 74: pp 235-245.
- Halperin, E.C., Bentel, G., Heinz, E.R. et al. (1989). Radiation therapy treatment planning in supratentorial glioblastoma multiforme: an analysis based on post mortem topographic anatomy with CT correlations. *Int J Radiat Oncol Biol Phys*; 17: pp 1347-1350.
- Hammer, J., Mazon, J.J & van Limbergen, E. (2001). Breast boost - Why, how, when? *Strahlenther Onkol*; 175: pp 478-483.
- Hellebust, T.P., Kirisits Ch., Berger D. et al. (2010). Recommendations from Gynaecological (GYN) GEC-ESTRO Working Group: Considerations and pitfalls in commissioning and applicator reconstruction in 3D image-based treatment planning of cervix cancer brachytherapy. *Radioth Oncol*; 96: pp 153-160.
- Hellebust, T.P., Tanderup, K., Bergstrand, E.S. et al. (2007). Reconstruction of the ring applicator set using CT imaging; impact of reconstruction method and applicator orientation. *Phys Med Biol*; 52: pp 4893-4904.
- Hochberg, F.H. & Pruitt, A. (1980). Assumptions in the radiotherapy of glioblastoma. *Neurology*; 30: pp 907-911.
- Jansen, J.P.M., Dewit, L.G.H., van Herk, M. et al. (2000). Target volumes in radiotherapy for high-grade malignant glioma of the brain. *Radiother Oncol*; 56: pp 151-156.
- Kolotas, Ch., Baltas, D & Zamboglou N. (1999). CT-Based Interstitial HDR Brachytherapy. *Strahlenther Onkol*; 175: pp 419-427.
- Kubaszewska, M., Dymnicka, M., Skowronek, J., et al. (2008). CT-image based conformal High Dose Rate Brachytherapy boost in the conservative treatment of stage I -II breast cancer - introducing the procedure. *Rep Pract Radioth Oncol*; 5: pp 227 - 239.
- Lagerwaard, F.J., Murrer, L.H.P., de Pan, C. et al. (2000). Mucosal Dose Prescription in Endobronchial Brachytherapy: A Study Based On CT-Dosimetry. *Int J Radiat Oncol Biol Phys*; 46: pp 1051-1059.
- Van Limbergen, E., Van den Bogaert, W., Van der Schueren, E., et al. (1987). Tumor excision and radiotherapy as primary treatment of breast cancer. Analysis of patient and treatment parameters and local control. *Radiother Oncol*; 8: pp 1-9.
- Ling, C., Schell, M., Working, K. et al. (1987). CT-assisted assessment of bladder and rectum dose in gynecological implants. *Int J Radiat Oncol Biol Phys*; 13: pp 1577-1582.
- Mazon, J.-J., Ardiet, J.-M., Haie-Méder, Ch. et al. (2009). GEC-ESTRO recommendations for brachytherapy for head and neck squamous cell carcinomas. *Radiother Oncol*; 91: pp 150-156.
- Merrick, G.S., Butler, W.M., Dorsey, A.T. et al. (1998). Influence of timing on the dosimetric analysis of transperineal ultrasound-guided prostatic conformal brachytherapy. *Rad Onc Invest*; 6: pp 182-190.
- Merrick, G.S., Butler, W.M., Dorsey, A.T. et al. (1999). The potential role of various dosimetric quality indications in prostate brachytherapy. *Int J Radiat Oncol Biol Phys*; 44: pp 717-724.
- Merrick, G.S., Butler, W.M., Dorsey, A.T. et al. (1999). The Dependence Of Prostate Postimplant Dosimetric Quality On Ct Volume Determination. *Int J Radiat Oncol Biol Phys*; 44: pp. 1111-1117.

- Mullokkandov, E. & Gejerman G. (2004). Analysis of Serial CT Scans to Assess Template and Catheter Movement in Prostate HDR Brachytherapy. *Int J Radiat Oncol Biol Phys*; 58: pp 1063–1071.
- Nag, S., Bice, W., de Wyngaert, K. et al. (2000). The American Brachytherapy Society recommendations for permanent prostate brachytherapy postimplant dosimetric analysis. *Int J Radiat Oncol Biol Phys*; 46: pp 221–230.
- Nag, S., Cardenas, H., Chang, S. et al. (2004). Proposed guidelines for image-based intracavitary brachytherapy for cervical carcinoma: Report from Image-Guided Brachytherapy Working Group. *Int J Radiat Oncol Biol Phys*; 60: pp 1160–1172.
- Nag, S., Shasha, D., Janjan, N. et al. for The American Brachytherapy Society. (2001). The American Brachytherapy Society Recommendations for Brachytherapy of Soft Tissue Sarcomas. *Int J Radiat Oncol Biol Phys*; 49: pp 1033–1043.
- Nag, S., Shi, P., Liu, B. et al. (2008). Comparison of Real-Time Intraoperative Ultrasound-Based Dosimetry with Postoperative Computed Tomography-Based Dosimetry for Prostate Brachytherapy. *Int J Radiat Oncol Biol Phys*; 70: pp 311–317.
- Pellizzon, A.C.A., Salvajoli, J.V., Kowalski, L.P. et al. (2006). Salvage for cervical recurrences of head and neck cancer with dissection and interstitial high dose rate brachytherapy. *Radiation Oncology*; 1: pp 27–32.
- Polgar, C., Fodor, J., Orosz, Z., et al. (2002). Electron and high-dose-rate brachytherapy boost in the conservative treatment of stage I-II breast cancer: First results of the randomized Budapest boost trial. *Strahlenther Onkol*; 178: pp 615–623.
- Polgár, C., Major, T., Somogyi, A. et al. (2000). CT-image based conformal brachytherapy of breast cancer: the significance of semi-3D and 3-D treatment planning. *Strahlenther Onkol*; 176: pp 118–124.
- Pötter, R., Haie-Meder, C., Van Limbergen, E. et al. (2006). Recommendations from gynaecological (GYN) GEC ESTRO working group (II): Concepts and terms in 3D image-based treatment planning in cervix cancer brachytherapy-3D dose volume parameters and aspects of 3D image-based anatomy, radiation physics, radiobiology. *Radiother Oncol*; 78: pp 67–77.
- Prestidge, B.R., Bice, W.S., Kiefer, E.T. et al. (1998). Timing of computed tomography based post-implant assessment following permanent transperineal prostate brachytherapy. *Int J Radiat Oncol Biol Phys*; 40: pp 1111–1115.
- Roach, M., Faillace-Akazawa, P., Malfatti, C. et al. (1996). Prostate volumes defined by magnetic resonance imaging and computerized tomographic scans for three-dimensional conformal radiotherapy. *Int J Radiat Oncol Biol Phys*; 35: pp 1011–1018.
- Sakurai, H., Mitsuhashi, N., Harashima, K. et al. (2004). CT-fluoroscopy guided interstitial brachytherapy with image-based treatment planning for unresectable locally recurrent rectal carcinoma. *Brachytherapy*; 3: pp 222–230.
- Senan, S., Lagerwaard, F.J., de Pan, C. on behalf of the Rotterdam Oncological Thoracic Study Group. (2000). A CT-assisted method of dosimetry in brachytherapy of lung cancer. *Radiother Oncol*; 55: pp 75–80.
- Shin, K.H., Kim, T.H., Cho, J.K. et al. (2006). CT-guided intracavitary radiotherapy for cervical cancer: Comparison of conventional Point A plan with clinical target volume-based three-dimensional plan using dose-volume parameters. *Int J Radiat Oncol Biol Phys*; 64: pp 197–204.

- Takácsi-Nagy, Z., Polgár, C., Oberna, F. et al. (2004). Interstitial High-Dose-Rate Brachytherapy in the Treatment of Base of Tongue Carcinoma. *Strahlenther Onkol*; 180: pp 768–775.
- Vicini, F.A., Horwitz, E.M., Lacerda, M.D. et al. (1997). Long term outcome with interstitial brachytherapy in the management of patient with early breast cancer treated with breast conserving therapy. *Int J Radiat Oncol Biol Phys*; 37: pp 845-852.
- Vicini, F.A., Jaffray, D.A., Horwitz, E.M. et al. (1998). Implementation of 3D-virtual brachytherapy in the management of breast cancer: a description of a new method of interstitial brachytherapy. *Int J Radiat Oncol Biol Phys*; 40: pp 629-635.
- Viswanathan, A.N. & Erickson, B. (2010). Three-Dimensional Imaging in Gynecologic Brachytherapy: A Survey of the American Brachytherapy Society. *Int J Radiat Oncol Biol Phys*; 76: pp 104–109.
- Viswanathan, A.N., Dimopoulos, J., Kirisits, C. et al. (2007). Computed tomography versus magnetic resonance imaging-based contouring in cervical cancer brachytherapy: Results of a prospective trial and preliminary guidelines for standardized contours. *Int J Radiat Oncol Biol Phys*; 68: pp 491–498.
- Wang, B., Kwon, A., Zhu, Y. et al. (2009). Image-guided intracavitary high-dose-rate brachytherapy for cervix cancer: A single institutional experience with three-dimensional CT-based planning. *Brachytherapy*; 8: pp 240-247.
- Wallner, K., Roy, J. & Harrison, L. (1995). Dosimetry guidelines to minimize urethral and rectal morbidity following transperineal I-125 prostate brachytherapy. *Int J Radiat Oncol Biol Phys*; 32: pp 465–471.
- Willins, J. & Wallner, K. (1997). CT based dosimetry for transperineal I-125 prostate brachytherapy. *Int J Radiat Oncol Biol Phys*; 39: pp 347–353.
- Waterman, F., Yue, N., Cord, B.W. et al. (1998). Edema associated with ^{125}I or ^{103}Pd prostate brachytherapy and its impact on post-implant dosimetry: An analysis based on serial CT acquisition. *Int J Radiat Oncol Biol Phys*; 41: pp 1069–1077.

IntechOpen



Theory and Applications of CT Imaging and Analysis

Edited by Prof. Noriyasu Homma

ISBN 978-953-307-234-0

Hard cover, 290 pages

Publisher InTech

Published online 04, April, 2011

Published in print edition April, 2011

The x-ray computed tomography (CT) is well known as a useful imaging method and thus CT images have continually been used for many applications, especially in medical fields. This book discloses recent advances and new ideas in theories and applications for CT imaging and its analysis. The 16 chapters selected in this book cover not only the major topics of CT imaging and analysis in medical fields, but also some advanced applications for forensic and industrial purposes. These chapters propose state-of-the-art approaches and cutting-edge research results.

How to reference

In order to correctly reference this scholarly work, feel free to copy and paste the following:

Janusz Skowronek (2011). CT-Image Guided Brachytherapy, Theory and Applications of CT Imaging and Analysis, Prof. Noriyasu Homma (Ed.), ISBN: 978-953-307-234-0, InTech, Available from: <http://www.intechopen.com/books/theory-and-applications-of-ct-imaging-and-analysis/ct-image-guided-brachytherapy>

INTECH
open science | open minds

InTech Europe

University Campus STeP Ri
Slavka Krautzeka 83/A
51000 Rijeka, Croatia
Phone: +385 (51) 770 447
Fax: +385 (51) 686 166
www.intechopen.com

InTech China

Unit 405, Office Block, Hotel Equatorial Shanghai
No.65, Yan An Road (West), Shanghai, 200040, China
中国上海市延安西路65号上海国际贵都大饭店办公楼405单元
Phone: +86-21-62489820
Fax: +86-21-62489821

© 2011 The Author(s). Licensee IntechOpen. This chapter is distributed under the terms of the [Creative Commons Attribution-NonCommercial-ShareAlike-3.0 License](#), which permits use, distribution and reproduction for non-commercial purposes, provided the original is properly cited and derivative works building on this content are distributed under the same license.

IntechOpen

IntechOpen